



## Mature Cystic Teratoma of Adrenal Gland (Adrenal Teratoma)

Parvin Mahzouni<sup>1</sup>, Behnaz Sabaghi<sup>1</sup>, Behnam Sanei<sup>2</sup>, Elham Arjang<sup>3</sup>

1- Department of Pathology, School of Medicine, Isfahan University of Medical Sciences, Isfahan, Iran

2- Department of General Surgery, School of Medicine, Isfahan University of Medical Sciences, Isfahan, Iran

3- Department of Pathology, School of Dentistry, Isfahan University of Medical Sciences, Isfahan, Iran

Received: 29 May 2016

Revised: 2 July 2016

Accepted: 25 September 2016

### ARTICLE INFO

Corresponding author:  
Behnaz Sabaghi

Email:  
[sabaghi\\_beh@yahoo.com](mailto:sabaghi_beh@yahoo.com)

Keywords:  
Matureteratoma;  
Primary teratoma;  
Adrenal gland

### ABSTRACT

We report a very rare case of benign mature cystic teratoma involving the right adrenal gland in a 14-year-old female.

**Citation:** Mahzouni P, Sabaghi B, Sanei B, Arjang E. **Mature Cystic Teratoma of Adrenal Gland (Adrenal Teratoma)**. Case Rep Clin Pract 2016; 1(3): 71-3.

### Introduction

Incidence of germ cell tumors has been estimated at about 0.9/100,000 population and of this teratoma has been reported as the leading fetal and neonatal neoplasm (1, 2).

Primary teratomas in the retroperitoneum are very rare in children and primary adrenal teratomas are extremely rare (3).

Most teratomas in this region are secondary to germ cell tumors of the testicles or ovaries. Retroperitoneal germ cell tumors are more likely to have metastasized from the testes

than to present as primary tumors (2).

### Case Report

A 14-year-old female without a medical history presented with loss of appetite, fatigue, and right flank pain. Physical examination revealed a palpable mass in the right flank. All laboratory tests were unremarkable except for anemia. Contrast-enhanced computed tomography (CT) scan showed a large multilocular cyst with thin septation as well as fat collection in the region of the right adrenal gland. The other

incidental radiologic finding a simple cyst in the liver.

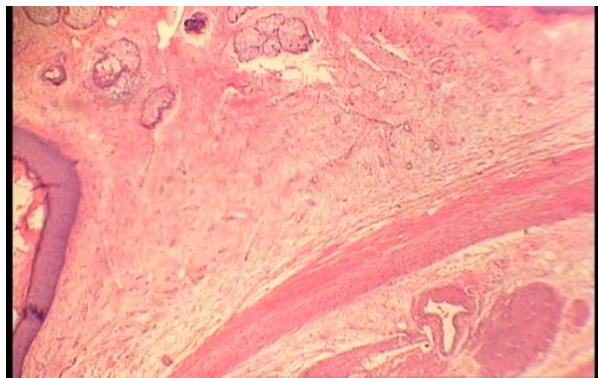
The patient underwent complete surgical resection of the right adrenal mass, a part of the right kidney, liver cyst, and retroperitoneal lymph nodes. All of the specimens were sent for pathologic examination. Grossly, the right adrenal mass weighted 400 g and measured 8.0 cm × 8.0 cm × 6.0 cm. The mass composed of a large cyst with sebaceous material and hair network. Some part of cyst wall had cartilaginous consistency (Figure 1).



**Figure 1.** Gross appearance of mature cystic teratoma of adrenal gland

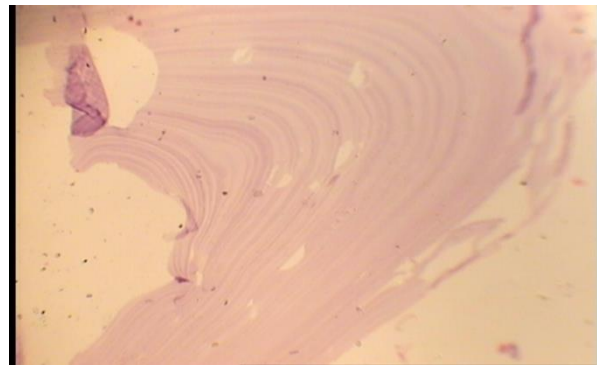
The liver cyst consists of multiple fragments of shiny white tissue. The greatest diameter of retroperitoneal lymph nodes was 1.5 cm, and there was no gross abnormality in kidney cut surface.

In microscopic examination, the adrenal cyst was lined by keratinizing squamous epithelium (Figure 2).



**Figure 2.** Micrograph of mature cystic teratoma of adrenal gland

It showed sebaceous glands, hair follicles, fat tissue, and calcification. Acute and chronic inflammation with foreign body reaction adjacent to cyst wall was also noted. The liver cyst was hydatid cyst (Figure 3).



**Figure 3.** Liver hydatid cyst (laminated layer)

## Discussion

Teratomas are germ cell tumors derived from totipotential cells which can differentiate in to all three embryonic layers: Ectoderm, mesoderm, and endoderm (4).

These tumors are subdivided into mature, immature, and malignant. Most teratomas are found in the gonads, but many extragonadal sites have been reported. In general, teratomas that occur in infancy and early childhood are usually extragonadal, whereas those found in older children are more commonly discovered in the gonads. The extragonadal sites have been reported are mediastinum, retroperitoneum, cranium, sacrococcygeal region, the large bowel, and the tongue (5-7).

The retroperitoneal teratomas are the rarest of the teratomas and those involving the adrenal glands are extremely rare and accounting for 4% of all primary teratomas.

The majority of patient with adrenal teratomas are asymptomatic, but some complaint of abdominal or flunk pain or identified incidentally by CT, magnetic resonance imaging, or sonography.

The differential diagnosis of retroperitoneal teratomas includes myelolipoma, renal cyst, Wilm's tumor, congenital mesoblastic nephroma, lymph nodes, and abscess (8-11).

The prognosis is excellent for benign mature teratomas of adrenal if complete resection can be done (12, 13).

The coincidental event in our case was hydatid cyst of the liver. The best treatment for our patient was total resection of teratoma and hydatid cyst of liver in the same surgery time (14, 15).

### Conflict of Interests

Authors have no conflict of interests.

### Acknowledgments

None.

### References

- Gobel U, Schneider DT, Calaminus G, Haas RJ, Schmidt P, Harms D. Germ-cell tumors in childhood and adolescence. GPOH MAKEI and the MAHO study groups. *Ann Oncol* 2000; 11(3): 263-71.
- Isaacs H Jr. Perinatal (fetal and neonatal) germ cell tumors. *J Pediatr Surg* 2004; 39(7): 1003-13.
- James J, Dhillon GS, Blewett CJ, Halldorsson A, Cecalupo AJ. A large adrenal teratoma in a neonate. *Am Surg* 2009; 75(4): 347-9.
- Rosai J. Peritoneum, retroperitoneum, and related structures. In: Rosai J, Editor. *Rosai and Ackerman's surgical pathology*. Philadelphia, PA: Elsevier Health Sciences; 2011. p. 2258-9.
- Rosai J. Liver. In: Rosai J, Editor. *Rosai and Ackerman's surgical pathology*. 10<sup>th</sup> ed. Philadelphia, PA: Elsevier Health Sciences; 2011. p. 915.
- Gschwend J, Burke TW, Woodward JE, Heller PB. Retroperitoneal teratoma presenting as an abdominal-pelvic mass. *Obstet Gynecol* 1987; 70(3 Pt 2): 500-2.
- Selimoglu E, Ozturk A, Demirci M, Erdogan F. A giant teratoma of the tongue. *Int J Pediatr Otorhinolaryngol* 2002; 66(2): 189-92.
- Ratan SK, Ratan J, Kalra R. Large benign cystic teratoma of the mesosigmoid causing intestinal obstruction: report of a case. *Surg Today* 2002; 32(10): 922-4.
- Engel RM, Elkins RC, Fletcher BD. Retroperitoneal teratoma. Review of the literature and presentation of an unusual case. *Cancer* 1968; 22(5): 1068-73.
- Nirgiotis JG, Black CT, Sherman JO. Wilms' tumor in horseshoe kidney: presentation due to ureteropelvic junction obstruction. *J Surg Oncol* 1991; 48(3): 210-2.
- Chen WY, Lin CN, Chao CS, Yan-Sheng Lin M, Mak CW, Chuang SS, et al. Prenatal diagnosis of congenital mesoblastic nephroma in mid-second trimester by sonography and magnetic resonance imaging. *Prenat Diagn* 2003; 23(11): 927-31.
- Richards ML, Gundersen AE, Williams MS. Cystic neuroblastoma of infancy. *J Pediatr Surg* 1995; 30(9): 1354-7.
- Pandya JS, Pai MV, Muchhala S. Retroperitoneal teratoma presenting as acute abdomen in an elderly person. *Indian J Gastroenterol* 2000; 19(2): 89-90.
- Ding Q, Zhu Y, Liang W. Adrenal teratoma: a case report and literature review. *Chinese J Androl* 2008; 10: 40-3.
- Ariogul O, Emre A, Alper A, Uras A. Introflexion as a method of surgical treatment for hydatid disease. *Surg Gynecol Obstet* 1989; 169(4): 356-8.