

We are IntechOpen, the world's leading publisher of Open Access books Built by scientists, for scientists

5,900

Open access books available

145,000

International authors and editors

180M

Downloads

Our authors are among the

154

Countries delivered to

TOP 1%

most cited scientists

12.2%

Contributors from top 500 universities



WEB OF SCIENCE™

Selection of our books indexed in the Book Citation Index
in Web of Science™ Core Collection (BKCI)

Interested in publishing with us?
Contact book.department@intechopen.com

Numbers displayed above are based on latest data collected.
For more information visit www.intechopen.com



Maxillary Sinus Augmentation for Dental Implants

Gökhan Göçmen and Yasar Özkan

Additional information is available at the end of the chapter

<http://dx.doi.org/10.5772/intechopen.69063>

Abstract

Pneumatization of the maxillary sinus secondary to posterior maxillary tooth loss is an extremely common finding. Significant atrophy of the maxilla prevents dental implant placement in this region. Grafting the floor of the maxillary sinus has emerged as the most common surgical modality for correcting this inadequacy. Graft material is introduced into the space created inferior to the sinus membrane. Various grafting materials and techniques might be used in this procedure. The aim of this article is to review the essentials of maxillary sinus augmentation, clarify this procedure for otolaryngologists, explain its function, and describe the augmentation materials, techniques, and complications.

Keywords: maxillary, sinus, augmentation, dental, implant

1. Introduction

Paranasal sinuses are important anatomical structures in both medicine and dentistry. The maxillary sinus is the most relevant to dental practitioners due to its proximity to the posterior maxillary teeth. Dentists are often required to make a diagnosis concerning orofacial pain that may be sinogenic in origin. Maxillary sinus diseases can be observed coincidentally on radiographs from routine dental examinations and considered in differential diagnosis. Therefore, most dentists unintentionally take a look at the maxillary sinus of their patients.

The maxillary sinus or antrum of Highmore is generally avoided during dental surgeries. Communication or the development of space, between the maxillary sinus and the buccal cavity (oroantral) or between the nasal and buccal cavities (oronasal), has always been considered an undesired issue but is accepted as a complication when encountered after tooth extraction or any other oral-surgical procedure [1]. Disintegration or perforation of the sinus membrane is an unwelcome incident because of the need for additional surgeries.

In the instance of chronic oroantral fistula occurrence, the established fistula enables the passage between the oral cavity and the maxillary sinus. Consequently, the microbial flora can exchange and inflammation may occur with various possible consequences. This simple complication might lead to major problems, be handled easily, or recover spontaneously. Therefore, oral and maxillofacial surgeons are always careful about complications associated with the maxillary sinus. Furthermore, in general, otolaryngologists, leading physicians in paranasal sinus diseases, prefer to avoid direct contact with the sinus. Thus, an open trans-antral approach (the Caldwell-Luc operation) is rarely performed compared to less invasive endoscopic approaches, except for occasional situations [2]. Conversely, almost every dental implant practitioner interferes directly with the maxillary sinus or its neighboring parts in the alveolar bone and performs surgeries within close proximity to the antrum of Highmore. In particular, maxillary sinus augmentation has become one of the most popular dental procedures performed.

Maxillary sinus augmentation is a procedure that aims to increase the vertical bone height of the alveolar bone to allow placement of dental implants. For more than 30 years, the maxillary sinus augmentation procedure has been performed for implant-directed maxillary reconstruction [3]. There are various techniques, approaches, and materials used in this procedure. The purpose of this chapter is to review the essentials of maxillary sinus augmentation, clarify this procedure for otolaryngologists, explain its function, and describe the augmentation materials, techniques, and complications.

2. Assessment of alveolar bone quality for dental implants

Alveolar bone quantity and quality are the most important parameters primarily affecting the success of implant treatment. Sufficient bone support is the main requirement to gain osseointegration of implants. The buccolingual width is measured to predict the implant height. Allowing a bony distance in the apical region from the anatomical landmarks, such as the maxillary sinus, is also recommended. In addition to bone width and height, density is also critical for ensuring implant success [4]. It is important to place implants in locations with good primary stability, which cannot be acquired in regions with low bone density.

In addition to structure, a particular assessment of the available residual bone by morphological evaluation is crucial. Determinants of available bone might be listed as height, width, size, and incline [5]. Current advances in implant surface technologies revealed that implants of ~8–10-mm length provided long-term successful outcomes [6]. It is mandatory to have at least 1-mm buccal and lingual bony thickness adjacent to the implant [7]. For long-term success, implants should be inserted parallel to each other and to the adjacent teeth, to obtain the best stress distribution [8]. A detailed superstructure and prosthetic treatment plan should also be deliberated, considering occlusal forces, interocclusal distance, and interarch relations in the particular region [9]. Consequently, an alveolar bone assessment is performed not only to evaluate existing bone features and anatomy but also to estimate future dynamics in the overall treatment process, including prosthetic design, surrounding soft-tissue support, dental

hygiene of the patient, and socioeconomic considerations, which provide long-term esthetics and functional outcomes of implant rehabilitation [10].

Both clinical and radiologic examinations are essential for treatment planning. The judgment of the clinician in treatment planning is paramount because each clinical case is unique. The medical history of the patient and a physical examination should be performed before treatment planning. History of nasal, sinus or maxillary surgery, chronic sinus/facial pain, acute upper respiratory infection, smoking habit, and chronic sinus disease are important to note. Panoramic X-ray imaging is generally used because it provides adequate information about the associated region. However, particular findings in panoramic imaging might lead the clinician to request further imaging methods, such as computed tomography (CT) or cone beam-computed tomography (CBCT). These techniques allow evaluating the exact amount of bone beneath the sinus floor, the sinus buccopalatal width, the presence of septa, and any preexisting sinus disease. Thus, based on a detailed CBCT examination, the necessary precautions can be taken, possible complications prevented, or surgery can be abandoned.

2.1. Anatomy

The maxillary sinus grows rapidly during childhood until it reaches the level of the floor of the nose. It may reach approximately 10 mm below the nasal floor [11]. The apexes of the maxillary premolars and molars have a close association with the inferior border of the maxillary sinus. The maxillary sinus extends to the premolar area at the anterior border and the roof is formed by the orbital floor.

The maxillary sinus volume increases continuously as a person ages, which is called pneumatization. It generally occurs in an inferior direction, frequently fasten with tooth extraction, such as loss of maxillary premolar or molars. It is reported that maxillary sinus pneumatization increases after tooth extractions [12]. Alveolar bone loss in the region creates a unique problem for implant placement following extraction. The pneumatization process can eventually result in extreme thinning of the alveolar bone and leave an inadequate amount of bone in the region assigned for dental implants. The vertical bone loss might occur only between the alveolar ridge crest and floor of the sinus, due to the resorption process following tooth extraction. It might also occur, while maintaining the level at the alveolar ridge crest with ongoing resorption under the sinus floor, due to increased osteoclast activity within the periosteum side of the Schneiderian membrane, or a combination of both occurrences. Additionally, low density of the posterior maxillary region might contribute to all these resorption processes, resulting in contour or dimensional changes (**Figure 1**). Considering interocclusal distance, prosthetic planning, predicted implant height and width, and also the density of the remaining bone are essential for successful prosthetic rehabilitation. The morphology of a bony defect is an important consideration in selecting an augmentation method. Sinus volume and the height of the semilunar hiatus define the maximum amount of elevation level of the membrane. An excessive amount of grafting material within the sinus may cause problems in sinus ventilation. The amount of sinus volume needed to raise the sinus floor is decided according to all these parameters.

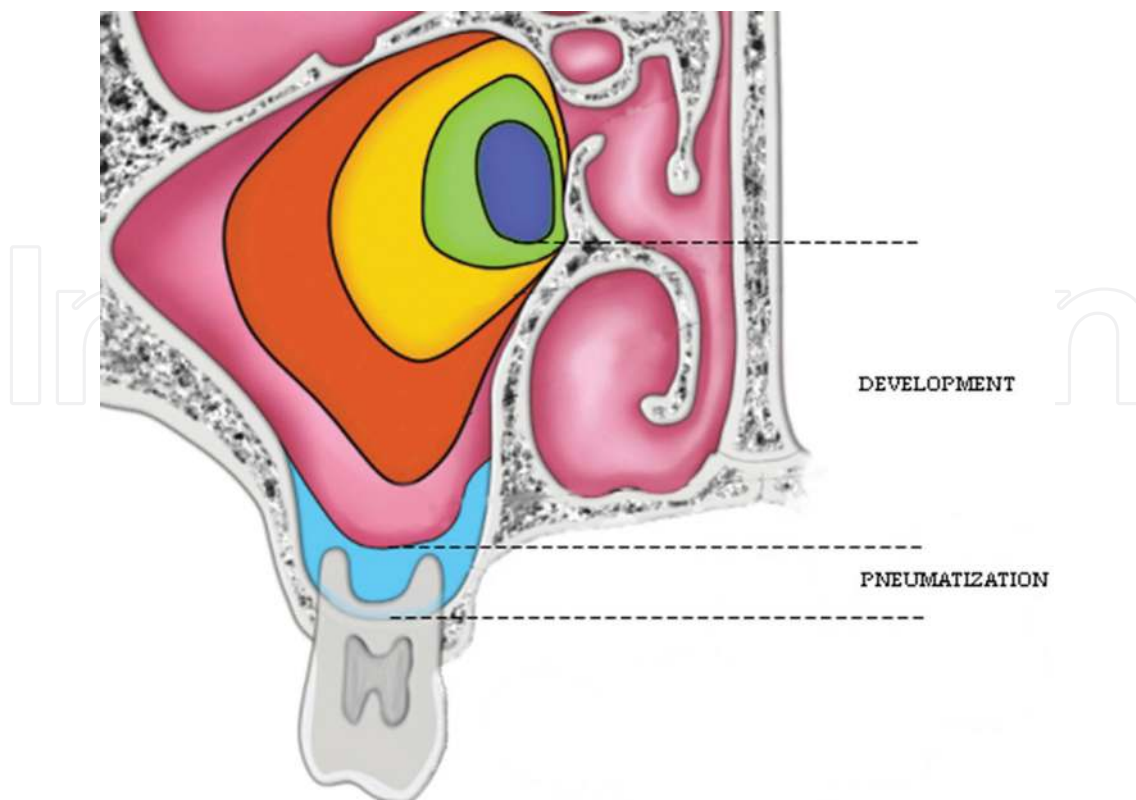


Figure 1. Pneumatization and development of maxillary sinus.

The Schneiderian membrane is a thin bilaminar mucoperiosteal membrane that lines the maxillary sinuses. One side of this membrane consists of epithelium, as per the remainder of the respiratory tract and nasal epithelium. The thin layer of pseudociliated stratified respiratory epithelium over the Schneiderian membrane establishes an important barrier for the protection and defense of the sinus cavity. The physiologic importance of the membrane cilia is to guide mucous discharge and debris toward the ostium so that in normal functioning, sinus drainage is constantly maintained. Some conditions, such as allergic rhinitis, dysfunctional sinus cilia, or sinusitis might lead to local swelling and blockage of the ostium; therefore, subsequent blockage of outflowing mucous discharge can cause complications after sinus lifting. The membrane is ~ 0.8 mm thick. [13] The sinus mucosa is less vascular and thinner than nasal mucosa. Elevation of the membrane is a delicate procedure. Maintenance of its integrity is essential for normal functioning of the sinus after surgery. Perforation of the sinus membrane is the most common complication that has been reported since the earliest reports on the procedure. Some anatomical variations, particularly those concerning the septa, might trigger such perforation [14].

The maxillary sinus septa were first described by Underwood [15]. Numerous variations of the maxillary sinus septa are described in the literature, such as the partial perpendicular septa, the partial horizontal septa, and the complete septation of the maxillary sinus by a complete vertical septum. The height and setting of the septa are also important because the septa can hinder the preservation of the membrane. Sometimes, the sinus can be divided into two or more compartments. In such instances, the inversion of the bone plate and elevation

of the Schneiderian membrane might be complicated. Septa generally arise between the areas of two adjacent teeth, and their formation might be promoted by the different phases of sinus pneumatization (**Figure 2**).

It is important to mention that a possible extraosseous anastomosis between the posterior superior alveolar artery and a terminal branch of the infraorbital artery might cause hemorrhage during flap elevation. An intraosseous anastomosis, by contrast, always occurs at a distance of 19–20 mm from the alveolar margin. If the intraosseous anastomosis is encountered during the preparation of the lateral bony window, hemorrhage might complicate the overall procedure.

2.2. Function

The aim of sinus floor elevation and augmentation is to create sufficient bone to house an implant with adequate stability. Pneumatization of the sinus results in an insufficient posterior maxillary alveolus. The adequate bone height and, thus, the moment when sinus floor elevation should be performed remain a controversial issue. Conversely, there are some other methods in which the sinus augmentation procedure is completely disregarded, such as using short implants, angulated implants, or distal cantilevers. All of these alternative methods are reported with long-term successful outcomes [16].

The requirement for maxillary sinus augmentation depends on the number of missing posterior teeth. If all premolars and molars are missing, it is more indispensable to perform sinus augmentation compared to a single missing molar or premolar tooth. The patient can choose to have a dental bridge restoration to replace a single missing tooth or two missing teeth. Moreover, patients missing all premolars and molars or do not have back teeth to support the bridge restoration might prefer a partial removable denture than maxillary sinus augmentation surgery [17].

The need for sinus augmentation is decided according to the size of the implant that is planned. Generally, implants are considered as short if it is smaller than 8 mm in height; therefore, it is expected that there should be >8 mm of subantral bone height to place the implants without sinus lifting. Various methods can be used while placing the implant in this region.

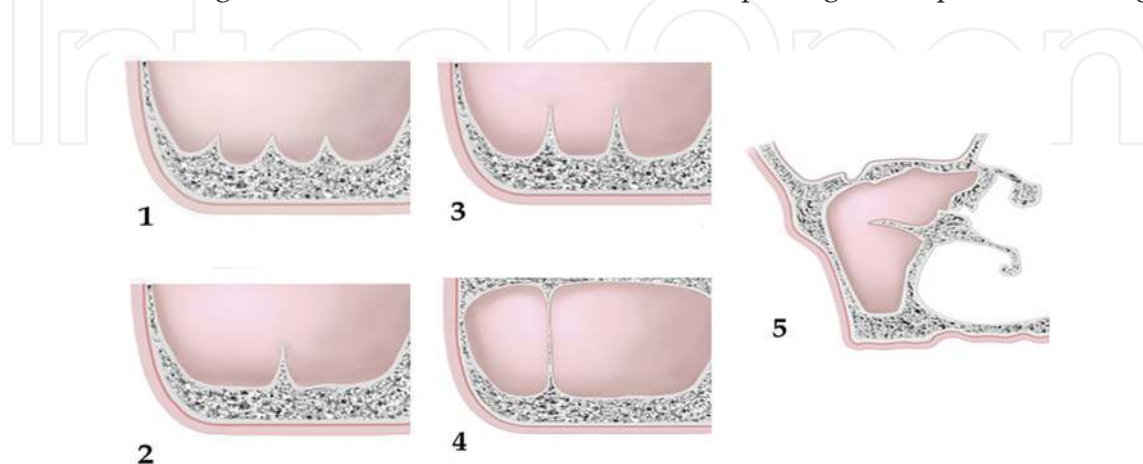


Figure 2. Possible variations of maxillary sinus septa. 1. Multiple septa, 2. Single septum, 3. Two basal septa, 4. Complete septum, 5. Partial horizontal septum.

The important point is to decide whether or not to interfere with the sinus when placing the implant. Essentially, it is important to have primary stabilization of the implant into the bone. For a successful osseointegration, the dental implant should be attached, or at least stay immobile, in the bone at the initial stages of the healing process. Based on these principles, the implant might be angulated to stay in the bone or shortened and thickened to increase the surrounding bony surface. However, it is well established that the implants should be placed parallel to each other in the long axis, as occurs in the natural roots.

2.3. Contraindication

The aim of maxillary sinus augmentation surgery is to place dental implants. Therefore, some contraindications with implant surgery are valid for sinus augmentation. Soft- and hard-tissue support of a predicted dental implant should be established before placement of a dental implant. Local or systemic conditions can compromise the bone healing and the osseointegration. Before planning sinus augmentation for dental implants, the patient's usual healing should be questioned and the sinus should be evaluated in detail. A sinus infection can directly affect the success of the sinus-lifting procedure. During the delicate lifting phase or following surgery, inflammatory fluid in the sinus can easily infiltrate to the augmented site and distract graft healing. Therefore, patients with acute sinus inflammation should be treated for their sinus disease. Smoking and chronic sinusitis can increase the risks associated with the sinus augmentation procedure. In smokers, the sinus membrane can be considerably thin and fragile, which contribute to ready laceration of the membrane during elevation. By contrast, chronic sinusitis and allergies may result in a thick membrane, which can also complicate membrane elevation. Any other finding associated with maxillary sinus disease requires consultation with an otolaryngologist during preoperative planning [18].

Uncontrolled diabetes, neoplasm, radiotherapy, or chemotherapy can also be considered contraindications to sinus augmentation for dental implants. Additionally, previous sinus surgeries or Le Fort I osteotomy may also be a contraindication because of the scar formation after surgery [19].

3. Graft materials used in maxillary sinus augmentation

Various materials have been used to graft the floor of the sinus and achieve the desired bone height. Grafting materials can be categorized based on their source, as autograft, xenograft, allograft, and alloplastic. These different types of grafting materials may be used alone or in any combination. Bone grafts heal by three different mechanisms: osteogenesis, osteoinduction, and osteoconduction. Osteogenesis is the ability to produce new bone. Osteoinduction is the process of stimulating osteogenesis. Finally, osteoconduction is the ability of a material to support the growth of bone over its surface. Grafting materials mostly use the mechanism of osteoconductivity to provide biomechanical support, stabilize the components during the healing phase, and establish the scaffold for new bone formation. The best graft healing should possess most of these mechanisms.

An autograft is considered as the golden standard for maxillary sinus augmentation. It has osteogenic, osteoinductive, and osteoconductive features. Furthermore, it has the best biocompatibility feature. However, it also has the disadvantage of donor-site morbidity. Extraoral or intraoral donor sites constitute a secondary surgical site and the risk of associated complications. They also have the highest rate of resorption. Autografts can be harvested from multiple sites. The amount of required bone amount is the main determinant for choosing the harvesting site. Donor-site morbidity and patient's preferences are the other important factors to consider when choosing the harvesting site. Intraoral mandibular symphysis, mandibular ramus, and tuberosity can present a moderate to small amount of bone for this procedure. Additional bone can be provided from any other intraoral-harvesting site or by adding some other source of ready-to-use graft material, such as xenograft or allograft if required. Autografts might be particulated using a bone mill or a bone grinder to spread the material out in the bony space or extend the volume. Particulated grafts can facilitate vascular infiltration, angiogenesis, bone matrix formation, and, thus, better healing. A mixture of the particulated bone chips with blood or platelet-rich fibrin can also enhance better bone matrix organization.

If additional autograft is needed or bilateral sinus augmentation is required or an additional onlay grafting is necessary, extraoral-harvesting sites, which present a significant amount of bone (~50 ml), can be used. Extraoral-harvesting sites can be ranked as providing the most amount of bone to relatively less: posterior ilium, anterior ilium, calvarium, and tibia. As expected, because of donor-site morbidity and requirement for more advanced surgeries, extraoral harvesting is not generally preferred by the patients. The calvarium has never been a priority harvesting site for a relatively simple bone augmentation surgery to place a dental implant. However, when other alternatives have failed and most of the donor sites had been attempted without success, it stands as an option. Complications at the donor sites after autogenous bone harvesting include infection, dental injury, pain, sensory disturbances, gait disturbance, and hernia, for example.

Allogeneic graft materials are also biocompatible and have some osteoconductive potential. They originate from humans and are acquired from tissue banks. However, the risk of disease transmission and high resorption rate are the main disadvantages of these graft materials. The mineralized form of these grafts is not preferred due to the slow bone formation rate, while demineralized forms are mostly preferred due to their bone morphogenic protein ingredients and associated osteoconductive feature. Alloplastic graft materials are made from hydroxyapatite, calcium phosphates, and bioactive glass. Also, they have a lower rate of resorption compared to autologous grafts. Xenografts are derived from a donor of a species different than the recipient. Deproteinized bovine bone is widely used in sinus augmentation surgery due to good osteoconductivity and can be used alone, or in combination with, other grafting materials.

All graft materials have different healing times, from 4 to 10 months. The resorption rate of the graft material is an important parameter in the sinus augmentation procedure because the volume of the graft will decrease if the material resorbs quickly. Waiting for the formation of qualified bone is critical to place the implant in the vital bone. Placement of implants can be performed earlier in such materials compared to non-resorbable materials. Alloplastic graft materials, calcium sulfate, and beta-tricalcium phosphate resorb quickly, while bioglass resorbs

considerably more slowly. Therefore, deciding the most appropriate time to place the implant according to the properties of the graft material is necessary. Autogenous bone and xenografts are reported to produce the most predictable and best results in sinus augmentation [20].

Knowing the features of the grafting material used plays a major role in the overall outcome and success of the grafting procedure. The posterior maxillary region and sinus membrane are rich in vasculature; therefore, grafting materials placed in these regions will have a rich blood supply. This regional advantage also enhances the osteoblastic activity of the augmented site. The importance of the membrane in the sinus-lift procedure should not be underestimated. It is reported that the Schneiderian membrane has the feature of inducing and increasing osteoprogenitor cells [21]. Various techniques are used to create a bony space for implant placement while maintaining the membrane intact to allow for graft nutrition and a barrier from the maxillary sinus cavity. Obtaining successful outcomes depends on multiple factors. Besides the unique anatomical features of every case, the surgeon's experience and the method used for augmentation are pivotal. Selecting the most proper technique for every individual case and applying sound surgical techniques at the appropriate surgical site are mandatory to obtain long-term successful outcomes.

4. Grafting techniques

Maxillary sinus lifting can be performed directly with lateral antrostomy under direct visualization or indirectly with the transalveolar approach. The amount of residual maxillary alveolar bone defines which approach to be used for sinus augmentation. Bone height below the sinus, alveolar bone width, and sinus anatomy should be assessed in detail, and CBCT can assist in providing accurate measurements. The indirect technique is used when the required augmentation height is 3 mm or less [22].

4.1. Direct technique

As first demonstrated by Tatum [23], the direct technique is performed with direct visualization of the sinus membrane. Initially, a midcrestal or palatally positioned incision is made in the mesiodistal direction along the length of the alveolar crest. Anterior- and posterior-releasing incisions are made. The incision should extend at least one tooth beyond the planned side. Adequate surgical exposure and visualization are directly related to the size of the incision. A full-thickness mucoperiosteal flap with a trapezoid base is elevated while maintaining periosteal integrity. The mucoperiosteal flap elevation should be performed carefully and start from the midcrest (i.e., more palatal region) to avoid exposure of the grafting area in the event of wound dehiscence. The size of the incision directly affects the manipulation during surgery, the size of the osteotomy, augmentation stage, and placement of the implant. Therefore, this stage should not be underestimated.

The superoinferior and anteroposterior borders of the lateral window are determined by the sinus volume, which is preoperatively examined by radiography. After mucoperiosteal flap elevation, most of the time shadow of the sinus space can be distinguished intraoperatively.

The inferior border of the lateral bony window should be 2–5 mm superior to the sinus floor, to prevent tearing of the sinus membrane and difficulty during infracturing. The anterior border is determined by the mesial extent of the sinus to the point that the sinus curette can extend and be manipulated for elevation, whereas the distal border determines the most posteriorly planned implant's location. The shape of the osteotomy window can be rectangular or oval and outlined with a size of $\sim 10 \times 20$ mm. The size of the window can increase or decrease, according to the size of the planned region that needs augmentation for implant placement. In some instances, it is necessary to prepare two openings, due to the presence of septa, to prevent laceration of the membrane (**Figure 3**) [24, 25].

The osteotomy starts by outlining the lateral window with a round bur until a bluish hue is visible along the outline. The osteotomy continues by connecting the holes. The center native bone window can either remain in place or be removed for replacement after the augmentation. However, when the bony window is small, the entire center part can be readily discarded during preparation. Finally, sharp edges and corners should be rounded to prevent membrane perforation during elevation [26].

There are various techniques available to perform a lateral sinus wall osteotomy. Different methods and various bur types or instruments exist to prevent tearing of the sinus mucosa. Traditional carbide or diamond burs are used for access preparations. Alternatively, a diamond-studded concave bur is used to prevent perforation during osteotomy. In addition, piezosurgery is an ultrasonic method, advised for its selective osteotomy with membrane preservation. The piezoelectric surgery systems have been designed to use a specific power, which allows the osteotomies to be made in thick and compact cortical bone. The real advantage of piezosurgery is that it does not cut soft tissue and helps to reduce the chance of perforating the membrane. It can also be used to detach the sinus membrane from the bone before elevation. Piezosurgery can be most useful in the instances involving considerable cortical bone and thin membranes. However, regardless of the method or instrument used, the sinus membrane is extremely fine and thin; thus, it can easily rupture when treated roughly or pressed during an osteotomy. Hence, clinicians should always be gentle during osteotomy and lifting [27, 28].

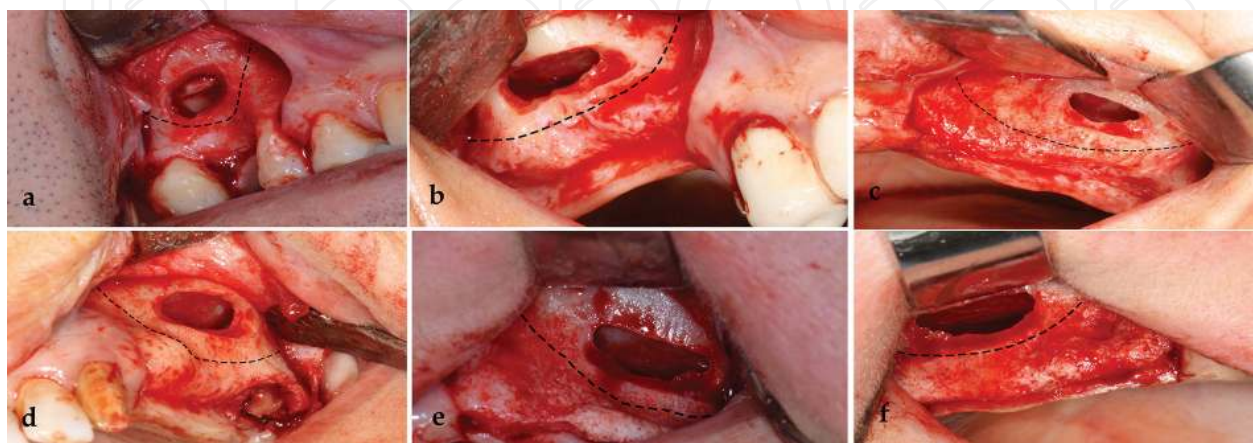


Figure 3. Various lateral windows to approach maxillary sinus membrane.

Once the sinus membrane starts to be detached from the corners and edges, the elevation can be performed using broad-based freers or curettes. Complete detachment of the membrane from all surfaces should be performed slowly and never lose bone contact. Before pushing the membrane in an upward direction, it should be assured that the membrane is separated from the bone. It is important to do this without excessive pressure. This releasing and detachment process is implemented until reaching the level of intended height. The most common mistake during this step is not to extend the medial side of the sinus, potentially leading to sinus perforation, while putting bone graft material due to the applied insertion pressure or to membrane damage when drilling the implant site [22].

In the one-stage protocol, when there is sufficient bone to support primary implant stability, which is about 5 mm in height, implant-site preparation is made according to the implant company's recommendation. During drilling, care should be taken not to harm the membrane with the tip of the implant drill [29]. In the two-stage protocol, the prepared graft material is placed by pieces into the drilled hole, followed by a 6-month wait. The particulated bone graft is then inserted into the bony floor space. The graft particles should reach the farthest distance, loosely placed, dispersed homogeneously, and should not be overpacked. After the bone is placed in the sinus, the mucoperiosteal flap is positioned and primary closure is achieved (**Figure 4**) [30].

4.2. Indirect technique

Developed by Summers in 1994, the indirect technique consists of a crestal incision, preparation of the bone, and elevation of the sinus by several millimeters [31]. The transalveolar sinus-lift technique is more conservative than the open approach. The sinus membrane is not directly instrumented. Also, the sinus cavity is not directly visualized and membrane perforations are more difficult to determine. This technique can be used when there is at least 5–6 mm of alveolar bone. A 4–8-mm bone height gain is achieved by using this technique. The augmentation procedure and implant-site preparation are performed simultaneously. However, there is an upper limit of intrusion regarding the amount of bone and tensile strength of the sinus mucosa because of the pushing without detachment. In this technique, the implant space is prepared not only by compacting the bone apically and elevating the sinus but also by compacting the bone laterally by using osteotomes of progressively increasing diameter [32, 33].

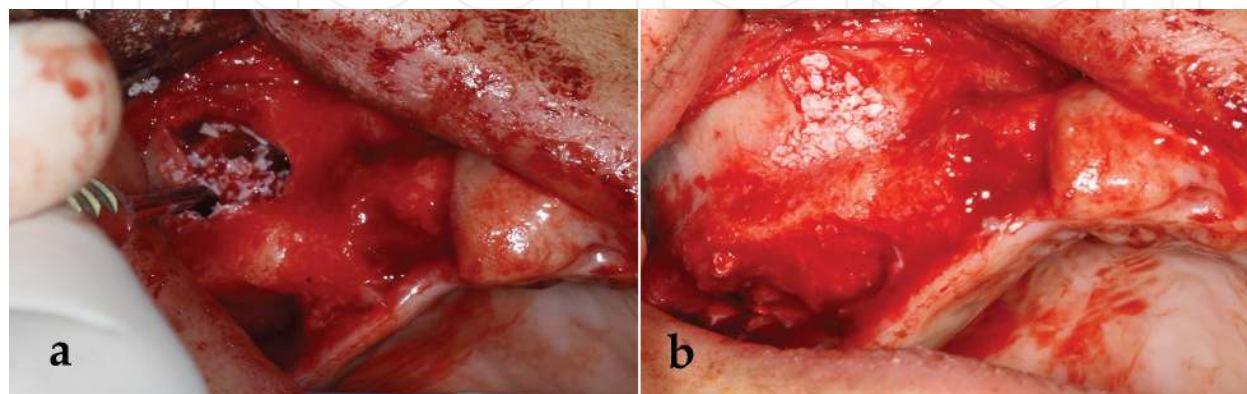


Figure 4. Insertion of bone graft into the bony space under the schneiderian membrane.

Once a full-thickness mucoperiosteal flap has been elevated, a marking drill is used to identify the exact place of the implant. A pilot drill (1-mm diameter) is used only to an initial depth of a few millimeters. It should be about 2 mm away from the sinus floor. Next, a mallet is used to drive the osteotomes. The first osteotome fractures the cortical border of the maxillary sinus floor. A gradual increase in the depth decreases the risk of membrane tear. Larger osteotomes are used, respectively, to the final implant depth until the planned implant width. The final osteotome should have a smaller diameter than the planned implant diameter, to obtain initial implant stability. For implantation in low-density bone, it might be considered to add some bone graft below the implant because of the lack of compressed bone. The mucoperiosteal flap is repositioned and primary closure is achieved after the implant placement [22, 26].

There are some other techniques for maxillary sinus augmentation surgery. For example, the balloon technique is an indirect sinus elevation method [34], performed with application of a balloon via a transcrestal approach that elevates the sinus membrane while the balloon inflates. Another method used does not involve a bone graft. In this technique, there must be some vertical bone height for holding the implant in a stable position (at least 5 mm). The sinus membrane is elevated traditionally via a lateral antrostomy approach; then, the implant is placed without any bone graft. The implant stands under the elevated sinus floor and elevated sinus membrane creates a tenting effect over the implant. The osteoprogenitor potential of the sinus membrane is believed to produce a bony support around the apical portion of the implant in time. This technique is called graftless lateral sinus floor elevation [35, 36].

5. Postoperative instructions after sinus augmentation surgery

There are several things that the patient should be informed about after surgery. Initially, routine postoperative instructions for oral-surgical procedures should be communicated, such as the application of ice and pressure to the site, elevation of the head, and rest. Additionally, patients should be instructed about sinus precautions, which are avoiding anything that can cause sudden pressure changes in the sinus, such as nose blowing with nostrils pinched closed and sneezing with a closed mouth. If there is an increase in pressure in the sinus, perforations and displacement of the particulate graft are possible and it prevents graft maturation and healing [26, 37]. In addition, the patient should be advised to take medications (such as anti-inflammatory drugs, antibiotics, and nasal decongestants) as prescribed by the surgeon.

6. Complications

The most frequently encountered surgical complication is perforation of the sinus membrane. It occurs particularly in the direct technique due to vigorous elevation, a thin membrane, sharp edges and ridges, and septated or irregular topography of the sinus. If the perforation is missed or not properly sealed, extravasation of the particulate graft into the maxillary sinus might predispose the patient to an infection or result in poor graft retention in the area. Management of this complication is made according to the size of the perforation [14]. Small perforations are relocated in an area where the elevated mucosa folds together. In such instances, there is

no need for further management. For larger perforations, attempts should be made to isolate and cover the gap with a resorbable membrane, to prevent loss of the graft into the sinus. If the perforation is sufficiently large that it cannot be covered by a resorbable membrane, the procedure is abandoned and a second surgery is considered after 2 months. Sinus perforations also increase the rates of postoperative sinusitis, infection, and graft failure [38].

The other reported complication of the sinus-lifting procedure is significant bleeding from the posterior superior alveolar artery. In some patients, arterial anastomoses can superficially exist on the lateral sinus wall. The location of the posterior superior alveolar artery should be considered before every surgery. Precautions must be taken to avoid massive bleeding and the trajectory of this artery should be considered after detailed CBCT examination. This artery might be encountered during a lateral wall osteotomy and compromise visibility of the surgical field, which can increase the possibility of membrane perforation and complicate placement of the graft. Therefore, the procedure may need to be stopped until the bleeding is controlled [39].

Maxillary septa are another issue that can complicate the sinus augmentation procedure. Their potential existence should be considered and necessary precautions should be taken. It is difficult or even impossible to separate the sinus membrane from septa without a tear. Preoperative evaluation with CBCT is useful to approach sinus septa while performing a lateral antrostomy. Most septa are located in the middle region of the antrum. Different methods, such as increasing the size of the bony window or preparing more than one lateral window, are available to overcome this issue [40].

Postoperative infection is another unwanted complication after maxillary sinus augmentation. In a case of infection spreading into the sinus, the infected graft material should be removed. Systemic antibiotics are to be adjusted accordingly. Graft failure is expected in these cases. It may also be necessary to remove the grafted material to clear the infection [18]. Patient selection, treatment planning, and the appropriate sinus augmentation technique are essential to minimize the risk of complications.

Author details

Gökhan Göçmen* and Yasar Özkan

*Address all correspondence to: gocmengokhan@hotmail.com

Department of Oral and Maxillofacial Surgery, Faculty of Dentistry, Marmara University, Istanbul, Turkey

References

- [1] Anzalone JV, Vastardis S. Oroantral communication as an osteotome sinus elevation complication. *Journal of Oral Implantology*. 2010;**36**:231–237. DOI: 10.1563/AAID-JOID-09-00026

- [2] Macbeth R, Caldwell, Luc, and their operation. *Laryngoscope*. 1971;**81**:1652–1657. DOI: 10.1288/00005537-197110000-00011
- [3] Mohan N, Wolf J, Dym H. Maxillary sinus augmentation. *Dental Clinics of North America*. 2015;**59**:375–388. DOI: 10.1016/j.cden.2014.10.001
- [4] Drage NA, Palmer RM, Blake G, Wilson R, Crane F, Fogelman I. A comparison of bone mineral density in the spine, hip and jaws of edentulous subjects. *Clinical Oral Implants Research*. 2007;**18**:496–500. DOI: 10.1111/j.1600-0501.2007.01379.x
- [5] Lundgren S, Cricchio G, Hallman M, Jungner M, Rasmusson L, Sennerby L. Sinus floor elevation procedures to enable implant placement and integration: techniques, biological aspects and clinical outcomes. *Periodontology 2000*. 2017;**73**:103–120. DOI: 10.1111/prd.12165
- [6] Thor A, Sennerby L, Hirsch JM, Rasmusson L. Bone formation at the maxillary sinus floor following simultaneous elevation of the mucosal lining and implant installation without graft material: An evaluation of 20 patients treated with 44 Astra Tech implants. *Journal of Oral & Maxillofacial Surgery*. 2007;**65**:64–72. DOI: 10.1016/j.joms.2006.10.047
- [7] Temmerman A, Keestra JA, Coucke W, Teughels W, Quirynen M. The outcome of oral implants placed in bone with limited bucco-oral dimensions: A 3-year follow-up study. *Journal of Clinical Periodontology*. 2015;**42**:311–318. DOI: 10.1111/jcpe.12376
- [8] Ramaglia L, Toti P, Sbordone C, Guidetti F, Martuscelli R, Sbordone L. Implant angulation: 2-year retrospective analysis on the influence of dental implant angle insertion on marginal bone resorption in maxillary and mandibular osseous onlay grafts. *Clinical Oral Investigation*. 2015;**19**:769–779. DOI: 10.1007/s00784-014-1275-5
- [9] Blanes RJ, Bernard JP, Blanes ZM, Belser UC. A 10-year prospective study of ITI dental implants placed in the posterior region. II: Influence of the crown-to-implant ratio and different prosthetic treatment modalities on crestal bone loss. *Clinical Oral Implants Research*. 2007;**18**:707–714. DOI: 10.1111/j.1600-0501.2006.01307.x
- [10] Clark D, Levin L. Dental implant management and maintenance: How to improve long-term implant success? *Quintessence International*. 2016;**47**:417–423. DOI: 10.3290/j.qi.a35870
- [11] Lawson W, Patel ZM, Lin FY. The development and pathologic processes that influence maxillary sinus pneumatization. *Anatomical Record (Hoboken)*. 2008;**291**:1554–1563. DOI: 10.1002/ar.20774
- [12] Sharan A, Madjar D. Maxillary sinus pneumatization following extractions: A radiographic study. *International Journal of Oral & Maxillofacial Implants*. 2008;**23**:48–56
- [13] Makary C, Rebaudi A, Menhall A, Naaman N. Changes in sinus membrane thickness after lateral sinus floor elevation: A radiographic study. *International Journal of Oral & Maxillofacial Implants*. 2016;**31**:331–337. DOI: 10.11607/jomi.4108

- [14] Monje A, Monje-Gil F, Burgueno M, Gonzalez-Garcia R, Galindo-Moreno P, Wang HL. Incidence of and factors associated with sinus membrane perforation during maxillary sinus augmentation using the reamer drilling approach: A double-center case series. *International Journal of Periodontics & Restorative Dentistry*. 2016;**36**:549–556. DOI: 10.11607/prd.2525
- [15] Underwood AS. An inquiry into the anatomy and pathology of the maxillary sinus. *Journal of Anatomical Physiology*. 1910;**44**:354–369
- [16] Jain N, Gulati M, Garg M, Pathak C. Short implants: New horizon in implant dentistry. *Journal of Clinical and Diagnostic Research*. 2016;**10**:ZE14–ZE17. DOI: 10.7860/JCDR/2016/21838.8550
- [17] Pieri F, Caselli E, Forlivesi C, Corinaldesi G. Rehabilitation of the atrophic posterior maxilla using splinted short implants or sinus augmentation with standard-length implants: A retrospective cohort study. *International Journal of Oral & Maxillofacial Implants*. 2016;**31**:1179–1188. DOI: 10.11607/jomi.4370
- [18] Moreno Vazquez JC, Gonzalez de Rivera AS, Gil HS, Mifsut RS. Complication rate in 200 consecutive sinus lift procedures: Guidelines for prevention and treatment. *Journal of Oral & Maxillofacial Surgery*. 2014;**72**:892–901. DOI: 10.1016/j.joms.2013.11.023
- [19] Schwarz L, Schiebel V, Hof M, Ulm C, Watzek G, Pommer B. Risk factors of membrane perforation and postoperative complications in sinus floor elevation surgery: Review of 407 augmentation procedures. *Journal of Oral & Maxillofacial Surgery*. 2015;**73**:1275–1282. DOI: 10.1016/j.joms.2015.01.039
- [20] Araujo DB, de Jesus Campos E, Oliveira MA, Lima MJ, Martins GB, Araujo RP. Surgical elevation of bilateral maxillary sinus floor with a combination of autogenous bone and lyophilized bovine bone. *The Journal of Contemporary and Dental Practice*. 2013;**14**:445–450
- [21] Srouji S, Ben-David D, Lotan R, Riminucci M, Livne E, Bianco P. The innate osteogenic potential of the maxillary sinus (Schneiderian) membrane: An ectopic tissue transplant model simulating sinus lifting. *International Journal of Oral & Maxillofacial Surgery*. 2010;**39**:793–801. DOI: 10.1016/j.ijom.2010.03.009
- [22] Carrao V, DeMatteis I. Maxillary sinus bone augmentation techniques. *Oral & Maxillofacial Surgery Clinics of North America*. 2015;**27**:245–253. DOI: 10.1016/j.coms.2015.01.001
- [23] Tatum H, Jr. Maxillary and sinus implant reconstructions. *Dental Clinics of North America*. 1986;**30**:207–229
- [24] Romanos GE. Window preparation for sinus lift procedures: A simplified technique. *Implant Dentistry*. 2008;**17**:377–381. DOI: 10.1097/ID.0b013e31818c65f6
- [25] Vercellotti T, De Paoli S, Nevins M. The piezoelectric bony window osteotomy and sinus membrane elevation: Introduction of a new technique for simplification of the sinus augmentation procedure. *International Journal of Periodontics & Restorative Dentistry*. 2001;**21**:561–567

- [26] Stern A, Green J. Sinus lift procedures: An overview of current techniques. *Dental Clinics of North America*. 2012;**56**:219–233. DOI: x. 10.1016/j.cden.2011.09.003
- [27] Kuhl S, Kirmeier R, Platzer S, Bianco N, Jakse N, Payer M. Transcrestal maxillary sinus augmentation: Summers' versus a piezoelectric technique – an experimental cadaver study. *Clinical Oral Implants Research*. 2016;**27**:126–129. DOI: 10.1111/clr.12546
- [28] Cassetta M, Ricci L, Iezzi G, Calasso S, Piattelli A, Perrotti V. Use of piezosurgery during maxillary sinus elevation: Clinical results of 40 consecutive cases. *International Journal of Periodontics & Restorative Dentistry*. 2012;**32**:e182–e188
- [29] Kahnberg KE, Ekkestubbe A, Grondahl K, Nilsson P, Hirsch JM. Sinus lifting procedure. I. One-stage surgery with bone transplant and implants. *Clinical Oral Implants Research*. 2001;**12**:479–487
- [30] Galindo-Moreno P, Avila G, Fernandez-Barbero JE, Aguilar M, Sanchez-Fernandez E, Cutando A, et al. Evaluation of sinus floor elevation using a composite bone graft mixture. *Clinical Oral Implants Research*. 2007;**18**:376–382. DOI: 10.1111/j.1600-0501.2007.01337.x
- [31] Summers RB. A new concept in maxillary implant surgery: The osteotome technique. *Compendium*. 1994;**15**:152 (154–156, 158 passim; quiz 162)
- [32] Agamy EM, Niedermeier W. Indirect sinus floor elevation for osseointegrated prostheses. A 10-year prospective study. *Journal of Oral Implantology*. 2010;**36**:113–121. DOI: 10.1563/AAID-JOI-D-09-00085
- [33] Draenert GF, Eisenmenger W. A new technique for the transcrestal sinus floor elevation and alveolar ridge augmentation with press-fit bone cylinders: a technical note. *Journal of Craniomaxillofacial Surgery*. 2007;**35**:201–206. DOI: 10.1016/j.jcms.2007.02.005
- [34] Kotsakis GA, Mazor Z. A simplified approach to the minimally invasive antral membrane elevation technique utilizing a viscoelastic medium for hydraulic sinus floor elevation. *Oral and Maxillofacial Surgery*. 2015;**19**:97–101. DOI: 10.1007/s10006-014-0473-2
- [35] Kosinski TF. Sinus tenting for posterior maxillary implant placement. *Dentistry Today*. 2014;**33**:58–61
- [36] Falah M, Sohn DS, Srouji S. Graftless sinus augmentation with simultaneous dental implant placement: clinical results and biological perspectives. *International Journal of Oral and Maxillofacial Surgery*. 2016;**45**:1147–1153. DOI: 10.1016/j.ijom.2016.05.006
- [37] Del Fabbro M, Corbella S, Ceresoli V, Ceci C, Taschieri S. Plasma rich in growth factors improves patients' postoperative quality of life in maxillary sinus floor augmentation: Preliminary results of a randomized clinical study. *Clinical Implant Dentistry and Related Research*. 2015;**17**:708–716. DOI: 10.1111/cid.12171
- [38] Shiffler K, Lee D, Aghaloo T, Moy PK, Pi-Anfruns J. Sinus membrane perforations and the incidence of complications: A retrospective study from a residency program. *Oral Surgery, Oral Medicine, Oral Pathology, Oral Radiology*. 2015;**120**:10–14. DOI: 10.1016/j.oooo.2015.02.477

- [39] Varela-Centelles P, Loira-Gago M, Gonzalez-Mosquera A, Seoane-Romero JM, Garcia-Martin JM, Seoane J. Distance of the alveolar antral artery from the alveolar crest. Related factors and surgical considerations in sinus floor elevation. *Medicina Oral, Patologia Oral Y Cirugia Bucal*. 2016;**21**:e758–e765
- [40] Al-Dajani M. Incidence, risk factors, and complications of schneiderian membrane perforation in sinus lift surgery: A meta-analysis. *Implant Dentistry*. 2016;**25**:409–415. DOI: 10.1097/ID.0000000000000411

IntechOpen

IntechOpen