

Mediastinal Tuberculous Lymphadenitis with Periodic Fever

Cheong Won Park, M.D., Hee Jin Cheong, M.D., Joon Young Song, M.D., Yu Mi Jo, M.D.,
Won Suk Choi, M.D., Mi Jeong Kim, M.D. and Woo Joo Kim, M.D.

Division of Infectious Diseases, Department of Internal Medicine, Korea University Medical Center, Seoul, Korea

A 60-year-old man undergoing maintenance hemodialysis presented with periodic fever, which resembled Pel-Ebstein fever of Hodgkin's lymphoma. Despite scores of diagnostic evaluations, origin of the fever remained obscure. On positron emission tomography/computed tomography scan, focal hot uptakes were seen in the mediastinum and mediastinoscopic biopsy showed many acid-fast bacilli with chronic granulomatous inflammation and necrosis. After a week of anti-tuberculosis medication, the patient remained afebrile without recourse to antipyretics.

Key Words : Tuberculous lymphadenitis, Fever of unknown origin, Periodic fever

Introduction

Approximately one third of the world's population has latent *Mycobacterium tuberculosis* infection and is at risk for reactivation (1, 2). Extrapulmonary disease is increasing these days, largely as a result of HIV coinfection, and it comprises 9.7 to 46% of all cases of tuberculosis, among which lymphadenitis is the most frequent form (2).

Tuberculosis is considered as one of the common causes of fever of unknown origin (FUO) in uremic patients from tuberculosis intermediate-burden areas, but its diagnosis is sometimes challenging and is often confused with lymphoma and other malignancies (3). Recently, we experienced a case of tuberculous mediastinal lymphadenopathy that presented with characteristic periodic fever mimicking Hodgkin's disease, the origin of which still remained obscure after the routine diagnostic work-up. Herein, we report an un-

usual case of mediastinal tuberculous lymphadenitis with periodic fever with the review of previously published literatures.

Case report

A 60-year-old man undergoing maintenance hemodialysis (3 times/week) presented with a 3-4 weeks' history of high fever ($\geq 38.5^{\circ}\text{C}$) and night sweating, which was repeated every 5 or 7 days and persisted for about 2 days. He had no recent traveling history, nor any history of trauma. The underlying cause of chronic renal failure was chronic glomerulonephritis, and he suffered from gout, taking allopurinol and colchicines to prevent gouty attacks. He had neither respiratory symptoms nor abdominal pain. Physical examination revealed no specific abnormalities; lymphadenopathy (cervical and axillary) and hepatosplenomegaly were not noted. Laboratory investigations showed a hemoglobin level of 10.0 mg/dL and a white blood cell count of $6,800/\text{mm}^3$ with a normal differential count. Erythrocyte sedimentation rate (ESR) was 82 mm/hour and the level of C-reactive protein (CRP) was 17.2 mg/L. Liver function test was normal, no

Submitted : 21 January, 2009, Accepted : 1 June, 2009
Correspondence author : Hee Jin Cheong, M.D., Ph.D.
Division of Infectious Disease, Department of Internal Medicine, Korea University Guro Hospital, 97 Guro Dong-gil, Guro-gu, Seoul, 152-703 Korea
Tel : +82-2-2626-3050, Fax : +82-2-2626-1104,
E-mail: heejinmd@medimail.co.kr

active pulmonary lesion was seen on the chest X-ray, and both the tuberculin skin test and repeated sputum Ziehl-Neelsen stains were negative.

The result of abdominal sonogram was not remarkable except for decreased kidney size. Fluorescent anti-nuclear antibody (FANA), anti-nuclear cytoplasmic antibody (ANCA), echocardiography, and blood culture results were all negative. Thyroid function test was within normal range. Routine diagnostic evaluations did not disclose the origin of the fever and since the high fever continued relapsing every 5-7 days, we conducted a positron emission tomography (PET)/computed tomography (CT) scan.

On PET/CT scan, focal hot uptaking lesions were noted in the mediastinum, which were not visible on routine chest X-ray; and subcarinal lymphadenopathies with internal low densities were observed on conventional CT scan (Fig. 1). The results of tumor markers were as follows: CEA, 1.91 ng/mL; β 2 microglobulin, 20.9 mg/L. With the suspicion of malignant lymphoma, considering the characteristic fever pattern, we performed transesophageal biopsy, but the amount of tissue sample was insufficient for proper diagnosis. Only after mediastinoscopic biopsy could we get sufficient specimens, which showed chronic caseating granuloma. Many acid-fast bacilli were seen on Ziehl-Neelsen stain, and polymerase chain reaction for *M. tuberculosis* was positive. There was no histo-

pathological evidence supporting lymphoma. Therefore, anti-tuberculosis medications (isoniazid, rifampin, and ethambutol) were instituted, and after a week of the medication, the patient became afebrile without antipyretics.

Discussion

Mediastinal tuberculous lymphadenopathy is a common disease, especially among children in the developing countries (1). Previously, isolated mediastinal lymph node involvement was reported to be about 1.3% among all tuberculosis cases; the right paratracheal lymph node is the most common site of mediastinal lymph node enlargement in adults (4). Most of the patients presented with mediastinal mass on chest X-ray, among whom systemic symptoms were not always evident. Interestingly, we experienced a rare case of tuberculous mediastinal lymphadenopathy accompanied by periodic fever mimicking Pel-Ebstein fever of lymphoma.

Pel-Ebstein fever has been considered to be cytokine-induced: pyrogenic cytokines such as tumor necrosis factor- α and interleukin-1 from tumor cells or infiltrating mononuclear cells (5, 6). Traditionally, though the incidence is low, Pel-Ebstein fever had been thought of as a fever exclusively associated with Hodgkin's disease, and there have been no reports

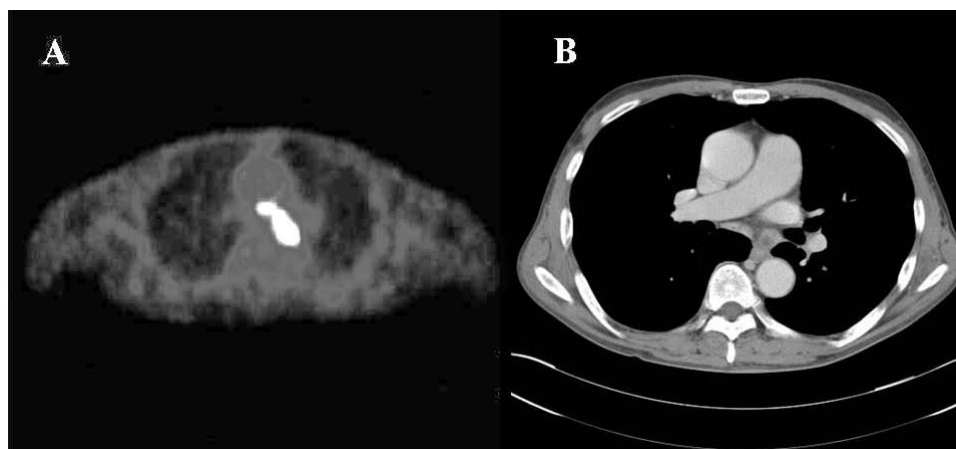


Figure 1. A) Positron emission tomography (PET)/computed tomography (CT) scan reveals focal hot uptaking lesions in the mediastinum, B) conventional chest CT scan is taken and reveals a well-enhancing soft tissue lesion with internal low density areas are noted in the mediastinum including the subcarinal area.

relating the cause to be infectious in origin (6–8). The mechanism could not be elucidated, but we assumed that *M. tuberculosis* could have induced indolent T-cell mediated immune responses in the uremic patient, which led to tissue necrosis that lasted for a relatively long period with some interval in between; the released pyrogenic cytokines could have caused periodic febrile response. Previously, Costa et al. reported three cases of simultaneous occurrence of tuberculosis and Hodgkin's disease (9), but immune stains in the present case revealed no evidence suggesting lymphoma or other malignancies. β 2 microglobulin level was increased due to renal failure, which was not useful for the differential diagnosis in uremic patients.

Besides Pel–Ebstein fever, many differential diagnoses should be considered in patients presenting with periodic fever such as adult-onset still's disease, Behcet's syndrome, inflammatory bowel diseases, and a variety of infectious diseases including borreliosis, malaria, etc (10). Of note, this is the first report describing tuberculous lymphadenopathy with indistinguishable clinical picture from that of Hodgkin's disease. Tuberculosis should be considered as one of the common causes of unexplained fever in uremic patients, although atypical manifestations owing to the disturbed immune response may cause difficulty in making the diagnosis.

References

- 1) Venkateswaran RV, Barron DJ, Brawn WJ, Clarke JR, Desai M, Samuel M, Parikh DH. A forgotten old disease: mediastinal tuberculous lymphadenitis in children. *Eur J Cardiothorac Surg* 27:401–4, 2005
- 2) Kim HJ, Lee HJ, Kwon SY, Yoon HI, Chung HS, Lee CT, Han SK, Shim YS, Yim JJ. The prevalence of pulmonary parenchymal tuberculosis in patients with tuberculous pleuritis. *Chest* 129:1253–8, 2006
- 3) Altıparmak MR, Apaydin S, Ataman R, Tabak F, Mert A, Serdengeçti K, Ereğ E. Fever of unknown origin in uremic patients: a controlled prospective study. *Scand J Infect Dis* 33:851–3, 2001
- 4) Geldmacher H, Taube C, Kroeger C, Magnussen H, Kirsten DK. Assessment of lymph node tuberculosis in northern Germany: a clinical review. *Chest* 121: 1177–82, 2002
- 5) Callen JP. Neutrophilic dermatoses. *Dermatol Clin* 20:409–19, 2002
- 6) Chng WJ, Howard MR. Pel–Ebstein fever with cyclical pancytopenia. *J R Soc Med* 94:84–5, 2001
- 7) Talbot TR. Cases from the Osler Medical Service at Johns Hopkins University. Hodgkin's disease with Pel–Ebstein fevers. *Am J Med* 112:312–3, 2002
- 8) Racchi O, Rapezzi D, Ferraris AM, Gaetani GF. Unusual bone marrow relapse of Hodgkin's disease with typical Pel–Ebstein fever. *Ann Hematol* 73: 39–40, 1996
- 9) Costa LJ, Gallafrio CT, Franca FO, del Giglio A. Simultaneous occurrence of Hodgkin disease and tuberculosis: report of three cases. *South Med J* 97:696–8, 2004
- 10) Mackowiak PA, Durack DT. Fever of unknown origin. In: Mandell G, Bennett J, Dolin R, eds. *Mandell, Douglas, and Bennett's principles and practice of infectious diseases*. 6th ed. Philadelphia, p718, Churchill Livingstone, 2005