



Medicinal Potentials of *Ocimum gratissimum* Linn Leaf Extract against Lead Acetate Disruptions in Rat Hippocampus and Electrolyte Concentration

Ubi Essien Isaac^{1*}

¹*Department of Human Anatomy, Faculty of Basic Medical Sciences, Cross River University of
Technology, Okuku Campus, Nigeria.*

Author's contribution

The sole author designed, analysed, interpreted and prepared the manuscript.

Article Information

DOI: 10.9734/JAMPS/2021/v23i330224

Editor(s):

(1) Dr. Amr Ahmed El-Arabey, Al-Azhar University, Egypt.

Reviewers:

(1) Bindu R.Nair , University of Kerala ,India.

(2) Anderson de Oliveira Souza, Federal University of Amazonas, Brazil.

Complete Peer review History: <http://www.sdiarticle4.com/review-history/62000>

Original Research Article

Received 15 August 2020

Accepted 20 October 2020

Published 17 April 2021

ABSTRACT

The present study determined the effect of *Ocimum gratissimum* Linn. leaves aqueous extract on lead-acetate alterations in the hippocampus and serum biochemical concentration of sodium (Na⁺) and potassium (K⁺) ions in animal models. Twenty male and female albino rats weighing around 155 g were randomly distributed to four groups, (n=5 each). Group A served as control, B received 500 mg/kg body weight of *O. gratissimum* leaf extract, C was administered 150 mg/kg of lead acetate, and group D was given both lead acetate and the named leaf extract at doses of 150 mg/kg and 500 mg/kg respectively. Treatments were given once daily via gavage and lasted 15 days while the animals had access to feed and water *ad libitum*. The rats were euthanized on the 16th day by cervical dislocation; the cranial cavity was carefully exposed and the brain dissected to excise tissue specimens from the hippocampus for histological studies. Blood samples were also collected through cardiac puncture and then centrifuged to obtain serum used for the biochemical parameter. The one-way Analysis of Variance was the statistical tool used to evaluate the differences in concentration of the electrolytes, and data was expressed as means \pm SD, while $P < 0.05$ was taken as a significant value. The results showed the extract to have a mitigating effect by alleviating lead-acetate induced histopathological distortions of the hippocampal pyramidal neurons and by

*Corresponding author: E-mail: isaacubi@crutech.edu.ng, isaacubireal@gmail.com;

counteracting the neurochemical alterations in brain electrolyte ion. The findings of this research therefore indicate that the leaf aqueous extract of *O. gratissimum* has anti-toxic properties and may therefore be explored by pharmaceuticals in search of alternative treatment for lead poisoning.

Keywords: *Ocimum gratissimum*; alleviation; lead toxicity; disruption; brain-hippocampus; electrolyte-ions.

1. INTRODUCTION

The growing use of medicinal plants or herbal medicines has created a critical need for investigations into their pharmacological properties and their abilities to treat various diseases. Clove basil scientifically named *Ocimum gratissimum* Linn, belongs to the group of plants known as spices. Among its alternative names are East Indian tree basil and African basil. The plant is an erect small plumb with many barnacles usually not more than one metre high. It is of the family-labiataea, genus-Ocimum and species-gratissimum [1,2]. The plant is found throughout the tropics and subtropics and its greatest variability occurs in tropical Africa and India [3].

The plant has clusters of flowers with fragrant leaves that have serrated margin and is originally from Africa, the Bismarck, Archipelago, Asia and Madagascar before spreading to other parts of the world such as Boliva, Polynesia, Panama, West Indies, Hawaii, Mexico and Brazil. African countries like Nigeria, Ghana and Cameroun use *O. gratissimum* for both nutritional and medicinal purposes. It is known by a variety of names in different parts of the world. In Nigeria it is known as “Nchanwu” in Igbo, “Efirin” in Yoruba, “Daidoya” in Hausa and “Ntong” in Ibibio; although it is commonly called “scent leaves” in Nigeria and in African diaspora. More so, it is called “wild basil” in Hawaii; “Nunu bush” in Jamaica; “Fubazen” in Haiti; “Mujaaja” in Uganda; “Maduruthala” in Sri Lanka; “Bai yeera” in Thai and “Rehani” in Georgian [4,5,6,7].

O. gratissimum is used in many parts of the world for a variety of reasons such as in culinary salads, soups, pastas, vinegars and jellies, in food flavoring and in traditional medicine. It is a home-grown shrub used mainly as spices for cooking delicacies due to its unique aromatic taste. Extracts of the leaves have been said to be used for the treatment of various health disorders, while the crushed leaf juice is used in the treatment of convulsions, stomach pain and catarrh [8]. Moreover, the plant has been reportedly used in the treatment of epilepsy, high

fever and diarrhoea [6,9]. According to Ijeh et al. [4] phytochemical evaluation of the plant has shown that it is rich in alkaloids, tannins, phytates, flavonoids and oligosaccharides.

Lead which has the symbol ‘Pb’ with atomic number 82, is a toxic heavy metal or element found in the earth’s crust. Its widespread use has resulted in extensive environmental contamination, human exposure and significant public health problems in many parts of the world [10]. Globally, it is an abundantly distributed, important yet dangerous environmental chemical; while its important physico-chemical properties like softness, high density, low melting point, malleability, ductility, poor conductibility, relative inertness to oxidation and resistance to corrosion seem to make difficult to give up its use. These properties, combined with its relative abundance and low cost have resulted in its extensive use in construction, plumbing, batteries, bullets or ammunition, weights equipment, solders, pewters, fusible alloys, white paints, leaded gasoline and radiation shielding [11,12].

Lead poisoning occurs mainly by ingestion of food or lead-contaminated water. However, accidental ingestion of contaminated soil, dust or lead-based paint may also result in poisoning. Lead is thought to be quickly absorbed in the blood stream and is believed to have adverse effect on almost every organ-system including the central nervous system, cardiovascular system, renal system and the immune system [13]. The brain is reported to be the most sensitive organ to lead exposure. It also interferes with the development of neurochemicals including neurotransmitters, organization of ion channel, causes loss of myelin sheath, reduction in the number of neurons and decreased neuronal growth [14,15,16]. Studies have shown that nutrition can play an important role in the prevention of lead-induced toxicity. Hsu and Guo [17] reports that the uptake of certain nutrients like mineral elements, flavonoids and vitamins can provide protection against lead poisoning. However, there is lack of sufficient evidence on the

protective potential of *O. gratissimum* against lead poisoning.

2. MATERIALS AND METHODS

2.1 Procurement of the Test Substances

50 g lead acetate powder was procured from a chemical shop in Aba, Abia State, while fresh leaves of *O. gratissimum* were purchased from a local market in Okigwe, Imo State in Nigeria and thereafter authenticated respectively at the Chemistry and Botany departments of ABSU.

2.2 Preparation of the Leaf Extract

The procured leaves were air-dried at room temperature for two weeks after which a mechanical blender was used for grinding them into fine powder. The maceration method was used to extract the ground leaf substance, with 100 g of the sample soaked in 1000 mls of water. The solution was warmed/heated for 3 days using an oven and percolated for about twenty-four hours, using sterile Whatman paper to decant and filter the mixture. The filtrate was evaporated to dryness to yield aqueous residue, according to the method described by Azwanida [18]. The semi solid extract obtained in syrup form was stored in a refrigerator for further use.

2.3 Tools/Equipment

These included protective clothing (lab coat), rat cages, hand gloves, permanent marker, electronic weighing balance for measuring the test samples and/or for checking the body weight of the animals (Brand: M/s Vijay Scales & Sons, Guwahati, Kamrup, Assam), syringes for measuring the doses (BD Emerald 2ml syringe with 22Gx1), medical dissecting kit, chemical reagents such as formalin (for fixation of tissue specimens), alcohol (for dehydration), xylene (for clearing or removing alcohol), hematoxylin and eosin (for staining the tissues), specimen collection containers, pulverizer (for grinding materials), graduated cylinder used to measure the volume of liquids (Brand: Nalgene), paraffin wax for embedding tissue, embedding mould for making blocks, rotary microtome for cutting thin sections of tissue, water bath used for relaxing and smoothening out the tissue prior to mounting on a glass slide, microscope slides used for holding the tissue sections for examination under a microscope, and a light microscope for viewing

the thin slices of tissue (Brand: MT5 Histology Pathology Lab Microscope).

2.4 Preparation of Stock Solution and Calculation of Doses

10 g of the leaf extract of *O. gratissimum* was dissolved in 50 mls of water to yield a stock concentration of 0.20 g/ml; while the stock solution of lead-acetate was prepared by dissolving 10 g of the powdered substance in 60 mls of water to give a concentration of 0.17 g/ml. The appropriate dosage for each animal was calculated using the formula: Dose (mg) x Body Weight (kg) ÷ Stock Concentration (mg).

2.5 Animal Safety Assessment of the Leaf Extract

Based on previous reports that Clove basil (*Ocimum gratissimum* L.) exhibits low toxicity, the limit test was carried out using the acute toxic class method 423 contained in the modified guidelines of Organization for Economic Cooperation and Development (OECD), [19]. Thus, 12 healthy female rats underwent fasting overnight and they were divided into four groups (n=3). Group 1 received vehicle (distilled water) to serve as the control, whereas groups 2, 3 and 4 each received 2000 mg/kg body weight of the extract. After administration the rats were observed continuously every one hour for four days. Further observation was carried out every 24 hours for 15 days to identify any change such as tremors, convulsions, lethargy, coma or any lethality. After four hours of observation, the rats were allowed access to feed and water; and the experiment was then repeated one week later with another set of animals.

2.6 Animal Procurement and Maintenance

Twenty albino Wistar rats comprising both male and female genders, with average body weight of 155 g were procured and secured in the animal house of the Department of Human Anatomy, in the College of Medicine and Health Sciences of Abia State University, Nigeria. They were allowed to acclimatize for seven days in a well-ventilated room with normal natural lighting condition, and as well allowed unhindered access to standard rat chow (produced by Topfeeds Ltd) and water. Experimental procedures involving the use of animals and their care were followed in line with the existing guidelines.

2.7 Experimental Design and Administration of Treatment

The animal subjects were divided into four groups designated as A, B, C, and D. Group A served as the control and received distilled water; group B was administered a dose of 500 mg/kg body weight per day of *O. gratissimum* leaf extract; group C was given 150 mg/kg body weight per day of lead acetate; and group D received 150 mg/kg of lead acetate and immediately followed with 500 mg/kg of the leaf extract. Treatments were given once daily via the oral route for 15 days using a syringe with attached micropipette tube. The rats were euthanized on the 16th day using the cervical dislocation method in accordance with the guidelines provided by the University of Texas at Austin, [20]. The cranial cavity was carefully exposed in order to dissect the brain and to collect tissue samples from the hippocampus for routine histological studies.

2.8 Histological Protocols

After the excision/collection of the tissue specimens (i.e., tissue sampling), the standard procedures for tissue processing/preparation as prescribed by Slaoui and Fiette, [21] were followed, starting with rapid and adequate fixation by immersing the samples in 10% neutral formalin for 24 hours to prevent autolysis, after which the tissues were properly trimmed to reach the adequate size and orientation as well as to reach a sample size that is compatible with subsequent histology steps such as embedding and sectioning. Next, the tissues were dehydrated in increased concentrations (70%, 90% and 100%) of alcohol solutions, and the alcohol was gradually replaced by a paraffin solvent called xylene that has the advantage of being miscible in both alcohol and paraffin. This sequential process prior to embedding was in order to infiltrate the tissue samples with molten paraffin wax (melted in an oven at a temperature of 60 to 67°C in glass containers), thus replacing water content of the tissue and also serving as a supporting material before sectioning.

After infiltration, the tissue samples were carefully embedded (i.e., positioned inside a metal base mold filled with melted paraffin) and immediately placed on a cooling surface to harden. The sectioning procedure that followed involved thin (4-5 µm thick) cuts of tissue from the paraffin blocks using a microtome with disposable blades in order to maintain constant

high quality and extremely thin sections. The ribbons obtained from this process were floated on a water bath maintained at 45°C to stretch the paraffin section, and a standard microscope glass slide was placed under the selected tissue section and then removed from the water bath, to dry in a thermostatic laboratory oven at 37°C.

During staining, some coloring reagents - hematoxylin and eosin (H&E) were applied in order to improve contrast of the tissue structures for proper microscopic evaluation. Due to the water soluble nature of the H&E dyes, the tissue sections were rehydrated to remove paraffin (with the sequential use of xylene, alcohol solutions and water). The staining procedure was then followed by placing a very thin glass (cover slip) over the tissue section to protect it, enhance its optical evaluation and to allow its storage for a longer period. This process consisted of gluing the cover slip glass over the tissue section on the microscope slide glass. Due to the insolubility of Distyrene Plasticizer Xylene (DPX) that was used as the mounting medium, the tissues were dehydrated again using solutions of increasing concentrations of alcohol and xylene. The manual cover slip mounting technique was applied as follows: the surface under the slide was wiped while keeping the tissue section covered with the clearing agent; three drops of the mounting medium were applied; a cover slip was placed on the slide while the formation of bubbles was avoided by pressing gently with forceps to remove any bubbles; and then the slides were dried overnight at room temperature on a flat surface. This was followed by micrographing and viewing of the tissue sections under a light microscope.

2.9 Biochemical Assay

The serum obtained by centrifuging blood samples was used for the neurochemical analysis to determine the electrolyte-ion concentration of Na⁺ and K⁺, using assay kits from agape diagnostics, based on the method of Tietz [22].

2.10 Statistical Analysis

The one-way analysis of variance (ANOVA) was used with the graph-pad prism software to ascertain the differences in serum concentration of ions among the various study groups. The data was presented as means ± SD, and P<0.05 was taken as the statistically significant value.

3. RESULTS

3.1 Histomorphological Findings

The following micrographic plates are the outcome of investigation of hippocampal tissue samples

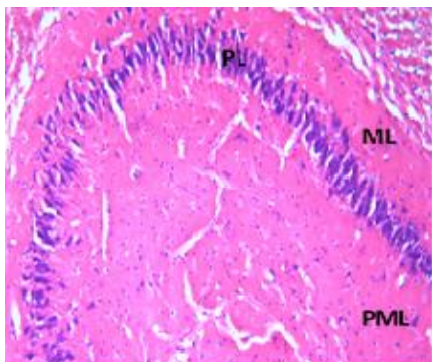


Fig. 1. Photomicrograph of tissue section from group A (control), (x100) (H/E): shows normal morphology of the hippocampus, with its three major layers: molecular layer (ML), pyramidal layer (PL) and polymorphic layer (PML)

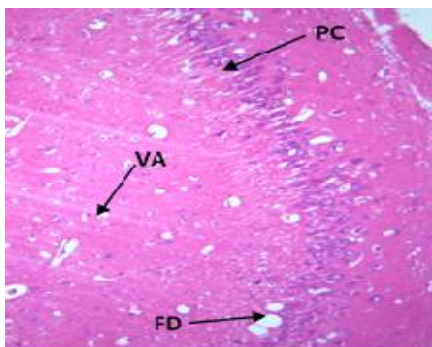


Fig. 2. Photomicrograph of section of hippocampus from group B, administered *Ocimum gratissimum* extract only (x400) (H/E): shows normal pyramidal cells (PC), moderate vacuolated area (VA) and some fatty deposits (FD); with no significant changes when compared with the control

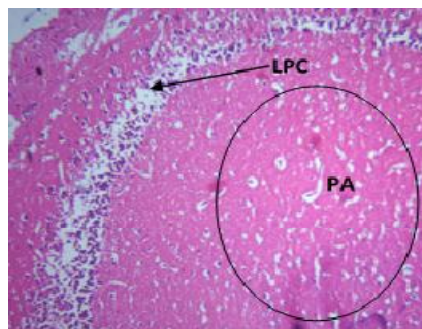


Fig. 3. Photomicrograph of hippocampal section from group C, administered lead acetate only (x400)(H/E): shows severe degeneration of tissue with edematous appearance, severe loss of pyramidal cell (LPC) and pyknotic appearance (PA) of the nuclei within the polymorphic layer

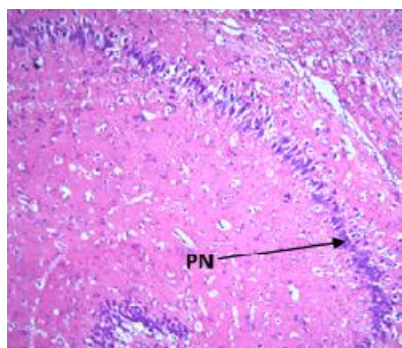


Fig. 4. Photomicrograph of section of hippocampus from group D, administered lead acetate and *O. gratissimum* (x400)(H/E): shows alleviation of damage due to regeneration of the tissue and the presence of sufficient pyramidal neurons (PN), when compared with group C that was given only lead acetate

3.2 Result of Biochemical Parameter

The following Table and graphs are the outcome of neurochemical assessment of the electrolyte concentrations:

Table 1. Statistical Analysis of Serum Concentration of Electrolyte-ions

	A (NC)	B (OG)	C (LA)	D (LA+OG)
Na ⁺ (mmol/L)	110.0 ± 2.45	110.1 ± 6.83	80.39 ± 4.28*	103.0 ± 6.76
K ⁺ (mmol/L)	8.708 ± 0.44	8.354 ± 1.84	10.34 ± 1.05	10.39 ± 1.04

Values are expressed as mean ± Standard deviation (P < 0.05);
Key: * indicates significant difference when compared with NC (normal control)

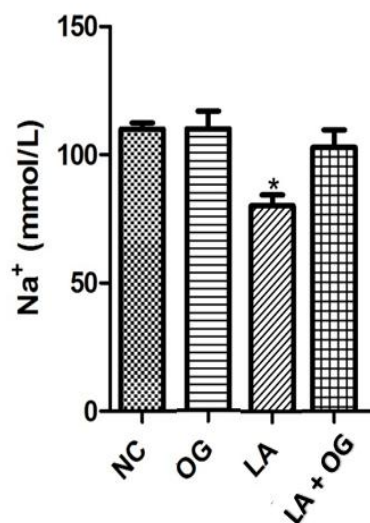


Fig. 5. Graph for sodium ion concentration, showing a significant decrease in LA (i.e., lead acetate-treated group (as denoted by the asterisk sign over this plot) when compared with the NC (i.e., normal control). However, there was a counteraction of Na⁺ reduction in the LA+OG group treated with lead acetate and *O. gratissimum*

observed to exhibit irritability, as they became somewhat aggressive while handling. This observation agrees with Murrel, [25] who reported that irritability, fatigue and loss of appetite are some of the signs of repeated lead exposure.

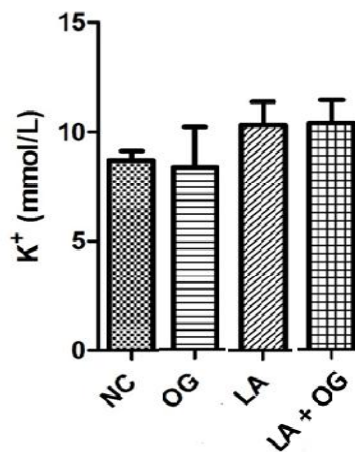


Fig. 6. Graph for potassium ion concentration, shows a very slight decrease in the OG plot, while there were some increases in the LA and LA+OG plots; however, these differences were not statistically significant when compared with NC

4. DISCUSSION

The outcome of histomorphological studies of the tissue samples administered only *O. gratissimum* extract showed non-significant changes in the hippocampal architecture when compared with the control. The photomicrograph in Fig. 2 revealed normal appearance of the pyramidal neurons or cells, with the molecular and polymorphic layers also intact; although there were some mild vacuolated area and fatty deposit observed in the tissue. Whereas, the photomicrograph of the section of hippocampus administered only lead acetate showed severe degeneration with edematous appearance and loss of pyramidal cells (Fig. 3). It has been reported from previous studies that lead induces damage in parts of the brain like cerebral cortex, hippocampus and cerebellum which can lead to a variety of disorders [23]. Moreover, the main reason for lead interfering with learning according to Mycyk et al. [24] is that it damages the cells within the hippocampus, as structural damages such as irregular nuclei and denaturation of myelin were reported in rats exposed to lead. Also, during the administration of treatment on the animal subjects, the rats that received only lead acetate were physically

However, the histological section of the hippocampus treated with 150 mg/kg lead acetate and immediately followed by 500 mg/kg *O. gratissimum* as presented in Fig. 4, showed the counteractive potential of this plant extract against lead acetate-induced distortions. This finding is in accordance with a report from related studies by Ibeagu et al. [26] on the effect of ethanolic extract of *O. gratissimum* on sodium nitrate induced cerebellar cortex toxicity in adult Wistar rats. These researchers had posited that the leaves in a controlled manner may be useful in the management of neurodegenerative conditions that involve free radical generation and reduction in brain energy production. Moreover, the animal safety assessment (acute toxicity test) of the leaf extract at a dose of 2000 mg/kg did not produce any mortality, neither was there any lethal reaction observed among the animals. This finding is in line with findings from the toxicological analysis of *Ocimum gratissimum* leaf extract which revealed that the plant extract exhibits mild toxicity at higher doses, with an overall remark that it was also safe at various concentrations [27].

The hippocampus is the “flash drive” of the human brain and often associated with memory consolidation and decision making, but it is far more complex in structure and function than a flash drive [28]. Three phases of memory include registration, storage and retrieval of information. In the event of bilateral damage to any region of the hippocampus, there is impairment of short-term memory leading up to an inability to form new memories. Apart from being the site for decision making and committing information to memory for future safety use, the hippocampus is also very hyper-excitable –meaning it can sustain weak electrical stimuli into a long, sustained memory from olfaction, visual, auditory, and tactile senses. Moreover, the pyramidal neurons found in the hippocampus are the most numerous excitatory cell type in mammalian cortical structures, suggesting that they play important roles in advanced cognitive functions [29].

From the result of the neurochemical analysis, the serum concentration of sodium ion significantly decreased in the lead-acetate (LA) treated group of experimental animals when compared with the normal control; with the respective means and standard deviation (SD) values of 80.39 ± 4.28 mmol/L and 110.0 ± 2.45 mmol/L, as shown in the statistical analysis table. The graph in Fig. 5 also shows this significant reduction as denoted by the presence of an asterisk sign over the LA plot. It has been reported from previous studies that lead also interferes with neurotransmitter release, disrupting the function of GABAergic, dopaminergic and cholinergic systems as well as inhibiting N-methyl-D-aspartate (NMDA) receptors or ion channels [30,31].

However, there was a counteraction of this abnormal decrease in Na^+ in the group administered both lead acetate and *O. gratissimum* as this produced a mean and SD value of 103.0 ± 6.76 as compared with 110.0 ± 2.45 mmol/L of the control, exhibiting the plant extract to have protective effect on lead toxicity. The analysis for serum concentration of potassium showed a very slight decrease from 8.708 ± 0.44 mmol/L in the normal control (NC) to 8.354 ± 1.84 mmol/L in the *Ocimum gratissimum* (OG) treated specimens. Whereas, there were non-significant increases in the groups which received lead acetate (LA) only and LA plus OG, with statistical values of 10.34 ± 1.05 mmol/L and 10.39 ± 1.04 mmol/L respectively. The graph presented in Fig. 6

shows the concentration levels of K^+ ion without any indication of significant differences among the various experimental groups.

Sodium (Na^+) and potassium (K^+) are electrolyte –ions known to have receptors in the brain in addition to their many roles in regulating normal life activities. Chemically, electrolytes are substances that become ion in fluid and acquire the capacity to conduct electricity. Thus, they are involved in many essential processes in the body such as conducting nervous impulses, contracting muscles, regulating pH levels and maintaining an optimal body environment, while their presence and balance are also vital for normal function of cells and organs. Sodium is the major positive ion (cation) in fluid outside of the cells. It regulates the total amount of water in the body and its movement or transmission into and out of individual cells is also critical in the generation of electrical signals required by the brain or nervous system in general for communication.

Potassium on the other hand, is the major positive ion found inside the cells and perhaps the most frequently supplemented electrolyte (a possible reason why it may not have been significantly altered in the present research, since the animal subjects treated with lead-acetate were observed during this study to consume more food when compared to those in other experimental groups). It plays an important role in cell membrane physiology, especially in maintaining resting membrane potential and in generating action potentials in the nervous system and heart [32,33].

The sodium-potassium pump is said to be an information processing element in brain coding and computation, as brain neurons can transmit signals using a flow of Na^+ and K^+ ions, which produce an electrical spike called an action potential (AP); thus Na^+/K^+ pumping in the brain accounts for the overwhelming majority of an animal's energy (ATP) consumption [34]. In order to show further that exposure to lead(Pb) can interfere with the development of neurochemicals as well as the organization of ion channels, another report from a similar study by Guilarte et al. [35] indicated that NMDARs (N-methyl-D-aspartate receptors) which play an important role in synaptic plasticity and brain development, are important targets for $\text{Pb}(2+)$ -induced neurotoxicity. This implies that the brain's functionality could also be impaired in lead-related toxicity due to the observed alteration in

ion channels, which the plant leaf extract of *O. gratissimum* in this experiment however has also shown the ability to attenuate.

5. CONCLUSION

This research indicates that the leaf aqueous extract of *Ocimum gratissimum* has anti-toxic potentials against lead acetate-induced toxicity. Hence, the plant may be explored by pharmaceutical industries in order to discover or develop alternative treatment for lead poisoning.

CONSENT AND ETHICAL APPROVAL

The required approval/consent to conduct this research was obtained from the Research and Ethics Committee of the Department of Anatomy in the College of Basic Medical Sciences of Abia State University (ABSU), Nigeria; and the guidelines for the use of experimental animals were also followed.

COMPETING INTERESTS

Author has declared that no competing interests exist.

REFERENCES

1. Vieira RF, Simon JE. Chemical characterization of *Ocimum gratissimum* found in the market and used in traditional medicine in Brazil. *J Econ Botany*. 2000;20:5-6.
2. Iwu MM. *Handbook of African Medicinal Plants*. CRC Press Inc. Boca Raton, Florida. 1993;23-28.
3. Aruna K, Sivaramakrishina VM. Plants as protective agents against cancer. *Indian J Exp Biol*. 1990;28(11):108-11.
4. Ijeh II, Omodamiro OD, Nwanna IJ. Antimicrobial effects of aqueous and ethanolic fractions of two species, *ocimum gratissimum* and *xylopia aethiopica*. *Afr J Biotech*. 2005;4:953-956.
5. Nwachukwu CU, Umeh CN, Kalu IG, Okere S, Nwoko MC. Identification and traditional uses of some common medical plants in Ezinihitte Mbaise L.G.A. of Imo State Nigeria. *Rep Opinion J*. 2010;2(6):1-8.
6. Sofowara LA. *Medicinal Plants and Traditional Medicine in Africa*. Spectrum Books Ltd, Ibadan. 1993;55-71.
7. United States Department of Agriculture: Natural Resources Conservation Service. Plants profile for *Ocimum gratissimum*; 2009. Available: <https://plants.usda.gov/core/profile/symbol=OCGR>
8. Ezekwesili CN, Obiora KA, Ugwu OP. Evaluation of anti-diarrhoeal property of crude aqueous extract of *Ocimum gratissimum* L. (Labiataea) in rats. *Biokemistri*. 2004;16:122-131.
9. Osifo NG. *A System of Traditional Health Care*. Neras Publishers Ltd., Ibadan, Nigeria. 1992;2:56.
10. World Health Organization Lead poisoning and health; 2018. Available: www.who.int.lead poisoning Accessed 2019 March 15
11. Mahaffy KR. Environmental lead toxicity: Nutrition as a component of intervention. *Environ Health Perspect*. 1990;89:75-78.
12. Reddy A, Braun CL. Lead and the Romans. *J Chem Edu*. 2010;87(10):1052-5. DOI: 10.1021/ed10063ly
13. Bergeson LL. The proposed lead: Is consideration of cost in clean air act's future? *Environ Quality Magt*. 2008;18:79-84.
14. Cleveland LM, Minter ML, Cobb KA, German VE. Lead hazard for pregnant women and children, *Am J Nurs*. 2008;108:40-49.
15. Casarett LJ, Klaassen CD, Doull J. *Casarett and Doull's Toxicology, Toxic Effects of Metals: The Basics Sciences of Poisons*, 7th Ed. MC Graw Hill Professional. 2007;42-48.
16. Pearson HA, Schonfeld DJ. Lead. Rudolph CD (Ed). *Rudolph's Pediatrics* 21st ed. MCGraw Hill Professional. 2003;28-34.
17. Hsu PC, Guo YL. Antioxidant nutrients and lead toxicity. *Toxicology*. 2002;180(1):33-44. DOI:10.1016/s0300-483x(02)00380-3
18. Azwanida NN. A review on the extraction methods used in medicinal plants, principle strength and limitation. *Med Aromat Plants*. 2014;4(3):196-201. DOI: 10.4172/2167-0412.1000196
19. Organization for Economic Co-operation and Development (OECD). *Guidance Document on Acute Oral Toxicity*. Environmental Health Safety Monograph Series on Testing and Assessment. 2000;24.
20. The University of Texas at Austin. *Guidelines for the use of cervical dislocation for rodent euthanasia*.

- Institutional Animal Care and Use Committee, Guideline #4; 2013. Available:<https://www.avma.org/issues/animalwelfare/euthanasia.pdf> Accessed 2019, December 2
21. Slaoui M, Fiette L. Histopathology procedures: from tissue sampling to histopathological evaluation. *Methods Mol Biol.* 2011;601:69-82. DOI:10.1007/978-1-60761-849-2_4
 22. Tietz NW. *Clinical Guide to Laboratory Test.* WB Saunders Company. 1995;68-72.
 23. Saunders T, Liu Y, Buchner V, Tchounwou PB. Neurotoxic effects and biomarkers of lead exposure: A review. *Rev Environ Health.* 2009;24:15-45.
 24. Mycyk M, Hryhorcu D, Amitai Y. Lead. In *Pediatric Toxicology: Diagnostic and Management of the Poisoned Child.* Erickson TB, Ahrens WR, Aks S, Ling L (Eds.). McGraw Hill Professional. 2005;83-92.
 25. Murrel D. Lead poisoning. Cafasso J. (Ed; 2018. Available:<https://www.health/lead.poisoning> Accessed 2019 April 15
 26. Ibeagu AO, Eze SM, Livinus PP, Adamu SA, Hamman OW, Umana UE, Musa SA. Effect of ethenolic extract of *Ocimum gratissimum* on sodium nitrate-induced cerebellar cortex toxicity in adult wistar rats. *J Exp Clin Anat.* 2015;14:120-125.
 27. Umar M, Nkemelu CP, Sagir MR, Mohammed SY, Ajiya Gk, Mohammed IB. Evaluation of phytochemical, antimicrobial activities and toxicological analysis of scent leaf (*Ocimum gratissimum* L.) leaf extracts. *Asian J Res Med Pharmaceutical Sci.* 2019;7(3):1-11. DOI: 10.9734/ajrimps/2019/v7i330123
 28. Fogwe LA, Mesfin FB. Neuroanatomy, hippocampus; 2019. Available:<https://www.ncbi.nlm.nih.gov/books/NBK482171/> Accessed 2019 May 23
 29. Spruston N. Pyramidal neuron. *Scholar Pedia.* 2009;4(5):6130. DOI: 10.4249/scholarpedia.6130
 30. Guilarte TR, Miceli RC, Altman L, Weinsberg F, Winneke G, Weigand H. Chronic prenatal and postnatal pb²⁺ exposure increases [³H]MK801 binding sites in adult rat forebrain. *Eur J Pharmacol.* 1993;284:273-275.
 31. Guilarte TR, Miceli RC, Jett DA. Biochemical evidence of interaction of lead at the zinc allosteric sites of the NMDA receptor complex: effects of neuronal development. *Nuerotoxicology.* 1995;16:63-71.
 32. West H. Electrolytes: definition, functions, imbalance and sources; 2018. Available:<https://www.www.healthline.com/nutrition/electrolytes> Accessed 2019 May 21
 33. Stoppler MC. Electrolytes. Sheil WC (Ed); 2018. Available:<https://www.medicinenet.com/electrolytes/article.htm> Accessed 2019 May 16
 34. Forrest MD. The sodium-potassium pump is an information processing element in brain computation. *Front Physiol.* 2014;5:472. DOI: 10.3389/fphys2014.00472
 35. Guilarte TR, McGlothlan JL, Nihei MK. Hippocampal expression of N methyl-D-aspartate receptors (NMDAR1) subunit splice variant mRNA is altered by developmental exposure to Pb (2+). *Mol Brain Res.* 2000;76:299-305.

© 2021 Isaac; This is an Open Access article distributed under the terms of the Creative Commons Attribution License (<http://creativecommons.org/licenses/by/4.0>), which permits unrestricted use, distribution, and reproduction in any medium, provided the original work is properly cited.

Peer-review history:

The peer review history for this paper can be accessed here:
<http://www.sdiarticle4.com/review-history/62000>