

# Medullary Thyroid Cancer: Management Guidelines of the American Thyroid Association

The American Thyroid Association Guidelines Task Force\*

Richard T. Kloos (Chair),<sup>1</sup> Charis Eng,<sup>2</sup> Douglas B. Evans,<sup>3</sup> Gary L. Francis,<sup>4</sup>  
Robert F. Gagel,<sup>5</sup> Hossein Gharib,<sup>6</sup> Jeffrey F. Moley,<sup>7</sup> Furio Pacini,<sup>8</sup> Matthew D. Ringel,<sup>9</sup>  
Martin Schlumberger,<sup>10</sup> and Samuel A. Wells Jr<sup>11</sup>

**Background:** Inherited and sporadic medullary thyroid cancer (MTC) is an uncommon and challenging malignancy. The American Thyroid Association (ATA) chose to create specific MTC Clinical Guidelines that would bring together and update the diverse MTC literature and combine it with evidence-based medicine and the knowledge and experience of a panel of expert clinicians.

**Methods:** Relevant articles were identified using a systematic PubMed search and supplemented with additional published materials. Evidence-based recommendations were created and then categorized using criteria adapted from the United States Preventive Services Task Force, Agency for Healthcare Research and Quality.

**Results:** Clinical topics addressed in this scholarly dialog included: initial diagnosis and therapy of preclinical disease (including *RET* oncogene testing and the timing of prophylactic thyroidectomy), initial diagnosis and therapy of clinically apparent disease (including preoperative testing and imaging, extent of surgery, and handling of devascularized parathyroid glands), initial evaluation and treatment of postoperative patients (including the role of completion thyroidectomy), management of persistent or recurrent MTC (including the role of tumor marker doubling times, and treatment of patients with distant metastases and hormonally active metastases), long-term follow-up and management (including the frequency of follow-up and imaging), and directions for future research.

**Conclusions:** One hundred twenty-two evidence-based recommendations were created to assist in the clinical care of MTC patients and to share what we believe is current, rational, and optimal medical practice.

## Introduction

**I**NHERITED AND SPORADIC MEDULLARY THYROID CANCER (MTC) is an uncommon and challenging malignancy. Its low incidence has limited both widespread clinical expertise

and definitive randomized clinical trials. Scientific advances relevant to MTC are reported in a wide range of literature including subspecialty publications of endocrinology, genetics, pediatrics, radiology, nuclear medicine, surgery, and oncology, which make it challenging for clinicians to remain

\*Authorship listed in alphabetical order following the Task Force Chairperson.

<sup>1</sup>Departments of Internal Medicine and Radiology; Divisions of Endocrinology, Diabetes and Metabolism & Nuclear Medicine; The Ohio State University, The Arthur G. James Cancer Hospital and Richard J. Solove Research Institute, and The Ohio State University Comprehensive Cancer Center, Columbus, Ohio.

<sup>2</sup>Genomic Medicine Institute, Lerner Research Institute and Taussig Cancer Institute, Cleveland Clinic Foundation, Cleveland, Ohio, and Department of Genetics and CASE Comprehensive Cancer Center, Case Western Reserve University School of Medicine, Cleveland, Ohio.

<sup>3</sup>Department of Surgery, Medical College of Wisconsin, Milwaukee, Wisconsin.

<sup>4</sup>Department of Pediatrics, Virginia Commonwealth University, Richmond, Virginia.

<sup>5</sup>Department of Endocrine Neoplasia and Hormonal Disorders, Division of Internal Medicine, The University of Texas M.D. Anderson Cancer Center, Houston, Texas.

<sup>6</sup>Mayo Clinic College of Medicine, Division of Endocrinology, Diabetes, Metabolism, and Nutrition, Rochester, Minnesota.

<sup>7</sup>Department of Surgery, Washington University School of Medicine, St. Louis, Missouri.

<sup>8</sup>Section of Endocrinology and Metabolism, Department of Internal Medicine, Endocrinology and Metabolism and Biochemistry, University of Siena, Policlinico Santa Maria alle Scotte, Siena, Italy.

<sup>9</sup>Department of Internal Medicine; Division of Endocrinology, Diabetes and Metabolism; The Ohio State University, The Arthur G. James Cancer Hospital and Richard J. Solove Research Institute, and The Ohio State University Comprehensive Cancer Center, Columbus, Ohio.

<sup>10</sup>Department of Nuclear Medicine and Endocrine Oncology, Institut Gustave Roussy and University Paris XI-Sud, Villejuif, France.

<sup>11</sup>Department of Surgery, Washington University Medical Center, St. Louis, Missouri.

current on all of these developments. Guidelines for the diagnosis and management of MTC have been previously published by several organizations, including some that are periodically updated in print and/or online (1–4). The American Thyroid association (ATA) chose to create specific MTC Clinical Guidelines that would bring together and update the diverse MTC literature and combine it with evidence-based medicine and input from a panel of expert clinicians.

It is our goal that these guidelines assist in the clinical care of patients; it is also our goal to share what we believe is current, rational, and optimal medical practice. In some circumstances, it may be apparent that the level of care recommended may be best provided in limited centers with specific expertise. Finally, it is not the intent of these guide-

lines to replace individual decision making, the wishes of the patient or family, or clinical judgment.

## Methods

### Presentation of results and recommendations

Table 1 presents the organization of the Task Force's results, recommendations, and definitions. Readers of the print version are referred to the page number for information about specific topics, recommendations, and definitions. The location key can be used if viewing the guidelines in a file or web page. Each location key is unique and can be copied into the Find or Search functions to rapidly navigate to the section of interest. Specific recommendations and definitions are presented as bulleted points in the main body of this scholarly

TABLE 1. ORGANIZATION OF MEDULLARY THYROID CARCINOMA GUIDELINES, RECOMMENDATIONS, AND DEFINITIONS

Location key <sup>a</sup>	Page	Section	Subsection	R or D number
[A]	568	<b>Background</b>		
[B]	569	<b>Initial diagnosis and therapy of preclinical disease in MEN 2 syndromes</b>		
[B1]	569		Clinical manifestations and syndromes of <i>RET</i> mutations in MEN 2A	D1
[B2]	570		Clinical manifestations and syndromes of <i>RET</i> mutations in FMTC	D2
[B3]	572		Clinical manifestations and syndromes of <i>RET</i> mutations in MEN 2B	D3
[B4]	573		Role of germline <i>RET</i> testing in MTC patients	R1–R5
[B5]	574		Prophylactic thyroidectomy	R6–R8
[B6]	575		<i>RET</i> testing in asymptomatic people	R9–R10
[B7]	576		<i>RET</i> testing methodologies	R11–R15
[B8]	576		Genetic testing: privacy vs. notification of potentially affected family members	R16
[B9]	577		Reproductive options of <i>RET</i> mutation carriers	R17
[B10]	577		Possibility of inherited disease in <i>RET</i> mutation–negative MTC patients and families	R18
[B11]	577		Preoperative testing of asymptomatic <i>RET</i> mutation–positive patients for MTC, PHPT, and PHEO	R19–R26
[B12]	578		Sources of Ct assay interference	R27
[B13]	579		Effects of age and sex on the normal Ct range	R28–R31
[B14]	579		Surgery for the youngest MEN 2B patients	R32–R33
[B15]	580		Surgery for the youngest MEN 2A or FMTC patients	R34–R36
[B16]	580		Preoperative imaging and biochemical testing to evaluate for MTC in older <i>RET</i> mutation–positive patients	R37
[B17]	580		Surgery for the older MEN 2B patients without evidence of cervical lymph node metastases and normal or minimally elevated Ct levels	R39–R40
[B18]	581		Surgery for the older MEN 2A or FMTC patients without evidence of cervical lymph node metastases and normal or minimally elevated Ct levels	R41–R42
[B19]	581		Diagnostic testing for <i>RET</i> mutation–positive patients suspected of having metastases based on imaging or serum Ct level	R43

(continued)

<sup>a</sup>If viewing these guidelines on the Web, or in a File, copy the Location Key to the Find or Search Function to navigate rapidly to the desired section.

MTC, medullary thyroid carcinoma; R, recommendations; D, definitions; MEN, multiple endocrine neoplasia; FMTC, familial medullary thyroid carcinoma; Ct, calcitonin; PHPT, primary hyperparathyroidism; FNA, fine-needle aspiration; DT, doubling time; CEA, carcinoembryonic antigen.

TABLE 1. (CONTINUED)

<i>Location key<sup>a</sup></i>	<i>Page</i>	<i>Section</i>	<i>Subsection</i>	<i>R or D number</i>
[B20]	581		Management of normal parathyroid glands resected or devascularized during surgery	R44–R46
[B21]	581		Treatment of PHPT in MEN 2A	R47–R50
[C]	<b>582</b>	<b>Initial diagnosis and therapy of clinically apparent disease</b>		R52
[C1]	583		Preoperative laboratory testing for presumed MTC when an FNA or Ct level is diagnostic or suspicious for MTC	R53
[C2]	583		Evaluation and treatment of PHEO	R54–R57
[C3]	584		Preoperative imaging for presumed MTC when an FNA or Ct level is diagnostic or suspicious for MTC	R58–R60
[C4]	584		Surgery for MTC patients without advanced local invasion or cervical node or distant metastases	R61
[C5]	585		Surgery for MTC patients with limited local disease and limited or no distant metastases	R62–R64
[C6]	585		Surgery for MTC patients with advanced local disease or extensive distant metastases	R65–R66
[C7]	586		Thyrotropin suppression therapy in MTC	R67
[C8]	586		Somatic <i>RET</i> testing in sporadic MTC	R68
[D]	<b>586</b>	<b>Initial evaluation and treatment of postoperative patients</b>		
[D1]	586		Postoperative staging systems	R69
[D2]	587		Completion thyroidectomy and lymph node dissection after hemithyroidectomy	R70–R72
[D3]	588		Laboratory testing after resection of MTC	R73
[D4]	588		Testing and treatment of patients with an undetectable postoperative basal serum Ct	R74
[D5]	588		Testing and treatment of patients with a detectable, but modestly elevated postoperative basal serum Ct	R75–R78
[D6]	590		Testing and treatment of patients with a significantly elevated postoperative basal serum Ct	R79–R84
[D7]	591		Role of postoperative radioiodine ablation	R85
[D8]	591		Role of empiric liver or lung biopsy, hepatic vein sampling, systemic vascular sampling, or hepatic angiography	R86
[E]	<b>591</b>	<b>Management of persistent or recurrent MTC</b>		
[E1]	591		Goal of management of patients with metastatic MTC: choosing when metastases require treatment	R87
[E2]	592		Management of patients with metastatic MTC: determining tumor burden and rate of progression using sequential imaging and tumor marker DTs	R88–R89
[E3]	592		Management of Ct-positive, but imaging-negative patients	R90–R91
[E4]	592		Adjunctive external beam irradiation to the neck	R92–R95
[E5]	593		Brain metastases	R96
[E6]	593		Bone metastases	R97–R103
[E7]	594		Lung and mediastinal metastases	R104
[E8]	594		Hepatic metastases	R105
[E9]	594		Palliative surgery	R106
[E10]	594		Chemotherapy and clinical trials	R107–R109
[E11]	595		Symptoms, evaluation, and treatment of hormonally active metastases	R110–R113
[F]	<b>596</b>	<b>Long-term follow-up and management</b>		
[F1]	596		Goals of long-term follow-up and management of patients with and without residual disease	R114–R118
[F2]	596		Follow-up of patients without MTC at thyroidectomy	R119
[F3]	597		Role of stimulation testing for serum Ct	R120
[F4]	597		Management of CEA-positive, but Ct-negative patients	R121
[F5]	597		Lichen planus amyloidosis	R122
[G]	<b>597</b>	<b>Directions for future research</b>		

TABLE 2. DEFINITIONS USED FOR MEDULLARY THYROID CANCER MANAGEMENT GUIDELINES

ACTH	Adrenocorticotrophic hormone
CEA	Carcinoembryonic antigen
CEA DT	Carcinoembryonic antigen doubling time
CLA	Cutaneous lichen amyloidosis
CRH	Corticotropin-releasing hormone
Ct	Calcitonin
Ct DT	Calcitonin doubling time
CT	Computed tomography
DT	Doubling time
DTPA	Diethylenetriamine pentaacetic acid
EBRT	External beam radiation therapy <sup>a</sup>
FMTC	Familial medullary thyroid cancer
FNA	Fine-needle aspiration
HSCR	Hirschsprung disease
MEN	Multiple endocrine neoplasia
MIBG	Metaiodobenzylguanidine
MRI	Magnetic resonance imaging
MTC	Medullary thyroid carcinoma
OS	Overall survival
PHEO	Pheochromocytoma
PHPT	Primary hyperparathyroidism
PTH	Parathyroid hormone
RAI	Radioactive iodine
US	Ultrasound

<sup>a</sup>May include intensity-modulated radiation therapy.

guidelines dialog. Table 2 presents a guide to the abbreviations used.

### Administration

The ATA Executive Council selected a MTC Guidelines Task Force chairman using criteria that included MTC clinical experience and the absence of dogmatically held views in areas of recognized controversy. A Task Force was selected based on clinical expertise to include representation of endocrinology, genetics, pediatrics, nuclear medicine, surgery, oncology, and clinical laboratory testing. The Task Force additionally included experts from both North America and Europe, and all members disclosed potential conflicts of interest. Guidelines funding was derived solely from the general funds of the ATA and Thyroid Cancer Survivors' Association, Inc. (ThyCa) through an unrestricted educational grant and were devoid of commercial support.

The Task Force considered how patients with MTC or a genetic predisposition for the disease are encountered, diagnosed, and treated. In this framework, a series of flow diagrams was created and revised, and a list of questions were developed and assigned to individual Task Force members to answer utilizing the published literature and expert opinion when relevant. Based on these documents a preliminary Guideline and a series of Recommendations were made and then critically reviewed and modified by the full Task Force. The level of evidence to support the Recommendations was categorized and reviewed. Finally, the full Task Force again critically reviewed the entire Guideline and Recommendations through several iterations and arrived at a document of

consensus. In most cases the consensus was unanimous while in some cases there were disparate views held by a minority of panel members; the most significant of which are noted in this document. The final document is the product of face-to-face meetings in Phoenix, Arizona, October 12, 2006; Columbus, Ohio, November 11, 2006; and Toronto, Ontario, June 2, 2007; and multiple electronic communications and telephone conference calls. The final document was approved by the ATA Board of Directors, and officially endorsed (in alphabetical order) by: American Academy of Otolaryngology—Head and Neck Surgery (AAO-HNS) Endocrine Surgery Committee, American Association of Clinical Endocrinologists (AACE), American Association of Endocrine Surgeons (AAES), American College of Endocrinology (ACE), Asia and Oceanic Thyroid Association (AOTA), British Association of Endocrine and Thyroid Surgeons (BAETS), British Association of Head and Neck Oncologists (BAHNO), Canadian Society of Otolaryngology—Head and Neck Surgery (CSOHNS), The Endocrine Society (ENDO), European Society of Endocrinology (ESE), European Society of Endocrine Surgery (ESES), European Thyroid Association (ETA), International Association of Endocrine Surgeons (IAES), Latin American Thyroid Society (LATS), and the Ukrainian Association of Endocrine Surgeons (UAES).

### Literature review and evidence-based medicine

Relevant articles were identified by searching PubMed MEDLINE at Pubmed (NLM) using the following search terms: (medullary carcinoma) OR (medullary thyroid cancer) OR (medullary thyroid carcinoma) OR (*RET*) OR (calcitonin) which yielded 30,095 articles on March 10, 2007. Limiting the search to include “humans”; and “randomized controlled trials” or “meta-analysis” from (medullary carcinoma) OR (medullary thyroid cancer) OR (medullary thyroid carcinoma) yielded 12 articles, of which 8 were relevant and they were reviewed in detail by the Task Force. In addition to these articles, numerous additional relevant articles, book chapters, and other materials were also supplied by Task Force members, including works published after the initial search. Published works were utilized to devise this Guideline as referenced.

The Task Force categorized our recommendations using criteria adapted from the United States Preventive Services Task Force, Agency for Healthcare Research and Quality (Table 3) as was used in the ATA publication *Management Guidelines for Patients with Thyroid Nodules and Differentiated Thyroid Cancer* (5).

### Results

#### [A] Background

MTC was first described by Jaquet in the German literature as “malignant goiter with amyloid” (6). In 1959, Hazard *et al.* (7) provided a definitive histological description, while Williams further suggested that MTC originated from the calcitonin (Ct)-secreting parafollicular C cells of the thyroid gland, which derive from the neural crest (8–10). Currently, MTC accounts for about 4% of all thyroid cancer cases in the United States (11). MTC presents worldwide as part of an autosomal dominant inherited disorder in about 20–25% of cases and as a sporadic tumor in the remainder (12–15).

TABLE 3. STRENGTH OF RECOMMENDATIONS BASED ON AVAILABLE EVIDENCE

Rating	Definition
A	<b>Strongly recommends.</b> The recommendation is based on good evidence that the service or intervention can improve important health outcomes. Evidence includes consistent results from well-designed, well-conducted studies in representative populations that directly assess effects on health outcomes.
B	<b>Recommends.</b> The recommendation is based on fair evidence that the service or intervention can improve important health outcomes. The evidence is sufficient to determine effects on health outcomes, but the strength of the evidence is limited by the number, quality, or consistency of the individual studies; generalizability to routine practice; or indirect nature of the evidence on health outcomes.
C	<b>Recommends.</b> The recommendation is based on expert opinion.
D	<b>Recommends against.</b> The recommendation is based on expert opinion.
E	<b>Recommends against.</b> The recommendation is based on fair evidence that the service or intervention does not improve important health outcomes or that harms outweigh benefits.
F	<b>Strongly recommends against.</b> The recommendation is based on good evidence that the service or intervention does not improve important health outcomes or that harms outweigh benefits.
I	<b>Recommends neither for nor against.</b> The panel concludes that the evidence is insufficient to recommend for or against providing the service or intervention because evidence is lacking that the service or intervention improves important health outcomes, the evidence is of poor quality, or the evidence is conflicting. As a result, the balance of benefits and harms cannot be determined.

Adapted from the U.S. Preventive Services Task Force, Agency for Healthcare Research and Quality.

Inherited MTC syndromes (multiple endocrine neoplasia type 2, MEN 2) affect approximately 1 in 30,000 individuals (16,17) and consist of MEN 2A (Sipple's syndrome), familial MTC (FMTC), and MEN 2B. Interestingly, the founding *de novo* mutations have occurred exclusively on the paternal allele (18,19). Affected individuals initially develop primary C-cell hyperplasia (CCH) that progresses to early invasive medullary microcarcinoma, and eventually develop grossly invasive macroscopic MTC (20). Secondary CCH has been described with aging, hyperparathyroidism, hypergastrinemia, near follicular derived tumors, and in chronic lymphocytic thyroiditis (21). Familial CCH is a preneoplastic lesion as opposed to secondary CCH, which is associated with much less, if any, malignant potential (21). Although there is controversy surrounding the definition of CCH (22), its utility to identify or confirm MEN 2 has been essentially replaced by *RET* (REarranged during T<sub>1</sub>ransfection) protooncogene testing.

Sipple (23) published a case report and review of the literature that demonstrated the association of thyroid cancer with pheochromocytoma (PHEO) in 1961. Steiner *et al.* (24) associated the presence of primary hyperparathyroidism (PHPT) with the syndrome and introduced the term "multiple endocrine neoplasia 2." Recent molecular evidence has demonstrated that the first description of PHEO in 1886 was a young woman with MEN 2A (25). FMTC is a variant of MEN 2A with multigenerational MTC without PHEO or PHPT. This variant was first categorized by Farndon and colleagues in 1986 (26). Initial descriptions of MEN 2B were recorded by Wagenmann in 1922 (27), Froboese in 1923 (28), and then Williams and Pollock in 1966 (29).

The *RET* gene was first identified in 1985 (30). In 1987, the genetic defect causing MEN 2A was located on chromosome 10 (31). In 1993 and 1994 it was demonstrated that MEN 2A and FMTC (16,17), and MEN 2B (32–34), respectively, were caused by germline *RET* mutations. Thus, a *RET* gene mutation occurring in the germline that results in expression of abnormally overactive Ret protein in all tissues in which it is

expressed causes these specific inherited syndromes. Somatic *RET* mutations that occur later in life and are limited to C cells are present in 40–50% of sporadic MTCs (35–37).

The 10-year disease-specific survival of MTC is about 75% (11). Important prognostic factors that predict adverse outcome include advanced age at diagnosis, extent of primary tumor, nodal disease, and distant metastases (11,13,38–40). The current American Joint Committee on Cancer (AJCC) 6th edition TNM (tumor, node, metastasis) classification system (41) is shown in Table 4. Using a prior TNM classification system, 10-year survival rates for stages I, II, III, and IV are 100%, 93%, 71%, and 21%, respectively (40). Unfortunately, there has been no significant trend toward earlier stage of disease at diagnosis with just under half of the patients presenting with stage III or IV disease (11), and no significant increase in the survival of patients with MTC in recent decades (42,43).

#### **[B] Initial diagnosis and therapy of preclinical disease in MEN 2 syndromes**

MEN 2 is an autosomal dominant hereditary cancer syndrome that implies a 50% risk to offspring of a carrier to inherit the disorder. It is caused by missense mutations in the *RET* protooncogene, that result in "gain of function" (44). All three clinical subtypes of MEN 2 are characterized by the presence of MTC.

*[B1] Clinical manifestations and syndromes of RET mutations in MEN 2A (Table 5).* The most common clinical subtype of MEN 2 is type 2A. The typical age of onset of this condition is the third or fourth decade of life and is characterized by a triad of features: MTC, PHEO, and PHPT. Nearly 90% of gene carriers will develop MTC, but this is dependent upon the mutation (2). The risk of developing unilateral or bilateral PHEO is as high as 57%, and 15–30% of gene carriers will develop PHPT (2,40,45). In the vast majority of cases, MEN 2A is caused by mutations affecting cysteine residues in codons

TABLE 4. AMERICAN JOINT COMMITTEE ON CANCER TNM CLASSIFICATION

<i>Primary tumor (T)</i>	
T0	No evidence of primary tumor
T1	Tumor 2 cm or less in greatest dimension limited to the thyroid ( <i>Supplementum to the 6th edition: T1a, tumor 1 cm or less; T1b, tumor more than 1 cm but not more than 2 cm</i> )
T2	Tumor more than 2 cm, but not more than 4 cm, in greatest dimension limited to the thyroid
T3	Tumor more than 4 cm in greatest dimension limited to the thyroid or any tumor with minimal extra-thyroidal extension (e.g. extension to sternothyroid muscle or perithyroid soft tissues)
T4a	Tumor of any size extending beyond the thyroid capsule to invade subcutaneous soft tissues, larynx, trachea, esophagus, or recurrent laryngeal nerve
T4b	Tumor invades prevertebral fascia or encases carotid artery or mediastinal vessels.
<i>Regional lymph nodes (N) are the central compartment, lateral cervical, and upper mediastinal lymph nodes</i>	
NX	Regional lymph nodes cannot be assessed
N0	No regional lymph node metastases
N1	Regional lymph node metastases
N1a	Metastasis to Level VI (pretracheal, paratracheal, and prelaryngeal/Delphian lymph nodes)
N1b	Metastasis to unilateral, bilateral, or contralateral cervical or superior mediastinal lymph nodes
<i>Distant metastases (M)</i>	
MX	Distant metastasis cannot be assessed
M0	No distant metastasis
M1	Distant metastasis
<i>Stage</i>	
• Stage I	○ T1, N0, M0
• Stage II	○ T2, N0, M0
• Stage III	○ T3, N0, M0
	○ T1, N1a, M0
	○ T2, N1a, M0
	○ T3, N1a, M0
• Stage IVA	○ T4a, N0, M0
	○ T4a, N1a, M0
	○ T1, N1b, M0
	○ T2, N1b, M0
	○ T3, N1b, M0
	○ T4a, N1b, M0
• Stage IVB	○ T4b, any N, M0
• Stage IVC	○ Any T, any N, M1

Sixth edition (41).

609, 611, 618, and 620 within exon 10 and, most commonly, codon 634 in exon 11 of *RET* (46).

Mutations in the *RET* codon 634 are causative of cutaneous lichen amyloidosis (CLA) in some MEN 2A/FMTC families (47).

Brauckhoff *et al.* (48) described papillary thyroid cancer in 9.1% of patients with *RET* mutations in exons 13 and 14, although this is considered a fortuitous association.

Germline mutations in *RET* have also been implicated in 10–40% of cases of Hirschsprung disease, with higher frequencies associated with familial cases (49,50). Hirschsprung disease is defined as the congenital absence of the enteric innervation, which causes bowel obstruction in infancy. In this disorder, deletions, insertions, missense, and nonsense mutations have been demonstrated throughout *RET*. These alterations cause loss of function, or inactivation of the encoded protein, and have reduced, sex-dependent penetrance and are associated with Hirschsprung disease without MEN 2A/FMTC. However, Mulligan *et al.* (51) found that Hirschsprung disease cosegregated with some activating mutations of MEN 2A/FMTC, although the penetrance is low. In all of these patients, the mutations occurred in exon 10 (Table 5) (51).

#### ■ DEFINITION 1

MEN 2A is defined as the presence of MTC, PHEO, and PHPT associated with a germline *RET* mutation. There are rare families with classical features of MEN 2A in the absence of an identifiable *RET* mutation. In a patient with one or two of the clinical features of MEN 2A, the only way to be certain of a diagnosis of MEN 2A is to identify a *RET* mutation or identify the clinical features of MEN 2A in other first-degree relatives. In the absence of an autosomal dominant familial inheritance pattern or *RET* mutation, at least two of the classical clinical features of MEN 2A are required to make a clinical diagnosis of MEN 2A. In the presence of a germline *RET* mutation and in the absence of any clinical features, that individual is said to be at risk for the clinical features of MEN 2A, and appropriate medical management should ensue.

[B2] *Clinical manifestations and syndromes of RET mutations in FMTC.* Defining and separating FMTC from MEN 2A has been challenging. The most rigid definition is multigenerational transmission of MTC in which no family member has PHEO or PHPT (26); a less rigid definition is the presence of MTC in four affected family members without other manifestations of MEN 2A (46). The controversy regarding this syndrome focuses on the concern that premature categorization of a family with a small number of MTC-affected individuals as FMTC could mask the eventual identification of a PHEO (52). The typical age of onset of this condition is later in life than in MEN 2A patients, and the penetrance of MTC is lower (53,54).

In the era of genetic testing, FMTC has been most commonly associated with mutations in codons 609, 611, 618, and 620 in exon 10; codon 768 in exon 13; and codon 804 in exon 14 (46). When FMTC is associated with mutations in codon 634 in exon 11, it is almost never C634R and is most commonly C634Y (46). Given the accumulating genotype–phenotype data over the last decades, and the eventual development of MEN 2A clinical features in some families once thought to

TABLE 5. GENOTYPE-PHENOTYPE CORRELATIONS AND RISK LEVELS FOR AGGRESSIVE MEDULLARY THYROID CANCER

Mutation	Exon	ATA risk level <sup>a</sup>	MTC risk level <sup>b</sup>	FMTC <sup>c</sup>	MEN 2A <sup>d</sup>					MEN 2B <sup>d</sup>		References
					MTC	PHPT	PHEO	CLA	HSCR	MTC	PHEO	
G321R <sup>e</sup>	5	A		+	MA	–	–	–	–	–	–	(100)
531/9 base pair duplication	8	A		+	MA	–	–	–	–	–	–	(364)
532 duplication <sup>e</sup>	8	A		+	?	–	–	–	–	–	–	(177)
C515S <sup>e</sup>	8	A		+	MA	–	–	–	–	–	–	(365)
G533C	8	A		+	MA	–	R	–	–	–	–	(99,366–368)
R600Q <sup>e</sup>	10	A		+	MI	–	–	–	–	–	–	(369)
K603E <sup>e</sup>	10	A		+	MI	–	–	–	–	–	–	(370)
Y606C <sup>e</sup>	10	A		+	?	–	–	–	–	–	–	(371,372)
C609F/R/G/S/Y	10	B	1	+	MA	MI	R	–	+	–	–	(14,46,85,373–375)
C611R/G/F/S/W/Y	10	B	2	+	MA	MI	R	–	+	–	–	(46,85)
C618R/G/F/S/Y	10	B	2	+	MA	MI	MI	–	+	–	–	(46,85)
C620R/G/F/S/W/Y	10	B	2	+	MA	MI	MI	–	+	–	–	(46,85,374)
C630R/F/S/Y	11	B		+	MA	R	R	–	–	–	–	(73,376,377)
D631Y <sup>e</sup>	11	B		+	?	–	–	–	–	–	–	(378)
633/9 base pair duplication	11	B		+	MA	MI	MI	–	–	–	–	(379)
C634R	11	C	2	–	MA	MI	MA	+	–	–	–	(46,85,380,381)
C634G/F/S/W/Y	11	C	2	+	MA	MI	MA	+	–	–	–	(46,85,380–382)
634/12 base pair duplication	11	B		+	MA	MI	–	–	–	–	–	(383)
635/insertion ELCR;T636P	11	A		+	MA	–	–	–	–	–	–	(371)
S649L	11	A		+	MI	R	–	–	–	–	–	(14,124,384,385)
K666E <sup>e</sup>	11	A		+	MI/MA	–	MI	–	–	–	–	(371)
E768D	13	A	1	+	MA	R	R	–	–	–	–	(46,73,90,378)
N777S <sup>e</sup>	13	A		+	MI	–	–	–	–	–	–	(386)
L790F	13	A	1	+	MA	R	R/MI	–	–	–	–	(86,378)
Y791F	13	A	1	+	MA	MI	MI	–	–	–	–	(86,378,387)
V804L	14	A	1	+	MA	MI	R	–	–	–	–	(46,86,388)
V804M	14	A	1	+	MA	R	R	–	–	–	–	(46,86,388,389)
V804M+V778I <sup>f</sup>	13/14	B		+	MA	–	–	–	–	–	–	(390)
V804M+E805K	14	D		–	–	–	–	–	–	MA	MA	(71)
V804M+Y806C	14	D		–	–	–	–	–	–	MA	MA	(72–74)
V804M+S904C <sup>g</sup>	14/15	D		–	–	MI	–	–	–	MA	–	(101)
G819K <sup>e</sup>	14	A		+	?	–	–	–	–	–	–	(14)
R833C <sup>e</sup>	14	A		+	?	–	–	–	–	–	–	(391)
R844Q <sup>e</sup>	14	A		+	?	–	–	–	–	–	–	(14,378)
R866W <sup>e</sup>	15	A		+	MA	–	–	–	–	–	–	(392)
A883F	15	D	3	–	–	–	–	–	–	MA	MA	(393,394)
S891A	15	A	1	+	MA	R	R	–	–	–	–	(14,395–397)
R912P	16	A		+	MI	–	–	–	–	–	–	(14,398)
M918T	16	D	3	–	–	–	–	–	–	MA	MA	(46)

<sup>a</sup>Risk from aggressive MTC: level D is highest risk.

<sup>b</sup>Risk from aggressive MTC from the Seventh International Workshop on MEN (2): level 1, high risk; level 2, higher risk; level 3, highest risk.

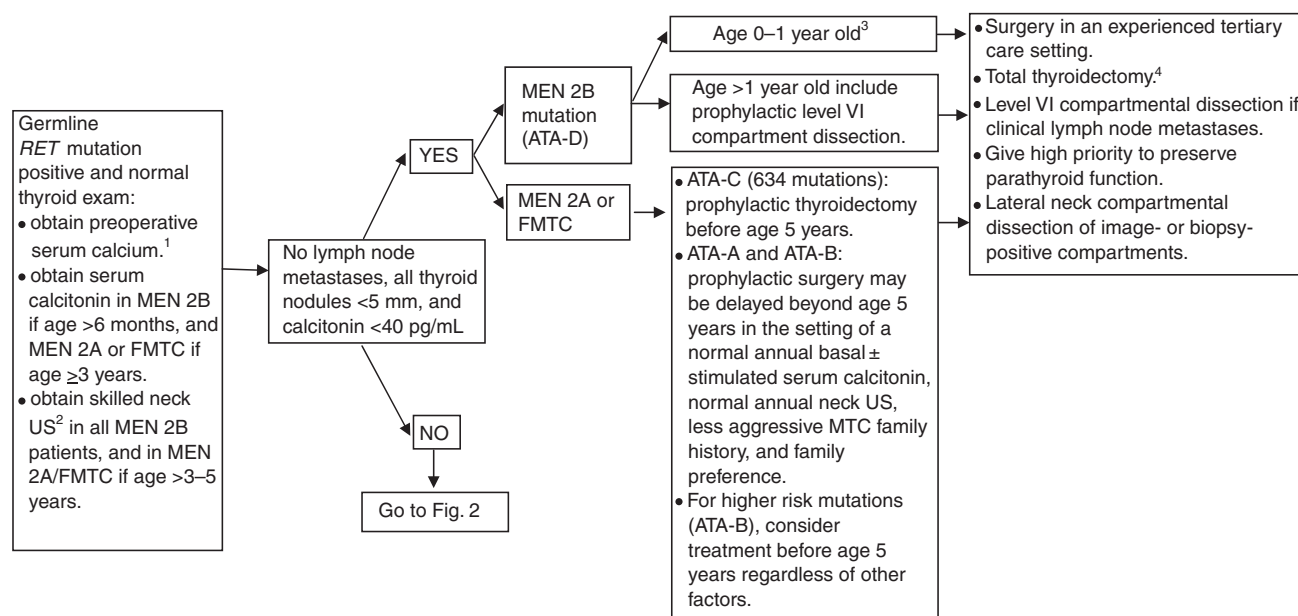
<sup>c</sup>Presence (+) of inherited MTC in the absence of PHPT or PHEO has been described, although the number of family members and number of family generations studied and duration of follow-up is variable. Historically, mutations initially considered diagnostic of FMTC have eventually demonstrated some penetrance of the MEN 2A phenotype. The absence (–) of association with FMTC indicates that inheritance of MTC in isolation is very unlikely.

<sup>d</sup>Organ-specific penetrance: MA, majority; MI, minority; R, rare.

<sup>e</sup>Mutations based on limited families/case reports and may represent variants of unknown significance.

<sup>f</sup>Phenotype associated with corneal nerve thickening.

<sup>g</sup>Phenotype associated with mucosal neurilemmomas.



<sup>1</sup>Treat hyperparathyroidism with 4 gland resection and autograft to heterotopic site, or subtotal parathyroidectomy. Consider cryopreservation. PHEO preoperative screening should begin by age 8 years for MEN 2B and mutated *RET* codons 634 and 630; otherwise by age 20 years for other *RET* mutations.

<sup>2</sup>Neck US to include the superior mediastinum and central and lateral neck compartments.

<sup>3</sup>Insufficient data to recommend routine prophylactic level VI compartment dissection.

<sup>4</sup>Parathyroid glands resected or devascularized should be autografted in the neck in *RET*-negative, MEN 2B, and FMTC patients, while MEN 2A glands should be auto graphed to a heterotopic site.

**FIG. 1. Initial diagnosis and therapy of pre-clinical disease.**

have FMTC (52), FMTC is now viewed as a phenotypic variant of MEN 2A with decreased penetrance for PHEO and PHPT rather than a distinct entity.

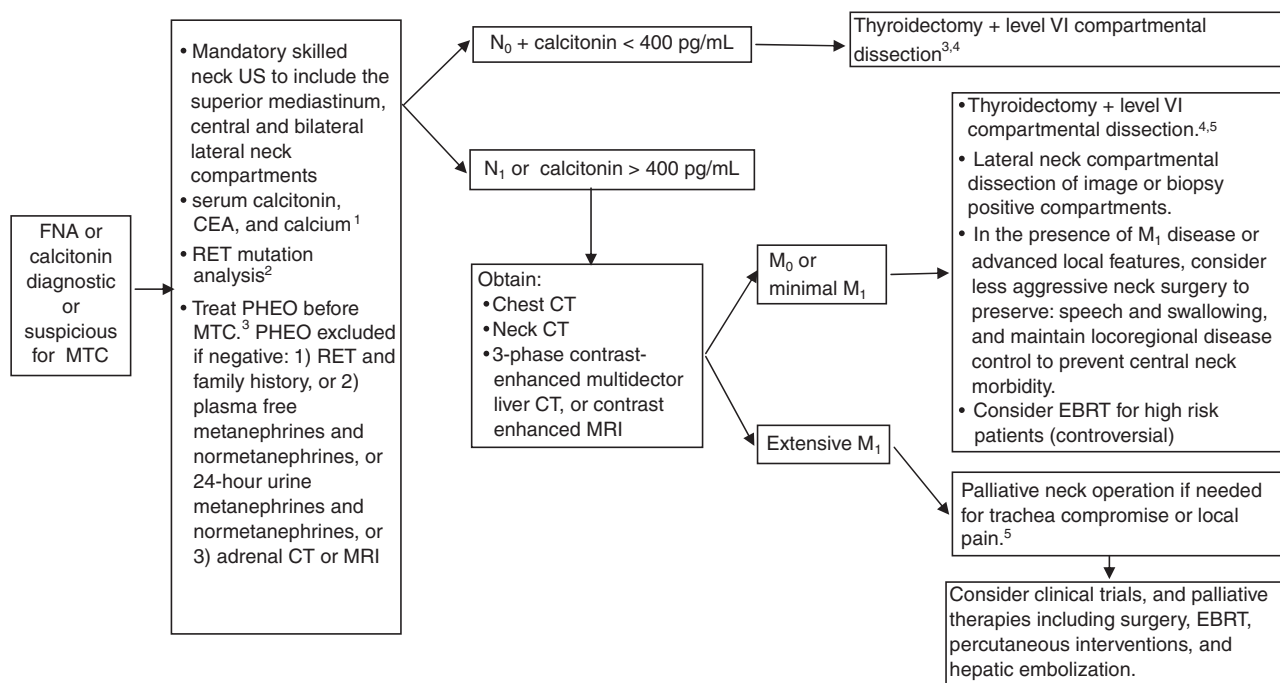
## ■ DEFINITION 2

Familial MTC is a clinical variant of MEN 2A in which MTC is the only manifestation. To prove that a particular kindred has FMTC it is necessary to demonstrate the absence of a PHEO or PHPT in two or more generations within a family or to have a *RET* mutation identified only in kindreds with FMTC (Table 5). In smaller kindreds or in those with a single affected generation, caution should be exercised in the classification of FMTC as there is the possibility of failure to recognize MEN 2A and the risk of PHEO.

[B3] *Clinical manifestations and syndromes of RET mutations in MEN 2B.* MEN 2B is the most rare and aggressive form of MEN 2 based on its development of MTC earlier in life (55–59). More than 50% of cases are *de novo* germline *RET* mutations (18,60). In multivariate analyses that incorporate disease stage and other factors, it has been suggested that the higher mortality rate of MEN 2B reflects its more advanced stage at presentation, rather than the tumor behavior once established (12,43,61,62). Like MEN 2A, MEN 2B is associated with PHEO. The youngest age at diagnosis of PHEO has been 12 years of age for the 918 *RET* mutation (63). In two series of MEN 2B patients, O’Riordain *et al.* (58) and Leboulleux *et al.*

(64) reported median ages (range) at presentation of PHEO as 23 (13–32) and 28 (17–33) years, respectively. MEN 2B is distinguished from MEN 2A by the absence of PHPT and the presence of distinct developmental defects. These typical phenotypic features include musculoskeletal abnormalities (marfanoid habitus, pes cavus, pectus excavatum, hyponia, proximal muscle weakness); neuromas of the lips, anterolateral surface of the tongue, and conjunctiva; medullated corneal-nerve fibers; urinary ganglioneuromatosis and malformations; and ganglioneuromatosis of the intestine. Gastrointestinal manifestations including vomiting, dehydration, failure to thrive, and possible intestinal obstruction are often initial disease manifestations that present for medical attention (58,65–69). In one study of 21 MEN 2B patients, 90% had colonic disturbances, typically chronic constipation from birth (58). Megacolon developed in two thirds of patients, and about one third required colonic surgery. Brauckhoff *et al.* (70) reported that fewer than 20% of MEN 2B children manifested the typical MEN 2B phenotype during the first year of life, whereas 86%, 61%, and 46% demonstrated the inability to cry tears, constipation, or feeding problems, respectively. The average age of onset of MTC is 10 years earlier than seen in MEN 2A (2,55,63). The mutation M918T (exon 16) is present in >95% of patients with MEN 2B with 2–3% of patients harboring the A883F mutation in exon 15 (46). Rare patients with the MEN 2B phenotype have a double *RET* mutation (71–74) (Table 5).





<sup>1</sup>Treat hyperparathyroidism with 4 gland resection and autograft to heterotopic site, or subtotal parathyroidectomy. Consider cryopreservation.

<sup>2</sup>Ideally performed with genetics counseling and completed preoperatively.

<sup>3</sup>PHEO preoperative screening should begin by age 8 years for MEN 2B and mutated *RET* codons 634 and 630; and by age 20 years for other *RET* mutations.

<sup>4</sup>Parathyroid glands resected or devascularized should be autografted in the neck in *RET*-negative, MEN 2B, and FMTC patients, while MEN 2A glands should be autografted to a heterotopic site.

<sup>5</sup>Consider external beam radiation of TNM stage T4 disease to prevent recurrent local disease.

FNA, fine-needle aspiration biopsy.

FIG. 2. Initial diagnosis and therapy of clinically apparent disease.

### ■ DEFINITION 3

MEN 2B is defined as the presence of MTC, marfanoid habitus, medullated corneal nerve fibers, ganglioneuromatosis of the gut and oral mucosa, and PHEO associated with a germline *RET* mutation. There are rare families with classical features of MEN 2B in the absence of an identifiable *RET* mutation. In a patient with one or two of the clinical features of MEN 2B, the only way to be certain of a diagnosis of MEN 2B is to identify a *RET* mutation or identify the clinical features of MEN 2B in other first-degree relatives. In the absence of an autosomal dominant familial inheritance pattern or *RET* mutation, the preponderance of the classical clinical feature of MEN 2B are required to make a clinical diagnosis of MEN 2B. In the presence of a germline *RET* mutation in a child, and in the absence of some or all of the clinical features, that individual is said to be at risk for developing the clinical features of MEN 2B, and appropriate medical management should ensue.

[B4] Role of germline *RET* testing in MTC patients (Figs. 1 and 2, Table 6). Germline testing of *RET* can be used to distinguish cases of sporadic from hereditary MTC (Fig. 2), and the precise *RET* mutations may suggest a predilection toward a particular phenotype (Table 5) and clinical course. This is important because the patient may also require surveillance and management of PHEO and PHPT, and additional family members may

be at risk for developing MTC. Knowledge of the *RET* mutation can guide decisions regarding prophylactic thyroidectomy (Table 6) and intra-operative management of the parathyroid glands. Approximately 95% of patients with MEN 2A and MEN 2B, and 88% of those with FMTC will have an identifiable *RET* mutation (2). In addition, about 1–7% of apparently sporadic cases have identifiable *RET* mutations (75,76), including about 2–9% with *de novo* germline mutations (19,77). *RET* mutations are more likely to be identified in patients with multifocal disease and/or MTC at a young age.

### ■ RECOMMENDATION 1

All patients with a personal medical history of primary C cell hyperplasia, MTC, or MEN 2 should be offered germline *RET* testing. Grade: A Recommendation

### ■ RECOMMENDATION 2

The differential diagnosis in patients with intestinal ganglioneuromatosis should include MEN 2B, which together with their history and physical examinations, family history, and ganglioneuromatosis histology may prompt germline *RET* testing. Grade: B Recommendation

### ■ RECOMMENDATION 3

All people with a family history consistent with MEN 2 or FMTC, and at risk for autosomal dominant inheritance of

TABLE 6. AMERICAN THYROID ASSOCIATION RISK LEVEL AND PROPHYLACTIC THYROIDECTOMY TESTING AND THERAPY

ATA risk level	Age of RET testing	Age of required first US	Age of required first serum Ct	Age of prophylactic surgery
D	ASAP and within the 1st year of life	ASAP and within the 1st year of life	6 months, if surgery not already done	ASAP and within the 1st year of life
C	<3–5 years	>3–5 years	>3–5 years	Before age 5 years
B	<3–5 years	>3–5 years	>3–5 years	Consider surgery before age 5. May delay surgery beyond age 5 years if stringent criteria are met. <sup>a</sup>
A	<3–5 years	>3–5 years	>3–5 years	May delay surgery beyond age 5 years if stringent criteria are met. <sup>a</sup>

<sup>a</sup>A normal annual basal  $\pm$  stimulated\* serum Ct, normal annual neck US, less aggressive MTC family history, and family preference. ASAP, as soon as possible.

the syndrome, should be offered *RET* testing. For MEN 2B this should be done shortly after birth. For MEN 2A and FMTC this should be done before 5 years of age (Table 6). Grade: A Recommendation

#### ■ RECOMMENDATION 4

Lichen planus amyloidosis or pruritis in the central upper back may indicate the presence of a 634 codon mutation and should prompt genetic testing. Grade: C Recommendation

#### ■ RECOMMENDATION 5

Pre- and post-test genetics counseling by a genetics counselor, or other qualified professional, should be offered to all patients undergoing *RET* testing. Grade: C Recommendation

[B5] *Prophylactic thyroidectomy (When should it be performed in a clinically asymptomatic individual with documented RET mutation but a normal thyroid physical examination and no suspicious lymph nodes or thyroid nodules >5 mm on US (if obtained)? See Fig. 1 and Table 6).* MEN 2 patients who present with palpable MTC have a low rate of cure (78,79). In MEN 2 patients, biochemical surveillance to detect CCH or early MTC significantly increased the rate of surgical cure (79), yet sensitivity and specificity were imperfect because some individuals who had surgery did not harbor *RET* mutations, while others experienced MTC recurrence (59,78). Unfortunately, in one series of MEN 2A or FMTC children who underwent prophylactic thyroidectomy at age 4 years or later, 11% experienced biochemical persistence or recurrence, all of whom were operated at age 13 years or later (80). Similarly, there was no persistent or recurrent MTC in a series of 50 children when they underwent prophylactic thyroidectomy and central neck dissection before age 8 years (81). Six children had persistent or recurrent disease postoperatively and had undergone surgery at ages 8, 10, 11, 14, 16, and 19 years old with *RET* mutations in codons 634, 620, 618, 620,

634, and 618, respectively. Of these children, four had no evidence of lymph node metastases at the primary surgery. Conversely, of the three patients with lymph node metastases at surgery, only one remained biochemically free of disease. Thus, biochemical surveillance for MTC has largely been replaced by the use of *RET* mutation status and knowledge of the age and penetrance of MTC in the codon mutated to guide the timing of prophylactic thyroidectomy (2,82,83). Unfortunately, metastatic MTC is not universally preventable in all MEN 2B patients despite prophylactic thyroidectomy shortly after birth (67).

At the Seventh International Workshop on MEN, a classification system was created for *RET* mutations based on risk for aggressive MTC (2). The purpose of the classification system was to offer recommendations for age of prophylactic thyroidectomy, predict phenotype, and establish who should be screened for PHEO (2). This system has been important, but may be improved by recognizing the more aggressive course of the 634 mutation, with young age of onset and a higher rate of PHPT and PHEO (15,84,85). Additionally, some *RET* mutations were not categorized by that system (including codon 630), or were judged appropriate to be reclassified based on more recent data (e.g. codon 609) (63). For these reasons, we have created a categorization system that makes these changes, and allows for periodic updating (see Table 5). ATA level D (ATA-D) mutations carry the highest risk for MTC. These mutations include codons 883 and 918, and are associated with the youngest age of onset and highest risk of metastases and disease specific mortality. ATA level C (ATA-C) mutations carry a lower, yet still high risk of aggressive MTC and include mutations at codon 634. ATA level B (ATA-B) mutations carry a lower risk for aggressive MTC mutations and include mutations at *RET* codons 609, 611, 618, 620, and 630. ATA level A (ATA-A) mutations carry the “least high” risk. Compared to ATA-B mutation carriers of the same age, these patients have lower serum Ct levels, lower tumor stage, and a higher rate of biochemical cure when they undergo prophylactic thyroidectomy at age  $\geq$  4 years old (80). ATA-A mutations include *RET*

\*Stimulated Ct testing historically was done by measuring serum Ct levels at intervals after intravenous administration of the secretagogue pentagastrin and/or calcium (92). Pentagastrin is not available in the United States and many other countries. Additionally, newer calcitonin assays have significantly improved functional sensitivities, currently as low as 1–2 pg/mL. Resultingly, most experts believe that there is rarely a need for stimulated Ct testing in the diagnosis or follow-up of MTC.

gene mutations at codons 768, 790, 791, 804, and 891. Despite this ATA categorization into four levels (A–D), differences in the development and behavior of MTC and the development of MEN 2A features are present between various *RET* mutations even within the same ATA level (86).

With the possible exception of certain “least high risk” ATA-A *RET* mutations, patients with germline *RET* mutations require prophylactic thyroidectomy (Table 6). At the MEN97 Workshop it was determined that surgery should be performed based on the results of *RET* testing for individuals with MEN 2 (87), as *RET* testing has a lower rate of false negatives and false positives than Ct testing (88), which was previously used for early identification and treatment of MTC (2). ATA levels B–D *RET* mutations are associated with nearly complete penetrance of the MTC phenotype at young ages and once metastatic are associated with a low rate of cure (81), and high rate of morbidity and eventual mortality. Early detection and intervention of MTC has been shown to significantly alter the associated mortality (2,79–81). Thus, the main debate now is the timing of prophylactic thyroidectomy during childhood, rather than if it should be done or not. ATA-A *RET* mutations comprise a group of phenotypes that are typically characterized by later onset of MTC that is associated with less aggressive clinical behavior. However, the phenotype of these *RET* mutations is heterogeneous within and between the various *RET* mutations so that at one end of the spectrum, and composing the majority, are MTC phenotypes with late onset, incomplete penetrance, and rare MTC-related death (89,90). At the other end of the spectrum, are the unpredictable minority that have demonstrated aggressive MTC, as witnessed in a 6-year-old child with metastatic MTC with an 804 *RET* mutation (84,91). Proposed strategies to determine the timing of prophylactic thyroidectomy for *RET* mutations have included age cut-offs based on the youngest child reported in the literature with metastatic disease, the more typical age of MTC development for the genotype, basal ± stimulated\* serum Ct measurements, annual neck ultrasound (US), the age that MTC developed in family members, and combinations of these factors (2,79,84,93). The incentive for early prophylactic thyroidectomy is to intervene before the development of metastases because once metastatic, these patients are often incurable (81,94). Further, thyroidectomy prior to lymph node metastasis obviates the need for central compartment lymph dissection which is associated with a higher rate of hypoparathyroidism (81) and vocal cord paralysis. The incentive to delay prophylactic thyroidectomy is to optimize patient safety by operating on older children, whose surgery is technically less difficult and in whom treatment of iatrogenic hypoparathyroidism may be easier. Children undergoing thyroidectomy or parathyroidectomy have higher complication rates than adults, and have better outcomes when operated on by high-volume surgeons (95). There is also some benefit to delayed iatrogenic hypothyroidism (80). From a technical standpoint regarding preservation of parathyroid function, and a developmental standpoint regarding iatrogenic hypothyroidism, experienced surgeons report little benefit to delaying thyroidectomy beyond 3–5 years of life.

#### ■ RECOMMENDATION 6

Infants with ATA-D mutations (MEN 2B) should undergo prophylactic total thyroidectomy as soon as possible and within the first year of life in an experienced tertiary care setting. Grade: B Recommendation

#### ■ RECOMMENDATION 7

Children with ATA-C mutations (codon 634) should undergo prophylactic total thyroidectomy before they are 5 years old in an experienced tertiary care setting. Grade: A Recommendation

#### ■ RECOMMENDATION 8

In patients with ATA-A and ATA-B *RET* mutations, prophylactic total thyroidectomy may be delayed beyond age 5 years in the setting of a normal annual basal ± stimulated\* serum Ct, normal annual neck US, less aggressive MTC family history, and family preference. Surgery is indicated if all of these features are not present. For higher risk mutations (ATA-B), consider treatment before age 5 years in an experienced tertiary care setting, regardless of other factors. Grade: B Recommendation

[B6] *RET* testing in asymptomatic people (In clinically asymptomatic people with normal thyroid physical examinations, who should undergo *RET* testing and why?). Ideally, the initial individual to undergo *RET* testing in any family would be an affected individual with features of MEN 2. Once a germline *RET* mutation has been identified in a family, genetic counseling and *RET* mutation analysis should be offered to all first-degree relatives (96,97). Offspring of a *RET* mutation-affected individual have a 50% risk of inheriting the mutation. Additional risks to members of the kindred are dependent on the relation to a known mutation carrier. Because the absence or presence of the family’s mutation in a relative is so important to their future care, some experts advocate that the test be repeated to confirm the result. In the absence of affected individuals available for testing (due to death or other barriers) within an affected kindred to determine the presence of a causative *RET* mutation, testing can be offered to unaffected individuals; however, the limitations of such testing need to be carefully discussed with the individual to be tested.

#### ■ RECOMMENDATION 9

Once a germline *RET* mutation has been identified in a family, *RET* mutation analysis should be offered to all first-degree relatives of known mutation carriers which should be done before the age of recommended prophylactic thyroidectomy whenever possible. Grade: A Recommendation

Additionally, testing of exon 10 should be considered in individuals with Hirschsprung disease (46). Although mutations are distributed throughout the gene, and some prefer sequencing of all exons in this setting, the most important clinical decision for Hirschsprung disease is whether they also have an activating exon 10 mutation which would confer risk of MEN 2.

\*See footnote, page 574.

#### ■ RECOMMENDATION 10

Testing of exon 10 for activating *RET* mutations should be considered in individuals with Hirschsprung disease. Grade: A Recommendation

[B7] *RET testing methodologies (Is all RET testing the same? How is this testing optimally done?)*. A review of the laboratories listed in the GeneTests directory identifies 38 laboratories that are currently performing DNA analysis of *RET* for MEN 2A, MEN 2B, and familial or sporadic MTC (98). All of the laboratories listed use direct sequence analysis for mutation identification with or without the addition of target mutation analysis for selected hotspots. Although their approaches differ slightly, nearly all evaluate patients for mutations in the five most commonly mutated codons in exons 10 and 11 (C634R, C609, C611, C618, and C620) (46). Multiple laboratories additionally sequence exons 13, 14, 15, and/or 16, while only a few include exon 8. Typically, the cost of the analysis increases as more exons are sequenced. A few laboratories sequence the entire coding region of *RET*, but at a substantially higher cost, and this is likely to be more testing than most patients require. Some laboratories (98) use a two-tiered approach to the analysis, starting with sequence analysis of the most commonly mutated “hotspot” exons and, at the request of the ordering physician, sequencing the remaining exons of *RET* if the initial analysis is negative (99,100). Tiered approaches are at risk of failing to detect rare double mutations. For example, there are a few reports suggesting that codon 804 mutations in conjunction with a second variant in *RET* could be associated with MEN 2B (71–73,101). Unfortunately, the phenotype is not particularly well documented in these reports.

#### ■ RECOMMENDATION 11

Analysis of the MEN 2–specific exons of *RET* is the recommended method of initial testing in either a single or multi-tiered approach. Grade: A Recommendation

#### ■ RECOMMENDATION 12

Sequencing the entire coding region of *RET* to identify MTC causative mutations is not recommended as the initial testing method (Grade: E Recommendation). However, it should be done when the analysis using the recommended method is negative in the clinical setting of MEN 2 or when there is a discrepancy between the genotype and phenotype. Grade: B Recommendation

#### ■ RECOMMENDATION 13

Testing of patients with MEN 2B should include analyses to detect the M918T (exon 16) and A883F mutations (exon 15) present in virtually all of these patients. Grade: A Recommendation

#### ■ RECOMMENDATION 14

In the clinical setting of MEN 2B and negative testing for M918T and A883F mutations, sequencing the entire coding region of *RET* should be performed. Grade: B Recommendation

#### ■ RECOMMENDATION 15

Until the phenotype of MEN 2B associated with codon 804 mutations in conjunction with a second variant in *RET*

is clarified, these patients and mutation carriers should be treated similarly to those with the more typical MEN 2B *RET*-causing mutations. Grade: C Recommendation

[B8] *Genetic testing: privacy vs. notification of potentially affected family members*. In a physician–patient relationship the duty to warn third parties of risk has been established in the case of *Tarasoff et al. v Regents of the University of California*, defined as the “duty to act to prevent foreseeable harm” (102,102a). However, as of 2006, only three legal cases regarding disclosure of genetic information have been brought to trial, two of which are specific to testing for cancer predisposition syndromes that take into account the duty to warn as well as the right to confidentiality (102a,103–105). The case of *Pate v Threlkel* (104), a case assessing duty to warn in an instance of FMTC tried in New Jersey, determined that “a physician can fulfill the duty to warn by notifying the patient of the risk the disorder poses to family members with the patient expected to pass the warning, and to require the physician to seek out at risk relatives would place too heavy a burden upon the physician.” However, in *Safer v the Estate of Pack* (105), a case assessing duty to warn in a family with familial polyposis syndrome, it was ruled that there was “no impediment, legal or otherwise, to recognizing a physician’s duty to warn those known to be at risk of avoidable harm from a genetically transmissible condition. In terms of foreseeability especially, there is no essential difference between the type of genetic threat at issue here and the menace of infection, contagion, or a threat of physical harm.” Thus, the law appears to have taken divergent views on the issue in these two cases under the two different jurisdictions.

Current accepted standards of clinical practice, existing as established professional guidelines, are extremely varied and provide room for interpretation with each case. These guidelines range from prohibiting direct communication between a patient’s physician and their relatives, to allowing contact under special considerations regardless of patient consent. The American Medical Association and American Society of Clinical Oncology guidelines take into consideration the belief that the confidentiality of genetic testing is an absolute with no exceptions, and that the duty to warn at-risk relatives falls to the moral obligation of the patient, owing to the belief that the physician’s foremost obligation is to the patient directly (106,107). However, many guidelines do allow for disclosure of results to at-risk individuals without the patient’s consent, particularly when efforts to obtain consent have failed; when the information disclosed will prevent serious harm; when there is no other reasonable alternative to preventing harm; and precautions are made to only disclose the appropriate information. The World Health Organization, the American Society of Human Genetics, and the National Human Genome Research Institute, as well as many other national and international groups, have adopted this view (108). Probably superseding all of these opinions, guidelines, and case law are the Health Insurance Portability and Accountability Act privacy regulations that make few exceptions for disclosure to inform or warn family members of genetic risk (109–111).

#### ■ RECOMMENDATION 16

The duty to warn should be fulfilled by notifying a competent patient (or legal guardian) of the risk the inherited *RET* mutation may pose to family members, ideally in the

setting of formal genetic counseling. This notification should include the seriousness of the disease and available forms of treatment and prevention. The highest recommendation should be made that the patient pass this warning to potentially affected family members, and the opportunity for genetic counseling and testing of these individuals should be provided. Conversely, physicians should not disclose confidential genetic or medical information without the patient's permission. When a patient or family refuses to notify relatives of their risk or to provide testing or treatment to legal dependents, the physician may involve the local medical ethics committee and/or legal system. Grade: C Recommendation

[B9] *Reproductive options of RET mutation carriers.* Both preimplantation and prenatal testing are available to individuals with MEN 2 (112–115). These testing options rely on identification of the familial *RET* mutation prior to fetal or embryonic testing. Prenatal testing can be performed in the first or second trimester via chorionic villus sampling or amniocentesis, respectively. Preimplantation genetic diagnosis (PGD) is an *in vitro* fertilization technique that isolates and tests a single embryonic cell for single-site *RET* testing. The unaffected embryos are then transferred to the uterus. Therefore, PGD has the potential to remove the disease from the family as only embryos without a *RET* mutation are implanted.

The role of PGD in adult-onset disease remains controversial; it is generally offered for syndromes that have a young age of onset with significant cancer risk and associated morbidity or mortality. With an average age of onset under 30 years of age for ATA level B–D mutations (63) (and cases of metastatic MTC reported in the first months of life in MEN 2B), and a >90% lifetime risk for MTC and up to 57% risk for PHEO, PGD may be an option for individuals with MEN 2 and a known *RET* mutation (114,115).

While a couple may not wish to proceed with prenatal or preimplantation diagnosis, the clinician may have a “duty to warn” and at the minimum, notify the couple that these options are available should they be interested, according to the case of *Meier v Malloy* (103,115).

#### ■ RECOMMENDATION 17

All *RET* mutation carriers of childbearing age should be considered for counseling about the options of prenatal or preimplantation diagnostic testing. Grade: C Recommendation

[B10] *Possibility of inherited disease in RET mutation–negative MTC patients and families (How should RET–negative MTC patients/families be advised about the possibility of inherited disease?).* Patients with sporadic MTC tend to have unifocal disease, later age of onset, and absence of CCH (116–121). The probability that an individual with an apparent sporadic MTC will be found to have a *RET* mutation is about 1–7% (2,75,76,122–124). If one assumes a probability of ≤7%, and a detection of *RET* mutations in 95% of MEN 2A and 2B individuals and 88% in FMTC individuals, then the remaining risk of a patient with apparently sporadic MTC still actually

having hereditary MTC despite no *RET* mutation being identified is <1% [prior probability × (1 – mutation detection frequency)] (2). Thus, additional testing of the patient or family for the development of MEN 2 features is not necessary. Conversely, in the rare family meeting clinical criteria for MEN 2A or 2B, or FMTC in the absence of a *RET* mutation, first-degree relatives of an affected individual have a 50% risk for inheriting the familial syndrome.

#### ■ RECOMMENDATION 18

In a family meeting clinical criteria for MEN 2A or 2B, or FMTC despite negative sequencing of the entire region of the *RET* oncogene, at-risk relatives should be periodically screened for MTC (neck US, basal ± stimulated\* Ct measurement) and associated PHPT (albumin-corrected calcium or ionized calcium) and/or PHEO (plasma free metanephrines and normetanephrines, or 24-hour urine metanephrines and normetanephrines) as indicated by the family phenotype. Screening should continue at 1–3 year intervals at least until the age of 50 years or 20 years beyond the oldest age of initial diagnosis in the family, whichever is latest. Grade: C Recommendation

[B11] *Preoperative testing of asymptomatic RET mutation–positive patients for MTC, PHPT, and PHEO.* In clinically asymptomatic patients with a normal thyroid physical examination and documented *RET* mutation (Fig. 1), what are the roles of preoperative testing for MTC (Ct and cervical US, Table 6), PHPT, and PHEO? In such patients, the primary issues influencing their clinical care are the likelihood they have metastatic MTC, PHPT, and/or PHEO. The risk of metastatic MTC in the youngest MEN 2A children undergoing prophylactic thyroidectomy under age 5 years is very low (84), while there are less data regarding MEN 2B children operated at less than 1 year of age (55,58,67–70,96,125,126). Thus, the value of Ct or US testing in MEN 2A and FMTC children under age 5 years has not been established. Alternatively, of the published MEN 2B cases that include postoperative data, about half of the children operated by 1 year of life have demonstrated persistent disease. Unruh *et al.* (67) described a 9-week-old MEN 2B child with a preoperative Ct of 1150.9 pg/mL. The child was treated with a total thyroidectomy, which demonstrated CCH and microcarcinoma, and excision of three central nodes (apparently benign). Two months postoperatively the serum Ct was 14.1 pg/mL. Nine months later the Ct was 18.7 ng/mL and bilateral neck dissection showed 39 benign lymph nodes and a postoperative Ct of 31.1 ng/mL. This case demonstrates several issues in the youngest MEN 2B patients: 1) post-natal “prophylactic” thyroidectomy to prevent metastatic disease is not possible in all patients, 2) a potential benefit to prophylactic lymph node dissection has not been demonstrated, and 3) the role of the preoperative Ct level in these children is not established. The influence of age on serum Ct is discussed below under the heading *Effects of age or sex on the normal Ct range.*

#### ■ RECOMMENDATION 19

Children with MEN 2A or FMTC who are to undergo prophylactic thyroidectomy before 5 years of age may undergo preoperative Ct and cervical US assessment when

\*See footnote, page 574.

>3 years old, whereas children older than 5 years require them because of the possibility of metastatic MTC, which would change their clinical management. Caution should be used in interpreting Ct values in children less than 3 years old, and especially in those during the first 6 months of life. Grade: B Recommendation

#### ■ RECOMMENDATION 20

Children with MEN 2B who are to undergo prophylactic thyroidectomy before age 6 months may undergo preoperative Ct assessment, whereas older children require it. Cervical US should be done in MEN 2B children as soon as possible. These tests are recommended because of the possibilities of metastatic MTC and of test results changing clinical management. Caution should be used in interpreting Ct values in children <3 years old, and especially those in the first 6 months of life. Grade: B Recommendation

#### ■ RECOMMENDATION 21

When it is decided to delay prophylactic thyroidectomy beyond the first 5 years of life in children with MEN 2A/FMTC:

- A. Basal serum Ct testing and cervical US should be performed annually starting by 5 years of age. Grade: B Recommendation
- B. The role of annual Ct stimulation\* testing in these patients is less certain but may be performed. Grade: C Recommendation

Childhood PHEO (127–129) is rare in MEN 2. The vast majority of MEN 2 PHEOs are intra-adrenal and benign (63). PHEO has been reported at 12 years of age for both the 918 and 634 *RET* mutations (59,63). However, PHEO has occurred in younger children; 8 and 10 years old with 634 *RET* mutations (JF Moley and RF Gagel, respectively, personal communications, February 9, 2009). Of the ATA-B mutations, including the 609 mutation, the youngest have been 19 years old (85), while the youngest ATA-A mutation has been age 28 years (63). From a series of 206 *RET* mutation carriers, Machens *et al.* (63) reported that the 5th percentile for age of PHEO diagnosis in those with *RET* mutations was in the third and fourth decades of life, depending on the mutation (63). They concluded that annual screening for PHEO may be warranted from age 10 years in carriers of *RET* mutations in codons 918, 634, and 630, and from age 20 years in the remainder. Data suggest that measurement of plasma or urinary fractionated metanephrines is the most accurate screening approach for PHEO (130). There is a lack of consensus with respect to imaging the abdomen periodically for PHEO in the absence of abnormal metabolic screening (2).

#### ■ RECOMMENDATION 22

Screening abdominal imaging for PHEO is not recommended in the absence of symptoms or biochemical data suggesting the tumor, except for the rare urgent need to exclude PHEO. Grade: D Recommendation

#### ■ RECOMMENDATION 23

Symptoms or signs consistent with catecholamine excess, or an adrenal mass, should prompt biochemical testing for a PHEO. Grade: B Recommendation

#### ■ RECOMMENDATION 24

In the absence of symptoms or an adrenal mass to suggest the possibility of PHEO, surveillance (including preoperative testing) should include annual plasma free metanephrines and normetanephrines, or 24-hour urine collection for metanephrines and normetanephrines beginning by age 8 years in carriers of *RET* mutations associated with MEN 2B and in codons 630 and 634, and by age 20 years in carriers of other MEN 2A *RET* mutations. Patients with *RET* mutations associated only with FMTC (Table 5) should be screened at least periodically from the age of 20 years. Grades: B Recommendation for genotype–phenotype distinctions, and C Recommendation for the frequency of testing.

#### ■ RECOMMENDATION 25

Because of the high risk to the fetus and mother, women with a *RET* mutation associated with MEN 2 should be biochemically screened for PHEO prior to a planned pregnancy or as soon as possible during an unplanned pregnancy. Grade: B Recommendation

Childhood PHPT (131–134) is rare in MEN 2. In two large studies of MEN 2A patients affected by PHPT the median age at diagnosis was 38 years (133,134). Skinner *et al.* (59) reported children 13 and 18 years of age with PHPT from a series of 38 MEN 2A children.

#### ■ RECOMMENDATION 26

Surveillance for PHPT should include annual albumin-corrected calcium or ionized serum calcium measurements (with or without serum intact-parathyroid hormone [PTH]) beginning by age 8 years in carriers of *RET* mutations in codons 630 and 634, and by age 20 years in carriers of other MEN 2A *RET* mutations, and periodically with *RET* mutations associated only with FMTC (Table 5) starting from age 20 years. Grades: B Recommendation for genotype–phenotype distinctions, and C Recommendation for the frequency of testing.

[B12] *Sources of Ct assay interference.* Accurate and consistent measurements of serum Ct levels are of critical importance for the evaluation and long-term follow-up of patients with MTC. Over the past decade, commercial assay methods for Ct have progressed to the newest two-site, two-step chemiluminescent immunometric assays (ICMAs) that are highly specific for monomeric Ct. With two-site Ct-ICMAs, cross-reactivity or change in results due to procalcitonin; related peptides; hyperparathyroidism (135); pregnancy or lactation (136–138); inflammation, infection, or sepsis (139–141); bilirubin; hemolysis or hemoglobin; and lipemia all appear to be minimal (142–144).

Mild elevations in basal and pentagastrin-stimulated Ct levels may occur with CCH (145), autoimmune thyroiditis

\*See footnote, page 574.

(146,147), chronic renal failure (142,148,149), and mastocytosis (150–153). Compared to the Ct assay upper normal value, these elevations are often up to a few fold higher, but occasionally be more than 10-fold higher (148). Minimal changes in serum Ct occur in healthy subjects with hypergastrinemia (154). The “hook effect” is less likely to occur with the two-site monoclonal, two-step assays, but should remain a concern in the interpretation of “low” Ct levels in patients with widely disseminated disease (155). Heterophilic antibodies (human antibodies that bind animal antibodies) have been described to cause falsely elevated (and rarely falsely lower) Ct levels (156–158). Nonthyroidal neuroendocrine tumors secreting Ct have been described including the foregut (159), pancreatic tumors (160,161), insulinoma (162), glucagonoma (163), VIPoma (164,165), carcinoid (166), prostate (167), small cell lung cancer (159), and large cell lung cancer with neuroendocrine differentiation (168). Two caveats which may be helpful diagnostically are that these tumors typically do not increase their Ct secretion in response to Ct stimulation testing and they usually produce less Ct per gram of tissue than is typical for MTC.

#### ■ RECOMMENDATION 27

It should be recognized that minimal or mild elevations in serum Ct may be seen in multiple clinical settings including CCH, renal failure, and autoimmune thyroiditis. Elevated Ct levels may occur from nonthyroidal neuroendocrine neoplasms and heterophilic antibodies. Falsely low Ct levels may occur in the setting of heterophilic antibodies and the “hook effect.” Grade: B Recommendation

[B13] *Effects of age or sex on the normal Ct range.* Considerable variability among commercial assay results (142) indicates a need to follow individual patients with the same assay over time. Laboratories should report the assay being used and notify clinicians of changes in methodology when they occur. If the method changes, optimally, Ct levels should be measured using both the current and prior methods to allow for a “re-baselining” of values. Conversely, if an unexplained change occurs in the Ct levels in a patient, a change in laboratory method should be considered as a potential cause. Current reference ranges vary with sex and are higher in men than women (142,144,169), possibly due to more C cells in men than women (170). Weak correlations between the Ct level and age, body mass index, and smoking have been reported (142). Depending on the assay used, about 56–88% of normal subjects have serum Ct levels below the assay functional sensitivity, while 3–10% of subjects have Ct levels >10 pg/mL (142). Using the Advantage system (Nichols Institute Diagnostics, San Juan Capistrano, CA), Basuyau *et al.* (144) found the 95th percentile to be 5.2 ng/L and 11.7 ng/L in women and men, respectively. Limited data have suggested that serum Ct levels may increase in response to a meal, although other studies have found no impact (171–175).

#### ■ RECOMMENDATION 28

Optimally, an individual should be followed using the same Ct assay over time. Whenever possible, a blood sample should be measured using both assays to re-establish the baseline when it is necessary to change the assay. Grade: C Recommendation

#### ■ RECOMMENDATION 29

Laboratories should report the Ct assay being used, and notify clinicians of changes in methodology when they occur. Grade: C Recommendation

#### ■ RECOMMENDATION 30

In the setting of an intact thyroid gland, Ct values should be interpreted in the setting of sex-specific reference ranges, at least in adults. Grade: B Recommendation

Few data exist on age-specific Ct levels for young children. Previous studies have suggested that Ct concentrations are particularly high during the first week of life, in low-birthweight children, and in premature infants (144). A previous two-site immunometric assay, that is no longer available, reported no difference in the mean Ct value for children ( $1.3 \pm 2.7$  pg/mL) and adults ( $0.9 \pm 2.5$  pg/mL) with more than half of the children having Ct levels <0.2 pg/mL with this assay (143). No significant sex difference was observed (143).

However, only a limited number of samples from children <3 years of age have been analyzed using a contemporary two-site immunometric assay. Using the Advantage system (Nichols Institute Diagnostics), Basuyau *et al.* (144) proposed a reference range of <40 ng/L in children under 6 months of age and <15 ng/L in children between 6 months and 3 years of age, and indicated that in children over 3 years of age the values were indistinguishable from those observed in adults. The highest value observed in their series was 75 ng/L at age 4.5 months with a follow-up value of 32.4 ng/L one month later (144).

#### ■ RECOMMENDATION 31

Due to the limited data available on the normal range for serum Ct in children <3 years of age and the probability that it may be higher than in adults, caution should be used in interpreting these values in young children. Grade: B Recommendation

[B14] *Surgery for the youngest MEN 2B patients (Fig. 1).* The youngest MEN 2B patients are <1 year of age. The age of MTC onset is much earlier in MEN 2B than in MEN 2A and FMTC (60,63). Foci of MTC may be present in infancy and nodal metastases can become apparent in early childhood (59,60,64,65,67,78). For these reasons, it is recommended that genetic testing be done as soon as possible after birth in at-risk infants (Table 6), and that thyroidectomy be performed in MEN 2B *RET*-positive individuals as soon as possible and within the first year of life if possible (Table 6, Fig. 1). It should be noted, however, that this opportunity is uncommon given the rarity of MEN 2B and that more than 50% of cases are *de novo* germline *RET* mutations diagnosed much later in life (18,60). Children undergoing thyroid or parathyroid surgery have higher complication rates than adult patients that are minimized when surgeries are performed by high volume surgeons (95). This emphasizes that it is important that the surgeon operating on infants be experienced, and familiar with the recurrent laryngeal nerve and parathyroid gland management in young children. The parathyroid glands are very small and translucent in infants. Proper identification and handling is critical to avoiding hypoparathyroidism. Nodal metastases may already be present, and a thorough central neck dissection may require removal and auto-transplantation of parathyroid glands, a technique in which

the surgeon should have expertise. While an elevated Ct level may indicate the presence of MTC, and high levels are consistent with metastases (94), the role, interpretation, and value of preoperative Ct and other biochemical or imaging tests in MEN 2B children <1 year old is unclear as published data have largely described older MEN 2B children with elevated Ct levels prior to thyroidectomy (58–60,64,176). While some have advocated for prophylactic central neck dissection (with or without lateral neck dissections) in the youngest MEN 2B children (12,58,59,64), its unproven benefits must be balanced against the risk and serious management challenge of hypoparathyroidism in this age group.

#### ■ RECOMMENDATION 32

MEN 2B patients undergoing prophylactic thyroidectomy within the first 1 year of life should have this procedure performed in an experienced tertiary care setting, and preservation of parathyroid function should be given a high priority. Grade: C Recommendation

#### ■ RECOMMENDATION 33

Prophylactic level VI central compartment neck dissection may not be necessary in MEN 2B patients who undergo prophylactic thyroidectomy within the first year of life unless there is clinical or radiological evidence of lymph node metastases or thyroid nodules >5 mm in size (at any age), or a serum basal serum Ct > 40 pg/mL in a child >6 months old; all of which suggests the possibility of more extensive disease that requires further evaluation and treatment (see Fig. 1). Grade: E Recommendation

[B15] *Surgery for the youngest MEN 2A or FMTC patients (Fig. 1).* The youngest MEN 2A and FMTC patients are 3–5 years of age. In the setting of a normal thyroid examination, it is not clear that these children are benefited by preoperative measurement of Ct, calcium, or neck US because the rates of metastases or PHPT are so low. Still, many clinicians prefer to obtain a preoperative basal serum Ct. If the basal Ct level is less than 40 pg/mL it is unlikely that lymph node metastases are present (80,94,177). Frank-Raue *et al.* (80) reported that only one of their five patients who had persistent or recurrent disease after undergoing prophylactic thyroidectomy had a preoperative Ct <40 pg/mL. Scheuba *et al.* (178) evaluated 97 patients with MTC ≤ 1 cm and reported one patient (1%) with lymph node metastases and a basal serum Ct <40 pg/mL. Thus, when the preoperative serum Ct is <40 pg/mL then a total thyroidectomy without central (level VI) neck dissection may be adequate therapy. In this procedure, all thyroid tissue should be removed. This includes the tubercle of Zuckerkandl, pyramidal lobe, and all superior pole tissue. If a thyroid US demonstrates a nodule >5 mm in size, or the basal Ct level is over 40 pg/mL (which is unlikely in this age group), there is a higher risk of lymph node metastases (94), and further evaluation prior to intervention is warranted (see Fig. 1). All efforts must be made during surgery to prevent hypoparathyroidism.

#### ■ RECOMMENDATION 34

MEN 2A or FMTC patients who undergo prophylactic thyroidectomy within the first 3–5 years should have this procedure performed in an experienced tertiary care setting, and preservation of parathyroid and recurrent laryn-

geal nerve function should be given a high priority. Grade: C Recommendation

#### ■ RECOMMENDATION 35

MEN 2A or FMTC patients undergoing prophylactic thyroidectomy within their first 3–5 years should not undergo prophylactic level VI compartmental dissection unless there is clinical or radiological evidence of lymph node metastases, or thyroid nodules >5 mm in size at any age, or a basal serum Ct >40 pg/mL (see Fig. 1). Grade: E Recommendation

#### ■ RECOMMENDATION 36

In MEN 2A or FMTC, the clinical or radiological evidence of lymph node metastases or thyroid nodules ≥5 mm in size at any age, or a serum basal serum Ct of >40 pg/mL when >6 months old, suggests the possibility of more extensive disease that requires further evaluation and treatment (see Fig. 1). Grade: B Recommendation

[B16] *Preoperative imaging and biochemical testing to evaluate for MTC in older RET mutation-positive patients (Fig. 1).* Older asymptomatic MEN 2A and FMTC patients are those >5 years of age, while for MEN 2B this cut-off is lowered to >1 year of age. Over these cut-offs, there is an increased possibility that MTC may have already developed and possibly metastasized. In these patients, evaluation should include physical examination, serum Ct, and neck US. The neck US should evaluate the thyroid, as well as the lymph nodes of the superior mediastinum, the central neck, and the lateral neck compartments. Experienced ultrasonographers have a high sensitivity to identifying cervical metastases in adults, especially in the lateral neck, whereas experience with childhood MTC is more limited. Machens *et al.* (94) reported from their series that nodal metastases began to be seen with serum Ct levels of 40 pg/mL, and primary tumors diameters as small as 5 mm. In MTC, the initial site of metastases is typically to cervical lymph nodes. Cervical lymph node metastases, as well as extra-thyroidal extension, are predictors of distant metastases. The basal serum Ct can also indicate the risk of distant metastases (94).

#### ■ RECOMMENDATION 37

In asymptomatic MEN 2A and FMTC patients who present at age >5 years and asymptomatic MEN 2B patients who present at age >1 year, preoperative basal serum Ct and neck ultrasonography should be performed. Grade: B Recommendation

#### ■ RECOMMENDATION 38

In asymptomatic MEN 2A and FMTC patients who present at age >5 years and asymptomatic MEN 2B patients who present at age >1 year, further evaluation prior to surgery and more extensive surgery are needed if the basal serum Ct is >40 pg/mL, if thyroid nodules are ≥5 mm, or if suspicious lymph nodes are identified on neck US. Grade: B Recommendation

[B17] *Surgery for the older MEN 2B patients without evidence of cervical lymph node metastases and normal or minimally elevated Ct levels (Fig. 1).* Identification of an MEN 2B patient >1 year old with all thyroid nodules <5 mm, normal-



appearing cervical lymph nodes on US, and a serum Ct level <40 pg/mL would be unusual. Most MEN 2B patients are diagnosed later in life with markedly elevated Ct levels and obvious lymph node metastases (58,59,64,176,179). Two recent series report that the mean age of diagnosis among their MEN 2B patients as 13–14 years old (70,180). In one of these series, 2 of 5 (40%) children operated at age <5 years versus only 1 of 20 (5%) children who were  $\geq$ 5 years old at surgery were biochemically cured of MTC (70). In a third series of 18 MEN 2B patients (64), the oldest child with disease status of T1N0M0 or less was 3.4 years old. These reports are consistent with other series showing that among MEN 2B children who undergo surgery by age 10 years old about half have cervical lymph node metastases (59,60,64) while still others will demonstrate recurrent or persistent disease during follow-up such that only about one-quarter remain free of disease.

#### ■ RECOMMENDATION 39

In an MEN 2B patient >1 year old with all thyroid nodules <5 mm on US and with a serum Ct level <40 pg/mL, a total thyroidectomy is recommended. Grade: A Recommendation

#### ■ RECOMMENDATION 40

In an MEN 2B patient >1 year old with all thyroid nodules <5 mm on US and with a serum Ct level <40 pg/mL, inadequate data are available to guide decisions on prophylactic lymph node dissections. Based on expert opinion, the Task Force favored a prophylactic central neck dissection (recognizing that this would likely require autotransplantation of at least the inferior parathyroid glands), without lateral compartment neck dissection except in the setting of radiographic or clinically proven metastases to these regions. Grade: C Recommendation

[B18] *Surgery for the older MEN 2A or FMTC patients without evidence of cervical node metastases and normal or minimally elevated Ct levels (Fig. 1).* In an MEN 2A or FMTC patient >5 years old with all thyroid nodules <5 mm on neck US and with a serum Ct level <40 pg/mL a prophylactic thyroidectomy is indicated. However, there is no evidence to compel prophylactic lymph node dissections because nodal metastases are unlikely when the basal serum Ct level is <40 pg/mL (80,94,178). Lymph node metastases are uncommon under the age of 11 years (3%), and when they are present their resection may result in long-term biochemical remission in only about one third of these patients, while 6% of all children undergoing central neck dissection may suffer hypoparathyroidism (81). During the thyroidectomy, all thyroid tissue should be removed including the tubercle of Zuckerkandl, the pyramidal lobe, and all superior pole tissue. If the basal Ct level is >40 pg/mL, there is a higher risk of lymph node metastases, and further evaluation is indicated (see Fig. 1).

#### ■ RECOMMENDATION 41

In an MEN 2A or FMTC patient >5 years old with all thyroid nodules <5 mm on neck US and with a serum Ct level <40 pg/mL, a total thyroidectomy is recommended. The age when this is performed is based on the ATA risk level (Tables 5 and 6). Grade: B Recommendation

#### ■ RECOMMENDATION 42

In an MEN 2A or FMTC patient >5 years old with all thyroid nodules <5 mm on neck US and with a serum Ct level <40 pg/mL, a prophylactic lymph node dissection is not recommended. Grade: E Recommendation

[B19] *Diagnostic testing for RET mutation–positive patients suspected of having metastases based on imaging or serum Ct level.*

#### ■ RECOMMENDATION 43

Patients harboring *RET* oncogene mutations who have clinical or radiographic findings suspicious for metastatic MTC, including those with thyroid nodules  $\geq$ 5 mm or a serum Ct level >40 pg/mL, should be considered for further evaluation prior to surgery as outlined in Fig. 2. Grade: B Recommendation

[B20] *Management for normal parathyroid glands resected or devascularized during surgery.* Normal parathyroid glands can be accidentally removed or devascularized during thyroidectomy or central neck lymph node dissection procedures. In all instances, the operating surgeon should be experienced at localizing the parathyroid glands, especially in children, and have expertise with parathyroid autotransplantation. Normal parathyroid tissue should be left in the patient whenever possible, either on an adequate vascular pedicle *in situ*, or if that is not possible, transplanted into the neck or forearm (181). The location to place the transplanted tissue is determined by the type of *RET* mutation present. Patients with a strong family history of PHPT, or with a *RET* mutation associated with a significant risk of PHPT (Table 5), should have the parathyroid tissue placed in the forearm. If the patient has MEN 2B, FMTC or a mutation with a low risk of PHPT (Table 5), the grafts may be placed in the sternocleidomastoid muscle.

#### ■ RECOMMENDATION 44

Devascularized normal parathyroid glands from patients with MEN 2B or FMTC should be autografted into the sternocleidomastoid muscle of the neck. Grade: C Recommendation

#### ■ RECOMMENDATION 45

Devascularized normal parathyroid glands from patients with MEN 2A in a kindred with strong family history of PHPT, or a *RET* mutation carrying a significant risk of PHPT, should be autografted into the forearm. Grade: C Recommendation

#### ■ RECOMMENDATION 46

Devascularized normal parathyroid glands from patients with a *RET* mutation associated with both MEN 2A with a low risk of PHPT and FMTC, whose kindred suggests FMTC, may undergo autograft of the parathyroid tissue into either the forearm or the sternocleidomastoid muscle. Grade: C Recommendation

[B21] *Treatment for PHPT in MEN 2A.* For the patient who has not had prior neck surgery and has PHPT diagnosed at the time of planned thyroidectomy, surgical options include resection of just the visibly enlarged glands (with a forearm

autograft), subtotal parathyroidectomy leaving one or a piece of one gland *in situ* (with a forearm autograft), and total parathyroidectomy with forearm autograft (81,182–184). It is argued that forearm parathyroid autografting should always be performed when parathyroid tissue is removed unless a functioning forearm autograft is known to already be present. This is because of the increased risk that subsequent neck operations will be needed (typically for recurrent MTC) and the remaining *in situ* parathyroid tissue may not be identified and preserved; resulting in permanent hypoparathyroidism. Importantly, most MEN 2A patients with PHPT have undergone prior thyroidectomy (prophylactically or therapeutically for MTC) with or without a complete level VI dissection. Such patients who then develop PHPT should not undergo a neck exploration without preoperative localization (e.g., US, sestamibi, computed tomography [CT]), and in general, only localized, hypertrophied parathyroid glands should be excised. Forearm parathyroid autografting should be performed unless a functioning forearm autograft is known to already be present, even if intra-operative PTH values suggest the presence of additional parathyroid tissue in the neck. This is because of the risk for MTC recurrence and the need for subsequent neck operations at which time all remaining parathyroid tissue in the neck may be removed with the tumor specimen and not recognized as parathyroid tissue. The result would be permanent hypoparathyroidism; an avoidable complication in most MEN 2A patients if autografting is performed at the first opportunity.

Considering medical therapy, calcimimetics increase the sensitivity of parathyroid calcium-sensing receptors to extracellular calcium, thereby reducing PTH secretion. A multicenter, randomized, double-blind, placebo-controlled study has assessed the ability of the oral calcimimetic cinacalcet HCl to achieve long-term reductions in serum calcium and PTH concentrations in patients with PHPT. Cinacalcet rapidly normalized serum calcium and reduced PTH in these patients and these effects were maintained with long-term treatment (185). Cinacalcet may be an effective, nonsurgical approach for management of PHPT, but whether or not these data are applicable to MEN 2A-associated PHPT is uncertain, and data regarding outcomes such as fractures, kidney stones, and cardiovascular disease are not available. However, medical therapy is likely to have an increased role in patients with persistent or recurrent PHPT, and in those who are suboptimal surgical candidates.

#### ■ RECOMMENDATION 47

Because of the high rate of biochemical cure of PHPT in MEN 2A with surgery, initial surgical therapy is preferred to medical therapy, in the absence of contraindications such as excessive surgical risk or limited life expectancy. Grade: C Recommendation

#### ■ RECOMMENDATION 48

Surgical management of PHPT at the time of initial thyroidectomy should always be performed if the diagnosis of PHPT is established. Surgical options include resection of just the visibly enlarged glands (with a forearm autograft), subtotal parathyroidectomy leaving one or a piece of one gland *in situ* (with a forearm autograft), and total parathyroidectomy with forearm autografting. Because of the risk for permanent hypoparathyroidism following one or more neck operations in patients with MEN 2A, combined

with the frequent delay in autograft function, forearm parathyroid autografting should always be performed with the initial PHPT surgery. Most experts avoid total parathyroidectomy unless all four glands are obviously abnormal and preservation of an *in situ* parathyroid remnant is not possible. Grade: C Recommendation

#### ■ RECOMMENDATION 49

For patients who are found to develop PHPT after a prior thyroidectomy, operative management should be directed parathyroid surgery and based on the findings from preoperative parathyroid localization studies. Forearm parathyroid autografting should always be performed unless a functioning forearm autograft is known to already be present; even if intra-operative PTH values suggest the presence of additional parathyroid tissue in the neck. Grade: C Recommendation

#### ■ RECOMMENDATION 50

Medical therapy to control PHPT in MEN 2A should be considered in patients with high risk of surgical mortality, limited life expectancies, or persistent or recurrent PHPT after one or more surgical attempts for cure. Grade: C Recommendation

#### [C] Initial diagnosis and therapy of clinically apparent disease

Fine-needle aspiration biopsy (FNA) of thyroid nodules is one of the most useful, safe, and accurate tools in the diagnosis of thyroid pathology. Chang and colleagues (186) investigated the pitfalls in the diagnosis of MTC by FNA. Cytomorphology was reviewed in the FNA slides of 34 patients with proven MTC. Eighty-two percent of cases were diagnosed correctly as MTC by FNA, three cases were misdiagnosed as follicular neoplasm and one as desmoid, and two cases were suspicious for MTC. Thus, FNA would have indicated the need for surgery due to lack of benign findings in essentially all of these patients. Similarly, Papaparaskeva *et al.* (187) reported that FNA findings indicated the need for surgery in 99% of their MTC cases, and diagnosed MTC in 89%. They reported that the most important cytologic criteria of MTC with FNA were dispersed cell-pattern of polygonal or triangular cells, azurophilic cytoplasmic granules, and extremely eccentrically placed nuclei with coarse granular chromatin and amyloid. Bugalho *et al.* (188) reported the sensitivity of FNA for MTC as 63%, compared to a sensitivity of 98% for serum Ct. However, while only 9% of patients might have escaped surgery based on FNA results, attention to the central neck compartment may have been diminished in a greater number due to the lack of suspected MTC.

Elisei and colleagues (189) reported the results of Ct screening in 10,864 patients with thyroid nodular disease. The prevalence of MTC found by Ct screening was 0.40%. A positive Ct test had a higher diagnostic sensitivity and specificity compared with FNA. Ct screening allowed the diagnosis of MTC at an earlier stage compared to an unmatched control group diagnosed with MTC that did not undergo Ct screening. Normalization of serum Ct levels (undetectable) after surgery was more frequently observed in the Ct-screened group. At the end of follow-up, complete remission was observed in 59% of the Ct-screened group and in 2.7% of the control group ( $p = 0.0001$ ).

Currently, the use of serum Ct to complement FNA in making the diagnosis of MTC remains controversial. It is recognized that basal (>20–100 pg/mL) and pentagastrin stimulated serum Ct levels (>100–500 pg/mL) may be used to identify patients with MTC, but with imperfect cut-off levels to optimize sensitivity and specificity (190,191). Karges *et al.* (3) recommended that to exclude MTC, serum Ct should be determined in patients with nodular thyroid disease. If basal serum Ct exceeds 10 pg/mL, Ct should be analyzed by pentagastrin stimulation testing, after renal insufficiency and proton pump inhibitor medication have been excluded as confounding contributors to the Ct level. Karges *et al.* (3) report that the risk for MTC is higher than 50% in patients with stimulated Ct values >100 pg/mL. Conversely, they reported that pentagastrin-stimulated Ct values <100 pg/mL are associated with a low risk of MTC, or very rarely, non-metastasizing micro-MTC (size <10 mm) (3). However, pentagastrin is not available for stimulation testing in the United States and many other countries. Costante *et al.* (190) reported that the positive-predictive value of basal Ct to diagnose MTC with values  $\geq 20$  and  $\leq 50$  pg/mL,  $\geq 50$  and  $\leq 100$  pg/mL, and  $\geq 100$  pg/mL were 8.3%, 25%, and 100%, respectively.

Given that MTC is present in about 0.3–1.4% of patients with thyroid nodules (189,191–199), routine serum Ct measurement in all patients with thyroid nodules has raised concerns of cost-effectiveness, especially when many of the operated patients would not have disease based on the imperfect specificity if a cut-off was chosen that optimized sensitivity. Additionally, the clinical significance and natural history of MTC diagnosed by Ct screening is unknown. However, cost-effectiveness studies in the United States have been favorable (200,201), although these models are quite sensitive to multiple important decision analysis variables, including cost of the Ct test, such that assuming a relatively small increase in cost could substantially alter the conclusions. Recent studies utilizing Ct measurement from thyroid nodule FNA washings may significantly improve this testing accuracy (202,203), although some questions of cost-effectiveness are likely to remain. However, the low rate of cure once disease is present outside of the thyroid gland bolsters interest in early diagnosis and treatment.

#### ■ RECOMMENDATION 52

This Guideline defers the recommended approach to thyroid nodules, including FNA and serum Ct testing, to the ATA Guideline that addresses thyroid nodules (5). However, if obtained, a basal or stimulated\* serum Ct level  $\geq 100$  pg/mL should be interpreted as suspicious for MTC and further evaluation and treatment should ensue (Fig. 2). Grade: A Recommendation

[C1] Preoperative laboratory testing for presumed MTC when an FNA or Ct level is diagnostic or suspicious for MTC (Fig. 2). Preoperative laboratory testing has three purposes: first, to predict the extent of metastatic disease because this will determine the extent of preoperative imaging and may alter the surgical approach (Fig. 2); second, to identify the comorbid conditions of PHPT and/or PHEO in MEN 2 that

would alter the surgical approach and surgical priorities; and third, to identify *RET* mutation carriers so that testing of appropriate family members can allow for early diagnosis and treatment of affected individuals.

Although a variety of substances including carcinoembryonic antigen (CEA), chromogranin A, Ct gene-related peptide, adrenocorticotrophic hormone, amyloid, somatostatin, serotonin, and vasoactive intestinal peptide can be produced by MTC tumor cells, Ct is the main biochemical marker used for detection, staging, postoperative management, and prognosis in patients with MTC. Very rarely Ct may not be elevated in the serum despite clinically apparent MTC (204).

Concomitant PHPT is unlikely in the absence of MEN 2A, however, because measurement of serum calcium is readily available and because *RET* oncogene testing results may not be available before surgery (although when possible, the germline *RET* mutation status of the patient should be determined prior to surgery), preoperative measurement of serum calcium is prudent. Similarly, PHEO is unlikely in the absence of MEN 2. However, because PHEO would alter operative planning it is critical that this tumor be excluded or treated prior to surgery for MTC. Completion of both the adrenal and neck surgeries during the same anesthesia induction may be considered.

#### ■ RECOMMENDATION 53

Preoperative evaluation of patients presumed to have MTC (when an FNA or Ct level is diagnostic or suspicious for MTC) should include serum measurements of basal Ct, CEA, and calcium (albumin-corrected or ionized); and *RET* protooncogene analyses. PHEO preoperative screening should begin by age 8 years for those with MEN 2B, and mutated *RET* codons 634 and 630; and by age 20 years for other *RET* mutations. Exclusion of PHEO may include any of the following tests: 1) negative *RET* protooncogene analysis and family history; 2) negative plasma free metanephrines and normetanephrines, or negative 24-hour urine metanephrines and normetanephrines; 3) negative adrenal CT or magnetic resonance imaging (MRI). Grade: A Recommendation

[C2] Evaluation and treatment of PHEO. Routine PHEO screening was discussed above. The high risk of anesthesia and surgery in the presence of a PHEO dictates that its management takes the highest surgical priority. In the setting of MTC, the presence of an extra-abdominal PHEO is rare.

#### ■ RECOMMENDATION 54

Patients with MTC and elevated plasma free metanephrines or normetanephrines, or elevated 24-hour urine metanephrines or normetanephrines should undergo adrenal imaging for PHEO with MRI or CT scan. Grade: A Recommendation

#### ■ RECOMMENDATION 55

In the setting of MTC, routine extra-abdominal imaging for PHEO is not indicated. Grade: E Recommendation

\*See footnote, page 574.

#### ■ RECOMMENDATION 56

PHEO should be surgically resected after appropriate preoperative preparation and prior to surgery for MTC or PHPT, preferably by laparoscopic adrenalectomy. Grade: A Recommendation

One study documented that 22% of patients experienced several episodes of Addisonian crisis, including a death, after bilateral adrenalectomy. The authors concluded that adrenal-sparing adrenalectomy and close monitoring of the remnant may be the treatment of choice for hereditary bilateral PHEO in MEN 2A, since overall recurrence is low (205).

#### ■ RECOMMENDATION 57

Cortical-sparing adrenal surgery may be considered in patients requiring surgery when there is only one remaining adrenal gland, or when bilateral PHEOs are present. Grade: C Recommendation

[C3] Preoperative imaging for presumed MTC when an FNA or Ct level is diagnostic or suspicious for MTC (Fig. 2). Preoperative imaging is indicated because local neck or distant metastatic disease may change the operative approach. The sensitivity of intra-operative palpation to detect lymph node metastases by experienced surgeons is only 64% (117). Lymph node metastases are present in >75% of patients with palpable MTC (117,119). In the setting of an experienced ultrasonographer, neck US is the most sensitive test to detect local metastases in the cervical compartments and upper aspect of the superior mediastinum (206). However, it is common that a higher number of malignant lymph nodes are removed surgically during compartmental lymph node dissections than were visualized preoperatively with US, which demonstrates the reduced sensitivity of all diagnostic maneuvers to localize the smallest lymph node metastases.

Patients with distant metastases are viewed as incurable, and the goals of locoregional surgery may differ from the goals of surgery in patients with less extensive disease. Distant metastases most commonly affect the bones/bone marrow, liver, and lungs (207). Metastases to brain and skin are less common and associated with multisystemic disease and poor 1-year survival (208). Liver metastases often appear similar to hepatic hemangiomas with calcifications (209). Unfortunately, radiographic detection of distant metastatic disease is unlikely when the preoperative Ct level is <250 pg/mL (210). Machens et al. (94) found that radiographically identifiable distant metastases began to appear in the primary surgery setting at a preoperative basal serum Ct level of 400 pg/mL and at primary tumor diameters of 12 mm. In the setting of the primary surgery, the risk of radiographically detectable distant metastases exceeded 50% at preoperative basal serum Ct levels of 15,000 pg/mL, and primary tumor diameters of 50 mm (94). Distant metastases were almost always present when preoperative basal serum Ct levels were >100,000 pg/mL or the primary tumor diameter was >60 mm (94). The cumulative risks of distant metastases did not differ between sporadic and hereditary MTC (94).

Giraudet et al. (206) reported that the most sensitive methods to detect metastases in the neck was US followed by contrast-enhanced CT. CT was most sensitive to detect lung and mediastinal lymph node metastases. Contrast-enhanced

MRI was the most sensitive to detect liver metastases. Axial MRI and bone scintigraphy were complementary and most sensitive to detect bone metastases. Fluorodeoxyglucose positron emission tomography (FDG PET) was less sensitive than these modalities to identify metastases. Oudoux et al. (211) also found that CT was more sensitive than FDG PET for the lung and liver, and that MRI of the spine and pelvis was more sensitive than FDG PET to detect bone and bone marrow metastases. However, FDG PET was more sensitive than CT to detect disease in the neck and mediastinum in their series. While correlated, Ct doubling time (DT) and the CEA DT are better predictors of tumor progression than is the FDG PET maximum standardized uptake value (SUVmax) (211,212).

Unfortunately, no single test provides optimal whole-body imaging. This Task Force concluded that a comprehensive preoperative imaging strategy was not practical, and probably was not necessary to guide initial therapy as nearly all patients with residual disease postoperatively can be identified biochemically and selected then for further evaluation.

#### ■ RECOMMENDATION 58

Preoperative neck US is recommended for all patients when an FNA or Ct level is diagnostic or suspicious for MTC. Grade: A Recommendation

#### ■ RECOMMENDATION 59

Preoperative chest CT, neck CT, and three-phase contrast-enhanced multidetector liver CT or contrast-enhanced MRI is recommended for all patients with suspected MTC when local lymph node metastases are detected (N<sub>1</sub>), or the serum Ct is >400 pg/mL. Grade: C Recommendation

#### ■ RECOMMENDATION 60

FDG PET imaging and somatostatin receptor imaging are not recommended for routine initial screening for MTC metastases in patients when an FNA and/or Ct level is diagnostic or suspicious for MTC. Grade: E Recommendation

[C4] Surgery for MTC patients without advanced local invasion or cervical node or distant metastases (Fig. 2). These patients have not undergone prior thyroidectomy, have no evidence of cervical lymph node metastases by physical examination and cervical US. MTC has a high rate of lymph node metastases (117,119) that are suboptimally detected preoperatively in the central compartment by US or intra-operatively by the surgeon (117), and re-operation is associated with a higher rate of surgical complications (119). For these reasons, most authors advocate for a total thyroidectomy and prophylactic central neck dissection in the setting of clinically detected MTC (12).

#### ■ RECOMMENDATION 61

Patients with known or highly suspected MTC with no evidence of advanced local invasion by the primary tumor, no evidence cervical lymph node metastases on physical examination and cervical US, and no evidence of distant metastases should undergo total thyroidectomy and prophylactic central compartment (level VI) neck dissection. Grade: B Recommendation

Because of the low rate of biochemical cure in patients with lymph node metastases or large primary tumors, there is diminished enthusiasm for prophylactic lateral neck dissections. Indeed, Machens et al. (94) reported that the cumulative rates of biochemical remission (basal and pentagastrin-stimulated serum Ct <10 pg/mL) in node-negative MTC patients declined to 50% when the preoperative basal serum Ct levels was >300 pg/mL, or the primary tumor measured more than 10 mm. Overall, 38% of node-negative MTC patients who undergo extensive surgery failed to achieve normal postoperative serum Ct levels, suggesting early radiographically occult distant metastases (94). In node-positive patients, only 10% achieved postoperative basal and pentagastrin-stimulated serum Ct levels <10 pg/mL, which did not happen when the preoperative basal Ct level was >3000 pg/mL or the tumor was >40 mm in diameter (94). The correlation with biochemical remission was better for basal than for pentagastrin-stimulated serum Ct levels. About 3.3% of patients that achieve biochemical remission are likely to demonstrate biochemical recurrence over the subsequent 0.7 to 7.5 years (213). In addition, lateral neck compartmental dissection can be associated with long-term cosmetic and functional consequences. Thus, in the current era of high resolution neck imaging, lateral neck dissection (levels IIA, III, IV, V) may be best reserved for patients with positive preoperative imaging, although a minority of the Task Force favored prophylactic lateral neck dissection when lymph node metastases were present in the adjacent paratracheal central compartment.

[C5] *Surgery for MTC patients with limited local disease and limited or no distant metastases (Fig. 2).* Limited local disease is considered  $\leq T3$  and  $\leq N1b$  lymph node status with subcentimeter lymph node metastases including those with minor extra-nodal extension (Table 4). Limited distant metastases are typically subcentimeter in size but may also include macroscopic distant metastases when they are few in number. Significant differences in survival times are present between patients who achieve complete remission, those with biochemically persistent disease postoperatively, and those with distant metastases (214). Unfortunately, most MTC patients with metastases to regional lymph nodes are not biochemically cured despite aggressive surgery to include bilateral neck dissection. Modigliani et al. (40) demonstrated in multivariate analysis that age and stage were independent predictive factors of survival, whereas the type of surgery was not. However, in patients with persistent elevations in Ct levels, survival was still good: 80.2% and 70.3% at 5 and 10 years, respectively. Similarly, Pelizzo et al. (12) demonstrated in multivariate analysis that age, stage, and extent of surgery were independent predictive factors of survival; with more extensive surgery correlating with a worse prognosis. Leggett et al. (215) demonstrated that an increased number of lymph nodes resected was associated with improved survival in node-positive patients by categorical (1 lymph node versus >1 lymph node), but not continuous, multivariate analysis. This finding was interpreted to indicate a finite benefit to increasing the number of lymph nodes resected with patient outcome being dominated by patient age and tumor size. Machens et al. (94) reported a 10% rate of normalization of postoperative basal Ct levels in node-positive MTC patients. Metastases in 10 or more lymph

nodes, or involvement of more than two lymph node compartments nearly precludes normalization of serum Ct (119,216,217). Unfortunately, lymph node involvement is common and the incidence of lateral compartment lymph node metastases is related to the incidence of central compartment lymph node metastases. Machens et al. (218) reported that the rate of ipsilateral lateral compartment lymph node metastases when no central compartment lymph node metastases were present, 1–3 central lymph node metastases were present, or when  $\geq 4$  central lymph nodes were present was 10.1%, 77%, and 98%, respectively. The rate of contralateral lateral compartment lymph node metastases when no central compartment lymph node metastases were present, 1–9 central lymph node metastases were present, or when  $\geq 10$  central lymph nodes were present was 4.9%, 38%, and 77%, respectively. However, resection of local disease may decrease the risk of local recurrence (13,119,219), and clearance of the central compartment may prevent future complications such as invasion into the recurrent laryngeal nerve or aerodigestive track with resulting loss of speech or swallowing (12). For these reasons, most authors suggest that if metastatic lymph nodes are identified, then a compartment-oriented lymph node dissection should be done (12,81,94,220–224).

#### ■ RECOMMENDATION 62

MTC patients with suspected limited local metastatic disease to regional lymph nodes in the central compartment (with a normal US examination of the lateral neck compartments) in the setting of no distant (extracervical) metastases, or limited distant metastases should typically undergo a total thyroidectomy and level VI compartmental dissection. A minority of the Task Force favored prophylactic lateral neck dissection when lymph node metastases were present in the adjacent paratracheal central compartment. Grade: B Recommendation

#### ■ RECOMMENDATION 63

MTC patients with suspected limited local metastatic disease to regional lymph nodes in the central and lateral neck compartments (with US-visible lymph node metastases in the lateral neck compartments) in the setting of no distant metastases, or limited distant metastases should typically undergo a total thyroidectomy, central (level VI), and lateral neck (levels IIA, III, IV, V) dissection. Grade: B Recommendation

#### ■ RECOMMENDATION 64

In the presence of distant metastatic disease, less aggressive neck surgery may be appropriate to preserve speech, swallowing, and parathyroid function while maintaining locoregional disease control to prevent central neck morbidity. Grade: C Recommendation

[C6] *Surgery for MTC patients with advanced local disease or extensive distant metastases (Fig. 2).* In most patients, the surgical goal is thyroidectomy, level VI compartmental dissection, and therapeutic (clinical or image-positive) lateral neck dissection. However, in the presence of extensive distant metastases or advanced local features, the goals of surgical therapy are typically more palliative with attention to

minimizing complications, such as hypoparathyroidism, and maintaining normal speech and swallowing. These patients should additionally be considered for clinical trials, and other palliative therapies including surgery, external beam radiation therapy (EBRT), and hepatic embolization. In patients with infiltrative central neck disease that does not involve the trachea or esophagus, the extent of local surgery—especially with respect to unilateral resection of the recurrent laryngeal nerve when the tumor or associated nodal disease can not be completely separated from the nerve—remains controversial even among the expert panel. In patients with high volume extra-cervical metastatic disease, preservation of speech and swallowing is the major goal of therapies (to include surgery) directed at the neck. In patients with small volume extra-cervical metastatic disease, or disease confined to the neck, a more aggressive approach to locally invasive central compartment disease may be more appropriate to prevent local tumor recurrence; in some patients, resection of a unilateral recurrent laryngeal nerve and the use of adjuvant EBRT may be appropriate.

In patients with locally invasive MTC that involves the trachea, thyroid cartilage, and/or esophagus, the extent of extirpative surgery performed in the neck (palliative debulking, laryngectomy, esophagectomy, laryngopharyngectomy, or observation alone) is influenced by an assessment of the patient's life expectancy based on the extent of extra-cervical metastatic disease and other medical comorbidities. The desire for the short-term maintenance of speech and swallowing is balanced by the concern for long-term locoregional disease control and critical to this balance is the estimated duration of survival. These decisions may be best individualized by an experienced multidisciplinary treatment team.

#### ■ RECOMMENDATION 65

In the presence of advanced local or distant disease, less aggressive neck surgery may be appropriate to maintain local disease control while preserving speech, swallowing, and parathyroid function. Grade: C Recommendation

#### ■ RECOMMENDATION 66

In patients with extensive distant metastases a palliative neck operation may still be needed when there is pain, or evidence of tracheal compromise and the need to maintain a safe airway. Otherwise, in the setting of moderate to high volume extra-cervical disease, neck disease may be observed and surgery deferred (Task Force opinion was not unanimous). Grade: C Recommendation

[C7] *Thyrotropin suppression therapy in MTC.* Differentiated epithelial cell-derived thyroid cancers are thyrotropin (TSH)-dependent and suppression of TSH is desirable to arrest or retard the rate of cell growth (5). By contrast, C-cell tumors are not TSH-dependent and there is no evidence that thyroxine ( $T_4$ ) therapy aimed at TSH suppression reduces recurrences or improves survival of patients with MTC. Serum TSH should be measured 2–3 months postoperatively, and  $T_4$  dose adjusted to keep the TSH in the normal range.

#### ■ RECOMMENDATION 67

Replacement rather than suppressive  $T_4$  therapy with target serum TSH levels between 0.5 and 2.5 mIU/L is

recommended for patients with MTC. Grade: B Recommendation

[C8] *Somatic RET testing in sporadic MTC.* The presence of somatic RET mutations in sporadic MTC cells is about 40–50% (35–37), however, these tumors are heterogeneous and meticulous microdissection studies have shown somatic RET mutations in up to 80% of sporadic MTCs, most commonly 918ATG → ACG (225,226), and less frequently at codon 634 and others (37).

There are two main reasons to consider genotyping sporadic MTCs. First, is that tumor mutation status may predict its response to therapy. Many of the new small molecule therapeutics are designed to target RET, or its downstream pathways, thus theoretically patients whose MTCs contain somatic RET mutations, compared to those whose MTCs do not, might be more likely to respond to these compounds. So far, however, this hypothesis has not been proven in MTC. Moreover, because many of the tyrosine kinase inhibitors entering clinical trials at present inhibit multiple kinases, the precise mechanisms by which they may inhibit tumor growth and/or progression may not be predicted by RET mutations.

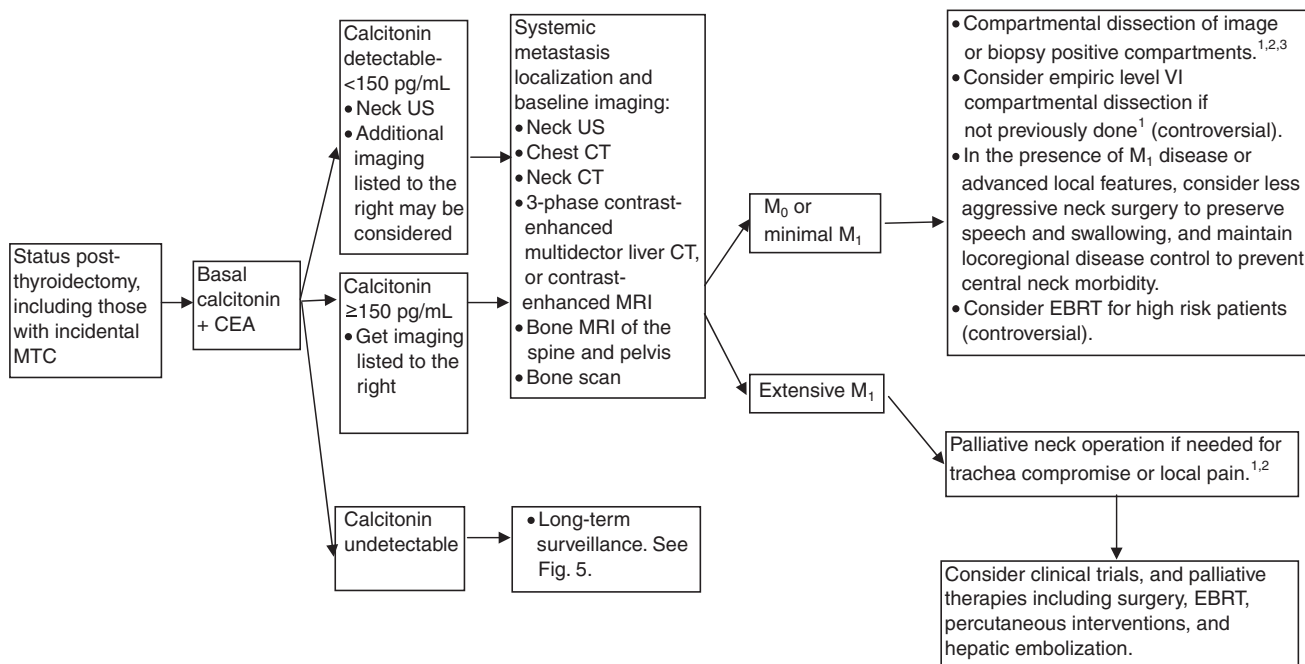
A second reason to consider analyzing sporadic MTCs for somatic RET mutations is that some studies have demonstrated that tumors with an identifiable RET mutation have a more aggressive course than those without RET mutations (36,37,227). However, others have not found this association (226). Recently, Elisei et al. (37) reported that the presence of a somatic RET mutation in sporadic MTC was associated with larger tumor size, the presence of nodal and distant metastases, and advanced stage at diagnosis. On multivariate analysis of all prognostic factors correlated with persistent disease or death, only advanced stage at diagnosis and the presence of a RET mutation showed an independent correlation. However, it is not clear how knowledge of the somatic RET mutational status would change patient management, or how this predictor of the clinical course compares to others such as the Ct or CEA DTs.

#### ■ RECOMMENDATION 68

Currently, sporadic MTC tumors should not be routinely evaluated for somatic RET mutations, although agreement amongst the Task Force was not unanimous. Grade: D Recommendation

### [D] Initial evaluation and treatment of postoperative patients

[D1] *Postoperative staging systems.* Postoperative staging is helpful in separating low-risk from high-risk patients with MTC. The updated (2002) American Joint Committee on Cancer (AJCC)/International Union Against Cancer (UICC) staging system has been applied to MTC by a number of investigators. The TNM system utilizes tumor size, extra-thyroidal invasion, nodal metastasis, and distant spread of the cancer (Table 4). However, the TNM classification lacks important prognostic factors such as gradations of age, the postoperative Ct level, or the postoperative Ct and CEA DTs. Indeed, Barbet et al. (228) reported that only the Ct DT remained an independent predictor of survival by multivariate analysis.



<sup>1</sup>Parathyroid glands resected or devascularized should be autografted in the neck in *RET*-negative, MEN 2B, and FMTC patients, while MEN 2A glands should be autografted to a heterotopic site.

<sup>2</sup>Consider external beam radiation of  $T_4$  disease to prevent recurrent local disease.

<sup>3</sup>Observation of nonthreatening locoregional disease  $<1\text{ cm}$  may be considered.

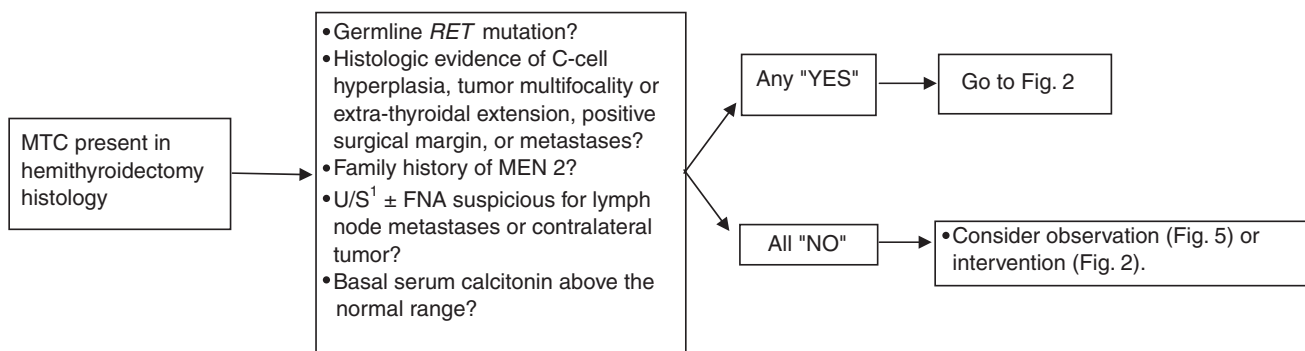
FIG. 3. Initial evaluation and treatment of postoperative patients.

#### RECOMMENDATION 69

Postoperatively, the TNM classification (Table 4) and other factors, such as the postoperative Ct level and the Ct and CEA DTs, should be used to predict outcome and to help plan long-term follow-up of patients with MTC (Figs. 3 and 5). Grade: C Recommendation

[D2] Completion thyroidectomy and lymph node dissection after hemithyroidectomy (Fig. 4). Occasionally, a patient undergoes a hemithyroidectomy and the diagnosis of MTC is made postoperatively. Patients with (or at risk) of residual metastatic or contralateral MTC are likely to benefit from

completion thyroidectomy, including (bilateral) central compartment lymph node dissection. The incidence of multifocal MTC in heritable MEN 2 is about 75% (116–119), while in sporadic MTC the incidence is 0–22% (116,119–121). Additional patients likely to benefit from further surgery would include those treated with a hemithyroidectomy who have an elevated postoperative basal serum Ct value. However, the ideal postoperative Ct cut-off value is unknown. Pelizzo et al. (12) advocated for completion thyroidectomy and lymphadenectomy, the outcome of this procedure in their patients was not reported. Using the Advantage system (Nichols Institute



<sup>1</sup>Neck US to include the superior mediastinum and central and lateral neck compartments.

FIG. 4. Management of MTC after hemithyroidectomy.

Diagnostics), Basuyau et al. (144) found the 95th percentile of adult serum Ct to be 5.2 and 11.7 ng/L in women and men, respectively (144). In the setting of a hemithyroidectomy, one may expect the normal range in women and men to be approximately half of these values. For simplicity, the upper normal value of the reference range may be a reasonable cut-off value. Patients with a post-hemithyroidectomy serum Ct levels above this cut-off should likely be evaluated and treated according to Fig. 2. However, there is an absence of data on which to base these conclusions, and the decision to follow a patient with sporadic MTC after hemithyroidectomy without central lymph node dissection should be made on an individual basis weighing the potential risks and benefits of additional surgery. During follow-up, a rise in the basal serum Ct should prompt additional imaging (Fig. 5).

#### ■ RECOMMENDATION 70

Patients with MTC diagnosed after hemithyroidectomy (including those with microscopic MTC) should undergo RET oncogene testing, measurement of serum Ct, and neck US. Grade: A Recommendation

#### ■ RECOMMENDATION 71

Additional testing and therapy (to likely include completion thyroidectomy and central lymph node dissection) should be offered if histology shows multicentric tumor, CCH, extra-thyroidal extension, or positive surgical margin; when neck US is suspicious for persistent local disease in the contralateral thyroid lobe, or central or lateral neck compartments; when RET mutation is positive; or when family history is positive for MEN 2. See Fig. 2. Grade: B Recommendation

#### ■ RECOMMENDATION 72

Patients treated with hemithyroidectomy who demonstrate unifocal intrathyroidal sporadic MTC confined to the thyroid who have no CCH, negative surgical margin, and no suspicion for persistent disease on neck US may be considered for additional surgery or follow-up without additional surgery if the basal serum Ct is below the upper normal of the reference range more than 2 months after surgery (Fig. 5). Those with a basal serum Ct above the normal reference range should undergo additional testing and therapy (to often include completion thyroidectomy and central lymph node dissection) per Fig. 2. Grade: B Recommendation

[D3] *Laboratory testing after resection of MTC (Fig. 3).* Measurements of the serum markers Ct and CEA are important in the follow-up of patients with MTC, and reliably reflect the presence and volume of disease in the vast majority of patients (229). These tumor markers typically require several months after surgery to achieve their nadir, although even longer time frames have been reported (229,230).

#### ■ RECOMMENDATION 73

MTC serum tumor markers (Ct and CEA) should be measured 2–3 months postoperatively. Grade: B Recommendation

[D4] *Testing and treatment of patients with undetectable postoperative basal serum Ct (Fig. 5).* Serum Ct is a sensitive marker of residual MTC. In a study of 214 athyreotic patients following thyroidectomy for differentiated thyroid carcinoma, the Ct concentrations were below the detection limit in all patients (231). In addition to basal serum Ct, a pentagastrin (or calcium when pentagastrin is not available) stimulated\* Ct level may be obtained (232). When both the basal and the stimulated serum Ct are undetectable the patient is in complete biochemical remission and has about a 3% chance of biochemical recurrent disease during follow-up (213). Modigliani et al. (40) reported that biochemical cure (using a less stringent definition) was predicted solely by disease stage, rather than type of surgery, and predicted a survival rate of 97.7% at 10 years.

Pentagastrin is not available in the United States and calcium stimulation testing is widely held to be inferior. The role of stimulation testing has diminished in recent years in the absence of pentagastrin and the improved sensitivity of basal serum Ct. Currently, when only the stimulated Ct level is detectable, the volume of residual disease is very low, unlikely to be found by imaging, and unlikely to be resolved with additional therapy.

#### ■ RECOMMENDATION 74

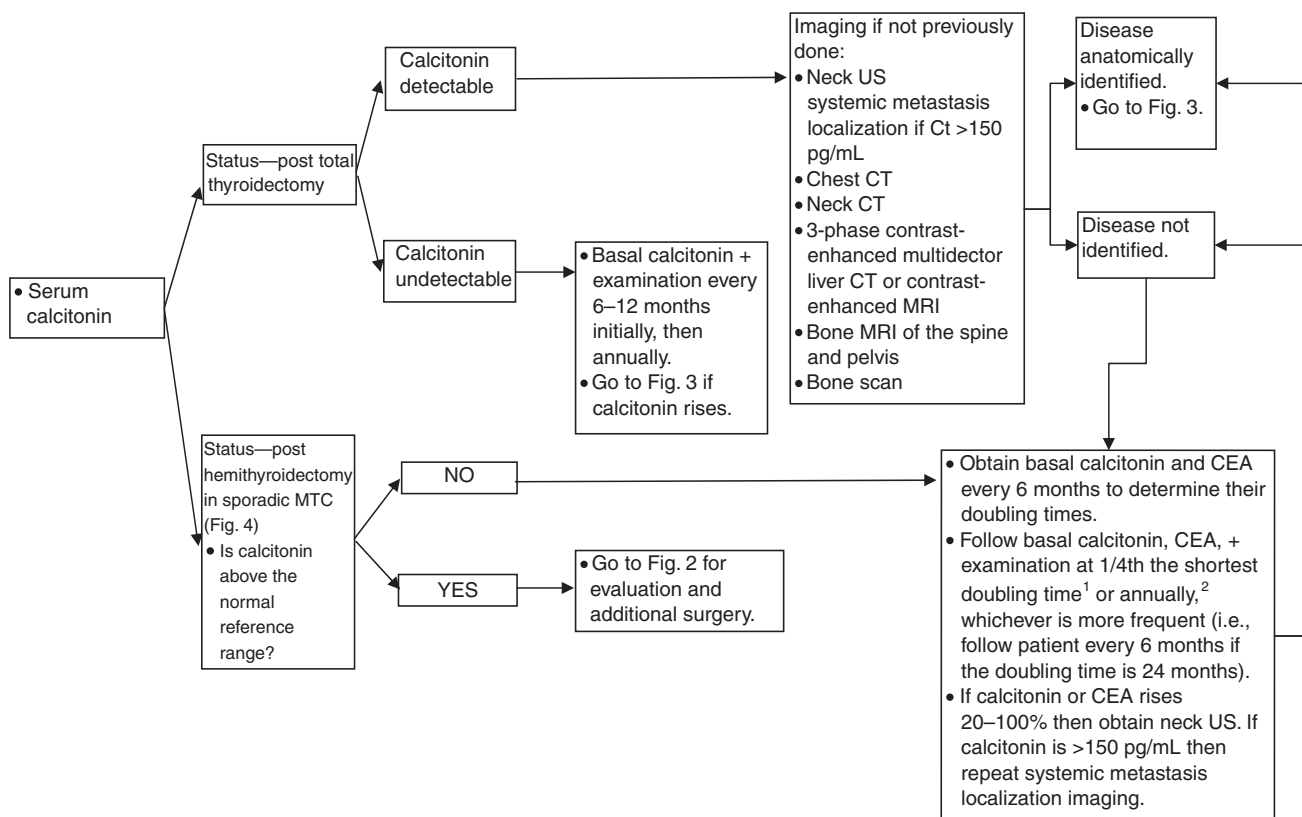
When the postoperative basal serum Ct is undetectable (along with an undetectable stimulated serum Ct if performed, although the majority of the Task Force felt it was unnecessary), the risk of persistent or recurrent residual disease is low, and other tests or imaging techniques are not immediately required and the patient may enter into long-term follow-up. A neck US may be considered to establish a baseline. Grade: E Recommendation

[D5] *Testing and treatment of patients with a detectable, but modestly elevated postoperative basal serum Ct (Fig. 3).* Modest Ct levels after surgery are considered detectable, yet <150 pg/mL. These levels may be associated with only locoregional disease. Distant metastases are also possible (212), but when associated with modest serum Ct levels they are usually of small size or in limited number, and are difficult to detect (210,233). An example of the average relationship between tumor volume and serum Ct concentration is the report by Wells and colleagues (79) that 1 cm<sup>3</sup> of MTC primary tumor was associated with a serum Ct level of approximately 1000 pg/mL (79). However, there are rare patients with poorly differentiated MTC that is associated with limited Ct levels despite large tumor deposits. They may be suspected based on their disproportionately high CEA levels and rapid CEA DTs, although even more rare MTC patients are described that lack elevation of both serum Ct and CEA (234).

Localization of disease should start with careful examination by neck US (235). If suspicious lymph nodes are detected, FNA should typically be performed to confirm the diagnosis. Recently, several studies have suggested that measurement of Ct in the FNA washout fluid from suspected local recurrences and lymph node metastases may have higher sensitivity and specificity (203).

\*See footnote, page 574.





<sup>1</sup>Doubling time may be estimated or optimally calculated by fitting data to single exponentials by nonlinear least-square analysis (calculator available at [www.thyroid.org](http://www.thyroid.org)).

<sup>2</sup>Patients with *RET* mutations associated with PHEO or primary hyperparathyroidism should be screen annually beginning at age 8 years in MEN 2B and mutated *RET* codons 634 and 630, and from age 20 years in carriers of other MEN 2A *RET* mutations, while those associated only with FMTC should be screened at least periodically.

FIG. 5. Long-Term surveillance.

Other optional imaging techniques include neck and chest CT, liver three-phase contrast-enhanced CT or contrast-enhanced MRI, liver US, bone scintigraphy, bone MRI of the spine and pelvis, <sup>18</sup>F-dihydroxyphenylalanine (DOPA) PET, and FDG-PET (206,207,209,233,236–241). The sensitivity of these tests range between 50% and 80% in localizing the disease, but is likely to be significantly lower in the setting of modest serum Ct values (233,240,241). Anti-CEA antibodies have been used for imaging and therapy (207,242), while scintigraphy with several tracers—such as somatostatin analogs (243–247), metaiodobenzylguanidine (MIBG), dimercaptosuccinic acid (DMSA), and gastrin—are usually less sensitive (233,248,249), and have also been used for therapy (250,251).

#### ■ RECOMMENDATION 75

Postoperative MTC patients with detectable serum Ct levels <150 pg/mL should be evaluated with neck US. Grade: B Recommendation

#### ■ RECOMMENDATION 76

In addition to neck US, postoperative MTC patients with detectable serum Ct levels that are <150 pg/mL may be considered for additional imaging to serve as baseline ex-

aminations for future comparison even though these studies are usually negative. Alternatively, this additional imaging can be deferred and subsequently implemented should the serum Ct rise over time. Grade: C Recommendation

Regarding treatment, the surgical principles outlined for initial surgical therapy largely apply. Whenever the residual or recurrent disease has been localized in the neck, there is the opportunity for a second surgical procedure. Several series have reported experience with repeat neck surgery for MTC (252–257); however, there have been no randomized trials whereby patients have been staged and randomized to treatment versus observation alone cohorts. In most of the series, about one third of patients have their basal or stimulated plasma Ct levels in the “normal range” after re-operation, while the number achieving an undetectable serum Ct level using a sensitive assay is less clear. Long-term outcomes in these patients have been fairly good, with excellent prevention of recurrence in the central neck, and durable reductions in Ct levels reported by some groups. Perhaps the most encouraging results were reported by Fialkowski et al. (258) from a series of 148 patients who had re-operations for recurrent or residual

MTC. Compartmental "microdissection" was performed on all patients, as described by Tissel et al. (255). Four patients died of their disease while 50 patients were alive with 8–10 year follow-up data available; 23 of 50 patients (46%) had basal Ct levels greater than or equal to their basal Ct levels prior to reoperation. Thirteen of 50 (26%) had basal Ct levels at least 30% lower than their basal preoperative levels, and 14 of the 50 (28%) had basal Ct levels of <10 pg/mL. Overall, 6 of 54 patients (11%) had an undetectable basal serum Ct level at their last follow-up evaluation. A total of 25 of the 54 (46%) patients had a basal serum Ct level <100 pg/mL at their last evaluation and none had any radiologic evidence of recurrence. Kebebew et al. (253) reported on 33 MTC patients who underwent 46 reoperations for locoregional residual MTC, and only two (6%) had postoperative undetectable basal Ct levels. These two patients had relatively low preoperative basal Ct levels of only 53 ng/L and 322 ng/L, and only three of their resected lymph nodes demonstrated metastases. On balance, re-operation with curative intent has a place in the management of patients with persistent or recurrent MTC localized to the neck which may prevent clinical or radiographic tumor recurrence; however, the majority of these patients will not become biochemically free of disease.

#### ■ RECOMMENDATION 77

Surgical resection of locoregional recurrent or persistent MTC in patients without distant metastases or with minimal distant metastases should include compartmental dissection of image or biopsy positive disease in the central (level VI) or lateral (levels IIA, III, IV, V) neck compartments. Removal of only grossly metastatic lymph nodes, or other limited procedures, should be avoided in the absence of extensive prior surgery in that compartment. Grade: B Recommendation

When there is no anatomic evidence of disease, despite detectable serum Ct, the best option is observation (259). Empiric surgical procedures aimed to remove all the lymph nodes of the neck and the mediastinum have been proposed, but the results have largely been disappointing. These procedures may yield no tumor resection and are unlikely to provide a biochemical remission (80).

#### ■ RECOMMENDATION 78

In the absence of residual anatomically identifiable disease (neck US and CT) in a thyroidectomized patient with a measurable Ct level who has not previously undergone a level VI compartmental dissection, an empiric central compartment dissection may be considered but remains controversial. Grade: C Recommendation

In case of distant metastases (M1), observation or palliative therapy (including surgery) may be considered. It is important to remember that these patients are incurable, and the risks and benefits of any procedure should be carefully considered. Considerations typically include the location of the lesion(s), their risk for harm, and their rate of growth (if known). These issues are further addressed below under the heading Management of persistent or recurrent MTC.

[D6] Testing and treatment of patients with a significantly elevated postoperative basal serum Ct (Fig. 3). Significantly

elevated Ct levels after surgery are defined as >150 pg/mL. The higher the Ct level, the greater the chance that the patient has demonstrable distant metastases (212). The evaluation of these patients is similar to when the basal postoperative Ct is detectable but limited (<150 pg/mL); however, a search for distant metastases is now emphasized (Fig. 3). Machens et al. (94) reported that distant metastases began appearing at preoperative basal serum Ct levels of 150 pg/mL in patients undergoing re-operation. The cumulative risks of identifiable distant metastases exceeded 50% at preoperative basal serum Ct levels of 5000 pg/mL in the re-operative setting. In the re-operative setting, distant metastases were almost always found when the preoperative basal serum Ct level exceeded 20,000 pg/mL. Similarly, Giraudet et al. (212) reported that in patients with one, or two to four sites of distant metastases the median Ct values were 1510 pg/mL (21–6000 pg/mL) and 18,450 pg/mL (276–247,000 pg/mL), respectively (212).

#### ■ RECOMMENDATION 79

In addition to neck US, postoperative MTC patients with serum Ct levels  $\geq 150$  pg/mL should undergo additional imaging techniques to evaluate for distant metastases (see Fig. 3). Grade: Recommendation B

The concepts regarding therapy for postoperative MTC patients with serum Ct levels  $\geq 150$  pg/mL are similar to those outline for initial therapy (Fig. 2) (260). However, these patients typically require consideration of locoregional disease control and may require palliation of distant metastases that ideally would benefit from an effective systemic therapy. Unfortunately, while several chemotherapeutic protocols have been proposed, all of them have limited value, with remission (usually partial) reported in no more than 30% of the cases, and usually short lasting. Stabilization of the disease has been reported in several series, but due to the slow evolution of the disease, it is difficult to definitively attribute the stabilization to the therapy rather than to the natural history of the disease alone. In many MTC patients with metastatic disease, the locoregional disease is small (<1 cm) and nonthreatening, and distant metastases are asymptomatic and stable. For these patients, immediate intervention is of unknown benefit and they may be observed. Current highly sensitive neck imaging is increasingly identifying small lymph node metastases that can be challenging for the surgeon to find and remove in their entirety, especially from neck compartments that have previously been operated. Many surgeons have arbitrarily considered 1 cm as a clinically appropriate size for lymph node metastases to consider re-operation. Percutaneous ethanol injection of locoregional MTC has been utilized (261) and may be a useful tool for locoregional disease control, although it is unclear exactly where and when it is best utilized. Rapid progress in drug development may allow more meaningful systemic therapy for MTC patients in the future should they demonstrate progressive disease. Treatment with somatostatin analogs or interferon has shown no convincing evidence of tumor stabilization or regression (262).

#### ■ RECOMMENDATION 80

In postoperative MTC patients with serum Ct levels  $\geq 150$  pg/mL with small (<1 cm) locoregional lymph node metastases that are nonthreatening, and with no evidence of distant metastases, immediate intervention is of un-

known benefit and such lymph nodes may be observed or undergo re-operative compartmental dissection of image or biopsy-positive compartments. Grade: C Recommendation

#### ■ RECOMMENDATION 81

In postoperative MTC patients with serum Ct levels  $\geq 150$  pg/mL with small ( $<1$  cm) locoregional metastatic disease that is asymptomatic and nonthreatening, and with distant metastases, immediate intervention towards the locoregional disease is of unknown benefit and such lymph nodes may be observed. Grade: C Recommendation

#### ■ RECOMMENDATION 82

Postoperative MTC patients with serum Ct levels  $\geq 150$  pg/mL with symptomatic and/or progressive locoregional disease  $>1$  cm should be considered for locoregional therapy (e.g., surgery), while those with symptomatic distant metastases should be considered for clinical trials and palliative therapies such as surgery, EBRT, percutaneous interventions, and hepatic embolization. Grade: B Recommendation

#### ■ RECOMMENDATION 83

The routine use of cytotoxic chemotherapy should be discouraged in patients with MTC. It may be considered for selected patients with rapidly progressive disease not amenable to clinical trials or other palliative therapies discussed below under **Management of persistent or recurrent metastatic MTC**. Grade: E Recommendation

#### ■ RECOMMENDATION 84

Somatostatin analogs are ineffective to control tumor growth and typically should not be considered for this purpose. Grade: F Recommendation

[D7] *Role of postoperative radioiodine ablation.* In the past a few reports suggested that metastatic MTC could be identified by radioactive iodine (RAI) scanning and, therefore, could be treated by RAI. However, it seems likely that metastatic differentiated epithelial cell-derived thyroid carcinoma may have been erroneously diagnosed as MTC. Others considered the possibility that RAI uptake into nearby follicular cells may provide therapy to adjacent MTC via a “bystander effect” (263,264). However, recent studies do not confirm that RAI treatment plays a role in the postoperative management of patients with MTC, either as remnant ablation or treatment of residual, recurrent, or metastatic disease (248).

#### ■ RECOMMENDATION 85

Postoperative radioactive iodine is not recommended for patients with MTC in the absence of concomitant epithelial cell-derived differentiated thyroid cancer. Grade: E Recommendation

[D8] *Role of empiric liver or lung biopsy, hepatic vein sampling, systemic vascular sampling, or hepatic angiography.* Sampling procedures have most commonly been considered for one of two reasons. One reason is that a suspicious anatomic lesion

was identified and positive sampling of the lesion would alter therapy towards it. Empiric sampling or empiric biopsies were also used to exclude distant occult metastases before embarking on extensive locoregional surgery with curative intent. Previously, routine direct liver examination by laparoscopy was found to be helpful in staging patients with elevated Ct levels, and no anatomic evidence of MTC metastases by routine imaging. Diagnostic laparoscopy enabled the surgeon to examine the surface of the liver with magnification, and small liver metastases were detected in 25% of these patients (265). Re-operation with “microdissection” in these patients was avoided in these Ct-positive patients who typically had previously undergone thyroidectomy without node dissection (266). Now, however, most patients have a lymph node dissection done as part of their primary operation, so the opportunity to apply this method is less frequent. In addition, it is recognized that many of these patients undergoing re-operation are still not biochemically rendered free of disease despite their negative liver evaluations, so that enthusiasm for re-operation in the absence of anatomically identified neck disease is diminished and the goals of therapy have shifted to more palliative rather than curative approaches. Further, radiological evaluation of the neck has become much more sensitive (especially US). Thus, patients with elevated serum Ct levels and negative imaging may be observed. Recent natural history studies indicate that such patients have a good prognosis (39,62,118,214,228,267). This approach can likely be extended to similar patients with small ( $<1$  cm) locoregional metastases, especially if the Ct and CEA DTs are  $>2$  years (62,212,228,268,269) (see section below on *Management of persistent or recurrent metastatic MTC*).

Concomitantly, enthusiasm for hepatic vein sampling (270) and hepatic angiography (271) have also diminished. These methods have been used to identify otherwise occult hepatic metastases, and improve preoperative staging in patients considering re-operation (270). Similarly, systemic vascular Ct sampling searching for Ct gradients from the neck or lungs have attempted to localize residual disease (272–274). However, biological cure was obtained in only a small percentage, if any, of these operated patients (272). Furthermore, recurrence rate and death rate were not significantly lower than those observed in patients treated by surgery without venous sampling (252–257,259,273).

#### ■ RECOMMENDATION 86

We do not recommend the routine use empiric liver or lung biopsies, hepatic vein sampling, systemic vascular sampling, or hepatic angiography prior to re-operation. These diagnostic procedures should be used sparingly, if at all. Grade: D Recommendation

#### [E] *Management of persistent or recurrent MTC*

[E1] *Goal of management of patients with metastatic MTC: choosing when metastases require treatment.* All patients with a history of cancer, especially one that is incurable and progressive, benefit from good psychological support. The ideal goal for all cancer patients would be to be free of disease without morbidity. Unfortunately, that is currently unlikely in patients with metastatic MTC because multifocal, and often multi-organ, metastases frequently develop early in the course of the disease. More realistic aims of current therapy are

palliative and strategically prophylactic. The goals of managing patients with persistent or recurrent metastatic disease are to provide locoregional disease control; palliate the symptoms of hormonal excess (such as diarrhea or Cushing's syndrome); palliate symptomatic distant metastases (such as pain); and control distant metastases that threaten to cause harm (such as impending bronchial obstruction, fracture, or spinal cord compression). The availability of new therapeutic compounds may change the management of metastatic disease in the future.

Metastases are often discovered at an early stage because detectable Ct levels lead to a compulsive search for them. When distant metastases are discovered, the initial decision is to choose which lesions require therapy. This decision must balance the usual slow rate of progressive disease and the prolonged life expectancy with good quality of life that many patients enjoy against the limited efficacy and potential toxicities of available local and systemic therapies.

#### ■ RECOMMENDATION 87

Active treatment is most often indicated in patients with lesions in critical locations such as brain metastases, impending or active central nervous system compression, airway compromise, symptomatic lesions, hormonal secretion, and impending or active fracture of a weight bearing bone. Grade: A Recommendation

[E2] *Management of patients with metastatic MTC: determining tumor burden and rate of progression using sequential imaging and tumor marker DTs.* Patients requiring active treatment typically include those with either a large tumor burden and/or a rapid rate of progression. Tumor burden is estimated from a complete imaging work-up (Fig. 5) (206,211,241). The progression rate can be assessed using response evaluation criteria in solid tumors (RECIST) on sequential imaging examinations or using a surrogate marker, such as Ct DT and CEA DT that are closely related to the progression rate (62,212,228,268,269). The use of tumor marker results from multiple time points helps eliminate the impact of short-term tumor marker fluctuation often seen when comparing results to only the prior values. Barbet et al. (228) studied MTC patients with abnormal Ct levels after total thyroidectomy and bilateral lymph node dissection. When the Ct DT was less than 6 months, the 5- and 10-year survivals were 25% and 8%, respectively; when 6–24 months, the 5- and 10-year survivals were 92% and 37%, whereas all patients with Ct DT greater than 2 years were alive at the end of the study. TNM stage, European Organization for Research and Treatment of Cancer score, and Ct DT were significant predictors of survival by univariate analysis, but only the Ct DT remained an independent predictor of survival by multivariate analysis. Ct DT was a better predictor than CEA DT, and Ct DT calculated using only the first four measurements was also an independent predictor of survival. Giraudet et al. (212) reported that the Ct DT and CEA DT were strongly correlated in 80% of patients, such that when they were both  $\leq 24$  or  $> 24$  months then progressive disease at 1 year was seen in 94% and 14% of cases, respectively. However, when the DTs were discordant, if only Ct DT or CEA DT was  $\leq 24$  months then progressive disease at 1 year was seen in 40% and 75% of cases, respectively, and thus determination of both DTs was recommended (212). To calculate the tumor marker DT, single exponentials

are fitted to the tumor marker concentration by nonlinear least square regression. Reliable estimates are obtained using a minimum of four data points obtained over a minimum of 2 years for most patients; however, the DT of patients with DT  $< 6$  months can be reliably estimated within the first 12 months (228). To assist with these computations a tumor marker DT calculator is available on the ATA website (<http://www.thyroid.org>).

#### ■ RECOMMENDATION 88

Asymptomatic patients with small volume metastatic disease that is stable to slowly progressive as determined by anatomic imaging, or Ct and CEA DT  $> 2$  years, typically do not require systemic therapy, and the decision to initiate such treatment should be made with the patient only after a thorough discussion. Grade: E Recommendation

#### ■ RECOMMENDATION 89

Patients with rapidly progressive disease by anatomic imaging or biochemical DT  $< 2$  years should be considered for treatment, ideally in the context of a well-designed clinical trial. Grade: B Recommendation

[E3] *Management of Ct-positive, but imaging-negative patients.* Patients with detectable serum Ct levels should be imaged to detect persistent or recurrent disease as previously described (Fig. 3). In those without anatomically identified disease, long-term surveillance is indicated. The optimal timing of this follow-up has not been determined, but because the Ct and CEA DTs are predictive of tumor progression (212,228) it follows that they may be useful to determine the interval of follow-up (Fig. 5).

#### ■ RECOMMENDATION 90

Patients with detectable basal serum Ct levels postoperatively with negative imaging should have the basal Ct and CEA levels obtained approximately every 6 months initially to determine the DTs. Ongoing follow-up of these tumor markers and physical examination should occur at one fourth the shortest DT or annually, whichever is more frequent (i.e., follow the patient every 6 months if the shortest DT is 24 months). Grade: B Recommendation

#### ■ RECOMMENDATION 91

In patients with detectable basal serum Ct levels postoperatively with negative imaging, if the Ct or CEA rises substantially since the previous anatomic imaging evaluation, then a neck US should be performed. The Ct elevation required to trigger this action typically depends on the basal serum Ct and the clinical situation, but elevation by more than 20% to 100% may prompt this evaluation. If the serum Ct is  $> 150$  pg/mL then systemic imaging should be repeated as well (Fig. 5). Grade: C Recommendation

[E4] *Adjunctive external beam irradiation to the neck.* The benefits of EBRT are poorly evaluated and only retrospective series are available (275–281). Normalization of serum Ct after EBRT is unlikely (278). Currently, the role of EBRT in MTC is controversial; however, some evidence suggests that EBRT may improve locoregional disease control in high risk

patients, although an improvement in overall survival has not been established (275,278). The morbidity of EBRT is typically greater in the elderly.

In a patient with macroscopic residual tumor in the neck after incomplete surgery, Schlumberger and colleagues (281) advocated EBRT for local disease control. Brierley et al. (279) reported in a series of MTC patients that the local/regional relapse free rate between patients that received EBRT and those that did not was no different; however, in high risk patients (microscopic residual disease, extraglandular invasion, or lymph node involvement), the local/regional relapse-free rate was 86% at 10 years with postoperative EBRT, and 52% for those with no postoperative EBRT ( $p = 0.049$ ). Similarly, Chow et al. (276) reported that in seven patients with lymph node metastasis, EBRT gave 100% (4/4) 10-year locoregional control compared with 33.3% (1/3) in those without EBRT.

After resection of extensive disease the use of EBRT is controversial in patients in whom surgery was macroscopically complete but who have persistently high Ct level in the absence of detectable distant metastases (278,281). The clinical dilemma is whether the residual disease is locoregional, distant, or both. In these patients, the benefits of EBRT to limit locoregional tumor recurrence may be counterbalanced by the fact that its morbidity may not be necessary, or that it may hamper any surgical procedure in case of clinical recurrence. Schlumberger and colleagues (281) studied 207 patients with MTC, 98 of who received EBRT. In 97 patients without distant metastases, EBRT was associated with decreased relapse in the neck only in patients with elevated postoperative serum Ct levels, even if surgery was macroscopically complete.

#### ■ RECOMMENDATION 92

EBRT should not be used as a substitute for surgery in patients in whom neck tumor foci can be resected without excessive morbidity. Grade: E Recommendation

#### ■ RECOMMENDATION 93

Postoperative EBRT to the neck and mediastinum may be indicated in patients who undergo a gross incomplete resection (R2 resection). Prior to initiating EBRT, physicians should ensure that optimal surgery has been performed as re-operation (other than major ablative procedures) is much more difficult, and may not be safely or technically possible, after EBRT. Grade: B Recommendation

#### ■ RECOMMENDATION 94

Postoperative adjuvant EBRT to the neck and mediastinum may be considered in patients who are found to have microscopic positive margin(s) (R1 resection) following surgery for moderate to high volume disease involving the central compartment (level VI) and one or both lateral neck compartments (levels 2A–V). EBRT may also be considered in those who appear to have undergone a margin-negative (R0) operation in the setting of moderate to high volume disease with extra-nodal soft tissue extension of tumor when the post-operative serum Ct remains detectable in the absence of distant metastases. Physicians should be sure that optimal surgery has been performed before proceeding with EBRT. (Task Force opinion was not unanimous as some questioned the benefits of EBRT in these settings) Grade: C Recommendation

#### ■ RECOMMENDATION 95

Postoperative adjuvant EBRT to the neck should not be performed in an effort to treat a persistent elevation in serum level of Ct in the absence of a gross or microscopic positive margin or moderate to high volume neck disease with extra-nodal soft tissue extension. Grade: E Recommendation

[E5] *Brain metastases.* Clinically apparent brain metastases from MTC are uncommon, but are probably more prevalent than has been reported due to the lack of routine CNS imaging. The possibility of brain metastases is most often considered in patients with residual or recurrent MTC and suspicious symptoms, in the setting of extensive distant metastases, and before initiation of systemic therapy (especially in the setting of a clinical trial). No randomized clinical trials exist on which to base treatment recommendations (282–284).

#### ■ RECOMMENDATION 96

Patients with isolated or limited brain metastases should be considered for surgical resection. EBRT (including stereotactic radiosurgery) may be indicated for brain metastases not amenable to surgery. Grade: C Recommendation

[E6] *Bone metastases.* Bone metastases may be found on anatomic or functional tumor imaging. Unfortunately, some patients present with painful bone lesions, fracture, or spinal cord compression.

#### ■ RECOMMENDATION 97

Patients with spinal cord compression require urgent glucocorticoid therapy, surgical evaluation, and subsequent radiation oncology consultation. Grade: C Recommendation

#### ■ RECOMMENDATION 98

Surgery is indicated in weight-bearing bone metastases with fracture or impending fracture. Grade: C Recommendation

#### ■ RECOMMENDATION 99

EBRT should be considered to treat painful bone metastases and is indicated for clinically significant lesions that are not candidates for surgery, especially if they demonstrate disease progression or may threaten adjacent structures if they progress. Grade: C Recommendation

#### ■ RECOMMENDATION 100

EBRT is indicated postoperatively for bone metastases that are incompletely resected. Grade: C Recommendation

Experience with osseous metastases from tumors other than MTC have demonstrated that percutaneous methods such as vertebroplasty (percutaneous osteoplasty/cementation) (285), radiofrequency ablation (286–289) ± cementation (290–292), cryosurgery (287,293), and arterial embolization (294–296) ± follow-up surgery (297), cementation (298), or EBRT (299) have been associated with pain reduction.

#### ■ RECOMMENDATION 101

Minimally invasive percutaneous methodologies (alone or in combination) should be considered to treat painful bone

metastases, especially those that have failed or are not candidates for surgery or EBRT. Grade: C Recommendation

Asymptomatic isolated bone metastases may be surgically resected, but it is extremely uncommon for these patients to be rendered free of disease.

#### ■ RECOMMENDATION 102

Small bone metastases that are asymptomatic and are not an immediate threat may be followed. Grade: C Recommendation

Intravenous bisphosphonates have been prescribed for painful bony metastases from other primary malignancies with some success. The use of bisphosphonates to prevent progression of existing osseous metastases has been well-studied in both hematological and solid malignancies, but there is no substantial published experience in MTC (300).

#### ■ RECOMMENDATION 103

Recommend neither for nor against the use of bisphosphonates in the setting of MTC with osseous metastases. Grade: I Recommendation

[E7] *Lung and mediastinal metastases.* Uncommonly, dominant mediastinal lesions may be considered for surgical resection. More often, lung and mediastinal lesions are left untreated or considered for clinical trials if the lesions are progressive. Lung or mediastinal lesions causing local compression of an airway or bleeding may be considered for surgery, EBRT, or radiofrequency ablation. Lesions with central airway invasion may be amenable to the addition of photodynamic therapy or airway stenting.

#### ■ RECOMMENDATION 104

Lung or mediastinal lesions that are progressive should be considered for clinical trials, or focal therapy. Grade: C Recommendation

[E8] *Hepatic metastases.* The liver is a major site of MTC metastases. When liver metastases are large or progressive or are associated with symptoms such as diarrhea or pain, there is a need for treatment. Single or limited large metastases requiring therapy should be surgically resected if possible. However, liver metastases are usually multiple and disseminated throughout the liver, and are usually not amenable to surgery, percutaneous ethanol ablation (261), or radiofrequency ablation (301,302), and may be best treated with chemoembolization (261,303,304) or systemic therapy (preferably within a clinical trial).

Chemoembolization has been reported to be effective in anecdotal MTC patients; in 11 patients, symptomatic improvement was observed in all, with transient remission or stabilization in 60% (303); in 12 MTC patients, 42% had partial responses and 42% had stabilization, while diarrhea improved in 40% (304). The extent of liver involvement was the main factor that influenced the results: partial responses being observed only in patients with liver involvement <30% and when metastases were <30 mm. Following a single cycle, the duration of partial responses and stabilizations was longer than 1

year. When disease progression occurred, additional therapy offered the opportunity for another partial tumor response, but of shorter duration. Despite these favorable responses, chemoembolization did not allow for subsequent curative surgery, which is typically not possible given the frequently diffuse nature of these metastases. It is important that patients have adequate liver and renal function prior to treatment. Toxicity was mild and transient, but care must be taken to exclude the presence of a PHEO, since one death was reported in a patient with an occult PHEO who was treated by this technique (303).

#### ■ RECOMMENDATION 105

Liver metastases that are progressive, large, or associated with symptoms such as diarrhea or pain, should be considered for active treatment. The method of treatment often depends on whether the lesions requiring therapy are limited or multiple and disseminated. Grade: B Recommendation

[E9] *Palliative surgery.* Surgery offers effective palliative treatment for metastatic disease in several situations. First, MTC neck metastases are frequently painful, resistant to medical treatment, and their resection may offer significant pain relief. Second, mechanical effects of bulky metastases such as acute spinal cord compression, or airway and esophageal obstruction (with coughing, dyspnea, and difficulty swallowing) can be improved by palliative resection of tumor in these areas (266). Third, the diarrheal syndrome caused by large MTC tumor burden can be alleviated by surgical tumor debulking (305,306). Another method to reduce the volume of liver metastases for palliation of diarrhea and pain is chemoembolization (303,304).

#### ■ RECOMMENDATION 106

Palliative therapy, including surgery, should be considered for symptomatic lesions causing pain, mechanical compression, or hormonal secretion. Grade: C Recommendation

[E10] *Chemotherapy and clinical trials.* Clinical trials of chemotherapeutic regimens in patients with persistent or recurrent MTC have shown limited efficacy, with best responses of partial remission generally in the range of 10–20%, and these responses are short lived. The agents yielding the best results have been dacarbazine, fluorouracil, and doxorubicin (307–313).

“Complementary” or “alternative” therapies can include a myriad of “nontraditional” approaches to promote a good attitude and healthy spirit; acupuncture and reflexology; herbs and vitamins; fasting, juicing, and other dietary practices; and nontraditional pharmacologic and biological therapies (314). Some cancer patients find that therapies can relieve some symptoms or side effects, ease pain, and enhance their lives during treatment. Unfortunately, there are no data that they enhance disease-specific survival or disease-free survival.

#### ■ RECOMMENDATION 107

The use of standard chemotherapeutic agents should not be considered as first-line therapy for patients with persistent or recurrent MTC given the low response rates and the advent of promising new compounds entering clinical trials and other available treatment options. Grade: D Recommendation

The experience with radio-labeled molecules delivering high radiation dose is limited, but only modest responses have been reported. Iten et al. (251) studied [<sup>90</sup>Yttrium-DOTA]-TOC in MTC patients with rising Ct levels and tumor uptake on <sup>111</sup>In-Octreoscan. Twenty-nine percent of patients demonstrated decreasing Ct levels after therapy. Thirteen percent developed hematologic toxicities and 23% developed renal toxicities. The visual grade of <sup>111</sup>In-Octreoscan tumor uptake was not associated with treatment response or survival.

The efficacy of pretargeted radio-immunotherapy with bispecific monoclonal antibody (BsMAB) and a <sup>131</sup>I-labeled bivalent hapten has been evaluated (211,315,316). Patients with advanced, progressive MTC (defined by short serum Ct DT) received an anti-CEA/anti-diethylenetriamine pentaacetic acid (DTPA)-indium BsMAB, followed 4 days later by a <sup>131</sup>I-labeled bivalent hapten (315). Overall survival (OS) was compared with contemporaneous untreated MTC patients with comparable prognostic indicators. OS was significantly longer in high-risk, treated patients (Ct DT <2 years) than in high-risk, untreated patients (median OS, 110 v 61 months;  $p < 0.030$ ). Forty-seven percent of treated patients demonstrated a greater than 100% increase in Ct DT. Treated patients with bone or bone-marrow disease had a longer survival than patients without such involvement (10-year OS, 83% vs. 14%;  $p < 0.023$ ). Toxicity was mainly hematologic and related to bone or bone-marrow tumor spread.

Treatment with <sup>131</sup>I-MIBG is generally regarded as ineffective for MTC, although some reports have described partial tumor remission or stability, improved symptoms and quality of life, and limited data suggesting prolonged survival (250,317–319).

#### ■ RECOMMENDATION 108

Treatment with radio-labeled molecules may be considered in selected patients, ideally in the setting of a well-designed clinical trial. Grade: C Recommendation

Recently, a number of promising agents have been studied in phase I and phase II clinical trials with results presented at national scientific meetings (320–324). Several of these agents have demonstrated significant partial response rates in the range of 20–50% with a larger number of patients demonstrating stable disease. Thus, while these cytostatic agents are unlikely to demonstrate a complete remission, they have the potential to provide high rates of disease control with durable responses and relatively low toxicity. Improved quality of life, such as diminished diarrhea, is also possible. However, it is difficult to make a specific recommendation regarding their use in patients with advanced MTC, since there is little peer-reviewed published data and most of these compounds have not been approved by the U.S. Food and Drug Administration. Further, long-term toxicity of these compounds needs to be investigated. Additionally, it is possible that combination therapy with two or more of these targeted agents, or a combination of a targeted agent with conventional cytotoxic chemotherapy will eventually prove more efficacious than a single targeted therapy alone.

#### ■ RECOMMENDATION 109

Given the absence of an established effective systemic therapy for patients with advanced MTC, physicians

should give high priority to facilitating enrollment of their patients into well-designed clinical trials. Grade: C Recommendation

[E11] *Symptoms, evaluation, and treatment of hormonally active metastases.* Diarrhea, ectopic corticotropin-releasing hormone (CRH), and ectopic adrenocorticotrophic hormone (ACTH) are the main hormonally mediated complications of MTC. Other rare situations include the ectopic production of PTH-related peptide, insulin, and glucagon.

Diarrhea occurs most frequently in the setting of advanced disease, frequently in patients with hepatic metastases. The diarrhea may be hypersecretory (325), or due to enhanced gastrointestinal motility (326), or a combination of both. The diarrhea can be debilitating both in terms of quality of life and nutrition. Therapy with antimotility agents (such as loperamide or codeine) is first-line therapy due to their low side effects and ease of administration. Treatment with somatostatin analogues and debulking of large tumor deposits have also been employed. Somatostatin analogue therapy for diarrhea has mostly been reported in this setting in small nonrandomized cohort studies with variable results that may suggest modestly improved symptoms in some patients (327–330). The combination of somatostatin analogs with interferon alpha has been reported in single center studies to improve symptoms of flushing and diarrhea in the majority of patients (331,332), although these findings have not been confirmed by others. Local treatment of large hepatic metastases using selective artery chemoembolization has also been reported in nonrandomized studies (303,304). Fromigue et al. (304) reported that five of their patients had diarrhea, but only two had an objective response. By contrast, Lorenz et al. (303) reported that all six of their patients with diarrhea had improvement.

#### ■ RECOMMENDATION 110

Therapy to reduce the frequency and amount of diarrhea in the setting of MTC should be employed. Initial therapy should include antimotility agents. Alternative therapies may include treatment with somatostatin analogues and local therapies such as surgery or chemoembolization in selected cases. Grade: C Recommendation

MTCs can occasionally secrete high levels of bioactive hormones other than Ct that rarely cause clinical manifestations; typically in the setting of metastatic disease that frequently includes large hepatic metastases. The most common of these additional hormonal secretions is ACTH or CRH that can result in Cushing syndrome, which may present with hypokalemia. MTC is reported to account for up to 2–6% of all cases of ectopic Cushing syndrome (333,334). Control of cortisol levels (or action) and clinical manifestations may be achieved by debulking of large hepatic metastases (surgery or chemoembolization), by medical therapy using ketocozazole, mifepristone, aminoglutethimide (335), metyrapone (335), or mitotane (336), and/or by bilateral adrenalectomy (333,334,337–339). Treatment with somatostatin analogs is ineffective. Overall, based on individual case reports or small clinical series, the development of Cushing syndrome from MTC is associated with poor patient survival due to the progressive MTC; however, because Cushing syndrome can be severe and debilitating, treatment should be considered even in the setting of widely metastatic MTC.

#### ■ RECOMMENDATION 111

Clinicians should maintain a heightened vigilance for Cushing syndrome due to tumoral production of ACTH and/or CRH from MTC. Grade: C Recommendation

#### ■ RECOMMENDATION 112

While MTC patients with Cushing syndrome typically have a poor prognosis, treatment should be considered even in the setting of widely metastatic MTC because the syndrome can be severe and debilitating. Grade: C Recommendation

#### ■ RECOMMENDATION 113

Cushing syndrome from MTC may be treated in a multimodality manner with therapy directed towards the tumor and medical therapy directed towards the Cushing Syndrome, or bilateral adrenalectomy. The choice of therapy may depend on multiple factors including the severity and the stability of the MTC and the response of the Cushing Syndrome to medical therapy. However, expert opinion of the Task Force generally favored bilateral adrenalectomy. Grade: C Recommendation

### **[F] Long-term follow-up and management**

[F1] *Goals of long-term follow-up and management of patients with and without residual disease.* For patients with sporadic or familial MTC with no evidence of residual disease after initial surgery based on radiographic and biochemical testing, long-term complete remission is a realistic goal. Early detection of recurrent MTC may reduce the likelihood of local complications or the development of distant metastases, but this has not been studied in a prospective manner. In one large cooperative study of 899 patients from France in which a biochemical recurrence was defined as an elevation of Ct after postoperative Ct "normalization," the rate was 4.9% (40). In a follow-up study from the same group utilizing a single and more sensitive Ct assay (sensitivity 2 ng/L), patients were identified who had an abnormal basal or pentagastrin stimulated serum Ct level >10 ng/L at their last visit. Of these, 3.3% were considered to have recurrent disease because they had previously demonstrated a postoperative pentagastrin-stimulated serum Ct of ≤10 ng/L within 6 months of surgery. Interestingly, one third of these patients had no evidence of nodal metastasis at initial surgery. The recurrences occurred at a mean of 3.2 (range 0.7–7.5 years) after the initial surgery (213). Disappointingly, about 7% of patients undergoing prophylactic thyroidectomy experience biochemical recurrence, although those children had surgery at 13 years of age or later (80). Using the more strict criteria of an undetectable basal and stimulated Ct, Skinner et al. (81) demonstrated a 2% rate of persistent disease after prophylactic thyroidectomy and a 10% rate of recurrence after 5–10 years of follow-up. Eighty percent of these patients with recurrence had no lymph node metastases found at the time of their thyroidectomy and central neck dissection.

#### ■ RECOMMENDATION 114

Long-term biochemical monitoring for patients with MTC who achieve a complete biochemical cure should be performed. Grade: B Recommendation

#### ■ RECOMMENDATION 115

Long-term biochemical monitoring for MTC patients who achieve a complete biochemical cure should include annual measurement of serum Ct. Grade: C Recommendation

In the setting of residual MTC after appropriate initial surgical resection, it is unlikely that a complete remission will be attained. The goals of follow-up in this setting are to prevent local complications of progressive residual disease and/or limit the likelihood and/or complications of metastatic MTC. Early detection of progressive disease may reduce the likelihood of local cervical complications and also complications of distant metastases located near critical structures, such as the spinal canal.

#### ■ RECOMMENDATION 116

Patients with persistent MTC should be monitored by measuring Ct and CEA levels, along with history and physical examinations. The timing of follow-up anatomic imaging may be based on the relative stability of these tests, presence or absence of symptoms, and the location of known or likely sites of metastatic deposits. Grade: C Recommendation

#### ■ RECOMMENDATION 117

Patients with detectable basal serum Ct levels postoperatively should have the basal Ct and CEA levels obtained approximately every 6 months to determine their DTs. Ongoing follow-up of these tumor markers and physical examination should occur at one fourth the shortest DT or annually, whichever is more frequent (i.e., follow patient every 6 months if the shortest DT is 24 months). Grade: C Recommendation

#### ■ RECOMMENDATION 118

In patients with detectable basal serum Ct levels postoperatively, if the Ct or CEA rises substantially since the previous anatomic imaging evaluation, then a neck US should be performed. The Ct elevation required to trigger this action typically depends on the basal serum Ct and the clinical situation, but elevation by more than 20–100% may prompt this evaluation. If the serum Ct is >150 pg/mL then systemic imaging should be repeated as well. Grade: C Recommendation

[F2] *Follow-up of patients without MTC at thyroidectomy (Fig. 5).* The risk of persistent or recurrent disease after prophylactic thyroidectomy reveals normal tissue or CCH is very low (84). Skinner et al. (81) studied 50 patients with MEN 2 who underwent prophylactic thyroidectomy and central neck dissection. Sixteen of these patients demonstrated only CCH or normal pathology, and none of them demonstrated any measurable Ct after stimulation testing through a minimum of 60 months of follow-up. Conversely, 6 of their 50 patients demonstrated persistent or recurrent disease, including two patients whose pathology demonstrated only microscopic evidence of MTC and no lymph node metastases. Their follow-up stimulated Ct testing first became abnormal 5–7 years after initial therapy, while their basal levels remained undetectable.



### ■ RECOMMENDATION 119

After prophylactic thyroidectomy demonstrates no evidence of MTC, the risk of developing MTC is low, and the optimal follow-up for these patients is uncertain. Annual measurement of basal serum Ct without measurement of CEA should be considered. Less frequent testing may be considered if there is no evidence of disease after prolonged follow-up. Grade: C Recommendation

[F3] *Role of stimulation testing for serum Ct.* In the past and present, some MTC patients have demonstrated undetectable basal serum Ct levels that rise after stimulation testing with pentagastrin, calcium, or both (92). Stimulation testing adds cost to patient follow-up, and pentagastrin frequently causes transient unpleasant symptoms. A rise in serum Ct after stimulation suggests residual or recurrent MTC (81). However, as the functional sensitivity of the Ct assays have become lower, those patients with abnormal testing only after stimulation typically have very low levels of disease that is unlikely to be found by anatomic or functional imaging (231). It is possible that knowledge of likely residual disease may prompt the patient and physician to maintain regular surveillance for disease progression. However, given the low rate of biochemical remission in patients with metastatic MTC, the impact of this knowledge is likely to be low. Further, pentagastrin is not available in many countries, and calcium stimulation testing is accepted as inferior (although demonstrative publications are largely lacking).

### ■ RECOMMENDATION 120

Stimulated serum Ct testing may detect low levels of residual disease despite undetectable basal Ct values. Such minimal disease is currently unlikely to be able to be localized or treated, and therefore this follow-up testing is not recommended (agreement amongst the Task Force was not unanimous). Grade: D Recommendation

[F4] *Management of CEA-positive, but Ct-negative patients.* Laboratory factors that may result in falsely low Ct levels were discussed previously. False elevation of serum CEA may result from heterophilic antibodies (340). Other possibility for this scenario include CEA coming from a condition other than MTC or the loss of Ct production by the MTC (341, 342).

CEA may be secreted by cancers of the digestive system, lung, prostate, breast, and ovary. Benign conditions associated with CEA elevation, to varying degrees, have included bronchogenic cyst, gastrointestinal tract inflammatory disease, chronic obstructive pulmonary disease, and benign pulmonary disease.

In patients with MTC, rising CEA levels suggest progressive disease, although the vast majority of such patients also have elevated serum Ct levels (212,269). Some patients with progressive disease demonstrate an increase in CEA while the Ct levels decline, which has been considered a mark of tumor dedifferentiation (343). Rarely MTC patients are described that lack elevation of both serum Ct and CEA which is thought to reflect more advanced dedifferentiation and convey a poor prognosis (234,342).

Mendelsohn et al. (344) studied CEA and Ct in MTC by immunohistochemistry. They found that in most cases, CEA and Ct were similar in the tumors, being expressed by almost

every cell. This was especially true for CCH, in early disease (microscopic MTC), and even in gross MTC confined to the thyroid. In contrast, primary and metastatic tumors from patients with invasive disease had an inverse relationship between CEA and Ct staining such that the most aggressive disease had persistent and intense CEA staining but minimal if any Ct staining. They suggested that CEA was a marker for early epithelial differentiation and therefore retained while Ct was a late marker for terminal differentiation and therefore lost.

### ■ RECOMMENDATION 121

Elevated CEA levels that are out of proportion to the serum Ct may occur from several causes, including some unrelated to MTC, which should be considered and evaluated as appropriate based on clinical judgment. Grade: C Recommendation

[F5] *Lichen planus amyloidosis.* Lichen planus amyloidosis (LPA) can be associated with MTC in the setting of MEN 2A with codon 634 mutations in RET (46,345–347). Verga et al. (47) reported an incidence of LPA, or pruritis without LPA, in 36% of patients with the 634 mutation. The initial classic symptom of LPA is intense pruritis between the scapulae that improves with sun exposure and worsens during periods of stress. Hyperpigmented lesions later develop believed to be secondary to the dermatomal scratching. However, amyloid in biopsies of LPA has been shown to be comprised of Ct using atomic force microscopy and MALDI-TOF analysis, suggesting a potential role for Ct in its development (348). The pruritis is often present in childhood and can pre-date the development of MTC (47,349). The pruritis can be a significant problem for patients as therapy typically provides incomplete symptom relief. Treatments have included moisturizing lotions and creams, local corticosteroids, systemic antihistamines, capsaicin, and phototherapy (47). Two patients with LPA treated with the tyrosine kinase inhibitor vandetanib experienced rapid disappearance of LPA, which reappeared with dose reduction (M. Schlumberger, personal communication, May 11, 2008).

### ■ RECOMMENDATION 122

LPA should be treated symptomatically to minimize pruritis. Grade: C Recommendation

### [G] *Directions for future research*

Directions for future research include: 1) The refinement of the cancer phenotype (especially age-related penetrance of component features) associated with specific mutations of RET to allow for more individualized surveillance and management recommendations, including the timing of prophylactic surgery. These questions will likely be best answered in the setting of an international consortium able to accrue large numbers of patients. Further studies are needed to answer whether there are truly mutations that predispose to only FMTC, or, rather do these mutations confer lower (but not nonexistent) penetrance for PHEO and PHPT. 2) The identification of potential modifier genes and “polymorphisms” within RET on the clinical phenotype (350–356). 3) Improving murine models of MEN 2. 4) Advancing knowledge of the role of RET signaling pathways in MTC biology; including tumorigenesis and progression, to devise novel therapies (357–359). 5) Elucidating the reasons for tissue selectivity of tumors

given the "germline" mutation status present in every cell. 6) Identifying the potential role of targeting RET or its signaling cascade at the level of the gene, mRNA, and/or protein in the prevention and treatment of MEN 2 (359).

In the absence of nonsurgical methods to prevent MTC, the optimal timing of prophylactic thyroidectomy in MEN 2 and FMTC remains an issue that may benefit from further study, particularly in identifying parameters that can identify subsets of patients in whom surgery can be safely delayed, thereby minimizing risks. Refinement of criteria that may allow the safe avoidance of central neck dissections may reduce the incidence of hypoparathyroidism and recurrent laryngeal nerve injuries. This includes a need for establishment and reporting of the normal Ct range on each Ct assay in children, especially in the first 12 months of life for the rare MEN 2B patients. Educational opportunities should be explored on how to optimally perform and interpret neck US in young children to differentiate suspicious from benign lymph nodes. The development and recognition of centralized referral centers for such rare cases would likely be of benefit, but are only practical if the medical and medical insurance communities endorsed such referral patterns. The fact that a high percentage of MEN 2B children are not cured of MTC due to both early metastases and late diagnosis suggests the need for effective therapy beyond that of extirpative surgery.

In the setting of established MTC, the optimal extent of preoperative metastatic screening is unclear. Should all patients have a significant metastatic survey preoperatively, or should this evaluation be minimized with the potential for further evaluation based on the postoperative Ct level? If a more complete preoperative evaluation is considered, should it be based on the extent of neck disease, the serum Ct level, or both?

New strategies to treat metastatic MTC are being evaluated and include radioimmunotherapy and vaccine-based therapies. There has been recent focus on the use of compounds that inhibit the function of receptors or intracellular kinases. Compounds have been developed that block kinases with greater or lesser degrees of specificity that are involved in the pathogenesis or progression of cancer. In MTC, the most obvious kinase target is RET due to its critical role in familial cases, as well as in 40–50% of sporadic cases. Molecules that block RET kinase activity directly, or that block subsequent downstream signaling molecules, have been shown to inhibit MTC cell proliferation and reduce the production of active peptides (360–362). Other targets for therapeutic intervention are proteins that facilitate cancer cell growth and/or blood vessel formation, such as vascular endothelial growth factor and its receptors. Currently, several kinase inhibitors are under evaluation in clinical trials and preliminary evidence indicates that they may have important clinical benefits (363). However, the final results of these trials and adequate follow-up observation times are needed. Further, most of these targeted therapies are more likely to be cytostatic rather than cytoreductive. While clinical stability is important in patients with progressive disease, most clinical trials are based on RECIST criteria that are designed to detect complete and partial tumor remissions, the latter defined as the reduction of the summed greatest tumor lengths of >30%. Additionally, these therapies have significant short and/or long-term toxicities. Thus, new approaches to clinical trial design and analysis are likely to be needed to evaluate the relevance of

these new compounds regarding clinically important measures: progression-free survival, disease-specific survival, overall survival, and quality of life.

Major future challenges including the likelihood that single agent-targeted therapies will not be a panacea, and that tumors will evade these blocks in signaling pathways and eventually manifest progressive disease. Thus, combination or sequential therapies may be required. Another concern is that targeted therapies may actually exert pressure on the tumor to find these alternative mechanisms for continued survival and growth, and thus may encourage more aggressive tumor behavior or dedifferentiation. Further, while reductions in tumor volume may be seen, many of these compounds are more likely to induce tumor stabilization, and therefore the optimal duration of therapy is unknown. Realistically, patients with metastatic MTC may be faced with taking a systemic therapy for the remainder of their lives, and the long-term effects of blocking these pathways for prolonged periods of time are currently unknown. The emergence of an effective systemic therapy, or combination of therapies, that is well-tolerated may lead to its potential use as an adjuvant treatment to surgery, or as an option for primary treatment for selected patients.

#### Acknowledgments

The patient organization, ThyCa: Thyroid Cancer Survivors' Association, Inc., contributed an unrestricted educational grant towards the development of the medullary thyroid cancer guidelines. The American Thyroid Association provided the remainder of the funding without commercial support.

The Task Force wishes to thank Ms. Barbara Smith, Executive Director, American Thyroid Association, for her valuable assistance, wisdom, and support. The ATA thanks Victor J. Bernet for developing the tumor marker calculator for the ATA website; David S. Cooper, Gilbert H. Daniels, and R. Michael Tuttle for critically reviewing this manuscript; and Emily Edelman, Shanna Gustafson, Brandie Heald Leach, Cheryl Scacheri, Amy Shealy, and Kevin Zbuk for input into early drafts of the manuscript.

#### Disclaimer

The American Thyroid Association develops Clinical Practice Guidelines to provide guidance and recommendations for particular practice areas concerning thyroid disease and thyroid cancer. The Guidelines are not inclusive of all proper approaches or methods, or exclusive of others. The Guidelines do not establish a standard of care and specific outcomes are not guaranteed.

Treatment decisions must be made based on the independent judgment of health care providers and each patient's individual circumstances. A guideline is not intended to take the place of physician judgment in diagnosing and treating particular patients.

The ATA develops guidelines based on the evidence available in the literature and the expert opinion of the task force in the recent timeframe of the publication of the guidelines. Management issues have not been and cannot be comprehensively addressed in randomized trials; therefore, the evidence cannot be comprehensive. Guidelines cannot

always account for individual variation among patients. Guidelines cannot be considered inclusive of all proper methods of care or exclusive of other treatments reasonably directed at obtaining the same results.

Therefore, the American Thyroid Association considers use of this guideline to aid in clinical decision-making to be voluntary, with the ultimate determination regarding its application to be made by the treating physician and health care professionals with the full consideration of the individual patient's clinical history and physical status. In addition, the guideline concerns the therapeutic interventions used in clinical practice and do not pertain to clinical trials.

### Disclosure Statement

Task Force disclosure information is provided for the two years prior to March 2008 and the known future as of February 2009. RTK served as a consultant for AstraZeneca, Bayer Pharmaceuticals Corporation, and Onyx Pharmaceuticals, Inc. (without compensation), and received grant support from Exelixis and Eisai. GLF is a stockholder of Pfizer Inc. RFG served as a consultant for Exelixis, and received grant support from AstraZeneca. MDR served as a consultant for Amgen, and received grant support from Exelixis and Eisai. MS served as a consultant for AstraZeneca; received speaker honoraria from AstraZeneca and Pfizer Inc.; and received or is the potential recipient of grant support from AstraZeneca, Amgen, Exelixis, and Eisai. SAW received speaker honoraria from AstraZeneca. CE, DBE, HG, JFM, and FP report that no competing financial interests exist.

### References

- Kendall-Taylor P 2003 Guidelines for the management of thyroid cancer. *Clin Endocrinol* **58**:400–402.
- Brandi ML, Gagel RF, Angeli A, Bilezikian JP, Beck-Peccoz P, Bordi C, Conte-Devolx B, Falchetti A, Gheri RG, Libroia A, Lips CJ, Lombardi G, Mannelli M, Pacini F, Ponder BA, Raue F, Skogseid B, Tamburrano G, Thakker RV, Thompson NW, Tomassetti P, Tonelli F, Wells SA Jr, Marx SJ 2001 Guidelines for diagnosis and therapy of MEN type 1 and type 2. *J Clin Endocrinol Metab* **86**:5658–5671.
- Karges W, Dralle H, Raue F, Mann K, Reiners C, Grussendorf M, Hufner M, Niederle B, Brabant G 2004 Calcitonin measurement to detect medullary thyroid carcinoma in nodular goiter: German evidence-based consensus recommendation. *Exp Clin Endocrinol Diabetes* **112**:52–58.
- Sherman SI, Angelos P, Ball DW, Byrd D, Clark OH, Daniels GH, Dilawari RA, Ehya H, Farrar WB, Gagel RF, Kandeel F, Kloos RT, Kopp P, Lamonica DM, Loree TR, Lydiatt WM, McCaffrey J, Olson JA Jr, Ridge JA, Shah JP, Sisson JC, Tuttle RM, Urist MM 2007 Thyroid carcinoma. *J Natl Compr Canc Netw* **5**:568–621.
- Cooper DS, Doherty GM, Haugen BR, Kloos RT, Lee SL, Mandel SJ, Mazzaferri EL, McIver B, Sherman SI, Tuttle RM 2006 Management guidelines for patients with thyroid nodules and differentiated thyroid cancer. *Thyroid* **16**:109–142.
- Jaquet AJ 1906 Ein fall von metastasierenden amyloidtumoren (lymphosarcoma). *Virchows Archiv* **185**:251–267.
- Hazard JB, Hawk WA, Crile G Jr 1959 Medullary (solid) carcinoma of the thyroid; a clinicopathologic entity. *J Clin Endocrinol Metab* **19**:152–161.
- Williams ED 1966 Histogenesis of medullary carcinoma of the thyroid. *J Clin Pathol* **19**:114–118.
- Williams ED 1966 Diarrhoea and thyroid carcinoma. *Proc R Soc Med* **59**:602–603.
- Williams ED, Brown CL, Doniach I 1966 Pathological and clinical findings in a series of 67 cases of medullary carcinoma of the thyroid. *J Clin Pathol* **19**:103–113.
- Hundahl SA, Fleming ID, Fremgen AM, Menck HR 1998 A National Cancer Data Base report on 53,856 cases of thyroid carcinoma treated in the U.S., 1985–1995 [see comments]. *Cancer* **83**:2638–2648.
- Pelizzo MR, Boschin IM, Bernante P, Toniato A, Piotto A, Pagetta C, Nibale O, Rampin L, Muzzio PC, Rubello D 2007 Natural history, diagnosis, treatment and outcome of medullary thyroid cancer: 37 years experience on 157 patients. *Eur J Surg Oncol* **33**:493–497.
- Baloch ZW, LiVolsi VA 2001 Prognostic factors in well-differentiated follicular-derived carcinoma and medullary thyroid carcinoma. *Thyroid* **11**:637–645.
- Paszko Z, Sromek M, Czetwertynska M, Skasko E, Czapczak D, Wisniewska A, Prokurat A, Chrupek M, Jagielska A, Kozlowicz-Gudzinska I 2007 The occurrence and the type of germline mutations in the RET gene in patients with medullary thyroid carcinoma and their unaffected kindreds from Central Poland. *Cancer Invest* **25**:742–749.
- Bergant D, Hocevar M, Besic N, Glavac D, Korosec B, Caserman S 2006 Hereditary medullary thyroid cancer in Slovenia—genotype-phenotype correlations. *Wien Klin Wochenschr* **118**:411–416.
- Mulligan LM, Kwok JB, Healey CS, Elsdon MJ, Eng C, Gardner E, Love DR, Mole SE, Moore JK, Papi L, Ponder MA, Telenius H, Tunnacliffe A, Ponder BAJ 1993 Germ-line mutations of the RET proto-oncogene in multiple endocrine neoplasia type 2A. *Nature* **363**:458–460.
- Donis-Keller H, Dou S, Chi D, Carlson KM, Tushima K, Lairmore TC, Howe JR, Moley JF, Goodfellow P, Wells SA Jr 1993 Mutations in the RET proto-oncogene are associated with MEN 2A and FMTC. *Hum Mol Genet* **2**:851–856.
- Carlson KM, Bracamontes J, Jackson CE, Clark R, Lacroix A, Wells SA Jr, Goodfellow PJ 1994 Parent-of-origin effects in multiple endocrine neoplasia type 2B. *Am J Hum Genet* **55**:1076–1082.
- Schuffenecker I, Ginet N, Goldgar D, Eng C, Chambe B, Boneu A, Houdent C, Pallo D, Schlumberger M, Thivolet C, Lenoir GM 1997 Prevalence and parental origin of de novo RET mutations in multiple endocrine neoplasia type 2A and familial medullary thyroid carcinoma. *Le Groupe d'Etude des Tumeurs a Calcitonine. Am J Hum Genet* **60**:233–237.
- Wolfe HJ, Melvin KE, Cervi-Skinner SJ, Saadi AA, Juliar JF, Jackson CE, Tashjian AH Jr 1973 C-cell hyperplasia preceding medullary thyroid carcinoma. *N Engl J Med* **289**:437–441.
- LiVolsi VA 1997 C cell hyperplasia/neoplasia. *J Clin Endocrinol Metab* **82**:39–41.
- Gimm O, Morrison CD, Suster S, Komminoth P, Mulligan L, Sweet KM 2004 Multiple endocrine neoplasia type 2. In: Dellellis RA, Lloyd RV, Heitz PU, Eng C (eds) *Pathology and Genetics of Tumours of Endocrine Organs*. IARC Press, Lyon, pp 211–218.
- Sipple J 1961 The association of pheochromocytoma with carcinomas of the thyroid gland. *Am J Med* **31**:163–166.
- Steiner AL, Goodman AD, Powers SR 1968 Study of a kindred with pheochromocytoma, medullary thyroid

- carcinoma, hyperparathyroidism and Cushing's disease: multiple endocrine neoplasia, type 2. *Medicine* **47**:371–409.
25. Neumann HP, Vortmeyer A, Schmidt D, Werner M, Erlic Z, Cascon A, Bausch B, Januszewicz A, Eng C 2007 Evidence of MEN-2 in the original description of classic pheochromocytoma. *N Engl J Med* **357**:1311–1315.
  26. Farndon JR, Leight GS, Dilley WG, Baylin SB, Smallridge RC, Harrison TS, Wells SA Jr 1986 Familial medullary thyroid carcinoma without associated endocrinopathies: a distinct clinical entity. *Br J Surg* **73**:278–281.
  27. Wagenmann A 1922 Multiple neurome des Auges und der Zunge. *Ber Dtsch Ophthal* **43**:282–285.
  28. Froboese C 1923 Das aus markhaltigen nervenfascern bestehende gangliezellenlose echte neurom in rankenformzugleich ein beitrag zu den nervosen Geschwulsten der zunge und des augenlides. *Virchows Arch Pathol Anat* **240**:312–327.
  29. Williams ED, Pollock DJ 1966 Multiple mucosal neuromata with endocrine tumours: a syndrome allied to von Recklinghausen's disease. *J Pathol Bacteriol* **91**:71–80.
  30. Takahashi M, Ritz J, Cooper GM 1985 Activation of a novel human transforming gene, ret, by DNA rearrangement. *Cell* **42**:581–588.
  31. Mathew CG, Chin KS, Easton DF, Thorpe K, Carter C, Liou GI, Fong SL, Bridges CD, Haak H, Kruseman AC, Schifter S, Hansen HH, Telenius H, Telenius-Berg M, Ponder BAJ 1987 A linked genetic marker for multiple endocrine neoplasia type 2A on chromosome 10. *Nature* **328**:527–528.
  32. Eng C, Smith DP, Mulligan LM, Nagai MA, Healey CS, Ponder MA, Gardner E, Scheumann GF, Jackson CE, Tunnacliffe A, Ponder BAJ 1994 Point mutation within the tyrosine kinase domain of the RET proto-oncogene in multiple endocrine neoplasia type 2B and related sporadic tumours. *Hum Mol Genet* **3**:237–241.
  33. Carlson KM, Dou S, Chi D, Scavarda N, Toshima K, Jackson CE, Wells SA Jr, Goodfellow PJ, Donis-Keller H 1994 Single missense mutation in the tyrosine kinase catalytic domain of the RET protooncogene is associated with multiple endocrine neoplasia type 2B. *Proc Natl Acad Sci U S A* **91**:1579–1583.
  34. Hofstra RM, Landsvater RM, Ceccherini I, Stulp RP, Stelwagen T, Luo Y, Pasini B, Hoppener JW, van Amstel HK, Romeo G, Lips CJ, Buys CH 1994 A mutation in the RET proto-oncogene associated with multiple endocrine neoplasia type 2B and sporadic medullary thyroid carcinoma. *Nature* **367**:375–376.
  35. de Groot JW, Links TP, Plukker JT, Lips CJ, Hofstra RM 2006 RET as a diagnostic and therapeutic target in sporadic and hereditary endocrine tumors. *Endocr Rev* **27**:535–560.
  36. Romei C, Elisei R, Pinchera A, Ceccherini I, Molinaro E, Mancusi F, Martino E, Romeo G, Pacini F 1996 Somatic mutations of the ret protooncogene in sporadic medullary thyroid carcinoma are not restricted to exon 16 and are associated with tumor recurrence. *J Clin Endocrinol Metab* **81**:1619–1622.
  37. Elisei R, Cosci B, Romei C, Bottici V, Renzini G, Molinaro E, Agate L, Vivaldi A, Faviana P, Basolo F, Miccoli P, Berti P, Pacini F, Pinchera A 2008 Prognostic significance of somatic RET oncogene mutations in sporadic medullary thyroid cancer: a 10-year follow-up study. *J Clin Endocrinol Metab* **93**:682–687.
  38. Miccoli P, Minuto MN, Ugolini C, Molinaro E, Basolo F, Berti P, Pinchera A, Elisei R 2007 Clinically unpredictable prognostic factors in the outcome of medullary thyroid cancer. *Endocr Relat Cancer* **14**:1099–1105.
  39. Cupisti K, Wolf A, Raffel A, Schott M, Miersch D, Yang Q, Eisenberger CF, Roher HD, Knoefel WT 2007 Long-term clinical and biochemical follow-up in medullary thyroid carcinoma: a single institution's experience over 20 years. *Ann Surg* **246**:815–821.
  40. Modigliani E, Cohen R, Campos JM, Conte-Devolx B, Maes B, Boneu A, Schlumberger M, Bigorgne JC, Dumontier P, Leclerc L, Corcuff B, Guilhem I 1998 Prognostic factors for survival and for biochemical cure in medullary thyroid carcinoma: results in 899 patients. The GETC Study Group. Groupe d'étude des tumeurs à calcitonine. *Clin Endocrinol* **48**:265–273.
  41. Greene FL, Page DL, Fleming ID, Fritz A, Balch DM 2003 *AJCC Cancer Staging Manual*, 6th edition. Springer Verlag, Chicago.
  42. Kebebew E, Greenspan FS, Clark OH, Woeber KA, Grunwell J 2005 Extent of disease and practice patterns for medullary thyroid cancer. *J Am Coll Surg* **200**:890–896.
  43. Roman S, Lin R, Sosa JA 2006 Prognosis of medullary thyroid carcinoma: demographic, clinical, and pathologic predictors of survival in 1252 cases. *Cancer* **107**:2134–2142.
  44. Hansford JR, Mulligan LM 2000 Multiple endocrine neoplasia type 2 and RET: from neoplasia to neurogenesis. *J Med Genet* **37**:817–827.
  45. Iihara M, Yamashita T, Okamoto T, Kanbe M, Yamazaki K, Egawa S, Yamaguchi K, Obara T 1997 A nationwide clinical survey of patients with multiple endocrine neoplasia type 2 and familial medullary thyroid carcinoma in Japan. *Jpn J Clin Oncol* **27**:128–134.
  46. Eng C, Clayton D, Schuffenecker J, Lenoir G, Cote G, Gagel RF, van Amstel HK, Lips CJ, Nishisho I, Takai SI, Marsh DJ, Robinson BG, Frank-Raue K, Raue F, Xue F, Noll WW, Romei C, Pacini F, Fink M, Niederle B, Zedenius J, Nordenskjold M, Komminoth P, Hendy GN, Gharib H, Thiobodeau SN, Lacroix A, Frilling A, Ponder, BAJ, Mulligan LM 1996 The relationship between specific RET proto-oncogene mutations and disease phenotype in multiple endocrine neoplasia type 2. International RET mutation consortium analysis. *JAMA* **276**:1575–1579.
  47. Verga U, Fugazzola L, Cambiaghi S, Pritelli C, Alessi E, Cortelazzi D, Gangi E, Beck-Peccoz P 2003 Frequent association between MEN 2A and cutaneous lichen amyloidosis. *Clin Endocrinol* **59**:156–161.
  48. Brauckhoff M, Gimm O, Hinze R, Ukkat J, Brauckhoff K, Dralle H 2002 Papillary thyroid carcinoma in patients with RET proto-oncogene germline mutation. *Thyroid* **12**:557–561.
  49. Eng C 1996 Seminars in medicine of the Beth Israel Hospital, Boston. The RET proto-oncogene in multiple endocrine neoplasia type 2 and Hirschsprung's disease. *N Engl J Med* **335**:943–951.
  50. Romeo G, Ceccherini I, Celli J, Priolo M, Betsos N, Bonardi G, Seri M, Yin L, Lerone M, Jasonni V, Martucciello G 1998 Association of multiple endocrine neoplasia type 2 and Hirschsprung disease. *J Intern Med* **243**:515–520.
  51. Mulligan LM, Eng C, Attie T, Lyonnet S, Marsh DJ, Hyland VJ, Robinson BG, Frilling A, Verellen-Dumoulin C, Safar A, Venter DJ, Munnich A, Ponder BAJ 1994 Diverse phenotypes associated with exon 10 mutations of the RET proto-oncogene. *Hum Mol Genet* **3**:2163–2167.
  52. Moers AM, Landsvater RM, Schaap C, Jansen-Schillhorn van Veen JM, de Valk IA, Blijham GH, Hoppener JW, Vroom TM, van Amstel HK, Lips CJ 1996 Familial medullary thy-

- roid carcinoma: not a distinct entity? Genotype-phenotype correlation in a large family. *Am J Med* **101**:635–641.
53. Machens A, Dralle H 2006 Multiple endocrine neoplasia type 2 and the RET protooncogene: from bedside to bench to bedside. *Mol Cell Endocrinol* **247**:34–40.
  54. Machens A, Gimm O, Hinze R, Hoppner W, Boehm BO, Dralle H 2001 Genotype-phenotype correlations in hereditary medullary thyroid carcinoma: oncological features and biochemical properties. *J Clin Endocrinol Metab* **86**:1104–1109.
  55. O'Riordain DS, O'Brien T, Weaver AL, Gharib H, Hay ID, Grant CS, van Heerden JA 1994 Medullary thyroid carcinoma in multiple endocrine neoplasia types 2A and 2B. *Surgery* **116**:1017–1023.
  56. Jackson CE, Talpos GB, Block MA, Norum RA, Lloyd RV, Tashjian AH Jr 1984 Clinical value of tumor doubling estimations in multiple endocrine neoplasia type II. *Surgery* **96**:981–987.
  57. Brunt LM, Wells SA Jr 1987 Advances in the diagnosis and treatment of medullary thyroid carcinoma. *Surg Clin North Am* **67**:263–279.
  58. O'Riordain DS, O'Brien T, Crotty TB, Gharib H, Grant CS, van Heerden JA 1995 Multiple endocrine neoplasia type 2B: more than an endocrine disorder. *Surgery* **118**:936–942.
  59. Skinner MA, DeBenedetti MK, Moley JF, Norton JA, Wells SA Jr 1996 Medullary thyroid carcinoma in children with multiple endocrine neoplasia types 2A and 2B. *J Pediatr Surg* **31**:177–181; discussion 181–172.
  60. Kaufman FR, Roe TF, Isaacs H Jr, Weitzman JJ 1982 Metastatic medullary thyroid carcinoma in young children with mucosal neuroma syndrome. *Pediatrics* **70**:263–267.
  61. Wygoda Z, Oczko-Wojciechowska M, Gubała E, Pawlaczek A, Kula D, Wiench M, Włoch J 2006 [Medullary thyroid carcinoma: the comparison of the hereditary and sporadic types of cancer]. *Endokrynol Pol* **57**:407–414. (In Polish.)
  62. de Groot JW, Plukker JT, Wolffenbuttel BH, Wiggers T, Sluiter WJ, Links TP 2006 Determinants of life expectancy in medullary thyroid cancer: age does not matter. *Clin Endocrinol* **65**:729–736.
  63. Machens A, Brauckhoff M, Holzhausen HJ, Thanh PN, Lehnert H, Dralle H 2005 Codon-specific development of pheochromocytoma in multiple endocrine neoplasia type 2. *J Clin Endocrinol Metab* **90**:3999–4003.
  64. Leboulleux S, Travagli JP, Caillou B, Laplanche A, Bidart JM, Schlumberger M, Baudin E 2002 Medullary thyroid carcinoma as part of a multiple endocrine neoplasia type 2B syndrome: influence of the stage on the clinical course. *Cancer* **94**:44–50.
  65. Samaan NA, Draznin MB, Halpin RE, Bloss RS, Hawkins E, Lewis RA 1991 Multiple endocrine syndrome type IIb in early childhood. *Cancer* **68**:1832–1834.
  66. Smith VV, Eng C, Milla PJ 1999 Intestinal ganglioneuromatosis and multiple endocrine neoplasia type 2B: implications for treatment. *Gut* **45**:143–146.
  67. Unruh A, Fitze G, Janig U, Bielack S, Lochbuhler H, Coerd W 2007 Medullary thyroid carcinoma in a 2-month-old male with multiple endocrine neoplasia 2B and symptoms of pseudo-Hirschsprung disease: a case report. *J Pediatr Surg* **42**:1623–1626.
  68. Yin M, King SK, Hutson JM, Chow CW 2006 Multiple endocrine neoplasia type 2B diagnosed on suction rectal biopsy in infancy: a report of 2 cases. *Pediatr Dev Pathol* **9**:56–60.
  69. Carney JA, Go VL, Sizemore GW, Hayles AB 1976 Alimentary-tract ganglioneuromatosis. A major component of the syndrome of multiple endocrine neoplasia, type 2b. *N Engl J Med* **295**:1287–1291.
  70. Brauckhoff M, Machens A, Hess S, Lorenz K, Gimm O, Brauckhoff K, Sekulla C, Dralle H 2008 Premonitory symptoms preceding metastatic medullary thyroid cancer in MEN 2B: an exploratory analysis. *Surgery* **144**:1044–1051.
  71. Cranston AN, Carniti C, Oakhill K, Radzio-Andzelm E, Stone EA, McCallion AS, Hodgson S, Clarke S, Mondellini P, Leyland J, Pierotti MA, Whittaker J, Taylor SS, Bongarzone I, Ponder BA 2006 RET is constitutively activated by novel tandem mutations that alter the active site resulting in multiple endocrine neoplasia type 2B. *Cancer Res* **66**:10179–10187.
  72. Miyauchi A, Futami H, Hai N, Yokozawa T, Kuma K, Aoki N, Kosugi S, Sugano K, Yamaguchi K 1999 Two germline missense mutations at codons 804 and 806 of the RET proto-oncogene in the same allele in a patient with multiple endocrine neoplasia type 2B without codon 918 mutation. *Jpn J Cancer Res* **90**:1–5.
  73. Kameyama K, Okinaga H, Takami H 2004 RET oncogene mutations in 75 cases of familial medullary thyroid carcinoma in Japan. *Biomed Pharmacother* **58**:345–347.
  74. Iwashita T, Murakami H, Kurokawa K, Kawai K, Miyauchi A, Futami H, Qiao S, Ichihara M, Takahashi M 2000 A two-hit model for development of multiple endocrine neoplasia type 2B by RET mutations. *Biochem Biophys Res Commun* **268**:804–808.
  75. Eng C, Mulligan LM, Smith DP, Healey CS, Frilling A, Raue F, Neumann HP, Ponder MA, Ponder BA 1995 Low frequency of germline mutations in the RET proto-oncogene in patients with apparently sporadic medullary thyroid carcinoma. *Clin Endocrinol* **43**:123–127.
  76. Bugalho MJ, Domingues R, Santos JR, Catarino AL, Sobrinho L 2007 Mutation analysis of the RET proto-oncogene and early thyroidectomy: results of a Portuguese cancer centre. *Surgery* **141**:90–95.
  77. Wohllk N, Cote GJ, Bugalho MM, Ordonez N, Evans DB, Goepfert H, Khorana S, Schultz P, Richards CS, Gagel RF 1996 Relevance of RET proto-oncogene mutations in sporadic medullary thyroid carcinoma. *J Clin Endocrinol Metab* **81**:3740–3745.
  78. Telander RL, Zimmerman D, Sizemore GW, van Heerden JA, Grant CS 1989 Medullary carcinoma in children. Results of early detection and surgery. *Arch Surg* **124**:841–843.
  79. Wells SA Jr, Baylin SB, Gann DS, Farrell RE, Dilley WG, Preissig SH, Linehan WM, Cooper CW 1978 Medullary thyroid carcinoma: relationship of method of diagnosis to pathologic staging. *Ann Surg* **188**:377–383.
  80. Frank-Raue K, Buhr H, Dralle H, Klar E, Senninger N, Weber T, Rondot S, Hoppner W, Raue F 2006 Long-term outcome in 46 gene carriers of hereditary medullary thyroid carcinoma after prophylactic thyroidectomy: impact of individual RET genotype. *Eur J Endocrinol* **155**:229–236.
  81. Skinner MA, Moley JA, Dilley WG, Owzar K, DeBenedetti MK, Wells SA Jr 2005 Prophylactic thyroidectomy in multiple endocrine neoplasia type 2A. *New Engl J Med* **353**:1105–1113.
  82. Machens A, Ukkat J, Brauckhoff M, Gimm O, Dralle H 2005 Advances in the management of hereditary medullary thyroid cancer. *J Intern Med* **257**:50–59.
  83. Yip L, Cote GJ, Shapiro SE, Ayers GD, Herzog CE, Sellin RV, Sherman SI, Gagel RF, Lee JE, Evans DB 2003 Multiple

- endocrine neoplasia type 2: evaluation of the genotype-phenotype relationship. *Arch Surg* **138**:409–416; discussion 416.
84. Szinnai G, Meier C, Komminoth P, Zumsteg UW 2003 Review of multiple endocrine neoplasia type 2A in children: therapeutic results of early thyroidectomy and prognostic value of codon analysis. *Pediatrics* **111**:E132–139.
  85. Quayle FJ, Fialkowski EA, Benveniste R, Moley JF 2007 Pheochromocytoma penetrance varies by RET mutation in MEN 2A. *Surgery* **142**:800–805; discussion 805.e1.
  86. Frank-Raue K, Machens A, Scheuba C, Niederle B, Dralle H, Raue F 2008 Difference in development of medullary thyroid carcinoma among carriers of RET mutations in codons 790 and 791. *Clin Endocrinol* **69**:259–263.
  87. Lips CJ 1998 Clinical management of the multiple endocrine neoplasia syndromes: results of a computerized opinion poll at the Sixth International Workshop on Multiple Endocrine Neoplasia and von Hippel-Lindau disease. *J Intern Med* **243**:589–594.
  88. Marsh DJ, McDowall D, Hyland VJ, Andrew SD, Schnitzler M, Gaskin EL, Nevell DF, Diamond T, Delbridge L, Clifton-Bligh P, Robinson BG 1996 The identification of false positive responses to the pentagastrin stimulation test in RET mutation negative members of MEN 2A families. *Clin Endocrinol* **44**:213–220.
  89. Shaha AR, Cohen T, Ghossein R, Tuttle RM 2006 Late-onset medullary carcinoma of the thyroid: need for genetic testing and prophylactic thyroidectomy in adult family members. *Laryngoscope* **116**:1704–1707.
  90. Dabir T, Hunter SJ, Russell CF, McCall D, Morrison PJ 2006 The RET mutation E768D confers a late-onset familial medullary thyroid carcinoma—only phenotype with incomplete penetrance: implications for screening and management of carrier status. *Fam Cancer* **5**:201–204.
  91. Frohnauer MK, Decker RA 2000 Update on the MEN 2A c804 RET mutation: is prophylactic thyroidectomy indicated? *Surgery* **128**:1052–1057; discussion 1057–1058.
  92. Wells SA Jr, Baylin SB, Linehan WM, Farrell RE, Cox EB, Cooper CW 1978 Provocative agents and the diagnosis of medullary carcinoma of the thyroid gland. *Ann Surg* **188**:139–141.
  93. Gill JR, Reyes-Mugica M, Iyengar S, Kidd KK, Touloukian RJ, Smith C, Keller MS, Genel M 1996 Early presentation of metastatic medullary carcinoma in multiple endocrine neoplasia, type IIA: implications for therapy. *J Pediatr* **129**:459–464.
  94. Machens A, Schneyer U, Holzhausen HJ, Dralle H 2005 Prospects of remission in medullary thyroid carcinoma according to basal calcitonin level. *J Clin Endocrinol Metab* **90**:2029–2034.
  95. Sosa JA, Tuggle CT, Wang TS, Thomas DC, Boudourakis L, Rivkees S, Roman SA 2008 Clinical and economic outcomes of thyroid and parathyroid surgery in children. *J Clin Endocrinol Metab* **93**:3058–3065.
  96. van Heurn LW, Schaap C, Sie G, Haagen AA, Gerver WJ, Freling G, van Amstel HK, Heineman E 1999 Predictive DNA testing for multiple endocrine neoplasia 2: a therapeutic challenge of prophylactic thyroidectomy in very young children. *J Pediatr Surg* **34**:568–571.
  97. Mulligan LM 2004 From genes to decisions: evolving views of genotype-based management in MEN 2. *Cancer Treat Res* **122**:417–428.
  98. GeneTests: Medical Genetics Information Resource (database online). Available at <http://www.genetests.org>. Accessed August 29, 2008.
  99. Kaldrymides P, Mytakidis N, Anagnostopoulos T, Vassiliou M, Tertipi A, Zahariou M, Rampias T, Koutsodontis G, Konstantopoulou I, Ladopoulou A, Bei T, Yannoukakos D 2006 A rare RET gene exon 8 mutation is found in two Greek kindreds with familial medullary thyroid carcinoma: implications for screening. *Clin Endocrinol* **64**:561–566.
  100. Dvorakova S, Vaclavikova E, Duskova J, Vlcek P, Ryska A, Bendlova B 2005 Exon 5 of the RET proto-oncogene: a newly detected risk exon for familial medullary thyroid carcinoma, a novel germ-line mutation Gly321Arg. *J Endocrinol Invest* **28**:905–909.
  101. Menko FH, van der Luijt RB, de Valk IA, Toorians AW, Sepers JM, van Diest PJ, Lips CJ 2002 Atypical MEN type 2B associated with two germline RET mutations on the same allele not involving codon 918. *J Clin Endocrinol Metab* **87**:393–397.
  102. Tarasoff v Regents of University of Calif, 551 P2d 334 (1976).
  - 102a. Rosenthal MS, Pierce HH 2005 Inherited medullary thyroid cancer and the duty to warn: Revisiting *Pate v. Threlkel* in light of HIPAA. *Thyroid* **15**:140–145.
  103. Malloy v Meier, 629 NW2d 711 (Minn 2004).
  104. Pate v Threlkel, 661 So 2d 278 (Fla 1995).
  105. Safer v Estate of T. Pack, 677 A 2d 1188 (NJ Supp 1996).
  106. American Society of Clinical Oncology 2003 American Society of Clinical Oncology policy statement update: genetic testing for cancer susceptibility. *J Clin Oncol* **21**:2397–2406.
  107. American Medical Association. Opinion 2.131 Disclosure of familial risk in genetic testing. Code of Medical Ethics. <http://www.ama-assn.org/ama/pub/physician-resources/medical-ethics/code-medical-ethics/opinion2131.shtml> accessed May 13, 2009.
  108. Godard B, Hurlimann T, Letendre M, Egalite N 2006 Guidelines for disclosing genetic information to family members: from development to use. *Fam Cancer* **5**:103–116.
  109. Fleisher LD, Cole LJ 2001 Health Insurance Portability and Accountability Act is here: what price privacy? *Genet Med* **3**:286–289.
  110. Gostin LO 2001 National health information privacy: regulations under the Health Insurance Portability and Accountability Act. *JAMA* **285**:3015–3021.
  111. 1996 Health Insurance Portability and Accountability Act. Vol Public Law No 104–191.
  112. Huang SM, Tao BL, Tzeng CC, Liu HT, Wang WP 1997 Prenatal molecular diagnosis of RET proto-oncogene mutation in multiple endocrine neoplasia type 2A. *J Formos Med Assoc* **96**:542–544.
  113. Martinelli P, Maruotti GM, Pasquali D, Paladini D, Agangi A, Ripa E, Colantuoni V, Bellastella A, Sinisi AA 2004 Genetic prenatal RET testing and pregnancy management of multiple endocrine neoplasia Type II A (MEN2A): a case report. *J Endocrinol Invest* **27**:357–360.
  114. Offit K, Kohut K, Clagett B, Wadsworth EA, Lafaro KJ, Cummings S, White M, Sagi M, Bernstein D, Davis JG 2006 Cancer genetic testing and assisted reproduction. *J Clin Oncol* **24**:4775–4782.
  115. Offit K, Sagi M, Hurley K 2006 Preimplantation genetic diagnosis for cancer syndromes: a new challenge for preventive medicine. *JAMA* **296**:2727–2730.
  116. Miyauchi A, Matsuzuka F, Hirai K, Yokozawa T, Kobayashi K, Ito Y, Nakano K, Kuma K, Futami H, Yamaguchi K 2002 Prospective trial of unilateral surgery for nonhereditary medullary thyroid carcinoma in patients without germline RET mutations. *World J Surg* **26**:1023–1028.
  117. Moley JF, DeBenedetti MK 1999 Patterns of nodal metastases in palpable medullary thyroid carcinoma: recom-

- mendations for extent of node dissection. *Ann Surg* **229**:880–887; discussion 887–888.
118. Kebebew E, Ituarte PH, Siperstein AE, Duh QY, Clark OH 2000 Medullary thyroid carcinoma: clinical characteristics, treatment, prognostic factors, and a comparison of staging systems. *Cancer* **88**:1139–1148.
  119. Weber T, Schilling T, Frank-Raue K, Colombo-Benkmann M, Hinz U, Ziegler R, Klar E 2001 Impact of modified radical neck dissection on biochemical cure in medullary thyroid carcinomas. *Surgery* **130**:1044–1049.
  120. Scopsi L, Sampietro G, Boracchi P, Del Bo R, Gullo M, Placucci M, Pilotti S 1996 Multivariate analysis of prognostic factors in sporadic medullary carcinoma of the thyroid. A retrospective study of 109 consecutive patients. *Cancer* **78**:2173–2183.
  121. Beressi N, Campos JM, Beressi JP, Franc B, Niccoli-Sire P, Conte-Devolx B, Murat A, Caron P, Baldet L, Kraimps JL, Cohen R, Bigorgne JC, Chabre O, Lecomte P, Modigliani E 1998 Sporadic medullary microcarcinoma of the thyroid: a retrospective analysis of eighty cases. *Thyroid* **8**:1039–1044.
  122. Decker RA, Peacock ML, Borst MJ, Sweet JD, Thompson NW 1995 Progress in genetic screening of multiple endocrine neoplasia type 2A: is calcitonin testing obsolete? *Surgery* **118**:257–263; discussion 263–254.
  123. Kitamura Y, Goodfellow PJ, Shimizu K, Nagahama M, Ito K, Kitagawa W, Akasu H, Takami H, Tanaka S, Wells SA Jr 1997 Novel germline RET proto-oncogene mutations associated with medullary thyroid carcinoma (MTC): mutation analysis in Japanese patients with MTC. *Oncogene* **14**:3103–3106.
  124. Wiench M, Wygoda Z, Gubala E, Wloch J, Lisowska K, Krassowski J, Scieglinska D, Fiszler-Kierzkowska A, Lange D, Kula D, Zeman M, Roskosz J, Kukulska A, Krawczyk Z, Jarzab B 2001 Estimation of risk of inherited medullary thyroid carcinoma in apparent sporadic patients. *J Clin Oncol* **19**:1374–1380.
  125. Jones BA, Sisson JC 1983 Early diagnosis and thyroidectomy in multiple endocrine neoplasia, type 2b. *J Pediatr* **102**:219–223.
  126. Erdogan MF, Gursoy A, Gullu S, Aydintug S, Kucuk B, Baskal N, Kamel N, Hoppner W, Erdogan G 2007 Clinical and genetic experience in Turkish multiple endocrine neoplasia type 2 families. *Endocrinologist* **17**:273–277.
  127. Barontini M, Levin G, Sanso G 2006 Characteristics of pheochromocytoma in a 4- to 20-year-old population. *Ann N Y Acad Sci* **1073**:30–37.
  128. De Krijger RR, Petri BJ, Van Nederveen FH, Korpershoek E, De Herder WW, De Muinck Keizer-Schrama SM, Dinjens WN 2006 Frequent genetic changes in childhood pheochromocytomas. *Ann N Y Acad Sci* **1073**:166–176.
  129. Mora J, Cascon A, Robledo M, Catala A 2006 Pediatric paraganglioma: an early manifestation of an adult disease secondary to germline mutations. *Pediatr Blood Cancer* **47**:785–789.
  130. Pacak K, Eisenhofer G, Ahlman H, Bornstein SR, Gimenez-Roqueplo AP, Grossman AB, Kimura N, Mannelli M, McNicol AM, Tischler AS 2007 Pheochromocytoma: recommendations for clinical practice from the First International Symposium. October 2005. *Nat Clin Pract Endocrinol Metab* **3**:92–102.
  131. Jackson MB, Guttenberg M, Hedrick H, Moshang T Jr 2005 Multiple endocrine neoplasia type 2A in a kindred with C634Y mutation. *Pediatrics* **116**:e468–471.
  132. Decker RA, Geiger JD, Cox CE, Mackovjak M, Sarkar M, Peacock ML 1996 Prophylactic surgery for multiple endocrine neoplasia type IIa after genetic diagnosis: is parathyroid transplantation indicated? *World J Surg* **20**:814–820; discussion 820–811.
  133. Kraimps JL, Denizot A, Carnaille B, Henry JF, Proye C, Bacourt F, Sarfati E, Dupond JL, Maes B, Travagli JP, Boneu A, Roger P, Houdent C, Barbier J, Modigliani E 1996 Primary hyperparathyroidism in multiple endocrine neoplasia type IIa: retrospective French multicentric study. Groupe d'Etude des Tumeurs à Calcitonine (GETC, French Calcitonin Tumors Study Group), French Association of Endocrine Surgeons. *World J Surg* **20**:808–812; discussion 812–803.
  134. Raue F, Kraimps JL, Dralle H, Cougard P, Proye C, Frilling A, Limbert E, Llenas LF, Niederle B 1995 Primary hyperparathyroidism in multiple endocrine neoplasia type 2A. *J Intern Med* **238**:369–373.
  135. Bevilacqua M, Dominguez LJ, Righini V, Valdes V, Vago T, Leopaldi E, Baldi G, Barrella M, Barbagallo M 2006 Dissimilar PTH, gastrin, and calcitonin responses to oral calcium and peptones in hypocalciuric hypercalcemia, primary hyperparathyroidism, and normal subjects: a useful tool for differential diagnosis. *J Bone Miner Res* **21**:406–412.
  136. Krebs NF, Reidinger CJ, Robertson AD, Brenner M 1997 Bone mineral density changes during lactation: maternal, dietary, and biochemical correlates. *Am J Clin Nutr* **65**:1738–1746.
  137. Ritchie LD, Fung EB, Halloran BP, Turnlund JR, Van Loan MD, Cann CE, King JC 1998 A longitudinal study of calcium homeostasis during human pregnancy and lactation and after resumption of menses. *Am J Clin Nutr* **67**:693–701.
  138. Prentice A, Jarjou LM, Stirling DM, Buffenstein R, Fairweather-Tait S 1998 Biochemical markers of calcium and bone metabolism during 18 months of lactation in Gambian women accustomed to a low calcium intake and in those consuming a calcium supplement. *J Clin Endocrinol Metab* **83**:1059–1066.
  139. Becker KL, Nysten ES, White JC, Muller B, Snider RH Jr 2004 Clinical review 167: procalcitonin and the calcitonin gene family of peptides in inflammation, infection, and sepsis: a journey from calcitonin back to its precursors. *J Clin Endocrinol Metab* **89**:1512–1525.
  140. Whang KT, Steinwald PM, White JC, Nysten ES, Snider RH, Simon GL, Goldberg RL, Becker KL 1998 Serum calcitonin precursors in sepsis and systemic inflammation. *J Clin Endocrinol Metab* **83**:3296–3301.
  141. Dandona P, Nix D, Wilson MF, Aljada A, Love J, Assicot M, Bohuon C 1994 Procalcitonin increase after endotoxin injection in normal subjects. *J Clin Endocrinol Metab* **79**:1605–1608.
  142. d'Herbomez M, Caron P, Bauters C, Cao CD, Schlienger JL, Sapin R, Baldet L, Carnaille B, Wemeau JL 2007 Reference range of serum calcitonin levels in humans: influence of calcitonin assays, sex, age, and cigarette smoking. *Eur J Endocrinol* **157**:749–755.
  143. Verga U, Morpurgo PS, Vaghi I, Radetti G, Beck-Peccoz P 2006 Normal range of calcitonin in children measured by a chemiluminescent two-site immunometric assay. *Horm Res* **66**:17–20.
  144. Basuyau JP, Mallet E, Leroy M, Brunelle P 2004 Reference intervals for serum calcitonin in men, women, and children. *Clin Chem* **50**:1828–1830.

145. Niccoli P, Conte-Devolx B, Lejeune PJ, Carayon P, Henry JF, Roux F, Wion-Barbot N, Bigorgne JC 1996 [Hypercalcitoninemia in conditions other than medullary cancers of the thyroid]. *Ann Endocrinol (Paris)* **57**:15–21. (In French.)
146. Karanikas G, Moameni A, Poetzi C, Zettinig G, Kaserer K, Bieglmayer C, Niederle B, Dudczak R, Pirich C 2004 Frequency and relevance of elevated calcitonin levels in patients with neoplastic and nonneoplastic thyroid disease and in healthy subjects. *J Clin Endocrinol Metab* **89**:515–519.
147. Schuetz M, Duan H, Wahl K, Pirich C, Antoni A, Kommata S, Kletter K, Dudczak R, Karanikas G, Willheim M 2006 T lymphocyte cytokine production patterns in Hashimoto patients with elevated calcitonin levels and their relationship to tumor initiation. *Anticancer Res* **26**:4591–4596.
148. Borchhardt KA, Heinzl H, Gessl A, Horl WH, Kaserer K, Sunder-Plassmann G 2006 Calcitonin concentrations in patients with chronic kidney disease and medullary thyroid carcinoma or c-cell hyperplasia. *Kidney Int* **70**:2014–2020.
149. Borchhardt KA, Horl WH, Sunder-Plassmann G 2005 Reversibility of 'secondary hypercalcitoninemia' after kidney transplantation. *Am J Transplant* **5**:1757–1763.
150. Butterfield JH, Tefferi A, Kozuh GF 2005 Successful treatment of systemic mastocytosis with high-dose interferon- $\alpha$ : long-term follow-up of a case. *Leuk Res* **29**:131–134.
151. Butterfield JH, Li CY 2004 Bone marrow biopsies for the diagnosis of systemic mastocytosis: is one biopsy sufficient? *Am J Clin Pathol* **121**:264–267.
152. Yocum MW, Butterfield JH, Gharib H 1994 Increased plasma calcitonin levels in systemic mast cell disease. *Mayo Clin Proc* **69**:987–990.
153. Lundin A, Oberg K 1984 Hypercalcitoninaemia in a patient with urticaria pigmentosa. A possible cause of diarrhoea. *Acta Med Scand* **215**:281–285.
154. Vitale G, Ciccarelli A, Caraglia M, Galderisi M, Rossi R, Del Prete S, Abbruzzese A, Lupoli G 2002 Comparison of two provocative tests for calcitonin in medullary thyroid carcinoma: omeprazole vs pentagastrin. *Clin Chem* **48**:1505–1510.
155. Leboeuf R, Langlois MF, Martin M, Ahnadi CE, Fink GD 2006 "Hook effect" in calcitonin immunoradiometric assay in patients with metastatic medullary thyroid carcinoma: case report and review of the literature. *J Clin Endocrinol Metab* **91**:361–364.
156. Preissner CM, Dodge LA, O'Kane DJ, Singh RJ, Grebe SK 2005 Prevalence of heterophilic antibody interference in eight automated tumor marker immunoassays. *Clin Chem* **51**:208–210.
157. Tommasi M, Brocchi A, Cappellini A, Raspanti S, Mannelli M 2001 False serum calcitonin high levels using a non-competitive two-site IRMA. *J Endocrinol Invest* **24**:356–360.
158. Papapetrou PD, Polymeris A, Karga H, Vaiopoulos G 2006 Heterophilic antibodies causing falsely high serum calcitonin values. *J Endocrinol Invest* **29**:919–923.
159. Machens A, Haedecke J, Holzhausen HJ, Thomusch O, Schneyer U, Dralle H 2000 Differential diagnosis of calcitonin-secreting neuroendocrine carcinoma of the foregut by pentagastrin stimulation. *Langenbecks Arch Surg* **385**:398–401.
160. Kaye TB 1995 PTHrP-mediated hypercalcemia in a calcitonin-producing islet cell tumor. *Endocr Pract* **1**:170–171.
161. Machens A, Haedecke J, Hinze R, Thomusch O, Schneyer U, Dralle H 2000 Hypercalcitoninemia in a sporadic asymptomatic neuroendocrine tumor of the pancreatic tail. *Dig Surg* **17**:522–524.
162. Pusztai P, Sarman B, Illyes G, Szekely E, Peter I, Boer K, Tihanyi T, Racz K 2006 Hypercalcitoninemia in a patient with a recurrent goitre and insulinoma: a case report. *Exp Clin Endocrinol Diabetes* **114**:217–221.
163. Wermers RA, Fatourech V, Wynne AG, Kvols LK, Lloyd RV 1996 The glucagonoma syndrome. Clinical and pathologic features in 21 patients. *Medicine* **75**:53–63.
164. Jackson C, Buchman AL 2005 Calcitonin-secreting VIPoma. *Dig Dis Sci* **50**:2203–2206.
165. Eskens FA, Roelofs EJ, Hermus AR, Verhagen CA 1997 Pancreatic islet cell tumor producing vasoactive intestinal polypeptide and calcitonin. *Anticancer Res* **17**:4667–4670.
166. Calhoun K, Toth-Fejel S, Cheek J, Pommier R 2003 Serum peptide profiles in patients with carcinoid tumors. *Am J Surg* **186**:28–31.
167. Sim SJ, Glassman AB, Ro JY, Lee JJ, Logothetis CJ, Liu FJ 1996 Serum calcitonin in small cell carcinoma of the prostate. *Ann Clin Lab Sci* **26**:487–495.
168. Pratz KW, Ma C, Aubry MC, Vrtiska TJ, Erlichman C 2005 Large cell carcinoma with calcitonin and vasoactive intestinal polypeptide-associated Verner-Morrison syndrome. *Mayo Clin Proc* **80**:116–120.
169. Suzuki H 1998 Calcitonin levels in normal individuals with new highly sensitive chemiluminescent enzyme immunoassay. *J Clin Lab Anal* **12**:218–222.
170. Guyétant S, Rousselet MC, Durigon M, Chappard D, Franc B, Guerin O, Saint-Andre JP 1997 Sex-related C cell hyperplasia in the normal human thyroid: a quantitative autopsy study. *J Clin Endocrinol Metab* **82**:42–47.
171. Pedrazzoni M, Ciotti G, Davoli L, Pioli G, Girasole G, Palummeri E, Passeri M 1989 Meal-stimulated gastrin release and calcitonin secretion. *J Endocrinol Invest* **12**:409–412.
172. Brandsborg M, Nielsen HE, Brandsborg O, Olsen KJ, Lovgreen NA 1980 The role of serum gastrin in the secretion of calcitonin: studies in patients with pernicious anaemia and in healthy subjects. *Scand J Gastroenterol* **15**:23–28.
173. Howe JC 1990 Postprandial response of calcium metabolism in postmenopausal women to meals varying in protein level/source. *Metab Clin Exp* **39**:1246–1252.
174. Filipponi P, Gregorio F, Cristallini S, Mannarelli C, Blass A, Scarponi AM, Vespasiani G 1990 Partial gastrectomy and mineral metabolism: effects on gastrin-calcitonin release. *Bone Miner* **11**:199–208.
175. Talmage RV, Grubb SA, Norimatsu H, Vanderwiel CJ 1980 Evidence for an important physiological role for calcitonin. *Proc Natl Acad Sci U S A* **77**:609–613.
176. Lee NC, Norton JA 2000 Multiple endocrine neoplasia type 2B—genetic basis and clinical expression. *Surg Oncol* **9**:111–118.
177. Niccoli-Sire P, Murat A, Rohmer V, Gibelin H, Chabrier G, Conte-Devolx B, Visset J, Ronceray J, Jaeck D, Henry JF, Proye C, Carnaille B, Kraimps JL 2003 When should thyroidectomy be performed in familial medullary thyroid carcinoma gene carriers with non-cysteine RET mutations? *Surgery* **134**:1029–1036; discussion 1036–1027.
178. Scheuba C, Kaserer K, Bieglmayer C, Asari R, Riss P, Drossten R, Niederle B 2007 Medullary thyroid microcarcinoma recommendations for treatment - a single-center experience. *Surgery* **142**:1003–1010; discussion 1010 e1001–1003.
179. Yoshimoto K, Iwahana H, Itakura M 1993 Relatively good prognosis of multiple endocrine neoplasia type 2B in Japanese: review of cases in Japan and analysis of genetic changes in tumors. *Endocr J* **40**:649–657.



180. Wray CJ, Rich TA, Waguespack SG, Lee JE, Perrier ND, Evans DB 2008 Failure to recognize multiple endocrine neoplasia 2B: more common than we think? *Ann Surg Oncol* **15**:293–301.
181. Olson JA Jr, DeBenedetti MK, Baumann DS, Wells SA Jr 1996 Parathyroid autotransplantation during thyroidectomy. Results of long-term follow-up. *Ann Surg* **223**:472–478; discussion 478–480.
182. O'Riordain DS, O'Brien T, Grant CS, Weaver A, Gharib H, van Heerden JA 1993 Surgical management of primary hyperparathyroidism in multiple endocrine neoplasia types 1 and 2. *Surgery* **114**:1031–1037; discussion 1037–1039.
183. van Heerden JA, Kent RB, 3rd, Sizemore GW, Grant CS, ReMine WH 1983 Primary hyperparathyroidism in patients with multiple endocrine neoplasia syndromes. Surgical experience. *Arch Surg* **118**:533–536.
184. Herfarth KK, Bartsch D, Doherty GM, Wells SA Jr, Lairmore TC 1996 Surgical management of hyperparathyroidism in patients with multiple endocrine neoplasia type 2A. *Surgery* **120**:966–973; discussion 973–964.
185. Peacock M, Bilezikian JP, Klassen PS, Guo MD, Turner SA, Shoback D 2005 Cinacalcet hydrochloride maintains long-term normocalcemia in patients with primary hyperparathyroidism. *J Clin Endocrinol Metab* **90**:135–141.
186. Chang TC, Wu SL, Hsiao YL 2005 Medullary thyroid carcinoma: pitfalls in diagnosis by fine needle aspiration cytology and relationship of cytomorphology to RET proto-oncogene mutations. *Acta Cytolog* **49**:477–482.
187. Papaparaskeva K, Nagel H, Droese M 2000 Cytologic diagnosis of medullary carcinoma of the thyroid gland. *Diagn Cytopathol* **22**:351–358.
188. Bugalho MJ, Santos JR, Sobrinho L 2005 Preoperative diagnosis of medullary thyroid carcinoma: fine needle aspiration cytology as compared with serum calcitonin measurement. *J Surg Oncol* **91**:56–60.
189. Elisei R, Bottici V, Luchetti F, Di Coscio G, Romei C, Grasso L, Miccoli P, Iacconi P, Basolo F, Pinchera A, Pacini F 2004 Impact of routine measurement of serum calcitonin on the diagnosis and outcome of medullary thyroid cancer: experience in 10,864 patients with nodular thyroid disorders. *J Clin Endocrinol Metab* **89**:163–168.
190. Costante G, Meringolo D, Durante C, Bianchi D, Nocera M, Tumino S, Crocetti U, Attard M, Maranghi M, Torlontano M, Filetti S 2007 Predictive value of serum calcitonin levels for preoperative diagnosis of medullary thyroid carcinoma in a cohort of 5817 consecutive patients with thyroid nodules. *J Clin Endocrinol Metab* **92**:450–455.
191. Papi G, Corsello SM, Cioni K, Pizzini AM, Corrado S, Carapezzi C, Fadda G, Baldini A, Carani C, Pontecorvi A, Roti E 2006 Value of routine measurement of serum calcitonin concentrations in patients with nodular thyroid disease: a multicenter study. *J Endocrinol Invest* **29**:427–437.
192. Henry JF, Denizot A, Puccini M, Gramatica L, Kvachenyuk A, Conte Devolx B, De Micco C 1998 Latent subclinical medullary thyroid carcinoma: diagnosis and treatment. *World J Surg* **22**:752–756; discussion 756–757.
193. Hahn JR, Lee MS, Min YK, Lee MK, Kim KW, Nam SJ, Yang JH, Chung JH 2001 Routine measurement of serum calcitonin is useful for early detection of medullary thyroid carcinoma in patients with nodular thyroid diseases. *Thyroid* **11**:73–80.
194. Niccoli P, Wion-Barbot N, Caron P, Henry JF, de Micco C, Saint Andre JP, Bigorgne JC, Modigliani E, Conte-Devolx B 1997 Interest of routine measurement of serum calcitonin: study in a large series of thyroidectomized patients. The French Medullary Study Group. *J Clin Endocrinol Metab* **82**:338–341.
195. Pacini F, Fontanelli M, Fugazzola L, Elisei R, Romei C, Di Coscio G, Miccoli P, Pinchera A 1994 Routine measurement of serum calcitonin in nodular thyroid diseases allows the preoperative diagnosis of unsuspected sporadic medullary thyroid carcinoma. *J Clin Endocrinol Metab* **78**:826–829.
196. Rieu M, Lame MC, Richard A, Lissak B, Sambort B, Vuong-Ngoc P, Berrod JL, Fombour JP 1995 Prevalence of sporadic medullary thyroid carcinoma: the importance of routine measurement of serum calcitonin in the diagnostic evaluation of thyroid nodules. *Clin Endocrinol* **42**:453–460.
197. Vantyghem MC, Pigny P, Leteurtre E, Leclerc L, Bauters C, Douillard C, D'Herbomez M, Carnaille B, Proye C, We-meau JL, Lecomte-Houcke M 2004 Thyroid carcinomas involving follicular and parafollicular C cells: seventeen cases with characterization of RET oncogenic activation. *Thyroid* **14**:842–847.
198. Vierhapper H, Niederle B, Bieglmayer C, Kaserer K, Baumgartner-Parzer S 2005 Early diagnosis and curative therapy of medullary thyroid carcinoma by routine measurement of serum calcitonin in patients with thyroid disorders. *Thyroid* **15**:1267–1272.
199. Vierhapper H, Raber W, Bieglmayer C, Kaserer K, Weinhausl A, Niederle B 1997 Routine measurement of plasma calcitonin in nodular thyroid diseases. *J Clin Endocrinol Metab* **82**:1589–1593.
200. Borget I, De Pourville G, Schlumberger M 2007 Editorial. Calcitonin determination in patients with nodular thyroid disease. *J Clin Endocrinol Metab* **92**:425–427.
201. Cheung K, Roman SA, Wang TS, Walker HD, Sosa JA 2008 Calcitonin measurement in the evaluation of thyroid nodules in the United States: a cost-effectiveness and decision analysis. *J Clin Endocrinol Metab* **93**:2173–2180.
202. Kudo T, Miyauchi A, Ito Y, Takamura Y, Amino N, Hirokawa M 2007 Diagnosis of medullary thyroid carcinoma by calcitonin measurement in fine-needle aspiration biopsy specimens. *Thyroid* **17**:635–638.
203. Boi F, Maurelli I, Pinna G, Atzeni F, Piga M, Lai ML, Mariotti S 2007 Calcitonin measurement in wash-out fluid from fine needle aspiration of neck masses in patients with primary and metastatic medullary thyroid carcinoma. *J Clin Endocrinol Metab* **92**:2115–2118.
204. Redding AH, Levine SN, Fowler MR 2000 Normal preoperative calcitonin levels do not always exclude medullary thyroid carcinoma in patients with large palpable thyroid masses. *Thyroid* **10**:919–922.
205. Asari R, Scheuba C, Kaczirek K, Niederle B 2006 Estimated risk of pheochromocytoma recurrence after adrenal-sparing surgery in patients with multiple endocrine neoplasia type 2A. *Arch Surg* **141**:1199–1205; discussion 1205.
206. Giraudet AL, Vanel D, Lebouilleux S, Aupepin A, Dromain C, Chami L, Ny Tovo N, Lumbroso J, Lassau N, Bonniaud G, Hartl D, Travagli JP, Baudin E, Schlumberger M 2007 Imaging medullary thyroid carcinoma with persistent elevated calcitonin levels. *J Clin Endocrinol Metab* **92**:4185–4190.
207. Mirallie E, Vuillez JP, Bardet S, Frampas E, Dupas B, Ferrer L, Faivre-Chauvet A, Murat A, Charbonnel B, Barbet J, Goldenberg DM, Chatal JF, Kraeber-Bodere F 2005 High

- frequency of bone/bone marrow involvement in advanced medullary thyroid cancer. *J Clin Endocrinol Metab* **90**:779–788.
208. Santarpia L, El-Naggar AK, Sherman SI, Hymes SR, Gagel RF, Shaw S, Sarlis NJ 2008 Four patients with cutaneous metastases from medullary thyroid cancer. *Thyroid* **18**:901–905.
  209. Leclère J, Sidibé S, Lassau N, Gardet P, Caillou B, Schlumberger M, Romaniuk C, Parmentier C 1996 [Ultrasonographic aspects of hepatic metastases of thyroid medullary cancers]. *Journal de radiologie* **77**:99–103. (In French.)
  210. Yen TW, Shapiro SE, Gagel RF, Sherman SI, Lee JE, Evans DB 2003 Medullary thyroid carcinoma: results of a standardized surgical approach in a contemporary series of 80 consecutive patients. *Surgery* **134**:890–899; discussion 899–901.
  211. Oudoux A, Salaun PY, Bournaud C, Campion L, Ansquer C, Rousseau C, Bardet S, Borson-Chazot F, Vuillez JP, Murat A, Mirallie E, Barbet J, Goldenberg DM, Chatal JF, Kraeber-Bodere F 2007 Sensitivity and prognostic value of positron emission tomography with f-18-fluorodeoxyglucose and sensitivity of immunoscintigraphy in patients with medullary thyroid carcinoma treated with anticarcinoembryonic antigen-targeted radioimmunotherapy. *J Clin Endocrinol Metab* **92**:4590–4597.
  212. Giraudet AL, Al Ghulzan A, Auperin A, Leboulleux S, Chehboun A, Troalen F, Dromain C, Lumbroso J, Baudin E, Schlumberger M 2008 Progression of medullary thyroid carcinoma: assessment with calcitonin and carcinoembryonic antigen doubling times. *Eur J Endocrinol* **158**:239–246.
  213. Franc S, Niccoli-Sire P, Cohen R, Bardet S, Maes B, Murat A, Krivitzky A, Modigliani E 2001 Complete surgical lymph node resection does not prevent authentic recurrences of medullary thyroid carcinoma. *Clin Endocrinol* **55**:403–409.
  214. Rendl G, Manzl M, Hitzl W, Sungler P, Pirich C 2008 Long-term prognosis of medullary thyroid carcinoma. *Clin Endocrinol* **69**:497–505.
  215. Leggett MD, Chen SL, Schneider PD, Martinez SR 2008 Prognostic value of lymph node yield and metastatic lymph node ratio in medullary thyroid carcinoma. *Ann Surg Oncol* **15**:2493–2499.
  216. Scollo C, Baudin E, Travagli JP, Caillou B, Bellon N, Leboulleux S, Schlumberger M 2003 Rationale for central and bilateral lymph node dissection in sporadic and hereditary medullary thyroid cancer. *J Clin Endocrinol Metab* **88**:2070–2075.
  217. Machens A, Gimm O, Ukkat J, Hinze R, Schneyer U, Dralle H 2000 Improved prediction of calcitonin normalization in medullary thyroid carcinoma patients by quantitative lymph node analysis. *Cancer* **88**:1909–1915.
  218. Machens A, Hauptmann S, Dralle H 2008 Prediction of lateral lymph node metastases in medullary thyroid cancer. *Br J Surg* **95**:586–591.
  219. Dralle H, Damm I, Scheumann GF, Kotzerke J, Kupsch E, Geerlings H, Pichlmayr R 1994 Compartment-oriented microdissection of regional lymph nodes in medullary thyroid carcinoma. *Surg Today* **24**:112–121.
  220. Fialkowski EA, Moley JF 2006 Current approaches to medullary thyroid carcinoma, sporadic and familial. *J Surg Oncol* **94**:737–747.
  221. Frilling A, Weber F, Tecklenborg C, Broelsch CE 2003 Prophylactic thyroidectomy in multiple endocrine neoplasia: the impact of molecular mechanisms of RET proto-oncogene. *Langenbecks Arch Surg* **388**:17–26.
  222. Dralle H, Gimm O, Simon D, Frank-Raue K, Gortz G, Niederle B, Wahl RA, Koch B, Walgenbach S, Hampel R, Ritter MM, Spelsberg F, Heiss A, Hinze R, Hoppner W 1998 Prophylactic thyroidectomy in 75 children and adolescents with hereditary medullary thyroid carcinoma: German and Austrian experience. *World J Surg* **22**:744–750; discussion 750–741.
  223. Machens A, Hinze R, Thomusch O, Dralle H 2002 Pattern of nodal metastasis for primary and reoperative thyroid cancer. *World J Surg* **26**:22–28.
  224. Quayle FJ, Benveniste R, DeBenedetti MK, Wells SA, Moley JF 2004 Hereditary medullary thyroid carcinoma in patients greater than 50 years old. *Surgery* **136**:1116–1121.
  225. Eng C 1999 RET proto-oncogene in the development of human cancer. *J Clin Oncol* **17**:380–393.
  226. Marsh DJ, Learoyd DL, Andrew SD, Krishnan L, Pojer R, Richardson AL, Delbridge L, Eng C, Robinson BG 1996 Somatic mutations in the RET proto-oncogene in sporadic medullary thyroid carcinoma. *Clin Endocrinol* **44**:249–257.
  227. Zedenius J, Larsson C, Bergholm U, Bovee J, Svensson A, Hallengren B, Grimelius L, Backdahl M, Weber G, Wallin G 1995 Mutations of codon 918 in the RET proto-oncogene correlate to poor prognosis in sporadic medullary thyroid carcinomas. *J Clin Endocrinol Metab* **80**:3088–3090.
  228. Barbet J, Campion L, Kraeber-Bodere F, Chatal JF 2005 Prognostic impact of serum calcitonin and carcinoembryonic antigen doubling-times in patients with medullary thyroid carcinoma. *J Clin Endocrinol Metab* **90**:6077–6084.
  229. Stephanas AV, Samaan NA, Hill CS Jr, Hickey RC 1979 Medullary thyroid carcinoma: importance of serial serum calcitonin measurement. *Cancer* **43**:825–837.
  230. Fugazzola L, Pinchera A, Luchetti F, Iacconi P, Miccoli P, Romei C, Puccini M, Pacini F 1994 Disappearance rate of serum calcitonin after total thyroidectomy for medullary thyroid carcinoma. *Int J Biol Markers* **9**:21–24.
  231. Engelbach M, Gorges R, Forst T, Pfutzner A, Dawood R, Heerdt S, Kunt T, Bockisch A, Beyer J 2000 Improved diagnostic methods in the follow-up of medullary thyroid carcinoma by highly specific calcitonin measurements. *J Clin Endocrinol Metab* **85**:1890–1894.
  232. Tisell LE, Dilley WG, Wells SA Jr 1996 Progression of postoperative residual medullary thyroid carcinoma as monitored by plasma calcitonin levels. *Surgery* **119**:34–39.
  233. Koopmans KP, de Groot JW, Plukker JT, de Vries EG, Kema IP, Sluiter WJ, Jager PL, Links TP 2008 18F-Dihydroxyphenylalanine PET in Patients with Biochemical Evidence of Medullary Thyroid Cancer: Relation to Tumor Differentiation. *J Nucl Med* **49**:524–531.
  234. Diez JJ, Iglesias P 2004 Lack of elevated serum carcinoembryonic antigen and calcitonin in medullary thyroid carcinoma. *Thyroid* **14**:984–985.
  235. Kouvaraki MA, Shapiro SE, Fornage BD, Edeiken-Monro BS, Sherman SI, Vassilopoulou-Sellin R, Lee JE, Evans DB 2003 Role of preoperative ultrasonography in the surgical management of patients with thyroid cancer. *Surgery* **134**:946–954; discussion 954–945.
  236. Szakall S Jr, Esik O, Bajzik G, Repa I, Dabasi G, Sinkovics I, Agoston P, Tron L 2002 18F-FDG PET detection of lymph node metastases in medullary thyroid carcinoma. *J Nucl Med* **43**:66–71.

237. Diehl M, Risse JH, Brandt-Mainz K, Dietlein M, Bohuslavizki KH, Matheja P, Lange H, Bredow J, Korber C, Grunwald F 2001 Fluorine-18 fluorodeoxyglucose positron emission tomography in medullary thyroid cancer: results of a multicentre study. *Eur J Nucl Med* **28**:1671–1676.
238. Gourgiotis L, Sarlis NJ, Reynolds JC, VanWaes C, Merino MJ, Pacak K 2003 Localization of medullary thyroid carcinoma metastasis in a multiple endocrine neoplasia type 2A patient by 6-[18F]-fluorodopamine positron emission tomography. *J Clin Endocrinol Metab* **88**:637–641.
239. Hoegerle S, Althoefer C, Ghanem N, Brink I, Moser E, Nitzsche E 2001 18F-DOPA positron emission tomography for tumour detection in patients with medullary thyroid carcinoma and elevated calcitonin levels. *Eur J Nucl Med* **28**:64–71.
240. Rubello D, Rampin L, Nanni C, Banti E, Ferdeghini M, Fanti S, Al-Nahhas A, Gross MD 2008 The role of 18F-FDG PET/CT in detecting metastatic deposits of recurrent medullary thyroid carcinoma: a prospective study. *Eur J Surg Oncol* **34**:581–586.
241. Ong SC, Schoder H, Patel SG, Tabangay-Lim IM, Doddaman I, Gonen M, Shaha AR, Tuttle RM, Shah JP, Larson SM 2007 Diagnostic accuracy of 18F-FDG PET in restaging patients with medullary thyroid carcinoma and elevated calcitonin levels. *J Nucl Med* **48**:501–507.
242. Sharkey RM, Hajjar G, Yeldell D, Brenner A, Burton J, Rubin A, Goldenberg DM 2005 A phase I trial combining high-dose 90Y-labeled humanized anti-CEA monoclonal antibody with doxorubicin and peripheral blood stem cell rescue in advanced medullary thyroid cancer. *J Nucl Med* **46**:620–633.
243. Czepczyński R, Kosowicz J, Ziemnicka K, Mikołajczak R, Gryczyńska M, Sowiński J 2006 [The role of scintigraphy with the use of <sup>99m</sup>Tc-HYNIC-TOC in the diagnosis of medullary thyroid carcinoma]. *Endokrynol Pol* **57**:431–435. (In Polish.)
244. Baudin E, Lumbroso J, Schlumberger M, Leclere J, Giammarile F, Gardet P, Roche A, Travagli JP, Parmentier C 1996 Comparison of octreotide scintigraphy and conventional imaging in medullary thyroid carcinoma. *J Nucl Med* **37**:912–916.
245. Kwekkeboom DJ, Reubi JC, Lamberts SW, Bruining HA, Mulder AH, Oei HY, Krenning EP 1993 In vivo somatostatin receptor imaging in medullary thyroid carcinoma. *J Clin Endocrinol Metab* **76**:1413–1417.
246. Frank-Raue K, Bihl H, Dorr U, Buhr H, Ziegler R, Raue F 1995 Somatostatin receptor imaging in persistent medullary thyroid carcinoma. *Clin Endocrinol* **42**:31–37.
247. Eising EG, Farahati J, Bier D, Knust EJ, Reiners C 1995 [Somatostatin receptor scintigraphy in medullary thyroid carcinomas, GEP and carcinoid tumors]. *Nuklearmedizin* **34**:1–7. (In German.)
248. Finny P, Jacob JJ, Thomas N, Philip J, Rajarathnam S, Oommen R, Nair A, Seshadri MS 2007 Medullary thyroid carcinoma: a 20-year experience from a centre in South India. *ANZ J Surg* **77**:130–134.
249. Behr TM, Gratz S, Markus PM, Dunn RM, Hufner M, Schauer A, Fischer M, Munz DL, Becker H, Becker W 1997 Anti-carcinoembryonic antigen antibodies versus somatostatin analogs in the detection of metastatic medullary thyroid carcinoma: are carcinoembryonic antigen and somatostatin receptor expression prognostic factors? *Cancer* **80**:2436–2457.
250. Gao ZR, An R, Zhang YX, Biersack HJ 2006 [Targeted radionuclide therapy for patients with metastatic medullary thyroid carcinoma]. *Zhonghua Zhong Liu Za Zhi* [Chinese journal of oncology] **28**:621–624. (In Chinese.)
251. Iten F, Muller B, Schindler C, Rochlitz C, Oertli D, Macke HR, Muller-Brand J, Walter MA 2007 Response to [90Yttrium-DOTA]-TOC treatment is associated with long-term survival benefit in metastasized medullary thyroid cancer: a phase II clinical trial. *Clin Cancer Res* **13**:6696–6702.
252. Tamagnini P, Bernante P, Piotto A, Toniato A, Pelizzo MR 2001 [Reoperation of medullary thyroid carcinoma: long-term results]. *Ann Chir (In French.)* **126**:762–767.
253. Kebebew E, Kikuchi S, Duh QY, Clark OH 2000 Long-term results of reoperation and localizing studies in patients with persistent or recurrent medullary thyroid cancer. *Arch Surg* **135**:895–901.
254. Tisell LE, Jansson S 1988 Recent results of reoperative surgery in medullary carcinoma of the thyroid. *Wien Klin Wochenschr* **100**:347–348.
255. Tisell LE, Hansson G, Jansson S, Salander H 1986 Reoperation in the treatment of asymptomatic metastasizing medullary thyroid carcinoma. *Surgery* **99**:60–66.
256. Moley JF, DeBenedetti MK, Dilley WG, Tisell LE, Wells SA 1998 Surgical management of patients with persistent or recurrent medullary thyroid cancer. *J Intern Med* **243**:521–526.
257. Dralle H 2002 Lymph node dissection and medullary thyroid carcinoma. *Br J Surg* **89**:1073–1075.
258. Fialkowski E, DeBenedetti M, Moley J 2008 Long-term outcome of reoperations for medullary thyroid carcinoma. *World J Surg* **32**:754–765.
259. van Heerden JA, Grant CS, Gharib H, Hay ID, Ilstrup DM 1990 Long-term course of patients with persistent hypercalcitoninemia after apparent curative primary surgery for medullary thyroid carcinoma. *Ann Surg* **212**:395–400; discussion 400–401.
260. Moley JF, Fialkowski EA 2007 Evidence-based approach to the management of sporadic medullary thyroid carcinoma. *World J Surg* **31**:946–956.
261. Isozaki T, Kiba T, Numata K, Saito S, Shimamura T, Kitamura T, Morita K, Tanaka K, Sekihara H 1999 Medullary thyroid carcinoma with multiple hepatic metastases: treatment with transcatheter arterial embolization and percutaneous ethanol injection. *Intern Med* **38**:17–21.
262. di Bartolomeo M, Bajetta E, Buzzoni R, Mariani L, Carnaghi C, Somma L, Zilembo N, di Leo A 1996 Clinical efficacy of octreotide in the treatment of metastatic neuroendocrine tumors. A study by the Italian Trials in Medical Oncology Group. *Cancer* **77**:402–408.
263. Deftos LJ, Stein MF 1980 Radioiodine as an adjunct to the surgical treatment of medullary thyroid carcinoma. *J Clin Endocrinol Metab* **50**:967–968.
264. Hellman DE, Kartchner M, Van Antwerp JD, Salmon SE, Patton DD, O'Mara R 1979 Radioiodine in the treatment of medullary carcinoma of the thyroid. *J Clin Endocrinol Metab* **48**:451–455.
265. Tung WS, Vesely TM, Moley JF 1995 Laparoscopic detection of hepatic metastases in patients with residual or recurrent medullary thyroid cancer. *Surgery* **118**:1024–1029; discussion 1029–1030.
266. Moley JF, Dilley WG, DeBenedetti MK 1997 Improved results of cervical reoperation for medullary thyroid carcinoma. *Ann Surg* **225**:734–740; discussion 740–743.

267. Clark JR, Fridman TR, Odell MJ, Brierley J, Walfish PG, Freeman JL 2005 Prognostic variables and calcitonin in medullary thyroid cancer. *Laryngoscope* **115**:1445–1450.
268. Miyauchi A, Onishi T, Morimoto S, Takai S, Matsuzuka F, Kuma K, Maeda M, Kumahara Y 1984 Relation of doubling time of plasma calcitonin levels to prognosis and recurrence of medullary thyroid carcinoma. *Ann Surg* **199**:461–466.
269. Saad MF, Fritsche HA Jr, Samaan NA 1984 Diagnostic and prognostic values of carcinoembryonic antigen in medullary carcinoma of the thyroid. *J Clin Endocrinol Metab* **58**:889–894.
270. Gautvik KM, Talle K, Hager B, Jorgensen OG, Aas M 1989 Early liver metastases in patients with medullary carcinoma of the thyroid gland. *Cancer* **63**:175–180.
271. Szavcsur P, Godeny M, Bajzik G, Lengyel E, Repa I, Tron L, Boer A, Vincze B, Poti Z, Szabolcs I, Esik O 2005 Angiography-proven liver metastases explain low efficacy of lymph node dissections in medullary thyroid cancer patients. *Eur J Surg Oncol* **31**:183–190.
272. Schott M, Willenberg HS, Sagert C, Nguyen TB, Schinner S, Cohnen M, Cupisti K, Eisenberger CF, Knoefel WT, Scherbaum WA 2007 Identification of occult metastases of medullary thyroid carcinoma by pentagastrin-stimulated intravenous calcitonin sampling followed by targeted surgery. *Clin Endocrinol* **66**:405–409.
273. Pellegriti G, Leboulleux S, Baudin E, Bellon N, Scollo C, Travagli JP, Schlumberger M 2003 Long-term outcome of medullary thyroid carcinoma in patients with normal postoperative medical imaging. *Br J Cancer* **88**:1537–1542.
274. Abdelmoumene N, Schlumberger M, Gardet P, Roche A, Travagli JP, Francesc C, Parmentier C 1994 Selective venous sampling catheterisation for localisation of persisting medullary thyroid carcinoma. *Br J Cancer* **69**:1141–1144.
275. Schwartz DL, Rana V, Shaw S, Yazbeck C, Ang KK, Morrison WH, Rosenthal DI, Hoff A, Evans DB, Clayman GL, Garden AS, Sherman SI 2008 Postoperative radiotherapy for advanced medullary thyroid cancer—local disease control in the modern era. *Head Neck* **30**:883–888.
276. Chow SM, Chan JK, Tiu SC, Choi KL, Tang DL, Law SC 2005 Medullary thyroid carcinoma in Hong Kong Chinese patients. *Hong Kong Med J* **11**:251–258.
277. Fife KM, Bower M, Harmer CL 1996 Medullary thyroid cancer: the role of radiotherapy in local control. *Eur J Surg Oncol* **22**:588–591.
278. Fersht N, Vini L, A'Hern R, Harmer C 2001 The role of radiotherapy in the management of elevated calcitonin after surgery for medullary thyroid cancer. *Thyroid* **11**:1161–1168.
279. Brierley J, Tsang R, Simpson WJ, Gospodarowicz M, Sutcliffe S, Panzarella T 1996 Medullary thyroid cancer: analyses of survival and prognostic factors and the role of radiation therapy in local control. *Thyroid* **6**:305–310.
280. Nguyen TD, Chassard JL, Lagarde P, Cutuli B, Le Fur R, Reme-Saumont M, Prevost B, Panis X, Verrelle P, Chaplain G 1992 Results of postoperative radiation therapy in medullary carcinoma of the thyroid: a retrospective study by the French Federation of Cancer Institutes—the Radiotherapy Cooperative Group. *Radiother Oncol* **23**:1–5.
281. Schlumberger M, Gardet P, de Vathaire F, Sarrazin D, Travagli JP, Parmentier C 1991 External radiotherapy and chemotherapy in MTC patients. In: Calmette C (ed) *Medullary Thyroid Carcinoma*. Vol 211. INSERM/John Libbey Eurotext Ltd., Paris, pp 213–220.
282. McWilliams RR, Giannini C, Hay ID, Atkinson JL, Stafford SL, Buckner JC 2003 Management of brain metastases from thyroid carcinoma: a study of 16 pathologically confirmed cases over 25 years. *Cancer* **98**:356–362.
283. Chiu AC, Delpassand ES, Sherman SI 1997 Prognosis and treatment of brain metastases in thyroid carcinoma. *J Clin Endocrinol Metab* **82**:3637–3642.
284. Kim IY, Kondziolka D, Niranjan A, Flickinger JC, Lunsford LD 2009 Gamma knife radiosurgery for metastatic brain tumors from thyroid cancer. *J Neurooncol* [Epub ahead of print].
285. Mont'Alverne F, Vallee JN, Cormier E, Guillemin R, Barragan H, Jean B, Rose M, Chiras J 2005 Percutaneous vertebroplasty for metastatic involvement of the axis. *AJNR Am J Neuroradiol* **26**:1641–1645.
286. Goetz MP, Callstrom MR, Charboneau JW, Farrell MA, Maus TP, Welch TJ, Wong GY, Sloan JA, Novotny PJ, Petersen IA, Beres RA, Regge D, Capanna R, Saker MB, Gronemeyer DH, Gevargez A, Ahrar K, Choti MA, de Baere TJ, Rubin J 2004 Percutaneous image-guided radiofrequency ablation of painful metastases involving bone: a multicenter study. *J Clin Oncol* **22**:300–306.
287. Callstrom MR, Charboneau JW 2007 Image-guided palliation of painful metastases using percutaneous ablation. *Tech Vasc Interv Radiol* **10**:120–131.
288. Thanos L, Mylona S, Galani P, Tzavoulis D, Kalioras V, Tanteles S, Pomoni M 2008 Radiofrequency ablation of osseous metastases for the palliation of pain. *Skeletal Radiol* **37**:189–194.
289. Simon CJ, Dupuy DE 2006 Percutaneous minimally invasive therapies in the treatment of bone tumors: thermal ablation. *Semin Musculoskelet Radiol* **10**:137–144.
290. Masala S, Manenti G, Roselli M, Mammucari M, Bartolucci DA, Formica V, Massari F, Simonetti G 2007 Percutaneous combined therapy for painful sternal metastases: a radiofrequency thermal ablation (RFTA) and cementoplasty protocol. *Anticancer Res* **27**:4259–4262.
291. Kastler B, Jacamon M, Aubry S, Barral FG, Hadjidekov G, Sarliève P, Saguet O, Lerais JM, Cadel G, Kovacs R, Boulahdour H, Pereira P 2007 [Combined bipolar radiofrequency and cementoplasty of bone metastases]. *J Radiol* **88**:1242–1247. (In French.)
292. Toyota N, Naito A, Kakizawa H, Hieda M, Hirai N, Tachikake T, Kimura T, Fukuda H, Ito K 2005 Radiofrequency ablation therapy combined with cementoplasty for painful bone metastases: initial experience. *Cardiovasc Intervent Radiol* **28**:578–583.
293. Papagelopoulos PJ, Mavrogenis AF, Soucacos PN 2007 Evaluation and treatment of pelvic metastases. *Injury* **38**:509–520.
294. Chiras J, Adem C, Vallee JN, Spelle L, Cormier E, Rose M 2004 Selective intra-arterial chemoembolization of pelvic and spine bone metastases. *Eur Radiol* **14**:1774–1780.
295. Nagata Y, Mitsumori M, Okajima K, Mizowaki T, Fujiwara K, Sasai K, Nishimura Y, Hiraoka M, Abe M, Shimizu K, Kotoura Y 1998 Transcatheter arterial embolization for malignant osseous and soft tissue sarcomas. II. Clinical results. *Cardiovasc Intervent Radiol* **21**:208–213.
296. Layalle I, Flandroy P, Trotteur G, Dondelinger RF 1998 Arterial embolization of bone metastases: is it worthwhile? *J Belge Radiol* **81**:223–225.

297. Guzman R, Dubach-Schwizer S, Heini P, Lovblad KO, Kalbermatten D, Schroth G, Remonda L 2005 Preoperative transarterial embolization of vertebral metastases. *Eur Spine J* **14**:263–268.
298. Baba Y, Hayashi S, Ueno K, Nakajo M 2007 Bone cement used as an embolic agent for active bleeding in vertebroplasty of metastatic lesions. *Acta Radiol* **48**:1024–1027.
299. Börüban S, Sancak T, Yildiz Y, Sağlık Y 2007 Embolization of benign and malignant bone and soft tissue tumors of the extremities. *Diagn Interv Radiol* **13**:164–171.
300. Vitale G, Fonderico F, Martignetti A, Caraglia M, Ciccarelli A, Nuzzo V, Abbruzzese A, Lupoli G 2001 Pamidronate improves the quality of life and induces clinical remission of bone metastases in patients with thyroid cancer. *Br J Cancer* **84**:1586–1590.
301. Mazzaglia PJ, Berber E, Milas M, Siperstein AE 2007 Laparoscopic radiofrequency ablation of neuroendocrine liver metastases: a 10-year experience evaluating predictors of survival. *Surgery* **142**:10–19.
302. Wertenbroek MW, Links TP, Prins TR, Plukker JT, van der Jagt EJ, de Jong KP 2008 Radiofrequency ablation of hepatic metastases from thyroid carcinoma. *Thyroid* **18**:1105–1110.
303. Lorenz K, Brauckhoff M, Behrmann C, Sekulla C, Ukkat J, Brauckhoff K, Gimm O, Dralle H 2005 Selective arterial chemoembolization for hepatic metastases from medullary thyroid carcinoma. *Surgery* **138**:986–993; discussion 993.
304. Fromigue J, De Baere T, Baudin E, Dromain C, Leboulloux S, Schlumberger M 2006 Chemoembolization for liver metastases from medullary thyroid carcinoma. *J Clin Endocrinol Metab* **91**:2496–2499.
305. Jensen RT 1999 Overview of chronic diarrhea caused by functional neuroendocrine neoplasms. *Semin Gastrointest Dis* **10**:156–172.
306. Alam MJ 1994 Chronic refractory diarrhoea: a manifestation of endocrine disorders. *Dig Dis* **12**:46–61.
307. Scherubl H, Raue F, Ziegler R 1990 Combination chemotherapy of advanced medullary and differentiated thyroid cancer. Phase II study. *J Cancer Res Clin Oncol* **116**: 21–23.
308. Orlandi F, Caraci P, Berruti A, Puligheddu B, Pivano G, Dogliotti L, Angeli A 1994 Chemotherapy with dacarbazine and 5-fluorouracil in advanced medullary thyroid cancer. *Ann Oncol* **5**:763–765.
309. Wu LT, Averbuch SD, Ball DW, de Bustros A, Baylin SB, McGuire WP, 3rd 1994 Treatment of advanced medullary thyroid carcinoma with a combination of cyclophosphamide, vincristine, and dacarbazine. *Cancer* **73**:432–436.
310. Schlumberger M, Abdelmoumene N, Delisle MJ, Couette JE 1995 Treatment of advanced medullary thyroid cancer with an alternating combination of 5 FU-streptozocin and 5 FU-dacarbazine. The Groupe d'Etude des Tumeurs a Calcitonine (GETC). *Br J Cancer* **71**:363–365.
311. Di Bartolomeo M, Bajetta E, Bochicchio AM, Carnaghi C, Somma L, Mazzaferro V, Visini M, Gebbia V, Tumolo S, Ballatore P 1995 A phase II trial of dacarbazine, fluorouracil and epirubicin in patients with neuroendocrine tumours. A study by the Italian Trials in Medical Oncology (I.T.M.O.) Group. *Ann Oncol* **6**:77–79.
312. Bajetta E, Rimassa L, Carnaghi C, Seregini E, Ferrari L, Di Bartolomeo M, Regalia E, Cassata A, Procopio G, Mariani L 1998 5-Fluorouracil, dacarbazine, and epirubicin in the treatment of patients with neuroendocrine tumors. *Cancer* **83**:372–378.
313. Petursson SR 1988 Metastatic medullary thyroid carcinoma. Complete response to combination chemotherapy with dacarbazine and 5-fluorouracil. *Cancer* **62**:1899–1903.
314. American Cancer Society 2009 Complementary and Alternative Therapies. Available at [http://www.cancer.org/docroot/ETO/ETO\\_5.asp?sitearea=ETO](http://www.cancer.org/docroot/ETO/ETO_5.asp?sitearea=ETO). Accessed February 21, 2009.
315. Chatal JF, Campion L, Kraeber-Bodere F, Bardet S, Vuillez JP, Charbonnel B, Rohmer V, Chang CH, Sharkey RM, Goldenberg DM, Barbet J 2006 Survival improvement in patients with medullary thyroid carcinoma who undergo pretargeted anti-carcinoembryonic-antigen radioimmunotherapy: a collaborative study with the French Endocrine Tumor Group. *J Clin Oncol* **24**:1705–1711.
316. Kraeber-Bodere F, Rousseau C, Bodet-Milin C, Ferrer L, Faivre-Chauvet A, Campion L, Vuillez JP, Devillers A, Chang CH, Goldenberg DM, Chatal JF, Barbet J 2006 Targeting, toxicity, and efficacy of 2-step, pretargeted radioimmunotherapy using a chimeric bispecific antibody and <sup>131</sup>I-labeled bivalent hapten in a phase I optimization clinical trial. *J Nucl Med* **47**:247–255.
317. Buscombe JR, Cwikla JB, Caplin ME, Hilson AJ 2005 Long-term efficacy of low activity meta-[<sup>131</sup>I]iodobenzylguanidine therapy in patients with disseminated neuroendocrine tumours depends on initial response. *Nucl Med Commun* **26**:969–976.
318. Pasiaka JL, McEwan AJ, Rorstad O 2004 The palliative role of <sup>131</sup>I-MIBG and <sup>111</sup>In-octreotide therapy in patients with metastatic progressive neuroendocrine neoplasms. *Surgery* **136**:1218–1226.
319. Kaltsas G, Rockall A, Papadogias D, Reznick R, Grossman AB 2004 Recent advances in radiological and radionuclide imaging and therapy of neuroendocrine tumours. *Eur J Endocrinol* **151**:15–27.
320. Boughton D, Rosen L, Van Vugt A, Kurzrock R, Eschenberg M, Wiezorek J, Ingram M, Wang D, Stepan D, Herbst RS 2006 Safety and antitumor activity of AMG 706 in patients (pts) with thyroid cancer (TC): A subset analysis from a phase 1 dose-finding study. *ASCO Annual Meeting Proceedings Part I* **24**:3030.
321. Wells SA, Gosnell JE, Gagel RF, Moley JF, Pfister DG, Sosa JA, Skinner M, Krebs A, Hou J, Schlumberger M 2007 Vandetanib in metastatic hereditary medullary thyroid cancer: follow-up results of an open-label phase II trial. *ASCO Annual Meeting Proceedings Part I* **25**:6016.
322. Kober F, Hermann M, Handler A, Krotia G 2007 Effect of sorafenib in symptomatic metastatic medullary thyroid cancer. *ASCO Annual Meeting Proceedings Part I* **25**: 14065.
323. Lam ET, Ringel MD, Kloos RT, Collamore M, Arbogast D, Liang J, Hall N, Knopp MV, Wright J, Shah MH 2009 Anti-tumor activity of Sorafenib in patients with Metastatic Medullary Thyroid Carcinoma. *Proceedings of the American Association for Cancer Research*. Abstract 4513.
324. Salgia R, Sherman S, Hong DS, Ng CS, Frye J, Janisch L, Ratain MJ, Kurzrock R 2008 A phase I study of XL184, a RET, VEGFR2, and MET kinase inhibitor, in patients (pts) with advanced malignancies, including pts with medullary thyroid cancer (MTC). *J Clin Oncol* **26**:abstract 3522.

325. Cox TM, Fagan EA, Hillyard CJ, Allison DJ, Chadwick VS 1979 Role of calcitonin in diarrhoea associated with medullary carcinoma of the thyroid. *Gut* **20**:629–633.
326. Rambaud JC, Jian R, Flourie B, Hautefeuille M, Salmeron M, Thuillier F, Ruskone A, Florent C, Chaoui F, Bernier JJ 1988 Pathophysiological study of diarrhoea in a patient with medullary thyroid carcinoma. Evidence against a secretory mechanism and for the role of shortened colonic transit time. *Gut* **29**:537–543.
327. Vainas I, Koussis C, Pazaitou-Panayiotou K, Drimonitis A, Chrisoulidou A, Iakovou I, Boudina M, Kaprara A, Maladaki A 2004 Somatostatin receptor expression in vivo and response to somatostatin analog therapy with or without other antineoplastic treatments in advanced medullary thyroid carcinoma. *J Exp Clin Cancer Res* **23**:549–559.
328. Zatelli MC, Piccin D, Tagliati F, Bottoni A, Luchin A, Vignali C, Margutti A, Bondanelli M, Pansini GC, Pelizzo MR, Culler MD, Degli Uberti EC 2006 Selective activation of somatostatin receptor subtypes differentially modulates secretion and viability in human medullary thyroid carcinoma primary cultures: potential clinical perspectives. *J Clin Endocrinol Metab* **91**:2218–2224.
329. Mahler C, Verhelst J, de Longueville M, Harris A 1990 Long-term treatment of metastatic medullary thyroid carcinoma with the somatostatin analogue octreotide. *Clin Endocrinol* **33**:261–269.
330. Barbosa SL, Rodien P, Leboulleux S, Niccoli-Sire P, Kraimps JL, Caron P, Archambeaud-Mouveroux F, Conte-Devolx B, Rohmer V 2005 Ectopic adrenocorticotrophic hormone-syndrome in medullary carcinoma of the thyroid: a retrospective analysis and review of the literature. *Thyroid* **15**:618–623.
331. Lupoli G, Cascone E, Arlotta F, Vitale G, Celentano L, Salvatore M, Lombardi G 1996 Treatment of advanced medullary thyroid carcinoma with a combination of recombinant interferon alpha-2b and octreotide. *Cancer* **78**:1114–1118.
332. Vitale G, Tagliaferri P, Caraglia M, Rampone E, Ciccarelli A, Bianco AR, Abbruzzese A, Lupoli G 2000 Slow release lanreotide in combination with interferon-alpha2b in the treatment of symptomatic advanced medullary thyroid carcinoma. *J Clin Endocrinol Metab* **85**:983–988.
333. Ilias I, Torpy DJ, Pacak K, Mullen N, Wesley RA, Nieman LK 2005 Cushing's syndrome due to ectopic corticotropin secretion: twenty years' experience at the National Institutes of Health. *J Clin Endocrinol Metab* **90**:4955–4962.
334. Smallridge RC, Bourne K, Pearson BW, Van Heerden JA, Carpenter PC, Young WF 2003 Cushing's syndrome due to medullary thyroid carcinoma: diagnosis by proopiomelanocortin messenger ribonucleic acid in situ hybridization. *J Clin Endocrinol Metab* **88**:4565–4568.
335. McElduff A, Clifton-Bligh P, Posen S 1979 Metastatic medullary carcinoma of the thyroid complicated by Cushing's syndrome. *Med J Austr* **1**:186–188.
336. Bourlet P, Dumoussat E, Nasser S, Chabrot P, Pezet D, Thieblot P, Garcier JM, Boyer L 2007 Embolization of hepatic and adrenal metastasis to treat Cushing's syndrome associated with medullary thyroid carcinoma: a case report. *Cardiovasc Intervent Radiol* **30**:1052–1055.
337. von Mach MA, Kann P, Piepkorn B, Bruder S, Beyer J 2002 [Cushing's syndrome caused by paraneoplastic ACTH secretion 11 years after occurrence of a medullary thyroid carcinoma]. *Dtsch Med Wochenschr* **127**:850–852. (In German.)
338. Winkvist EW, Laskey J, Crump M, Khamsi F, Shepherd FA 1995 Ketoconazole in the management of paraneoplastic Cushing's syndrome secondary to ectopic adrenocorticotropin production. *J Clin Oncol* **13**:157–164.
339. Mure A, Gicquel C, Abdelmoumene N, Tenenbaum F, Francese C, Travagli JP, Gardet P, Schlumberger M 1995 Cushing's syndrome in medullary thyroid carcinoma. *J Endocrinol Invest* **18**:180–185.
340. Bjerner J, Nustad K, Norum LF, Olsen KH, Borner OP 2002 Immunometric assay interference: incidence and prevention. *Clin Chem* **48**:613–621.
341. Wang TS, Ocal IT, Sosa JA, Cox H, Roman S 2008 Medullary thyroid carcinoma without marked elevation of calcitonin: a diagnostic and surveillance dilemma. *Thyroid* **18**:889–894.
342. Dora JM, da Silva Canalli MH, Capp C, Punaes MK, Vieira JG, Maia AL 2008 Normal perioperative serum calcitonin levels in patients with advanced medullary thyroid carcinoma: case report and review of the literature. *Thyroid* **18**:895–899.
343. Busnardo B, Girelli ME, Simioni N, Nacamulli D, Busetto E 1984 Nonparallel patterns of calcitonin and carcinoembryonic antigen levels in the follow-up of medullary thyroid carcinoma. *Cancer* **53**:278–285.
344. Mendelsohn G, Wells SA Jr, Baylin SB 1984 Relationship of tissue carcinoembryonic antigen and calcitonin to tumor virulence in medullary thyroid carcinoma. An immunohistochemical study in early, localized, and virulent disseminated stages of disease. *Cancer* **54**:657–662.
345. Seri M, Celli I, Betsos N, Claudiani F, Camera G, Romeo G 1997 A Cys634Gly substitution of the RET proto-oncogene in a family with recurrence of multiple endocrine neoplasia type 2A and cutaneous lichen amyloidosis. *Clin Genet* **51**:86–90.
346. Nunziata V, di Giovanni G, Lettera AM, D'Armiento M, Mancini M 1989 Cutaneous lichen amyloidosis associated with multiple endocrine neoplasia type 2A. *Henry Ford Hosp Med J* **37**:144–146.
347. Donovan DT, Levy ML, Furst EJ, Alford BR, Wheeler T, Tschen JA, Gagel RF 1989 Familial cutaneous lichen amyloidosis in association with multiple endocrine neoplasia type 2A: a new variant. *Henry Ford Hosp Med J* **37**:147–150.
348. Khurana R, Agarwal A, Bajpai VK, Verma N, Sharma AK, Gupta RP, Madhusudan KP 2004 Unraveling the amyloid associated with human medullary thyroid carcinoma. *Endocrinology* **145**:5465–5470.
349. Nunziata V, Giannattasio R, Di Giovanni G, D'Armiento MR, Mancini M 1989 Hereditary localized pruritus in affected members of a kindred with multiple endocrine neoplasia type 2A (Sipple's syndrome). *Clin Endocrinol* **30**:57–63.
350. Gimm O, Neuberg DS, Marsh DJ, Dahia PL, Hoang-Vu C, Raue F, Hinze R, Dralle H, Eng C 1999 Over-representation of a germline RET sequence variant in patients with sporadic medullary thyroid carcinoma and somatic RET codon 918 mutation. *Oncogene* **18**:1369–1373.
351. Borrego S, Wright FA, Fernandez RM, Williams N, Lopez-Alonso M, Davuluri R, Antinolo G, Eng C 2003 A founding locus within the RET proto-oncogene may account for a large proportion of apparently sporadic Hirschsprung disease and a subset of cases of sporadic medullary thyroid carcinoma. *Am J Hum Genet* **72**:88–100.
352. Cebrian A, Lesueur F, Martin S, Leyland J, Ahmed S, Luccarini C, Smith PL, Luben R, Whittaker J, Pharoah PD, Dunning AM, Ponder BA 2005 Polymorphisms in the ini-

- tiators of RET (rearranged during transfection) signaling pathway and susceptibility to sporadic medullary thyroid carcinoma. *J Clin Endocrinol Metab* **90**:6268–6274.
353. Costa P, Domingues R, Sobrinho LG, Bugalho MJ 2005 RET polymorphisms and sporadic medullary thyroid carcinoma in a Portuguese population. *Endocrine* **27**:239–243.
  354. Cardot-Bauters C, Leteurtre E, Leclerc L, Vantyghem MC, Do Cao C, Wemeau JL, d'Herbomez M, Carnaille B, Barbu V, Pinson S, Pigny P 2008 Does the RET variant G691S influence the features of sporadic medullary thyroid carcinoma? *Clin Endocrinol* **69**:506–510.
  355. Fugazzola L, Muzza M, Mian C, Cordella D, Barollo S, Alberti L, Cirello V, Dazzi D, Girelli ME, Opocher G, Beck-Peccoz P, Persani L 2008 RET genotypes in sporadic medullary thyroid cancer: studies in a large Italian series. *Clin Endocrinol* **69**:418–425.
  356. Weinhausen A, Scheuba C, Lauss M, Kriegner A, Kaserer K, Vierlinger K, Haas OA, Niederle B 2008 The influence of gender, age, and RET polymorphisms on C-cell hyperplasia and medullary thyroid carcinoma. *Thyroid* **18**:1269–1276.
  357. Ruiz-Llorente S, Montero-Conde C, Milne RL, Moya CM, Cebrian A, Leton R, Cascon A, Mercadillo F, Landa I, Borrego S, de Nanclares GP, Alvarez-Escola C, Diaz-Perez JA, Carracedo A, Urioste M, Gonzalez-Neira A, Benitez J, Santisteban P, Dopazo J, Ponder BA, Robledo M 2007 Association study of 69 genes in the Ret pathway identifies low-penetrance loci in sporadic medullary thyroid carcinoma. *Cancer Res* **67**:9561–9567.
  358. Joshi PP, Kulkarni MV, Yu BK, Smith KR, Norton DL, Veelen W, Hoppener JW, Franklin DS 2007 Simultaneous downregulation of CDK inhibitors p18(Ink4c) and p27(Kip1) is required for MEN2A-RET-mediated mitogenesis. *Oncogene* **26**:554–570.
  359. Gujral TS, Singh VK, Jia Z, Mulligan LM 2006 Molecular mechanisms of RET receptor-mediated oncogenesis in multiple endocrine neoplasia 2B. *Cancer Res* **66**:10741–10749.
  360. Akeno-Stuart N, Croyle M, Knauf JA, Malaguamera R, Vitagliano D, Santoro M, Stephan C, Grosios K, Wartmann M, Cozens R, Caravatti G, Fabbro D, Lane HA, Fagin JA 2007 The RET kinase inhibitor NVP-AST487 blocks growth and calcitonin gene expression through distinct mechanisms in medullary thyroid cancer cells. *Cancer Res* **67**:6956–6964.
  361. Carlomagno F, Anaganti S, Guida T, Salvatore G, Troncone G, Wilhelm SM, Santoro M 2006 BAY 43-9006 inhibition of oncogenic RET mutants. *J Natl Cancer Inst* **98**:326–334.
  362. Knowles PP, Murray-Rust J, Kjaer S, Scott RP, Hanrahan S, Santoro M, Ibanez CF, McDonald NQ 2006 Structure and chemical inhibition of the RET tyrosine kinase domain. *J Biol Chem* **281**:33577–33587.
  363. Cohen EE, Rosen LS, Vokes EE, Kies MS, Forastiere AA, Worden FP, Kane MA, Sherman E, Kim S, Bycott P, Tورتorici M, Shalinsky DR, Liau KF, Cohen RB 2008 Axitinib is an active treatment for all histologic subtypes of advanced thyroid cancer: results from a phase II study. *J Clin Oncol* **26**:4708–4713.
  364. Pigny P, Bauters C, Wemeau JL, Houcke ML, Crepin M, Caron P, Giraud S, Calender A, Buisine MP, Kerckaert JP, Porchet N 1999 A novel 9-base pair duplication in RET exon 8 in familial medullary thyroid carcinoma. *J Clin Endocrinol Metab* **84**:1700–1704.
  365. Fazioli F, Piccinini G, Appolloni G, Bacchiocchi R, Palmone G, Recchioni R, Pierpaoli E, Silvetti F, Scarpelli M, Bruglia M, Melillo RM, Santoro M, Boscaro M, Taccaliti A 2008 A new germline point mutation in ret exon 8 (cys515ser) in a family with medullary thyroid carcinoma. *Thyroid* **18**:775–782.
  366. Da Silva AM, Maciel RM, Da Silva MR, Toledo SR, De Carvalho MB, Cerutti JM 2003 A novel germ-line point mutation in RET exon 8 (Gly(533)Cys) in a large kindred with familial medullary thyroid carcinoma. *J Clin Endocrinol Metab* **88**:5438–5443.
  367. Bethanis S, Koutsodontis G, Palouka T, Avgoustis C, Yannoukakos D, Bei T, Papadopoulou S, Linos D, Tzagarakis S 2007 A newly detected mutation of the RET protooncogene in exon 8 as a cause of multiple endocrine neoplasia type 2A. *Hormones (Athens)* **6**:152–156.
  368. Peppas M, Boutati E, Kamakari S, Pikounis V, Peros G, Panayiotides IG, Economopoulos T, Raptis SA, Hadjidakis D 2008 Multiple endocrine neoplasia type 2A in two families with the familial medullary thyroid carcinoma associated G533C mutation of the RET proto-oncogene. *Eur J Endocrinol* **159**:767–771.
  369. Sáez ME, Ruiz A, Cebrián A, Morales F, Robledo M, Antiñolo G, Borrego S 2000 A new germline mutation, R600Q, within the coding region of RET proto-oncogene: a rare polymorphism or a MEN 2 causing mutation? *Hum Mutat* **15**:122.
  370. Rey JM, Brouillet JP, Fonteneau-Allaire J, Boneu A, Bastie D, Maudelonde T, Pujol P 2001 Novel germline RET mutation segregating with papillary thyroid carcinomas. *Genes Chromosomes Cancer* **32**:390–391.
  371. Ahmed SA, Snow-Bailey K, Highsmith WE, Sun W, Fenwick RG, Mao R 2005 Nine novel germline gene variants in the RET proto-oncogene identified in twelve unrelated cases. *J Mol Diagn* **7**:283–288.
  372. Ercolino T, Lombardi A, Becherini L, Piscitelli E, Cantini G, Gagliano MS, Serio M, Luconi M, Mannelli M 2008 The Y606C RET mutation causes a receptor gain of function. *Clin Endocrinol* **69**:253–258.
  373. Igaz P, Patocs A, Racz K, Klein I, Varadi A, Esik O 2002 Occurrence of pheochromocytoma in a MEN2A family with codon 609 mutation of the RET proto-oncogene. *J Clin Endocrinol Metab* **87**:2994.
  374. Fialkowski EA, DeBenedetti MK, Moley JF, Bachrach B 2008 RET proto-oncogene testing in infants presenting with Hirschsprung disease identifies 2 new multiple endocrine neoplasia 2A kindreds. *J Pediatr Surg* **43**:188–190.
  375. Kinlaw WB, Scott SM, Maue RA, Memoli VA, Harris RD, Daniels GH, Porter DM, Belloni DR, Spooner ET, Ernesti MM, Noll WW 2005 Multiple endocrine neoplasia 2A due to a unique C609S RET mutation presents with pheochromocytoma and reduced penetrance of medullary thyroid carcinoma. *Clin Endocrinol* **63**:676–682.
  376. Yonekawa H, Sugitani I, Fujimoto Y, Arai M, Yamamoto N 2007 A family of multiple endocrine neoplasia type 2A (MEN 2A) with Cys630Tyr RET germline mutation: report of a case. *Endocr J* **54**:531–535.
  377. Frank-Raue K 2008 Clinical update: genotype-phenotype correlation of RET mutations. *Hot Thyroidology* 2008; November:HT03/08. Available at <http://www.hotthyroidology.com/index.php>. Accessed November 30, 2008.
  378. Berndt I, Reuter M, Saller B, Frank-Raue K, Groth P, Grussendorf M, Raue F, Ritter MM, Hoppner W 1998 A new hot spot for mutations in the ret protooncogene causing familial medullary thyroid carcinoma and multiple

- endocrine neoplasia type 2A. *J Clin Endocrinol Metab* **83**:770–774.
379. Hoppner W, Dralle H, Brabant G 1998 Duplication of 9 base pairs in the critical cysteine-rich domain of the RET proto-oncogene causes multiple endocrine neoplasia type 2A. *Hum Mutat Suppl* **1**:S128–130.
380. Pinales MK, Graf H, Gross JL, Maia AL 2003 RET codon 634 mutations in multiple endocrine neoplasia type 2: variable clinical features and clinical outcome. *J Clin Endocrinol Metab* **88**:2644–2649.
381. Zhou YL, Zhu SX, Li JJ, Liu JB, Yin M, Xiao BY, Yu CL, Wang LM, Gu LQ, Cui B, Ning G, Li XY, Zhao YJ 2007 [The clinical patterns and RET proto-oncogene in fifteen multiple endocrine neoplasia type 2A pedigrees]. *Zhonghua Nei Ke Za Zhi* [Chinese journal of internal medicine] **46**:466–470. (In Chinese.)
382. Lemos MC, Carrilho F, Rodrigues FJ, Santos P, Carvalheiro M, Ruas MA, Regateiro FJ 2002 Early onset of medullary thyroid carcinoma in a kindred with multiple endocrine neoplasia type 2a associated with cutaneous lichen amyloidosis. *Endocr Pract* **8**:19–22.
383. Hoppner W, Ritter MM 1997 A duplication of 12bp in the critical cysteine rich domain of the RET proto-oncogene results in a distinct phenotype of multiple endocrine neoplasia type 2A. *Hum Mol Genet* **6**:587–590.
384. Vierhapper H, Bieglmayer C, Heinze G, Baumgartner-Parzer S 2004 Frequency of RET proto-oncogene mutations in patients with normal and with moderately elevated pentagastrin-stimulated serum concentrations of calcitonin. *Thyroid* **14**:580–583.
385. Colombo-Benkmann M, Li Z, Riemann B, Hengst K, Herbst H, Keuser R, Gross U, Rondot S, Raue F, Semninger N, Putzer BM, Frank-Raue K 2008 Characterization of the RET protooncogene transmembrane domain mutation S649L associated with nonaggressive medullary thyroid carcinoma. *Eur J Endocrinol* **158**:811–816.
386. D'Aloiso L, Carlomagno F, Bisceglia M, Anaganti S, Ferretti E, Verrienti A, Arturi F, Scarpelli D, Russo D, Santoro M, Filetti S 2006 Clinical case seminar: in vivo and in vitro characterization of a novel germline RET mutation associated with low-penetrant nonaggressive familial medullary thyroid carcinoma. *J Clin Endocrinol Metab* **91**:754–759.
387. Vestergaard P, Vestergaard EM, Brockstedt H, Christiansen P 2007 Codon Y791F mutations in a large kindred: is prophylactic thyroidectomy always indicated? *World J Surg* **31**:996–1001; discussion 1002–1004.
388. Learoyd DL, Gosnell J, Elston MS, Saurine TJ, Richardson AL, Delbridge LW, Aglen JV, Robinson BG 2005 Experience of prophylactic thyroidectomy in multiple endocrine neoplasia type 2A kindreds with RET codon 804 mutations. *Clin Endocrinol* **63**:636–641.
389. Recasens M, Oriola J, Fernandez-Real JM, Roig J, Rodriguez-Hermosa JL, Font JA, Galofre P, Lopez-Bermejo A, Ricart W 2007 Asymptomatic bilateral adrenal pheochromocytoma in a patient with a germline V804M mutation in the RET proto-oncogene. *Clin Endocrinol* **67**:29–33.
390. Kasprzak L, Nolet S, Gaboury L, Pavia C, Villabona C, Rivera-Fillat F, Oriola J, Foulkes WD 2001 Familial medullary thyroid carcinoma and prominent corneal nerves associated with the germline V804M and V778I mutations on the same allele of RET. *J Med Genet* **38**:784–787.
391. Cranston A, Carniti C, Martin S, Mondellini P, Hooks Y, Leyland J, Hodgson S, Clarke S, Pierotti M, Ponder BA, Bongarzone I 2006 A novel activating mutation in the RET tyrosine kinase domain mediates neoplastic transformation. *Mol Endocrinol* **20**:1633–1643.
392. Prazeres HJ, Rodrigues F, Figueiredo P, Naidenov P, Soares P, Bugalho MJ, Lacerda M, Campos B, Martins TC 2006 Occurrence of the Cys611Tyr mutation and a novel Arg886Trp substitution in the RET proto-oncogene in multiple endocrine neoplasia type 2 families and sporadic medullary thyroid carcinoma cases originating from the central region of Portugal. *Clin Endocrinol* **64**:659–666.
393. Gimm O, Marsh DJ, Andrew SD, Frilling A, Dahia PL, Mulligan LM, Zajac JD, Robinson BG, Eng C 1997 Germline dinucleotide mutation in codon 883 of the RET proto-oncogene in multiple endocrine neoplasia type 2B without codon 918 mutation. *J Clin Endocrinol Metab* **82**:3902–3904.
394. Smith DP, Houghton C, Ponder BA 1997 Germline mutation of RET codon 883 in two cases of de novo MEN 2B. *Oncogene* **15**:1213–1217.
395. Hofstra RM, Fattoruso O, Quadro L, Wu Y, Libroia A, Verga U, Colantuoni V, Buys CH 1997 A novel point mutation in the intracellular domain of the ret protooncogene in a family with medullary thyroid carcinoma. *J Clin Endocrinol Metab* **82**:4176–4178.
396. Dang GT, Cote GJ, Schultz PN, Khorana S, Decker RA, Gagel RF 1999 A codon 891 exon 15 RET proto-oncogene mutation in familial medullary thyroid carcinoma: a detection strategy. *Mol Cell Probes* **13**:77–79.
397. Jimenez C, Habra MA, Huang SC, El-Naggar A, Shapiro SE, Evans DB, Cote G, Gagel RF 2004 Pheochromocytoma and medullary thyroid carcinoma: a new genotype-phenotype correlation of the RET protooncogene 891 germline mutation. *J Clin Endocrinol Metab* **89**:4142–4145.
398. Jimenez C, Dang GT, Schultz PN, El-Naggar A, Shapiro S, Barnes EA, Evans DB, Vassilopoulou-Sellin R, Gagel RF, Cote GJ, Hoff AO 2004 A novel point mutation of the RET protooncogene involving the second intracellular tyrosine kinase domain in a family with medullary thyroid carcinoma. *J Clin Endocrinol Metab* **89**:3521–3526.

Address reprint requests to:  
 Richard T. Kloos, M.D.  
 The Ohio State University  
 446 McCampbell Hall  
 1581 Dodd Drive  
 Columbus, OH 43210

E-mail: richard.kloos@osumc.edu



**This article has been cited by:**

1. Friedhelm Raue, Karin Frank-Raue. 2010. Update multiple endocrine neoplasia type 2. *Familial Cancer* . [[CrossRef](#)]
2. Ashok R. Shaha, R. Michael Tuttle. 2010. Author Reply: Management of Mild Elevation of Calcitonin After Thyroidectomy. *Annals of Surgical Oncology* 17:1, 329-330. [[CrossRef](#)]
3. Charles H. Emerson . 2009. Guidelines for Guidelines: Content, Accountability, Peer Review, and Intellectual OwnershipGuidelines for Guidelines: Content, Accountability, Peer Review, and Intellectual Ownership. *Thyroid* 19:11, 1137-1138. [[Citation](#)] [[Full Text](#)] [[PDF](#)] [[PDF Plus](#)]
4. Alexander R. Novotny , Peter Lippa , Robert Rosenberg , H. Schneider , Matthias Maak , Holger Bartels , Bernhard Holzmann , Helmut Friess . 2009. Procalcitonin Can Be Used for Monitoring Sepsis in Patients with Medullary Thyroid CarcinomaProcalcitonin Can Be Used for Monitoring Sepsis in Patients with Medullary Thyroid Carcinoma. *Thyroid* 19:11, 1287-1289. [[Citation](#)] [[Full Text](#)] [[PDF](#)] [[PDF Plus](#)]
5. Leonard Wartofsky . 2009. Highlights of the American Thyroid Association Guidelines for Patients with Thyroid Nodules or Differentiated Thyroid Carcinoma: The 2009 RevisionHighlights of the American Thyroid Association Guidelines for Patients with Thyroid Nodules or Differentiated Thyroid Carcinoma: The 2009 Revision. *Thyroid* 19:11, 1139-1143. [[Citation](#)] [[Full Text](#)] [[PDF](#)] [[PDF Plus](#)]
6. 2009. CorrectionCorrection. *Thyroid* 19:11, 1295-1295. [[Citation](#)] [[Full Text](#)] [[PDF](#)] [[PDF Plus](#)]
7. Richard T. Kloos . 2009. Protecting Thyroid Cancer Patients from Untoward Effects of Radioactive Iodine TreatmentProtecting Thyroid Cancer Patients from Untoward Effects of Radioactive Iodine Treatment. *Thyroid* 19:9, 925-928. [[Citation](#)] [[Full Text](#)] [[PDF](#)] [[PDF Plus](#)]
8. Kenneth D. Burman . 2009. The 80th Annual Meeting of the American Thyroid Association Returns to Palm Beach, FloridaThe 80th Annual Meeting of the American Thyroid Association Returns to Palm Beach, Florida. *Thyroid* 19:7, 677-678. [[Citation](#)] [[PDF](#)] [[PDF Plus](#)]
9. Michael Brauckhoff , Oliver Gimm . 2009. Extrathyroidal Manifestations of Multiple Endocrine Neoplasia Type 2Extrathyroidal Manifestations of Multiple Endocrine Neoplasia Type 2. *Thyroid* 19:6, 555-557. [[Citation](#)] [[PDF](#)] [[PDF Plus](#)]
10. Steven G. Waguespack . 2009. A Perspective from Pediatric Endocrinology on the Hereditary Medullary Thyroid Carcinoma SyndromesA Perspective from Pediatric Endocrinology on the Hereditary Medullary Thyroid Carcinoma Syndromes. *Thyroid* 19:6, 543-546. [[Citation](#)] [[PDF](#)] [[PDF Plus](#)]
11. Andreas Machens , Henning Dralle . 2009. Prophylactic Thyroidectomy in RET Carriers at Risk for Hereditary Medullary Thyroid CancerProphylactic Thyroidectomy in RET Carriers at Risk for Hereditary Medullary Thyroid Cancer. *Thyroid* 19:6, 551-554. [[Citation](#)] [[PDF](#)] [[PDF Plus](#)]
12. Douglas W. Ball . 2009. American Thyroid Association Guidelines for Management of Medullary Thyroid Cancer: An Adult Endocrinology PerspectiveAmerican Thyroid Association Guidelines for Management of Medullary Thyroid Cancer: An Adult Endocrinology Perspective. *Thyroid* 19:6, 547-550. [[Citation](#)] [[PDF](#)] [[PDF Plus](#)]