

## Research Article

# Melatonin Alleviated Potassium Dichromate-Induced Oxidative Stress and Reprotoxicity in Male Rats

Samir A. E. Bashandy <sup>1</sup>, Hossam Ebaid <sup>2</sup>, Jameel Al-Tamimi,<sup>2</sup>  
Omar A.-H. Ahmed-Farid <sup>3</sup>, Enayat A. Omara,<sup>4</sup> and Ibrahim M. Alhazza <sup>2</sup>

<sup>1</sup>Pharmacology Department, National Research Centre, 33 El-Bohouth St., Dokki, P.O. 12622, Giza, Cairo, Egypt

<sup>2</sup>Department of Zoology, College of Science, King Saud University, Riyadh 11451, Saudi Arabia

<sup>3</sup>Physiology Department, National Organization for Drug Control and Research, Cairo, Egypt

<sup>4</sup>Pathology Department, National Research Centre, Cairo, Egypt

Correspondence should be addressed to Samir A. E. Bashandy; bashandysamir@gmail.com

Received 10 August 2020; Revised 7 April 2021; Accepted 27 May 2021; Published 16 June 2021

Academic Editor: Valeria Pasciu

Copyright © 2021 Samir A. E. Bashandy et al. This is an open access article distributed under the Creative Commons Attribution License, which permits unrestricted use, distribution, and reproduction in any medium, provided the original work is properly cited.

Melatonin (ML) is a potent antioxidant that reduces oxidative stress. This study was designed to examine the protective effect of melatonin on potassium dichromate- (PDC-) induced male reproductive toxicity. Forty rats were divided into five groups: the control group, rats administered PDC orally (10 mg/kg body weight) for eight weeks, rats administered ML intraperitoneally at doses of either 2.5 or 5 mg/kg followed by the administration of PDC, and rats administered 5 mg/kg ML only. The treatment of rats with PDC led to a decrease in the levels of plasma sex hormones, glutathione, superoxide dismutase, catalase, carnitine, sperm count, and motility. Testicular malondialdehyde levels, nitric oxide concentrations, and abnormalities increased significantly in the PDC group. Melatonin administration to the PDC-treated rats reduced the increase of malondialdehyde and restored the activity of antioxidant enzymes (superoxide dismutase and catalase), glutathione, and sex hormone levels. Moreover, ML attenuated PDC-induced increase in levels of tumor necrosis factor- $\alpha$  or interleukin-6. ML alleviated histopathological changes and an increase of p53-positive immune reaction due to PDC. Furthermore, ML inhibited PDC-induced decrease in the DNA content of spermatogenic cells. This study proposed that melatonin may be useful in mitigating oxidative stress-induced testicular damage due to potassium dichromate toxicity.

## 1. Introduction

Melatonin (ML) is a hormone secreted by the pineal gland in response to darkness. Melatonin known as N-acetyl-5-methoxytryptamine is synthesized from the amino acid, tryptophan [1], and has a remarkable influence on the sleep-wake cycle, pubertal development, and memory [2]. It displayed antioxidant, anticancer, and anti-inflammatory activities [3–5]. Melatonin controls various physiologic processes, including circadian rhythms, mood regulation, anxiety, sleep, appetite, immune responses, and cardiac functions [6]. Melatonin may also exhibit anticancer and protective tumor activities through several mechanisms, including inhibition of cancer cell proliferation, decrease in oxidative stress, and an increase in immune system activity [7, 8]. Moreover, the

role of ML in the management of some disorders as Alzheimer's, obesity, and cardiovascular disease has been reported [9–11]. ML maintains spermatogenesis in diabetic rats and lowers inflammatory cytokine levels [12, 13]. It has been shown to reduce testicular damage in rats encouraged by acetylsalicylic acid or methotrexate via enhancement of antioxidant capacity [14, 15]. It was concluded that melatonin is capable of reducing spermatozoa apoptosis and DNA fragmentation stimulated by reactive oxygen species [16, 17]. Being an amphiphilic molecule, melatonin can cross the blood–testes barrier to inhibit oxidative and nitrosative stress-induced damages to the germinal epithelium [18].

Chromium is a naturally occurring element in rocks, animals, plants, soil, volcanic dust, and gases. Chromium exists mostly in two valence states in nature: hexavalent chromium

TABLE 1: Effect of melatonin and potassium dichromate administration on the body weight (g) of rats.

Group Time in week	Control	PDC	PDC		Melatonin 5 mg/kg
			+2.5 mg/kg melatonin	+5 mg/kg melatonin	
0	150.00 ± 6.71	158.57 ± 9.50	160.54 ± 8.35	154.00 ± 8.55	163.12 ± 6.34
2	183.37 ± 6.40	151.63 ± 9.36	166.78 ± 10.63	183.00 ± 9.56	196.54 ± 5.61
4	224.76 ± 13.81	170.57 ± 11.21*	179.23 ± 8.55*	200.19 ± 14.98	230.00 ± 12.82
6	250.36 ± 14.20	159.75 ± 5.62*	194.86 ± 10.22* <sup>@</sup>	236.71 ± 13.00 <sup>@</sup>	242.45 ± 7.34
8	290.65 ± 15.06	186.57 ± 10.84*	224.67 ± 9.34* <sup>@</sup>	256.95 ± 11.68 <sup>@</sup>	261.78 ± 9.00

Each value is the mean ± SE,  $n = 8$ . \*Significant difference from the control,  $P \leq 0.01$ . <sup>@</sup>Significant difference from the PDC group,  $P \leq 0.01$ .

TABLE 2: Reproductive organ weights (g) relative to the body weight of rats treated with potassium dichromate and melatonin.

Group Organ	Control	PDC	PDC		Melatonin 5 mg/kg
			+2.5 mg/kg melatonin	+5 mg/kg melatonin	
Left testis	0.65 ± 0.03	0.46 ± 0.02*	0.59 ± 0.03* <sup>@</sup>	0.58 ± 0.02* <sup>@</sup>	0.64 ± 0.02
Vas deferens	0.07 ± 0.005	0.04 ± 0.002*	0.08 ± 0.002* <sup>@</sup>	0.08 ± 0.003* <sup>@</sup>	0.07 ± 0.002
Epididymis	0.31 ± 0.01	0.21 ± 0.01*	0.29 ± 0.01 <sup>@</sup>	0.30 ± 0.01 <sup>@</sup>	0.30 ± 0.01
Prostate	0.42 ± 0.01	0.17 ± 0.004*	0.23 ± 0.01* <sup>@</sup>	0.24 ± 0.01* <sup>@</sup>	0.40 ± 0.03
Seminal vesicle	0.62 ± 0.02	0.22 ± 0.01*	0.32 ± 0.01* <sup>@</sup>	0.41 ± 0.02* <sup>@M</sup>	0.64 ± 0.01

Each value is the mean ± SE,  $n = 8$ . \*Significant difference from the control,  $P \leq 0.01$ . <sup>@</sup>Significant difference from the PDC group,  $P \leq 0.01$ . <sup>M</sup>Significant difference from the PDC+melatonin 2.5 mg/kg group,  $P \leq 0.01$ .

TABLE 3: Oxidative stress parameters of rats treated with melatonin and potassium dichromate.

Group Parameter	Control	PDC	PDC		Melatonin 5 mg/kg
			+2.5 mg/kg melatonin	+5 mg/kg melatonin	
MDA (nmol/g tissue)	14.78 ± 0.63	28.61 ± 1.32*	17.41 ± 1.26* <sup>@</sup>	12.75 ± 0.57 <sup>@M</sup>	13.22 ± 1.00
GSH ( $\mu$ mol/g tissue)	6.00 ± 0.43	3.51 ± 0.11*	3.90 ± 0.039*	4.79 ± 0.36 <sup>@M</sup>	5.76 ± 0.36
GSSG ( $\mu$ mol/g tissue)	0.75 ± 0.04	1.20 ± 0.07*	0.90 ± 0.04* <sup>@</sup>	0.63 ± 0.04* <sup>@M</sup>	0.70 ± 0.03
CAT (mmol H <sub>2</sub> O <sub>2</sub> /min/mg protein)	6.00 ± 0.43	3.10 ± 0.01*	5.00 ± 0.12 <sup>@</sup>	5.82 ± 0.01 <sup>@M</sup>	5.78 ± 0.36
SOD (U/g tissue)	52.45 ± 1.40	44.28 ± 1.06*	46.19 ± 2.36*	50.14 ± 3.89 <sup>@</sup>	55.24 ± 4.18
NO (nitrate/nitrite) ( $\mu$ mol/g tissue)	0.38 ± 0.02	0.61 ± 0.03*	0.54 ± 0.02* <sup>@</sup>	0.38 ± 0.01 <sup>@M</sup>	0.40 ± 0.01
Car (nmol/g tissue)	475.70 ± 29.38	355.91 ± 15.51*	353.86 ± 24.10*	492.09 ± 27.32 <sup>@M</sup>	483.22 ± 35.96

Each value is the mean ± SE,  $n = 8$ . \*Significant difference from the control,  $P \leq 0.01$ . <sup>@</sup>Significant difference from the PDC group,  $P \leq 0.01$ . <sup>M</sup>Significant difference from the PDC+melatonin 2.5 mg/kg group,  $P \leq 0.01$ .

(chromium (VI)) and trivalent chromium (chromium (III), an essential nutrient). Chromium (VI) is commonly used in industrial chrome plating, welding, painting, metal finishes, steel manufacturing, alloy, cast iron, and wood treatment and is a proven toxin, mutagen, and carcinogen. Chromium (III) is essential for proper insulin function, and it is required for normal protein, fat, and carbohydrate metabolism [19]. Occupational and environmental exposure to Cr (VI)-containing compounds are known to be toxic, mutagenic, and carcinogenic to human beings and diverse animals [20], leading to serious damage to the kidney [21], liver [22], lung [23], skin [24], hypothalamus, and anterior pituitary [25]. Potassium dichromate (PDC) is a form of hexavalent chromium, an environmental pollutant that has been suggested to be linked with reproductive defects in male rats. PDC causes reproductive system toxicity possibly by decreasing blood

luteinizing hormone (LH) level, testosterone level, sperm motility, and epididymal spermatozoa count. Moreover, PDC treatment led to testicular tissue damage as evidenced by marked degenerative necrotic spermatogonial cell layers, associated with interstitial hemorrhage and vacuolated Leydig cells. [26]. Reportedly, ROS is produced during the cellular reduction of hexavalent chromium to trivalent chromium [27]. Melatonin has a potential antioxidant effect to abolish oxidative damage through scavenging of ROS [3] and may improve the testicular function associated with PDC toxicity. In this study, we investigated the role of ML in reducing PDC-evoked testicular oxidative stress, sperm morphology abnormalities, and a decrease in the activity of antioxidant enzymes or sex hormone levels. Additionally, the DNA content and immunohistochemical change of p53 in spermatogenic cells need to be examined.

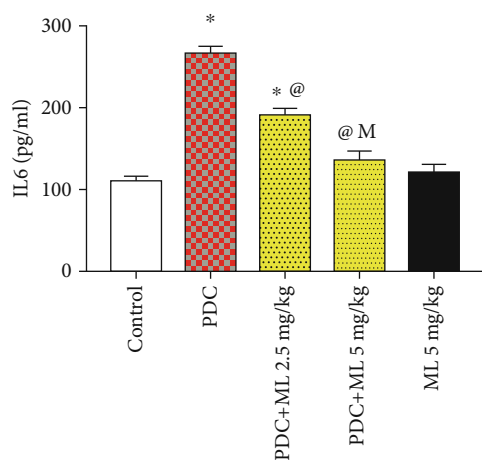


FIGURE 1: Effect of melatonin and potassium dichromate on plasma IL-6 level. Values are expressed as means SE.  $n = 8$  per group. PDC: potassium dichromate; ML: melatonin; OD: optical density. \* Significant difference from the control,  $P \leq 0.01$ . @Significant difference from PDC,  $P \leq 0.01$ . MSignificant difference from ML2 2.5 mg/kg,  $P \leq 0.01$ .

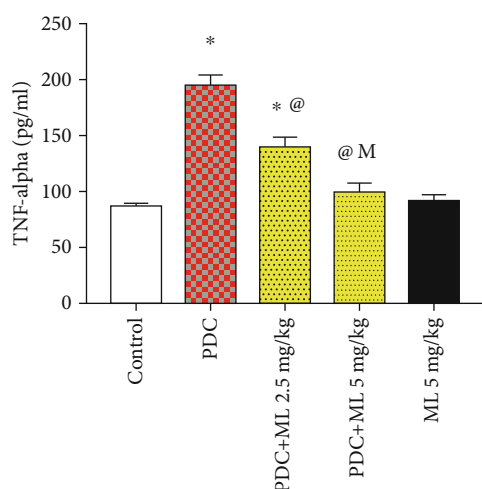


FIGURE 2: Effect of melatonin and potassium dichromate on plasma TNF- $\alpha$  level. Values are expressed as means SE.  $n = 8$  per group. PDC: potassium dichromate; ML: melatonin; OD: optical density. \*Significant difference from the control,  $P \leq 0.01$ . @Significant difference from PDC,  $P \leq 0.01$ . MSignificant difference from ML2 2.5 mg/kg,  $P \leq 0.01$ .

## 2. Material and Methods

**2.1. Chemicals.** Melatonin was procured from MP Biomedicals, LLC (Lkirch, France). PDC was produced by Sigma Aldrich, USA. Other chemicals used in these experiments were analytical grade from commercial sources.

**2.2. Animals.** Adult male Wistar rats (weighing 150-160 g and 3 months age) were chosen from the animal house of the National Research Centre, Egypt. Rats were fed a standard pellet diet, provided water ad libitum, and housed at an adjusted temperature ( $22 \pm 2^\circ\text{C}$ ) with a 12 h light-dark

cycle. Animal handling was carried out following the Ethics and the recommendations of the National Institutes of Health Guide for Care and Use of Laboratory Animals (Publication No. 85-23, revised 1985).

**2.3. Study Design.** Forty rats were categorized equally into five groups:

Group I included controls orally administered the same volume of a vehicle, water (1 ml) daily for 8 weeks

Group II included rats that were orally administered 10 mg/kg body weight of PDC [28] daily for 8 weeks

Group III included rats pretreated with 2.5 mg/kg ML intraperitoneally followed by treatment with PDC after 30 min daily for 8 weeks

Group IV included rats pretreated with 5 mg/kg ML intraperitoneally followed by treatment with PDC after 30 min daily for 8 weeks. The doses of melatonin were chosen according to the previous study of Chabra et al. [29]

Group V included rats treated with 5 mg/kg ML (IP) only daily for 8 weeks

The daily treatment of rats was carried out (at 5 PM) 1 h before lights off for 8 weeks. The experiment was finished at the 8<sup>th</sup> week because the duration of spermatogenesis in rats is 54 days [30]. Melatonin or PDC was dissolved in water.

**2.4. Sample Collection.** Blood (3 ml) was collected after 2 months of treatment in heparinized tubes from the retroorbital plexus under local anesthesia using diethyl ether. The animals were culled 8 weeks posttreatment by cervical dislocation under ether anesthesia. Plasma was isolated by centrifugation at 3000 g for 15 min. Body weight was recorded every 2 weeks, and the weight of sexual organs was measured at the end of experiment time (8 weeks). The left epididymis was incubated at  $37^\circ\text{C}$  in phosphate-buffered saline (PBS) for the evaluation of sperm motility, count, and abnormality. The left testis was processed for histological study, and the right one was collected for the evaluation of malondialdehyde (MDA), reduced glutathione (GSH), oxidized glutathione (GSSG), superoxide dismutase (SOD), catalase (CAT), nitric oxide (NO), tumor necrosis factor- $\alpha$  (TNF- $\alpha$ ), interleukin-6 (IL-6), and carnitine (Car).

**2.5. Testicular Homogenate.** Each right testis was weighed and homogenized in saline (10% w/v). Samples were centrifuged (4500 rpm) for 15 min; then, the supernatant was isolated and stored at  $-80^\circ\text{C}$  until assay.

**2.6. Testicular Oxidative Stress Parameters.** Testicular MDA, GSH, GSSG, NO, and Car levels were evaluated using a high-performance liquid chromatography system (Agilent 1200 series; Santa Clara, CA) employing a quaternary pump, a column oven, a Rheodyne injector, 20  $\mu\text{l}$  loop, and an ultraviolet variable wavelength detector.

**2.6.1. Determination of the Testicular Tissue MDA Level (nmol/g Tissue) by HPLC.** The analytical column was Supelcosil C18 (5  $\mu\text{m}$  particle and 80  $\text{\AA}$  pore size) ( $250 \times 4.6$  ID). The mobile phase was 82.5:17.5 (v/v) 30 mM monobasic potassium phosphate-methanol (pH 3.6), and the flow rate

TABLE 4: Protective effect of melatonin on PDC-induced alteration of male sex hormones.

Group Hormone	Control	PDC	PDC		Melatonin 5 mg/kg
			+melatonin 2.5 mg/kg	+melatonin 5 mg/kg	
Testosterone (ng/ml)	1.87 ± 0.04	0.55 ± 0.02*	0.89 ± 0.04* <sup>@</sup>	1.34 ± 0.07* <sup>@M</sup>	1.91 ± 0.13
LH (mIU/ml)	3.60 ± 0.13	1.41 ± 0.07*	2.27 ± 0.06* <sup>@</sup>	3.00 ± 0.10* <sup>@M</sup>	3.51 ± 0.12
FSH (mIU/ml)	2.63 ± 0.16	10.04 ± 0.34*	7.00 ± 0.11* <sup>@</sup>	5.21 ± 0.18* <sup>@M</sup>	2.82 ± 0.20

Each value is the mean ± SE,  $n = 8$ . \*Significant difference from the control,  $P \leq 0.01$ . <sup>@</sup>Significant difference from the PDC group,  $P \leq 0.01$ . <sup>M</sup>Significant difference from the PDC+melatonin 2.5 mg/kg group,  $P \leq 0.01$ .

was 1.2 ml/min, and wavelength 250 nm was applied for detection. MDA standard was prepared by dissolving 25  $\mu$ l 1,1,3,3 tetraethoxypropane (TEP) in 100 ml of water to give a 1 mM stock solution. Working standard was prepared by hydrolysis of 1 ml TEP stock solution in 50 ml 1% sulfuric acid and incubation for 2 h at room temperature. The resulting MDA standard of 20 nmol/ml was further diluted with 1% sulfuric acid to yield the final concentration of 1.25 nmol/ml to get the standard for the estimation of total MDA [31].

**2.6.2. Determination of the Testicular Tissue GSH and GSSG Levels ( $\mu$ mol/g Tissue) by HPLC.** The thiol compounds of oxidized and reduced glutathione were detected by the HPLC system. The report and chromatogram were taken from Chemstation program purchased from Agilent. 30 cm  $\times$  3.9 mm C18  $\mu$ Bondapak column was used. The flow rate was 1 ml/min, and UV detection at wavelength 190 nm was applied. 0.0025 M sodium phosphate buffer, pH 3.5, containing 0.005 M tetrabutylammonium phosphate, and 13% methanol were used as the mobile phase [32]. Samples were compared to glutathione (oxidized and reduced) reference standard purchased from Sigma Chemical Co.

**2.6.3. Determination of the Testicular Tissue NO Level ( $\mu$ mol/g Tissue) by HPLC.** Nitric oxide level (nitrate/nitrite) was determined using Agilent HP 1200 series HPLC apparatus (USA) as described above. The analytical column was anion exchange PRP-X100 Hamilton, 150  $\times$  4.1 mm, 10  $\mu$ m. The mobile phase was a mixture of 0.1 M NaCl-methanol, at a volume ratio 45:55. The flow rate of 2 ml/min, wavelength adjusted to 230 nm [33]. The resulting chromatogram identified the concentration from the sample as compared to that of the standard purchased from Sigma Aldrich.

**2.6.4. Determination of SOD, CAT, and Carnitine.** SOD activity was assayed in the homogenate by the method reported by Marklund and Marklund [34]. Enzyme activity (expressed as U/g tissue) was defined as the activity that could inhibit 50% of pyrogallol autooxidation in 1 min. Catalase activity (mmol H<sub>2</sub>O<sub>2</sub>/min/mg protein) was measured by a spectrophotometric method based on the decomposition of H<sub>2</sub>O<sub>2</sub> [35]. Carnitine (nmol/g tissue) was evaluated colorimetrically using a kit produced by Abcam, UK.

**2.7. Plasma Inflammatory Markers.** TNF- $\alpha$  (catalog no PMTA00B) and IL-6 (catalog no PR6000B) were assayed using an enzyme immunoassay kit manufactured by R&D Systems (USA).

**2.8. Histological Analysis.** The testis was fixed in 10% formaldehyde saline for 1 week. The samples were subjected to routine histology and stained with hematoxylin and eosin.

**2.9. Immunohistochemistry of p53.** Sections were deparaffinized in xylene and rehydrated. The sections were incubated with primary monoclonal antibody for p53 (code no: M7001, dilution 1:50, DAKO) at a dilution of 1:200, for 2 h at 25°C in a humidification chamber. The slides were washed three times with phosphate -buffered saline (PBS). Biotinylated polyvalent secondary antibody (Vectastain Elite ABC Kit; Vector Laboratories, Burlingame, CA) was incubated with tissue sections for 30 min. To visualize bound antibodies, sections were washed in PBS and covered with a 3,3'-diaminobenzidine substrate and incubated for 10 min. Counterstaining was performed by hematoxylin stain. Slides were examined using a light microscope ( $\times$ 400) (Olympus BX-50 Olympus Corporation, Tokyo, Japan).

**2.10. Feulgen's Reaction.** Testis sections of all groups were stained with Feulgen stain to identify DNA. Stained sections were subjected to quantitative analysis using a computerized image analyzer (Leica Qwin 500). The steps of staining are as follows:

- (1) Deparaffinize sections and hydrate through two changes each of 100% and 95% ethyl alcohols, wash well with distilled water
- (2) Hydrolyze sections in hydrochloric acid working solution at 60°C for 10 minutes
- (3) Place slides directly in Schiff Reagent, McManus for 45 minutes
- (4) Wash in running tap water for 5 minutes, rinse in distilled water
- (5) Counterstain in Light Green Stain 0.2% for 1 minute
- (6) Dehydrate in two changes each of 95% and 100% ethyl alcohol, clear in xylene

**2.11. Hormonal Assay.** Plasma testosterone (R&D Systems USA, catalog no PKGE010), luteinizing hormone (LH) (MyBioSource, USA, catalog no MBS764675), and follicle-stimulating hormone (FSH) (MyBioSource, USA, catalog no MBS2502190) levels were determined using enzyme immunoassay kits.

TABLE 5: Protective effect of melatonin on K dichromate-induced alteration of sperm characteristics.

Group Sperm parameter	Control	PDC	PDC		Melatonin 5 mg/kg
			+2.5 mg/kg melatonin	+5 mg/kg melatonin	
Sperm motility (%)	88.24 ± 5.74	36.11 ± 2.49*	62.39 ± 1.72*	76.45 ± 2.32 <sup>@M</sup>	91.44 ± 3.76
Sperm count per epididymis (×10 <sup>6</sup> )	25.49 ± 1.37	12.67 ± 0.58*	17.00 ± 0.08 <sup>@</sup>	20.91 ± 0.46 <sup>@M</sup>	23.00 ± 0.52
Sperm abnormality (%)					
Head	1.58 ± 0.06	10.81 ± 0.42*	5.11 ± 0.26 <sup>@</sup>	3.09 ± 0.04 <sup>@M</sup>	1.46 ± 0.06
Tail	2.00 ± 0.07	6.33 ± 0.35*	4.00 ± 0.08 <sup>@</sup>	2.36 ± 0.08 <sup>@M</sup>	1.93 ± 0.02
Total	3.44 ± 0.28	16.43 ± 1.07*	9.00 ± 0.23 <sup>@</sup>	5.32 ± 0.16 <sup>@M</sup>	3.28 ± 0.10

Each value is the mean ± SE, n = 8. \*Significant difference from the control, P ≤ 0.01. <sup>@</sup>Significant difference from the PDC group, P ≤ 0.01. M Significant difference from the PDC+melatonin 2.5 mg/kg group, P ≤ 0.01.

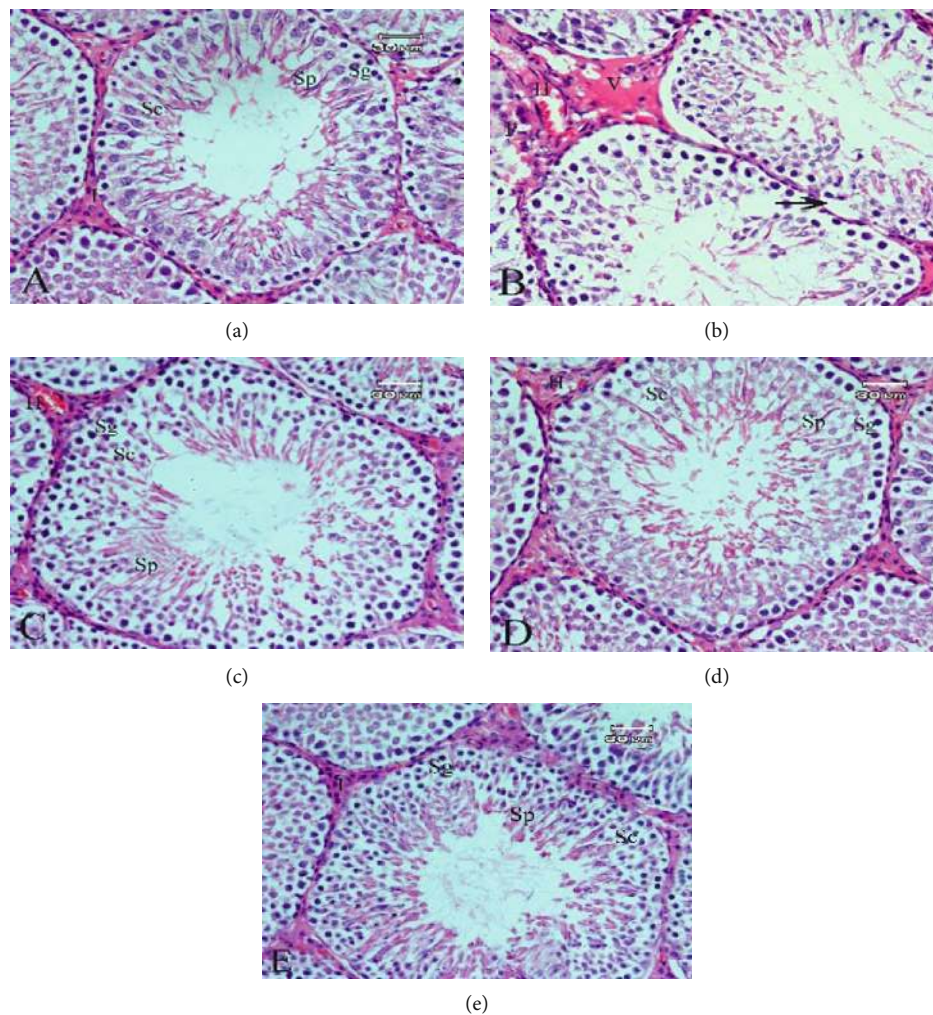


FIGURE 3: Photomicrograph of the testis section of rat stained with H&E. (a) The control group showing normal spermatogonia (Sg), spermatocytes (Sc), spermatids (Sp), and interstitial cells (I). (b) The potassium dichromate group showing degeneration of spermatogenic cells (arrow), pyknotic nuclei (P), vacuolated Leydig cells (V), and congestion of blood vessels (H). (c) The potassium dichromate and melatonin low-dose group showing partial improvement of spermatogenic cells with interstitial congestion (H). (d) The potassium dichromate and melatonin high-dose group showing the spermatogenic cells were improved. (e) The melatonin group showing normal structure (H&E: ×400).

2.12. *Sperm Characteristics.* One epididymis was cut into small pieces in warm PBS (3 ml) to obtain sperm suspension that was incubated for 10 minutes to allow for sperm disper-

sion into the buffered solution. Sperm motility was evaluated by counting motile and nonmotile spermatozoa in the same field. The count was repeated until the total sperm count



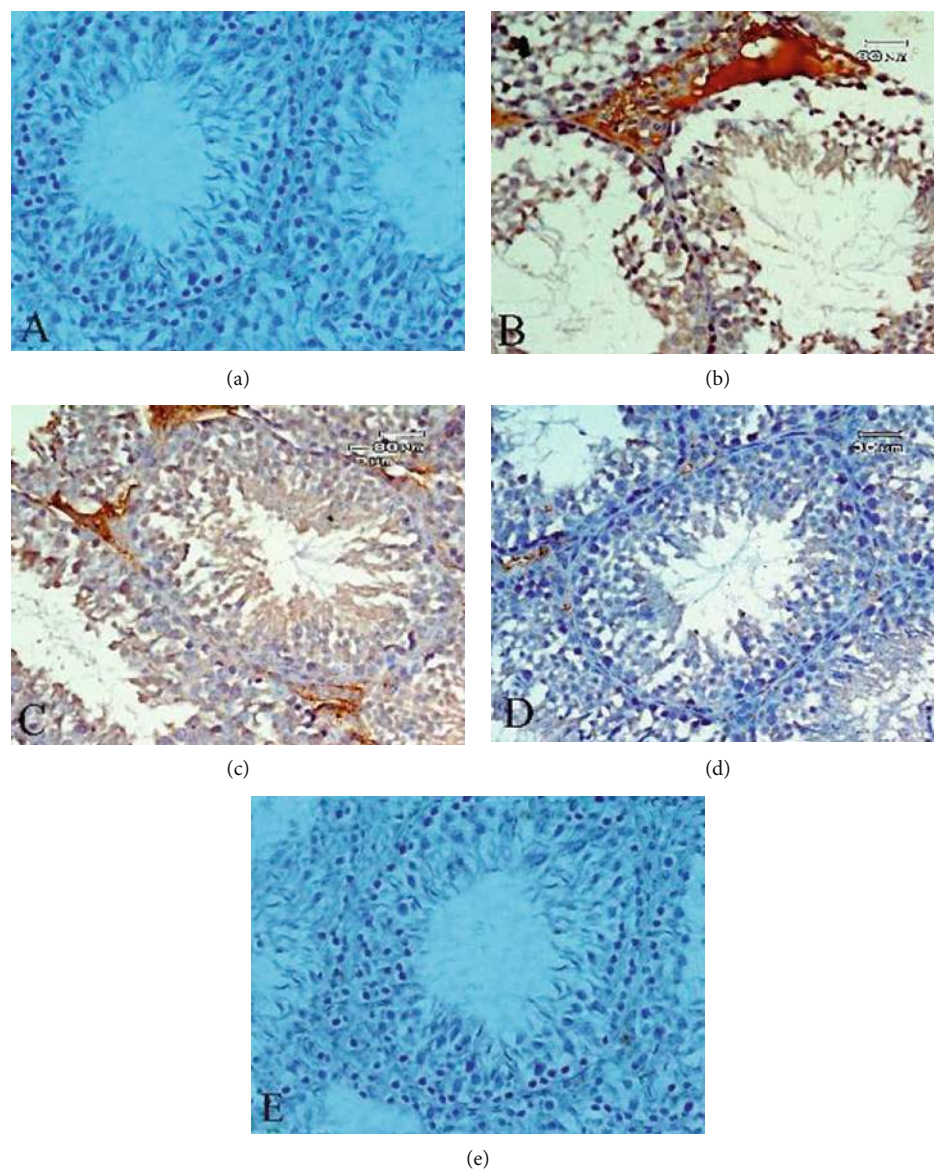


FIGURE 4: Photomicrograph of the testis section of rat stained with p53 immunohistochemical stain. Brown-stained nuclei indicates positive stain for p53. (a) The control group showing negative staining. (b) The potassium dichromate group showing increase of p53 expression in spermatogenic cells. (c) The potassium dichromate and melatonin low-dose group showing a moderate decrease of p53 reaction. (d) The potassium dichromate and melatonin high-dose group showing a marked decrease of p53 reaction. (e) The melatonin group showing negative staining (p53 immune staining:  $\times 400$ ).

was approximately 300. The percentage of motile spermatozoa was calculated. The suspension was filtered, and a fixed volume of suspension was passed through Neubauer's counting chamber hemocytometer [36] to compute the number of spermatozoa (million/1 ml). A portion of the filtrate was stained with 1% eosin to estimate the number of abnormal sperm, under a light microscope [37]. The morphological abnormalities were divided into head and tail defects. The percentages of abnormally shaped sperms were calculated.

**2.13. Statistical Analysis.** Statistical analysis of the data was performed by SPSS 17.0 (SPSS Corp., Armonk, NY, USA) using a one-way analysis of variance followed by Tukey's multiple range tests for multiple comparisons. The variance

was considered statistically significant when  $P < 0.01$ . The results were expressed as means  $\pm$  standard errors of the mean (SEM).

### 3. Results

**3.1. Body and Sexual Organ Weights.** Treatment of rats with PDC led to a significant decrease ( $P \leq 0.01$ ) in body weight at 2, 4, 6, and 8 weeks, whereas ML showed a protective effect against PDC-induced decrease in body weight (Table 1). The percentages of body weight gain were 94% (for control), 18% (for PDC group), 40% (for PDC+2.5 mg/kg ML group), and 67% (for PDC+5 mg/kg ML group) after 8 weeks. The weights of the testis, vas deferens, epididymis, prostate, and

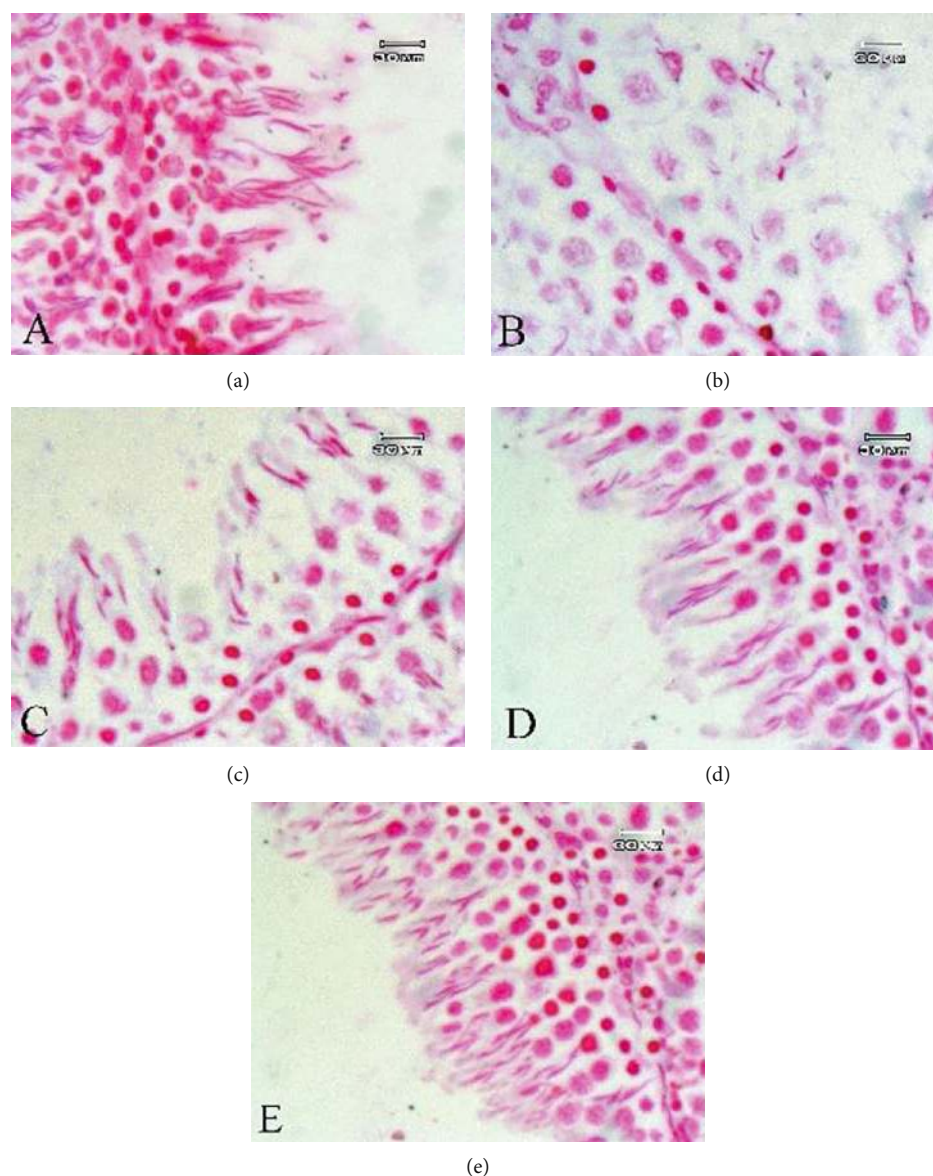


FIGURE 5: Photomicrograph of the testis section of rat stained with Feulgen's reaction to demonstrate DNA as a magenta color. (a) The control group showing normal DNA contents. (b) The potassium dichromate group showing decrease in DNA content. (c) The potassium dichromate and melatonin low-dose group showing partial restoration of DNA content. (d) The potassium dichromate and melatonin high-dose group showing restoration of DNA content. (e) The melatonin group showing nearly normal DNA contents (Feulgen's reaction:  $\times 1000$ ).

seminal vesicle decreased significantly ( $P \leq 0.01$ ) in the PDC group in comparison with control values (Table 2). The sexual organ weights of rats in the ML+PDC group were significantly higher than those of the PDC group. The administration of ML only in rats had no significant influence on all parameters tested in this study.

**3.2. Oxidative Stress Parameters.** Table 3 illustrates the role of ML in the protection against PDC-produced testicular oxidative stress. The administration of PDC to rats led to a significant increase ( $P \leq 0.01$ ) of MDA, GSSG, and NO levels relative to the control group. In contrast, there was a significant decrease in testicular GSH, CAT, SOD, and Car in the

PDC group. The treatment of ML in rats administered PDC reduced the toxic effect of PDC in tested parameters.

**3.3. Inflammatory Markers.** Results showed a significant increase ( $P \leq 0.01$ ) in plasma TNF- $\alpha$  and IL-6 levels in the PDC group which were reduced by ML treatment (Figures 1 and 2).

**3.4. Sex Hormones.** As seen in Table 4, the treatment of rats with ML mitigated the decrease of testosterone and LH levels or the increase of FSH level in the plasma due to PDC administration.

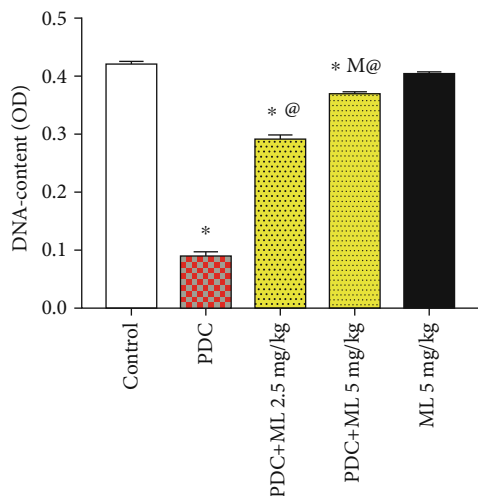


FIGURE 6: DNA content in spermatogenic cells of rats treated with melatonin and potassium dichromate. Values are expressed as means SE.  $n = 8$  per group. PDC: potassium dichromate; ML: melatonin; OD: optical density. \*Significant difference from the control,  $P \leq 0.01$ . @Significant difference from PDC,  $P \leq 0.01$ . MSignificant difference from ML 2.5 mg/kg,  $P \leq 0.01$ .

**3.5. Sperm Characteristics.** The rats administered PDC displayed a significant decrease in sperm motility and/or sperm count with a significant increase in sperm abnormalities (Table 5). The treatment of rats with ML alleviated the adverse effects of PDC on sperm parameters.

**3.6. Histopathological Results.** Rats treated with PDC showed many histopathological changes, including disorganization and degeneration of spermatogenic cells, and decreased spermatogenic layers in most seminiferous tubules and atrophy. Pyknotic nuclei, vacuolated Leydig cells, and congestion of blood vessels were also observed (Figure 3(b)). Furthermore, compared with control treatment (Figure 3(a)), PDC induced a pronounced alteration of the spermatogenic process with remarkable reductions of spermatozoa produced in the lumen of the seminiferous tubules (Figure 3(b)). These histopathological changes including degeneration of spermatogenic cells were reduced in the rats treated with PDC and ML in a dose-dependent manner. However, interstitial congestion was still observed in these rats (Figures 3(c) and 3(d)).

**3.7. Immunohistochemistry.** Rats treated with PDC showed an increase in p53 expression in spermatogenic cells (Figure 4(b)). p53 expression was decreased in the PDC and ML (low and high) group (Figures 4(c) and 4(d)) in a dose-dependent manner.

**3.8. Histochemical Result of Feulgen's Reaction.** Rats treated with PDC exhibited a decrease in DNA content of spermatogenic cells (Figure 5(b)) compared with rats treated under control conditions (Figure 5(a)). Rats treated with PDC and ML at a high dose showed restoration of DNA content in the testis tissue which was comparable with that observed in the control (Figure 5(d)), whereas rats in the PDC and ML (low-dose) group showed partial restoration of DNA

content (Figure 5(c)). These results were confirmed with that in Figure 6, since rats treated with PDC revealed a decrease in DNA content of spermatogenic cells (Figure 6) compared with control rats.

#### 4. Discussion

Chromium, one of the most abundant elements in the earth's surface, has been reported to negatively impact spermatogenesis via the stimulation of oxidative stress [38]. Therefore, supplementation with antioxidants may be beneficial to maintain spermatogenesis [39]. It has been reported that ML has protective properties against doxorubicin-, acetylsalicylic acid-, and diabetes-induced impairment of male reproductive function and oxidative stress [14, 40, 41]. In the present study, we examined the protective effects of ML against PDC-motivated testicular damage, oxidative stress, inflammation, and histopathological alterations. The results of the present study demonstrated testicular oxidative stress as a consequence of oral administration of PDC daily for 8 weeks in rats. In the present study, the evidence for oxidative stress triggered by PDC was the significant increase of testicular MDA, NO, and GSSG. Moreover, testicular SOD, CAT, GSH, and Car were significantly reduced in the PDC group compared with those in the control group. These results are compatible with those of previous studies showing that PDC treatment results in oxidative stress which leads to testicular dysfunction [42, 43]. It is well known that SOD, CAT, and GSH play vital roles in reducing free radicals and maintaining antioxidant homeostasis in tissues [44, 45]. In the present study, elevated levels of MDA in the testes of rats exposed to PDK indicate oxidative injury possibly due to the inability of the antioxidant enzymes to scavenge the oxidants generated in the testicular tissue. MDA is a stable end-product of lipid peroxidation which is well known to be an indirect indicator of increased intracellular ROS generation [46].

Lipid peroxidation leads to free radical reaction propagation that may affect membrane integrity and result in cell death [47]. In the present work, sperm characteristics were affected by PDC, which was shown by an increase of sperm abnormalities and a decrease of sperm motility and count. It was concluded that lipid peroxidation of the sperm membrane can lead to sperm dysfunction and infertility [48]. Spermatozoa are rich in polyunsaturated fatty acids and a decline in antioxidant enzymes in the testis may increase the sensibility of spermatozoa to damage by the free radicals leading to decreased sperm motility and density [49]. Reactive oxygen species generated during chromium reduction [17] may lower spermatozoa motility by affecting the phosphorylation of axonemal proteins essential for the spermatozoa movement [50]. Moreover, the damaged mitochondrial DNA by ROS leads to decreased ATP and energy availability or activation of caspases and ultimately apoptosis, hindering spermatozoa motility [51, 52]. Since, high serum FSH level was observed in patients with low sperm counts [53], it can be postulated that decreased sperm count by PDC was associated with disabled steroidogenesis and elevation of serum FSH level. The elevated FSH level in the PDC group



is likely due to a decrease in inhibin production by Sertoli cells that affect negative feedback on the hypothalamic-pituitary axis [54].

It was concluded that the increased oxidative stress had an adverse effect on testicular function and sperm quality by perturbation of the antioxidant systems [55]. This study demonstrated that coadministration of ML with PDC lowered the testicular oxidative stress shown by a decrease of MDA levels and enhanced SOD, CAT, GSH, and Car levels. Carnitine can participate to the antioxidant defenses either by inhibiting enzymes responsible for free radical production, by maintaining the integrity of electrontransport chain of mitochondria in stress conditions or by direct scavenging of free radical. Carnitine can also share in the maintenance of optimal redox status of the cell by stimulating antioxidant enzymes and nonenzymatic antioxidants, mainly via transcription factors, including Nrf2 and NF- $\kappa$ B [56]. Here, the results demonstrated that the treatment of rats with ML could efficiently protect against testicular lipid peroxidation and oxidative stress induced by PDC. ML utilizes antioxidant effects by suppressing the production of ROS and intracellular oxidative stress, and/or through the activation of antioxidant enzymes. Furthermore, ML can scavenge oxygen radicals directly [57]. Here, ML alleviated the decrease in sperm count and motility or the increase in sperm abnormalities evoked by PDC. It was previously reported that ML decreased lipid peroxidation in the semen and lowered the ratio of polyunsaturated fatty acids in the sperm membrane lipid composition without affecting fertility [58]. Moreover, ML has the potential to reduce disturbance in spermatogenesis produced by PDC through maintaining testosterone and LH levels that are pivotal for normal spermatogenesis [59]. Moreover, ML preserves spermatogenic cells, Leydig cells, and the histoarchitecture of the rats administered PDC which may indicate the ability of ML in reducing the reproductive damages caused by PDC that affect male fertility through oxidative damage. ML mitigated the decrease in the reproductive organ weights evoked by PDC treatment in rats which may be due to its protective effect on testosterone that is responsible for the growth of male reproductive organs [60]. The protective mechanism of ML against PDC encouraged testicular toxicity and infertility may also involve a decrease in the levels of inflammation markers, cytokines (TNF- $\alpha$  and IL-6), and nitric oxide. TNF- $\alpha$  has been demonstrated to inhibit steroidogenesis in Leydig cells at the transcriptional level [61]. Inflammation affects male fertility as it has been associated with elevated levels of ROS and oxidative stress [62]. It was previously reported that ML maintained spermatogenesis through a decrease in serum inflammatory cytokine levels in diabetic rats [63].

Elevated oxidative stress impacts the physiological function of the interstitial cells of Leydig, which plays a crucial role in synthesis of testosterone [64]. Interstitial hemorrhage and vacuolated Leydig cells were observed in the rats treated with PDC. The reduction in observed testosterone concentration in the PDC group can be assigned to the deformed Leydig cells and a decline of LH level. Moreover, the diminution of testosterone production due to PDC treatment can be attributed to an increase of testicular nitric oxide or TNF- $\alpha$

that restrain steroidogenesis in Leydig cells at the transcriptional level of steroidogenic enzymes via activation of nuclear factor  $\kappa$ B (NF- $\kappa$ B) [61, 65].

Histochemical analysis in the present study showed that the treatment of rats with PDC led to a decrease in DNA content of spermatogenic cells which may result from the inhibition of DNA replication [66]. In contrast, ML was found to inhibit PDC-induced decrease of spermatogenic DNA. ML might be beneficial in reducing oxidative tissue and DNA damage induced by formaldehyde [67]. Moreover, ML mitigated PDC-induced elevation of spermatogenic p53 expression. Moreover, melatonin mitigated the elevation of spermatogenic p53 expression due to PDC. Therefore, p53 may represent a risk factor for male infertility [68]. Our results suggest that the protective effect of ML illustrated in this study has primarily resulted from its antioxidant activity, including its ability to enhance antioxidant defense systems and decrease the level of lipid peroxidation products.

In conclusion, our finding proved promise protective effects of ML against potassium dichromate-created testicular toxicity, alteration of sperm parameters or sexual hormones, inflammation, and oxidative stress in rats. Besides, the protective effects of melatonin may be due to both the inhibition of lipid peroxidation and the increase in antioxidant activity. These findings suggest that melatonin is a useful protective agent against antifertility induced by potassium dichromate. However, this therapeutic impact of ML needs to be intensively investigated in the future study that focuses on patient-oriented outcomes.

## Data Availability

The data used to support the findings of this study are available from the corresponding author upon request.

## Conflicts of Interest

The authors declare no conflict of interest.

## Acknowledgments

This work was supported by the Researchers Supporting Project number RSP-2020/225, King Saud University, Riyadh, Saudi Arabia. The authors also thank the Deanship of Scientific Research and RSSU at King Saud University for their technical support.

## References

- [1] R. J. Reiter, D. X. Tan, and L. Fuentes-Broto, "Melatonin: A Multitasking Molecule," *Progress in Brain Research*, vol. 181, pp. 127–151, 2010.
- [2] S. R. Pandi-Perumal, I. Trakht, V. Srinivasan et al., "Physiological effects of melatonin: role of melatonin receptors and signal transduction pathways," *Progress in Neurobiology*, vol. 85, no. 3, pp. 335–353, 2008.
- [3] R. J. Reiter, J. C. Mayo, D. X. Tan, R. M. Sainz, M. Alatorre-Jimenez, and L. Qin, "Melatonin as an antioxidant: under promises but over delivers," *Journal of Pineal Research*, vol. 61, no. 3, pp. 253–278, 2016.

- [4] M. Sánchez-Hidalgo, J. M. Guerrero, I. Villegas, G. Packham, and C. A. de la Lastra, "Melatonin, a natural programmed cell death inducer in cancer," *Current Medicinal Chemistry*, vol. 19, no. 22, pp. 3805–3821, 2012.
- [5] R. A. Kireev, A. C. Tresguerres, C. Garcia, C. Ariznavarreta, E. Vara, and J. A. F. Tresguerres, "Melatonin is able to prevent the liver of old castrated female rats from oxidative and pro-inflammatory damage," *Journal of Pineal Research*, vol. 45, no. 4, pp. 394–402, 2008.
- [6] S. Comai and G. Gobbi, "Unveiling the role of melatonin MT2 receptors in sleep, anxiety and other neuropsychiatric diseases: a novel target in psychopharmacology," *Journal of Psychiatry & Neuroscience*, vol. 39, no. 1, pp. 6–21, 2014.
- [7] A. Sánchez, A. C. Calpena, and B. Clares, "Evaluating the oxidative stress in inflammation: role of melatonin," *International Journal of Molecular Sciences*, vol. 16, no. 8, pp. 16981–17004, 2015.
- [8] A. Bukowska, "Anticarcinogenic role of melatonin–potential mechanisms," *Medycyna Pracy*, vol. 62, no. 4, pp. 425–434, 2011.
- [9] D. P. Cardinali, L. I. Brusco, C. Liberchuk, and A. M. Furio, "The use of melatonin in Alzheimer's disease," *Neuro Endocrinology Letters*, vol. 1, pp. 20–23, 2002.
- [10] B. Prunet-Marcassus, M. Desbazeille, A. Bros et al., "Melatonin reduces body weight gain in Sprague Dawley rats with diet-induced obesity," *Endocrinology*, vol. 144, no. 12, pp. 5347–5352, 2003.
- [11] A. Dominguez-Rodriguez, "Melatonin in cardiovascular disease," *Expert Opinion on Investigational Drugs*, vol. 21, no. 11, pp. 1593–1596, 2012.
- [12] H. Ebaid, S. A. E. Bashandy, A. M. Abdel-Mageed, J. Al-Tamimi, I. Hassan, and I. Alhazza, "Folic acid and melatonin mitigate diabetic nephropathy in rats via inhibition of oxidative stress," *Nutrition & Metabolism*, vol. 17, pp. 1–14, 2020.
- [13] H. Ebaid, S. A. E. Bashandy, I. M. Alhazza, A. Rady, and S. El-Shehry, "Folic acid and melatonin ameliorate carbon tetrachloride-induced hepatic injury, oxidative stress and inflammation in rats," *Nutrition & Metabolism*, vol. 2013, p. 20, 2013.
- [14] N. H. Emami, F. M. Lafout, and F. M. Ghasemi, "Administration of melatonin protects against acetylsalicylic acid-induced impairment of male reproductive function in mice," *Iranian journal of basic medical sciences*, vol. 21, no. 2, pp. 124–129, 2018.
- [15] Y. Wang, T. T. Zhao, H. Y. Zhao, and H. Wang, "Melatonin protects methotrexate-induced testicular injury in rats," *European Review for Medical and Pharmacological Sciences*, vol. 22, no. 21, pp. 7517–7752, 2018.
- [16] J. Espino, I. Bejarano, A. Ortiz et al., "Melatonin as a potential tool against oxidative damage and apoptosis in ejaculated human spermatozoa," *Fertility and Sterility*, vol. 94, no. 5, pp. 1915–1917, 2010.
- [17] J. Espino, A. Ortiz, I. Bejarano et al., "Melatonin protects human spermatozoa from apoptosis via melatonin receptor- and extracellular signal regulated kinase-mediated pathways," *Fertility and Sterility*, vol. 95, no. 7, pp. 2290–2296, 2011.
- [18] R. J. Aitken and S. D. Roman, "Antioxidant systems and oxidative stress in the testes," *Oxidative Medicine and Cellular Longevity*, vol. 1, no. 1, 24 pages, 2008.
- [19] D. Bagchi, S. J. Stohs, B. W. Downs, M. Bagchi, and H. G. Preuss, "Cytotoxicity and oxidative mechanisms of different forms of chromium," *Toxicology*, vol. 180, no. 1, pp. 5–22, 2002.
- [20] M. D. Stout, R. A. Herbert, G. E. Kissling et al., "Hexavalent chromium is carcinogenic to F344/N rats and B6C3F1 mice after chronic oral exposure," *Environmental Health Perspectives*, vol. 117, no. 5, pp. 716–722, 2009.
- [21] J. Pedraza-Chaverri, D. Barrera, O. N. Medina-Campos et al., "Time course study of oxidative and nitrosative stress and antioxidant enzymes in K2Cr2O7-induced nephrotoxicity," *BMC Nephrology*, vol. 6, p. 4, 2005.
- [22] A. A. Shati, "Ameliorative effect of vitamin E on potassium dichromate-induced hepatotoxicity in rats," *Journal of King Saud University-Science*, vol. 26, no. 3, pp. 181–189, 2014.
- [23] M. Neghab, P. Azad, M. Honarbakhsh, F. Zarei, and E. Ghaderi, "Acute and chronic respiratory effects of chromium mists," *Journal of Health Sciences & Surveillance System*, vol. 3, no. 3, pp. 119–124, 2015.
- [24] C.-C. Lin, M.-L. Wu, C.-C. Yang, J. Ger, W.-J. Tsai, and J.-F. Deng, "Acute severe chromium poisoning after dermal exposure to hexavalent chromium," *Journal of the Chinese Medical Association*, vol. 72, no. 4, pp. 219–221, 2009.
- [25] S. I. Nudler, F. A. Quinteros, E. A. Miler, J. P. Cabilla, S. A. Ronchetti, and B. H. Duvilanski, "Chromium VI administration induces oxidative stress in hypothalamus and anterior pituitary gland from male rats," *Toxicology Letters*, vol. 185, no. 3, pp. 187–192, 2009.
- [26] S. Bashandy, O. Ahmed-Farid, E. A. Omara, S. A. El-Toumy, and J. Y. Salib, "Protective effect of Citrus reticulata peel extract against potassium dichromate induced reproductive toxicity in rats," *Asian Pacific Journal of Reproduction*, vol. 8, no. 6, pp. 267–275, 2019.
- [27] S. Stohs, J. Bagghid, E. Hassoun, and M. Bagghi, "Oxidative mechanisms in the toxicity of chromium and cadmium ions," *Journal of Environmental Pathology, Toxicology and Oncology*, vol. 20, no. 2, pp. 77–88, 2001.
- [28] M. V. Rao, S. S. Parekh, and S. L. Chawla, "Vitamin E supplementation ameliorates chromium- and/or nickel induced oxidative stress in vivo," *Journal of Health Science*, vol. 52, no. 2, pp. 142–147, 2006.
- [29] A. Chabra, M. Shokrzadeh, F. Naghshvar, F. Salehi, and A. Ahmadi, "Melatonin ameliorates oxidative stress and reproductive toxicity induced by cyclophosphamide in male mice," *Human & Experimental Toxicology*, vol. 33, no. 2, pp. 185–195, 2013.
- [30] M.-H. Perrard, N. Sereni, C. Schluth-Bolard et al., "Complete human and rat ex vivo spermatogenesis from fresh or frozen testicular tissue," *Biology of Reproduction*, vol. 95, no. 4, pp. 1–10, 2016.
- [31] F. Karatas, M. Karatepe, and A. Baysar, "Determination of free malondialdehyde in human serum by high-performance liquid chromatography," *Analytical Biochemistry*, vol. 311, no. 1, pp. 76–79, 2002.
- [32] T. Yoshida, "Determination of reduced and oxidized glutathione in erythrocytes by high-performance liquid chromatography with ultraviolet absorbance detection," *Journal of Chromatography. B, Biomedical Applications*, vol. 678, no. 2, pp. 157–164, 1996.
- [33] I. N. Papadoyannis, V. F. Samanidou, and C. C. Nitsos, "Simultaneous determination of nitrite and nitrate in drinking water and human serum by high performance anion-exchange chromatography and uv detection," *Journal of Liquid*

- Chromatography and Related Technologies*, vol. 22, no. 13, pp. 2023–2041, 1999.
- [34] S. Marklund and G. Marklund, "Involvement of the superoxide anion radical in the autoxidation of pyrogallol and a convenient assay for superoxide dismutase," *European Journal of Biochemistry*, vol. 47, no. 3, pp. 469–474, 1974.
- [35] H. Aebi, "Catalase in vitro," *Methods in Enzymology*, vol. 105, pp. 121–216, 1984.
- [36] K. Narayana, N. Prashanthi, A. Nayanatara, H. H. Kumar, K. Abhilash, and K. L. Bairy, "Effects of methyl parathion (o,o-dimethyl o-4-nitrophenyl phosphorothioate) on rat sperm morphology and sperm count, but not fertility, are associated with decreased ascorbic acid level in the testis," *Mutation Research*, vol. 588, no. 1, pp. 28–34, 2005.
- [37] A. J. Wyrobek and W. R. Bruce, "Chemical induction of sperm abnormalities in mice," *Proceedings of the National Academy of Sciences of the United States of America*, vol. 72, no. 11, pp. 4425–4429, 1975.
- [38] M. M. Aruldas, S. P. Subramanian, G. Vengatesh, G. Chandrasaran, P. Govindarajulu, and M. A. Akbarsha, "Chronic chromium exposure-induced changes in testicular histoarchitecture are associated with oxidative stress: study in a non-human primate (*Macaca radiata* Geoffroy)," *Human Reproduction*, vol. 20, no. 10, pp. 2801–2813, 2005.
- [39] N. Asadi, M. Bahmani, A. Kheradmand, and M. Rafieian-Kopae, "The impact of oxidative stress on testicular function and the role of antioxidants in improving it: a review," *Journal of Clinical and Diagnostic Research*, vol. 11, no. 5, pp. IE01–IE05, 2017.
- [40] K.-M. Lee, I.-C. Lee, S.-H. Kim et al., "Melatonin attenuates doxorubicin-induced testicular toxicity in rats," *Andrologia*, vol. 44, pp. 796–803, 2012.
- [41] M. G. Gobbo, C. F. Costa, D. G. Silva, E. A. de Almeida, and R. M. Góes, "Effect of melatonin intake on oxidative stress biomarkers in male reproductive organs of rats under experimental diabetes," *Oxidative medicine and cellular longevity*, vol. 2015, Article ID 614579, 2015.
- [42] N. Marouani, O. Tebourbi, D. Hallègue et al., "Mechanisms of chromium hexavalent-induced apoptosis in rat testes," *Toxicology and Industrial Health*, vol. 33, no. 2, pp. 97–106, 2015.
- [43] M. Rasool, K. Zaigham, A. Malik et al., "Potential reproductive health effects and oxidative stress associated with exposure to potassium dichromate (K<sub>2</sub>Cr<sub>2</sub>O<sub>7</sub>) and magnesium sulphate (MgSO<sub>4</sub>) in male mice," *Pakistan Journal of Medical Sciences*, vol. 30, no. 4, pp. 819–823, 2014.
- [44] O. M. Ighodaro and O. A. Akin, "First line defence antioxidants-superoxide dismutase(SOD), catalase (CAT) and glutathione peroxidase(GPX): their fundamental role in the entire antioxidant defence grid," *Alexandria Journal of Medicine*, vol. 54, no. 4, pp. 287–293, 2018.
- [45] S. C. Lu, "Regulation of hepatic glutathione synthesis: current concepts and controversies," *The FASEB Journal*, vol. 1, pp. 1169–1175, 1999.
- [46] D. A. Cherian, T. Peter, A. Narayanan, S. S. Madhavan, S. Achammada, and G. P. Vynat, "Malondialdehyde as a marker of oxidative stress in periodontitis patients," *Journal of Pharmacy & Bioallied Sciences*, vol. 11, Supplement 2, pp. S297–S300, 2019.
- [47] A. Ayala, M. F. Muñoz, and S. Argüelles, "Lipid peroxidation: production, metabolism, and signaling mechanisms of malondialdehyde and 4-hydroxy-2-nonenal," *Oxidative Medicine and Cellular Longevity*, vol. 2014, Article ID 360438, 2014.
- [48] A. Atessahin, E. Sahna, G. Turk et al., "Chemoprotective effect of melatonin against cisplatin-induced testicular toxicity in rats," *Journal of Pineal Research*, vol. 41, no. 1, pp. 21–27, 2006.
- [49] S. C. Sikka, "Role of oxidative stress and antioxidants in andrology and assisted reproductive technology," *Journal of Andrology*, vol. 25, no. 1, pp. 5–18, 2004.
- [50] E. De Lamirande and C. Gagnon, "Reactive oxygen species and human spermatozoa. I. Effects on the motility of intact spermatozoa and on sperm axonemes," *Journal of Andrology*, vol. 13, no. 5, pp. 368–378, 1992.
- [51] Y. J. Menezo, A. Hazout, G. Panteix, F. Robert, J. Rollet, and P. Cohen-Bacrie, "Antioxidants to reduce sperm DNA fragmentation: an unexpected adverse effect," *Reproductive Bio-Medicine Online*, vol. 14, no. 4, pp. 418–421, 2007.
- [52] J. Gual-Frau, C. Abad, M. J. Amengual, N. Hannaoui, M. A. Checa, and J. Ribas-Maynou, "Oral antioxidant treatment partly improves integrity of human sperm DNA in infertile grade I varicocele patients," *Human Fertility*, vol. 18, no. 3, pp. 225–229, 2015.
- [53] H. Li, Q. Chen, S. Li et al., "Effect of Cr(VI) exposure on sperm quality: human and animal studies," *The Annals of Occupational Hygiene*, vol. 45, no. 7, pp. 505–511, 2001.
- [54] M. L. Pereira, T. M. Santos, R. P. das Neves, F. G. Costa, and J. P. de Jesus, "Cr (V) involvement in the toxicity pathway of testicular damage," *Asian Journal of Andrology*, vol. 4, no. 2, pp. 153–155, 2002.
- [55] I. A. Adedara, A. O. Abolaji, B. E. Odion, A. A. Omolaja, I. J. Okwudi, and E. O. Farombi, "Redox status of the testes and sperm of rats following exposure to 2,5-hexanedione," *Redox Report*, vol. 21, no. 6, pp. 239–247, 2016.
- [56] P. F. Surai, "Antioxidant action of carnitine: molecular mechanisms and practical applications," *Veterinary Science*, vol. 2, no. 1, pp. 66–84, 2015.
- [57] M. Moniruzzaman, I. Ghosal, D. Das, and S. B. Chakraborty, "Melatonin ameliorates H<sub>2</sub>O<sub>2</sub>-induced oxidative stress through modulation of Erk/Akt/ NFκB pathway," *Biological Research*, vol. 51, p. 17, 2018.
- [58] M. Meamar, A. Z. Shahneh, M. J. Zamiri et al., "Preservation effects of melatonin on the quality and fertility of native Fars rooster semen during liquid storage," *Czech Journal of Animal Science*, vol. 61, no. 1, pp. 42–48, 2016.
- [59] S. Ramaswamy and G. F. Weinbauer, "Endocrine control of spermatogenesis: role of FSH and LH/ testosterone," *Spermatogenesis*, vol. 4, no. 2, article e996025, 2014.
- [60] G. R. Dohle, M. Smit, and R. F. Weber, "Androgens and male fertility," *World Journal of Urology*, vol. 21, no. 5, pp. 341–345, 2003.
- [61] C. Y. Hong, J. H. Park, R. S. Ahn et al., "Molecular mechanism of suppression of testicular steroidogenesis by proinflammatory cytokine tumor necrosis factor alpha," *Molecular and Cellular Biology*, vol. 24, no. 7, pp. 2593–2604, 2004.
- [62] O. Sarkar, J. Bahrainwala, S. Chandrasekaran, S. Kothari, P. P. Mathur, and A. Agarwal, "Impact of inflammation on male fertility," *Frontiers in Bioscience*, vol. 1, no. 3, pp. 89–95, 2011.
- [63] A. Bozkurt, M. Karabakan, M. Aydin et al., "Effects of melatonin treatment on the spermatogenesis and serum inflammatory cytokine levels in diabetic rats," *Annals of Medical Research*, vol. 26, no. 1, pp. 12–16, 2019.

- [64] R. T. W. Holdcraft and R. T. E. Braun, "Hormonal regulation of spermatogenesis," *International Journal of Andrology*, vol. 27, no. 6, pp. 335–342, 2004.
- [65] V. P. Singh and C. M. Chaturvedi, "Correlation of nitric oxide and testicular activity in laboratory mouse, *Mus musculus*," *International Journal of Innovative Science, Engineering and Technology*, vol. 2, no. 3, pp. 721–729, 2013.
- [66] T. O'Brien, J. Xu, and S. R. Patierno, "Effects of glutathione on chromium-induced DNA crosslinking and DNA polymerase arrest," *Molecular and Cellular Biochemistry*, vol. 222, no. 1/2, pp. 173–182, 2001.
- [67] S. Aydemir, S. G. Akgun, A. Beceren et al., "Melatonin ameliorates oxidative DNA damage and protects against formaldehyde-induced oxidative stress in rats," *International Journal of Clinical and Experimental Medicine*, vol. 10, no. 4, pp. 6250–6261, 2017.
- [68] T. L. Beumer, H. L. Roepers-Gajadien, I. S. Gadema, and P. W. van Buul, "The role of the tumor suppressor p53 in spermatogenesis," *Cell Death & Differentiation*, vol. 5, no. 8, pp. 669–677, 1998.