

Memory for object features versus memory for object location: A positron-emission tomography study of encoding and retrieval processes

ADRIAN M. OWEN*, BRENDA MILNER, MICHAEL PETRIDES, AND ALAN C. EVANS

Montreal Neurological Institute, McGill University, Montreal, QC, Canada H3A 2B4

Contributed by Brenda Milner, May 15, 1996

ABSTRACT Regional cerebral blood flow was measured with positron-emission tomography during two encoding and two retrieval tasks that were designed to compare memory for object features with memory for object locations. Bilateral increases in regional cerebral blood flow were observed in both anterior and posterior regions of inferior temporal cortex and in ventral regions of prefrontal cortex, when the condition that required retrieval of object locations was subtracted from the condition that required retrieval of object features. During encoding, these changes were less pronounced and were restricted to the left inferior temporal cortex and right ventral prefrontal cortex. In contrast, both encoding and retrieval of object location were associated with bilateral changes in dorsal prefrontal and posterior parietal cortex. Finally, the two encoding conditions activated left frontal lobe regions preferentially, whereas the two retrieval conditions activated right frontal lobe regions. These findings confirm that, in human subjects, memory for object features is mediated by a distributed system that includes ventral prefrontal cortex and both anterior and posterior regions of the inferior temporal gyrus. In contrast, memory for the locations of objects appears to be mediated by an anatomically distinct system that includes more dorsal regions of prefrontal cortex and posterior regions of the parietal lobe.

Evidence from the study of patients has suggested that lateral inferotemporal regions play a critical role in memory for the characteristic features of objects (1, 2). Related studies in the monkey have demonstrated that bilateral excision of the anterior portion of the inferotemporal cortex (area TE) produces recognition-memory impairments that are restricted to the visual characteristics of objects (3, 4). Lesions restricted to the perirhinal cortex and the parahippocampal gyrus (5, 6) or to the perirhinal cortex alone (7) also produce profound deficits on visual object-recognition tasks.

The above studies suggest that both medial (i.e., perirhinal) and inferotemporal regions of anterior temporal cortex are involved in memory for the visual features of objects. A number of issues remain to be resolved. First, the impairment in memory for figurative detail observed after right anterior temporal lobectomy appears to depend on the interpolation of a short delay between stimulus presentation and recall (2). This finding suggests a more critical role for the anterior temporal region in the maintenance and retrieval of object features than in the initial encoding of this information. Second, on the basis of the patient data alone, it is difficult to assign any specific role to particular parts of the anterior temporal lobe because the anterior temporal resection typically includes both the lateral temporal neocortex and the more medial perirhinal cortex, together with the amygdala and varying amounts of the hippocampus and parahippocampal gyrus. Finally, while the lesion studies described above favor a

central role for the anterior temporal region in memory for object identity, the precise nature of this involvement and its dependence on functional interactions with other cortical areas remains unclear. Ungerleider and Mishkin (8) have suggested that, in nonhuman primates, extrastriate cortical areas are organized into two anatomically distinct pathways, functionally specialized for identifying objects (the occipitotemporal pathway or “ventral stream”) or spatial locations (the occipitoparietal pathway or “dorsal stream”) (see also refs. 9 and 10). It seems likely that the posterior neocortical regions that are specialized for the perceptual analysis of objects or spatial location may also participate in memory for that same type of information (4, 11, 12). The results of several recent functional imaging studies also suggest that specific regions of the frontal lobe may participate in encoding and retrieval of information held in long-term memory (13–16), although no deficits in object recognition memory are observed after frontal lobe damage in patients (e.g., refs. 1 and 2) or monkeys (e.g., refs. 17 and 18).

The present positron-emission tomography (PET) study was designed to investigate these issues further with four tasks that emphasized encoding or retrieval for object features or object location. On the basis of the work in humans and monkeys, it was predicted that both the perirhinal cortex and the inferior temporal cortex would be involved when the subjects were required to remember information about the visual properties of objects. In addition, given previous findings in patients (2), we hypothesized that this involvement would be more salient in the right, than in the left, anterior temporal region and that it would be more evident during the retrieval than during the encoding of object features. In contrast, we hypothesized that encoding and retrieval of object location would preferentially activate the hippocampus and related structures, as well as regions of the posterior parietal cortex. Furthermore, we predicted that a dissociation between the ventral and dorsal processing systems would be evident in regions of striate and prefrontal cortex associated with the early processing of information relating to objects or spatial location, respectively. Finally, by using an object features paradigm that minimizes verbal mediation, the experimental design allowed us to test the generality of recent proposals, derived from verbal paradigms, that encoding and retrieval differentially involve left and right frontal lobe regions (15, 16).

METHODS

Subjects. Six male and six female right-handed undergraduate volunteers with no history of neurological or psychiatric illness participated in the study. Each subject underwent seven 60-sec PET scans within a single session and a magnetic resonance imaging (MRI) scan on a different day. Four of the seven

Abbreviations: PET, positron-emission tomography; CBF, cerebral blood flow; rCBF, regional CBF.

*To whom reprint requests should be addressed at: Neuropsychology/Cognitive Neuroscience Unit, Montreal Neurological Institute, 3801 University Street, Montreal, QC, Canada H3A 2B4.

The publication costs of this article were defrayed in part by page charge payment. This article must therefore be hereby marked “advertisement” in accordance with 18 U.S.C. §1734 solely to indicate this fact.

scanning conditions administered pertain to the current study and will be described here. The ages of the subjects ranged from 18 to 35 years (mean age, 26.8 years). All subjects gave informed, written consent for participation in the study after its nature and possible consequences had been explained to them. The study was approved by the Research Ethics Committee of the Montreal Neurological Institute and Hospital.

Scanning Methods and Data Analysis. PET scans were obtained with the Scanditronix (Uppsala) model PC-2048 system, which produces 15 image slices at an intrinsic resolution of $5.0 \times 5.0 \times 6.0$ mm (19). Regional cerebral blood flow (rCBF) was measured with the bolus $H_2^{15}O$ methodology (20). For each subject, a high-resolution MRI (160 sagittal slices, 1-mm thick) was also obtained and resliced so as to be coregistered with the PET data (21). The PET data were normalized for global CBF value, averaged across subjects for each activation state, and the mean CBF change image was obtained (22) and converted to a *t* statistic volume (23). Composite stereotaxic MRI and PET volumes were merged to allow direct anatomical localization of regions with a high *t* value. The significance of a given change in rCBF was assessed by a method based on three-dimensional Gaussian random-field theory (23). The threshold for reporting a peak as significant was set at $t = 3.5$, corresponding to an uncorrected probability of $P < 0.0002$ (one-tailed). We also carried out a directed search for predicted frontal activation foci in the comparisons between the encoding and retrieving conditions and, for these analyses, the threshold for significance was set at $t = 3.00$, corresponding to an uncorrected probability of $P < 0.0013$.

Experimental Procedure. The stimuli used in all four experimental conditions were white squares (5×5 cm), containing digitized representational drawings of common objects, presented against a black background, on a high-resolution, touch-sensitive screen (39×29 cm) (see Fig. 1). The screen was suspended ≈ 50 cm above the subject and was therefore within comfortable reach. In two of the conditions, which we refer to as *Encoding Object Features* and *Retrieving Object Features*, the drawings were always presented either in the center of the screen (encoding object features) or to the left and right of the center position (retrieving object features). In the other two conditions, which we refer to as *Encoding Object Location* and *Retrieving Object Location*, the drawings were presented in various locations on the screen, although, to discourage verbal labeling of spatial location, the four corners of the monitor and positions immediately adjacent to the edge of the screen were not used in either condition. In each condition, the same locations or objects were used for all subjects, although the order in which the stimuli were presented was randomly varied. The order in which the Object Location and the Object Features conditions were administered across scans was also randomized for the different subjects, with the necessary restriction that each of the retrieval tasks was presented during the scan immediately following the corresponding encoding condition. Each PET scan lasted 60 sec, and testing on each condition was initiated ≈ 10 sec before scanning began. All subjects completed the same fixed number of trials in each condition, with the performance lasting for ≈ 90 sec in total. Performance data were collected throughout this 90-sec period.

Successive scans were separated by ≈ 10 min, during which time the requirements of the task were explained to the subject, and practice trials were administered to ensure that the task had been fully understood. In all cases, these practice trials involved objects or locations different from those used during the actual scanning conditions. In addition, the subjects were instructed not to spend too long encoding or retrieving any particular stimulus during the scan (because each stimulus would be presented more than once), and to maintain a constant response rate of approximately one touch per second.

Encoding Object Features. During scanning, eight white squares were presented, one at a time, in the center of the

computer screen (Fig. 1*a*). Each square contained a digitized monochrome image (representational drawing) of a different everyday object (leaf, fly, chair, duck, hat, hammer, tie, and lamp). Subjects were instructed to attend to each object, to remember its distinguishing features, and then to touch it in order that the next object should be presented. When an object

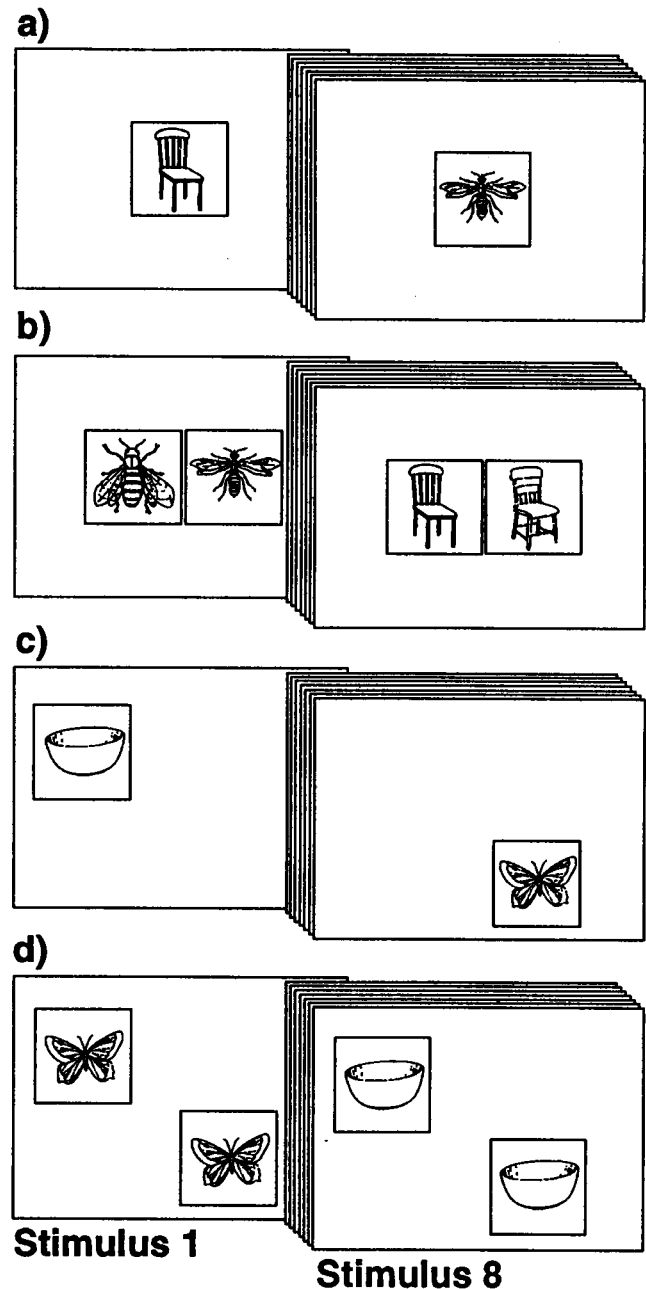


FIG. 1. Encoding and Retrieving Object Features versus Object Locations. (*a*) Encoding Object Features. The subjects were instructed to attend to each object, to remember it, and then to touch it to move on to the next object. (*b*) Retrieving Object Features. The subjects were instructed to decide which of the two drawings was identical to one that they had seen earlier and to respond by touching that drawing to move on to the next pair. (*c*) Encoding Object Location. The subjects were instructed to attend to each object, to remember its location and then to touch it to move on to the next object. (*d*) Retrieving Object Location. The subjects were instructed to decide which of the two possible locations was correct for each object and to respond by touching that position to move on to the next pair. In both the encoding and recall conditions, the entire set of eight stimuli was shown four times during the scanning period.

was touched, it disappeared, and, after 1 sec, the next object appeared. In this and in subsequent scans, the entire set of eight objects was shown four times, the order of presentation being randomized within each block of eight.

Retrieving Object Features. Eight pairs of representational drawings were presented, one pair at a time, to the left and right of the center of the computer screen (Fig. 1*b*). One of the drawings in each pair was identical to one of the stimuli presented during the Encoding Object Features condition, while the other drawing was the same type of object, but one that differed slightly in terms of its characteristic features. The subject responded by touching the drawing that corresponded exactly to the one seen previously. Immediately after a touch, both squares disappeared and 1 sec later the next pair was presented. This procedure was followed regardless of whether the drawing selected was correct or incorrect, and the subjects were informed of the results only when the entire scanning session was complete.

Encoding Object Location. This condition and the next one (Retrieving Object Location) are the same as those described in a related article (13). They are included here because they will be compared with the Object Features conditions. The procedure for the Encoding Object Location condition was similar to that for the Encoding Object Features task, except that each of the eight stimuli used (brush, cake, glasses, bowl, candle, butterfly, hen, and bow) appeared in a different location on the screen (Fig. 1*c*). Thus, eight different stimuli were presented in eight different locations. The subjects were instructed to attend to each stimulus, to remember its location, and then to touch it in order that the next one should be presented.

Retrieving Object Location. The procedure for this condition was similar to that of the Retrieving Object Features condition described above. Eight pairs of representational drawings were presented on the computer screen, one pair at a time (Fig. 1*d*). Both squares contained an identical image of one of the eight objects presented in the previous Encoding

Object Location condition. One of the locations had been occupied by that particular object in the Encoding Object Location condition and the other location had been occupied by one of the other seven objects, but not by the one currently being presented. The subjects were instructed to decide which of the two locations was correct for that object and to respond by touching it to move onto the next pair.

RESULTS

The Retrieving Object Features and the Retrieving Object Location tasks were performed equally well with subjects scoring 98% correct in each case.

Object Features Versus Object Location. *Encoding.* When blood flow in the Encoding Object Location condition was subtracted from that in the Encoding Object Features condition (Table 1), significant changes in rCBF were observed bilaterally in medial orbitofrontal and ventrolateral frontal cortex. Other significant rCBF changes were located in the inferior temporal gyrus in the left hemisphere (Fig. 2*a*), and in the anterior cingulate cortex, the lateral prestriate cortex, and the striate cortex in the right hemisphere. No significant changes were observed in the perirhinal region. When blood flow in the Encoding Object Features condition was subtracted from that in the Encoding Object Location condition, significant rCBF changes were observed bilaterally in posterior parietal cortex (Fig. 2*b*). In addition, significant rCBF changes were observed, in the left hemisphere, in the striate cortex, in ventral regions of the prestriate cortex, and in the premotor cortex. In the right hemisphere, significant changes were observed in dorsal and ventral prestriate regions and in the cerebellum.

Retrieval. When blood flow in the Retrieving Object Location condition was subtracted from that in the Retrieving Object Features condition (Table 2), significant changes were observed bilaterally in both anterior and posterior regions of the inferior temporal gyrus (Fig. 2*c*), but not in the perirhinal

Table 1. Encoding Object Features compared with Encoding Object Location

Brain region	Stereotaxic coordinates			<i>t</i>
	<i>X</i>	<i>Y</i>	<i>Z</i>	
<i>Encoding Object Features minus Encoding Object Location</i>				
Left hemisphere				
Medial orbitofrontal cortex (area 11)	-4	42	-15	3.52
Ventrolateral frontal cortex (area 47-12)	-31	41	-6	4.23
Inferior temporal cortex (area 20)	-38	-11	-30	3.74
Right hemisphere				
Medial orbitofrontal cortex (area 11)	2	42	-17	3.61
Ventrolateral frontal cortex (area 47-12)	32	25	-18	4.05
Anterior cingulate cortex (area 32)	8	44	11	3.67
Lateral prestriate cortex (area 18)	44	-83	-9	3.86
Striate cortex (area 17)	19	-95	-15	5.38
<i>Encoding Object Location minus Encoding Object Features</i>				
Left hemisphere				
Premotor cortex (area 6)	-26	3	54	3.80
Posterior parietal cortex (area 7)	-29	-78	33	4.01
Posterior parietal cortex (area 7)	-16	-69	50	5.06
Ventral prestriate cortex (area 18)	-11	-73	0	4.25
Right hemisphere				
Posterior parietal cortex (area 7)	13	-64	48	4.72
Ventral prestriate cortex (area 18)	17	-71	-5	6.10
Dorsal prestriate cortex (area 19)	12	-81	33	3.89
Cerebellum	12	-66	-17	3.63
Midline				
Striate cortex (area 17)	0	-73	14	7.35

Peaks of statistically significant changes in normalized CBF are represented. The stereotaxic coordinates are expressed in mm. *X*, medial-to-lateral distance relative to the midline (positive = right hemisphere); *Y*, anterior-to-posterior distance relative to the anterior commissure (positive = anterior); *Z*, superior-to-inferior distance relative to the anterior commissure-posterior commissure line (positive = superior). Significance levels are given in *t* test values (see text for details).

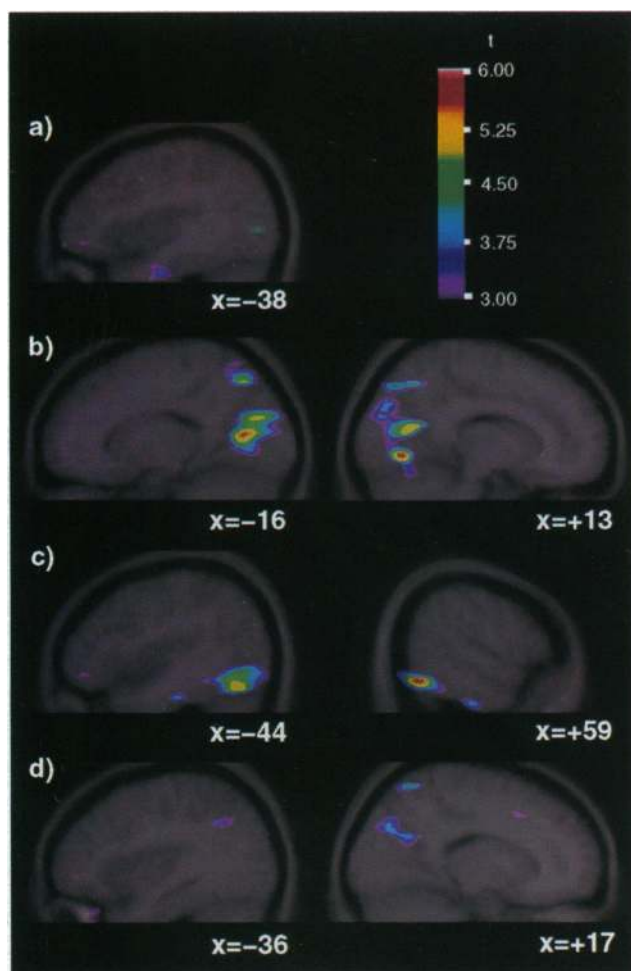


FIG. 2. The averaged PET subtraction images are shown superimposed upon the corresponding averaged MRI scans. Subtraction of one condition from another yielded the focal changes in blood flow shown as a t statistic image, whose range is coded by the color scale placed to the right of the figure. (a) Encoding Object Features minus Encoding Object Location. The sagittal section, at coordinate $x = -38$ (left hemisphere), illustrates the significant rCBF increases observed in the anterior region of the inferior temporal gyrus (see Table 1). (b) Encoding Object Location minus Encoding Object Features. The sagittal sections, at coordinates $x = -16$ (left hemisphere) and $x = +13$ (right hemisphere), illustrate the significant rCBF increases observed in the posterior parietal cortex and in dorsal regions of prefrontal cortex (see Table 1). (c) Retrieving Object Features minus Retrieving Object Location. The sagittal sections, at coordinates $x = -44$ and $x = +59$, illustrate the significant bilateral rCBF increases observed in anterior and posterior regions of the inferior temporal gyrus and in ventral prefrontal cortex (see Table 2). (d) Retrieving Object Location minus Retrieving Object Features. The sagittal sections, at coordinates $x = -36$ and $x = +17$, illustrate the significant bilateral rCBF increases observed in the posterior parietal cortex (see Table 2).

cortex. Bilateral activation was also observed in striate and ventral prefrontal regions, as well as in the ventrolateral region of the frontal lobe. In contrast, when blood flow in the Retrieving Object Features condition was subtracted from that in the Retrieving Object Location condition, significant rCBF changes were observed bilaterally in posterior parietal cortex (Fig. 2d), in the precuneus, and in the striate cortex. Significant rCBF changes were also observed in the posterior cingulate cortex, in the dorsal striate cortex and prefrontal cortex in the left hemisphere, and in the premotor cortex in the right hemisphere.

Encoding Versus Retrieval. Features. When blood flow in the Retrieving Object Features condition was subtracted from that in the Encoding Object Features condition (Table 3),

significant changes in rCBF were observed in the left lateral temporal cortex. In the frontal lobe, also, all significant changes were located, in the left hemisphere, in the middle-solateral frontal cortex, and in the posterior inferior frontal region (Broca's area). In the right hemisphere, the only significant rCBF change was located in the central opercular region. In contrast, when the Encoding Object Features condition was subtracted from the Retrieving Object Features condition, significant rCBF changes were observed in the left prefrontal cortex and in the right ventrolateral frontal cortex and the striate cortex.

Object location. The CBF changes resulting from the comparison of the Encoding Object Location condition with the Retrieving Object Location condition have already been presented (Table 3 in reference 13). When blood flow in the Retrieving Object Location condition was subtracted from that in the Encoding Object Location condition, significant changes in rCBF were observed in the left hemisphere only, in ventrolateral and dorsolateral frontal areas, in both posterior and anterior regions of the inferior temporal gyrus, and in parietal area 40. In contrast, when the Encoding Object Location condition was subtracted from the Retrieving Object Location condition, significant rCBF changes were observed in the right hemisphere only, in medial and ventral frontal areas, posterior cingulate cortex, and in striate and prefrontal cortex.

DISCUSSION

The major question addressed in this study was whether there would be significant functional activation of the inferior temporal gyrus and/or perirhinal cortex when subjects were required to retrieve information about the visual features of objects. When activation in the Retrieving Object Location condition was subtracted from that in the Retrieving Object Features condition, significant rCBF changes were observed, bilaterally, in the inferior temporal gyrus, but were not seen in the perirhinal region or the hippocampus and parahippocampal gyrus. The activated region corresponds to the anterior inferotemporal cortical area TE of the monkey brain, which is assumed to be critical for the perception of object identity (8). Within the ventral occipitotemporal pathway, area TE occupies a pivotal position by virtue of its prominent projections to the amygdala and to the hippocampal formation through the perirhinal cortex and the caudally adjacent parahippocampal gyrus (24). Bilateral lesions of this region in the monkey produce profound visual recognition memory impairments (4), and, for this reason, it has been strongly implicated in the mnemonic processes of storage and retrieval that accompany object perception (4). The fact that bilateral rCBF changes were observed in the current investigation fully concurs with these lesion studies in the monkey, but provides no indication that, in the human brain, the right temporal lobe plays a more important role than the left, as has been predicted on the basis of patient studies (1, 2).

In monkeys, restricted lesions of the perirhinal cortex and the parahippocampal gyrus (5, 6) or of the perirhinal cortex alone (7) also cause profound deficits on visual object-recognition tasks. In the current study, no significant rCBF changes were observed in the perirhinal cortex when blood flow in the Retrieving Object Location condition was subtracted from that in the Retrieving Object Features condition. This finding suggests that the perirhinal region may be less specifically involved in object-recognition memory than the inferior temporal cortex, although there is reason to think that this area may play a more general role in mnemonic processing. Thus, when compared with a condition requiring recall of location alone (see ref. 13), the Retrieving Object Locations condition used in this paper is associated with a significant rCBF increase in a region of the right anterior parahippocampal gyrus corresponding to the entorhinal cortex. Given that

Table 2. Retrieving Object Features compared with Retrieving Object Location

Brain region	Stereotaxic coordinates			<i>t</i>
	<i>X</i>	<i>Y</i>	<i>Z</i>	
<i>Retrieving Object Features minus Retrieving Object Location</i>				
Left hemisphere				
Ventrolateral frontal cortex (area 47-12)	-32	37	-9	5.29
Inferior temporal gyrus anterior (area 20)	-44	-24	-26	3.89
Inferior temporal gyrus posterior (area 37)	-50	-42	-14	3.88
Ventral prefrontal cortex (area 18)	-24	-95	-14	5.36
Striate cortex (area 17)	-27	-97	0	4.22
Right hemisphere				
Ventrolateral frontal cortex (area 47-12)	48	41	-15	3.55
Inferior temporal gyrus anterior (area 20)	59	-21	-32	3.99
Inferior temporal gyrus anterior (area 20)	47	-26	-27	3.52
Inferior temporal gyrus posterior (area 37)	52	-59	-14	6.60
Ventral prefrontal cortex (area 18)	38	-83	-8	5.87
Striate cortex (area 17)	23	-97	0	5.65
<i>Retrieving Object Location minus Retrieving Object Features</i>				
Left hemisphere				
Posterior cingulate cortex (area 31)	-7	-42	36	3.72
Posterior parietal cortex (area 40)	-36	-57	35	3.77
Precuneus (area 7)	-11	-59	15	3.69
Medial posterior parietal cortex (area 7)	-5	-68	50	5.48
Prefrontal cortex (area 18)	-1	-78	23	5.23
Prefrontal cortex (area 19)	-17	-81	35	4.84
Right hemisphere				
Premotor cortex (area 6/8)	24	12	47	4.21
Posterior parietal cortex (area 7)	17	-61	65	4.53
Precuneus (area 7)	7	-66	24	4.65
Midline				
Striate cortex (area 17)	0	-69	3	5.15

See Table 1 legend for details.

memory for object features and memory for object location were compared directly in the current study, activation in medial regions of the temporal lobe may have been subtracted out, leaving only those more lateral changes in blood flow specifically related to memory for the features of objects.

In the Encoding Object Features minus Encoding Object Location subtraction, a significant change in rCBF was observed in the anterior and lateral part of the left inferior temporal gyrus. This anterior region, which projects directly to

ventral areas in the left frontal lobe (also activated in this encoding condition), may interact with the ventrolateral frontal cortex to facilitate the encoding of object features, perhaps through the use of verbal mediation (12). This finding confirms that anterior regions of the temporal cortex are important for encoding information about figurative detail as well as for maintaining and retrieving this information (2).

Another question addressed here was whether the retrieval of information about the visual features of objects would also

Table 3. Encoding Object Features compared with Retrieving Object Features

Brain region	Stereotaxic coordinates			<i>t</i>
	<i>X</i>	<i>Y</i>	<i>Z</i>	
<i>Encoding Object Features minus Retrieving Object Features</i>				
Left hemisphere				
Middorsolateral frontal cortex (area 46/9)	-38	46	29	3.79
Middorsolateral frontal cortex (area 9)	-28	36	38	3.52
Posterior inferior frontal cortex (area 44)	-54	12	2	3.81
Superior temporal gyrus anterior (area 22)	-54	-16	6	4.03
Superior temporal gyrus posterior (area 22)	-60	-57	21	3.78
Inferior temporal gyrus anterior (area 20)	-40	-9	-30	3.68
Inferior temporal gyrus posterior (area 20)	-56	-22	-29	3.54
Inferior temporal gyrus posterior (area 20)	-43	-40	-23	3.67
Middle temporal gyrus (area 21)	-62	-52	-6	3.94
Posterior cingulate cortex (area 31)	-4	-42	35	3.74
Right hemisphere				
Central opercular cortex (area 43)	38	-9	23	3.64
<i>Retrieving Object Features minus Encoding Object Features</i>				
Left hemisphere				
Ventral prefrontal cortex (area 18)	-11	-76	-2	4.77
Right hemisphere				
Ventrolateral frontal cortex (area 47-12)	25	22	-5	3.98
Striate cortex (area 17)	13	-80	8	6.34

See Table 1 legend for details.

be associated with significant rCBF changes in the more posterior inferior temporal and occipitotemporal areas of the ventral visual system for object vision (8). The results of several recent functional imaging studies suggest that those posterior neocortical regions that are specialized for the perceptual analysis of visual or spatial stimuli may also participate in memory for that same type of information (9–11, 25). For example, Moscovitch *et al.* (11) recently observed significant rCBF changes in posterior, but not anterior, regions of the inferior temporal gyrus/fusiform gyrus when subjects were required to retrieve information about object identity, as compared with object location, from long-term memory. In the present study, when activation in the Retrieving Object Location condition was subtracted from that in the Retrieving Object Features condition, significant positive rCBF changes were observed bilaterally in a posterior region of the inferior temporal gyrus. In the monkey, this area is critical for visual pattern perception (4). Even in prestriate regions, significant rCBF changes were confined to ventral areas in this subtraction. In contrast, when the Retrieving Object Features condition was subtracted from the Retrieving Object Location condition, significant rCBF changes were observed bilaterally in dorsal, but not in ventral, extrastriate areas. In addition, both the retrieving and the encoding object location conditions were associated with significant blood flow changes in posterior regions of parietal cortex, while no significant changes were observed in either lateral or medial temporal lobe regions. Together, these results clearly support recent suggestions that the posterior cortical regions that mediate the perception of visual patterns and spatial locations, respectively, are similarly specialized for, and critically involved in, remembering that same type of information (4, 10–12). This possibility is strengthened considerably by the fact that, as in two other recent studies (10, 11), the perceptual characteristics of the stimuli used in the two encoding conditions and in the two retrieval conditions in the present study were formally identical.

Finally, one purpose of the present experiment was to test the generality of recent proposals that encoding and retrieval differentially involve left and right frontal lobe regions, respectively (15, 16, 26). To address this issue, we compared the encoding and retrieval conditions for both object features and object locations. When activation in the Retrieving Object Features condition was subtracted from activation in the Encoding Object Features condition, significant changes in rCBF were observed in the left middorsolateral and ventrolateral frontal regions (Table 3). The reverse subtraction yielded fewer significant foci overall, although in the frontal lobe only the right ventrolateral region was activated. Similar results were obtained in the comparison between the Encoding Object Location and Retrieving Object Location conditions (see ref. 13). Encoding Object Location minus Retrieving Object Location yielded significant peaks only in the left hemisphere, including middorsolateral and ventrolateral frontal cortex, while Retrieving Object Location minus Encoding Object Location resulted in significant peaks only in the right hemisphere, including medial and ventral frontal areas. Interestingly, a recent PET study has demonstrated a similar pattern of left and right frontal lobe involvement during face encoding and face retrieval (27).

Although it is possible to interpret the above findings in terms of the proposed hemispheric asymmetry in encoding and retrieval, we have recently argued that this apparent dissociation may reflect more basic differences in the conditions used (13). For example, during the initial presentation of the stimuli to be remembered, subjects may preferentially adopt internal (i.e., nonvocal) verbal strategies to facilitate the encoding of either object location or object features, processes which probably involve left hemisphere mechanisms. In contrast,

during retrieval of either object location or object features, verbal descriptions are less useful because the subjects are required to choose between two identical drawings in different locations, in one case, or between two similar drawings of the same object, in the other. Subjects may, therefore, rely preferentially on nonverbal representations of the remembered locations or features, processes that are less likely to involve left hemisphere regions (28).

This work was supported by the McDonnell-Pew Program in Cognitive Neuroscience and by the Medical Research Council of Canada Special Project Grant SP-30.

- Burke, T. & Milner, B. (1991) *IBRO World Congr. Neurosci. Abstr.* **3**, 180.
- Pigott, S. & Milner, B. (1993) *Neuropsychologia* **31**, 1–16.
- Iwai, E., Osawa, Y. & Okuda, H. (1990) in *Vision, Memory, and the Temporal Lobe*, eds. Iwai, E. & Mishkin, M. (Elsevier, New York), pp. 1–12.
- Mishkin, M. (1982) *Philos. Trans. R. Soc. London B* **298**, 85–95.
- Suzuki, W. A., Zola-Morgan, S., Squire, L. R. & Amaral, D. G. (1993) *J. Neurosci.* **13**, 2430–2451.
- Zola-Morgan, S., Squire, L. R., Amaral, D. G. & Suzuki, W. A. (1989) *J. Neurosci.* **9**, 4355–4370.
- Meunier, M., Bachevalier, J., Mishkin, M. & Murray, E. A. (1993) *J. Neurosci.* **13**, 5418–5432.
- Ungerleider, L. G., Mishkin, M. (1982) in *Analysis of Visual Behavior*, eds. Ingle, D. J., Goodale, M. A. & Mansfield, R. J. W. (MIT Press, Cambridge, MA), pp. 549–586.
- Haxby, J. V., Horwitz, B., Ungerleider, L. G., Maisog, J. M., Pietrini, P. & Grady, C. L. (1994) *J. Neurosci.* **14**, 6336–6353.
- Kohler, S., Kapur, S., Moscovitch, M. & Winocur, G. (1995) *NeuroReport* **6**, 1865–1868.
- Moscovitch, M., Kapur, S., Kohler, S. & Houle, S. (1995) *Proc. Natl. Acad. Sci. USA* **92**, 3721–3725.
- Petrides, M. (1994) in *Handbook of Neuropsychology*, eds. Boller, F. & Grafman, J. (Elsevier, Amsterdam), Vol. 9, pp. 59–82.
- Owen, A. M., Milner, B., Petrides, M. & Evans, A. C. (1996) *J. Cogn. Neurosci.*, in press.
- Petrides, M., Alivisatos, B. & Evans, A. C. (1995) *Proc. Natl. Acad. Sci. USA* **92**, 5803–5807.
- Shallice, T., Fletcher, P., Frith, C. D., Grasby, P., Frackowiak, R. S. J. & Dolan, R. J. (1994) *Nature (London)* **368**, 633–635.
- Tulving, E., Kapur, S., Craik, F. I. M., Moscovitch, M. & Houle, S. (1994) *Proc. Natl. Acad. Sci. USA* **91**, 2016–2020.
- Bachevalier, J. & Mishkin, M. (1986) *Behav. Brain Res.* **20**, 249–261.
- Petrides, M. (1995) *J. Neurosci.* **15**, 359–375.
- Evans, A. C., Thompson, C. J., Marrett, S., Meyer, E. & Mazza, M. (1991) *IEEE Trans. Med. Imaging* **10**, 90–98.
- Raichle, J. E., Martin, W. R. W., Herscovitch, P., Mintum, M. A. & Markham, J. (1983) *J. Nucl. Med.* **24**, 790–798.
- Evans, A. C., Marrett, S., Torrescorzo, J., Ku, S. & Collins, L. (1991) *J. Cereb. Blood Flow Metab.* **11**, A69–A78.
- Fox, P. T., Perkmutter, J. S. & Raichle, M. E. (1985) *J. Comput. Assist. Tomogr.* **9**, 141–153.
- Worsley, K. J., Evans, A. C., Marrett, S. & Neelin, P. (1992) *J. Cereb. Blood Flow Metab.* **12**, 900–918.
- Amaral, D. G., Witter, M. P. & Insausti, R. (1993) in *Brain Mechanisms of Perception and Memory: From Neuron to Behavior*, eds. Ono, T., Squire, L. R., Raichle, M. E., Perret, D. I. & Fukuda, M. (Oxford Univ. Press, New York), pp. 228–240.
- Martin, A., Wiggs, C. L., Ungerleider, L. G. & Haxby, J. V. (1996) *Nature (London)* **379**, 649–652.
- Nyberg, L., Tulving, E., Habib, R., Nilsson, L.-G., Kapur, S., Houle, S., Cabeza, R. & McIntosh, A. R. (1995) *NeuroReport* **7**, 249–252.
- Haxby, J. V., Ungerleider, L. G., Horwitz, B., Maisog, J. M., Rapoport, S. I. & Grady, C. L. (1996) *Proc. Natl. Acad. Sci. USA* **93**, 922–927.
- Milner, B. (1974) in *The Neurosciences: Third Study Program*, eds. Schmitt, F. O. & Worden, F. G. (MIT Press, Cambridge, MA), pp. 75–89.