

Methods and Limits of Digital Image Compression of Retinal Images for Telemedicine

Robert H. Eikelboom, Kanagasingam Yogesan, Chris J. Barry, Ian J. Constable, Mei-Ling Tay-Kearney, Ludmila Jitskaia, and Philip H. House

PURPOSE. To investigate image compression of digital retinal images and the effect of various levels of compression on the quality of the images.

METHODS. JPEG (Joint Photographic Experts Group) and Wavelet image compression techniques were applied in five different levels to 11 eyes with subtle retinal abnormalities and to 4 normal eyes. Image quality was assessed by four different methods: calculation of the root mean square (RMS) error between the original and compressed image, determining the level of arteriole branching, identification of retinal abnormalities by experienced observers, and a subjective assessment of overall image quality. To verify the techniques used and findings, a second set of retinal images was assessed by calculation of RMS error and overall image quality.

RESULTS. Plots and tabulations of the data as a function of the final image size showed that when the original image size of 1.5 MB was reduced to 29 KB using JPEG compression, there was no serious degradation in quality. The smallest Wavelet compressed images in this study (15 KB) were generally still of acceptable quality.

CONCLUSIONS. For situations where digital image transmission time and costs should be minimized, Wavelet image compression to 15 KB is recommended, although there is a slight cost of computational time. Where computational time should be minimized, and to remain compatible with other imaging systems, the use of JPEG compression to 29 KB is an excellent alternative. (*Invest Ophthalmol Vis Sci.* 2000;41:1916-1924)

Along with the advances in computers, communication, and imaging technologies, there has been an increase in the use and applications of telemedicine: the exchange of medical information (data, voice, and still or video images) using telecommunication equipment. Telemedicine has already been used successfully in a number of areas of medicine. In remote Australia, live slit-lamp images were transmitted 900 km to an ophthalmologist to determine the need to transfer a patient to a regional center for specialist treatment,¹ reducing the need for urgent air transfer of patients from 17 in 1 year to 4 in the next, and those requiring nonurgent transfer from 41 to 30. Crump et al.² also tested a NASA Telemedicine Instrument Pack (containing a fundus camera, nasopharyngoscope, and a dermoscope) in a general practice environment.

One of telemedicine's main attractions lies in the ability to provide specialist medical care to areas that are underserved, particularly those located remotely from major population centers. For example, the state of Western Australia (land area 2,500,000 km²) has a population of 1.9 million, 70% of whom are located in the lower southwest corner. Because all ophthalmic specialists are located in this area, special trips are

made to cover the vast remaining areas. This isolation is worsened by high rates of diabetes, cataract, trauma, and endemic trachoma in the aboriginal population.³

Tele-ophthalmology has the potential to improve the accessibility of people in remote areas to specialist ophthalmic care, and in turn to help fight preventable blindness.⁴ It can also have a large impact on the costs and necessity of transporting patients to regional centers. As a primary screening tool, tele-ophthalmology also has a role in identifying patients needing nonurgent treatment. In this way, the expense of sending ophthalmic teams to remote, isolated, and sparsely populated areas can be reduced.

The essential parts of a store-and-forward telemedicine system include good quality data recording equipment and effective communications systems operated by trained health personnel, and a data archiving and viewing system accessible by specialist medical personnel. In the case of ophthalmology, where ocular imaging plays a significant role in clinical diagnosis, good quality digital images of the retina and external eye form the key part of the system.

Although the technical issues of image capture, digitizing, and transmission can easily be addressed, two factors that are linked can make the whole tele-ophthalmology system ineffective. Communication systems in remote areas are often of low quality and in some cases nonexistent. Satellite telephones can be used, but affordable systems suffer from low data transfer rates and are expensive to operate. Furthermore, digitized ocular images require substantial storage space and take a long time to transmit. A high-quality digital image can reach a size of 1.5 MB or greater. Over a 9600 bauds/sec modem line, this image can take at least 25 minutes to be transmitted,⁵ which

From the Lions Eye Institute, Centre for Ophthalmology and Visual Science, The University of Western Australia, Nedlands, Australia.

Submitted for publication June 25, 1999; revised November 1, 1999; accepted December 30, 1999.

Commercial relationships policy: N.

Corresponding author: Robert H. Eikelboom, Lions Eye Institute, Centre for Ophthalmology and Visual Science, The University of Western Australia, 2 Verdurn Street, Nedlands WA 6009, Australia. robeik@cyllene.uwa.edu.au

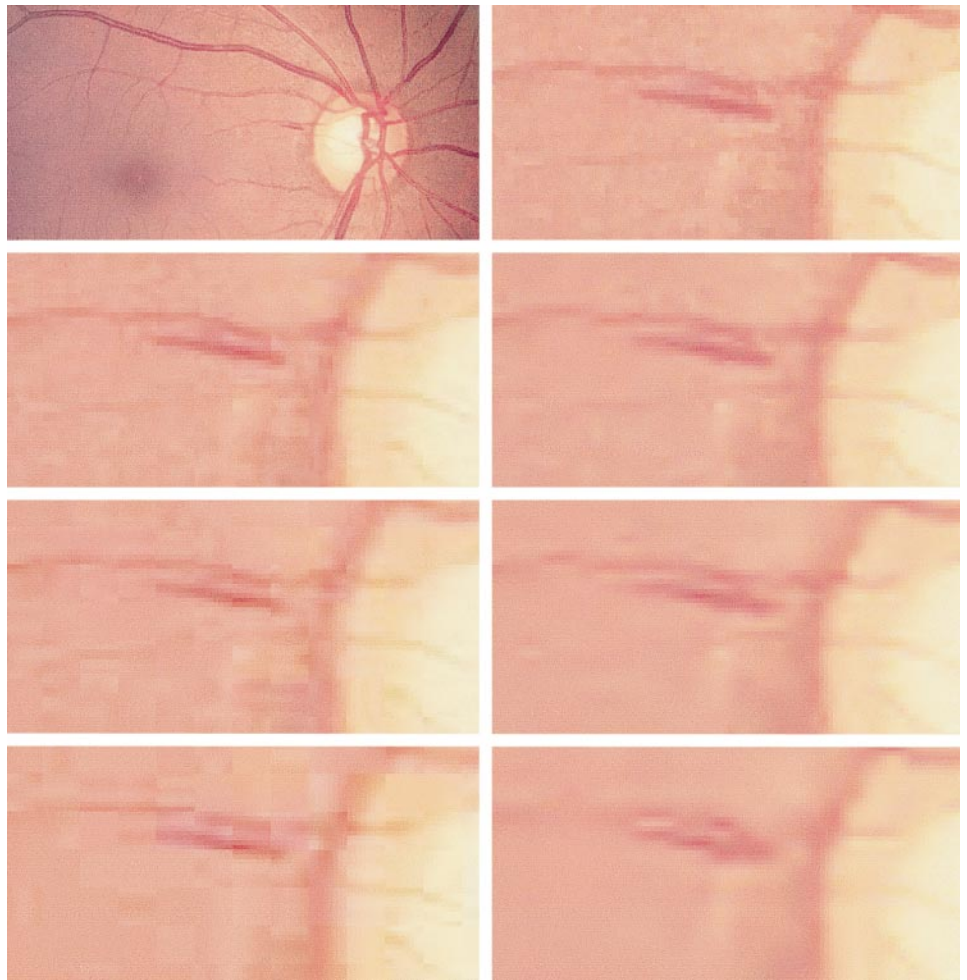


FIGURE 1. (Top Left) Photograph of a retina with a nerve fiber layer hemorrhage close to the optic disc between 9- and 10-o'clock positions. (Top Right) A 100×50 pixel detail of the digitized image. The lower six images show the effect of compression on this section of the image. Left column: JPEG compression to overall file size of 55 KB, 24 KB, and 15 KB, respectively. Right column: Wavelet compression to overall file size of 56 KB, 23 KB, and 16 KB, respectively.

becomes important when a large number of images are to be transmitted.

Image compression is common in the transmission of images. JPEG (Joint Photographic Experts Group) compression, the most common image format used on the Internet, is also used for medical imaging,⁶⁻⁸ although Wavelet image compression has also been investigated.^{9,10} To achieve an appreciable reduction in image size (i.e., more than 1:4) some loss of information and consequently some degradation of image quality must be expected.

JPEG image compression breaks the image into blocks of 8 by 8 pixels and converts these blocks subsequently into spatial frequency components. A sampling is made of this frequency domain information (in a step called quantization) by closely preserving the low-frequency components and approximating the high-frequency components. The amount of information that is discarded determines the amount of compression. A coding process compresses the remaining frequency coefficients. The decompressing process reverses these steps. The effects of compression can be seen at high compression levels when "blocking artifacts" become evident (see Fig. 1).

There are a number of different Wavelet algorithms, their differences lying in the type of filter used. In general, band- and low-pass filters are applied to the pixel rows of an image and then reapplied to the columns of pixels. This produces information on the low-frequency components of the image and the

horizontal, vertical, and diagonal detail in the image. As with the JPEG algorithm, there are also quantizing and coding steps.

A number of studies have been conducted on medical image compression. Bittorf et al.¹¹ assessed compressed images of skin lesions, concluding that images needed to be at least 768×512 pixels with 24-bit color resolution (i.e., >1 MB images) to be suitable for diagnosis. Persons et al.⁷ found that low-contrast objects in the images still remain visible after JPEG and Wavelet image compression of magnetic resonance imaging and computed tomography images, although fine and irregular details are easily degraded. Martin et al.⁶ compressed 2-, 3-, and 4-MB fundus images and found that a compression ratio of 1:24 still produced images of diagnostic quality.

A number of approaches can be taken to find the optimum level of image compression. Some studies determine the compression level at which changes from the original image are first noticed ("just-noticeable-difference"). In one study the compression ratio limit for chest radiograph images is shown to be 1:6.¹² Erickson et al.¹⁰ rated the appearance of structures on chest radiographs, finding that a Wavelet image compression ratio of 1:40 produced images indistinguishable from the original images. Another approach is to determine at what compression level the abnormalities become indistinguishable or the highest compression level that is clinically acceptable. In a previous study we found that a JPEG compression ratio of approximately 1:30 (approximately 20–30 KB images) can be achieved without affecting the ability of the ophthalmologist to

identify these abnormalities.¹³ Kim¹⁴ used JPEG compression for 900-KB gastrointestinal color images and showed that compressed images approximately 20 KB in size were still acceptable.

In the present study we continued our investigation to determine the effects of digital image compression on various types of retinal images and the level of compression tolerable. Of interest was the comparison of JPEG and Wavelet image compression techniques.

METHODS

Two sets of images were used in this study. In the first set, 15 eyes were selected from a set of over 150 subjects photographed in a major screening of aborigines in the northwest of Western Australia.

To test the limits of image compression, eyes with subtle abnormalities were selected; in most cases these abnormalities were of low clinical significance, requiring only to be noted for future observation. The abnormalities included small nerve fiber layer and macular hemorrhages, macular and peripheral drusen, and cotton wool spots. Four of the 15 eyes were normal controls, taken from the same set of eyes. Images with extreme abnormalities were not used because some preliminary investigations indicated that these images could be compressed to well over 1:300 using JPEG, and abnormalities in the retina could still be detected.

The 35-mm slides were digitized with a Polaroid Sprint-Scan35 (Cambridge, MA) at a resolution of 675 dots/inch with 24-bit color, resulting in a file size of 1.5 MB (752 × 680 pixels). This produced a high-quality digital image, without making the image size too large to be unmanageable. The images were stored as TIFF (Tagged Interchange File Format) files. The images were all compressed to five different levels using JPEG and Wavelet algorithms. The goal was to produce some compressed images in which the image quality was too low to be useful for assessment.

JPEG compression was performed by an algorithm developed from standards set by the Joint Photographic Experts Group (<http://www.jpeg.org/>). The JPEG algorithm is also available in many imaging software programs, although there appears to be a variation among some of these in the definition of the compression level. The compression level is determined by selecting a quality (Q) value, and the exact compressed file size cannot be predicted. Q values of 20, 40, 60, 80, and 100 were used, which resulted in images that were approximately 350 KB, 49 KB, 29 KB, 21 KB, and 14 KB, respectively, in size.

The Wavelet compression was applied by using a baseline wavelet transform coder with an Antonini filter¹⁵ in custom written software. The resultant file size after Wavelet compression could be predicted; compression ratios were selected to produce files equivalent to the JPEG compressed images, but still using a "round" compression ratio. The compression ratios were 1:5, 1:30, 1:50, 1:70, and 1:100, resulting in image sizes of approximately 300 KB, 52 KB, 31 KB, 22 KB, and 15 KB, respectively.

After compression, each image was decompressed and saved as a 752 by 680 pixel TIFF image to ensure that each image was loaded for viewing at the same rate.

Four methods were used to assess the quality of the 165 images:

Objective Assessment by RMS Error

An objective method of measuring image fidelity was obtained by calculating the root-mean-square (RMS) error between the original and compressed images.¹⁶ This calculates the sum of the differences between each pixel value in the original image and the corresponding pixel in the compressed image. Each digital image contains three color channels (red, green and blue; or RGB); RMS error was calculated for each channel.

Vessel Branching

A semiobjective method of assessment involved observation of blood vessel branching.¹⁷ Images were assessed by displaying them on a computer monitor. Two assessors working together identified a retinal artery on the highest quality image, noting the number of branches of this vessel that were visible. A branch was defined where the distal branch of the artery had a decreased diameter compared with the prebranch vessel. The successive compressions of this image were then displayed, with the assessors noting the number of branches that continued to be visible. Grading of image quality was arbitrarily determined by the following: four branches visible, excellent; three, good; two, acceptable; and one, poor or unacceptable. Retinal arteries were selected because they are generally thinner and are less contrasted than the veins.

Ophthalmic Assessment

All compressed images and original images were displayed as TIFF images in a random order on a 17-inch computer monitor (dot pitch 0.28 mm) set to 1024 by 768 pixels. Each image was shown with no zoom and filled most of the screen. The same monitor was used by each assessor. Ophthalmologists experienced in mass screenings were asked to note their observations from all 90 images (6 of each eye); they were not told the number of normal subjects, or the abnormalities that they could expect to see. Four ophthalmologists assessed the JPEG compressed images and three the Wavelet compressed images.

Sensitivity, specificity, and kappa agreement were calculated to summarize the assessments of the ophthalmologists. Kappa indices¹⁸ were used for agreement between the observations from the compressed images and the gold standard assessments. Values of kappa of 0.6 or over are generally taken as indicating good agreement.

Subjective Assessment of Image Quality

While assessing the images, the assessors were also asked to grade the image quality as being good (image degradation not evident), acceptable (image degradation evident, but still able to make an assessment), or poor (quality not sufficient from which to make an assessment).

After these images were assessed, a second set of images of eight eyes was obtained to determine whether compression also affected other types of images in a similar manner. These images, showing mild to gross retinal abnormalities, were digitized as described above and compressed to the same compression ratios. They were then analyzed by calculating the RMS error and by qualitatively assessing image quality: good, acceptable, or poor.

RESULTS

To illustrate the effect of image compression, a small section from one of the images in this study is shown in Figure 1. The

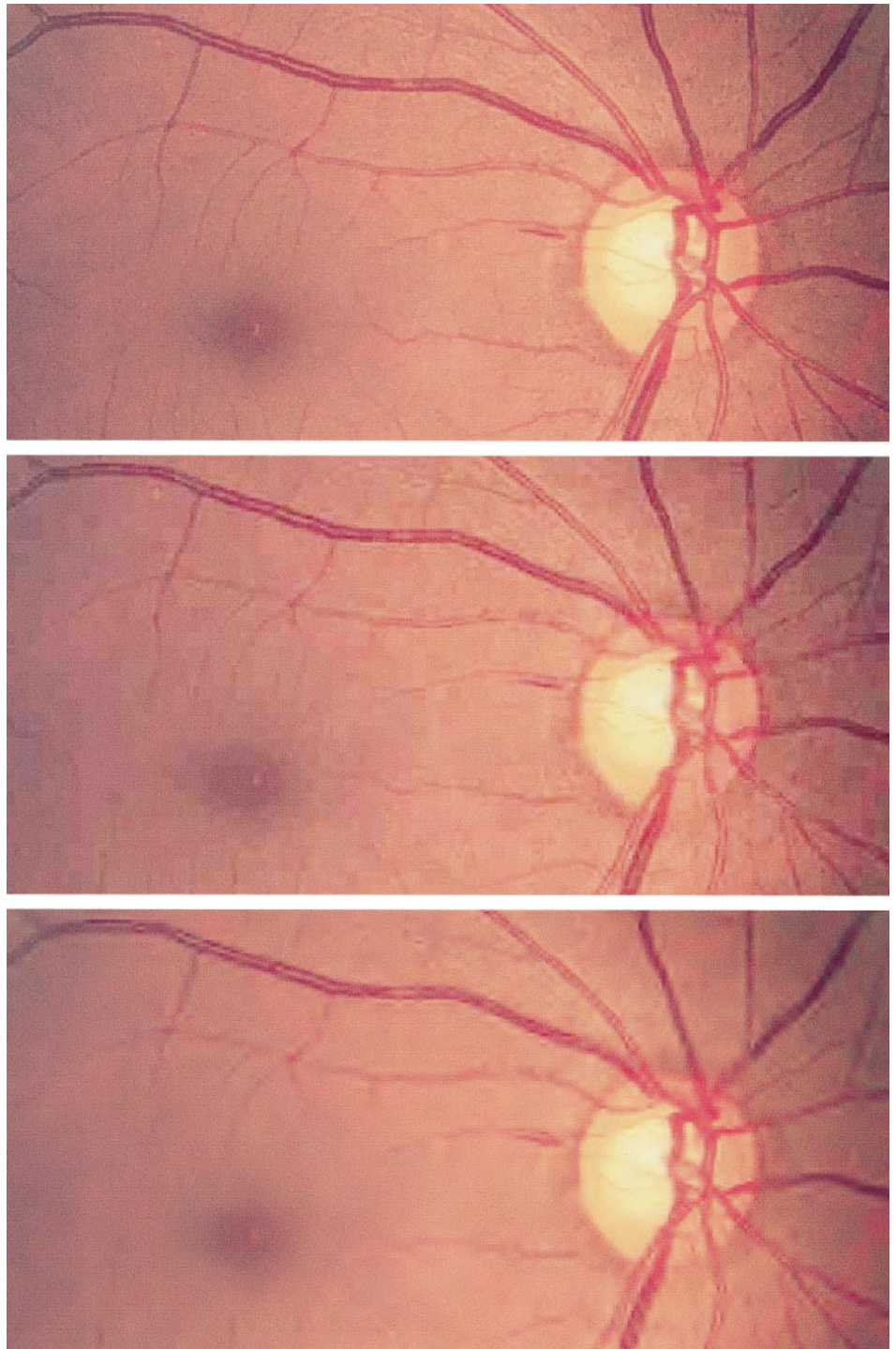


FIGURE 2. Fuller views of the 15-KB JPEG compressed image (*upper*) and 16-KB Wavelet-compressed image (*lower*).

subject has a retinal nerve fiber layer hemorrhage close to the optic disc at the 10-o'clock position. The size of this section is 100 by 50 pixels and the pixelization caused by digitizing can be seen in a few areas. The images below this on the left show the effect of progressive JPEG compression, whereas those on the right show that of progressive Wavelet compression.

Compression ratios to approximately the same file size were obtained for each right and left pair: 55 KB, 24 KB, and 15 KB. The blocking effect can be seen on the lower two JPEG compressed images, particularly in the lowest images. However, most of the details of the hemorrhage and the

blood vessels are retained, despite their taking on a sheared appearance. The Wavelet compressed images on the right appear fuzzy and out of focus; the vessels start to blend into the surroundings to the extent that for the highest compression the hemorrhage starts to become indistinguishable from the neighboring blood vessels. In both cases, two small reddish dots near the top right-hand corner of the image disappear with progressive compression. In Figure 2, fuller views of the most compressed images are shown; in both cases the hemorrhage can be seen clearly. However, the blocking effect of the JPEG image makes the Wavelet com-

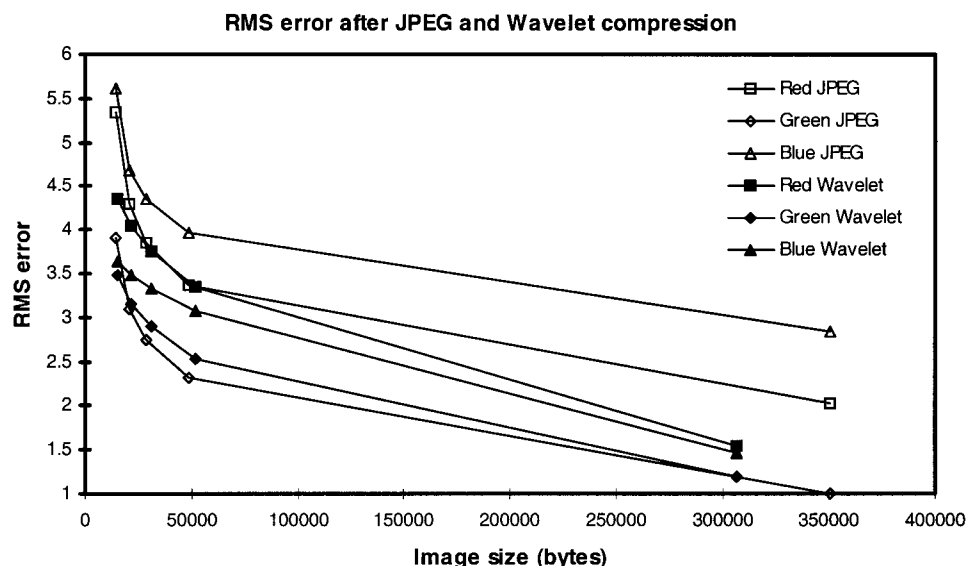


FIGURE 3. Mean \pm SD of the RMS error for the three color channels of 15 images after various rates of JPEG image compression.

pressed image a more attractive image subjectively, despite being rather fuzzy.

Objective Assessment by RMS Error

Figure 3 is a plot of the RMS error as a function of image size, for each of the RGB color channels after JPEG and Wavelet image compression. The slope of the curves for JPEG compression have an abrupt change, whereas those for Wavelet have a gentle change. For JPEG compression the greatest change in slopes of the curves is when the images are compressed to 21 KB. If one takes the RMS error level at that compression level as being acceptable, then Wavelet compression limits can be taken to be 15 KB. There was less variation of RMS error among JPEG compressed images. The effects on the color channels also differed, with the blue channel after JPEG compression having the largest RMS errors.

Vessel Branching

The visibility of retinal arteries is summarized in Table 1. In general these data show that image quality remains at least acceptable for all compression levels tested; only in one case of JPEG compression was image quality unacceptable. The tables do not show this, but in all cases for each image if there was a decrease in vessel visibility, it was with an increase in image compression. It is noted that at no stage did image compression

improve vessel visibility, although often compression did not change the visibility of branches.

Ophthalmic Assessment

Details of the 15 images and a summary of the observations by the assessors is shown in Table 2, and the calculations for sensitivity, specificity, and kappa are summarized in Table 3. These values were all higher when the Wavelet images were analyzed. The values of kappa suggest that a 29-KB JPEG image could be considered equivalent to a 15-KB Wavelet image.

Subjective Assessment of Image Quality

Table 4 summarizes the image quality assessments made by the ophthalmologists, which show that poor images were not seen except after high compression.

Table 5 summarizes all the data, indicating the limits of compression for methods of compression as determined by each method of assessment. It shows that retinal images could be compressed to at least 29 KB, which for 1.5-MB images is a compression ratio of 1:52.

Because the four assessment methods provided consistent results, it was decided to assess another set of images by calculating RMS errors and simple image quality assessments. Figure 4 plots the RMS errors for JPEG and Wavelet compression levels for each of the color channels for the second set of

TABLE 1. Quality of Original and JPEG or Wavelet-Compressed Images Graded by Visibility of Vessel Branching

Image Size	Compression and Image Size											
	JPEG						Wavelet					
	1.5MB	350K	49K	29K	21K	14K	1.5MB	300K	52K	31K	22K	15K
Q/Compression ratio	—	100	80	60	40	20	—	1:5	1:30	1:50	1:70	1:100
Quality												
Excellent	9	7	7	5	4	0	10	10	5	2	1	0
Good	6	8	7	9	7	6	5	5	9	11	11	7
Acceptable	0	0	1	1	4	8	0	0	1	2	3	8
Unacceptable	0	0	0	0	0	1	0	0	0	0	0	0

TABLE 2. Details of the Images Used in the Study, with the Percentage of Assessors That Made a Correct Judgment of the Image for Each Method and Level of Compression

Subject Gold Standard Diagnosis	JPEG Compression Image Size						Wavelet Compression Image Size					
	1.5MB	350K	49K	29K	21K	14K	1.5MB	300K	52K	31K	22K	15K
1 Fine macular drusen	100	100	100	100	100	50	100	100	100	100	100	100
2 Normal	100	100	100	100	100	100	100	100	100	100	100	66
3 Normal	100	100	100	100	100	100	100	100	100	100	100	66
4 Normal	100	100	100	100	100	100	100	100	100	100	100	100
5 Normal	100	100	100	100	100	100	100	100	100	100	100	100
6 Macular drusen; stenosed artery	100	100	100	100	50	0	100	100	100	100	100	100
7 Drusen	100	100	100	75	100	0	100	100	100	100	100	100
8 Splinter haemorrhage	100	100	75	100	100	50	100	100	100	100	100	100
9 Macular haemorrhage; macular oedema; laser scars	75	75	75	50	100	0	66	100	100	100	100	100
10 Drusen; macular haemorrhage	100	75	100	75	25	25	66	100	66	100	66	33
11 Macular drusen	100	100	25	50	25	0	100	100	100	100	100	100
12 Normal	100	100	100	100	100	100	100	66	100	100	100	100
13 Haemorrhage; scattered drusen	50	50	50	50	100	25	100	100	100	66	66	33
14 Scattered drusen	100	100	100	100	100	50	100	100	100	66	100	100
15 Normal	100	100	100	100	100	100	100	100	100	100	100	66

images. They show a similar effect of compression as seen in Figure 4; Wavelet compression produces less RMS error than JPEG compression, with the rate of increase of RMS error being greatest when the compressed image is approximately 25 KB. A subjective assessment of image quality by two assessors showed that the images were all of good quality and that the compression did not affect the ability to see that these eyes were abnormal.

DISCUSSION

A purely analytical method of assessment (i.e., by calculating the RMS error) is an attractive way of analyzing image compression; with all subjectivity removed, it can be performed easily on a computer, and the valuable time of clinicians is not required. However, there are no guidelines that indicate what is an acceptable RMS value for retinal images. Furthermore, some studies have indicated a poor relationship between RMS error (and other mathematical methods of measuring image fidelity) and degradation of the diagnostic quality of images.¹⁹ In the present study we determined the limits by observing the rate of change of the slope of the JPEG curves in Figure 3. In this way the three semiobjective and subjective techniques used in this study appeared to confirm the objective method.

The results of the various methods of assessment of the quality of compressed retinal images are relatively consistent. They show that 1.5-MB images can be compressed to at least 29 KB (compression ratio 1:52) for JPEG compression and 22 KB (1:68) for Wavelet compression before there is a loss in image quality.

Although there are only 15 images in the study, the low standard deviation of the objective assessments (4.6% and 8.3% of the mean RMS error for JPEG and Wavelet compressed images, respectively) suggest that this is sufficient.²⁰ Future studies with more images will confirm the power of the methods.

Compression ratios on their own should be treated carefully because they do not reveal the original size of the image. For example, Martin et al.⁶ found they could compress fundus images to 1:24 but started with images of 2, 3, and 4 MB. This means the final image sizes would have been 83 KB, 125 KB, and 166 KB, respectively. Therefore, it is probably better to use uncompressed and compressed image sizes to compare image compression.

One other, and also brief, report has been found of ophthalmic image compression. Anagnoste and colleagues²¹ compressed 12 color fundus and fluorescein angiogram images using JPEG format and assessed subjectively the projected

TABLE 3. Sensitivity, Specificity, and Kappa Calculated from the Observations of Abnormalities from JPEG and Wavelet Compressed Images

Image Size	JEG Compression			Image Size	Wavelet Compression		
	Sensitivity	Specificity	Kappa		Sensitivity	Specificity	Kappa
Original (1.5MB)	91.7	92	0.86	Original	93.3	100	0.90
350K	88.9	95.8	0.83	300K	96.7	100	0.95
49K	83.3	91.7	0.73	52K	93.3	100	0.90
29K	80.6	95.8	0.74	31K	93.3	100	0.95
21K	77.8	83.3	0.59	22K	93.3	100	0.90
14K	22.2	100	0.20	15K	90	86.7	0.75

TABLE 4. Average Value of Image Quality of 15 JPEG Compressed Images, as Assessed by Ophthalmologists

Image Size	Compression and Image Size											
	JPEG						Wavelet					
	1.5MB	350K	49K	29K	21K	14K	1.5MB	300K	52K	31K	22K	15K
Q/Compression ratio	—	20	40	60	80	100	—	1:5	1:30	1:50	1:70	1:100
Quality												
Good	13.5	13	13.5	10.75	5.25	0	13.3	14	12	5.7	4.3	0.3
Acceptable	1.5	2	1.5	3.75	7.25	2	1.7	1	2.7	9	8.7	9
Poor	0	0	0	0.5	2.5	13	0	0	0.3	0.3	2.3	6

images. They found that compression ratios of 1:28 and 1:12, respectively, produce images in which compression was not noticeable. However, the original image size was not provided.

Comment should also be made on the semiobjective and subjective methods used. Observation of the blood vessel branching was relatively straightforward. However, initial attempts displayed the images in a random order. Although the results still showed a trend similar to that presented in Tables 1 and 3, there was some variation because the same vessel was not always tracked by the assessors. Smaller original vessel diameters degenerate sooner than larger vessels with compression.

The use of ophthalmologists to record retinal abnormalities was the most time-consuming; 90 images could generally be assessed in about 1 hour. Although display order of the images was randomized, the assessors were still in many cases able to recognize images they had previously seen. This section of the study could have been changed to overcome this. The number of eyes could have been increased or the images broken up into sets of different compression levels and assessed with breaks of 1 week or 1 month. However, it is doubtful whether the effect of memory of images on this type of study can be completely overcome.

As was expected, there was some variation in the terminology that assessors used to describe an abnormality. Guidelines for this could be provided in future studies.

The assessment of overall image quality by the ophthalmologists was also straightforward. They recognized immediately that the 14-KB JPEG compressed images were of poor quality, because the blocking effects were very obvious. However, comments were made anyway that these images would still be suitable if assessing parameters such as optic-disc cupping.

The plots of the RMS error reveal a variation in the effect of image compression on each of the color channels, and a different relative effect on the color channels, depending on

the compression technique used. The blue channel after JPEG compression stands out a little in Figure 3 as having higher RMS error. When the images are displayed in their three different channels it can be seen that there is little information in the blue channel and that it contributes little to the full color image; it is quite dark, and varies little in gray level. More variation is seen in the green channel, with most in the red channel (which is also the brightest as would be expected). This is due to the spectral characteristics of the eye. However, it can be considered that loss of information in the blue channel is not as important as it may be to the other channels.

That RMS error is less after Wavelet image compression than that with an image of equivalent size by JPEG compression is due to JPEG compression operating on small blocks of the image, whereas Wavelet compression works on the whole image. Therefore there is some level of averaging in a 8×8 block by JPEG compression, which is independent of the neighboring 8×8 blocks; at higher levels of compression this manifests itself as the blocking artifact. The differing relative effects on the channels are probably attributable to the methods used for compression. For JPEG compression, the image was compressed as a whole, whereas for Wavelet compression each color channel was compressed separately.

The computational speed of each technique should also be noted. JPEG compression requires very little computational time (a second or less); Wavelet compression, however, requires the image to be analyzed as a whole, which is more memory and computational intensive, and takes in the order of 60 seconds per image. Decompression of compressed images has the same relative time difference. However, these time differentials will decrease with improved software, and an increased computer processing speed.

This last factor can be crucial in determining a choice between selecting JPEG or Wavelet compression. We have shown that a high degree of image compression can be achieved with both methods. If one were to use JPEG to

TABLE 5. Summary of Limits of JPEG and Wavelet Image Compression Assessed by Four Methods

Method	JPEG		Wavelet	
	Image Size	Compression Ratio	Image Size	Compression Ratio
RMS Error	21K	1:71	15K	1:100
Vessel branching	29K	1:52	15K	1:100
Assessment by ophthalmologists	21K	1:71	15K	1:100
Quality assessment	21K	1:71	22K	1:68

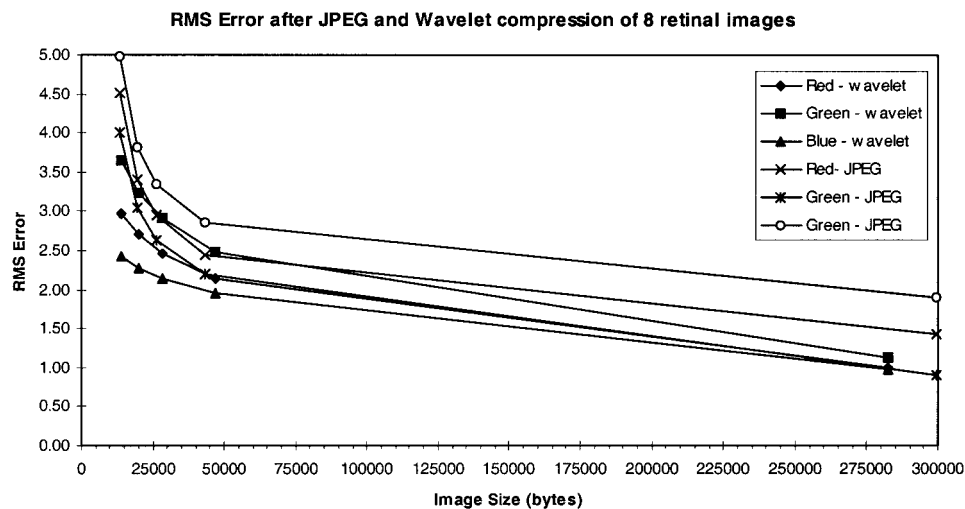


FIGURE 4. RMS error for a set of images of abnormal retinas after JPEG and Wavelet compression.

compress a 1.5-MB image to 29 KB, transmission speed is reduced from 25 minutes to 30 seconds. A major attraction of JPEG compression is its popularity with computer systems, software, and users. Most imaging software can read it, and it has wide use on the Internet.

Where computational time was not an issue, a Wavelet compression ratio of 1:68 can reduce this time to 21 seconds. If one considers that in this study we assessed images with subtle abnormalities, it could be argued that if one were screening for more serious, and more obvious, abnormalities, then Wavelet compression down to 15-KB image size (1:100) would still provide good quality images. Transmission time in this case would be 15 seconds. Even then, in cases in which there is some doubt, the ophthalmologist can request a higher resolution image, with the original image being retained uncompressed at the remote site.

Compression algorithms are still evolving. The JPEG committee is working on a new standard named JPEG 2000, which includes a Wavelet algorithm. Yang and Mitra²² use a vector quantization technique to encode radiographs. Although this study has concentrated on the compression of still images, moving images (e.g., from an ophthalmoscope) also play an important role in ophthalmic diagnosis²³ and, therefore, compression of video images, for example using MPEG or Apple QuickTime, must also be addressed. Furthermore, because this study was based on scanned 35-mm slides, our results may not apply to images acquired directly from digital retinal cameras and other ophthalmic devices with video attachments. Compression and readability of these images should also be investigated.

CONCLUSIONS

We conclude the following. (1) JPEG and Wavelet algorithms are both suitable for compression of retinal images; (2) Wavelet compression of a 1.5-MB image to 15 KB is recommended if transmission times and costs are an issue, bearing in mind that higher resolution images can be requested. (3) JPEG compression of a 1.5-MB image to 29 KB is an excellent alternative if image compatibility and/or computational time is an issue, but slightly more image degradation can be expected. (4) Compression of retinal images will be important for mass screening

programs by health workers in remote communities, where images can be assessed in a regional center in close to real-time, negating the need for a second consultation with the patient to organize ongoing treatment.

Acknowledgments

Wade Ormesher assisted in the analysis of the images and the data, and Ian McAllister provided the retinal images, with the help of Moira McKinnon of the Health Department of Western Australia.

References

- Blackwell NA, Kelly GJ, Lenton LM. Telemedicine ophthalmology consultation in remote Queensland. *Med J Aust.* 1997;167:583-586.
- Crump WJ, Levy BJ, Billica RD. A field trial of the NASA telemedicine instrument pack in a family practice. *Aviat Space Environ Med.* 1996;67:1080-1085.
- Taylor HR. *Eye Health in Aboriginal and Torres Strait Islander Communities.* Canberra, Australia: Commonwealth Department of Health and Family Services; 1997.
- Sommer A. Avoidable blindness. *Aust NZ J Ophthalmol.* 1988;16:31-35.
- Yogesana K, Constable IJ, Eikelboom RH, van Saarloos PP. Tele-ophthalmic screening using digital imaging devices. *Aust NZ J Ophthalmol.* 1998;26:S9-S11.
- Martin C, Packer S, Lesser M. Perceived quality of compressed digital fundus images [ARVO Abstract]. *Invest Ophthalmol Vis Sci.* 1991;32(4):S690. Abstract nr 127.
- Persons K, Palisson P, Manduca A, Erickson BJ, Savchenko V. An analytical look at the effects of compression on medical images. *J Digit Imaging.* 1997;10:60-66.
- Yamamoto LG. Using JPEG image compression to facilitate telemedicine. *Am J Emerg Med.* 1995;13:55-57.
- Schomer DF, Elekes AA, Hazle JD, et al. Introduction to wavelet-based compression of medical images. *Radiographics.* 1998;18:469-481.
- Erickson BJ, Manduca M, Palisson P, et al. Wavelet compression of medical images. *Radiology.* 1998;206:599-607.
- Bittorf A, Fartasch M, Schuler G, Diepgen TL. Resolution requirements for digital images in dermatology. *J Am Acad Dermatol.* 1997;37:195-198.
- Misra BM, Judy PF, Jacobson FL, Hanlon WB, Davis SH. Acceptable compression ratio for CR images for PACS archives. In: Krupinski EA, ed. *Medical Imaging 1999: Image Perception and Performance.* Washington, DC: SPIE; 1999:14-23.
- Eikelboom RH, Yogesana K, Constable IJ, et al. Digital image compression of retinal images for telemedicine applications. *Ophthalmic Res.* 1998;30:122.

14. Kim CY. Reevaluation of JPEG image compression to digitalized gastrointestinal endoscopic color image: a pilot study. In: Mun SK, Kim Y, eds. *Medical Imaging 1999: Image Display*. Washington, DC: SPIE; 1999:420–426.
15. Antonini M, Barlaud M, Mathieu P, Daubechies I. Image coding using wavelet transform. *IEEE Transactions on Image Processing*. 1992;1:205–220.
16. Gonzales RC, Wintz P. Image encoding. In: *Digital Image Processing*. Reading, MA: Addison-Wesley; 1987:256–257.
17. Diamond JP, McKinnon M, Barry CJ, et al. Non-myriatic fundus photography: a viable alternative to fundoscopy for identification of diabetic retinopathy in an Aboriginal population in rural Western Australia? *Aust NZ J Ophthalmol*. 1998;26:109–115.
18. Altman DG. *Practical Statistics for Medical Research*. London: Chapman and Hall; 1993:404–419.
19. Lattner S, Good WF, Maitz GS. Visually weighted assessment of image degradation resulting from image compression. In: Kim Y, ed. *Medical Imaging 1996: Medical Display*. Washington, DC: SPIE; 1996:507–518.
20. Snedecor GW. *Statistical Methods*. 4th ed. Ames, Iowa: Iowa State University Press; 1946:47.
21. Anagnoste SR, Orlock D, Spaide R, et al. Digital compression of ophthalmic images: maximum JPEG compression undetectable by retina specialists [ARVO Abstract]. *Invest Ophthalmol Vis Sci*. 1998;39(4):S922. Abstract nr 4242.
22. Yang S-Y, Mitra S. Adaptive vector quantization of radiographic images at very low bit rates. In: Hanson KM, ed. *Medical Imaging: Image Processing*. Washington, DC: SPIE; 1999:1607–1616.
23. Marcus DM, Brooks SE, Ulrich LD, et al. Telemedicine diagnosis of eye disorders by direct ophthalmoscopy: a pilot study. *Ophthalmology*. 1998;105:1907–1914.