

Neurosurg Focus 7 (5):Article 5, 1999

## Microendoscopic approach to far-lateral lumbar disc herniation

Kevin T. Foley, M.D., Maurice M. Smith, M.D., and Y. Raja Rampersaud, M.D.

*Semmes-Murphey Clinic, Department of Neurosurgery, University of Tennessee, Memphis, Tennessee; and Department of Neurosurgery, University of Toronto, Toronto, Ontario, Canada*

The purpose of this study was to determine the feasibility of performing far-lateral lumbar discectomy by using the microendoscopic discectomy (MED) technique. The authors studied 11 consecutive patients with unilateral, single-level radiculopathy secondary to far-lateral disc herniation. There were eight men and three women, with an average age of 43 years. In all patients magnetic resonance imaging and/or computerized tomography scanning documented far-lateral disc herniations. Six patients experienced motor deficits, nine patients sensory abnormalities, and five depressed reflexes. All patients complained of radicular pain, which failed to improve with conservative care.

After induction of epidural anesthesia, single-level, unilateral percutaneous discectomies were performed using the MED technique. Five discectomies were performed at L3-4 and six at L4-5. There were four contained and seven sequestered disc herniations. All surgeries were performed on an outpatient basis. Follow up ranged from for 12 to 27 months. Improvement was shown in all patients postoperatively. Using modified Macnab criteria to assess results of surgery, there were 10 excellent results and one good result. None of the patients experienced residual motor deficits, four had residual decreased sensation, and one still had some degree of nonradicular pain. There were no complications.

Although various open techniques exist for the treatment of far-lateral disc herniation, MED is unique in that far-lateral pathological entities can be directly visualized and removed via a 15-mm paramedian incision. The percutaneous approach avoids larger, potentially denervating and destabilizing procedures. The need for general anesthesia can be avoided, and surgery is performed on an outpatient basis, thereby reducing hospital cost and length of stay.

**Key Words \* discectomy \* percutaneous approach \* endoscopy \* intervertebral disc \* lumbar vertebra**

The term "far lateral" is often used to describe a lumbar disc herniation that compresses the exiting nerve root at the same level, lateral to the neuroforamen. Abdullah and colleagues,[1] using the term "extreme lateral," first described the corresponding clinical syndrome in 1974. This syndrome represents 0.7 to 11.7% of all lumbar disc herniations.[1,2,11,15,26-28,35,36] Despite increased clinical awareness, far-lateral lumbar disc herniation can still pose a diagnostic and management challenge to spine

surgeons.

Operative management of far-lateral disc herniations can be technically demanding. A number of approaches have been described for gaining access to these lesions. They include: midline interlaminar approaches with or without facetectomy, or with removal of the pars interarticularis;[1,2,9,10,14,16,25-29] combined approaches in which the surgeon works both medial and lateral to the foramen;[7,9,10,12,17,26,28] as well as more direct intermuscular, extraforaminal, and paramedian approaches.[3,6,31,35,40,43,44] Percutaneous techniques for far-lateral discectomy have also been described.[4,21] However, the efficacy and limitations of percutaneous discectomy have been questioned.[5,19,20]

The senior authors (K.T.F. and M.M.S.) have previously described a new surgical technique for lumbar discectomy called microendoscopic discectomy (MED).[13] This approach combines endoscopic and standard open microsurgical techniques, and the primary goal is to minimize paraspinous muscle trauma. It has been used successfully in the management of posterolateral lumbar disc herniations located from L2-3 to L5-S1.[13]

The purpose of this study was to determine the feasibility of performing far-lateral lumbar discectomy using the MED technique.

## CLINICAL MATERIAL AND METHODS

### *Patient Population*

Eleven consecutive patients underwent MED for far-lateral lumbar disc herniation between September 1996 and January 1998 at the Semmes-Murphey Clinic, Memphis, Tennessee. Data were collected in a prospective manner. Preoperatively, all patients presented with radicular pain and variable neurological signs and symptoms (Table 1).

Characteristic	No. of Patients
male	8
female	3
preoperative symptom	
radicular pain	11
sensory deficit	9
motor deficit	6
decreased/absent DTR	5
location of herniation	
L4-5	6
L3-4	5
contained disc herniation	4
sequestered disc herniation	7

\* DTR = deep tendon reflex.

Appropriate conservative management had failed to relieve patients of their symptoms. All patients had unilateral, single-level, far-lateral lumbar disc herniation demonstrated on computerized tomography and/or magnetic resonance imaging (Fig. 1). All herniations were shown to compress the symptomatic exiting nerve root lateral to the neuroforamen. The procedures were performed on an outpatient basis

after induction of epidural anesthesia.

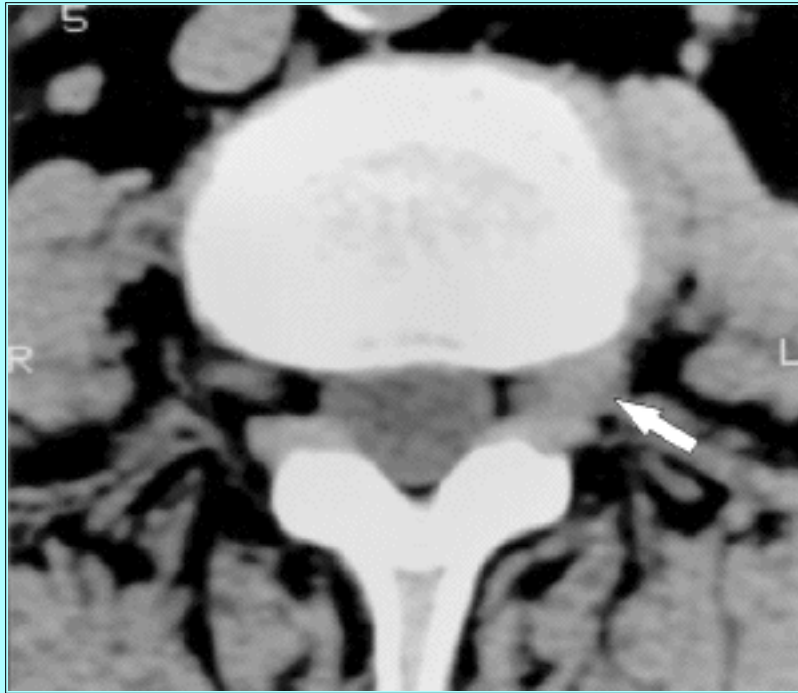


Fig. 1. Axial computerized tomography scan obtained of a left L3-4 far lateral disc herniation (arrow) compressing the exiting L-3 nerve root.

### *Surgical Technique*

The patient was positioned prone on a Wilson frame with a C-arm fluoroscope draped into the field. The midline was identified, and a mark was made 4.5 to 5 cm lateral to it, ipsilateral to the side of the herniation. The appropriate level was identified using a spinal needle and the fluoroscope (Fig. 2).

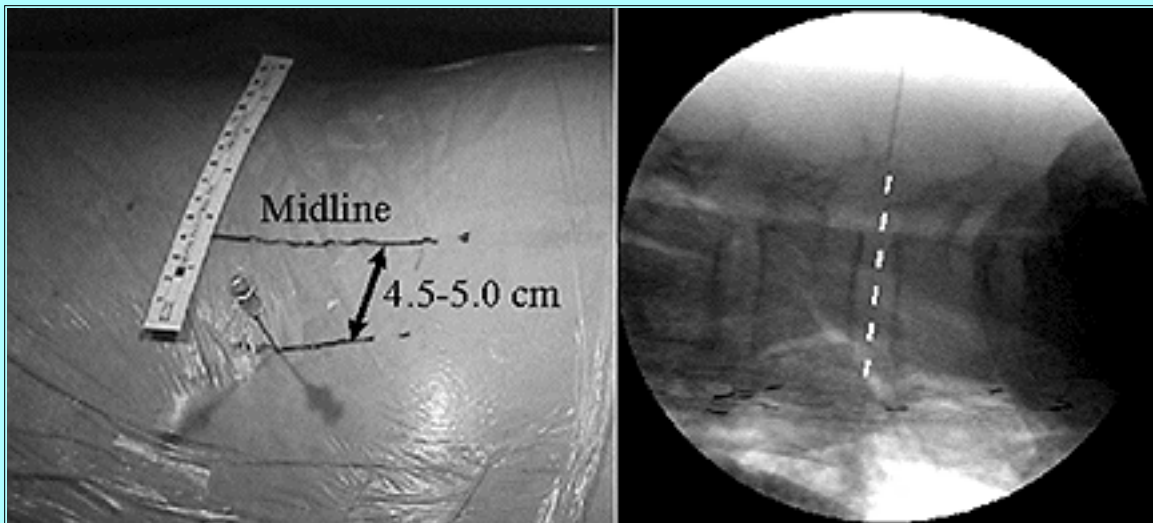


Fig. 2. Left: A spinal needle is inserted 5 cm lateral to the midline, localizing the incision site. Right: An imaginary line extending from the tip of the needle should bisect the appropriate disc space.

A 15-mm incision was centered on the needle insertion site and carried only into the subcutaneous tissues. A K-wire was then inserted through the incision, and the lumbodorsal fascia, directed toward the junction of the transverse process and pars interarticularis (pars) of the superior vertebra (that is, the L-4

vertebra for a L4-5 far-lateral disc herniation). The initial cannulated dilator was then placed over the wire through the lumbodorsal fascia, and the K-wire was withdrawn. This initial dilator was docked onto the junction of the cephalad transverse process and the pars. This position was confirmed by palpation of the bony landmarks and by fluoroscopy (Fig. 3).

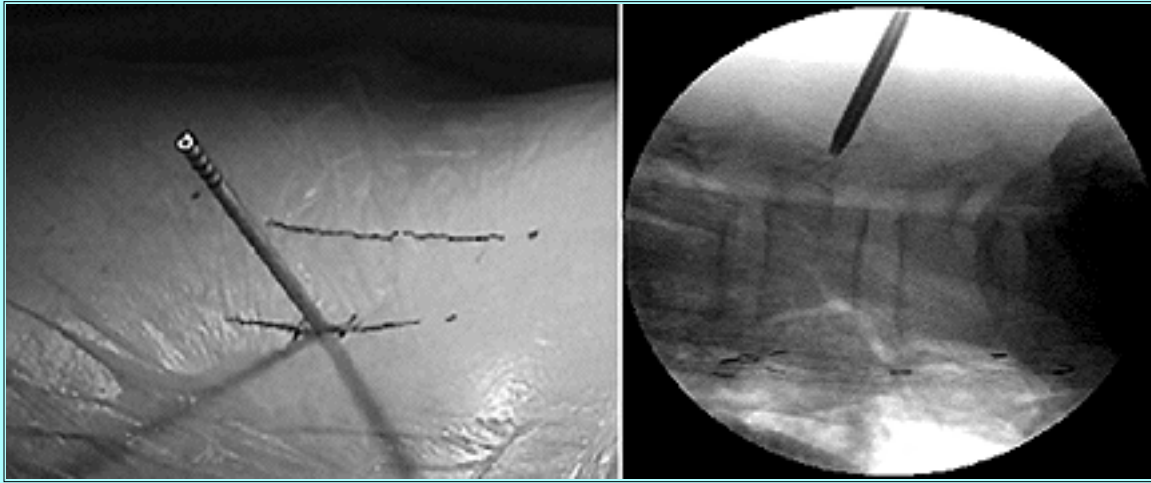


Fig. 3. Left: The initial dilator is inserted through the skin incision and advanced until it reaches the junction of the transverse process and pars above the symptomatic disc. Right: This is done under fluoroscopic guidance.

After the remaining dilators were placed, a 16-mm-diameter tubular retractor was held in place by an articulated arm. A 25° rod-lens endoscope was then placed down the tubular retractor, and the endoscopic image was oriented to the patient's position. Under endoscopic visualization, the transverse process-pars junction was exposed using monopolar and bipolar cautery, microscissors, and a pituitary forceps (Fig. 4).

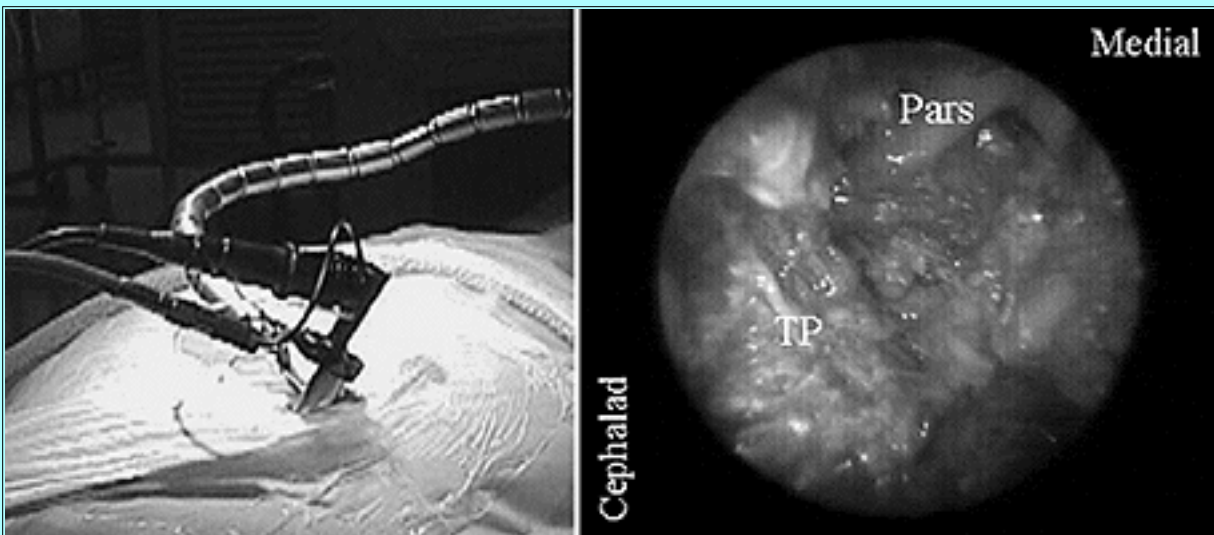


Fig. 4. Left: The tubular retractor with attached endoscope is held in position by the articulated arm. Right: The initial anatomical landmark is the lateral portion of the pars interarticularis at its junction with the transverse process.

Typically, the pars artery was identified, coagulated, and divided early in the exposure. The lateral edge of the pars was defined. Subsequently, an angled curette was used to dissect the undersurface of the inferomedial aspect of the transverse process and the pars, thereby releasing the medial aspect of the



intertransverse ligament (Fig. 5).

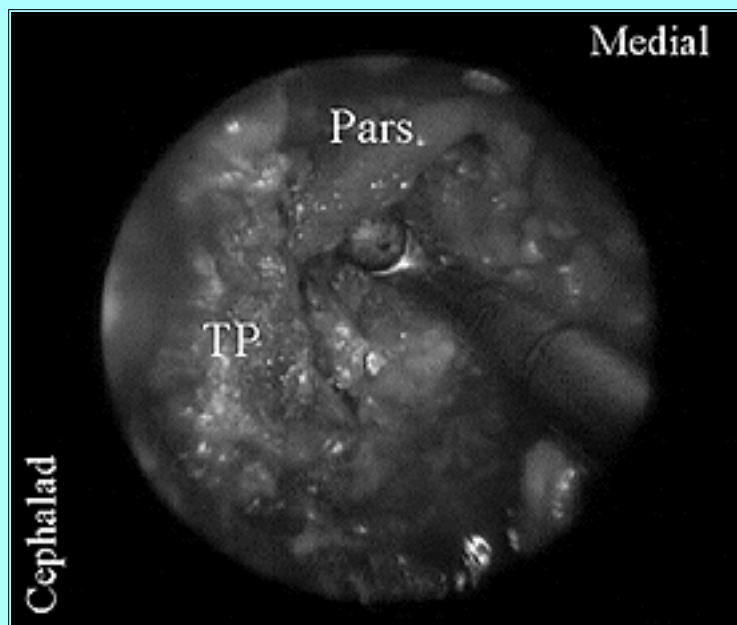


Fig. 5. The medial edge of the intertransverse ligament is released from the undersurface of the pars and inferomedial transverse process.

Resection of a small portion of the inferomedial transverse process and the most lateral aspect of the pars was then performed using an angled Kerrison rongeur. This maneuver opened the lateral aspect of the neuroforamen, allowing palpation of the pedicle and facilitating identification of the exiting nerve root adjacent to the pedicle (Fig. 6).

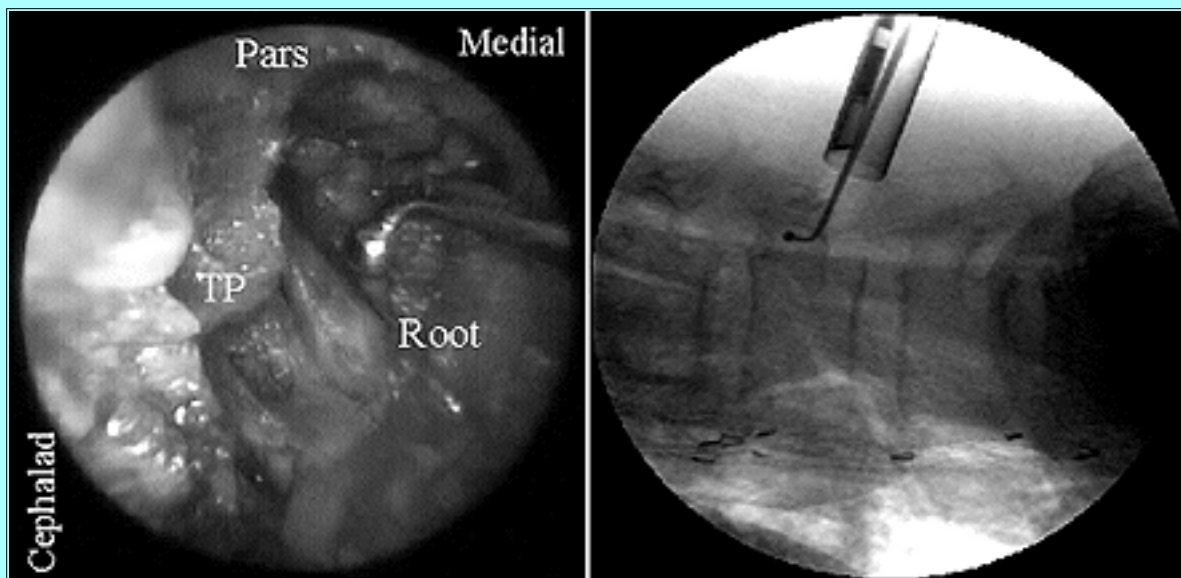


Fig. 6. A small portion of the lateral pars and inferomedial transverse process has been removed with a fine Kerrison rongeur. This maneuver allows for palpation of the pedicle (right) and facilitates identification of the exiting nerve root (left, adjacent to ball-tip probe).

Once the exiting root had been identified at the level of the pedicle, dissection was extended distally, following the course of the root toward the disc by angling the tubular retractor in a caudal direction. If coexisting facet hypertrophy impeded access to the root at the disc level, a small portion of the lateral margin of the superior articular process was resected using a Kerrison rongeur or high-speed drill. The

root was then explored and decompressed, with identification and removal of any sequestered disc fragments (Fig. 7). Subsequently, the disc space was entered to remove any additional disc material, if deemed necessary. Once the surgeon was satisfied with the root decompression, the wound was irrigated and the tubular retractor was removed. The muscle was left minimally traumatized and spontaneously reapproximated on removal of the retractor.

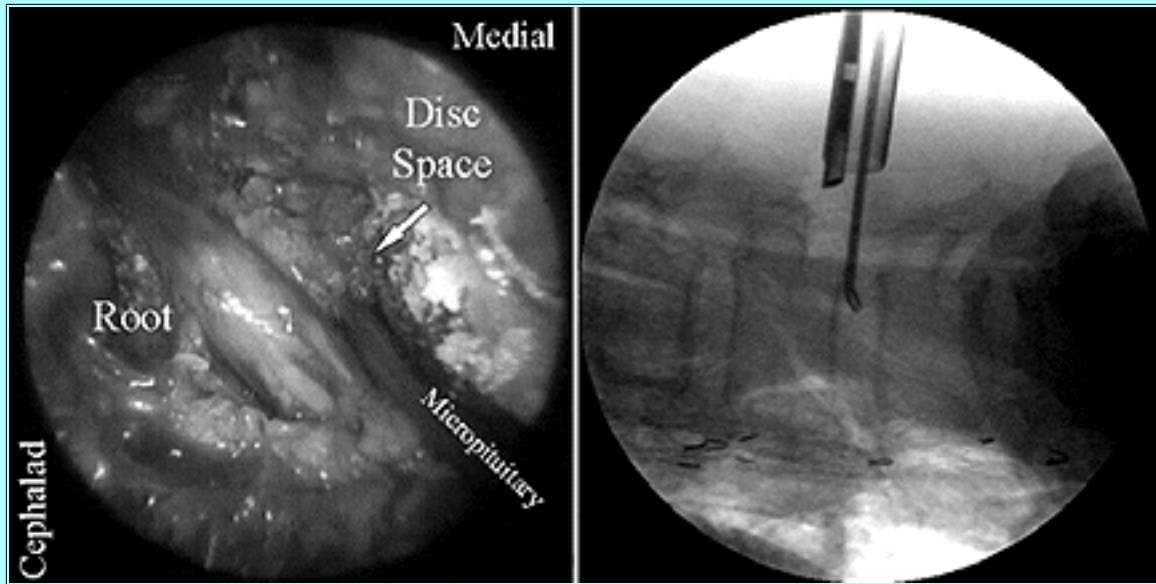


Fig. 7. A micropituitary rongeur has been inserted into the disc space, medial to the exiting nerve root.

## RESULTS

All procedures were completed using the aforementioned endoscopic technique. The operative time ranged from 90 to 120 minutes.

All patients were discharged less than 6 hours postprocedure. No patient required parenteral analgesic medication. Postdischarge, no patient required readmission to the hospital or the emergency room.

The follow-up periods ranged from 12 to 27 months. All patients improved. Using modified Macnab criteria to qualify outcome (Table 2), results were considered excellent in 10 cases and good in one. No patients experienced any residual motor deficits. Of the nine patients with preoperative sensory abnormalities, four had residual decreased sensation. One patient still experienced some mild degree of nonradicular pain.

Result	Criteria
excellent	no pain; no restriction of mobility; able to return to normal work & activities
good	occasional nonradicular pain; relief of presenting symptoms; able to return to modified work
fair	some improved functional capacity; still handicapped &/or unemployed
poor	continued objective symptoms of root involvement; additional op intervention needed at the index level, irrespective of length of postop follow up

All eight patients who worked preoperatively returned to work at an average of 21 days postoperatively.

There were no complications or recurrences in this small series of patients.

## DISCUSSION

The terms far lateral, extreme lateral, and extraforaminal have all been used to describe a lumbar disc herniation that compresses the nerve root exiting at the same disc level, lateral to the neuroforamen. Over the past two decades numerous reports have improved our understanding and management of these lesions. Far-lateral herniations represent 0.7 to 11.7% of all lumbar disc herniations.[1,2,11,16,26-28,35,36] They can present at any age, but usually occur in patients who are older than those with typical posterolateral herniations.[1-3,6,7,9-14,25-28,31,35,37] In contrast to these more common herniations, far-lateral lumbar disc herniations typically occur at more proximal lumbar levels, with L4-5 being the most common (30-60% of cases).[2,6,7,11-14,28,31,35,37,44] Consequently, they more commonly present with femoral radiculopathy. The clinical presentation of far-lateral disc herniations and the requisite diagnostic imaging are well documented in the literature and are not the focus of this paper.[1,2,6-12,14,16,25-28,31,35-37,44] However, a high index of suspicion and an awareness of the clinical and radiological manifestations of far-lateral disc herniations are necessary to avoid missing the sometimes elusive diagnosis.

Because of the relative infrequency of far-lateral lumbar disc herniations, reported series are limited by the small number of patients and by retrospective data.[1-3,6,7,9-12,14,16,17,25-29,31,35,40] Although a wide variety of operative approaches have been described, there is a continued debate regarding the ideal surgical technique for managing this entity. These approaches can be generally categorized as midline, paramedian, combined, and percutaneous.

Midline approaches are familiar to all spine surgeons and can provide good visualization of the neuroforamen, especially if the surgeon stands on the side contralateral to the herniation. To obtain exposure of far-lateral herniations, varying degrees of bony resection are typically necessary that may include complete resection of the pars interarticularis (foraminectomy) and/or the facet.[1,2,10,11,14,16,25-29] Such extensive bone resection undoubtedly provides excellent visualization of the exiting nerve root and the offending pathological entities, but may also lead to destabilization of the motion segment.[11,14,18,38]

To avoid such extensive bone resection, some authors recommend working both medial and lateral to the

neuroforamen (the combined approach).[7,10,11,12,17,26,28] To obtain adequate visualization of the intertransverse (transverse process-transverse process) anatomy, a combined approach requires extensive stripping and lateral retraction of the paraspinal muscles. Standard midline or combined approaches to far-lateral lumbar disc herniations are more extensive than those required for typical posterolateral disc herniations. The paraspinal muscular dysfunction and disability that result from midline dorsal spinal exposures have been well documented.[15,23,24,30,34,39,41]

The paramedian approach to far-lateral disc herniations offers a more direct approach to the neuroforamen.[3,6,31,35,40,43,44] Originally described by Wiltse,[42,43] this approach requires the splitting of muscles but very little bone resection. Despite these advantages, the approach is not familiar to many surgeons and has not gained widespread acceptance.

The use of percutaneous approaches to far-lateral lumbar disc herniation has been described previously.[4,21] The efficacy of these procedures, particularly automated percutaneous lumbar discectomy, has been questioned.[5,19,20] The best outcomes have been reported in patients with contained disc herniations.[4,5,19-22,32,33] Furthermore, the presence of bony lateral stenosis is a relative contraindication to most percutaneous disc procedures. The incidence of free pathological fragments and concomitant foraminal stenosis in surgically treated patients with far-lateral disc herniations has been reported to be as high as 92% and 72%, respectively.[2,3,7,11-13,28,31,35] In our series, a free fragment was present in seven (64%) of 11 patients, and lateral bone resection of an overhanging, hypertrophied facet was necessary in four (36%). For these reasons the authors specifically question the utility of other percutaneous techniques in the surgical treatment of far-lateral herniations.

Reported good or excellent clinical outcomes following the surgical management of far-lateral lumbar disc herniation range from 68 to 100%.[2,6,7,9-12,14,26,28,31,35,36] Good or excellent outcomes range from 70 to 100% with the use of a paramedian approach compared with 67 to 100% in series in which a midline or combined approach is used. Given the small size of our series and the lack of a control group, drawing any statistically significant conclusions regarding the MED technique as compared with open techniques is impossible. We have, however, demonstrated the efficacy of the microendoscopic approach to far-lateral lumbar disc herniations, producing clinical outcomes comparable with those published in the literature. Furthermore, the feasibility of this minimally invasive technique as a viable alternative to standard approaches to far-lateral disc herniations has also been demonstrated.

The reported length of hospital stay following surgical management of far-lateral disc herniation is 1 to 8 days.[6,12,31] Darden, et al., using a paramedian approach in 25 patients with these lesions, reported an average hospital stay of 3.8 days.[6] These authors believed that the hospital stay was longer in this group of patients as compared to those with typical posterolateral disc herniations secondary to the increased surgical exposure and greater average patient age. In contrast, we have demonstrated that the MED technique can be routinely performed on an outpatient basis. The resultant cost reduction provided by decreased hospital stay is advantageous.

It must be noted that all procedures were performed by the senior authors (K.T.F. and M.M.S.), both of whom developed the MED technique and have significant experience with its use for posterolateral disc herniations. The use of the MED system for far-lateral disc herniations is technically demanding and is not recommended until the surgeon has gained facility with its use for more typical disc herniations. Once mastered, however, MED offers a minimally invasive, muscle-splitting approach to far-lateral lumbar disc herniations. It requires minimal soft-tissue and bone resection, and the pathological herniated



disc is directly visualized, all through a 15-mm incision. This technique avoids significant muscle-related trauma, the risk of muscle denervation caused by extensive exposure, and potential spinal destabilization due to excessive bone resection.

In conclusion, the MED technique is both a feasible and efficacious minimally invasive approach to far-lateral lumbar disc herniation. It has significant potential to decrease the patient's hospital stay and perioperative morbidity. It is, however, a technically demanding procedure.

---

## References

1. Abdullah AF, Ditto EW III, Byrd EB, et al: Extreme-lateral lumbar disk herniations. Clinical syndrome and special problems of diagnosis. **J Neurosurg** **41**:229-234, 1974
2. Abdullah AF, Wolber PGH, Warfield JR, et al: Surgical management of extreme lateral lumbar disc herniations: review of 138 cases. **Neurosurgery** **22**:648-653, 1988
3. An HS, Vaccaro A, Simeone FA, et al: Herniated lumbar disc in patients over the age of fifty. **J Spinal Disord** **3**:143-146, 1990
4. Bonafe A, Tremoulet M, Sabatier J, et al: [Foraminal and latero-foraminal hernia. Mid-term results of percutaneous techniques nucleolysis-nucleotomy.] **Neurochirurgie** **39**:110-115, 1993 (Fr)
5. Chatterjee S, Foy PM, Findlay GF: Report of a controlled clinical trial comparing automated percutaneous lumbar discectomy and microdiscectomy in the treatment of contained lumbar disc herniation. **Spine** **20**:734-738, 1995
6. Darden BV II, Wade JF, Alexander R, et al: Far lateral disc herniations treated by microscopic fragment excision. Techniques and results. **Spine** **20**:1500-1515, 1995
7. Donaldson WF III, Star MJ, Thorne RP: Surgical treatment for the far lateral herniated disc. **Spine** **18**:1263-1267, 1993
8. Ducker TB: Extreme lateral lumbar disc herniation. **J Spinal Disord** **2**:131-141, 1992
9. Epstein NE: Different surgical approaches to far lateral lumbar herniations. **J Spinal Disord** **8**:383-394, 1995
10. Epstein NE: Evaluation of varied surgical approaches used in the management of 170 far-lateral lumbar disc herniations: indications and results. **J Neurosurg** **83**:648-656, 1995
11. Epstein NE, Epstein JA, Carras R, et al: Far lateral lumbar disc herniations and associated structural abnormalities. An evaluation in 60 patients of the comparative value of CT, MRI, and myelo-CT in diagnosis and management. **Spine** **15**:534-549, 1990
12. Faust SE, Ducker TB, VanHassent JA: Lateral lumbar disc herniations. **J Spinal Disord** **5**:97-103, 1992
13. Foley KT, Smith MM: Microendoscopic discectomy. **Tech Neurosurg** **3**:301-307, 1997
14. Garrido E, Connaughton PN: Unilateral facetectomy approach for lateral lumbar disc herniation. **J Neurosurg** **74**:754-756, 1991

15. Jackson RK: The long-term effects of wide laminectomy for lumbar disc excision. A review of 130 patients. **J Bone Joint Surg (Br)** **53**:609-616, 1971
16. Jackson RP, Glah JJ: Foraminal and extraforaminal lumbar disc herniation: diagnosis and treatment. **Spine** **12**:576-585, 1987
17. Jane JA, Haworth CS, Broaddus WC, et al: A neurosurgical approach to far-lateral disc herniation. Technical note. **J Neurosurg** **72**:143-144, 1990
18. Johnsson KE, Willner S, Johnsson K: Postoperative instability after decompression for lumbar spinal stenosis. **Spine** **11**:107-110, 1986
19. Kahanovitz N: Percutaneous discectomy. **Clin Orthop** **284**:75-79, 1992
20. Kahanovitz N, Viola K, Goldstein T, et al: A multicenter analysis of percutaneous discectomy. **Spine** **15**:713-715, 1990
21. Kambin P, O'Brien E, Zhou L, et al: Arthroscopic microdiscectomy and selective fragmentectomy. **Clin Orthop** **347**:150-167, 1998
22. Kambin P, Zhou L: History and current status of percutaneous arthroscopic disc surgery. **Spine** **22** (Suppl 24):57S-61S, 1996
23. Kawaguchi Y, Matsui H, Tsuji H: Back muscle injury after posterior lumbar spine surgery. A histologic and enzymatic analysis. **Spine** **21**:941-944, 1996
24. Kawaguchi Y, Yabuki S, Styf J, et al: Back muscle injury after posterior lumbar spine surgery. Topographic evaluation of intramuscular pressure and blood flow in the porcine back muscle during surgery. **Spine** **21**:2683-2688, 1996
25. Kornberg M: Extreme lateral lumbar disc herniations. Clinical syndrome and computed tomography recognition. **Spine** **12**:586-589, 1987
26. Kunogi J, Hasue M: Diagnosis and operative treatment of intraforaminal and extraforaminal nerve root compression. **Spine** **16**:1312-1320, 1991
27. Kurobane Y, Takahashi T, Tajima T, et al: Extraforaminal disc herniation. **Spine** **11**:260-268, 1986
28. Lejeune JP, Hladky JP, Cotten A, et al: Foraminal lumbar disc herniation. Experience with 83 patients. **Spine** **19**:1905-1908, 1994
29. Macnab I: Negative disc exploration. **J Bone Joint Surg (Am)** **53**:891-903, 1971
30. Macnab I, Cuthbert H, Godfrey CM: The incidence of denervation of the sacrospinales muscles following spinal surgery. **Spine** **2**:294-298, 1977
31. Maroon JC, Kopitnik TA, Schulhof LA, et al: Diagnosis and microsurgical approach to far-lateral disc herniation in the lumbar spine. **J Neurosurg** **72**:378-382, 1990
32. Mathews HH: Transforaminal endoscopic microdiscectomy. **Neurosurg Clin North Am** **7**:59-63, 1996

33. Mayer HM: Percutaneous lumbar disc surgery. **Spine** **19**:2719-2723, 1994
  34. Naylor A: The late results of laminectomy for lumbar disc prolapse. **J Bone Joint Surg (Br)** **56**:17-29, 1974
  35. O'Hara LJ, Marshall RW: Far lateral lumbar disc herniation. **J Bone Joint Surg (Br)** **79**:943-947, 1997
  36. Postacchini F, Montanaro A: Extreme lateral herniations of lumbar disk. **Clin Orthop** **138**:222-227, 1979
  37. Rust MS, Olivero WC: Far lateral disc herniations: the results of conservative management. **J Spinal Disord** **12**:138-140, 1999
  38. Shenkin HA, Hash CJ: Spondylolisthesis after multiple bilateral laminectomies and facetectomy for lumbar spondylosis. **J Neurosurg** **50**:45-47, 1979
  39. Sihvonen T, Herno A, Paljarvi L, et al: Local denervation atrophy of paraspinal muscles in postoperative failed back syndrome. **Spine** **18**:575-581, 1993
  40. Spencer DL, Bernstein AJ, Bridwell KH: Lumbar intervertebral disc surgery, in Bridwell KH, DeWald RL (eds): **Textbook of Spinal Surgery, ed 2**. Philadelphia: Lippincott-Raven, 1997, pp 1547-1560
  41. Styf J, Willen J: The effects of external compression by three different retractors on pressure in the erector spine muscles during and after posterior lumbar spine surgery in humans. **Spine** **23**:354-358, 1998
  42. Wiltse LL: The paraspinal sacrospinalis-splitting approach to the lumbar spine. **Clin Orthop** **91**:48-57, 1973
  43. Wiltse LL, Spencer CW: New uses and refinements of the paraspinal approach to the lumbar spine. **Spine** **13**:696-706, 1988
  44. Zindrick MR, Wiltse LL, Rauschnig W: Disc herniations lateral to the intervertebral foramen, in White AH, Rothman RH, Ray CD (eds): **Lumbar Spine Surgery. Techniques and Complications**. St. Louis: Mosby, 1987, pp 195-207
- 

Manuscript received November 1, 1999.

Accepted in final form November 8, 1999.

Research support was provided by Medtronic Sofamor Danek, Memphis, Tennessee.

Address reprint requests to: Kevin T. Foley, M.D., Image Guided Surgery Research Center, 220 South Claybrook, Suite 700, Memphis, Tennessee 38104. email: kfoley@usit.net.

---