

Midterm to Long-term Followup of Staged Reimplantation for Infected Hip Arthroplasty

Joaquin Sanchez-Sotelo MD, PhD, Daniel J. Berry MD,
Arlen D. Hanssen MD, Miguel E. Cabanela MD

Published online: 24 September 2008
© The Association of Bone and Joint Surgeons 2008

Abstract Most reports on two-stage reimplantation have focused on the short-term cure rate of infection, but little is known about long-term reinfection-free survival or mechanical durability. We retrospectively reviewed 168 patients (169 hips) with infected arthroplasty, all of whom had two-stage reimplantation for the treatment of an infected total hip arthroplasty between 1988 and 1998. In the second stage, the femoral component was fixed with antibiotic-loaded bone cement in 121 hips; the remaining femoral components and all acetabular components were uncemented. The minimum followup time was 2 years (mean, 7 years; range, 2–16 years). At most recent followup, 12 hips (7.1%) were reoperated on for reinfection and 13 hips (7.7%) were revised for aseptic loosening or osteolysis. Apparently aseptic loosening occurred on one or both sides of the joint in 24 hips (14.2%). The 10-year survivals free of reinfection and mechanical failure were 87.5% and 75.2% respectively. Nineteen hips dislocated and eight underwent revision surgery for instability. The

method of femoral component fixation, either with or without cement, did not correlate with risk of infection, loosening, or mechanical failure. Based on these results, the method of fixation used for the femoral component during two-stage reimplantation surgery should be based on the surgeon's preference for fixation combined with the assessment of femoral bone stock.

Level of Evidence: Level IV, case series. See the Guidelines for Authors for a complete description of levels of evidence.

Introduction

Deep periprosthetic infection is one of the most serious complications of hip arthroplasty [8, 9]. Ideally, treatment of this complication should accomplish eradication of infection, restoration of function, and durable joint reconstruction. Of the different treatment alternatives, removal of the prosthesis and all foreign material followed by delayed implantation of a new prosthesis, so-called two-stage reimplantation, is the most commonly used option in the United States and most other countries [9].

Most reports on the outcome of two-stage reimplantation for an infected THA have included relatively small numbers of patients and have focused on the short-term rate of reinfection [2, 5, 7, 11–15, 18]. Currently, most revisions performed in the absence of infection involve the use of uncemented femoral components [6, 16] because revision with a cemented femoral component is associated with a relatively high failure rate [3, 17]. However, cement fixation has been used classically for femoral component reimplantation because it allows the use of antibiotics in the cement to reduce the risk of recurrent infection [4]. Several recent studies seem to indicate the use of

Each author certifies that he or she has no commercial associations (e.g., consultancies, stock ownership, equity interest, patent/licensing arrangements, etc.) that might pose a conflict of interest in connection with the submitted article. One of the authors (DJB) receives royalties on selected Hip implants manufactured by DePuy; the Department of Orthopedic surgery receives royalty income from DePuy, Zimmer, and Stryker, some of which is used to fund some research activities. Each author certifies that his or her institution has approved the human protocol for this investigation, that all investigations were conducted in conformity with ethical principles of research, and that informed consent for participation in the study was obtained.

J. Sanchez-Sotelo (✉), D. J. Berry, A. D. Hanssen,
M. E. Cabanela
Department of Orthopaedic Surgery, Mayo Clinic,
200 First Street SW, Rochester, MN 55905, USA
e-mail: sanchezsotelo.joaquin@mayo.edu

cementless components in two-stage hip reimplantation is not associated with an increased rate of reinfection in the short term [11, 14]. However, the mid- to long-term rate of reinfection and mechanical failure of hip reimplantation using a cemented or uncemented femoral component is largely unknown.

The purposes of our study were to (1) determine the rate of survival free of infection, the survival free of femoral failure, and survival free of overall mechanical failure of two-stage reimplantation for the treatment of an infected THA using an uncemented acetabular component and a cemented or uncemented femoral component; (2) determine factors associated with the three survival endpoints; (3) establish rates and reasons for reoperation; (4) ascertain rates of dislocation; and (5) determine function at last followup.

Materials and Methods

Between January 1988 and December 1998 we treated 168 patients with infected arthroplasty (169 hips) with two-stage reimplantation for the treatment of an infected THA. Forty-two of the index arthroplasties had been performed at our institution and 127 were performed elsewhere and referred to us for the care of the infected hip arthroplasty. The infection complicated 106 primaries and 63 revision THAs. The median time between the index arthroplasty and the reimplantation arthroplasty was 5.1 years (range, 4 months to 20 years). There were 109 men and 59 women with a median age of 67 years (range, 32–89 years) at the time of reimplantation. Their mean height was 169 cm and their mean weight was 67 kg. We classified 42 patients as immunocompromised based on diabetes mellitus (22 patients), chronic steroid use (18 patients), use of cytotoxic drugs (one patient), and underlying infection with HIV (one patient). Thirty-two patients had a history of malignancy; these patients were not categorized as immunocompromised. There were 100 right and 69 left hips. The underlying diagnosis leading to the index THA was osteoarthritis in 99 hips, avascular necrosis in 20 hips, rheumatoid arthritis in 15 hips, femoral neck fracture in 11 hips, developmental dysplasia in eight hips, old septic arthritis in five hips, Perthes disease in three hips, slipped capital femoral epiphysis in three hips, ankylosing spondylitis in two hips, Paget disease in one hip, hemophilic arthropathy in one hip, and pigmented villonodular synovitis in one hip. All but nine of the 169 patients had a minimum of 2 years of followup. Four patients died less than 2 years after reimplantation, and one patient was lost to followup before 2 years after surgery. One of the patients who died had undergone surgical irrigation and débridement for recurrent infection; none of the other four patients

with less than 2 years of followup had evidence of infection at their last followup. The remaining four patients with less than 2 years of followup had resection for recurrent infection (three hips) or revision for aseptic loosening (one hip) within the first 2 years after reimplantation. The minimum followup for the remaining 160 hips averaged 2 years (mean, 7 years; range, 2–16 years). This study was approved by the Institutional Review Board and all patients provided consent for participation in this study.

We diagnosed deep periprosthetic infection if two or more cultures of intraoperative specimens yielded the same microorganism, if there was frank purulence surrounding the prosthesis at the time of resection, if there was evidence of acute inflammation on intraoperative histopathologic examination, and/or if a sinus tract communicated with the prosthesis. Positive intraoperative cultures were present in 146 hips, positive intraoperative pathology in 113 hips, and sinus formation in 12 hips. Frank purulence or other macroscopic surgical findings consistent with infection were present in 112 hips. Of the 23 hips with negative intraoperative cultures, we diagnosed the infection based on positive intraoperative pathology (13 hips), frank purulence (nine hips, six of them with positive pathology), a positive preoperative aspiration (14 hips, seven of them with positive pathology), and/or macroscopic evidence of infection.

We identified a single causative organism in 138 hips. Infections were considered polymicrobial in 22 hips with two (18 cases), three (three hips), or four (one hip) organisms cultured. We did not identify any infective organisms in nine hips (culture-negative infections). Causative infective organisms included *Staphylococcus aureus* (26), methicillin-resistant *S. aureus* (three), coagulase-negative staphylococci (48), methicillin-resistant coagulase-negative staphylococci (35), *Streptococcus* spp (21), and other miscellaneous organisms (Table 1). We cultured *S. aureus* in five and coagulase-negative staphylococci were cultured in 13 polymicrobial infections.

The two-staged procedures included removal of all prosthetic components, cement if present, and all foreign bodies followed by intravenous antibiotic therapy and delayed reimplantation of a THA. We used a spacer made of antibiotic-loaded polymethylmethacrylate in 31 hips, whereas the remaining hips were treated with resection arthroplasty for the time interval between implant removal and reimplantation. The average duration of intravenous antibiotic therapy was 6 weeks (range, 3–18 weeks). The median interval between resection and reimplantation was 9.4 months (range, 3–18 months). After reimplantation, we stopped antibiotics when the intraoperative cultures were finalized except in 16 patients (16 hips) in whom chronic oral suppression antibiotic therapy was used.

The surgical approach we used for the reimplantation was anterior in 128 hips, posterior in 32 hips, and

Table 1. Organisms cultured in the 169 hips included in this study

Culture	Single organism (138)	Polymicrobial (22)
Staphylococcus aureus (26)	21	5
Methicillin-resistant <i>S. aureus</i> (3)	3	—
Coagulase-negative staphylococci (48)	38	10
Methicillin-resistant coagulase-negative staphylococci (35)	32	3
Streptococcus spp (21)	18	3
Miscellaneous	Acinetobacter calcoaceticum	Actinomyces
	Bacillus spp	Bacillus
	Candida	Brucella abortus
	Corynebacterium	Cladosporium
	Escherichia coli (4)	Corynebacterium
	Enterobacter cloacae	Enterococcus spp
	Enterococcus spp (2)	Klebsiella oxytoca
	Erysipelothrix rhusiopathiae	Penicillium
	Peptostreptococcus spp (4)	Peptostreptococcus spp
	Propionibacterium acnes (5)	Propionibacterium spp
	Pseudomonas aeruginosa (3)	Serratia spp
	Salmonella spp (1)	
Culture negative (9)		

transtrochanteric in six hips; an extended trochanteric osteotomy was used in three hips. The acetabular components used at the time of reimplantation were uncemented and included Harris-Galante I (six), Harris-Galante II (39), and Trilogy (11) (Zimmer, Warsaw, IN); Osteonics PSL (78), Osteonics Spherical (17), and Osteonics Dual Geometry (two) (Osteonics, Allendale, NJ); Reflection (six) (Richards, Memphis, TN); and SROM Oblong (three) (DePuy, Warsaw, IN). We performed acetabular reconstruction using a custom-made component in one hip, a Muller reinforcement ring in five hips, and an acetabular cage in one hip. The diameter of the heads and polyethylene liners used included 22 mm (three), 26 mm (11), 28 mm (146), and 32 mm (six); we used a constrained liner in three hips.

We fixed the femoral component with antibiotic-loaded bone cement in 121 hips and without cement in 48 hips. Cemented components included Omnifit (41; Osteonics), Harris Precoat (31; Zimmer), Centralign (23; Zimmer), ODC (seven; Osteonics), Precision (six; Howmedica, Rutherford, NJ), Head-Neck (six; Howmedica), ZCH (Zimmer), Bias (one; Zimmer), PFC (one; DePuy), and Implex (one; Zimmer); one cemented component was

custom-made. The cement we used for fixation of the femoral component was loaded with vancomycin in 83 hips, tobramycin in 13 hips, and both vancomycin and tobramycin in 25 hips. Uncemented components included Solution (17; DePuy), Omnifit (11; Osteonics), Bias (11; Zimmer), Anatomic (four; Zimmer), Harris-Galante (two; Zimmer), Omniflex (two; Osteonics), and Wagner (one; Protek); one uncemented femoral component was custom-made.

We treated associated bone defects with bone graft or graft substitutes in 50 hips. Morselized bone allograft was used on the acetabular side in 37 hips, and it was augmented with demineralized bone matrix in three hips; we used demineralized bone matrix with no additional graft in one acetabulum. Morselized bone allograft was used on the femoral side in 10 hips. We used structural bone allograft on the femoral side in 13 hips.

Patients were followed up at 1 year, 2 years, 5 years, and every 5 years after arthroplasty by examination, standardized letter, or telephone questionnaire. We used the Harris hip score to assess functional outcome in 143 patients with enough data to calculate the score [10].

The Kaplan–Meier survival method was used to estimate long-term postoperative survival free of major reoperation for infection or mechanical failure. Reinfection was defined with the same criteria used for diagnosis of the index infection. We used paired t-tests or Wilcoxon signed rank tests when appropriate to determine the association between variables. We performed all analyses using SAS statistical software (Statistical Analysis System, Cary, NC).

Results

The estimated survival free of reinfection was 96.5% (range, 93.5%–99.6%) at 5 years and 87.5% (range, 79.6%–95.3%) at 10 years (Fig. 1A–C). The estimated survival free of femoral loosening was 97.9% (range, 95.5%–100%) at 5 years and 85.4% (range, 77.3%–94.2%) at 10 years. The estimated survival free of mechanical failure was 94.6% (range, 91%–98.3%) at 5 years and 75.2% (range, 66.1%–85.6%) at 10 years. Infection with *S. aureus* was associated with a lower ($p = 0.02$) survival free of infection compared with Staphylococcus coagulase-negative infection (70.8% versus 89.6%).

Female gender was associated with a lower ($p = 0.003$) survival free of mechanical failure. We found no other factors associated with survival free of reinfection, femoral loosening, or mechanical failure.

At most recent followup, 40 hips (24%) had been reoperated. Twelve hips (7.1%) had undergone resection (10 hips) or surgical irrigation and débridement (two hips) for recurrent infection. Thirteen additional hips (7.7%) had had revision surgery for aseptic loosening (12 hips) or

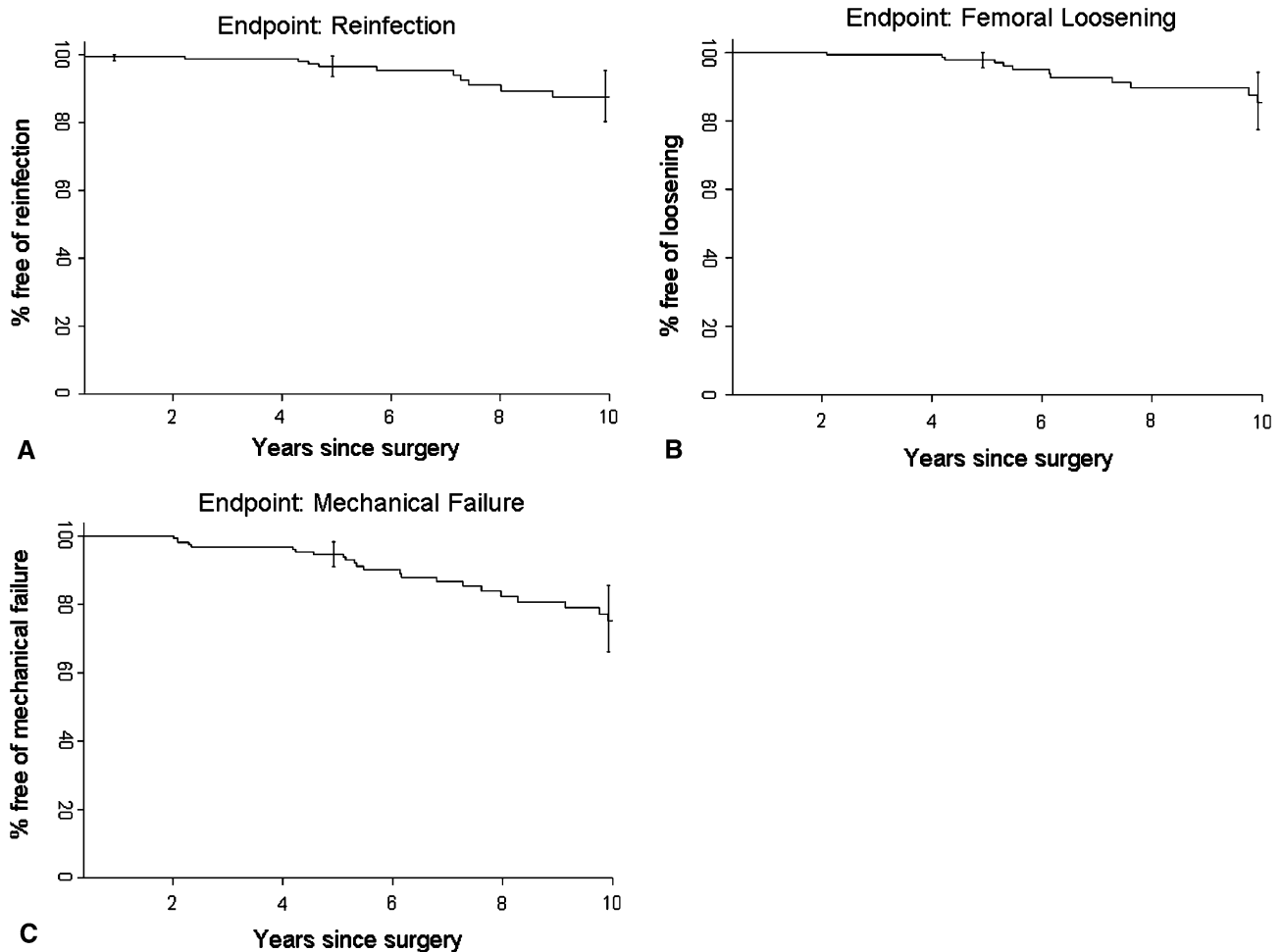


Fig. 1A–C Kaplan–Meier survivorship curves are shown for (A) reinfection, (B) femoral loosening, and (C) mechanical failure as end points.

osteolysis (one hip). The remaining 21 hips had undergone additional surgery for other reasons. The mean time to reoperation for reinfection was 3.3 years (range, 1 month to 11 years). The underlying diagnosis in the 12 hips with reinfection included osteoarthritis in eight hips, rheumatoid arthritis in two hips, developmental dysplasia in one hip, and femoral neck fracture in one hip. Of these 12 patients, five were immunocompromised as a result of diabetes mellitus (three patients) or corticosteroid use (two patients). Four of the 12 reinfections were diagnosed and treated within the first year after the reimplantation and the remaining eight were diagnosed more than 1 year after reimplantation. Antibiotic-loaded cement had been used for femoral component fixation in 10 of the 12 patients who had a reinfection. The risk of recurrent infection was not correlated with the type of organism or patient demographics. With the numbers available, we could not detect a difference in terms of either reinfection or mechanical failure rate based upon whether a spacer had been used or not. Thirteen hips had revision surgery for aseptic

loosening (12 hips) or osteolysis (one hip) at a mean time of 5.8 years (range, 11 months to 10 years) after the reimplantation. In addition, one small-diameter fully coated femoral component fractured and had revision surgery. All these hips had negative cultures and negative pathology at the time of revision. The indication for revision surgery was acetabular loosening in four hips, femoral loosening in three hips, loosening of both the acetabular and femoral component in five hips, and osteolysis in one hip. Revision surgery was performed within 2 years after the reimplantation in two hips, between 2 and 5 years after the reimplantation in three hips, and more than 5 years after the reimplantation in the remaining eight hips.

Based on its radiographic appearance, the acetabular component was considered loose in six additional hips and the femoral component was considered loose in seven additional hips (Fig. 2A–E). Overall, aseptic loosening was identified on one or both sides of the joint in 24 hips (14.2%); the acetabular component was loose in 12 hips, and the femoral component was loose in 16 hips. Cement

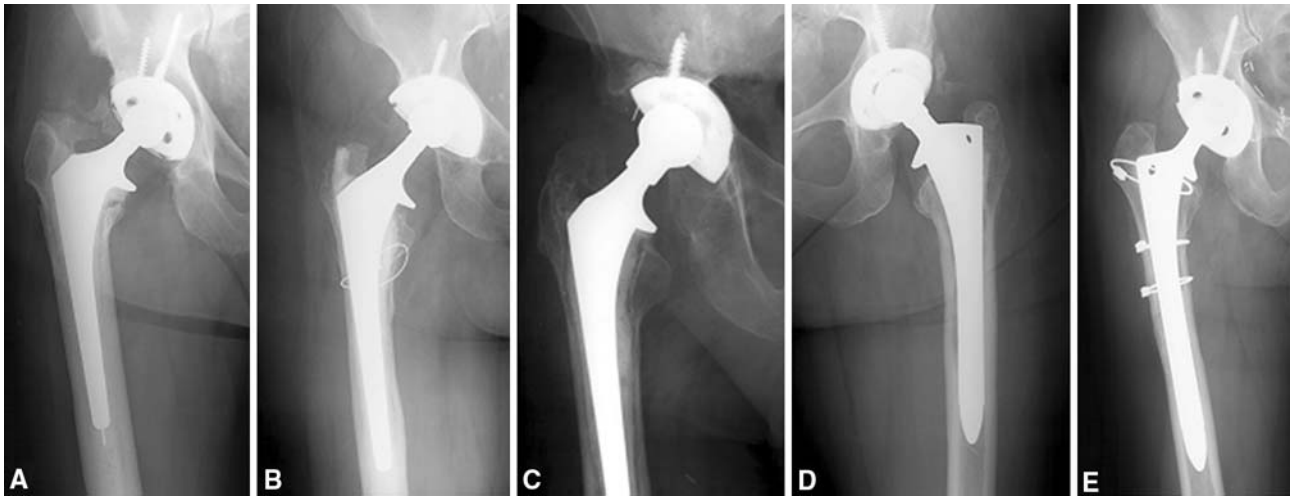


Fig. 2A–E (A) This figure shows a well-fixed cemented femoral component 5 years after reimplantation; (B) a well-fixed cemented femoral component 8 years after reimplantation; (C) a loose femoral component 6 years after reimplantation in a patient free of infection;

(D) a well-fixed uncemented fully coated stem 6 years after reimplantation; (E) and a well-fixed uncemented fully-coated stem 2 years after reimplantation. Note the well-healed extended trochanteric osteotomy.

had been used for fixation in seven of the 16 hips with femoral loosening. Femoral aseptic loosening affected seven of the 121 cemented femoral reimplantations (6%) and nine of the 48 uncemented femoral reimplantations (19%). With the numbers available, fixation of the femoral component with or without cement did not correlate with the risk of mechanical failure. Proximal femoral radiographic osteolysis was present in five hips, whereas acetabular osteolysis was present in two hips. Brooker III or IV heterotopic ossification was identified in five hips.

Nineteen hips (11%) sustained one or more episodes of dislocation. Three additional patients reported subluxation episodes. Eight hips were reoperated on for recurrent dislocation. Other complications included nine intraoperative femoral fractures, one intraoperative acetabular fracture, one postoperative femoral periprosthetic fracture, superficial wound infection (three hips), wound hematoma for which patients were reoperated (three hips), and deep venous thrombosis (two hips).

Before resection, most patients reported moderate or severe hip pain and poor function in addition to other symptoms. At most recent followup, 14 of the 143 patients without reoperation for reinfection, loosening, osteolysis, or component fracture had moderate pain and four reported severe pain. At most recent followup, the average Harris hip score for this group of patients was 70 points (range, 42–100 points).

Discussion

Deep periprosthetic hip infection remains a devastating complication with serious implications for affected patients

and a substantial financial impact [1]. Treatment options include chronic antibiotic suppression, débridement with component retention, component removal, one-stage implant exchange, and two-stage reimplantation [9]. Traditionally, the success of these various modalities is evaluated based on the likelihood of each of them to eradicate the infection. Two-stage reimplantation seems to provide the best chance of infection cure for most patients with an infected hip arthroplasty. However, reinfection is only one of the multiple failure modes of treatment; mechanical failure and dislocation may complicate reimplantation, translate into pain and poor function, and subsequent surgery. Most reports on the outcome of two-stage reimplantation for an infected THA have included relatively small numbers of patients and have focused on the short-term rate of reinfection [2, 5, 7, 11–15, 18]. The purpose of our study was to evaluate the midterm and long-term results with respect not only to the risk of reinfection, but also to the mechanical durability of two-stage reimplantation for the treatment of an infected THA using an uncemented acetabular component and a cemented or uncemented femoral component.

We note some limitations. This group was established over a long period of time and necessarily involved heterogeneity in use of cement spacers, antibiotic protocols, number of weeks between resection and reimplantation. We also used a diversity of implant designs. Thus, the treatments were not uniform. However, the long period did allow us to accumulate a relatively large number of patients and long followup.

Several important conclusions may be derived from the data in our study. Two-stage reimplantation is associated with a modest rate of both reinfection and mechanical

failure. The rate of reinfection in our study was 7.1%. The rate of mechanical failure was higher; aseptic loosening was identified on one or both sides of the joint in 14.2% of the hips, and two additional patients had surgery for osteolysis and a fractured stem. With the numbers available, reinfection and mechanical failure were not associated with patients' demographics or the use of cement for femoral component fixation. Infection with *Staphylococcus aureus* was associated with a lower 10-year survivorship free of reinfection. Recurrent dislocation was another relatively frequent complication after reimplantation, leading to revision surgery in a relatively large number of patients.

Currently, most revisions performed in the absence of infection involve the use of uncemented femoral components [6, 16] because revision with a cemented femoral component is associated with a relatively high failure rate [3, 17]. However, cement fixation has been used classically for femoral component reimplantation because it allows the use of antibiotics in the cement to reduce the risk of recurrent infection [4]. The initial experience using uncemented components for two-stage reimplantation was associated with a relatively high rate of reinfection [15]. More recent studies have reported improved infection cure rates using uncemented fixation for both the acetabular and the femoral components. Kraay et al. [11] reported a 7% reinfection rate in a consecutive series of 33 two-staged reimplantations using uncemented components; there were three cases of acetabular aseptic loosening, but none of the femoral components failed. Masri et al. [14] reported a 10.3% reinfection rate in a consecutive series of 29 patients treated with resection, placement of a PROSTALAC articulated spacer, and reimplantation with an uncemented femoral component. At a mean followup of 4 years, none of the components were loose. These data along with the results of our study suggest that with current techniques, the absence of antibiotic-loaded cement at the time of the second stage does not seem to increase the rate of reinfection.

The relatively high rate of mechanical failure in our study needs to be considered in light of the implant designs used during the study period. A large proportion of uncemented femoral components used in this study were designed for proximal fixation. Currently, most surgeons recognize the value of distal fixation in the revision setting. The use of uncemented components designed for distal fixation is likely to translate into decreased rates of mechanical failure after reimplantation.

Our data suggest two-stage reimplantation is associated with a high rate of early success in the treatment of deep infection after THA but is associated with a modest rate of recurrent infection or mechanical failure. As followup increases, a similar number of failures occur secondary to reinfection and mechanical failure. This suggests surgeons should place emphasis on sound mechanical reconstruction

during the second stage of treatment of the infected THA and not just on the eradication of infection.

References

1. Bozic KJ, Ries MD. The impact of infection after total hip arthroplasty on hospital and surgeon resource utilization. *J Bone Joint Surg Am.* 2005;87:1746–1751.
2. Colyer RA, Capello WN. Surgical treatment of the infected hip implant. Two-stage reimplantation with a one-month interval. *Clin Orthop Relat Res.* 1994;298:75–79.
3. Davis CM 3rd, Berry DJ, Harmsen WS. Cemented revision of failed uncemented femoral components of total hip arthroplasty. *J Bone Joint Surg Am.* 2003;85:1264–1269.
4. Duncan CP, Masri BA. The role of antibiotic-loaded cement in the treatment of an infection after a hip replacement. *Instr Course Lect.* 1995;44:305–313.
5. Fehring TK, Calton TF, Griffin WL. Cementless fixation in 2-stage reimplantation for periprosthetic sepsis. *J Arthroplasty.* 1999;14:175–181.
6. Garbuz DS, Toms A, Masri BA, Duncan CP. Improved outcome in femoral revision arthroplasty with tapered fluted modular titanium stems. *Clin Orthop Relat Res.* 2006;453:199–202.
7. Haddad FS, Muirhead-Allwood SK, Manktelow AR, Bacarese-Hamilton I. Two-stage uncemented revision hip arthroplasty for infection. *J Bone Joint Surg Br.* 2000;82:689–694.
8. Hanssen AD, Rand JA. Evaluation and treatment of infection at the site of a total hip or knee arthroplasty. *Instr Course Lect.* 1999;48:111–122.
9. Hanssen AD, Spangehl MJ. Treatment of the infected hip replacement. *Clin Orthop Relat Res.* 2004;420:63–71.
10. Harris WH. Traumatic arthritis of the hip after dislocation and acetabular fractures: treatment by mold arthroplasty. An end-result study using a new method of result evaluation. *J Bone Joint Surg Am.* 1969;51:737–755.
11. Kraay MJ, Goldberg VM, Fitzgerald SJ, Salata MJ. Cementless two-staged total hip arthroplasty for deep periprosthetic infection. *Clin Orthop Relat Res.* 2005;441:243–249.
12. Lai KA, Shen WJ, Yang CY, Lin RM, Lin CJ, Jou IM. Two-stage cementless revision THR after infection. 5 recurrences in 40 cases followed 2.5–7 years. *Acta Orthop Scand.* 1996; 67:325–328.
13. Lieberman JR, Callaway GH, Salvati EA, Pellicci PM, Brause BD. Treatment of the infected total hip arthroplasty with a two-stage reimplantation protocol. *Clin Orthop Relat Res.* 1994;301: 205–212.
14. Masri BA, Panagiotopoulos KP, Greidanus NV, Garbuz DS, Duncan CP. Cementless two-stage exchange arthroplasty for infection after total hip arthroplasty. *J Arthroplasty.* 2007;22: 72–78.
15. Nestor BJ, Hanssen AD, Ferrer-Gonzalez R, Fitzgerald RH Jr. The use of porous prostheses in delayed reconstruction of total hip replacements that have failed because of infection. *J Bone Joint Surg Am.* 1994;76:349–359.
16. Pappas WG, Greidanus NV, Antoniou J. Minimum 10-year results of extensively porous-coated stems in revision hip arthroplasty. *Clin Orthop Relat Res.* 1999;369:230–242.
17. Stromberg CN, Herberts P, Palmertz B. Cemented revision hip arthroplasty. A multicenter 5–9-year study of 204 first revisions for loosening. *Acta Orthop Scand.* 1992;63:111–119.
18. Younger AS, Duncan CP, Masri BA, McGraw RW. The outcome of two-stage arthroplasty using a custom-made interval spacer to treat the infected hip. *J Arthroplasty.* 1997;12:615–623.