

Migraine aura and related phenomena: beyond scotomata and scintillations

MB Vincent¹ & N Hadjikhani^{2,3,4}

¹Hospital Universitário Clementino Fraga Filho, Faculdade de Medicina, Universidade Federal do Rio de Janeiro, Brazil, ²Athinoula A. Martinos Center for Biomedical Imaging, Massachusetts General Hospital, Harvard Medical School, Charlestown, MA, USA, ³Division of Health Sciences and Technology, Harvard-MIT, Cambridge, MA, USA, and ⁴Brain Mind Institute, EPFL, Lausanne, Switzerland

Cephalalgia

Vincent MB & Hadjikhani N. Migraine aura and related phenomena: beyond scotomata and scintillations. *Cephalalgia* 2007. London. ISSN 0333-1024

Migraine affects the cortical physiology and may induce dysfunction both ictally and interictally. Although visual symptoms predominate during aura, other contiguous cortical areas related to less impressive symptoms are also impaired in migraine. Answers from 72.2% migraine with aura and 48.6% of migraine without aura patients on human faces and objects recognition, colour perception, proper names recalling and memory in general showed dysfunctions suggestive of prosopagnosia, dyschromatopsia, ideational apraxia, alien hand syndrome, proper name anomia or aphasia, varying in duration and severity. Symptoms frequently occurred in a successively building-up pattern fitting with the geographical distribution of the various cortical functions. When specifically inquired, migraineurs reveal less evident symptoms that are not usually considered during routine examination. Spreading depression most likely underlies the aura symptoms progression. Interictal involvement indicates that MWA and MWOA are not completely silent outside attacks, and that both subforms of migraine may share common mechanisms. □ *Migraine, aura, spreading depression, cortical dysfunction*

Maurice Vincent, Avenida das Américas, 1155/504, CEP 22631-000 Rio de Janeiro, Brazil. Tel. + 5521 24913678, fax + 5521 24943678, e-mail vincent@ufrj.br
Received 31 December 2006, accepted 30 March 2007

Introduction

Migraine is a disorder that may manifest as a myriad of neurological symptoms named aura, usually – but not always – preceding the typical headache phase. The most frequent aura (from Greek ‘breeze’) type is visual, characterized mostly by flashes of light, or bright zigzag, horseshoe shaped expanding visual perceptions (1). Some patients may experience diverse visual (2), as well as sensory (3), motor (4) or language disturbances (5), indicating that other areas of the cortex distinct from the occipital lobes must be affected.

The exact mechanism of aura is not known. The remarkable progressive nature of the aura symptoms fits with the pace of spreading depression (SD), a neurophysiological phenomenon present in grey matter of various species (6). The occurrence of

SD in humans has been debated, but both indirect and direct SD recordings (7, 8) are available (9). Existing evidence indicates that SD underlies migraine aura (7, 10). However, SD may also occur in migraine without aura (11). Recent data show that clinically effective migraine preventive drugs block SD (12).

The occipital cortex is considered the area where most migraine-related SD would start (7). Based on the fact that SD is a dynamic process that progresses throughout contiguous areas of the cortex, we tested the hypothesis that some of the SD waves in migraineurs would be expressed as more subtle neurological abnormalities involving neighbouring cortical areas more often than hitherto supposed. Specifically, we investigated for the presence of symptoms in migraineurs related to colours and complex visual phenomena, face recognition and memory in general, and whether patients

diagnosed as MWoA presented overlooked cortical dysfunction during routine consultations.

Patients and methods

This study was approved by the University Hospital Ethics Committee at UFRJ, Rio de Janeiro (protocol 077/06). Electronic mail messages containing specific questions about pre-headache symptoms in migraine (Table 1) were sent on 9 February 2006 to 553 migraine patients from one of the investigators files (MV), who had previously examined all patients. One hundred and fifty-eight (28.57%) messages were refused from servers due to various reasons including mailbox overflow or unknown recipients. A second reinforcing message was sent on 24 February 2006 to 96 recipients who had not replied. Among the 395 e-mails effectively sent, 143 (36.2%) individuals (females = 118 (82.5%); age = 36.9 ± 14.0 (11–84); age at onset = 17.6 ± 9.6 (4–55); migraine time span = 19.3 ± 14.0 (0–64), values in mean years \pm S.D. (min–max)) answered the questions. Data received until 15 March were collected and analysed together with further information obtained from individual records. To improve clarity, e-mails were further exchanged with some subjects in case of incomplete or doubtful answers. To avoid recall biases, symptoms not clearly and comprehensively remembered were not considered. Responders had previously to this study been classified as IHS 1988 migraine with aura (MWA) if at least two attacks had any type of aura ($n = 36$, 25.2%), otherwise they were considered as migraine without aura (MwoA, $n = 107$, 74.8%). Headache comorbidity was allowed, tension-type headache being the most frequent comorbid diagnosis (17.5%), and being more pronounced in the MWoA group (MWA, 2 (5.5%); MwoA, 23 (21.5%), $P = 0.0294$). The Mann–Whitney test was used for age comparisons, shown as mean years old \pm S.D. (P level of significance 0.05).

Table 1 E-mail questionnaire

Before the headache onset, have you ever noticed:

1	Difficulties in recognizing people? Do they have the usual appearance?
2	Changes in colours? Do colours get brighter? People or objects appear to have different colours?
3	Difficulties in recognizing familiar objects?
4	Difficulties in recalling proper names?
5	Other memory problems?
6	Please describe other phenomena you may find of interest.

Results

Seventy-eight (54.5%) patients reported abnormalities associated with higher tier areas, including face and colour recognition difficulties, language and memory abnormalities, as well as irritability and sleep disturbances. These disorders were related to the migraine attack, but in some cases persisted interictally (Table 2). Significantly more patients reported symptoms in the MWA group (MWA, 26 (72.2%); MwoA, 52 (48.6%); $P = 0.013$). However, the presence of cognitive changes associated with migraine attacks was noteworthy in the MWoA group. In total, 30 (20.9%) patients reported symptoms outside attacks (OA), equally distributed between the two migraine sub-forms (MWA, 7 (19.4%); MwoA, 23 (21.5%); $P = 0.793$). Attack-related memory disturbances comparing patients with and without complaints were not influenced by age (respectively 36.6 ± 16.6 and 35.8 ± 13.9 years old; $P = 0.8493$). Memory complaints regardless of attack association showed a tendency to increase with age (respectively 35.8 ± 13.9 and 40.7 ± 13.4 ; $P = 0.0588$).

Prosopagnosia and dyschromatopsia

Four individuals had prosopagnosia immediately before a migraine attack, and three mentioned suffering difficulties in physiognomy recognition irrespective of migraine attacks (Table 3). Two MWA patients reported dyschromatopsia. One of them also suffers from sleep-related seizures. She did not present typical visual aura symptoms, but colours 'get mixed up'. Although she easily recognizes faces, it is particularly difficult to remember peoples' names during the aura phase. The second patient, who also has prosopagnosia, reports that 'the colours get mixed' (Table 3, patient 2).

Migraine-related brighter colours were noticed by 20 patients (Table 2). This sensation was sometimes very marked ('colours get so bright that I feel they will attack me'). Brighter colours were much more common than the opposite, as only five patients (MWA, 4; MwoA, 1) reported AR colour paleness or a tendency to a colourless, black-and-white vision. Three out of these five subjects also had prosopagnosia (Table 3, patients 1, 2 and 4).

Visual agnosia

Six (AR, 5; OA, 1) individuals claimed object recognition was defective in association with attacks (Table 2), such as not recognizing familiar products

Table 2 Reported symptoms in migraine subjects

		Total		MWA		MwoA	
		n	%	n	%	n	%
Prosopagnosia	AR	4	2.80%	3	8.33%	1	0.93%
	OA	3	2.10%	2	5.56%	1	0.93%
Dyschromatopsia	AR	2	0.51%	2	5.56%	0	0.00%
Hypo/achromatopsia	AR	5	3.50%	4	11.11%	1	0.93%
Brighter colours	AR	20	13.99%	8	22.22%	12	11.21%
Visual agnosia	AR	5	3.50%	3	8.33%	2	1.87%
	OA	1	0.70%	0	0.00%	1	0.93%
Proper name agnosia	AR	14	9.79%	7	19.44%	7	6.54%
	OA	12	8.39%	5	13.89%	7	6.54%
Transient amnesia	AR	11	7.69%	3	8.33%	8	7.48%
	OA	21	14.69%	4	11.11%	17	15.89%
Aphasia	AR	7	4.90%	4	11.11%	3	2.80%
Irritability	AR	6	4.20%	2	5.56%	4	3.74%
Distraction	AR	11	7.69%	2	5.56%	9	8.41%
Fatigue/sleep	AR	4	2.80%	1	2.78%	3	2.80%
Yawning	AR	2	1.40%	0	0.00%	2	1.87%
Hungry/craving	AR	3	2.10%	1	2.78%	2	1.87%
Total subjects with symptoms		78	54.55%	26	72.22%	52	48.60%

MWA, migraine with aura; MwoA, migraine without aura.

AR, attack related; OA, outside attack.

in the supermarket. Only one patient (Table 3, subject 6) said objects might look unfamiliar OA.

Other attack-related symptoms

A feeling of general strangeness ('I feel my bed and pillow differently, as if I had changed to another body'), including a non-explainable sensation of imminent attack, was reported by some patients. The following reports were given each by a different subject: feeling of reduced speed of events as in a slow-motion movie; diplopia; visual perception of objects turning more 'fluid' and mixing one to each other. Remaining symptoms are displayed in Table 2.

The two richest and stereotyped aura descriptions are presented in further detail.

Complex aura 1: fortification spectra, prosopagnosia, apraxia, anaesthesia and aphasia

In a 31-year-old male MWA patient symptoms begin always by scintillations at the central part of the visual field, expanding outwards. His vision becomes distorted with dysmorphopsias and dyschromatopsias, followed by difficulty in recognizing human faces (Table 3, patient 2). Twenty minutes later, he notices paraesthesia at the middle right

forearm, progressively expanding both to the hand and proximally to the ipsilateral lower hemiface, gum and leg, until a complete right hemianaesthesia is present, which lasts for 2–3 h. There is no motor deficit. Marked aphasia develops 1–2 h afterwards, simultaneously with a mild headache. The aphasia may outlast the short headache phase for up to 3 days, and is accompanied by pronounced ideational apraxia, impeding the use of a fork, knife or toothbrush for 12–14 h. Less frequently, he may experience a left-sided hemiparaesthesia without aphasia. Attacks vary in frequency, from around once a week to years of being symptom-free. He experienced auras in different 'grades', from mild to serious, not just in terms of duration, but also for the symptoms' intensity.

Complex aura 2: fortification spectra, paraesthesia, weakness and alien hand syndrome (AHS)

A 29-year-old female MWA patient, suffering attacks since the age of 10, described her episodes as always starting by a poorly defined reduced visual acuity in the left side of the visual field, averaging one episode per month. After 15–20 min, she experiences expanding fortification spectra-like scintillations, leaving behind a scotoma that

Table 3 Prosopagnosia

	Gender	Age	Onset	Diagnosis		Patient's reports
1	Female	39	27	MWA*	AR	Before the attack: difficulties in recognizing people and objects. 'My brain works separately, information is there but I cannot retrieve it. The colours get opaque, towards black or white. Familiar objects and routes become strange.'
2	Male	31	14	MWA	AR	'I do not recognize familiar people. I cannot even recognize my own face in the mirror. I see shades of my face but not the whole face. It looks see-through. The same counts for the faces of others.'
3	Female	33	10	MWoA**	AR	Feelings of strangeness, of being slower. 'People are not recognized immediately. I must wait a little before I recognize them. It is like looking but not seeing.'
4	Female	33	21	MWA	AR	'When I look at peoples faces I do not identify the mouth, eyes and nose. I see faces like drawings, with the outline and one single colour inside.'
5	Female	58	44	MWA	OA	'I always have difficulties in recognizing physiognomies. If something changes, like hair colour or style, it gets more difficult to recognize. I usually wait until the person talks to me or gives any other hint.'
6	Female	29	20	MWoA***	OA	'Objects and people that should look familiar sometimes are strange.'
7	Male	49	7	MWA	OA	'I have problems with proper names and faces, not related to migraine attacks.'

Onset: Age of migraine onset, in years. AR: Attack related. OA: outside attack

*Lobar spontaneous cerebral haemorrhage 10 years after migraine onset, with secondary epilepsy. Concomitant idiopathic stabbing headache.

**She remembers once 'numbness' in one side of the body, but cannot confirm if that was related to a migraine attack. She never reported visual aura.

***Concomitant chronic tension-type headache. No history of seizures or other neurological disorders.

occupies almost all her visual field in 30 min, followed by paraesthesia starting at the right shoulder, progressively expanding to the ipsilateral hand. At this moment, a comparatively mild paraesthesia affects the left hand. As the paraesthesia progresses, the scotomata improve until she returns to normal vision. The next feeling is a clear visual sensation of non-ownership towards her distal right forearm and hand, followed some minutes later by a moderate migrainous headache. The patient avoids staring at the affected body segments due to the extreme unpleasantness of such sensations. This patient also experienced episodes of aphasia, macropsias and dysmorphopsias during aura.

Discussion

Data show that neurological symptoms in both MWA and MWoA other than the classic visual aura may be underestimated. Bizarre perceptions in migraine may be more frequent than commonly supposed (13). Data show that symptoms are frequently present not only during attack, but also

interictally in both types of migraine. This is in accordance with the fact that brain structural changes are present in migraine and may account for interictal dysfunction in various areas of the brain (14).

The most common form of migraine aura is visual. Fortification spectra are present in 20% of the cases (2). These typical migraine visual abnormalities are probably related to 'early' visual cortical areas. Spreading fMRI BOLD signals have been shown during visual aura initiating at the visual cortex (7), suggesting SD as the underlying pathophysiological process in migraine aura.

Other relatively rare complex visual abnormalities may occur in migraine. Lilliputian hallucinations, characterized by the vision of either people or objects as miniatures or small fantastic little animals or creatures, have been described, as well as splitting or misinterpretations of the body image (15), macro- and microsomatagnosia (16). In the so-called 'Alice in Wonderland syndrome' (17), which may be associated with migraine or epilepsy, patients experience bizarre perceptual sensations.

Migraine and agnosias

Object recognition impairment may represent failure in naming (optic aphasia), stimulus perception (appreciative agnosia) or meaning attribution (associative agnosia) (18). Visual recognition is related to specific cortical areas in the lateral occipital complex (LOC) (19). The transitory and sometimes mild form of object agnosia present in our cases does not allow precise appreciation of their cognitive disorders, but as the subjects specifically mentioned object recognition impairment irrespectively of naming difficulties, we are confident that associative agnosia is the most probable dysfunction.

This is the largest series of migraine aura-related prosopagnosia so far, as there are four similar cases published to the best of our knowledge (20–23). Although controversy has emerged concerning how independent prosopagnosia would be as compared with other visual agnosias, evidence supports the concept of face recognition as a specifically devoted brain function (18). This ability is located in at least two neighbouring visual areas, in the inferior occipital cortex (IOG) and in the lateral posterior fusiform gyrus (FFA) (24). Mostly right-sided – but also bilateral – FFA or IOG lesions may lead to prosopagnosia (25), as well as other simultaneous visual agnosia symptoms depending on the extension of the affected neighbouring cortices. The relative paucity of prosopagnosia in migraine may be related to the fact that this function is bilaterally located. Prosopagnosia may vary from inability to recognize one's own face in a mirror to failure related to some individuals in a particular context (18). The migraine-related prosopagnosia patients described herein presented other concomitant visual abnormalities such as dyschromatopsia and dysmorphopsia, indicating that broader areas of dysfunctional cortex are involved. Just behind the FFA lies area V8, which is implicated with the perception of colour and visual glowing stimuli (25, 26). In this series, subjects reported vision of brighter colours much more frequently than paleness. Interestingly enough, none of the four subjects with prosopagnosia during attacks perceived vivid colours, and actually, three were those who reported colourless vision. This suggests a dysfunction of V8-FFA/IOG areas during migraine aura.

As unilateral lesions of V8 may impair hue recognition in one hemifield, which is usually not noticed by the patients (27), patients may not be aware of aura-related hemiachromatopsia. Colour changes are not usually reported by migraine aura patients. Indeed, colourful positive visual

experiences are mostly related to epilepsy, as migraine visual aura tends to bright, glowing, flashing type of long-lasting vision changes (28). The bilateral representation of the hue recognition function may explain why relatively few migraineurs report on colour agnosia.

The alien-hand syndrome (AHS) is usually due to medial frontal, callosal or posterior lesions. Patients develop a complex of phenomena including foreign behaviour of a hand (Doctor Strangelove syndrome) or a feeling of non-ownership towards the affected limb (29). AHS has been rarely described in association with migraine (30). The self-attribution sense for the hand depends on a frontal-parietal interplay, the premotor cortex being particularly activated for this feeling (31).

Migraine, memory and language functions

Thinking disturbances have long been observed in migraine (32). Memory processes involve regions in the medial temporal lobes including the hippocampus, which may be implicated in migraine. SD has been documented in the hippocampus, where it may eventually induce damage (33); hippocampal SD may induce c-fos expression in the trigeminal nucleus caudalis (34). Memory dysfunction has been documented in migraine (35), including in the interictal phase (36). Distraction (36) and exaggerated sense of attentiveness (37) have been described in migraine. There is controversy concerning cognitive permanent deficits in migraine (38). Recognition of places has been related to the parahippocampal place area (39). If injured, these regions may explain the disorientation symptoms reported by migraineurs. Havoc to the temporal lobes may impair recalling of names in general (40), as well as proper names in particular (41), indicating that these areas may be functionally impaired in migraine.

Aphasia, sometimes insurmountable enough to impede communication, is a well-known disturbance during migraine aura. In a series of 164 'classic migraine' patients, 17% presented aphasia (42), which is even more prevalent in sporadic and familial hemiplegic migraine (43). This phenomenon is a clear indication of temporal/frontal dysfunction in migraine.

Migraine apraxia

Apraxia is the inability to perform a task in the absence of other neurological lesions impeditive of motor performance, such as weakness, akinesia,

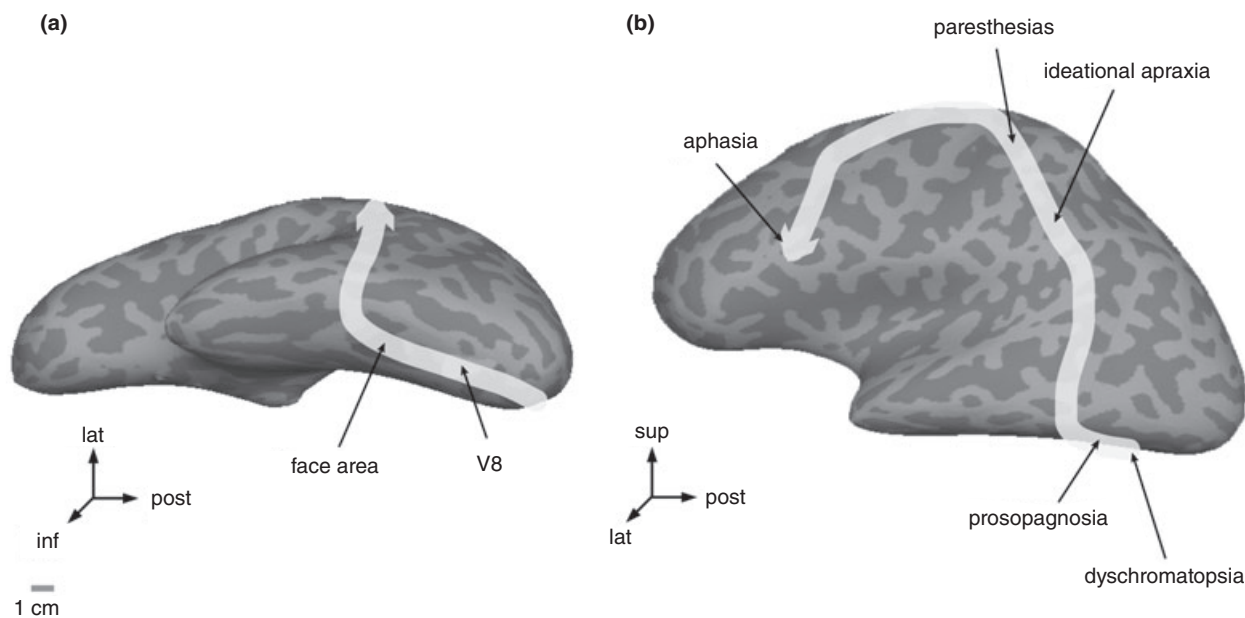


Figure 1 The add-on symptoms pattern presented by the complex aura patient 1 is related to contiguous cortical areas successively affected as indicated by the yellow arrow. Human artificially flattened cortical surfaces obtained by MRI imaging as described elsewhere (54) are used to illustrate the position of the distinct cortical functions. Panel A: inferior view. Panel B: lateral view.

incoordination, or movement disorders (44). Limb apraxias may be classified as kinetic (inability to perform fine and precise movements), ideomotor (inability to perform purposive movements according to what had been previously imagined) and ideational (failure in the ideation of a tool use) (45). There is probably no unique lesion site for apraxia, as many parietal-frontal networking systems are required for movement planning (45). Left parietal lesions in humans are related to apraxia (46). As our patient does not suffer from any motor complaint but does present sensory deficits, it is probable that his apraxic symptoms are related to left parietal dysfunction. To the best of our knowledge, we are not aware of other similar aura-related apraxia cases.

Spreading depression

Several lines of evidence support the possibility of SD underlying migraine aura pathophysiology. First, the typical zigzag patterns as described by Lashley (47) are compatible with SD propagating on the primary visual cortex, based on the organization of orientation preference maps in V1 (48). Secondly, the multitude of successive cortical dysfunctions in migraine aura fits with a propagating type of disorder. Our aura cases have first occipital symptomatology, progressing afterwards in a

geographically compatible pattern to successive cortical areas, as suggested by the building-up symptomatology (Figures 1 and 2). Although irrefutable human documentation of SD propagating beyond the central sulcus is not available, this phenomenon remains as the most suitable explanation for the complex symptoms in our cases. Moreover, the timing, as suggested by Lashley (47), is compatible with the known SD propagation velocity considering the cortical function maps and their relative positions. Thirdly, fMRI data obtained during human aura show a BOLD signal changes propagating at velocity of 3.5 ± 1.1 mm/min, again within the same range (7).

The analysis of the present cases and general experience indicate that aura symptoms, regardless of their form, vary to a great extent in duration and severity from patient to patient, and also within the same individual. Positive visual phenomena may present as tiny, mild light spots of short duration, as well as vision impairing impressive fortification spectra. There are patients who recurrently present one type of aura for many years, and change to a new pattern without obvious reasons. Aphasia is sometimes so marked that patients cannot communicate, but in other cases, there is but a mild language dysfunction. This variability accounts for all aura phenomena, including motor, sensory, and

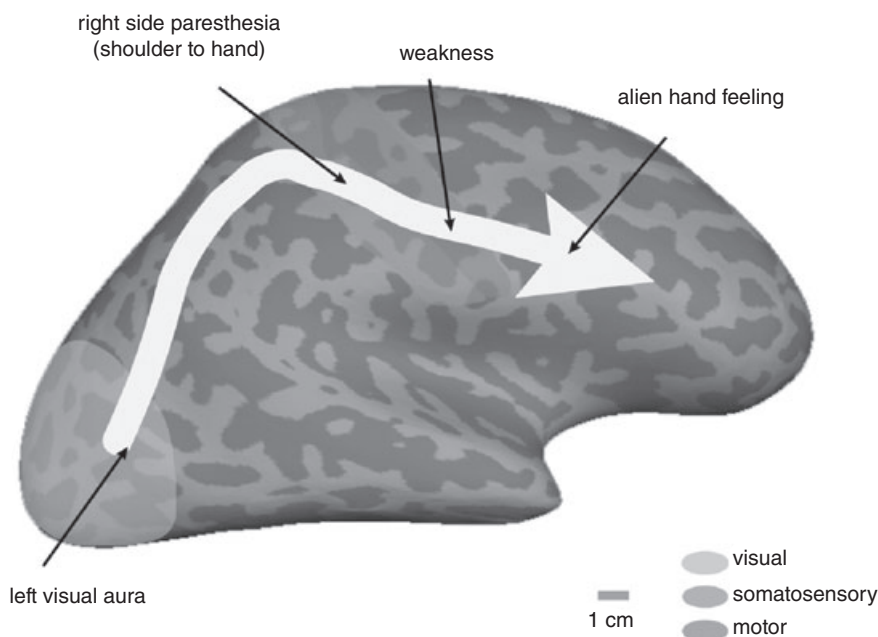


Figure 2 The add-on symptoms pattern presented by the complex aura patient 2 spreads throughout contiguous cortical areas successively affected as indicated by the yellow arrow. A human artificially flattened cortical surface obtained by MRI imaging as described elsewhere (54) is used to illustrate the position of the distinct cortical functions.

even our prosopagnosia findings. It is noteworthy that SD is not a multigradient, progressive phenomenon, but rather an all-or-nothing sort of event. Provided SD produces aura symptoms in migraine, clinical expression does vary in intensity while the underlying pathophysiological process does not. There seems to be therefore a clinically variable clinical expression threshold (CET) that determines to which extent the pathophysiological underlying processes is translated into symptoms (Figure 3). MWA is a condition in which this hypothetical PT is relatively low, leading patients to have most of their attacks (but not necessarily all) accompanied by aura. On the contrary, in MWOA, with the CET being relatively insensible, underlying SD would not be expressed as aura symptoms. This is supported by existing SD-compatible neuroimaging findings (11).

The number of patients who reported symptoms not related to attacks is expressive, and did not differ between MWA and MWOA. Interictal transient visual disturbances may represent mild auras and are present in the general population (49). Mild visual auras are also supported by the findings of Cologno et al., who reported on 13.6% of transient visual disturbances in MWOA (50). A series of interictal abnormalities, such as changes in vigour (51) or attention (36), have been described in migraine, suggesting that the pathophysiological mechanism

underlying the attacks, putatively SD, may occur rather frequently in subclinical or mildly expressed forms.

Electronic internet-based surveys ('e-surveys') are emerging as an alternative research methodology, but results may be influenced by response biases (52). First, researchers do not control how many recipients really read the questionnaires. Secondly, patients suffering from the inquired abnormalities tend to respond at a higher rate, leading to an overestimation due to a non-responders bias (53). Thus, the percentages obtained here may not reflect accurately the symptoms' real occurrence rates. Nevertheless, the results clearly indicate that certain cortical dysfunctions must be largely underestimated in migraine because specific questioning is not part of the routine clinical evaluation. Another important methodological issue to be considered is recall bias, as information not directly requested was also considered in this survey (question 6, Table 1). Complex or less clear cognitive changes are particularly susceptible to recall biases. Thus, it is possible subjects erroneously describe or relate them to migraine, if they had occurred too far in the past. On the other hand, clear-cut disturbances such as prosopagnosia are hardly forgotten. As this is a retrospective study and therefore subjects did not register the ongoing development of their symptoms, time restrictions relative to the headache

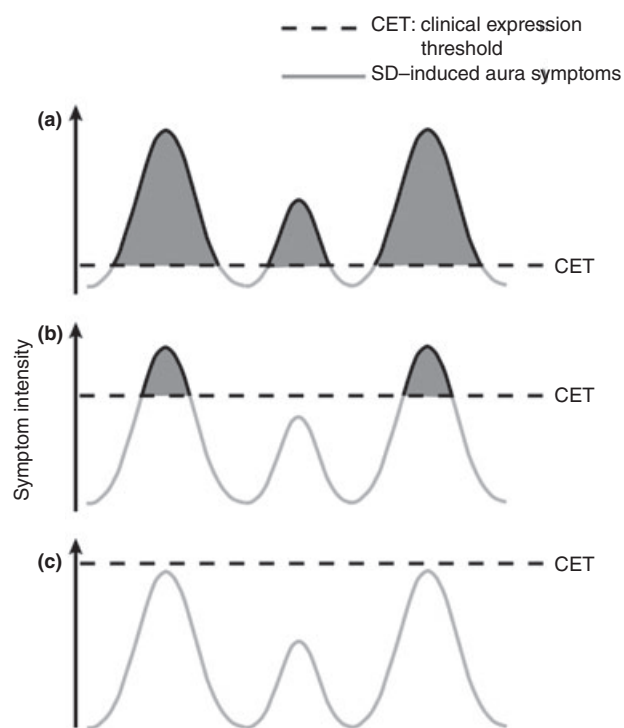


Figure 3 Schematic representation of aura clinical expression in migraine. Depending on the patient sensitivity, as indicated by the hypothetical 'clinical expression threshold' (dotted line), the underlying pathological process in migraine would be translated into symptoms. In panel A, the patient is comparatively sensitive to aura symptoms, leading to massive and variable phenotypes. In panel B, sensitivity is comparatively reduced, leading to mild aura phenomena. In panel C, due to a very resistant status, aura is not clinically expressed.

phase were not considered. However, all attack-related symptoms were relatively close in time to the head pain, making the possibility of aura-related phenomena more likely than prodromic events. The final methodological issue to be raised is the fact that no patient underwent formal neuropsychological examination, leading to the possibility of misinterpretation of symptoms. In spite of this, the episodic nature in most of the dysfunctions would impair the results of interictal cognitive testing. The methodological restrictions were minimized, however, by case histories analysis among the responders. Epidemiological studies (specifically designed) are needed to estimate the precise prevalence of distinct cortical symptoms in migraine.

This study does not allow conclusions on the possible effects of preventive drugs. Medication included agents such as topiramate and sodium divalpoate, which may be related to cognitive

changes. The majority of the subjects were on migraine prophylaxis, with different agents, either isolated or in combination, in distinct periods during various lengths of time. The symptoms, however, were not related by the subjects to the medication calendar, and were therefore more likely related to the disease itself. Attack-related symptoms are less probably induced by medication. Complex spreading symptoms following add-on patterns as seen in some cases are hardly due to side effects. Finally, no patient related the reported symptoms to the use of a particular medication. Less marked cognitive phenomena, such as mild memory problems, may have been induced by drugs. As patients were contacted by e-mail, psychiatric or other comorbidity could not be excluded, which could have influenced some reports.

In conclusion, MWA and MWoA are symptom-rich neurological conditions marked by overlooked abnormalities that may predominate during attacks but also occur at interictal phases. This may indicate that MWA and MWoA are closer to each other if comprehensively appraised. Today's knowledge on cortical function mapping, previous neuroimaging studies, the aura time course, and the add-on pattern of different symptoms' progression during aura, support SD as the most probable pathophysiological aura underlying the phenomenon. Doubt remains as to why SD, an all-or-nothing type of cortical event, expresses at different degrees from the clinical point of view. The pathophysiology of migraine will not be understood before the mechanisms behind the clinical expression of SD become apparent.

Acknowledgements

The authors are indebted to Dr Michael Moskowitz, Professor of Neurology at Harvard Medical School, Boston, USA, for his comments on the manuscript. Financial support: Maurice Vincent, CAPES – Coordenação de Aperfeiçoamento de Pessoal de Nivel Superior, Ministry of Education, Brazil, and Fulbright, USA, for a visiting professor scholarship; Nouchine Hadjikhani, NIH grant 5PO1 NS 35611-09. The authors have reported no conflicts of interests. MV has full access to all of the data in the study and takes responsibility for the integrity of the data and the accuracy of the data analysis.

References

- 1 Cologno D, Torelli P, Manzoni GC. Migraine with aura: a review of 81 patients at 10–20 years' follow-up. *Cephalalgia* 1998; 18:690–6.

- 2 Queiroz LP, Rapoport AM, Weeks RE, Sheftell FD, Siegel SE, Baskin SM. Characteristics of migraine visual aura. *Headache* 1997; 37:137–41.
- 3 Jensen K, Tfelt-Hansen P, Lauritzen M, Olesen J. Classic migraine. A prospective recording of symptoms. *Acta Neurol Scand* 1986; 73:359–62.
- 4 Thomsen LL, Olesen J. Sporadic hemiplegic migraine. *Cephalalgia* 2004; 24:1016–23.
- 5 Almeida DB, Arruda WO, Ramina R, Pedrozo AA, Raskin S. Migrânea com afasia. Relato de uma família. *Arq Neuropsiquiatr* 1999; 57:111–3.
- 6 Leão AAP, Morison RS. Propagation of spreading cortical depression. *J Neurophysiol* 1945; 8:33–45.
- 7 Hadjikhani N, Sanchez Del Rio M, Wu O, Schwartz D, Bakker D, Fischl B et al. Mechanisms of migraine aura revealed by functional MRI in human visual cortex. *Proc Natl Acad Sci USA* 2001; 98:4687–92.
- 8 Avoli M, Drapeau C, Louvel J, Pumain R, Oliver A, Villemure J-G. Epileptiform activity induced by low extracellular magnesium in the human cortex maintained in vitro. *Ann Neurol* 1991; 30:589–96.
- 9 Dreier JP, Woitzik J, Fabricius M, Bhatia R, Major S, Drenckhahn C, et al. Delayed ischaemic neurological deficits after subarachnoid haemorrhage are associated with clusters of spreading depolarizations. *Brain* 2006; 129:3224–37.
- 10 Milner PM. Note on a possible correspondence between the scotomas of migraine and spreading depression of Leão. *Electroencephal Clin Neurophysiol* 1958; 10:705.
- 11 Woods RP, Iacoboni M, Mazziotta JC. Bilateral spreading cerebral hypoperfusion during spontaneous migraine headache. *New Engl J Med* 1994; 331:1689–92.
- 12 Ayata C, Jin H, Kudo C, Dalkara T, Moskowitz MA. Suppression of cortical spreading depression in migraine prophylaxis. *Ann Neurol* 2006; 59:652–61.
- 13 Morrison DP. Abnormal perceptual experiences in migraine. *Cephalalgia* 1990; 10:273–7.
- 14 Granziera C, Dasilva AF, Snyder J, Tuch DS, Hadjikhani N. Anatomical alterations of the visual motion processing network in migraine with and without aura. *Plos Med* 2006; 3:e402.
- 15 Podoll K, Robinson D. Splitting of the body image as a somesthetic aura symptom in migraine. *Cephalalgia* 2002; 22:62–5.
- 16 Lippman CW. Certain hallucinations peculiar to migraine. *J Nerv Ment Dis* 1952; 116:346–51.
- 17 Evans RW, Rolak LA. The Alice in Wonderland syndrome. *Headache* 2004; 44:624–5.
- 18 De Renzi E. Disorders of visual recognition. *Semin Neurol* 2000; 20:479–85.
- 19 Malach R, Reppas JB, Benson RR, Kwong KK, Jiang H, Kennedy WA, et al. Object-related activity revealed by functional magnetic resonance imaging in human occipital cortex. *Proc Natl Acad Sci USA* 1995; 92:8135–9.
- 20 Martins IP, Cunha e Sa M. Loss of topographic memory and prosopagnosia during migraine aura. *Cephalalgia* 1999; 19:841–3.
- 21 Sandor P, Morath G, Hess K, Kaube H, Agosti R, Regard M. Prosopagnosia as symptom of migraine with aura: a case report. *Cephalalgia* 2006; 26:345–8.
- 22 Lawden MC, Cleland PG. Achromatopsia in the aura of migraine. *J Neurol, Neurosurgery Psychiatry* 1993; 56:708–9.
- 23 Sacks O. *Migraine*. London: Faber and Faber, 1991.
- 24 Haxby JV, Hoffman EA, Gobbini MI. The distributed human neural system for face perception. *Trends Cogn Sci* 2000; 4:223–33.
- 25 Bouvier SE, Engel SA. Behavioral deficits and cortical damage loci in cerebral achromatopsia. *Cereb Cortex* 2006; 16:183–91.
- 26 Hadjikhani N, Liu AK, Dale AM, Cavanagh P, Tootell RB. Retinotopy and color sensitivity in human visual cortical area V8. *Nat Neurosci* 1998; 1:235–41.
- 27 Damasio A, Yamada T, Damasio H, Corbett J, McKee J. Central achromatopsia: behavioral, anatomic, and physiologic aspects. *Neurology* 1980; 30:1064–71.
- 28 Panayiotopoulos CP. Elementary visual hallucinations, blindness, and headache in idiopathic occipital epilepsy: differentiation from migraine. *J Neurol Neurosurg Psychiatry* 1999; 66:536–40.
- 29 Biran I, Chatterjee A. Alien hand syndrome. *Arch Neurol* 2004; 61:292–4.
- 30 Raieli V, Eliseo GL, Monforte EM, Puma D, Ragusa D, Eliseo M. The alien hand and migraine with aura: a case report. *Cephalalgia* 2002; 22:692–4.
- 31 Ehrsson HH, Spence C, Passingham RE. That's my hand! Activity in premotor cortex reflects feeling of ownership of a limb. *Science* 2004; 305:875–7.
- 32 Ekblom KA. Duration of the scintillating scotoma. *Headache* 1975; 14:241–6.
- 33 Pomper JK, Haack S, Petzold GC, Buchheim K, Gabriel S, Hoffmann U et al. Repetitive spreading depression-like events result in cell damage in juvenile hippocampal slice cultures maintained in normoxia. *J Neurophysiol* 2006; 95:355–68.
- 34 Kunkler PE, Kraig RP. Hippocampal spreading depression bilaterally activates the caudal trigeminal nucleus in rodents. *Hippocampus* 2003; 13:835–44.
- 35 Le Pira F, Zappala G, Giuffrida S, Lo Bartolo ML, Reggio E, Morana R et al. Memory disturbances in migraine with and without aura: a strategy problem? *Cephalalgia* 2000; 20:475–8.
- 36 Mulder EJ, Linssen WH, Passchier J, Orlebeke JF, de Geus EJ. Interictal and postictal cognitive changes in migraine. *Cephalalgia* 1999; 19:557–65, discussion 541.
- 37 Podoll K, Robinson D. Recurrent Lilliputian hallucinations as visual aura symptom in migraine. *Cephalalgia* 2001; 21:990–2.
- 38 Pearson AJ, Chronicle EP, Maylor EA, Bruce LA. Cognitive function is not impaired in people with a long history of migraine: a blinded study. *Cephalalgia* 2006; 26:74–80.
- 39 Epstein R, Kanwisher N. A cortical representation of the local visual environment. *Nature* 1998; 392:598–601.
- 40 Seidenberg M, Geary E, Hermann B. Investigating temporal lobe contribution to confrontation naming using MRI quantitative volumetrics. *J Int Neuropsychol Soc* 2005; 11:358–66.
- 41 Hanley JR, Kay J. Proper name anomia and anomia for the names of people: functionally dissociable impairments? *Cortex* 1998; 34:155–8.

- 42 Manzoni GC, Farina S, Lanfranchi M, Solari A. Classic migraine – clinical findings in 164 patients. *Eur Neurol* 1985; 24:163–9.
- 43 Eriksen MK, Thomsen LL, Olesen J. Implications of clinical subtypes of migraine with aura. *Headache* 2006; 46:286–97.
- 44 Ochipa C, Gonzalez Rothi LJ. Limb apraxia. *Semin Neurol* 2000; 20:471–8.
- 45 Leiguarda RC, Marsden CD. Limb apraxias: higher-order disorders of sensorimotor integration. *Brain* 2000; 123:860–79.
- 46 Rushworth MF, Johansen-Berg H, Gobel SM, Devlin JT. The left parietal and premotor cortices: motor attention and selection. *Neuroimage* 2003; 20 (Suppl. 1):S89–100.
- 47 Lashley KS. Patterns of cerebral integration indicated by the scotomas of migraine. *Arch Neurol Psychiatry* 1941; 46:259–64.
- 48 Dahlem MA, Engelmann R, Lowel S, Muller SC. Does the migraine aura reflect cortical organization? *Eur J Neurosci* 2000; 12:767–70.
- 49 Mattsson P, Lundberg PO. Characteristics and prevalence of transient visual disturbances indicative of migraine visual aura. *Cephalalgia* 1999; 19:479–84.
- 50 Cologno D, Torelli P, Manzoni GC. Transient visual disturbances during migraine without aura attacks. *Headache* 2002; 42:930–3.
- 51 Stronks DL, Tulen JH, Busmann JB, Mulder LJ, Passchier J. Interictal daily functioning in migraine. *Cephalalgia* 2004; 24:271–9.
- 52 Eysenbach G, Wyatt J. Using the internet for surveys and health research. *J Med Internet Res* 2002; 4:e13.
- 53 Kjoller M, Thoning H. Characteristics of non-response in the Danish Health Interview Surveys, 1987–94. *Eur J Public Health* 2005; 15:528–35.
- 54 Dale AM, Fischl B, Sereno MI. Cortical surface-based analysis. I. Segmentation and surface reconstruction. *Neuroimage* 1999; 9:179–94.