

CASE REPORT

MIGRATING FOREIGN BODY IN THE THYROID GLAND, AN UNUSUAL CASE

Tatheer Zohra, Mubasher Ikram, Moghira Iqbal, Shabbir Akhtar, Seyed Akbar Abbas

Department of Otolaryngology Head and Neck Surgery, Aga Khan University Hospital, Karachi, Pakistan.

We report an unusual case of an ingested foreign body in 26 year old female that perforated the esophagus and penetrated the thyroid gland. A neck exploration was done to remove the foreign body.

Keywords: Foreign body, Thyroid gland, perforated esophagus

INTRODUCTION

In literature various cases have been described where foreign bodies ingested were lodged in the upper aero digestive tract, but only few of these foreign bodies perforate the oesophagus and an even fewer migrate extraluminally.¹ If untreated, they may result in life threatening suppurative or vascular complications. Exploration of the neck via an external approach to remove the foreign body is the recommended treatment. The CT scan utilizing fine cuts is invaluable in localizing the foreign body for exploration. Oesophageal penetration and migration of oesophageal foreign bodies into the thyroid gland is extremely rare with only occasional case reports appearing in the medical literature over the years. We report an unusual case of an ingested foreign body that perforated the esophagus and penetrated the thyroid gland. A neck exploration was required to remove the foreign body.

CASE REPORT

A 26 years old woman presented to the ENT clinic at Aga Khan University Hospital with 3 weeks history of pain in the throat. She gave history of having food at a roadside restaurant 3 weeks back after which this pain started. There were no associated symptoms like dysphagia hoarseness or difficulty in breathing. Past medical history was unremarkable.

The patient was examined in the otolaryngology clinic palpation of the neck did not reveal any abnormality. Findings on routine ENT examination were normal. Fiberoptic laryngoscopy was done which showed normal valleculae, epiglottis, posterior pharyngeal wall, larynx, and vocal folds.

Suspecting a foreign body an x-ray of the lateral neck was ordered which showed a foreign body in soft tissues of the neck (fig1). To further assess the extent of damage and exact location of the foreign body a CT scan was done that showed foreign body penetrating the right lobe of the thyroid gland (fig2).

An exploration of the neck was done on this patient and the foreign body was removed from the thyroid gland. The foreign body was a sharp metallic wire.

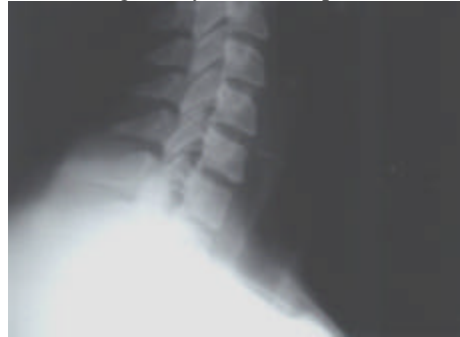

Fig.1: Migrating Foreign Body in the thyroid gland as seen on X-ray

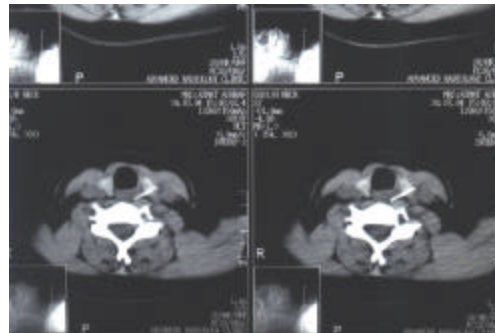


Fig.2: Migrating Foreign Body in thyroid gland as seen on CT scan

DISCUSSION

Foreign bodies penetrating the oesophagus and lying extraluminally in the neck are a rare occurrence. Goh and Tan described a series of four cases where fish bones penetrated the oesophagus and migrated of into the thyroid gland, over a period of 11 years. All of these bones were successfully removed by neck exploration with only one case requiring thyroid lobectomy.²

The majority of foreign bodies ingested become impacted in the tonsils, base of tongue or vallecula and can be easily removed in the clinic. In few cases the foreign body becomes lodged at one of the constrictions along the oesophagus, requiring

removal by rigid oesophagoscopy under general anaesthesia. In even fewer cases, the foreign body penetrates the oesophageal mucosa and “migrates” through it. In some instances, the foreign body can migrate completely through the oesophageal wall and become impacted in the soft tissues of the neck.^{3,4} “Migrating foreign bodies” is the term used for such cases. A migrated foreign body can remain silent or cause serious suppurative or vascular complications.⁵ In Remsen et al’s series⁵, 321 cases of penetrating foreign bodies were reviewed from the literature and only 43 were found extraluminally.

Chee and Sethi reported a series of 24 migrated foreign bodies in the neck.⁶ All of the foreign bodies in their series were sharp and linear.

X rays of lateral neck though useful, do not help determine if migration has occurred. Foreign-body migration is suspected on the basis of suggestive history, a positive finding on lateral neck radiography, and a negative finding on rigid esophagoscopy. A CT scan can then be used to localize the foreign body and estimate the extent of damage done. Main complications of foreign-body migration include retro-pharyngeal abscess, perforation of the esophagus, perforation of the aorta, embedment in the thyroid gland, and migration through the common carotid artery.⁷ Al Muhanna et al described a case in which repeated oesophagoscopy failed to locate any foreign body in a patient with painful dysphagia.⁴ Following which a CT scan was done that showed a fish bone embedded in the right thyroid lobe. Sethi and Stanley described two cases of fish bones penetrating the oesophagus and showed that CT was the investigation of choice for localising the foreign body planning the neck exploration.⁸ Hadi and Ikram reported from Pakistan removal of fish bone after 3 weeks of ingestion.⁹

When such a case presents, management involves exploration of the neck by an external approach to identify the foreign body and remove it.

In practice, this is often a difficult task. The main difficulty is the localization of the foreign body in the soft tissue, after which removal is usually simple. The position of the head and neck at surgery may be different from that when the CT scan was done as the soft tissues of the neck are mobile in relation to the bony and cartilaginous structures. The foreign body at surgery may not be located exactly where it is shown to be in the CT scan.¹⁰

Systematic exploration of the neck via an external approach using the CT scan as a guide will decrease the chances of an unsuccessful exploration. Removal of the foreign body will prevent the occurrence of life threatening complications.

REFERENCES

1. Sreetharan SS, Prepageran N, Satwant S. Unusual migratory foreign body in the neck. *Singapore Med J* 2004; 45(10):487
2. Goh YH, Tan NG. Penetrating oesophageal foreign bodies in the thyroid gland. *J Laryngol Otol* 1999; 113:769-71
3. Jemerin EF, Amoff JS. Foreign body in thyroid following perforation of oesophagus surgery. 1949; 25:52-9
4. Muhanna AA, Abu Chra KA, Dasti H, Behbehani A, Al-Naqeeb N. Thyroid lobectomy for removal of a fish bone. *J Laryngol Otol* 1990; 104:511-2
5. Remsen K, Lawson W, Biller HF, Som ML. Unusual presentations of penetrating foreign bodies of upper GIT. *Ann Otol Rhinol Laryngol Supp* 1983; 105:32-44.
6. Chee LW, Sethi DS. Diagnostic and therapeutic approach to migrating foreign bodies. *Ann Otol Rhinol Laryngol* 1999; 108:177-80
7. Osinubi OA, Osiname AI, Pal A, Lonsdale RJ, Butcher C. Foreign body in throat migrating through the common carotid artery. *Laryngol Otol* 1996; 110:793-5
8. Sethi DS, Stanley RE. Migrating foreign bodies in the upper digestive tract. *Ann Acad med Singapore* 1992 May; 21(3):390-3.
9. Hadi A, Ikram M. Fish Bone in neck. *Pak J Otolaryngology* 1994; 10(4):244-5.
10. Lu PK, Brett RH, Aw CY, Singh R. Migrating Oesophageal Foreign Body - An Unusual Case *Singapore Med J* 2000; 41(2):77-9.

Address For Correspondence:

Dr. Mubasher Ikram, Department of Otolaryngology Head and Neck Surgery, Aga Khan University Hospital Stadium Road, PO Box 3500, Karachi-74800, Pakistan
Phone (92 21) 48594779, 48594770
Email: mubasher.ikram@aku.edu