

Mini-open pedicle subtraction osteotomy as a treatment for severe adult spinal deformities: case series with initial clinical and radiographic outcomes

Michael Y. Wang, MD,¹ and Gerd Bordon, MD²

¹Department of Neurological Surgery, University of Miami Miller School of Medicine, Miami, Florida; and ²Department of Orthopedic Surgery, Hospital Manises, Valencia, Spain

OBJECTIVE Pedicle subtraction osteotomy (PSO) is a powerful but high-risk surgical technique for destabilizing the spine for deformity correction in both the sagittal and coronal planes. Numerous reports have demonstrated the benefits of this technique for realigning the spine in a physiological posture; however, the open surgical technique is associated with a high complication rate. In this report the authors review data obtained in a series of patients who underwent PSO through a less invasive approach.

METHODS Sixteen patients with severe coronal- and/or sagittal-plane deformities were treated in this series. Conservative measures had failed in all cases and patients had undergone a single-level PSO or extended PSO at L-2 or L-3. Fixation was accomplished using percutaneous instrumentation and interbody or facet joint fusions were used at the remaining levels. None of the procedures were aborted or converted to a traditional open procedure. Standard clinical and radiographic measures were used to assess patient outcomes.

RESULTS Mean age was 68.8 years and mean follow-up duration was 17.7 months. An average of 7.6 levels were fused, and 50% of the patients had bilateral iliac screw fixation, with all constructs crossing both the thoracolumbar and lumbosacral junctions. Operative time averaged 356 ± 50 minutes and there was a mean blood loss of 843 ± 339 ml.

The leg visual analog scale score improved from a mean of 5.7 ± 2.7 to one of 1.3 ± 1.6 , and the back visual analog scale score improved from a mean of 8.6 ± 1.3 to one of 2.4 ± 2.1 . The Oswestry Disability Index score improved from a mean of 50.1 ± 14.4 to 16.4 ± 12.7 , representing a mean reduction of 36.0 ± 16.9 points. The SF-36 physical component summary score changed from a mean of 43.4 ± 2.6 to one of 47.0 ± 4.3 , and the SF-36 mental component summary score changed from a mean of 46.7 ± 3.6 to 46.30 ± 3.0 .

Coronal alignment improved from a mean of 27.9 ± 43.6 mm to 16.0 ± 17.2 mm. The lumbar Cobb angle improved from a mean of $41.2^\circ \pm 18.4^\circ$ to $15.4^\circ \pm 9.6^\circ$, and lumbar lordosis improved from $23.1^\circ \pm 15.9^\circ$ to $48.6^\circ \pm 11.7^\circ$. Pelvic tilt improved from a mean of $33.7^\circ \pm 8.6^\circ$ to $24.4^\circ \pm 6.5^\circ$, and the sagittal vertical axis improved from 102.4 ± 73.4 mm to 42.2 ± 39.9 mm. The final lumbar lordosis–pelvic incidence difference averaged $8.4^\circ \pm 12.1^\circ$. There were 4 patients who failed to achieve less than or equal to a 10° mismatch on this parameter. Ten of the 16 patients underwent delayed post-operative CT, and 8 of these had developed a solid arthrodesis at all levels treated. A total of 6 complications occurred in this series. There were no cases of symptomatic proximal junction kyphosis.

CONCLUSIONS Advancements in minimally invasive technique have resulted in the ability to manage increasingly complex deformities with hybrid approaches. In this limited series, the authors describe the results of utilizing a tissue-sparing mini-open PSO to correct severe spinal deformities. This method was technically feasible in all cases with acceptable radiographic outcomes similar to open surgery. However, high complication rates associated with these deformity corrections remain problematic.

<http://thejns.org/doi/abs/10.3171/2015.7.SPINE15188>

KEY WORDS minimally invasive; spinal deformity; interbody fusion; BMP; osteotomy; scoliosis; kyphosis; pedicle screw; percutaneous

ABBREVIATIONS ASD = adult spinal deformity; MCS = mental component summary; MIS = minimally invasive surgical; ODI = Oswestry Disability Index; PCS = physical component summary; PSO = pedicle subtraction osteotomy; QOL = quality of life; SVA = sagittal vertical axis; TLIF = transforaminal lumbar interbody fusion; VAS = visual analog scale.

SUBMITTED February 10, 2015. **ACCEPTED** July 29, 2015.

INCLUDE WHEN CITING Published online January 8, 2016; DOI: 10.3171/2015.7.SPINE15188.

Loss of spinal balance due to a deformity has been associated with significant negative effects on patient-reported quality of life (QOL) measures. The appropriate surgical treatment of these disorders can lead to significant and reliable improvements in a patient's pain, function, and satisfaction. As such, the treatment of adult spinal deformity (ASD) remains a major focus of spinal surgeons, and many contemporary surgical techniques have been developed to treat symptomatic kyphosis and scoliosis. The majority of these rely on some form of anterior column height restoration or osteotomy to improve spinal alignment, particularly if the deformity is severe.^{5,11,14,19,20,25,27} However, these techniques often require multilevel, staged operations and involve trauma to the soft-tissue envelope and significant blood loss. In this aged ASD population of individuals, in whom multiple medical comorbidities are frequent, such surgeries pose challenges associated with high rates of intraoperative and postoperative complications.²³

Over the past decade, various minimally invasive surgical (MIS) techniques have been developed to improve the clinical outcomes of spinal deformity surgery.²² The potential for MIS techniques to reduce the morbidity of these operations has been a major impetus in the search for improved surgical solutions. Indeed, correction of coronal deformities measuring less than 30° with minimal sagittal imbalance has become increasingly popular.^{2,8,12,29} However, the limitations of these MIS methods have been highlighted in several recent publications from the International Spine Study Group (ISSG), which compared various MIS deformity operations performed at US centers with special expertise in this area. In those studies, a ceiling effect of 34° for coronal curve correction was observed unless the dorsal spine was exposed to allow for multilevel osteotomies.¹⁰ Furthermore, significant limitations for enhancing lumbar lordosis and improving sagittal balance have been a major impediment to the utility of MIS ASD correction. These findings were corroborated in a report by Acosta et al.¹

Recognizing that a more powerful MIS method for correcting severe scoliosis and improving sagittal alignment was necessary, we sought to develop a mini-open approach to perform three-column osteotomy. This would allow for correction of more significant deformities but potentially reduce the magnitude of soft-tissue trauma seen with traditional open procedures. This technique was initially explored in a cadaveric model by Voyadzis et al.²⁶ and then extended to clinical application. This report expands upon the initial description of the mini-open pedicle subtraction osteotomy (PSO) in the clinical setting.²⁸

Methods

Patient Population

A consecutive series of 16 patients included in this series underwent surgical treatment over a 33 month period. All patients underwent surgery where the soft-tissue envelope was opened through a subperiosteal dissection primarily at the PSO site. The remainder of the surgery was performed through a minimally invasive approach using MIS transforaminal lumbar interbody fusion (TLIF) and

percutaneous screws. Patients underwent surgery in one of two academic institutions with institutional review board approval.

Clinical Outcome Measures

Surgical data were obtained and analyzed retrospectively with regard to the parameters of operative time, surgical blood loss, units of allogeneic blood transfused, hospital length of stay, and discharge status. Patient-reported outcome measures included visual analog scale (VAS) (leg), VAS (back), SF-36 physical component summary (PCS), SF-36 mental component summary (MCS), and Oswestry Disability Index (ODI) scores obtained preoperatively and postoperatively at last follow-up. All clinical outcome measures were performed by the patients themselves either at home or in the clinic waiting rooms. Complications were identified through a chart review process.

Radiographic Outcome Measures

All patients underwent preoperative CT scanning and 36-inch standing radiography to assess spinal alignment. Cobb angles were measured to establish the degree of scoliosis. This was determined by measuring the maximal coronal angulation between the two most angulated upper vertebral endplates on 36-inch standing radiographs. Global lumbar lordosis was determined by measuring the sagittal angulation between lines drawn parallel to the upper endplates of L-1 and S-1. The sagittal vertical axis (SVA) was measured by dropping a plumb line from the anterior inferior aspect of the C7 vertebra. The minimum distance from this line to the posterior superior endplate of S-1 was the SVA measured in centimeters. Coronal balance was measured on anteroposterior 36-inch standing radiographs and was determined as the offset between a line drawn vertically between the pedicles of S-1 and T-1. Fusion was determined to have occurred if bridging bone had formed at all fused levels either posteriorly or in the interbody space and at the PSO site.

Surgical Technique

After the patient was placed in the prone position, a dorsal midline skin incision allowed access to all levels of interest. This avoided the need for multiple stab incisions, but the skin opening was only taken down to the subcutaneous fat layer so that all subsequent steps were performed through the fascia. A bilateral subperiosteal dissection was then taken laterally at the level of the intended PSO (L-2 or L-3) out laterally to the transverse processes of that level. Any interbody fusion below the level of the PSO was performed through the same incision using a unilateral subperiosteal exposure of the facet joint(s).

The PSO was then performed by removing the entire posterior spinous process, lamina, and facets with a rongeur. The exiting nerve roots surrounding the pedicle to be removed were skeletonized and the right and left pedicles were removed entirely. In certain cases an extended PSO was achieved by incising the cranial intervertebral disc space. A bilateral decancellation osteotomy was then performed using a series of enlarging curettes to remove two cones of cancellous bone from the vertebral body. Cen-

tral bone was removed with a curved curette. Cottonoids were then used to dissect and secure the lateral vertebral wall and its associated vasculature, and this was followed by removal of the posterior vertebral wall and posterior longitudinal ligament. Autologous bone removed during decompression and osteotomy was saved for later grafting purposes.

Control of the spine was then achieved by placing percutaneous pedicle screws at least 3 levels above and below the PSO site. Once screw fixation was achieved, the lateral vertebral body walls were removed using a Leksell rongeur, completing the three-column osteotomy. Four rods were then bent to the appropriate degree of lordotic curvature, and 2 rods were then passed from above, 2 from below (Fig. 1). This allowed the tip of the 4 rods to meet in the open osteotomy site, protruding dorsally out of the wound. Set screws were then fashioned loosely to each screw-rod interface. In this fashion, control of the spine was achieved to allow closure of the osteotomy by manipulating the 4 rod holders (Fig. 2). A rod-to-rod connector was then used to connect the cranial and caudal rods on each side through the open site. All set screws were then final tightened. The nerve roots and thecal sac were then inspected to ensure that there was no neural compression, and any bleeding was controlled with powdered collagen matrix. Fusion above the PSO site was achieved by drilling the facet joints percutaneously and attaching 0.25 mg of recombinant human bone morphogenetic protein-2 (InFuse, Medtronic Sofamor Danek) to the screw saddle so that the osteobiological material sat between the screws and the facet joints.

Mean values are presented \pm SD.

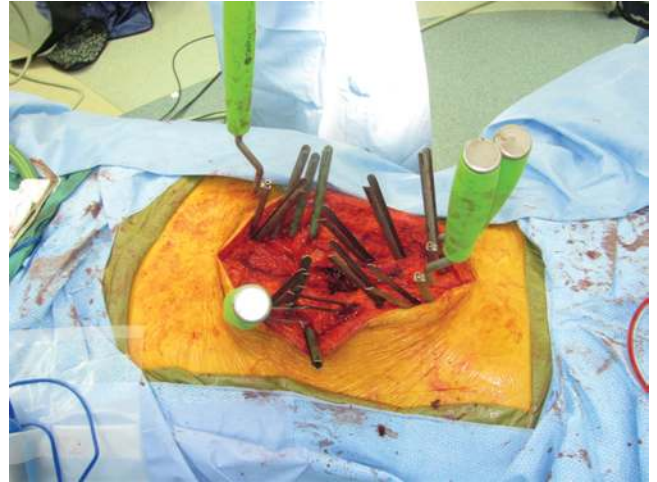


FIG. 2. Intraoperative photograph showing PSO reduction with the four-rod technique.

Results

Patient Demographics, Surgical Procedure, and Acute Hospitalization

Of the 16 patients treated, half were male, and the mean age of the population was 68.8 ± 9.3 years. Follow-up time averaged 17.7 ± 10.5 months (Table 1). The average number of intervertebral disc levels fused was 7.6 ± 1.1 , and 50% had bilateral iliac screw fixation. All constructs extended across the thoracolumbar and lumbosacral junctions. Six of the cases had the PSO performed at L-2, and 10 were

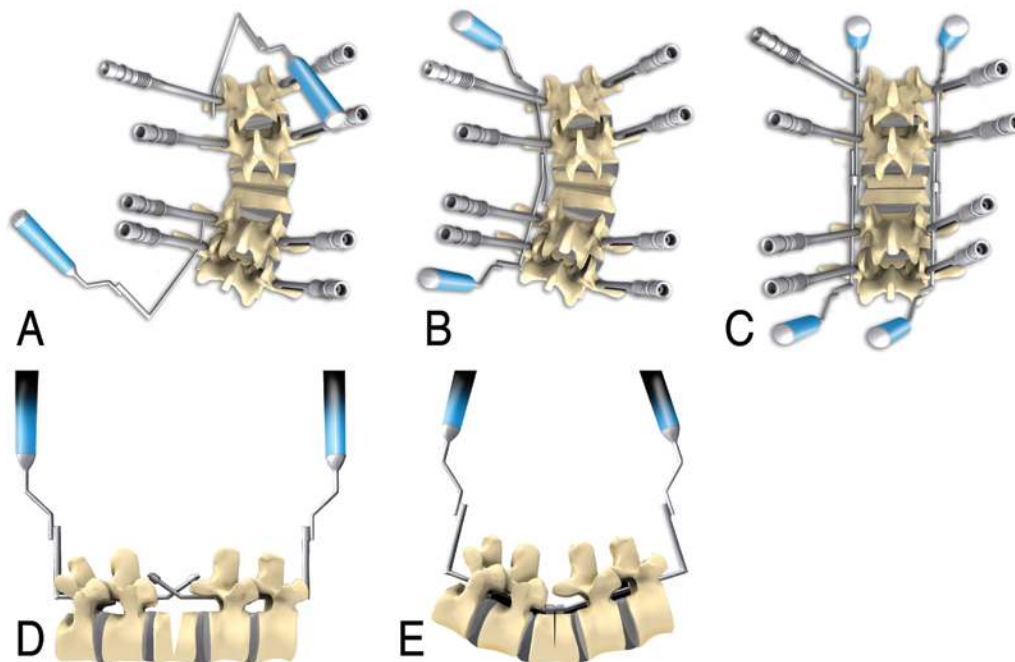


FIG. 1. Artist's depiction of a 4-rod cantilever technique to control the spine as well as close the osteotomy to improve the deformity, as shown in the coronal (A-C) and sagittal (D and E) planes. Copyright Roberto Suazo. Published with permission.

TABLE 1. Demographic and acute care variables*

Variable	Value
No. of patients	16
Male/female ratio	8:8
Mean age (yrs)	68.8 ± 9.3
Mean follow-up (mos)	17.7 ± 10.5
No. of intervertebral levels	7.6 ± 1.1
Iliac fixation	50%
Extension across thoracolumbar junction	100%
Extension across lumbosacral junction	100%
PSO level	
L-2	6
L-3	10
No. of interbody fusion levels	32
Operative time (mins)	356 ± 50
Intraoperative blood loss (ml)	843 ± 339
Length of hospitalization (days)	7.2 ± 2.7
Discharge disposition	
Home	69%
Rehabilitation	32%

* Mean values are presented ± SD.

done at the L-3 level. A total of 32 interbody fusion levels were performed. The operative time from skin incision to final closure averaged 356 ± 50 minutes. Intraoperative blood loss averaged 843 ± 339 ml. Half the patients received an allogeneic blood transfusion during the acute period of their hospitalization, with a mean of 1.2 units of blood given per patient. There were no conversions to fully open operations and no aborted operative attempts. The length of hospitalization averaged 7.2 ± 2.7 days with 69% of patients being discharged to home after surgery. The remaining patients were sent for inpatient rehabilitation.

Clinical Outcomes

Preoperative patient-reported variables were compared with postoperative outcomes established at the last follow-up (Table 2). Leg VAS scores improved from a mean of 5.7 ± 2.7 to one of 1.3 ± 1.6, whereas back VAS scores improved from a mean of 8.6 ± 1.3 to one of 2.4 ± 2.1. The ODI score improved from a mean of 50.1 ± 14.4 to one of 16.4 ± 12.7, representing a mean reduction of 36.0 ± 16.9 points. The SF-36 PCS score changed from a mean of 43.4 ± 2.6 to a score of 47.0 ± 4.3, whereas the SF-36 MCS score changed from a mean of 46.7 ± 3.6 to a score of 46.30 ± 3.0. As a result of neural decompression, spinal stabilization, and deformity correction, the associated functional limitations were improved as expected. Maximal ambulation distance increased from a mean of 116 ± 130 feet to one of 2109 ± 3043 feet, reflecting a mean 1992 ± 2965 improvement. There were no patients for whom ambulatory function worsened.

Radiographic Outcomes

Preoperative radiographic measures were compared

TABLE 2. Clinical and radiographic outcome measures*

Measure	Preoperative	Postoperative
Leg VAS score	5.7 ± 2.7	1.3 ± 1.6
Back VAS score	8.6 ± 1.3	2.4 ± 2.1
ODI score	50.1 ± 14.4	16.4 ± 12.7
SF-36 PCS score	43.4 ± 2.6	47.0 ± 4.3
SF-36 MCS score	46.7 ± 3.6	46.30 ± 3.0
Maximal ambulation distance (ft)	116 ± 130	2109 ± 3043
Coronal alignment (mm)	27.9 ± 43.6	16.0 ± 17.2
Lumbar Cobb angle (°)	41.2 ± 18.4	15.4 ± 9.6
Lumbar lordosis (°)	23.1 ± 5.9	48.6 ± 11.7
Pelvic tilt (°)	33.7 ± 8.6	24.4 ± 6.5
SVA (mm)	102.4 ± 73.4	42.2 ± 39.9

* Values are presented as the mean ± SD.

with postoperative measures at last follow-up. Coronal alignment improved from a mean of 27.9 ± 43.6 mm to one of 16.0 ± 17.2 mm, representing an improvement of 29.3 ± 29.2 mm (Figs. 3 and 4). The lumbar Cobb angle improved from a mean of 41.2° ± 18.4° to one of 15.4° ± 9.6°, representing an improvement of 25.9° ± 12.0°. The maximal preoperative Cobb angle of 75° improved to 30°.

The lumbar lordosis improved from a mean of 23.1° ± 15.9° to one of 48.6° ± 11.7°, representing an improvement of 25.4° ± 8.4°. The maximal amount of total lordosis added was 44°. Pelvic tilt improved from a mean of 33.7° ± 8.6° to one of 24.4° ± 6.5°, representing an improvement of 9.3° ± 8.4°. The SVA improved from a mean of 102.4 ± 73.4 mm to a mean of 42.2 ± 39.9 mm, representing an improvement of 60 ± 44.6 mm. In 3 patients, a final SVA of less than 60 mm was not achieved. When the final lumbar lordosis was subtracted from the pelvic incidence, the mean result was 8.4° ± 12.1°. There were 4 patients who failed to achieve less than or equal to a 10° mismatch on this parameter.

Fusion rates were assessed based on postoperative CT scans. Of the 16 patients, 10 had undergone postoperative CT scanning and a solid arthrodesis at all levels treated had developed in 8 of these patients; CT scans were not obtained in all patients because those with no clinical or radiographic evidence of pseudarthrosis and refusing 3D imaging due to radiation dose concerns were not re-scanned. CT scans were obtained at 1 year after surgery. There were no cases of symptomatic proximal junction kyphosis.

Complications

Complications in this series are shown in Table 3. Intraoperative complications included one unintentional durotomy. Postoperative complications included one wound infection and one watershed stroke that developed due to preexisting but undiagnosed bilateral carotid artery stenosis (degree of stenosis 99%). Implant and hardware complications included one iliac screw-rod dislodgment and one interbody graft extrusion, both of which were corrected by a return to the operating room within the first 3 months after surgery. In one patient, rod fractures developed at the

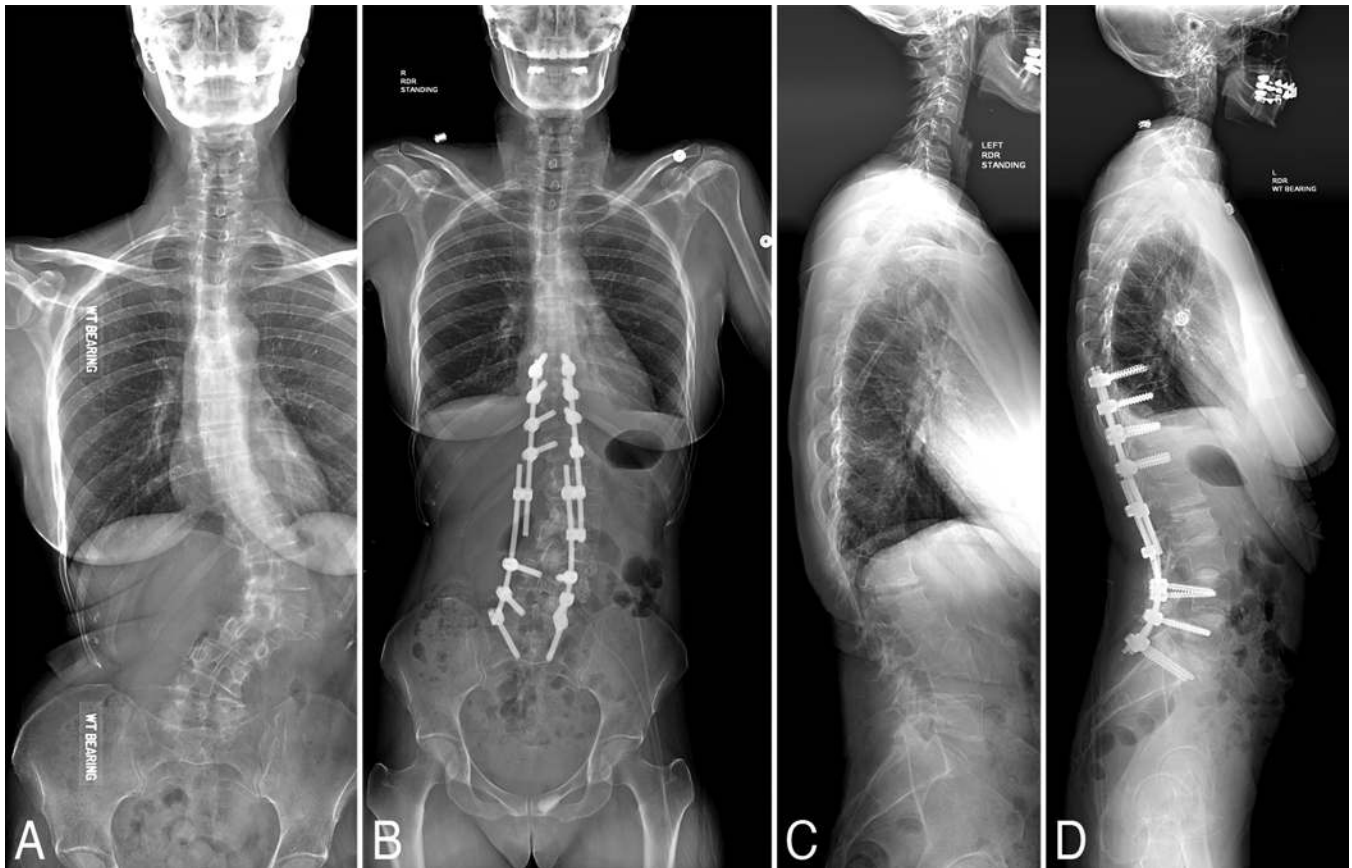


FIG. 3. Illustrative case showing anteroposterior (A and B) and lateral (C and D) 36-inch standing radiographs before and after the mini-open PSO was performed for deformity correction.

PSO site 12 months after surgery (Fig. 4). There were no deaths or cases of paralysis.

Discussion

The search for a less morbid method for surgically correcting kyphoscoliosis has remained elusive despite the development of numerous MIS procedures. To date, few MIS publications have reported or focused on the patient's sagittal balance, a metric that may be the most reliable predictor of surgical success as determined by QOL measures.^{6,13,15,21} A recent meta-analysis by Costanzo et al. reviewed lateral interbody MIS fusion results as reported in 14 peer-reviewed papers.⁷ The study encompassed a total of 1266 levels in 476 patients and found that obtaining additional lordosis of greater than 10° or improvements in SVA of more than 5 cm was difficult to achieve.

The development of anterior column release techniques has led to improvement in these two factors; Manwaring et al. reported on their first 9 cases managed with this technique, indicating that lumbar lordosis improved by 16.5° and the SVA was on average reduced by 4.8 cm.¹⁸ However, the rate of complications associated with this approach has not been fully evaluated and is likely to be high given the proximity of large retroperitoneal vessels that may not be adequately visualized or controlled.^{4,16} Furthermore, this technique is technically challenging and may not be

easily learned or applied. Currently, lateral approaches are used very effectively for coronal realignment,³ but sagittal realignment has remained challenging. Thus, many series of "MIS" approaches involve open posterior exposures that include open multilevel osteotomies.²⁴

In the current report we describe our initial experience with a mini-open PSO technique. This method was originally described in 2012 as an attempt to minimize the high morbidity rate seen with open PSO surgeries.²⁸ While the procedure requires opening the PSO site, this opening is roughly what is needed for a two-level posterior instrumented fusion. Opening this area accomplishes 4 very important goals: 1) it allows for efficient decompression of neural elements at a level that is frequently stenotic; 2) it allows for the application of well-accepted and widely used standard PSO methods used in open surgery; 3) it allows for direct visualization of the thecal sac during osteotomy closure, which is a potential source of catastrophic complications with PSO surgery; and 4) it allows for connection of the 4 rods passed from above and below the surgery site.

The 4-rod technique is borrowed from traditional open ASD surgery and is known as a rod-cantilever technique. This approach allows for creation of a lordotic construct passed subfascially through a kyphotic spinal column, which is a major challenge in MIS procedures. These 4 rods allow for control of the spine during osteotomy clo-

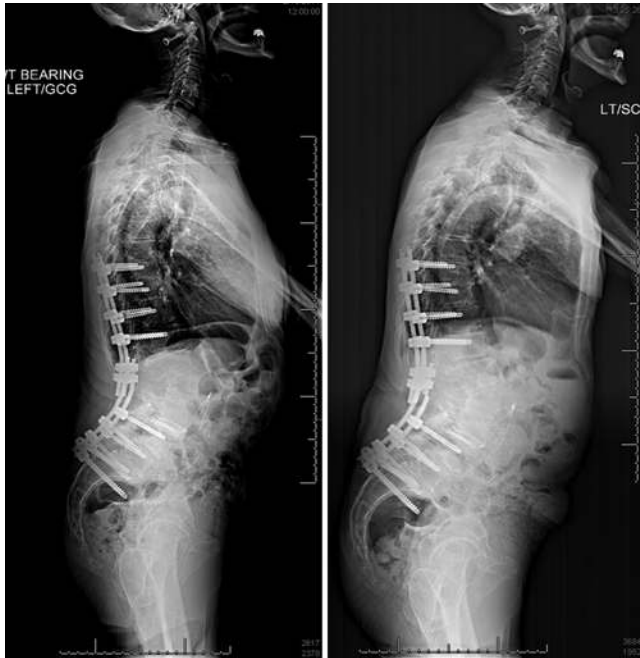

FIG. 4. Illustrative case showing rod fracture following mini-open PSO due to a nonunion at the osteotomy level: before rod fracture (**left**) and after fracture (**right**).

sure, which is challenging in the absence of a complete opening of the soft-tissue envelope. A final benefit of the rod-cantilever method is that it helps reduce hardware pullout during the deformity reduction by separating the spine into two biomechanically discrete units (cranial and caudal constructs). Thus, all 6–8 screws in the upper part of the construct work in unison rather than independently.

Using these methods, we were able to achieve a mean improvement of the lumbar Cobb angle of $25.9^\circ \pm 12.0^\circ$. Lumbar lordosis was improved from by a mean of $25.4^\circ \pm 8.4^\circ$, and the maximal amount of total lordosis added was 44° . This was accompanied by a mean SVA reduction of 60 ± 44.6 mm. With these changes in spinal alignment, we saw the expected changes in patient QOL and function one expects with standard, open deformity surgery. In this study, the ODI was reduced an average of 36 points, well above the minimal clinically important difference threshold.

All surgeries were conducted in a single setting on 1 day, which is important given the recent trend for MIS ASD surgery to be performed over multiple days with different anesthetic administrations and multiple approaches. While the advantages of limiting the scope of any single surgical event are obvious, comparisons to open surgery require that MIS procedures be comparable in terms of cost and scope.

Complications

As with any new technique, a critical scientific appraisal of its drawbacks is vital to allow for sustainable advancements. Since this technique involves a PSO, all of the attendant risks and complications of that component of the technique are to be expected in both MIS and open

TABLE 3. Complications

Complication	No.
Conversion to open surgery	0
Wound infection	1
Unintentional durotomy	1
Nerve root injury	0
Pneumonia	0
Deep vein thrombosis	0
Pulmonary embolism	0
Urinary tract infection	0
Rod-screw dislodgment	1
Rod fracture	1
Interbody cage displacement	1
Proximal junctional kyphosis	0
Renal failure	0
Myocardial infarction	0
Paralysis	0
Stroke	1
Blindness	0
Death	0

versions of the surgery. This is evidenced by the significant average blood loss of 843 ml. While advancements in surgical hemostasis would offer the opportunity for reductions in blood loss, we would not expect the blood loss from the osteotomy to be any less than that seen in an open surgery.

Similarly, one would expect to see hardware failures in this series. Due to the destabilizing effects of a three-column osteotomy, a nonunion at the PSO site, combined with the acute rod bends necessary, lends a high rate of rod fracture to the construct.¹⁷ In a recent series by Lenke’s group, the rate of pseudarthrosis with rod fracture could be expected to be as high as 10%.⁹ The reports on open ASD surgery underscore the need for long-term outcome studies in the range of 5 to 10 years so that the full effects and long-term outcome of these complex procedures can be fully and adequately assessed.³⁰

Limitations of This Study

This study has numerous limitations. The short-term follow-up does not adequately capture the true rates of pseudarthrosis and hardware failure that can only be detected with long-term monitoring of these patients. Follow-up CT scanning is not performed in all patients and currently serves as the gold standard for identifying non-unions in the absence of clinical symptoms. The application of the mini-PSO also relies heavily on off-label use of cages and osteobiologics to promote a successful fusion.

With regard to meeting the spinal deformity correction, this series demonstrates a significant improvement over previous techniques. However, in 3 of our patients a final SVA of less than 60 mm was not achieved, and in 4 patients mismatch remained between lumbar lordosis and pelvic incidence by more than 10°. The mean final pelvic tilt was 24.4°, and 8 patients fell short of a final pelvic

tilt of less than 25°. The inability to add posterior column osteotomies due to the limited opening of the soft-tissue envelope is likely responsible for these effects, as currently there is no method for performing posterior column osteotomies in an efficient MIS manner. While the clinical outcome measures in these patients demonstrated significant improvements, this was in part due to the severity of their preoperative disability. It is likely that closer approximation to the ideal sacral-pelvic parameters would have resulted in even better clinical outcomes.

Conclusions

Ultimately, the feasibility of this mini-open PSO technique will need to be validated with large clinical series at multiple institutions and with longer follow-up periods, preferably over 5 years. Given the propensity for delayed hardware pullout, rod breakage, pseudarthrosis, and proximal junctional kyphosis, this technique must be fully validated before widespread acceptance can be expected. However, by respecting traditional deformity principles, we were able to achieve excellent deformity correction in two planes without the extensive soft-tissue envelope disruption seen in the open procedures.

References

- Acosta FL, Liu J, Slimack N, Moller D, Fessler R, Koski T: Changes in coronal and sagittal plane alignment following minimally invasive direct lateral interbody fusion for the treatment of degenerative lumbar disease in adults: a radiographic study. **J Neurosurg Spine** 15:92–96, 2011
- Anand N, Rosemann R, Khalsa B, Baron EM: Mid-term to long-term clinical and functional outcomes of minimally invasive correction and fusion for adults with scoliosis. **Neurosurg Focus** 28(3):E6, 2010
- Arnold PM, Anderson KK, McGuire RA Jr: The lateral transposas approach to the lumbar and thoracic spine: A review. **Surg Neurol Int** 3 (Suppl 3):S198–S215, 2012
- Assina R, Majmundar NJ, Herschman Y, Heary RF: First report of major vascular injury due to lateral transposas approach leading to fatality. **J Neurosurg Spine** 21:794–798, 2014
- Bridwell KH, Lewis SJ, Lenke LG, Baldus C, Blanke K: Pedicle subtraction osteotomy for the treatment of fixed sagittal imbalance. **J Bone Joint Surg Am** 85-A:454–463, 2003
- Clark AJ, Garcia RM, Keefe MK, Koski TR, Rosner MK, Smith JS, et al: Results of the AANS membership survey of adult spinal deformity knowledge: impact of training, practice experience, and assessment of potential areas for improved education: Clinical article. **J Neurosurg Spine** 21:640–647, 2014
- Costanzo G, Zoccali C, Maykowski P, Walter CM, Skoch J, Baaj AA: The role of minimally invasive lateral lumbar interbody fusion in sagittal balance correction and spinal deformity. **Eur Spine J** 23 (Suppl 6):699–704, 2014
- Dakwar E, Cardona RF, Smith DA, Uribe JS: Early outcomes and safety of the minimally invasive, lateral retroperitoneal transposas approach for adult degenerative scoliosis. **Neurosurg Focus** 28(3):E8, 2010
- Dickson DD, Lenke LG, Bridwell KH, Koester LA: Risk factors for and assessment of symptomatic pseudarthrosis after lumbar pedicle subtraction osteotomy in adult spinal deformity. **Spine (Phila Pa 1976)** 39:1190–1195, 2014
- Haque RM, Mundis GM Jr, Ahmed Y, El Ahmadih TY, Wang MY, Mummaneni PV, et al: Comparison of radiographic results after minimally invasive, hybrid, and open surgery for adult spinal deformity: a multicenter study of 184 patients. **Neurosurg Focus** 36(5):E13, 2014
- Heary RF, Bono CM: Pedicle subtraction osteotomy in the treatment of chronic, posttraumatic kyphotic deformity. **J Neurosurg Spine** 5:1–8, 2006
- Hsieh PC, Koski TR, Sciubba DM, Moller DJ, O'Shaughnessy BA, Li KW, et al: Maximizing the potential of minimally invasive spine surgery in complex spinal disorders. **Neurosurg Focus** 25(2):E19, 2008
- Johnson RD, Valore A, Villaminar A, Comisso M, Balsano M: Pelvic parameters of sagittal balance in extreme lateral interbody fusion for degenerative lumbar disc disease. **J Clin Neurosci** 20:576–581, 2013
- Kim YJ, Bridwell KH, Lenke LG, Cheh G, Baldus C: Results of lumbar pedicle subtraction osteotomies for fixed sagittal imbalance: a minimum 5-year follow-up study. **Spine (Phila Pa 1976)** 32:2189–2197, 2007
- Le Huec JC, Faundez A, Dominguez D, Hoffmeyer P, Aunoble S: Evidence showing the relationship between sagittal balance and clinical outcomes in surgical treatment of degenerative spinal diseases: a literature review. **Int Orthop** 39:87–95, 2015
- Lenke LG: Editorial. Sagittal balance. **J Neurosurg Spine** 20:512–514, 2014
- Luca A, Lovi A, Galbusera F, Brayda-Bruno M: Revision surgery after PSO failure with rod breakage: a comparison of different techniques. **Eur Spine J** 23 (Suppl 6):610–615, 2014
- Manwaring JC, Bach K, Ahmadian AA, Deukmedjian AR, Smith DA, Uribe JS: Management of sagittal balance in adult spinal deformity with minimally invasive anterolateral lumbar interbody fusion: a preliminary radiographic study. **J Neurosurg Spine** 20:515–522, 2014
- Mummaneni PV, Dhall SS, Ondra SL, Mummaneni VP, Berven S: Pedicle subtraction osteotomy. **Neurosurgery** 63 (3 Suppl):171–176, 2008
- Ondra SL, Marzouk S, Koski T, Silva F, Salehi S: Mathematical calculation of pedicle subtraction osteotomy size to allow precision correction of fixed sagittal deformity. **Spine (Phila Pa 1976)** 31:E973–E979, 2006
- Scheer JK, Lafage V, Smith JS, Deviren V, Hostin R, McCarthy IM, et al: Impact of age on the likelihood of reaching a minimum clinically important difference in 374 three-column spinal osteotomies: clinical article. **J Neurosurg Spine** 20:306–312, 2014
- Schwender JD, Holly LT, Rouben DP, Foley KT: Minimally invasive transforaminal lumbar interbody fusion (TLIF): technical feasibility and initial results. **J Spinal Disord Tech** 18 (Suppl):S1–S6, 2005
- Smith JS, Shaffrey CI, Glassman SD, Berven SH, Schwab FJ, Hamill CL, et al: Risk-benefit assessment of surgery for adult scoliosis: an analysis based on patient age. **Spine (Phila Pa 1976)** 36:817–824, 2011
- Tormenti MJ, Maserati MB, Bonfield CM, Okonkwo DO, Kanter AS: Complications and radiographic correction in adult scoliosis following combined transposas extreme lateral interbody fusion and posterior pedicle screw instrumentation. **Neurosurg Focus** 28(3):E7, 2010
- van Loon PJ, van Stralen G, van Loon CJ, van Susante JL: A pedicle subtraction osteotomy as an adjunctive tool in the surgical treatment of a rigid thoracolumbar hyperkyphosis: a preliminary report. **Spine J** 6:195–200, 2006
- Voyadzis J, Gala V, O'Toole J, Eichholz K, Fessler R: Minimally invasive posterior osteotomies. **Neurosurgery** 63:A204–A210, 2008
- Wang MY, Berven SH: Lumbar pedicle subtraction osteotomy. **Neurosurgery** 60:ONS140–ONS146, 2007
- Wang MY, Madhavan K: Mini-open pedicle subtraction

- osteotomy: surgical technique. **World Neurosurg** **81**:843.e11–843.e14, 2014
29. Wang MY, Mummaneni PV: Minimally invasive surgery for thoracolumbar spinal deformity: initial clinical experience with clinical and radiographic outcomes. **Neurosurg Focus** **28(3)**:E9, 2010
 30. Yadla S, Maltenfort MG, Ratliff JK, Harrop JS: Adult scoliosis surgery outcomes: a systematic review. **Neurosurg Focus** **28(3)**:E3, 2010
-

Disclosures

Dr. Wang serves as a consultant for and receives royalty pay-

ments from DePuy-Synthes Spine, Inc., is a consultant for Aesculap Spine, owns stock in Spincity, and has received grants from the Department of Defense. Dr. Bordon is a consultant for DePuy and Medtronic.

Author Contributions

Conception and design: Wang. Acquisition of data: Wang. Drafting the article: Wang. Critically revising the article: both authors.

Correspondence

Michael Y. Wang, Department of Neurological Surgery, Lois Pope Life Center, 1095 NW 14th Terrace, Miami, FL 33136. email: mwang2@med.miami.edu.