



## Minimally Invasive Video-assisted Thyroidectomy: Multiinstitutional Experience

Paolo Miccoli, M.D.,<sup>1</sup> Rocco Bellantone, M.D.,<sup>2</sup> Michel Mourad, M.D.,<sup>3</sup> Martin Walz, M.D.,<sup>4</sup>  
Marco Raffaelli, M.D.,<sup>1</sup> Piero Berti, M.D.<sup>1</sup>

<sup>1</sup>Dipartimento di Chirurgia, Università degli Studi di Pisa, Via Roma 67, 56100 Pisa, Italy

<sup>2</sup>Unità di Endocrinochirurgia, Università Cattolica di Roma, Via della Pineta Sacchetti, Rome, Italy

<sup>3</sup>Services Transplantation Renale et Chirurgie Endocrinienne Cliniques, Universitaires Saint Luc, Avenue Hippocrate 10, 1200 Bruxelles, Belgium

<sup>4</sup>Center for Minimal Invasive Surgery, Kliniken Essen, Henricistrasse Mitte 92, 45136 Essen, Germany

Published Online: May 21, 2002

**Abstract.** Minimally invasive video-assisted thyroidectomy (MIVAT) was described in 1998. In this study we collected the experience of four third-level referral centers that adopted this technique. A total of 336 patients (279 females, 57 males) were selected for MIVAT. Selection criteria were thyroid volume < 15 ml, nodules not exceeding 3.5 cm of diameter, and an absence of thyroiditis, previous neck surgery, or previous irradiation. The procedure, totally gasless, is carried out through a 15 mm central incision above the sternal notch. Dissection is performed under endoscopic vision using conventional and endoscopic instruments. The mean operating time was  $69.4 \pm 30.6$  minutes for lobectomy (range 20–150 minutes) and  $87.4 \pm 43.5$  minutes for total thyroidectomy (range 30–220 minutes). The mean postoperative stay was  $1.9 \pm 0.8$  days. Postoperative complications were 7 transient and 1 definitive recurrent nerve palsies and 11 cases of hypoparathyroidism (9 transient, 2 definitive). Conversion to open surgery was necessary in 15 patients (4.5%). This study confirms in a large number of cases the safety and feasibility of MIVAT, even in different surgical settings where similar results were achieved. The complication rate was not different from that of standard thyroidectomy. Although the operating time appears longer than with conventional procedures, the learning curve demonstrates a sharp decrease with increasing experience and the introduction of new technologies. The number of patients eligible for this approach remains low, thereby limiting its use, but it should be considered a valid option in selected surgical centers, offering some advantages to patients in terms of cosmetic results and postoperative distress.

Albeit minimally invasive thyroid surgery is becoming one of the possible options for the treatment of small thyroid nodules [1–5], its use is not widespread as yet. Indeed, great skepticism remains about its real advantages, particularly when comparing it with conventional neck surgery, which has become an excellent standard in this field. One of the reasons for the caution about endoscopic thyroid surgery is probably the lack of large series of patients operated on using a single, well standardized technique; this situation always makes it difficult to have an effective com-

parison between traditional surgery and any innovative procedure. Furthermore, the procedures are generally too long and technically demanding to be adopted on a large scale. The minimally invasive approach we adopted, though, has some important advantages in terms of duration and simplicity, which renders it competitive even in comparison with conventional thyroidectomy [6].

This paper reports on a representative number of consecutive patients operated on through a single well defined operation performed in four third-level referral surgical centers with recognized experience in endocrine surgery. An overall evaluation of this operation thus can be given through an analysis of the results obtained in a series of more than 300 patients.

### Materials and Methods

The centers that took part in the study were the Department of Surgery, University of Pisa, Italy (P.M.); Unit of Endocrine Surgery, Catholic University of Rome, Italy (R.B.); Services Transplantation Rénale et Chirurgie Endocrinienne Cliniques, Universitaires Saint Luc, Brussels, Belgium (M.M.); and Center for Minimally Invasive Surgery, Essen Hospital, Germany (M.W.).

### Patients

Between January 1999 and June 2001 a total of 336 consecutive consenting patients were referred to these surgical centers for thyroid nodular disease and were selected to undergo a minimally invasive video-assisted procedure on the basis of the following criteria:

1. Presence of a nodule not exceeding 3.5 cm in maximum diameter
2. Total thyroid volume < 15 ml, echographically determined
3. Absence of thyroiditis diagnosed by biochemical or echographic signs

This International Association of Endocrine Surgeons (IAES) article was presented at the 39th World Congress of Surgery International Surgical Week (ISW01), Brussels, Belgium, August 26–30, 2001.

Correspondence to: P. Miccoli, M.D.

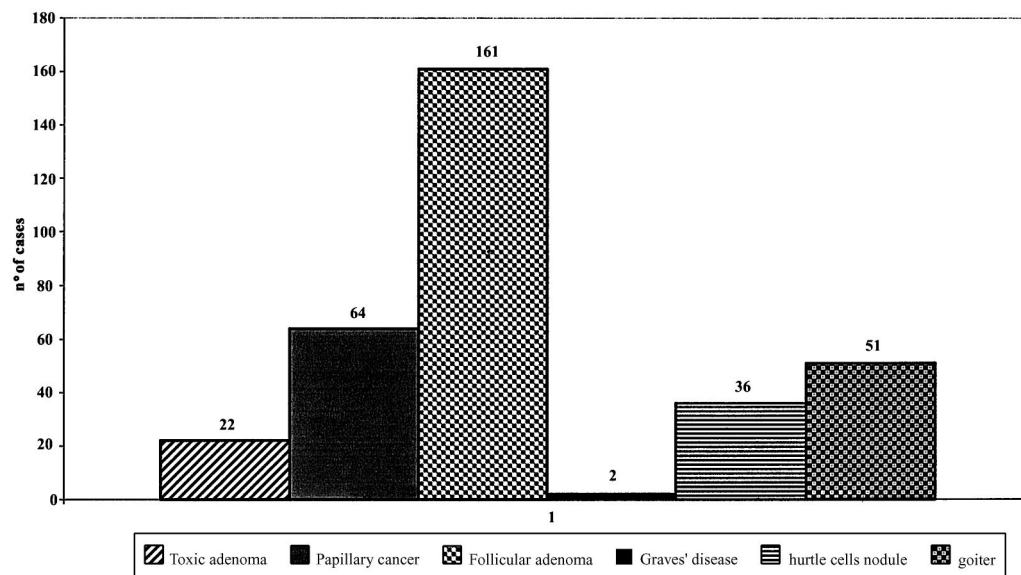


Fig. 1. Preoperative diagnosis.

4. Cytologic and clinical evidence of benign disease, follicular tumor, or “low risk” papillary carcinoma [7]
5. Absence of echographically enlarged lymph nodes in the neck

There were 279 females and 57 males with a mean age of  $42.1 \pm 12.7$  years (range 10–77 years). The preoperative diagnosis was follicular nodule in 161 cases, low risk papillary carcinoma in 64, toxic adenoma in 22, nodular goiter in 51, Graves’ disease in 2, and Hürthle cell nodule in 36 (Fig. 1).

*Surgical Procedure*

Minimally invasive video-assisted thyroidectomy (MIVAT) has been described elsewhere [4]. Briefly, it is characterized by a single access of 1.5 cm in the middle area of the neck a couple of centimeters above the sternal notch; the thyroid space is reached through the midline only by blunt dissection using no gas. The procedure is then performed endoscopically using a 30-degree endoscope 5 mm in diameter and external retraction. Once the superior laryngeal nerve is visualized, the upper pedicle and other vascular minor connections are ligated and the upper parathyroid carefully prepared. The recurrent nerve is then traced along its course, and the lobe is completely freed. At this point it can be extracted by gently pulling it out through the skin incision. The isthmus is then dissected from the trachea and divided, as during conventional surgery. After checking the recurrent laryngeal nerve once again, the lobe is finally removed and the incision closed by means of a simple skin sealant using no drainage. All operations were performed by a single surgeon in each center.

**Results**

Total thyroidectomy was performed in 112 patients, and 224 patients underwent hemithyroidectomy (right lobe in 111, left lobe in 113). The mean operating time was  $69.4 \pm 30.6$  minutes for lobectomy (range 20–150 minutes) and  $87.4 \pm 43.5$  minutes for total thyroidectomy (range 30–220 minutes).

**Table 1.** MIVAT operative complications.

| Complication                 | No.       |
|------------------------------|-----------|
| Hemorrhage                   | 3 (0.9%)  |
| Wound sepsis                 | 1 (0.3%)  |
| Recurrent nerve palsy        |           |
| Transient                    | 7 (2.1%)  |
| Permanent                    | 1 (0.3%)  |
| Transient hypocalcemia       | 9 (2.67%) |
| Permanent hypoparathyroidism | 2 (0.6%)  |

MIVAT: minimally invasive video-assisted thyroidectomy.

**Table 2.** MIVAT: reasons for conversion.

| Reason for conversion    | No.       |
|--------------------------|-----------|
| Hemorrhage               | 2 (0.6%)  |
| Difficult dissection     | 10 (2.9%) |
| Completion thyroidectomy | 2 (0.6%)  |
| Esophageal infiltration  | 1 (0.3%)  |

Operative complications (Table 1) were recurrent nerve palsy in eight cases (2.1%). One patient had a permanent lesion (0.3%), and in seven the lesion was transient, lasting less than 1 month in all cases. Eleven patients exhibited hypoparathyroidism, which corresponds to 9.8% of the 112 total thyroidectomies performed; Only two had permanent hypocalcemia that necessitated substitution therapy, thus reducing the rate of permanent hypoparathyroidism to only 1.8%. Three patients experienced hemorrhage, which required conversion in only one case (bleeding from the upper pedicle too hazardous to manage via the endoscopic procedure). The hemorrhage resolved into a postoperative hematoma in two cases, where only conservative therapy was necessary. Wound sepsis occurred in one case.

The conversion rate was 4.5%. The reasons for conversion to open surgery are summarized in Table 2. In most cases it was due to difficulty during the lobe dissection that made identification of the most important structures, such as the recurrent nerve, un-

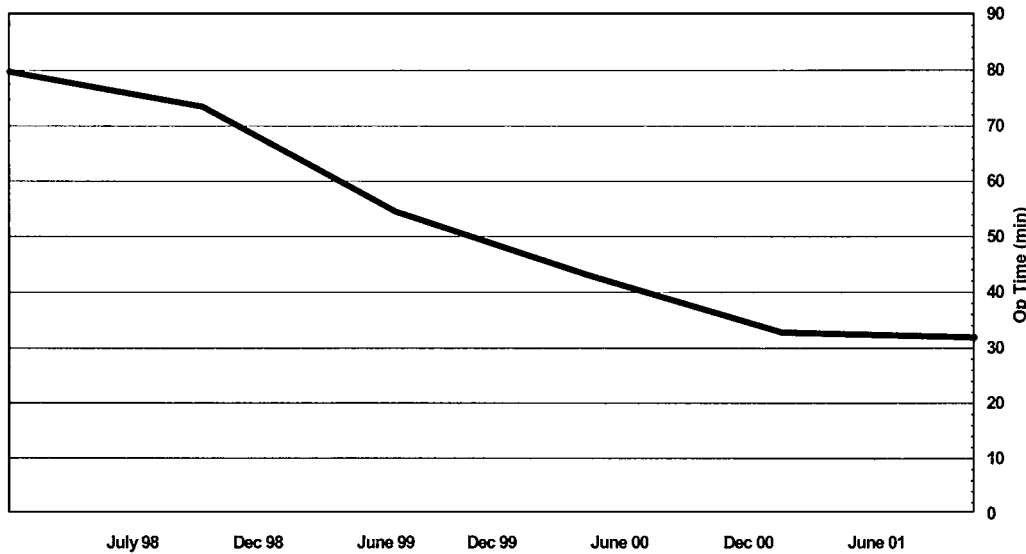


Fig. 2. Learning curve for video-assisted lobectomy. Op: operating.

certain. The mean hospital stay was  $1.9 \pm 0.8$  days after the operation (range 1–5 days).

Postoperative histology confirmed the preoperative diagnosis in all cases of papillary carcinoma, Graves' disease, toxic adenoma, and benign goiter. Follicular nodules proved to be benign in most of the patients. In 27 cases (16.7%) a malignant neoplasm was present, making a completion total thyroidectomy necessary. In 20 patients it was performed during the same operation because it was revealed by frozen section analysis; in 7 cases it was carried out 1 to 3 weeks later through the same access.

## Discussion

The large number of cases recruited for MIVAT during a relatively short period of time (30 months) is proof that, even following strict inclusion criteria such as the ones indicated in this protocol, this surgery is not a matter of sporadic reports but can be proposed to a selected but relevant group of patients. This is true also in endemic goiter countries where chiefly large thyroids are expected to undergo surgical operation.

Even though the feasibility of this procedure had already been demonstrated [4], its safety was yet to be confirmed, particularly when performed in several surgical settings. The complication rate is not different from that of conventional surgery [8] (Table 2), and it proved to be the same even when considering the surgical groups separately. In particular, recurrent nerve palsy has an overall incidence of 2.7%, which is not dramatically high assuming that malignancies are well represented in this series and that transient forms are prevalent and short-lasting; furthermore, no single group showed an overall incidence of this lesion that was higher than 3%. It could be argued that the peculiar selection of the patients for operation led to a significant number of small thyroids undergoing surgery in this series; but even assuming that this constitutes a bias, a unique case of permanent recurrent nerve palsy among 91 carcinomas operated on is still low. The incidence of transient hypoparathyroidism, in contrast, proved to be slightly higher than with conventional surgery; on the other hand, the incidence of permanent hypoparathyroidism seems to be low, only 1.8%.

The incidence of malignancy among the follicular nodules population is low, but this is not surprising considering that the prevalence of small follicular tumors, which are less prone to exhibit follicular carcinoma according to the current literature [9]. Some concern could be expressed about the radicality of this minimally invasive procedure because "low risk" papillary carcinoma accounts for almost 20% of all the cases. We had already evaluated whole body scans (WBS) and serum thyroglobulin (sTg) dosage in these patients in a previous series [4]. The results were comparable to those of traditional surgery in terms of  $^{131}\text{I}$  uptake and sTg levels, thus demonstrating that satisfying radicality can be achieved from this kind of carcinoma.

The operating time remains longer than for standard thyroidectomy. This difference arose also in two prospective comparative studies, where it proved to be statistically significant [6, 10]. This is particularly evident during the early phase of the learning curve, although it shows a constant decrease (Fig. 2). New technologies, such as the 5 mm scissor grip handle connected to the Harmonic Scalpel (Ethicon Endosurgery, Cincinnati, OH, USA), play an important role in reducing the operation's length [4]. The impact of this particular scalpel could not be evaluated statistically in this study because it has not yet been adopted in all the surgical settings. When considering the last 100 operations, however, the mean duration of the procedure was 40 minutes, which rivals that of standard lobectomy.

What should also be demonstrated is that the procedure has some advantages with respect to conventional surgery because of its feasibility and safety, although this does not necessarily mean that it has to be adopted. These advantages are not easy to demonstrate, as they are mainly subjective, such as the patients' satisfaction with their scars and postoperative distress. There is only one prospective study in the literature showing a statistically significant better outcome for minimally invasive thyroidectomy in terms of both cosmetic result and postoperative pain, but it is based on a small number of cases [6]. The present series was not a prospective study and consequently cannot confirm the statistical conclusions of the other studies. However, it seems easy to accept the conclusion that a 1.5 cm scar is better than a 6.0 cm

scar. There are no differences in the hospital stay (1.9 days), which is minimal also for conventional surgery.

## Conclusions

We reaffirmed that MIVAT, performed on a large scale in different surgical settings, proved to be a safe procedure. It can be considered a valid option because of its cosmetic advantages, which are particularly appreciated by young patients (the mean age in the present sample was around 40 years).

**Résumé.** La thyroïdectomie mini-invasive vidéo-assistée (TIMIVA) a été décrite en 1998. Dans cette étude, nous avons colligé l'expérience de quatre centres de soins «tertiaires» qui ont adopté cette technique. 336 patients (279 femmes et 57 hommes) ont été sélectionnés pour la TMIVA. Les critères de sélection ont été le volume de la thyroïde < 15 ml, les nodules inférieurs à 3.5 cm de diamètre, absence de thyroïdite, d'antécédent de chirurgie cervicale ou d'irradiation. Le procédé, entièrement sans l'utilisation du pneumopéritoine, est mené par une incision de 15-mm juste au-dessus du manubrium sternal. La dissection est menée sous vision laparoscopique, à l'aide des instruments conventionnels et laparoscopiques. La durée opératoire moyenne a été de  $69.4 \pm 30.6$  minutes pour la lobectomie (extrêmes: 20–150) et de  $87.4 \pm 43.5$  minutes pour la thyroïdectomie totale (extrêmes: 30–220). La durée moyenne de séjour a été de  $1.9 \pm 0.8$  jours. Parmi les complications postopératoires on a noté huit cas de paralysie récurrentielle transitoire ( $n = 7$ ) ou définitive ( $n = 1$ ) et 11 cas d'hypoparathyroïdie (9 transitoires et 2 définitives). La conversion à la chirurgie traditionnelle a été nécessaire chez 15 patients (94.5%). Cette étude a confirmé la sûreté et la faisabilité de la TMIVA sur un nombre important de cas, avec des résultats similaires quelles que soient les conditions chirurgicales. Le taux de complications ne diffère pas de celui de la thyroïdectomie standard. Bien que la durée opératoire puisse apparaître plus longue que dans les procédés conventionnels, la courbe d'apprentissage démontre une diminution marquée selon l'expérience et l'introduction de nouvelles technologies. Le nombre de patients potentiellement susceptibles de profiter de cette approche reste peu élevé, limitant ainsi sa diffusion, mais dans les centres rompus à la technique, il faut la considérer comme une option valide, offrant à certains patients des avantages d'ordre cosmétique ou en termes de détresse postopératoire.

**Resumen.** La tiroidectomía mínimamente invasiva realizada con videocámara (MIVAT) fue descrita en 1998. Recogemos la experiencia con esta técnica de 4 centros de tercer nivel en los que se seleccionaron 336 pacientes (279 mujeres y 57 hombres) para ser tratados mediante el MIVAT. Los criterios de selección fueron: volumen tiroideo < 15 ml, adenopatías < 3.5 cm de diámetro, ausencia de tiroiditis, cirugía cervical o irradiación previas. La técnica, sin empleo de gas alguno, se llevó a cabo

mediante una incisión central de 15 mm, situada sobre el yugulum esternal. La disección se realizó bajo visión endoscópica utilizando instrumentos convencionales o endoscópicos. Duración media de la operación para la lobectomía:  $69.4 \pm 30.6$  minutos (rango 20–150); para la tiroidectomía total:  $87.4 \pm 43.5$  minutos (rango 30–220). Hospitalización media  $1.9 \pm 0.8$  días. Complicaciones postoperatorias: 7 parálisis recurrenciales transitorias, una definitiva y 11 hipoparatiroidismos (9 transitorios, 2 definitivos). Reversión a cirugía abierta en 15 pacientes (4.5%). Este estudio, con amplia casuística, confirma que la MIVAT es posible y segura, obteniéndose, incluso con equipos quirúrgicos diferentes, resultados similares. La tasa de complicaciones es semejante a la cirugía convencional. Aunque la duración de la intervención parece mayor que con la cirugía convencional, tras la curva de aprendizaje, los tiempos operatorios se reducen drásticamente debido al aumento de la experiencia y al desarrollo de nuevas tecnologías. Aunque el número de pacientes susceptibles de tratamiento con MIVAT es pequeño, lo que limita su difusión, esta técnica ha de ser considerada como una opción en centros quirúrgicos seleccionados, pues ofrece ventajas para los pacientes por lo que a la enfermedad postoperatoria y a los resultados cosméticos se refiere.

## References

1. Shimizu K, Akira S, Jasmi AY, et al. Video-assisted neck surgery: endoscopic resection of thyroid tumors with a very minimal neck wound. *J. Am. Coll. Surg.* 1999;188:697–703
2. Ikeda Y, Takami H, Sasaki Y, et al. Endoscopic neck surgery by the axillary approach. *J. Am. Coll. Surg.* 2000;191:336–340
3. Ohgami M, Ishii S, Arisawa Y, et al. Scarless endoscopic thyroidectomy: breast approach for better cosmesis. *Surg. Laparosc. Endosc. Percutan. Tech.* 2000;10:339
4. Miccoli P, Berti P, Raffaelli M, et al. Minimally invasive video-assisted thyroidectomy. *Am. J. Surg.* 2001;181:567–570
5. Bellantone R, Lombardi CP, Raffaelli M, et al. Minimally invasive, totally gasless video-assisted thyroid lobectomy. *Am. J. Surg.* 1999;177:342–343
6. Miccoli P, Berti P, Raffaelli M, et al. Comparison between minimally invasive video-assisted thyroidectomy and conventional thyroidectomy: a prospective randomized study. *Surgery* 2001;130:1039–1043
7. Hay ID, Bergstralh EJ, Goellner JR, et al. Predicting outcome in papillary thyroid carcinoma: development of a reliable prognostic scoring system in a cohort of 1779 patients surgically treated at one institution during 1940 through 1989. *Surgery* 1993;114:1050–1057
8. Songun I, Kievitt J, Van de Velde CJH. Complications of thyroid surgery. In Clark OH, Duh QY, editors, *Textbook of Endocrine Surgery*, Philadelphia, Saunders, 1997;167–173
9. Williams D. Morphological aspects of thyroid cancer and tumour prognosis. *J. Endocrinol. Invest.* 1995;18:153–154
10. Walz MK, Lederbogen S, Limmer J, et al. Die videoskopisch-assistierte Hemithyroidektomie: operative Technik und erste Ergebnisse. *Chirurg.* 2001;72:1054–1057