

Mirror Syndrome: A Systematic Review of Fetal Associated Conditions, Maternal Presentation and Perinatal Outcome

Thorsten Braun^a Martin Brauer^a Ilka Fuchs^a Christoph Czernik^b
Joachim Wolfram Dudenhausen^a Wolfgang Henrich^a Nanette Sarioglu^c

Departments of ^aObstetrics, ^bNeonatology, and ^cPathology, Charité Campus Virchow, Berlin, Germany

Key Words

Ebstein's anomaly · Mirror syndrome · Ballantyne syndrome · Hydrops fetalis · Anemia · Maternal edema

Abstract

Introduction: Mirror syndrome, also referred to as Ballantyne's syndrome, is normally defined as the development of maternal edema in association with fetal hydrops. The incidence of mirror syndrome is low and few cases have been published. We describe a case report in association with fetal Ebstein anomaly and provide a systematic review on the fetal associated conditions, maternal presentation and perinatal outcome reported for mirror syndrome. **Data Sources:** A PubMed database search was done until December 2008 (English, French or German) without any restriction of publication date or journal, using the following key words: Ballantyne syndrome, Mirror syndrome, Triple edema, Pseudotoxemia, Maternal hydrops syndrome, Pregnancy toxemia, Acute second trimester gestosis, and Early onset preeclampsia. Reported cases were considered eligible when fetal associated conditions, maternal symptoms and fetal outcome were clearly described. **Results:** Among 151 publications a total of 56 reported cases satisfying all inclusion criteria were identified. Mirror syndrome was associated with rhesus isoimmunization (29%), twin-twin transfusion syndrome (18%),

viral infection (16%) and fetal malformations, fetal or placental tumors (37.5%). Gestational age at diagnosis ranged from 22.5 to 27.8 weeks of gestation. Maternal key signs were edema (80–100%), hypertension (57–78%) and proteinuria (20–56%). The overall rate of intrauterine death was 56%. Severe maternal complications including pulmonary edema occurred in 21.4%. Maternal symptoms disappeared 4.8–13.5 days after delivery. **Discussion:** Mirror syndrome is associated with a substantial increase in fetal mortality and maternal morbidity.

Copyright © 2010 S. Karger AG, Basel

Introduction

John W. Ballantyne [1–3] in 1892 was the first to describe the association of maternal edema in pregnancy with fetal and placental hydrops due to rhesus isoimmunization [4]. Over the years this maternal pathology which 'mirrors' fetal pathology has been given various names, such as pseudotoxemia, maternal hydrops syndrome, pregnancy toxemia, acute second trimester gestosis, early onset preeclampsia, maternal hydrops syndrome, triple edema or mirror syndrome [5, 6]. As it is uncommon and frequently underdiagnosed, the incidence of mirror syndrome is not clear. Prior to 2007 (less

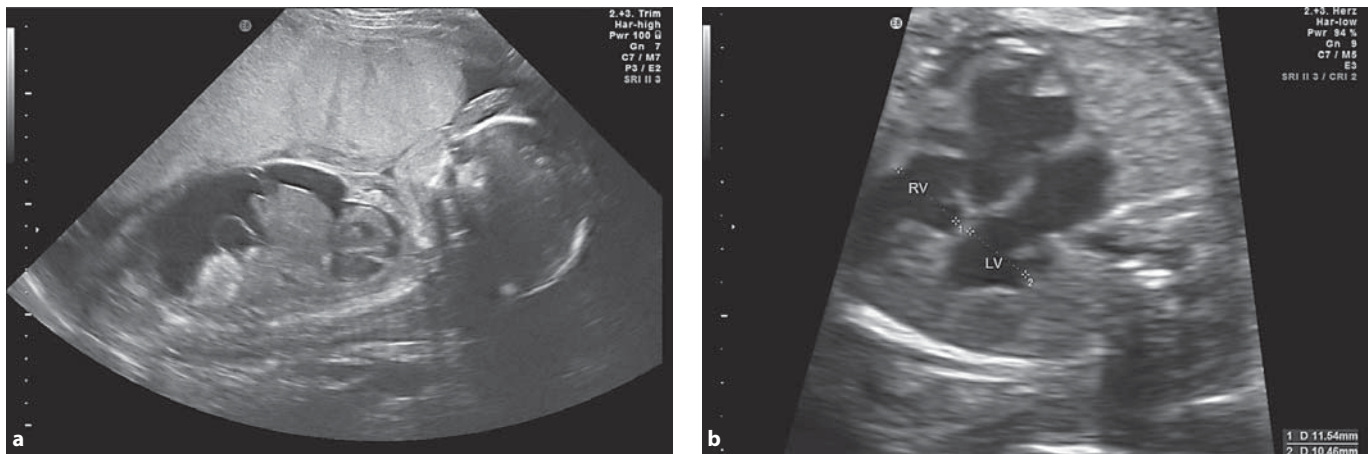


Fig. 1. a Ultrasonographic findings at 26 weeks 0 days of gestation of the placental edema; fetal hydrops with ascites and subcutaneous edema, pronounced at the forehead. **b** Ultrasonographic findings of the fetal echocardiography: cardiomegaly with biventricular myocardial hypertrophy; displacement of the tricuspid valve towards the apex of the right ventricle. RV = Right ventricle, LV = left ventricle.

than) 25 cases were reported [7, 8]. The pathogenesis and pathophysiology is unknown [8]. In the late 1970s the development of ultrasound and prenatal diagnosis allowed description of cases of mirror syndrome in association with non-immunological, structural causes, for example aneurysm of Galen's vein [9], sacrococcygeal teratoma [10] or placental chorioangioma [11]. Non-structural causes such as fetal arrhythmias [12], human parvovirus infection [7, 13, 14] and Coxsackie virus [15] infection were reported as well (table 1). Ebstein's anomaly occurs in 0.5% of patients with congenital heart disease with a sonographic typical distal displacement of the septal and posterior leaflets of the tricuspid valve. In severe cases this malformation is associated with hydrops fetalis and a very poor fetal prognosis [6, 16, 17].

Case Report

A 27-year-old woman, gravida 1, para 1, group A, rhesus-negative was referred at 25 weeks 6 days of gestation to our department because of severe hydrops fetalis. Maternal examination revealed mild edema of the ankles and legs, normal blood pressure, minimal proteinuria (table 2). No blood group antibody was detected, TORCH serology was normal, amniocentesis showed a normal karyotype.

Fetal ultrasonic examination confirmed a massive ascites, subcutaneous edema, placental edema, pleural effusion and polyhydramnios (fig. 1a). Fetal echocardiography presented a cardiomegaly with biventricular myocardial hypertrophy and a severe Ebstein's anomaly: third-degree tricuspid insufficiency, displacement of the tricuspid valve towards the apex of the right ventricle,

valve leaflets in part attached to the septal wall (fig. 1b). The right atrium was dilated to 17.5 mm with no evidence of blood flow via the foramen ovale. Truncus pulmonalis appeared to be normal, but without visualization of antegrade blood flow via the pulmonary valve. The perfusion of the pulmonary arteries seemed to be retrograde via the ductus arteriosus.

An intravenous digoxin therapy with an initial dose of 800 µg/day, followed by an oral preservation therapy with methyl digoxin (Novodigal®) with a serum level of up to 2.5 µg/l, was started to improve fetal cardiac function and to reduce the hydrops fetalis as reported before to be useful in Ebstein's anomaly [18]. Maternal echocardiography was normal at the time of admission.

After 3 days, the patient presented increased dyspnea, chest pain, mild fever and a need for oxygen. With pneumonia as the tentative diagnosis, combined antibiotic therapy was started. The patient developed massive generalized edema and total body weight increased 9 kg in 8 days. A repeated maternal echocardiography on day 7 presented an increased insufficiency of the mitral valve, tricuspid valve and pulmonary valve with biventricular increase of volume and pressure load and pericardial effusion. A spiral CT scan of the lungs completed the clinical diagnosis of a massive lung edema and pleural effusion. No signs of embolization of the pulmonary arteries were noted.

Fetal echocardiography itself presented a progress of hydrops fetalis. Fewer fetal movements were observed, pulsed-wave Doppler of the umbilical artery revealed increased pulsatility indices, and pulsed-wave Doppler of the middle cerebral artery presented a trend towards a brain-sparing effect. Fetal prognosis was estimated to be very poor by the obstetrical and pediatric staff due to congestive heart failure; discussion with the patient and her husband led to abstention. After induction with 4 doses of misoprostol (4 × 50 µg Cytotec®) the patient went into labor. At 26 weeks 6 days of gestation, a girl, 1,860 g, was spontaneously delivered alive but died 9 min after. The placenta was grossly edematous, weighed 885 g with no signs of chorioamnionitis. Fetal hemoglobin was 14.7 g/dl.

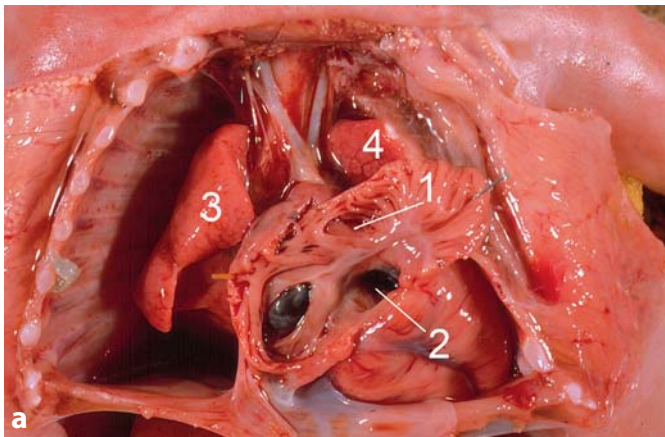
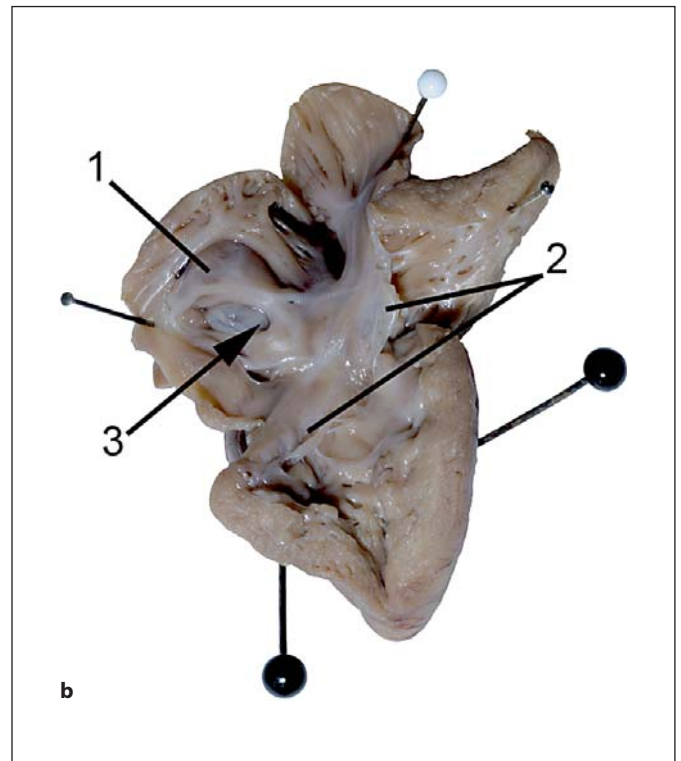


Fig. 2. a Autopsy images at 28 weeks of gestation. The heart is in situ. The right atrium is opened. View through the right atrioventricular junction into the right ventricle (1 = right atrium, 2 = tricuspid valve, 3 = right lung, 4 = left lung). **b** This heart has been opened through the right atrioventricular junction to show the typical feature of Ebstein's malformation. Displacement of the hinge point of the septal and dorsal leaflets of the tricuspid valve from the atrioventricular junction into the cavity of the right ventricle, the leaflets themselves being dysplastic. The foramen ovale is open but narrow (1 = right atrium, 2 = septal and dorsal leaflets of the tricuspid valve, 3 = foramen ovale).



The patient was discharged 7 days after delivery with normal cardiac function and well-being (weight loss = 17 kg). Autopsy confirmed the prenatal findings and diagnosis of an Ebstein's anomaly; pulmonary cardiac failure due to lung hypoplasia and decompensated congenital cardiac anomaly caused fetal death (fig. 2).

Systematic Review of Mirror Syndrome

A PubMed database search in English, French or German was performed without any restriction of publication date or journal, using the following key words: Ballantyne syndrome, Mirror syndrome, Triple edema, Pseudotoxemia, Maternal hydrops syndrome, Pregnancy toxemia, Acute second trimester gestosis, and Early onset preeclampsia. The last search was updated in December 2008. All references of the selected articles were hand-searched for relevant studies not captured by electronic searches. Cases reported more than once by the same team in different publications were counted only once. Individually reported cases were not recounted in the larger case series. For each included case we focused on the following criteria: time of diagnosis, time of antenatal symptoms, time of delivery, time until maternal convalescence, maternal symptoms (weight gain/edema, hypertension, maternal anemia/low hematocrit, proteinuria/albuminuria, elevated uric acid and creatinine, pulmonary edema, elevated liver enzymes, oliguria, headache/visual disturbances/nausea/vomiting, thrombocytopenia) and fetal outcome (intrauterine death/stillbirth, death after delivery, survival) (table 3). From all the reported cases, only those publications were retained where the diagnosis of fetal hydrops associated with maternal symptoms was certain.

Results

After reviewing of 151 articles, 56 cases published between 1956 and 2009 met the above criteria in which cases of fetal hydrops associated with maternal symptoms were presented. Mirror syndrome could be grouped into cases associated with rhesus isoimmunization (n = 15, 28.6%), multiple pregnancies (n = 10, 17.9%), viral infections (n = 9, 6.1%) and others including fetal malformations, fetal and placental tumors, fetal arrhythmia, etc. (n = 21, 37.5%) (table 3). The case reports were analyzed regarding the time of diagnosis of fetal symptoms, the time when maternal symptoms appeared, the time of delivery, fetal outcome and the time of maternal convalescence. The time in pregnancy when maternal symptoms first occurred ranged from 16 to 34 weeks of gestation (table 1). The earliest time of diagnosis of mirror syndrome was made in a case of twin pregnancies at 16 weeks of gestation, in 4 out of 56 cases the diagnosis was made postpartum. Maternal symptoms were analyzed and could be grouped into ten (for details, see table 3). The most common maternal symptoms were weight gain and maternal edema (89.3%), followed by elevated blood pressure (60.7%), mild anemia and hemodilution (46.4%),

Table 1. Literature review with case reports of mirror syndrome

No.	Author	Time of diagnosis	Fetal pathology	Fetal symptoms	Time of maternal symptoms	Maternal symptoms
a Rhesus isoimmunization						
1	Cohen 1960 [28]	28	rhesus isoimmunization	no ultrasound available, fetal heart sounds were not present at admission; generalized edema and large and pale placenta	27	leg edema, anemia, polyuria
2	De Silva 1971 [29]		rhesus isoimmunization	placenta megaly, hydrops fetalis	27	edema, anemia
3	Hirsch 1964 [30]	30	rhesus isoimmunization	placenta megaly	28	edema, anemia, albuminuria
4	John 1964 [31]	28	rhesus isoimmunization	hydrops fetalis (X-ray)	26	hypertension, edema, albuminuria
5	Keane 1978 [32]	29	rhesus isoimmunization	palpable hydramnion, fetal hydrops (X-ray), placenta hydrops	26	edema, with 29 weeks hypertension
6	Lobato 2008 [33]	28	rhesus isoimmunization	pericardial effusion, subcutaneous edema, hepatosplenomegaly, severe ascites, hydropic placenta	28	hypertension, edema, proteinuria, mild anemia, low hematocrit
7	Mahmood 1987 [34]	26	rhesus isoimmunization	hydrops fetalis, polyhydramnion	26	hypertension, albuminuria, anemia
8	Nicolay 1964 [35]	post partum	Rhesus isoimmunization	hydrops fetalis, hydropic placenta	34	edema, hypertension, mid proteinuria
9	Nicolay 1964 [35]	post partum	rhesus isoimmunization	hydrops fetalis, hydropic placenta	30	edema, weight gain
10	Nicolay 1964 [35]	post partum	rhesus isoimmunization	hydrops fetalis, hydropic placenta	29	edema, weight gain
11	O'Driscoll 1956 [36]	32	rhesus isoimmunization	hydropic placenta, massive fetal ascites	32	dyspnea, faintness, slight vaginal bleeding, anemia, edema, mild hypertension, blebs on the abdominal wall
12	Rustamov 2006 [37]	26	rhesus isoimmunization	oligohydramnion, fetal ascites, pericardial effusion, fetal anemia	26	moderate edema, headaches, vomiting, mild hypertension, proteinuria, high urea level; 26+3 severe pulmonary edema, anemia, thrombocytopenia
13	Van Selm 1991 [5]	22	rhesus isoimmunization	severe fetal and placental hydrops	22	edema, anemia, hypertension, high plasma uric levels
14	Van Selm 1991 [5]	25	rhesus isoimmunization	severe fetal and placental hydrops	25+5	edema, hypertension, eclamptic convulsion, cerebral hemorrhagic infarction
15	Van Selm 1991 [5]	28	rhesus isoimmunization	massive hydrops fetalis, anemia, placental hydrops	28	edema, epigastric pain, nausea, vomiting, visual disturbances
b Twin pregnancies						
1	Heyborne 2004 [24]	16	dichorionic twins	recipient: one fetus with ascites, pleural and pericardial effusions, generalized skin edema	16	massive edema, mild thrombocytopenia, elevated liver enzymes (ALT/AST)
2	Heyborne 2000 [23]	16	dichorionic twins, cause for fetal hydrops unknown	recipient: hydrops fetalis, ascites, pericardial effusion, generalized skin edema	16	rapid-onset generalized edema, elevated AST/ALT, no preeclamptic findings
3	Pirhonen 2004 [38]	28+1	dichorionic twins	recipient: severe hydrops of the male twin, skin edema, ascites, pleural and pericardial effusions; terminal heart insufficiency, reverse flow in the umbilical artery and ductus venosus, hydropic placenta	26+1	extreme maternal edema, blood pressure increase, proteinuria, elevated uric acid and creatinine, high serum potassium and a low serum sodium, liver enzymes were mildly elevated
4	Hayashi 2006 [39]	24+5	monochorionic-diamniotic twins with TTTS	recipient: polyhydramnion, reverse flow in the ductus venosus and pulsatile umbilical venous, hypertrophic cardiomegaly; prior to surgery hydrops fetalis with ascites, mild skin edema, pericardiac effusion, placenta megaly	25+0	mild edema, hemoglobin and hematocrit values decreased sharply just before the operation; 30 min after surgery acute respiratory failure with dyspnea, pulmonary edema, skin edema, oliguria, acute anemia, hypoproteinemia; patient stayed intubated until postoperative day 6
5	Matsubara 2008 [40]	23+2	monochorionic, triamniotic-triplets with TTTS between acardius and twin A	two living fetuses (A+B) with PROM, one acardius: edema, placenta megaly	23+2	edema, hypertension, proteinuria, anemia, low hematocrit, cardiomegaly
6	Olivella 2006 [41]	27+6	monochorionic-diamniotic twins with TTTS	recipient with hydrops fetalis	27+6	hypertension, tachycardia and tachypnea, acute respiratory failure and oliguria 1 day after laser therapy

Treatment	Gestation at delivery	Fetal outcome	Maternal reconvalescence
reserpine, acetazolamide, low-salt diet	28	stillborn delivered by craniotomy	not reported
iron, vitamin B ₁₂ , calcium lactate, hydrochlorothiazide	30	stillbirth	disappeared at 27+3 weeks
bedrest, chlorthiazide, salt-poor diet, pironolactone, ACTH, methylprednisolone, maternal blood transfusion	31	intrauterine death	2 weeks
diuretics	28	artificial rupture of the membranes, stillbirth	not reported
none	29	stillborn after induction	within 36 h after delivery
4 × intrauterine exchange transfusion, methyl dopa	32	after initial improvement worsening of fetal symptoms, cesarean section, discharged 46 days after birth	shortly after the forth intrauterine infusion (31 weeks of gestation)
none	27	PROM, fetus died 30 min after delivery	febrile infection, normalization 10 days after delivery
various diuretics	35+2	died 30 min after delivery	within 72 h after delivery
various diuretics	33	premature labor, paracentesis to effect delivery	within 72h after delivery
not reported	30	spontaneous labor, died within minutes after delivery	not reported
none	not reported	spontaneous delivery, not reported	48 h after delivery
intrauterine exchange transfusion	26+3	died 1 h after delivery	improved rapidly after delivery
none	27	intrauterine death	12 h after deliver
intrauterine exchange transfusion	27	intrauterine death	1 week after eclamptic convulsion
intrauterine exchange transfusion	28+4	intrauterine death	2 days after delivery
dexamethasone, selective fetocide of the affected twin	term	healthy	1–2 weeks after delivery
dexamethasone, selective fetocide of the affected twin	term	healthy	1–2 weeks after delivery
not reported	29+4	stillbirth of hydropic twin, 31+3 weeks cesarean section due to preterm labor, female fetus healthy	normalization of blood pressure within 24 h after hydropic twin died, after 3 weeks full remission
2 × amnion fluid drainage in 3 days, laser ablation therapy with 27 weeks	25+1	stillbirth of recipient twin, ascites of donor twin on postoperative day 1, delivered on postoperative day 6, recipient died on postoperative day 13 due to severe acidemia and sepsis	shortly after delivery
not reported	23+5	emergency cesarean section due to cord prolapse	3 days after delivery
successful laser ablation therapy	not reported	not reported	not reported

Table 1 (continued)

No.	Author	Time of diagnosis	Fetal pathology	Fetal symptoms	Time of maternal symptoms	Maternal symptoms
7	Olivella 2006 [41]	19+3	monochorionic-diamniotic twins with TTTS	recipient: severe polyhydramnion	19+3	hypertension, elevated liver enzymes, anemia
8	Kumar 2007 [8]	26	monochorionic-diamniotic twins with TTTS	recipient: polyhydramnion, enlarged heart, poorly contracting, ascites; donor: oligohydramnion	27	hypertension, generalized edema
9	Chang 2007 [42]	19	dichorionic-triplets with TTTS	one set of female twins with poly-/oligohydramnion sequence, male fetus with a normal amount of amniotic fluid, recipient twin reverse A wave of the ductus venosus and pulsation of the umbilical vein	19	severe edema, hypertension, mild anemia, high uric acid, high LDH level
10	Matsubara 2008 [43]	21+3	monochorionic-twins with FTTS	recipient: polyhydramnion, hydrops fetalis, skin edema, ascites, pleural effusion, hypertrophic cardiomegaly	21+3	weight gain, anemia, low albuminemia, elevated hCG; initial worsening of maternal symptoms 4 days after surgery
c Viral infections						
1	Ambrosini 2008 [15]	26+5	Coxsackie B virus	hydrops fetalis, ascites, pericardial effusion, polyhydramnion, skin and placenta edema, increased middle cerebral artery peak systolic velocity, fetal anemia	27	dilution anemia; after transfusion increased edema, oliguria, anemia; 27+3 weeks peripartum cardiomyopathy: hypotension, cyanosis, generalized edema
2	Quagliarello 1978 [44]	30	cytomegalovirus	audible heart tones; obduction: hydrops fetalis, pericardial effusion, ascites, hepato- and splenomegaly, edematous placenta	30	edema, hypertension
3	Rana 2007 [19]	29+4	cytomegalovirus	ascites, pleural effusions, placental edema, fetal skin edema pleural effusion, hepatosplenomegaly, cardiomegaly, pulmonary hypoplasia, pathologic CTG	29+4	worsening leg swelling over 1 week, hypertension, proteinuria
4	Brochot 2006 [13]	20	parvovirus B19	hydrops fetalis and IUGR, fetal anemia	25	moderate hypertension, elevated liver enzymes, hyperuricemia, 48 h later edema, hemodilution, epigastric pain, pulmonary edema, pleura effusions
5	Duthie 1995 [45]	25	parvovirus B19	hydrops fetalis, oligohydramnion, hydropic placenta, fetal anemia	25	edema, proteinuria, hypertension, moderate thrombocytopenia
6	Goeden 2005 [7]	21+5	parvovirus B19	hydrops fetalis, scalp edema, pleural and pericardial effusions, ascites, thickened placenta	23+4	edema, anemia, hypertension, proteinuria, hyperuricemia
7	Proust 2006 [46]	25	parvovirus B19	hydrops fetalis, anasarca, placenta hypertrophy	25	edema, proteinuria, hypertension
8	Proust 2006 [46]	22	parvovirus B19	hydrops fetalis, anemia, placenta hypertrophy	24+6	edema, proteinuria, pruritus, hyperuricemia, elevated liver enzymes
9	Ville 1995 [14]	25	parvovirus B19	fetal and placental hydrops, ascites, subcutaneous edema, heart dilatation, pericardial effusion	25	chest pain, headache, leg and hand edema, mild hypertony; right pleural effusion and bilateral interstitial syndrome; hyponatremia, hypoosmolality and secondary hyperaldosteronism
d Tumors, congenital anomalies and others						
1	Ordorica 1990 [9]	27/33	aneurysm of vein of Galen	27 weeks: hydrops fetalis, vein of Galeni malformation, polyhydramnion; 33 weeks: ascites, cardiomegaly, placenta megaly	30	edema, mildly proteinuria, pulmonary edema with dyspnea, next week renal insufficiency, hypertension
2	Mizrahi-Arnaud 2006 [47]	29	aortic stenosis	hydrops fetalis, pericardial effusion, ascites, aortic stenosis, dilated left ventricle, polyhydramnion, placenta megaly	30+4	after surgery, pulmonary edema, impaired hepatic function, low thyroid-stimulating hormone, high chorionic gonadotropin
3	Wurm 2007 [48]	31	congenital disorders of glycosylation type Ia	hydrops fetalis, ascites	31	maternal edema, mild oliguria
4	Paternoster 2006 [49]	28+4	cystic hygroma at the fetal neck	hydrothorax, subcutaneous edema, placental edema, polyhydramnion, borderline ventriculomegaly, pleural effusion, edematous umbilical cord, absent or reversed end-diastolic flow, increased pulsatility index in middle cerebral artery	30	edema of hands and face, anemia
5	Valsky 2007 [50]	25+6	Diamond-Blackfan anemia	hypoechoic fetal abdominal cyst, 5.5 cm in diameter, hydrops fetalis, severe ascites, pericardial effusion, scalp edema, pronounced cardiomegaly myocardial hypertrophy, biventricular dilatation with tricuspid and mitral regurgitation, dilatation of the vena cava, reversed flow in the ductus venosus, oligohydramnion, fetal anemia; at 26+6 weeks severe placental edema	26+6	rapidly increasing maternal edema, hypertension, proteinuria, decreased hematocrit elevated liver enzymes, uric acid was elevated

Treatment	Gestation at delivery	Fetal outcome	Maternal reconvalescence
none	not reported	termination of pregnancy	not reported
successful laser ablation therapy with 27 weeks; donor developed ascites and hydrops afterwards	27	donor with progressive ascites after cesarean section, anuric, developed RDS and died 1 week after delivery	shortly after cesarean section
laser therapy was not possible	19+1	termination of recipient twin with electrocoagulation of the umbilical cord; postoperative day 2 donor twin died as well; miscarriage with 21 weeks due to vaginal bleeding	1–2 days after termination
fetoscopic laser photocoagulation	37	cesarean section	10 days after surgery
intrauterine blood transfusion	27+3	emergency cesarean section, healthy	17 days after delivery
not reported	30+2	intrauterine death, spontaneous delivery with 31+2 weeks	not reported
not reported	29+5	emergency cesarean section, neonate had severe anemia and lived 1 h for the duration of resuscitation	not reported
nicardipine followed by labetalol and diuretics, 2 intrauterine exchange transfusions; intensive care unit with positive pressure ventilation	36	MRT at 32 weeks revealed severe fetal cerebral abnormalities, fetocide and induction of labor at 36 weeks	shortly after delivery
intrauterine transfusion, day 7 fetal ascites disappeared	37	spontaneous delivery, healthy newborn	few weeks after delivery
lung maturation, intrauterine exchange transfusion unsuccessful	36+6	healthy	28+4 weeks of gestation spontaneous complete remission of maternal and fetal symptoms
none	25	intrauterine death	not reported
intrauterine transfusion	25	intrauterine death	few days after delivery
water depletion, 20 g albumin	25+3	induction with prostaglandins after intrauterine death	18 h after intrauterine death maternal RDS, diuretics, several pleural drainages, discharged 10 days after delivery
digoxin, furosemide	34	cesarean section, neonate died shortly after delivery of cardiovascular collapse	5 days after delivery
digoxin, fetal aortic valve dilatation	30+6	cesarean section, balloon dilatation, died of fungal sepsis 13 days after birth	7 days after delivery
not reported	36	cesarean section	not reported
2 pleuroamniotic shunts with 29+4, disappearance of hydrothorax	30+3	cesarean section because of pathologic CTG	6 days after delivery
2 × intrauterine blood transfusion at 26/28 weeks; magnesium sulfate	34+1	cesarean section, Diamond-Blackfan anemia as postnatal diagnosis	30 weeks of gestation symptoms completely disappeared

Table 1 (continued)

No.	Author	Time of diagnosis	Fetal pathology	Fetal symptoms	Time of maternal symptoms	Maternal symptoms
6	Carbillon 1997 [6]	30+3	Ebstein's anomaly	hydrops fetalis, pleural effusion, massive tricuspid reverse flow, pulmonary atresia, placental edema, polyhydramnion	30+4	edema, anemia, thrombocytopenia
7	Leung 2006 [27]	27	Ebstein's anomaly	cardiomegaly, ascites, subcutaneous edema, pericardial effusion, polyhydramnion, placental edema	29	edematous, right upper quadrant abdominal pain and palpitations, sinus tachycardia, elevated liver enzymes, borderline hypothyroidism, oliguria, increased creatinine and urate level, anemia, during labor induction impending eclampsia
8	Livingston 2007 [22]	29+2	endodermal sinus tumor of the sacrococcygeal region	heterogeneous mass protruding in the sacrococcygeal area, fetal abdominal urinary ascites, skin edema, placenta megaly, oligohydramnion, hydroureter, hydronephrosis, evidence of bladder rupture	29+2	edema, shortness of breath, chest pain, palpitations, blurred vision, hypertension, anemia, hyperuricemia; 30+1 weeks dyspnea, tachycardia
9	Allen 2007 [51]	27+6	fetal renal neuroblastoma, metastatic to the placenta	hydrops fetalis, mass within the left kidney, scalp edema, placenta megaly	28+6	edema, mild hypertension, oliguria
10	Dorman 1995 [11]	>19	placental chorangioma	hydropic fetus, thickened placenta	>19	mild frontal headache, slight nausea, marked peripheral edema, hypertension, proteinuria
11	Gherman 1998 [52]	25	placental chorangioma	23 weeks: polyhydramnion; 25 weeks: placental mass, hydrops fetalis	25	acute onset lower extremity edema, hyperuricemia, generalized pruritus, dyspnea, hemodilutional anemia, pre-term labor; markedly elevated human chorionic gonadotrophin
12	Galimberti 2000 [53]	26	placental chorangioma, cardiac failure secondary to shunting through the placental tumor	subcutaneous edema, ascites, pleura effusion, polyhydramnion, suspicious mass adjacent to the placenta	26	edema, mild hypertension, proteinuria, hyperreflexia, anemia, mildly elevated urate
13	Deurloo 2003 [54]	29	primary chylothorax with secondary hydrops and polyhydramnion due to cardiac and esophageal compression	severe polyhydramnion, hydrops fetalis, bilateral hydrothorax, increased placental thickness	30	abdominal overdistension, pain, headache, visual disturbances, back pain, massive edema, very active patellar reflexes, hypertensive, proteinuria, slightly raised liver enzymes, anemia, mild albuminuria
14	Finamore 2007 [10]	29	sacrococcygeal teratoma	29 weeks increased cerebral flow; 29+5 weeks enlarged heart, thickened placenta, increased liver length, mild polyhydramnion	30	pruritic rash, edema, hypertension, epigastric pain, proteinuria, anemia and thrombocytopenia
15	Ibele 2008 [55]	25+3	sacrococcygeal teratoma	mild pericardial effusion, 27 weeks: placenta megaly, polyhydramnion, scalp edema, ascites, pericardial and pleural effusions	27+2	hypertension, edema, highly elevated liver enzymes
16	Midgley 2000 [12]	27	supraventricular tachycardia	pericardial effusion, scalp edema, ascites	27	headaches, visual disturbances, hypertension, proteinuric, raised uric acid
17	John 1964 [31]	30	unknown	hydrops fetalis (X-ray); placenta megaly	28	edema, with 30 weeks hypertension, proteinuria
18	Kaiser 1971 [4]	after delivery	unknown	hydrops fetalis, ascites, pericardial effusion, large and edematous placenta	28	edema, mild anemia, later dyspnea, oliguria, mild proteinuria, hypertension
19	Nakamura 2002 [56]	23	unknown	subcutaneous edema, massive ascites, hydrothorax, single heart ventricle, common atrioventricular canal, enlarged placenta	23	hydrothorax, generalized edema, proteinuria, mild hypertension
20	Vidaeff 2002 [57]	31	unknown	hydramnion and fetal ascites	31	massive edema, anemia
21	Vidaeff 2003 [58]	32	unknown	hydramnion, scalp edema, pleural effusions, mild ascites, placenta megaly	32	edema

TTTS = Twin-to-twin transfusion syndrome.

Treatment	Gestation at delivery	Fetal outcome	Maternal reconvalescence
bedrest	31+3	stillbirth	4 days after delivery
intrauterine blood transfusion	30	stillbirth	shortly after delivery
furosemide, fluid restriction; 30+2 weeks fetal peritoneal-amniotic shunt with fast removal of fetal and maternal symptoms	34+4	cesarean section, successful surgery and removal of the sacrococcygeal mass	3 days after shunting
not reported	29	pulmonary hypertension, sepsis, and renal failure, death on day 4 of life	endometritis postpartum
methyl dopamine	19+	stillborn hydropic fetus	2 days after delivery
magnesium sulfate tocolysis, therapeutic amniocentesis	26	secondary cesarean section, died 2 days later	after delivery preeclampsia-like syndrome with oliguria and pulmonary effusions, 3 weeks later complete remission
none	26	emergency cesarean section following abnormal cardiotocographic trace, died after unsuccessful resuscitation	6 days after delivery
ultrasound-guided thoracocentesis, within 24 h recurrence of hydrothorax and polyhydramnion; worsening fetal hydrops led to the decision for thoracoamniotic shunting; two silastic 'Rodeck' pigtail shunts were successfully inserted on both sides of the thorax	30+1	neonate required intubation successful postnatal drainage	4 days after delivery
intrauterine blood transfusion	30	cesarean section, successful surgery after delivery	shortly after delivery
not reported	27+5	emergency cesarean section, discharge at day 60 after fetal surgery	not reported
flecainide	40+1	healthy, no treatment after delivery	1 week after flecainide treatment and resolution of fetal SVTs
not reported	30	amniotomy, healthy	not reported
diuretics, digitalis, phenobarbital	32	cesarean section, neonate died shortly after delivery	few days after delivery
not reported	25+0	intrauterine death with 24+6 weeks, induction of labor	after 6 days, peripartum cardiomyopathy last for 23 days after delivery
not reported	31+3	healthy, ascites resolved rapidly	few days after delivery
not reported	32+1	cesarean section due to maternal cerebral cavernous hemangiomas, fetus died 24 h later due to pulmonary hypoplasia	48 h after delivery breast enlargement, next day multiple blisters, superficial necrosis, skin breakdown; in less than 24 h, fever, acute respiratory distress syndrome, and acute renal failure, intubated and transferred to the intensive care unit, after breast reduction fast recovery

Table 2. Blood count and plasmatic ionogram

	Reference values	Admission			Delivery day 8	Discharge day 15
		day 0	day 5	day 7		
Hemoglobin, g/dl	12.0–15.7	11.2	9.6	8.8	9.8	9.9
Hematocrit, l/l	0.35–0.47	0.33	0.29	0.27	0.29	0.31
Leukocytes/nl	4.5–11.0 × 10 ³	7.81	14.59	10.42	19.66	12.27
Platelets/nl	150–400 × 10 ³	158	160	145	142	396
C-reactive protein, mg/dl	<0.5	<0.5	0.82	5.29	2.76	0.93
ALT/37°, U/l	<34	–	97	100	96	58
AST/37°, U/l	<35	–	58	50	59	37
LDH/37°, U/l	<247	–	–	–	296	–
Sodium, mmol/l	134–145	–	138	134	137	144
Potassium, mmol/l	4.4–5.2	4.5	4.3	3.7	4.2	4.9
Creatinine, mg/dl	<1.0	–	0.71	0.72	0.68	0.66
Urea, mg/dl	14–46	–	–	–	41	30

Table 3. Mirror syndrome – analyses of the literature review

Fetal pathology	A	B	C	Maternal symptoms									
				D	E	F	G	H	I	J	K	L	M
Rhesus isoimmunization	15 (28.6)	27.4 ± 2.6 ¹	27.7 ± 2.8	14 (93.3)	9 (60)	8 (53.3)	6 (40)	3 (20.0)	2 (13.4)	–	–	2 (13.4)	1 (6.7)
Multiple pregnancies	10 (17.9)	22.5 ± 4.7	22.4 ± 4.5	8 (80)	6 (60)	5 (50)	2 (20)	2 (20)	2 (20)	5 (50)	3 (30)	–	1 (10)
TTTS	7 (70)	23.4 ± 3.3	23.6 ± 4.4										
Unknown	3 (30)	20.3 ± 7.5	19.7 ± 6.4										
Viral infections	9 (6.1)	25.1 ± 3.5	26.2 ± 2.3	9 (100)	7 (77.8)	3 (33.3)	5 (55.6)	3 (33.3)	2 (22.2)	2 (22.2)	1 (11.1)	1 (11.1)	1 (11.1)
Parvovirus B19	6 (66.7)	23.2 ± 2.1	24.8 ± 0.4										
CMV	2 (22.2)	30 ± 0	30.0										
Coxsackie B	1 (11.1)	27	27										
Others	21 (37.5)	27.8 ± 3.0	28.4 ± 3.3	19 (90.5)	12 (57.1)	10 (47.6)	11 (52.4)	6 (28.6)	6 (28.6)	4 (19.0)	5 (23.8)	5 (23.8)	1 (4.8)
Malformation, arrhythmia	6 (28.6)	28.3 ± 1.6	29.7 ± 1.5										
Fetal tumor	5 (23.8)	28.4 ± 1.5	29.4 ± 0.9										
Placental tumor	3 (14.3)	23.7 ± 3.2	23.7 ± 3.2										
Metabolic disorders	2 (9.5)	29 ± 4.2	28.4 ± 3.5										
Unknown	5 (23.8)	29 ± 4.1 ²											

Values in parentheses are percentages. A = Number of cases (total n = 56); B = time of diagnosis (weeks of gestation ± SD); C = time of maternal symptoms (weeks of gestation ± SD); D = weight gain, edema; E = hypertension; F = anemia, low hematocrit; G = proteinuria, albuminuria; H = elevated uric acid and creatinine; I = pulmonary edema, dyspnoea; J = ele-

vated liver enzymes; K = oliguria; L = headache, visual disturbances, nausea, vomiting; M = thrombocytopenia; N = time of delivery (weeks of gestation ± SD); O = intrauterine death still birth; P = death after delivery; Q = survival; R = time until maternal reconvalence (days ± SD).

¹ Three cases postpartum. ² One case postpartum.

albuminuria and proteinuria (42.9%), elevated uric acid and creatinine (25%), mild elevated liver enzymes (19.6%), oliguria (16.1%) and headache and visual disturbances (14.3%). Severe maternal complications including pulmonary edema occurred in 21.4% of cases. The average rate of intrauterine death and stillbirth was 35.7% and the average time until maternal symptoms disappeared was 8.9 days.

Discussion

The present case of a fetal congenital heart disorder (Ebstein's anomaly) is a typical example of how fetal symptoms of severe hydrops and subcutaneous edema

can 'mirror' and can cause maternal complications. In this case the patient presented preeclampsia-like symptoms with severe edema, mild elevated liver enzymes and mild anemia without hypertension or decreased platelets. In addition, the patient developed a pulmonary infection on top of severe pleural effusion and presented right cardiac failure with pericardial effusion.

The etiology of the mirror syndrome remains unclear and a review of 56 cases reported in the literature until December 2008 presents a wide variety of fetal causes associated with mirror syndrome (table 1). In most of the cases (29%) severe rhesus isoimmunization in association with the mirror syndrome has been reported. Besides these immunological complications, mirror syndrome was reported in cases with twin pregnancies ($n = 10$) and viral infections (parvovirus B19 $n = 6$, cytomegalovirus $n = 2$, Coxsackie B virus $n = 1$). Others reported cases of placenta anomalies such as placental tumors ($n = 3$), cases of sacrococcygeal teratoma ($n = 3$), aneurysm of the vein of Galen ($n = 1$), stenosis of the aorta ($n = 1$) and Ebstein's anomaly ($n = 2$). 'Toxic placental agents' were suspected to be involved in the mirror syndrome. Increased levels of angiogenic factors (sFLT1, sENG) in a case of CMV infection [19, 20], as well as elevated IL-6 level seemed to be involved [5]. For a review of the pathophysiological hypotheses, see Carbillon et al. [6].

The mirror syndrome which is related to fetal hydrops and large placental mass has several clinical characteristics, but maternal edema as in our case seems to be a key symptom (89.3%). Further markers such as mild anemia and hemodilution (46.4%), mild elevated liver enzymes (19.6%) and pulmonary edema (21.4%) were reported (table 3). Other indicators found in the literature such as elevated blood pressure (60.7%), albuminuria and proteinuria (42.9%), elevated uric acid and creatinine (25%), oliguria (16.1%), headache and visual disturbances (14.3%) and low platelets (7.1%) were not present in our case.

The problem of distinguishing between mirror syndrome and preeclampsia is obvious. Maternal symptoms included a wide variety. Several authors have tried to differentiate between the mirror syndrome and preeclampsia, however, since the incidence of the mirror syndrome is low, no large series of patients have been published. This is the first complete review of mirror syndrome, which includes 56 cases reported in the literature. In the present review, characteristics which were reported to be of value to differentiate between mirror syndrome and preeclampsia such as generalized pruritus ($n = 2$), formation of abdominal blebs ($n = 1$), and the absence of hyper-

Fetal outcome				R
N	O	P	Q	
29.6 ± 2.7	8 (53.3)	4 (26.7)	2 (13.3)	4.8 ± 4.5
30.5 ± 7.6 26.8 ± 6.3 36.7 ± 5.8	3 (30)	2 (20)	5 (50)	10.7 ± 7.3
30.6 ± 5 31.0 ± 6.2 30.5 ± 0.7 28.0	5 (55.6)	1 (11.1)	3 (33.3)	13.5 ± 4.9
30.8 ± 4.4 33.2 ± 4.1 30.6 ± 2.7 24.0 ± 3.5 35.5 ± 0.7 30.4 ± 3.2	4 (19)	7 (33.3)	10 (47.6)	6.7 ± 5.3

active reflexes (n = 1) were found only in very few cases (table 1). Hemoconcentration is a typical pathophysiological feature in preeclampsia [21]. Reviewing the available cases in the literature (table 1), the consistent reporting of observation of low maternal hematocrit concentrations and mild anemia as the third most common symptom (46.6% of all reported cases) seems to be capable of differentiating the mirror syndrome from preeclampsia as suggested before [5, 6]. Further symptoms such as elevated serum uric acid or creatinine levels were only reported in 25% of all cases (table 3). Regardless of the fetal cause, maternal hypertension was the second most common symptom and illustrates the difficulty to distinguish mirror syndrome from preeclampsia.

Once the cause is treated and the fetal hydrops improves, maternal symptoms might disappear as described in several cases. Allen et al. [51] published a case of fetal pelvic mass which resulted in bladder outlet obstruction, subsequent bladder rupture and massive urinary ascites with thoracic and cardiac compression, and subsequent hydrops fetalis. Placement of a peritoneal-amniotic shunt resolved the fetal hydrops and maternal mirror syndrome [22]. In another case, hypertension and severe edema of the mother resolved after selective termination of the hydropic fetus in a twin-twin transfusion syndrome [23, 24]. Maternal treatment with diuretics, calcium channel blockers and β -blockers in a case of mirror syndrome due to parvovirus B19 complicated by severe maternal pulmonary effusion resolved maternal symptoms [13]. Ad-

equate treatment of fetal tachycardia in fetuses with hydrops due to cardiac failure resulted in an improvement of fetal heart function, reduction in fetal hydrops and maternal edema [25, 26].

Reviewing the literature, maternal symptoms associated with mirror syndrome disappeared shortly after the successful treatment of fetal symptoms or the termination of pregnancy (mean 8.9 days). Treatment of hydrops fetalis depends on the cause. In our case, maternal therapy with methyldigoxin – described before to be possibly successful in the treatment of Ebstein’s anomaly [18] – unfortunately did not improve fetal cardiac function and did not reduce fetal hydrops or maternal symptoms. Compared to the two cases of Ebstein’s anomaly associated with mirror syndrome found in the literature [6, 27], labor induction was required due to the worsening of maternal symptoms and the newborn died few minutes after birth.

In conclusion, this case of Ebstein’s anomaly and mirror syndrome demonstrates how fetal symptoms of cardiac failure, fetal hydrops and edema can be mirrored into maternal symptoms. Maternal edema and hemodilution associated with hydrops fetalis should alert physicians of this entity as it is associated with increased fetal mortality and maternal morbidity. However, the number of reported cases of mirror syndrome are limited. Further studies, both on the role of the placenta and the pathophysiology, are compulsory.

References

- Dunn PM: Dr John Ballantyne (1861–1923): perinatologist extraordinary of Edinburgh. *Arch Dis Child* 1993;68:66–67.
- Ballantyne JW: The disease and deformities of the fetus. Edinburgh, Oliver & Boyd, 1892.
- Reiss HE: Historical insights: John William Ballantyne 1861–1923. *Hum Reprod Update* 1999;5:386–389.
- Kaiser IH: Ballantyne and triple edema. *Am J Obstet Gynecol* 1971;110:115–120.
- Van Selm M, Kanhai HH, Gravenhorst JB: Maternal hydrops syndrome: a review. *Obstet Gynecol Surv* 1991;46:785–788.
- Carbillon L, Oury JF, Guerin JM, Azancot A, Blot P: Clinical biological features of Ballantyne syndrome and the role of placental hydrops. *Obstet Gynecol Surv* 1997;52:310–314.
- Goeden AM, Worthington D: Spontaneous resolution of mirror syndrome. *Obstet Gynecol* 2005;106:1183–1186.
- Kumar B, Nazaretian SP, Ryan AJ, Simpson I: Mirror syndrome: a rare entity. *Pathology* 2007;39:373–375.
- Ordorica SA, Marks F, Frieden FJ, Hoskins IA, Young BK: Aneurysm of the vein of Galen: a new cause for Ballantyne syndrome. *Am J Obstet Gynecol* 1990;162:1166–1167.
- Finamore PS, Kontopoulos E, Price M, Giannina G, Smulian JC: Mirror syndrome associated with sacrococcygeal teratoma: a case report. *J Reprod Med* 2007;52:225–227.
- Dorman SL, Cardwell MS: Ballantyne syndrome caused by a large placental chorioangioma. *Am J Obstet Gynecol* 1995;173:1632–1633.
- Midgley DY, Harding K: The mirror syndrome. *Eur J Obstet Gynecol Reprod Biol* 2000;88:201–202.
- Brochot C, Collinet P, Provost N, Subtil D: Mirror syndrome due to parvovirus B19 hydrops complicated by severe maternal pulmonary effusion. *Prenat Diagn* 2006;26:179–180.
- Ville Y, de Gayffier A, Brivet F, Leruez M, Marchal P, Morinet F, Troalen F, Fernandez H, Frydman R: Fetal-maternal hydrops syndrome in human parvovirus infection. *Fetal Diagn Ther* 1995;10:204–206.
- Ambrosini G, Nanhorgue K, Pascoli I, Cester M, Cosmi E: Mirror syndrome due to Coxsackie B virus associated to maternal peripartum cardiomyopathy. *J Perinat Med* 2008;36:453–454.
- Chaoui R, Bollmann R, Hoffmann H, Zienert A, Bartho S: Ebstein anomaly as a rare cause of a non-immunological fetal hydrops: prenatal diagnosis using Doppler echocardiography (in German). *Klin Pädiatr* 1990;202:173–175.

- 17 Hornberger LK, Sahn DJ, Kleinman CS, Copel JA, Reed KL: Tricuspid valve disease with significant tricuspid insufficiency in the fetus: diagnosis and outcome. *J Am Coll Cardiol* 1991;17:167-173.
- 18 Hsieh YY, Lee CC, Chang CC, Tsai HD, Yeh LS, Tsai CH: Successful prenatal digoxin therapy for Ebstein's anomaly with hydrops fetalis. A case report. *J Reprod Med* 1998;43:710-712.
- 19 Rana S, Venkatesha S, DePaape M, Chien EK, Paglia M, Karumanchi SA: Cytomegalovirus-induced mirror syndrome associated with elevated levels of circulating antiangiogenic factors. *Obstet Gynecol* 2007;109:549-552.
- 20 Stepan H, Faber R: Cytomegalovirus-induced mirror syndrome associated with elevated levels of angiogenic factors. *Obstet Gynecol* 2007;109:1205-1206.
- 21 Redman CW: Hypertension in pregnancy: a case discussion. *Kidney Int* 1987;32:151-160.
- 22 Livingston JC, Malik KM, Crombleholme TM, Lim FY, Sibai BM: Mirror syndrome: a novel approach to therapy with fetal peritoneal-amniotic shunt. *Obstet Gynecol* 2007;110:540-543.
- 23 Heyborne KD, Chism DM: Reversal of Ballantyne syndrome by selective second-trimester fetal termination. A case report. *J Reprod Med* 2000;45:360-362.
- 24 Heyborne KD, Porreco RP: Selective fetocide reverses preeclampsia in discordant twins. *Am J Obstet Gynecol* 2004;191:477-480.
- 25 Frohn-Mulder IM, Stewart PA, Witsenburg M, Den Hollander NS, Wladimiroff JW, Hess J: The efficacy of flecainide versus digoxin in the management of fetal supraventricular tachycardia. *Prenat Diagn* 1995;15:1297-1302.
- 26 Simpson JM, Sharland GK: Fetal tachycardias: management and outcome of 127 consecutive cases. *Heart* 1998;79:576-581.
- 27 Leung WC, Lam HS, Tang MH, Lao TT: Biochemical hypothyroidism - a new finding in mirror syndrome? *Eur J Obstet Gynecol Reprod Biol* 2006;125:269-271.
- 28 Cohen A: Maternal syndrome in Rh isoimmunization: report of a case. *J Obstet Gynaecol Br Emp* 1960;67:325-327.
- 29 De Silva K, Fonseka MN: Rhesus isoimmunization with a complex maternal syndrome. A case report of a patient with hydrops foetalis, pregnancy, toxemia, large placenta and bilateral theca-lutein cysts with torsion of one ovary. *Ceylon Med J* 1971;16:178-181.
- 30 Hirsch MR, Mark MS: Pseudotoxemia and erythroblastosis. Report of a case. *Obstet Gynecol* 1964;24:47-48.
- 31 John AH, Duncan AS: The maternal syndrome associated with hydrops foetalis. *J Obstet Gynaecol Br Commonw* 1964;71:61-65.
- 32 Keane B: Maternal syndrome associated with hydrops fetalis: case report. *NZ Med J* 1978;88:56-57.
- 33 Lobato G, Nakamura-Pereira M: Reversion of the Ballantyne syndrome despite fetal hydrops persistence. *Fetal Diagn Ther* 2008;24:474-477.
- 34 Mahmood TA: A reappraisal of the maternal syndrome associated with hydrops fetalis. *Eur J Obstet Gynecol Reprod Biol* 1987;25:159-163.
- 35 Nicolay KS, Gaaney HL: Pseudotoxemic state associated with severe Rh isoimmunization. *Am J Obstet Gynecol* 1964;89:41-45.
- 36 O'Driscoll DT: A fluid retention syndrome associated with severe iso-immunization to the rhesus factor. *J Obstet Gynaecol Br Emp* 1956;63:372-374.
- 37 Rustamov O: PO02.85: mirror syndrome: a case report. *Ultrasound Obstet Gynecol* 2006;28:543.
- 38 Pirhonen JP, Hartgill TW: Spontaneous reversal of mirror syndrome in a twin pregnancy after a single fetal death. *Eur J Obstet Gynecol Reprod Biol* 2004;116:106-107.
- 39 Hayashi S, Sago H, Hayashi R, Nakagawa S, Kitagawa M, Miyasaka K, Chiba T, Natori M: Manifestation of mirror syndrome after fetoscopic laser photocoagulation in severe twin-twin transfusion syndrome. *Fetal Diagn Ther* 2006;21:51-54.
- 40 Matsubara S, Ohmaru T, Ohkuchi A, Arai F, Kuwata T, Usui R, Takahashi K, Izumi A, Watanabe T, Suzuki M: Mirror syndrome associated with hydropic acardius in triplet pregnancy. *Fetal Diagn Ther* 2008;24:429-433.
- 41 Olivella A, Martinez JM, Lopez M, Del Rio M, Bannasar M, Peurto B, Coll O, Gratacos E: PO5.07: Two cases of mirror syndrome in TTTS with and without fetoscopic treatment. *Ultrasound Obstet Gynecol* 2006;28:561.
- 42 Chang YL, Chao AS, Hsu JJ, Chang SD, Soong YK: Selective fetocide reversed mirror syndrome in a dichorionic triplet pregnancy with severe twin-twin transfusion syndrome: a case report. *Fetal Diagn Ther* 2007;22:428-430.
- 43 Matsubara M, Nakata M, Murata S, Miwa I, Sumie M, Sugino N: Resolution of mirror syndrome after successful fetoscopic laser photocoagulation of communicating placental vessels in severe twin-twin transfusion syndrome. *Prenat Diagn* 2008;28:1167-1168.
- 44 Quagliarello JR, Passalacqua AM, Greco MA, Zinberg S, Young BK: Ballantyne's triple edema syndrome: prenatal diagnosis with ultrasound and maternal renal biopsy findings. *Am J Obstet Gynecol* 1978;132:580-581.
- 45 Duthie SJ, Walkinshaw SA: Parvovirus associated fetal hydrops: reversal of pregnancy-induced proteinuric hypertension by in utero fetal transfusion. *Br J Obstet Gynaecol* 1995;102:1011-1013.
- 46 Proust S, Philippe HJ, Paumier A, Joubert M, Boog G, Winer N: Mirror preeclampsia: Ballantyne's syndrome. Two cases (in French). *J Gynecol Obstet Biol Reprod (Paris)* 2006;35:270-274.
- 47 Mizrahi-Arnaud A, Wilkins Haug L, Marshall A, Silva V: Maternal mirror syndrome after in utero aortic valve dilation. A case report. *Fetal Diagn Ther* 2006;21:439-443.
- 48 Wurm D, Loffler G, Lindinger A, Gortner L: Congenital disorders of glycosylation type Ia as a cause of mirror syndrome. *J Perinatol* 2007;27:802-804.
- 49 Paternoster DM, Manganelli F, Minucci D, Nanhorgue KN, Memmo A, Bertoldini M, Nicolini U: Ballantyne syndrome: a case report. *Fetal Diagn Ther* 2006;21:92-95.
- 50 Valsky DV, Daum H, Yagel S: Reversal of mirror syndrome after prenatal treatment of Diamond-Blackfan anemia. *Prenat Diagn* 2007;27:1161-1164.
- 51 Allen AT, Dress AF, Moore WF: Mirror syndrome resulting from metastatic congenital neuroblastoma. *Int J Gynecol Pathol* 2007;26:310-312.
- 52 Gherman RB, Incerpi MH, Wing DA, Goodwin TM: Ballantyne syndrome: is placental ischemia the etiology? *J Matern Fetal Med* 1998;7:227-229.
- 53 Galimberti A, Jain S: Placental chorioangioma as a cause of maternal hydrops syndrome. *J Obstet Gynaecol* 2000;20:91.
- 54 Deurloo K, Devlieger R, Oepkes D: Maternal hydrops syndrome following successful treatment of fetal hydrops by shunting of bilateral hydrothorax. *Prenat Diagn* 2003;23:944-945.
- 55 Ibele A, Flake A, Shaaban A: Survival of a profoundly hydropic fetus with a sacrococcygeal teratoma delivered at 27 weeks of gestation for maternal mirror syndrome. *J Pediatr Surg* 2008;43:e17-e20.
- 56 Nakamura K, Itoh H, Sagawa N, Kakui K, Nakayama T, Yamada S, Fujii S: A case of peripartum cardiomyopathy with a transient increase of plasma interleukin-6 concentration occurred following mirror syndrome. *J Perinat Med* 2002;30:426-428.
- 57 Vidaeff AC, Pschirrer ER, Mastrobattista JM, Gilstrap LC 3rd, Ramin SM: Mirror syndrome. A case report. *J Reprod Med* 2002;47:770-774.
- 58 Vidaeff AC, Ross PJ, Livingston CK, Parks DH: Gigantomastia complicating mirror syndrome in pregnancy. *Obstet Gynecol* 2003;101:1139-1142.