



Cercek, A. et al. (2020) Mismatch repair-deficient rectal cancer and resistance to neoadjuvant chemotherapy. *Clinical Cancer Research*, 26(13), pp. 3271-3279.

There may be differences between this version and the published version. You are advised to consult the publisher's version if you wish to cite from it.

<http://eprints.gla.ac.uk/211027/>

Deposited on: 25 February 2020

Enlighten – Research publications by members of the University of Glasgow
<http://eprints.gla.ac.uk>

Research Article

Mismatch Repair Deficient Rectal Cancer and Resistance to Neoadjuvant Chemotherapy

Andrea Cercek,¹ Gustavo Dos Santos Fernandes,² Campbell S. D. Roxburgh,³ Karuna Ganesh,¹ Shu Y. Ng,⁴ Francisco Sanchez-Vega,⁵ Rona Yaeger,¹ Neil H. Segal,¹ Diane L. Reidy,¹ Anna Varghese,¹ Arnold J. Markowitz,¹ Chao Wu,⁶ Bryan C. Szeglin,⁶ Charles Sauve,⁶ Erin Salo-Mullen,¹ Christina Tran,¹ Zalak Patel,¹ Asha Krishnan,¹ Kaitlyn Tkachuk,¹ Garrett M. Nash,⁶ Jose G. Guillem,⁶ Philip B. Paty,⁶ Jinru Shia,⁷ Nikolaus Schultz,⁵ Julio Garcia-Aguilar,⁶ Luis A. Diaz Jr.,¹ Karyn Goodman,⁸ Leonard B. Saltz,¹ Martin R. Weiser,⁶ J. Joshua Smith,^{6,9} and Zsofia K. Stadler^{1*}

¹Department of Medicine, Memorial Sloan Kettering Cancer Center, New York. ²Division of Medical Oncology, Hospital Sírio-Libanês, Brasilia, Brazil. ³Institute of Cancer Sciences, College of Medical, Veterinary and Life Sciences, University of Glasgow, Glasgow, United Kingdom. ⁴Alfred Health Radiation Oncology, Victoria, Australia. ⁵Department of Epidemiology and Biostatistics, Memorial Sloan Kettering Cancer Center, New York. ⁶Department of Surgery, Memorial Sloan Kettering Cancer Center, New York. ⁷Department of Pathology, Memorial Sloan Kettering Cancer Center, New York. ⁸Department of Radiation Oncology, University of Colorado School of Medicine, Aurora, Colorado. ⁹Human Oncology and Pathogenesis Program, Memorial Sloan Kettering Cancer Center, New York.

Running title: dMMR Rectal Cancer and Resistance to Neoadjuvant Therapy

Keywords: Rectal cancer; Mismatch repair deficiency; Neoadjuvant chemotherapy; Lynch syndrome; Neoadjuvant chemoradiation

Financial Support

This research was funded in part through the Romeo Milio Lynch Syndrome Foundation, the Marie-Josée and Henry R. Kravis Center for Molecular Oncology, the Robert and Kate Niehaus Center for Inherited Cancer Genomics, the Fieldstone Family Fund, a Stand Up to Cancer Colorectal Cancer Dream Team Translational Research Grant (SU2C-AACR-DT22-17) (Stand Up to Cancer is a program of the Entertainment Industry Foundation. Research grants are administered by the American Association for Cancer Research, a scientific partner of SU2C), and the National Institutes of Health Cancer Center Support Grant P30 CA008748. J.J.S. is supported by the American Society of Colon and Rectal Surgeons Career Development Award, the Joel J. Roslyn Faculty Research Award, the American Society of Colon and Rectal Surgeons Limited Project Grant, the Memorial Sloan Kettering Department of Surgery Junior Faculty Award, and the John Wasserman Colon and Rectal Cancer Fund. J.J.S. is also supported by the Colorectal Cancer Alliance and the Chris4Life Research Award.

Corresponding Author

Zsofia K. Stadler, MD, Clinical Genetics & Gastrointestinal Oncology Service, Department of Medicine, Memorial Sloan Kettering Cancer Center, 1275 York Ave., New York, NY 10065. Phone: 646-888-4615. E-mail: stadlerz@mskcc.org

Disclosure

AC has received research funding from Seattle Genetics and serves on the advisory boards of Bayer, Proteus, and Amgen. GDSF has received advisory board fees from Roche, Bayer, and Celgene; reimbursement of meeting expenses from Roche; and research funding from Bristol-Myers Squibb, MSD, and Servier. NHS has received consulting fees from PsiOxus, PureTech Ventures, Amgen, GSK, CStone Pharmaceuticals, Synlogic, Pieris, AstraZeneca, Gritstone Oncology, TRM Oncology, Roche/Genentech, Bristol-Myers Squibb, Kyn Therapeutics, Aduro, and Boehringer Ingelheim. DLR serves on the advisory board of Novartis AAA and has received research funding from Merck and Ipsen Novartis and consulting fees from Lexicon. AV has received research funding from Lilly, Bristol-Myers Squibb, Verastem, BioMed Valley Discoveries, and Silenseed (AV's immediate family member has received research funding from Illumina and reimbursement of travel expenses from Roche). GMN has received meal reimbursement from Intuitive Surgical. JGA has received honoraria from Medtronic, Johnson & Johnson, and Intuitive Surgical. LAD serves on the board of directors of Personal Genome Diagnostics and Jounce Therapeutics; is a paid consultant to Personal Genome Diagnostics, 4Paws, and NeoPhore; is an uncompensated consultant for Merck; has received research funding from Merck; holds licensed patents (with Johns Hopkins University) related to technology for analysis of circulating tumor DNA and mismatch repair deficiency, which are associated with equity and royalty payments; and holds equity in Personal Genome Diagnostics, Jounce Therapeutics, Thrive Earlier Detection, and NeoPhore (LAD's spouse holds equity in Amgen). KG serves on the advisory board of RenovoRX. LBS has received research funding from Taiho. JJS has received travel reimbursement from Intuitive Surgical and has served as a clinical advisor to Guardant Health. ZKS's immediate family member serves as a consultant for Allergan, Adverum Biotechnologies, Alimera Sciences, BioMarin, Fortress Biotech, Genentech/Roche, Novartis, Optos, Regeneron, Regenxbio, and Spark Therapeutics. All remaining authors have no potential conflicts of interest to disclose.

Word count: 4140

Tables: 2

Figures: 3

Equal Contribution

A.C. and G.D.S.F. contributed equally.

Prior Presentation

Presented in part at the 2018 Annual Meeting of the European Society of Medical Oncology, Munich, Germany.

Translational Relevance

While treatment of locally advanced rectal cancer with neoadjuvant chemotherapy is efficacious and has become more commonplace, our study demonstrates resistance to standard neoadjuvant chemotherapy (fluorouracil/oxaliplatin), both clinically and *ex vivo*, in patients with locally advanced MMR-deficient (dMMR) rectal cancer. Thus, induction systemic chemotherapy in dMMR locally advanced rectal cancer should be pursued with caution. In comparison, dMMR rectal tumors appear to be sensitive to chemoradiation. The vast majority of dMMR rectal tumors occur in the setting of Lynch syndrome, with an enrichment of *MSH2* and *MSH6* germline mutations. To optimize treatment selection, all locally advanced rectal tumors should be screened for dMMR with subsequent genetic testing for Lynch syndrome in those with dMMR tumors.

ABSTRACT

Purpose: Evaluate response of mismatch repair deficient (dMMR) rectal cancer to neoadjuvant chemotherapy.

Patients and Methods: dMMR rectal tumors at Memorial Sloan Kettering were retrospectively reviewed for characteristics, treatment, and outcomes. Fifty dMMR rectal cancer patients were identified by immunohistochemistry and/or microsatellite instability analysis, with initial treatment response compared to a matched pMMR rectal cancer cohort. Germline and somatic mutation analyses were evaluated. Patient-derived dMMR rectal tumoroids were assessed for chemotherapy sensitivity.

Results: Of 21 patients receiving neoadjuvant chemotherapy (fluorouracil/oxaliplatin), 6 (29%) had progression of disease. In comparison, no progression was noted in 63 pMMR rectal tumors ($P = 0.0001$). Rectal cancer dMMR tumoroids reflected this resistance to chemotherapy. No genomic predictors of chemotherapy response were identified. Of 16 patients receiving chemoradiation, 13 (93%) experienced tumor downstaging; one patient had stable disease, comparable to 48 pMMR rectal cancers. Of 13 patients undergoing surgery, 12 (92%) had early-stage disease. Forty-two (84%) of the 50 patients tested positive for Lynch syndrome (LS) with enrichment of germline *MSH2* and *MSH6* mutations when compared to 193 LS-associated colon cancer patients (*MSH2*, 57% vs 36%; *MSH6*, 17% vs 9%; $P < .003$).

Conclusions: Over one-fourth of dMMR rectal tumors treated with neoadjuvant chemotherapy exhibited disease progression. Conversely, dMMR rectal tumors were sensitive to chemoradiation. MMR status should be performed upfront in all locally advanced rectal tumors with careful monitoring for response on neoadjuvant chemotherapy and genetic testing for LS in dMMR rectal cancer patients.

Introduction

Screening for deficient DNA mismatch repair (dMMR) is now recommended for all individuals with colorectal cancer (CRC) (1). While in colon cancers dMMR occurs in 15-20% of tumors, the prevalence of dMMR in rectal cancer is less frequent at ~10%. Microsatellite instability (MSI), the hallmark of dMMR tumors, may be caused by a germline mutation in one of the MMR genes (*MLH1*, *MSH2*, *MSH6*, *PMS2* and deletion of *EPCAM*), consistent with Lynch syndrome (LS)—or by epigenetic silencing of the *MLH1* promoter region (2). In colon cancer, dMMR tumors differ from MMR-proficient (pMMR) tumors in several aspects, including prognosis, response to treatment, and pattern of metastatic spread (3).

Initial clinical differences in dMMR tumors were described in adjuvant studies of resected early stage CRCs where tumors exhibiting microsatellite instability (MSI/dMMR) were noted to have a favorable prognosis but no improvement with adjuvant 5-fluorouracil (5-FU)-based chemotherapy (4-7). The prognostic impact of dMMR appears to diminish with advancing disease stage, and the addition oxaliplatin to fluoropyrimidines seems to be associated with a survival benefit in stage III MSI/dMMR CRC (8,9). In the metastatic setting, dMMR/MSI is considerably less common, occurring in 3% to 5% of cases and, while data are sparse and inconsistent, dMMR tumors appear to be less responsive to chemotherapy (10-12). but have a similar response to chemoradiation (13). More recently, checkpoint inhibitors have demonstrated impressive responses in metastatic dMMR CRCs, as well as in other dMMR tumors (14,15).

The prognostic and predictive role of MSI/dMMR in rectal cancer is not well characterized. In one study, dMMR rectal cancers appeared to have excellent prognosis with traditional trimodality therapy that included neoadjuvant chemoradiation, surgery, and adjuvant systemic chemotherapy (13). More recently, a shift in the treatment paradigm of locally advanced rectal cancer has resulted in a total

neoadjuvant approach (TNT), now incorporated into the National Comprehensive Cancer Network (NCCN) guidelines (1), wherein the sequencing of trimodality therapy is altered and is comprised of neoadjuvant systemic chemotherapy followed by chemoradiation and subsequent surgery (16-22). The efficacy of neoadjuvant systemic chemotherapy in dMMR rectal tumors, however, has not been investigated.

Patients and Methods

Patients

After Institutional Review Board (IRB) approval, we retrospectively reviewed our Center's clinical cancer database to identify patients with a diagnosis of dMMR CRC from 2003-2018. This study was conducted in accordance with the Declaration of Helsinki and all applicable laws. LS was defined as patients with a likely pathogenic or pathogenic germline mutation in a MMR gene. dMMR was determined by immunohistochemistry and/or MSI testing. MSI testing was performed either using a standard PCR-based method or using targeted next-generation sequencing via MSISensor, a computational algorithm that analyzes sequencing reads at designated microsatellite regions in tumor-normal pairs (23). The distribution of germline mutations in the MMR genes was compared between LS-associated colon and LS-associated rectal cancer patients.

Among dMMR or MSI-high CRCs, we then identified all those with rectal cancer as defined in the Supplement (22). Patients were divided into three groups based on initial treatment received. Treatment choice was dependent on staging, with clinical stage I patients proceeding directly to surgery. Patients with locally advanced rectal cancer underwent chemoradiotherapy prior to 2012 and TNT after 2012, reflecting the changes in institutional clinical practice after the acceptance of TNT as initial treatment.

Neoadjuvant Regimens

The TNT regimen included mFOLFOX which is described in the Supplement (24-26). Chemoradiation was administered as initial neoadjuvant therapy or commenced 2-4 weeks after completing neoadjuvant chemotherapy. Details of chemoradiation administration and scheduling are in the Supplement.

Response to Neoadjuvant Chemotherapy or Neoadjuvant Chemoradiation

To assess the efficacy of neoadjuvant chemotherapy, we evaluated patients who underwent pre- and post-chemotherapy (before chemoradiation initiation) staging with rectal MRI and/or endorectal ultrasound and digital examination. Most, but not all, patients received all modalities of evaluation. For chemoradiation response, pathology specimens were evaluated for partial or complete pathologic response according to published criteria (27).

Germline Analyses

Clinical germline genetic analyses included full gene sequencing and multiplex ligation-dependent probe amplification analysis for large genomic rearrangement of the implicated DNA MMR gene(s) according to immunohistochemical staining patterns. For MLH1/PMS2 deficient tumors, germline analysis included the *PMS2* and *MLH1* genes while for MSH2/MSH6 deficient tumors, *MSH2* and *MSH6* were analyzed. For MSH2/MSH6 deficient tumors, once commercially available, 3' deletions of the *EPCAM* gene and *MSH2* exons 1-7 inversion analysis were included.

Molecular Analyses

Archival formalin-fixed paraffin-embedded (FFPE) samples of 16 patients (18 samples) were analyzed by using an on-site cancer-associated gene bait capture, next generation sequencing (NGS) assay MSK-

IMPACT, using a 341 to 468 gene-panel. The assay is capable of detecting mutations, small insertions and deletions, copy number alterations, and select structural rearrangements (28). Tumor tissue samples were obtained either pre or post treatment at the time of surgical resection or at development of metastatic disease. All subjects undergoing this molecular analysis via MSK-IMPACT provided written consent in the setting of a prospective IRB-approved institutional protocol.

Comparison with Historical Controls

Outcomes for the dMMR patients who received upfront chemotherapy or upfront chemoradiation were compared with outcomes for pMMR rectal cancer patients who received the same treatment modality matched for pre-treatment tumor and lymph node staging, based on our previously published study (17), by using a 3:1 pairing (upfront chemotherapy, 21 dMMR:63 pMMR; upfront chemoradiation, 16 dMMR:48 pMMR). The pairings were selected chronologically from our existing database based upon previously published data (17). Baseline demographics were compared between the pMMR and dMMR cases. The spectrum of germline MMR mutations in LS-associated rectal cancer (n=42) was compared to all LS-associated colon cancer patients (n=193) using the Clinical Genetics LS database, which captures all patients undergoing germline testing for LS under an MSK IRB-approved protocol since 2004.

Tumoroids

Pre-treatment tumoroids were derived as described (29,30) from fresh rectal tumor samples and embedded in Matrigel. Tumoroids were validated by comparison to the rectal specimens from which they were derived via immunohistochemistry, targeted gene sequencing, and MMR staining to verify retention of alterations present in the original tumor. Drug treatments with FOLFOX were conducted as reported (29) with cell viability assessed using the CellTiter Glo assay (Promega, Madison Wi, USA) following kit protocol. Details on tumoroid treatment and analyses are provided in the Supplementary

Methods and have been previously published (29). All subjects from whom tumor tissue was used for tumoroid analysis provided written consent in the setting of a prospective IRB-approved institutional protocol.

Statistical Analysis

Continuous variables were compared using a two-tailed *t* test. Categorical variables were compared using χ^2 statistics or Fisher's exact test, for limited sample sizes. *P* values < 0.05 were considered statistically significant. Tumoroid IC50 values with 95% confidence intervals were calculated as described in the Supplementary Methods and as previously described (29). Non-overlapping 95% confidence intervals were used to determine statistical significance with *P* < 0.05 (31).

Results

Patient and Tumor Characteristics

Fifty patients met criteria of dMMR and/or MSI rectal adenocarcinoma with 25 having had IHC alone, 7 MSI alone, and 18 having both IHC and MSI analysis. At diagnosis, 38 (76%) had locally advanced disease (stage II or III), 3 (6%) had metastatic disease, and 8 (16%) had stage I disease; one patient's disease stage was unknown. Of the 50 patients, 21 (42%) received chemotherapy with fluorouracil and oxaliplatin as initial treatment, 16 (32%) received chemoradiation as initial treatment, and 13 (26%) proceeded directly to surgery (Fig 2a). The patients' clinical and pathological characteristics are summarized in **Table 1**.

Germline Genetic Characteristics

Of 50 patients, 42 (84%) had a LS-associated germline mutation in a MMR gene (**Fig 1a**). In LS patients, the prevalence of germline *MSH2* and *MSH6* mutations was significantly higher in the rectal (n=42) versus colon (n=193) cancer patients (rectal vs colon: *MSH2*: 57% vs 36%; *MSH6*: 17% vs 9%; *P*-value <0.003) (**Fig 1b**). The mean age at rectal cancer diagnosis in the LS patients (40.1 years) was equivalent to those without a germline mutation (45.6 years). Eleven (26%) of LS patients had a prior primary-cancer diagnosis and 13 (31%) developed metachronous cancers. No prior or metachronous cancers were observed in the non-LS patients. The mechanism of dMMR in the 8 non-LS patients was found to be *MLH1*-promoter hypermethylation in 2 cases, double somatic mutation in 1 case, and unknown in 5 cases.

Initial Treatment with Neoadjuvant Chemotherapy

Twenty-one patients, all meeting criteria for evaluation of response to induction chemotherapy, underwent pre- and post-chemotherapy staging with rectal MRI and/or endorectal ultrasound prior to chemoradiation(**Fig 2b**). Nineteen had locally advanced and two stage IV disease. Six (29%) of the 21 patients had local disease progression, with symptoms including change in stool caliber (4) and return of rectal pain (2). Progression was confirmed by rectal MRI (4), CT (1), or endoscopic evaluation(1). Five of the six patients had LS with three harboring an *MSH6* mutation. In the remaining 15 patients, tumor response was detected by MRI or endorectal examination.

Seventeen of 21 patients who received initial chemotherapy were evaluable for response to subsequent neoadjuvant chemoradiation. Four (24%) of the 17 patients had a complete response (3 with pathological complete response, 1 clinical complete response), 11 (65%) had tumor downstaging (T, N, or both), 1 (6%) had stable disease, and 1 (6%) was upstaged. Of the four (19%) patients deemed not evaluable, one had inadequate baseline imaging, one had metastatic disease prior to treatment

initiation, and two did not receive chemoradiation (one declined due to fertility concerns). Of the two patients who did not receive chemoradiation, one had a complete pathologic response to FOLFOX and the other had disease progression with upstaging on pathologic examination. Details of patient TNM staging, treatment, and outcomes are outlined in **Fig 2b**.

Eighteen (86%) of the 21 patients underwent total mesorectal excision. Of the three patients (14%) who did not undergo surgery, one had a clinical complete response and opted for watchful waiting, one had local disease progression while on FOLFOX, and one had metastatic progression in the peritoneum while on FOLFOX.

Of the 6 (29%) patients whose disease progressed during induction FOLFOX therapy, four received neoadjuvant chemoradiation resulting in downstaging (2) and stable disease (2). The fifth patient did not receive chemoradiation due to peritoneal disease progression. The sixth patient declined chemoradiation for fertility preservation; this patient received three months of adjuvant FOLFIRI but experienced rapid progression of disease in the liver and peritoneum with eventual, long-term response to a checkpoint inhibitor (CPI) (**Fig 2b**). None of these six patients had a prior cancer diagnosis nor received chemotherapy prior to the diagnosis of rectal cancer.

Initial Treatment with Neoadjuvant Chemoradiation

Of 16 patients treated with initial neoadjuvant chemoradiation, 14 were evaluable for response and 13 (93%) experienced tumor downstaging, 12 by pathological findings. Two patients (14%) experienced a pathologic complete response. Two patients did not undergo surgery due to complete clinical response. One patient did not undergo surgery due to synchronous liver disease. Two patients developed disease

recurrence and received immunotherapy with checkpoint inhibitors. The treatment course and outcome of these patients is outlined in **Fig 2c**.

Initial Treatment with Surgical Resection

Thirteen patients underwent upfront surgical resection; 8 due to clinical stage I disease and five for borderline stage I-II disease. The 12 lymph-node negative patients remain disease free, while 1 patient developed disease recurrence. Three received adjuvant chemoradiation. All patients are alive with a median follow up of 60 months (range 25-304).

Comparison of Neoadjuvant Therapies with pMMR Historical Controls

We next compared our dMMR rectal cancer patients who received upfront chemotherapy with our recently published pMMR rectal cancer cohort receiving the same neoadjuvant treatment (17). We sequentially evaluated 63 (3:1 pairing) pMMR patients and tabulated clinical and pathological characteristics and evaluated for response using the criteria described above. Demographics for both the pMMR and dMMR cohorts are outlined in Supplementary Table 1. As expected, the dMMR rectal cancer patients reflect a younger cohort due to the presence of Lynch syndrome. However, no significant differences were noted in other baseline demographics including gender, race, or tumor grade. In contrast to dMMR patients where 29% progressed on FOLFOX, none of the pMMR patients progressed on neoadjuvant chemotherapy and 89% had tumor downstaging (P -value = 0.0001) (**Table 2**). In a similar fashion, we compared dMMR rectal cancer patients receiving upfront chemoradiation to 48 (3:1 pairing) pMMR published historical controls. Of baseline demographics, again, only age was different in the pMMR and dMMR upfront chemoradiation groups (Supplementary Table 1). The pathologic response rate of 13% in the dMMR group was similar to the 17% in the pMMR cohort (**Table 2**).

Recurrent and Persistent Disease

Of the 50 patients, 9 experienced disease progression or recurrent disease. Six patients in the neoadjuvant chemotherapy cohort, two in the chemoradiation cohort, and one in the surgical cohort. Eight patients were treated with CPIs for persistent (2), locally recurrent (5), or metastatic disease (1). Remarkably, seven (88%) had significant response radiographically and all but one are alive with a mean follow up time from initiation of immunotherapy of 13 months (9-44 months). One patient with local disease recurrence had significant tumor response on a CPI, which has been sustained for >1 year (**Fig 3a**). One patient developed rapidly progressive disease recurrence and died three weeks after receiving the first cycle of CPI (**Fig 2a**). One patient who was treated with upfront surgery developed a recurrence in the liver and underwent curative liver resection.

Molecular Analyses

Sixteen patients who received neoadjuvant chemotherapy as initial treatment had tissue samples available for genomic analyses. All but one patient had tumor sequencing performed on samples obtained after treatment from the resected tumor (n=11), a post treatment biopsy (n=1) or from a site of metastatic recurrence (n=4). No significant genomic differences, including tumor mutational burden, were found between responders to chemotherapy and non-responders. There were no BRAF mutations in the eight non-LS patients. (**Fig 3b**).

Proof of principle chemosensitivity assay in patient-derived rectal cancer tumoroids

To investigate the association between MMR status and chemoresistance in a biological model, pre-treatment rectal cancer tumoroids were derived from pMMR and dMMR rectal tumors as previously described (29). We tested the tumoroids for *ex vivo* sensitivity to FOLFOX to determine if our clinical observations would be reflected in the patient-derived tumoroids (29). Indeed, in this proof of principle

assay, the dMMR rectal cancer tumoroids demonstrated significant resistance to FOLFOX compared to pMMR tumoroids (IC50 = 1.97 [95% CI 1.49-2.538] vs. 5.02 [95% CI 3.86-6.63], respectively; **Fig 3c**).

Discussion

Colon tumors exhibiting dMMR/MSI are biologically and clinically distinct; however, differences resulting from dMMR/MSI status specific to rectal cancers are not well-defined. In our study, 29% of dMMR/MSI locally advanced rectal tumors had disease progression on neoadjuvant chemotherapy, an alarmingly high rate compared to no progression in our large cohort of pMMR rectal tumors as well as published data from prospective studies of neoadjuvant therapy in locally advanced rectal cancer (32-34). With the recent shift in the delivery of systematic chemotherapy in locally advanced rectal cancers from the adjuvant to the neoadjuvant setting (18-20,22), this observation has important clinical implications.

Historically, dMMR/MSI has been both a prognostic and a predictive marker with dMMR/MSI portending a better prognosis in early-stage colorectal tumors, yet limited benefit from fluoropyrimidines (6,35,36). As the backbone of systemic therapy, fluoropyrimidine resistance raises concern for primary chemotherapy resistance in dMMR CRC patients. In fact, in the metastatic setting, small but well analyzed retrospective data consistently suggest that dMMR CRCs achieve inferior progression-free survival and response rates to chemotherapy compared to pMMR tumors (13). Further supporting our clinical findings are emerging data from the FoxTrot neoadjuvant colon cancer study, demonstrating a significantly worse response to neoadjuvant FOLFOX in dMMR versus pMMR colon tumors, with 75% of dMMR colon tumors exhibiting no pathologic response to chemotherapy. As in our cohort, one dMMR tumor had a complete pathologic response indicating that resistance is not universal (37).

Studies of dMMR/MSI as a biomarker of radiation response have failed to demonstrate its predictive utility (38-40). Our finding, of a 93% response to neoadjuvant chemoradiation, is analogous to previously published dMMR rectal tumors (13) and similar to pMMR rectal cohorts (17). Notably, some patients with progression of disease on neoadjuvant chemotherapy achieved a subsequent response to chemoradiation, suggesting that at least a fraction of such patients may be salvaged with chemoradiation. However, as many locally advanced rectal cancer patients have bulky and clinically symptomatic tumors, prompt local control with selection of the optimal first-line treatment is imperative.

While our somatic genomic analysis of dMMR rectal tumors did not identify any significant differences in genomic profiles among chemotherapy responders and non-responders, utilizing tumoroids derived from LS-associated dMMR rectal tumors, we were able to replicate the observed clinical resistance to FOLFOX. Additionally, our prior work has shown that dMMR rectal cancer tumoroids are exquisitely sensitive to radiotherapy (29). These patient-derived biological models of rectal cancer provide the means to study mechanisms of resistance to chemotherapy in real-time and could also help inform if an early change in therapy is indicated.

LS comprised a very high proportion (84%) of our dMMR rectal cancer patients, similar to the series by de Rosa et al (13). In contrast, approximately two-thirds of dMMR/MSI colon cancers are driven by epigenetic factors, most commonly *MLH1* promoter hypermethylation (41,42). We also found that the distribution of germline MMR mutations varies in rectal versus colon cancer, with *MSH2* and *MSH6* mutations accounting for nearly 75% versus only 45% of LS-associated rectal cancer and colon cancer patients, respectively. Most studies have consistently demonstrated that CRC is more prevalent in *MLH1* than *MSH2* mutations carriers (2,16,17,25). As the majority of dMMR/MSI cancers arise in the proximal colon, and most prior studies have analyzed dMMR CRCs without distinguishing tumor location

(43,44), the high prevalence of LS in dMMR rectal cancer may have inadvertently been masked. With increasing recognition of the biological importance of CRC sub-site stratification (45,46), whether dMMR rectal tumors portend a different tumor biology from right-sided dMMR tumors remains to be elucidated. Nonetheless, while a rare entity, the diagnosis of a dMMR rectal cancer in a patient should prompt referral for genetic testing and counseling given implications for cancer surveillance and risk-reduction measures.

In our analysis, patient derived organoid (PDO) models replicated the clinical resistance to FOLFOX chemotherapy in select dMMR/MSI cases. Our group, as well as others, have demonstrated the feasibility of establishing PDOs in evaluating sensitivity to therapy (29,47,48). In locally advanced rectal cancer, PDOs may serve as an important test of sensitivity to other agents in select patients including chemoradiation (29) and irinotecan-based therapies (47). Use of organoid models as ‘oracles of response prediction’ in dMMR and pMMR rectal cancers still requires additional validation and prospective testing, but our data suggest that it is possible and provides the first evidence of this potential utility in dMMR rectal patients.

Universal tumor testing for markers of MMR deficiency is now endorsed for all CRC patients (1). However, our study also suggests that, in rectal cancer, MMR status should be determined *prior* to treatment initiation to allow for optimal selection of first-line treatment. Studies have demonstrated excellent concordance of IHC staining in matched biopsy and CRC resection samples (49), as well as concern that neoadjuvant treatment, especially chemoradiation, may cause inaccuracies in IHC analysis (50). As such, if tissue sample is inadequate from baseline colonoscopy biopsy, a repeat sampling of the rectal tumor prior to treatment initiation is appropriate.

The inherent limitations of our study include its retrospective design, and the heterogeneity of disease stages and subsequent treatment approaches. However, we were able to separate treatment

modalities and evaluate response independently with comparison to unselected locally advanced pMMR rectal cancer patients who were receiving treatment at the same time, utilizing identical modalities, at the same institution. As dMMR rectal cancer is rare, prospective randomized studies are not feasible; however, large national studies like the PROSPECT trial (NCI 2012-00234) in locally advanced rectal cancer may help shed further light on the impact of MMR status on treatment response. Further studies of the etiology of chemoresistance via RNA analysis and epigenetic modification using dMMR tumors, organoids, and/or cell lines is clearly warranted. Furthermore, we noted a strong sustained response to CPIs in our patients with disease progression or recurrence, in line with the success of immunotherapy in advanced dMMR solid tumors. Trials of immunotherapy in early-stage dMMR colon cancer (ATOMIC NCT02912559) and in locally advanced rectal cancers are on-going or planned.

In conclusion, our analyses demonstrate that induction chemotherapy is far less efficacious in dMMR than in pMMR rectal cancer, with over one-fourth of patients progressing while on induction chemotherapy. As such, our data strongly suggests that in dMMR rectal cancer patients, induction systemic chemotherapy should be undertaken with careful monitoring for tumor response, with close assessment of clinical symptoms. If concern is raised, prompt proctosigmoidoscopy or rectal MRI should be performed to evaluate for response and ensure a timely transition to chemoradiation. Additionally, given the importance of MMR status in the optimal selection of first-line treatment for locally advanced rectal cancer patients, MMR assessment should be performed at the time of rectal cancer diagnosis using biopsy samples, via IHC staining or MSI analysis, with subsequent germline genetic analysis in all those identified to harbor a dMMR rectal tumor.

REFERENCES

1. Benson AB, 3rd, Venook AP, Cederquist L, Chan E, Chen YJ, Cooper HS, *et al.* Colon Cancer, Version 1.2017, NCCN Clinical Practice Guidelines in Oncology. *J Natl Compr Canc Netw* **2017**;15(3):370-98.
2. Herman JG, Umar A, Polyak K, Graff JR, Ahuja N, Issa JP, *et al.* Incidence and functional consequences of hMLH1 promoter hypermethylation in colorectal carcinoma. *Proc Natl Acad Sci U S A* **1998**;95(12):6870-5.
3. Tran B, Kopetz S, Tie J, Gibbs P, Jiang ZQ, Lieu CH, *et al.* Impact of BRAF mutation and microsatellite instability on the pattern of metastatic spread and prognosis in metastatic colorectal cancer. *Cancer* **2011**;117(20):4623-32.
4. Bertagnolli MM, Redston M, Compton CC, Niedzwiecki D, Mayer RJ, Goldberg RM, *et al.* Microsatellite instability and loss of heterozygosity at chromosomal location 18q: prospective evaluation of biomarkers for stages II and III colon cancer--a study of CALGB 9581 and 89803. *J Clin Oncol* **2011**;29(23):3153-62.
5. Merok MA, Ahlquist T, Royrvik EC, Tufteland KF, Hektoen M, Sjo OH, *et al.* Microsatellite instability has a positive prognostic impact on stage II colorectal cancer after complete resection: results from a large, consecutive Norwegian series. *Ann Oncol* **2013**;24(5):1274-82.
6. Sargent DJ, Marsoni S, Monges G, Thibodeau SN, Labianca R, Hamilton SR, *et al.* Defective mismatch repair as a predictive marker for lack of efficacy of fluorouracil-based adjuvant therapy in colon cancer. *J Clin Oncol* **2010**;28(20):3219-26.
7. Sargent DJ, Marsoni S, Thibodeau SN, Labianca R, Hamilton SR, Torri V, *et al.* Confirmation of deficient mismatch repair (dMMR) as a predictive marker for lack of benefit from 5-FU based chemotherapy in stage II and III colon cancer (CC): A pooled molecular reanalysis of randomized chemotherapy trials. **2008**;26(15_suppl):4008-.
8. Gavin PG, Colangelo LH, Fumagalli D, Tanaka N, Remillard MY, Yothers G, *et al.* Mutation profiling and microsatellite instability in stage II and III colon cancer: an assessment of their prognostic and oxaliplatin predictive value. *Clin Cancer Res* **2012**;18(23):6531-41.
9. Tougeron D, Mouillet G, Trouilloud I, Lecomte T, Coriat R, Aparicio T, *et al.* Efficacy of Adjuvant Chemotherapy in Colon Cancer With Microsatellite Instability: A Large Multicenter AGEO Study. *J Natl Cancer Inst* **2016**;108(7).
10. Brueckl WM, Moesch C, Brabletz T, Koebnick C, Riedel C, Jung A, *et al.* Relationship between microsatellite instability, response and survival in palliative patients with colorectal cancer undergoing first-line chemotherapy. *Anticancer Res* **2003**;23(2c):1773-7.
11. Koopman M, Kortman GA, Mekenkamp L, Ligtenberg MJ, Hoogerbrugge N, Antonini NF, *et al.* Deficient mismatch repair system in patients with sporadic advanced colorectal cancer. *Br J Cancer* **2009**;100(2):266-73.
12. Alex AK, Siqueira S, Coudry R, Santos J, Alves M, Hoff PM, *et al.* Response to Chemotherapy and Prognosis in Metastatic Colorectal Cancer With DNA Deficient Mismatch Repair. *Clin Colorectal Cancer* **2017**;16(3):228-39.
13. de Rosa N, Rodriguez-Bigas MA, Chang GJ, Veerapong J, Borrás E, Krishnan S, *et al.* DNA Mismatch Repair Deficiency in Rectal Cancer: Benchmarking Its Impact on Prognosis, Neoadjuvant Response Prediction, and Clinical Cancer Genetics. *J Clin Oncol* **2016**;34(25):3039-46.
14. Overman MJ, McDermott R, Leach JL, Lonardi S, Lenz HJ, Morse MA, *et al.* Nivolumab in patients with metastatic DNA mismatch repair-deficient or microsatellite instability-high colorectal cancer (CheckMate 142): an open-label, multicentre, phase 2 study. *Lancet Oncol* **2017**;18(9):1182-91.

15. Le DT, Uram JN, Wang H, Bartlett BR, Kemberling H, Eyring AD, *et al.* PD-1 Blockade in Tumors with Mismatch-Repair Deficiency. *N Engl J Med* **2015**;372(26):2509-20.
16. Cercek A, Goodman KA, Hajj C, Weisberger E, Segal NH, Reidy-Lagunes DL, *et al.* Neoadjuvant chemotherapy first, followed by chemoradiation and then surgery, in the management of locally advanced rectal cancer. *J Natl Compr Canc Netw* **2014**;12(4):513-9.
17. Cercek A, Roxburgh CSD, Strombom P, Smith JJ, Temple LKF, Nash GM, *et al.* Adoption of Total Neoadjuvant Therapy for Locally Advanced Rectal Cancer. *JAMA Oncol* **2018**;4(6):e180071.
18. Habr-Gama A, Perez RO, Nadalin W, Sabbaga J, Ribeiro U, Jr., Silva e Sousa AH, Jr., *et al.* Operative versus nonoperative treatment for stage 0 distal rectal cancer following chemoradiation therapy: long-term results. *Ann Surg* **2004**;240(4):711-7; discussion 7-8.
19. Habr-Gama A, Sabbaga J, Gama-Rodrigues J, Sao Juliao GP, Proscurshim I, Bailao Aguilar P, *et al.* Watch and wait approach following extended neoadjuvant chemoradiation for distal rectal cancer: are we getting closer to anal cancer management? *Dis Colon Rectum* **2013**;56(10):1109-17.
20. Heald RJ, Ryall RD. Recurrence and survival after total mesorectal excision for rectal cancer. *Lancet* **1986**;1(8496):1479-82.
21. Hong TS, Ryan DP. Total Neoadjuvant Therapy for Locally Advanced Rectal Cancer-The New Standard of Care? *JAMA Oncol* **2018**;4(6):e180070.
22. Sauer R, Becker H, Hohenberger W, Rodel C, Wittekind C, Fietkau R, *et al.* Preoperative versus postoperative chemoradiotherapy for rectal cancer. *N Engl J Med* **2004**;351(17):1731-40.
23. Middha S, Zhang L, Nafa K, Jayakumaran G, Wong D, Kim HR, *et al.* Reliable Pan-Cancer Microsatellite Instability Assessment by Using Targeted Next-Generation Sequencing Data. *JCO Precis Oncol* **2017**;2017.
24. Haller DG, Tabernero J, Maroun J, de Braud F, Price T, Van Cutsem E, *et al.* Capecitabine plus oxaliplatin compared with fluorouracil and folinic acid as adjuvant therapy for stage III colon cancer. *J Clin Oncol* **2011**;29(11):1465-71.
25. Schmoll HJ, Twelves C, Sun W, O'Connell MJ, Cartwright T, McKenna E, *et al.* Effect of adjuvant capecitabine or fluorouracil, with or without oxaliplatin, on survival outcomes in stage III colon cancer and the effect of oxaliplatin on post-relapse survival: a pooled analysis of individual patient data from four randomised controlled trials. *Lancet Oncol* **2014**;15(13):1481-92.
26. Zhao L, Liu R, Zhang Z, Li T, Li F, Liu H, *et al.* Oxaliplatin/fluorouracil-based adjuvant chemotherapy for locally advanced rectal cancer after neoadjuvant chemoradiotherapy and surgery: a systematic review and meta-analysis of randomized controlled trials. *Colorectal Dis* **2016**;18(8):763-72.
27. Trakarnsanga A, Gonen M, Shia J, Nash GM, Temple LK, Guillem JG, *et al.* Comparison of tumor regression grade systems for locally advanced rectal cancer after multimodality treatment. *J Natl Cancer Inst* **2014**;106(10).
28. Middha S, Zhang L, Nafa K, Jayakumaran G, Wong D, Kim HR, *et al.* Reliable Pan-Cancer Microsatellite Instability Assessment by Using Targeted Next-Generation Sequencing Data. **2017**(1):1-17.
29. Ganesh K, Wu C, O'Rourke KP, Szeglin BC, Zheng Y, Sauve CG, *et al.* A rectal cancer organoid platform to study individual responses to chemoradiation. *Nat Med* **2019**;25(10):1607-14.
30. Sato T, Stange DE, Ferrante M, Vries RG, Van Es JH, Van den Brink S, *et al.* Long-term expansion of epithelial organoids from human colon, adenoma, adenocarcinoma, and Barrett's epithelium. *Gastroenterology* **2011**;141(5):1762-72.
31. Cumming G. Inference by eye: reading the overlap of independent confidence intervals. *Stat Med* **2009**;28(2):205-20.

32. Schrag D, Weiser MR, Goodman KA, Gonen M, Hollywood E, Cercek A, *et al.* Neoadjuvant chemotherapy without routine use of radiation therapy for patients with locally advanced rectal cancer: a pilot trial. *J Clin Oncol* **2014**;32(6):513-8.
33. Fernandez-Martos C, Pericay C, Aparicio J, Salud A, Safont M, Massuti B, *et al.* Phase II, randomized study of concomitant chemoradiotherapy followed by surgery and adjuvant capecitabine plus oxaliplatin (CAPOX) compared with induction CAPOX followed by concomitant chemoradiotherapy and surgery in magnetic resonance imaging-defined, locally advanced rectal cancer: Grupo cancer de recto 3 study. *J Clin Oncol* **2010**;28(5):859-65.
34. Chua YJ, Barbachano Y, Cunningham D, Oates JR, Brown G, Wotherspoon A, *et al.* Neoadjuvant capecitabine and oxaliplatin before chemoradiotherapy and total mesorectal excision in MRI-defined poor-risk rectal cancer: a phase 2 trial. *Lancet Oncol* **2010**;11(3):241-8.
35. Lothe RA, Peltomaki P, Meling GI, Aaltonen LA, Nystrom-Lahti M, Pylkkanen L, *et al.* Genomic instability in colorectal cancer: relationship to clinicopathological variables and family history. *Cancer Res* **1993**;53(24):5849-52.
36. Thibodeau SN, Bren G, Schaid D. Microsatellite instability in cancer of the proximal colon. *Science* **1993**;260(5109):816-9.
37. Seymour MT, D M. FOxTROT: an international randomised controlled trial in 1052 patients evaluating neoadjuvant chemotherapy for colon cancer. *J Clin Oncol* **2019**;37.
38. Shin JS, Tut TG, Yang T, Lee CS. Radiotherapy response in microsatellite instability related rectal cancer. *Korean J Pathol* **2013**;47(1):1-8.
39. Charara M, Edmonston TB, Burkholder S, Walters R, Anne P, Mitchell E, *et al.* Microsatellite status and cell cycle associated markers in rectal cancer patients undergoing a combined regimen of 5-FU and CPT-11 chemotherapy and radiotherapy. *Anticancer Res* **2004**;24(5b):3161-7.
40. Qiu H, Sirivongs P, Rothenberger M, Rothenberger DA, Garcia-Aguilar J. Molecular prognostic factors in rectal cancer treated by radiation and surgery. *Dis Colon Rectum* **2000**;43(4):451-9.
41. Kane MF, Loda M, Gaida GM, Lipman J, Mishra R, Goldman H, *et al.* Methylation of the hMLH1 promoter correlates with lack of expression of hMLH1 in sporadic colon tumors and mismatch repair-defective human tumor cell lines. *Cancer Res* **1997**;57(5):808-11.
42. Hampel H, Frankel WL, Martin E, Arnold M, Khanduja K, Kuebler P, *et al.* Feasibility of screening for Lynch syndrome among patients with colorectal cancer. *J Clin Oncol* **2008**;26(35):5783-8.
43. Hong SP, Min BS, Kim TI, Cheon JH, Kim NK, Kim H, *et al.* The differential impact of microsatellite instability as a marker of prognosis and tumour response between colon cancer and rectal cancer. *Eur J Cancer* **2012**;48(8):1235-43.
44. Samowitz WS, Curtin K, Wolff RK, Tripp SR, Caan BJ, Slattery ML. Microsatellite instability and survival in rectal cancer. *Cancer Causes Control* **2009**;20(9):1763-8.
45. Guinney J, Dienstmann R, Wang X, de Reynies A, Schlicker A, Sonesson C, *et al.* The consensus molecular subtypes of colorectal cancer. *Nat Med* **2015**;21(11):1350-6.
46. Riihimaki M, Hemminki A, Sundquist J, Hemminki K. Patterns of metastasis in colon and rectal cancer. *Sci Rep* **2016**;6:29765.
47. Ooft SN, Weeber F, Dijkstra KK, McLean CM, Kaing S, van Werkhoven E, *et al.* Patient-derived organoids can predict response to chemotherapy in metastatic colorectal cancer patients. *Sci Transl Med* **2019**;11(513).
48. Yao Y, Xu X, Yang L, Zhu J, Wan J, Shen L, *et al.* Patient-Derived Organoids Predict Chemoradiation Responses of Locally Advanced Rectal Cancer. *Cell Stem Cell* **2020**;26(1):17-26.e6.

49. Shia J, Stadler Z, Weiser MR, Rentz M, Gonen M, Tang LH, *et al.* Immunohistochemical staining for DNA mismatch repair proteins in intestinal tract carcinoma: how reliable are biopsy samples? *Am J Surg Pathol* **2011**;35(3):447-54.
50. Vilkin A, Halpern M, Morgenstern S, Brazovski E, Gingold-Belfer R, Boltin D, *et al.* How reliable is immunohistochemical staining for DNA mismatch repair proteins performed after neoadjuvant chemoradiation? *Hum Pathol* **2014**;45(10):2029-36.

TABLE 1. Patient Characteristics

Characteristic	No. (%) of Patients (n = 50)
Age, median (range)	39 (23-83)
Sex	
Male	34 (68)
Female	16 (32)
Race	
White	39 (78)
Hispanic	3 (6)
Black	1 (2)
Asian	5 (10)
Ashkenazi Jewish	9 (18)
Not declared	2 (4)
Histology	
Well differentiated	0 (0)
Moderately differentiated	37 (74)
Poorly differentiated	10 (20)
Not available	3 (6)
Clinical stage at diagnosis	
I	8 (16)
II	8 (16)
III	30 (60)
IV	3 (6)
Not available	1 (2)
First treatment for rectal cancer	
Surgery	13 (26)
Chemoradiation	16 (32)
FOLFOX chemotherapy	21 (42)
dMMR patients with Lynch Syndrome	42 (84)

TABLE 2. Outcomes in Rectal Cancer Patients with dMMR or pMMR

Outcome	No. of Patients (%)	
	dMMR	pMMR
FOLFOX as initial treatment	<i>n = 21</i>	<i>n = 63</i>
Progression of disease	6 (29)	0
Response or stable disease	15 (71)	63 (100)
Chemoradiation as initial treatment	<i>n = 16</i>	<i>n = 48</i>
Progression of disease	0	0
Complete pathologic response	2 (13)	8 (17)

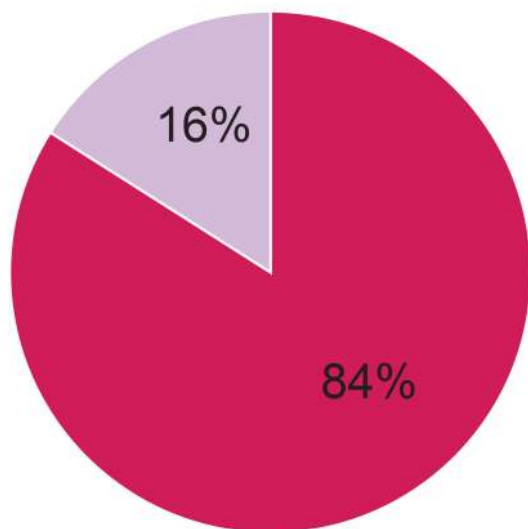
Figure 1. Germline mutations in patients with Lynch syndrome.

Figure 2. Overall study flow is demonstrated in (A). Patient characteristics, treatments, and outcomes for patients who received neoadjuvant FOLFOX chemotherapy (B) or chemoradiotherapy (ChemoRT) (C) as initial treatment. 5-FU, fluorouracil; CR, complete response; F/U, follow-up; NED, no evidence of disease; pCR, pathological complete response; PD, progression of disease; PR, partial response; SD, stable disease.

Figure 3. (A) Endoscopic imaging of a recurrent dMMR rectal adenocarcinoma pre and 5 and 8 months post treatment with pembrolizumab. (B) Oncoprint and tumor mutational burden in FOLFOX responders and non-responders with dMMR rectal adenocarcinoma. (C) Tumoroid ex vivo sensitivity to FOLFOX demonstrating relative sensitivity to FOLFOX in pMMR tumoroids and resistance in dMMR tumoroids with calculated IC50 values reported as 95% confidence intervals (IC50 = 1.97 [95% CI 1.49-2.538] vs. 5.02 [95% CI 3.86-6.63], respectively; at left). At right, representative brightfield microscopy of tumoroids in 3D culture both pre (top micrographs) and post (bottom micrographs) treatment with FOLFOX chemotherapy from which the IC50 data was derived. Decreased confluence demonstrates relative, qualitative resistance to FOLFOX treatment in dMMR tumoroids compared with pMMR tumoroids.

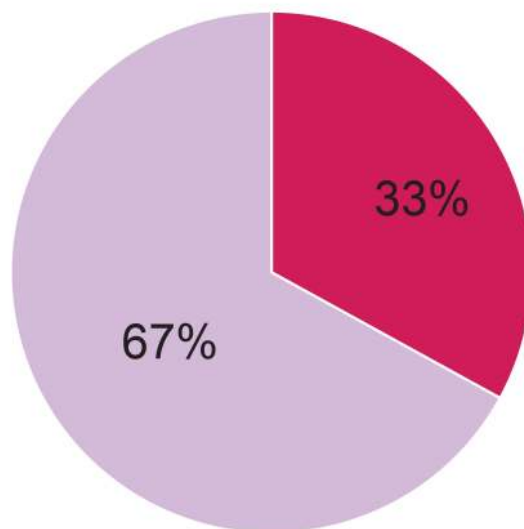
Figure 1A

MMR deficient rectal cancer



■ Germline mutation identified

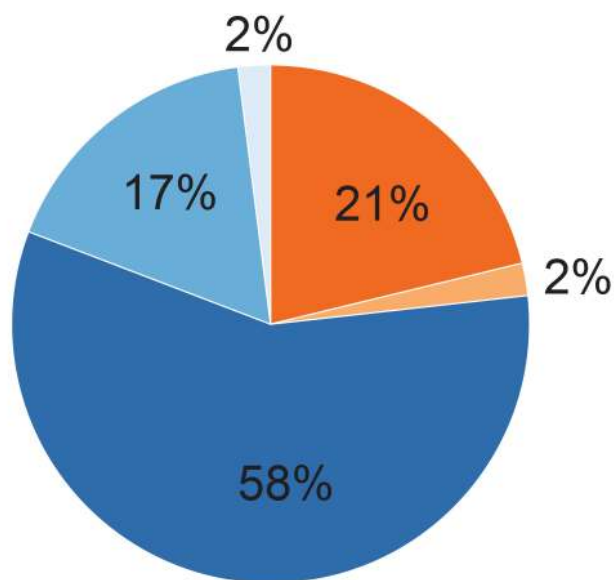
MMR deficient colon cancer



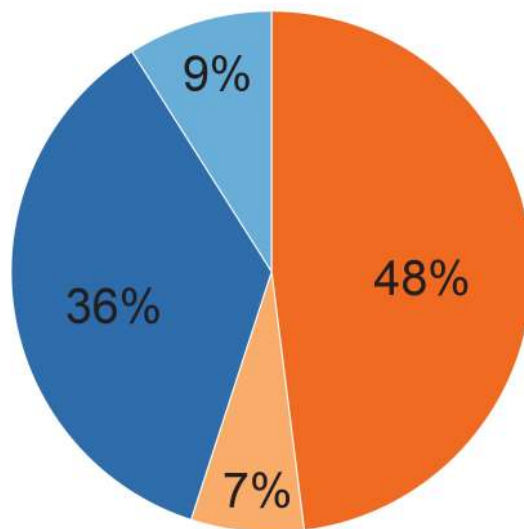
■ No germline mutation identified

Figure 1B

Distribution of germline mutations in rectal cancer



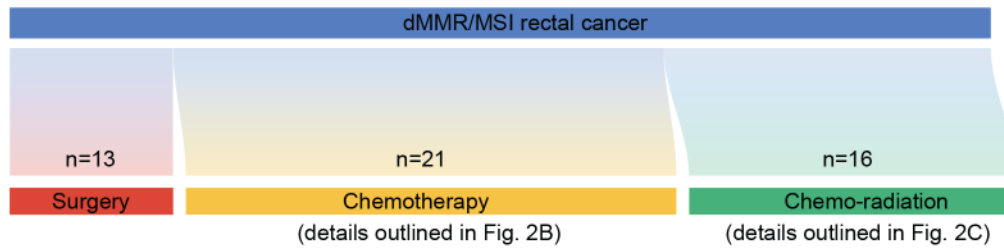
Distribution of germline mutations in colon cancer



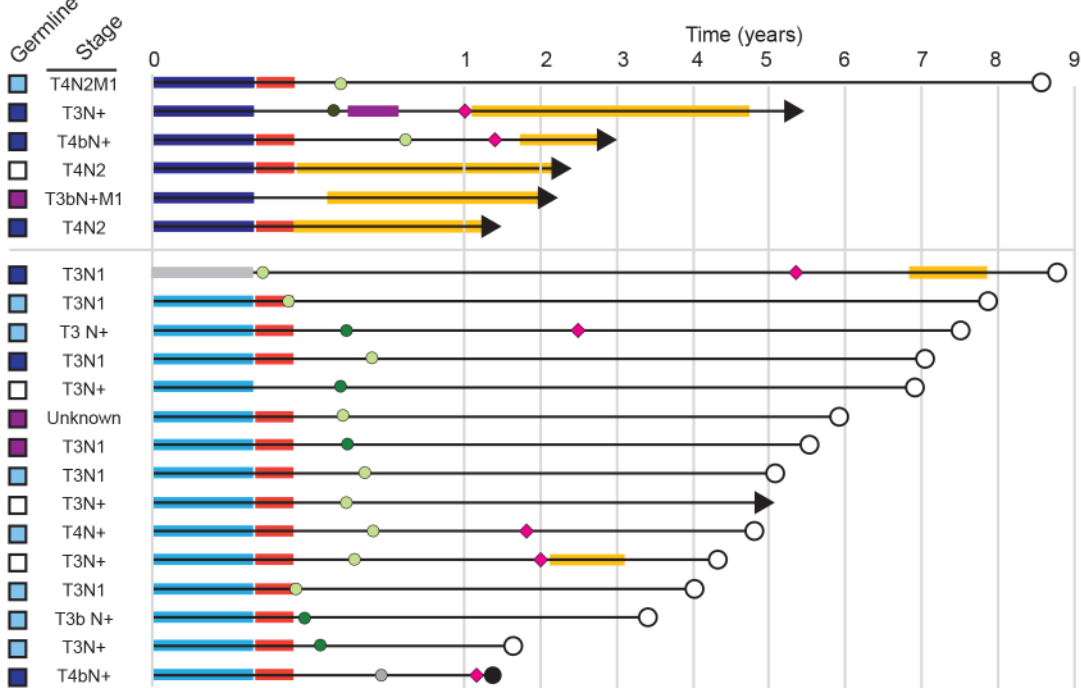
Pathogenic germline mutation identified:

■ MLH1 ■ PMS2 ■ MSH2 ■ MSH6 ■ EPCAM

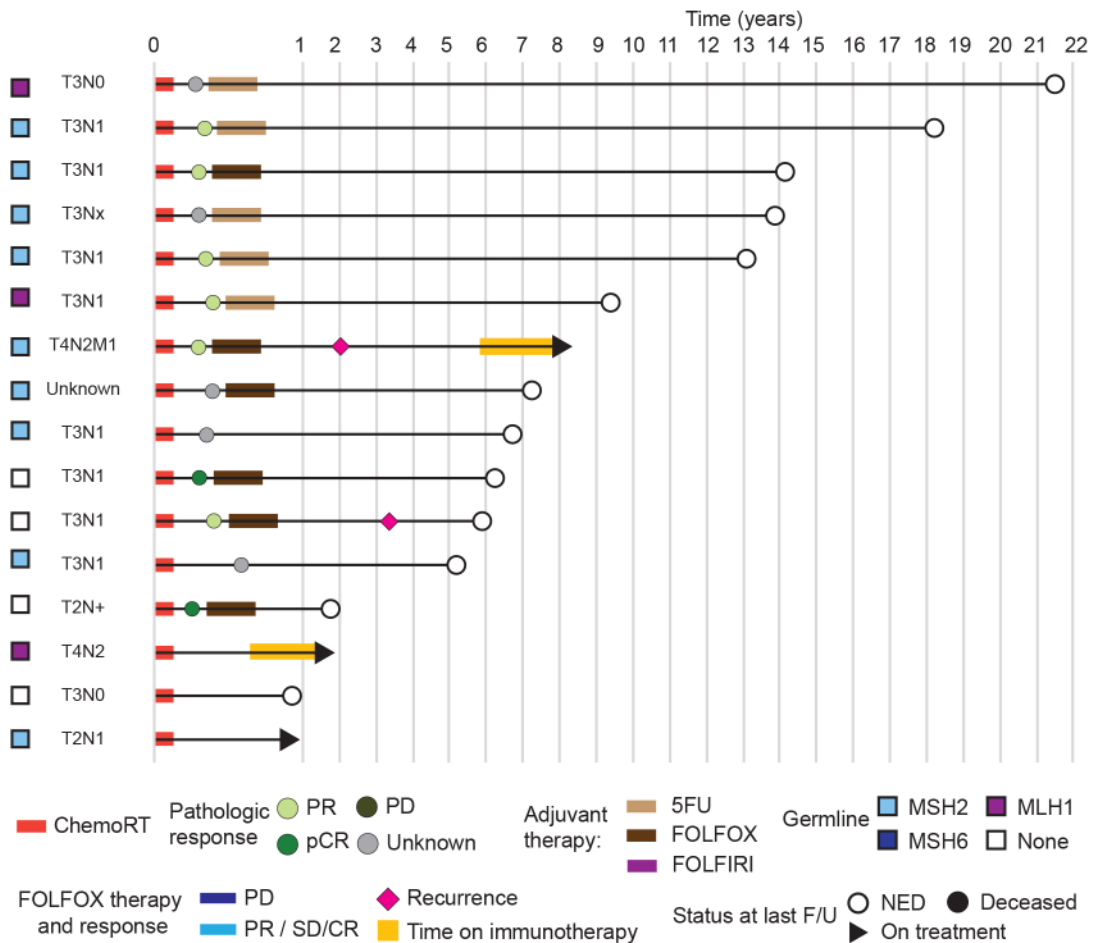
A Flow diagram of 50 dMMR/MSI rectal cancer patients and upfront treatment modalities.



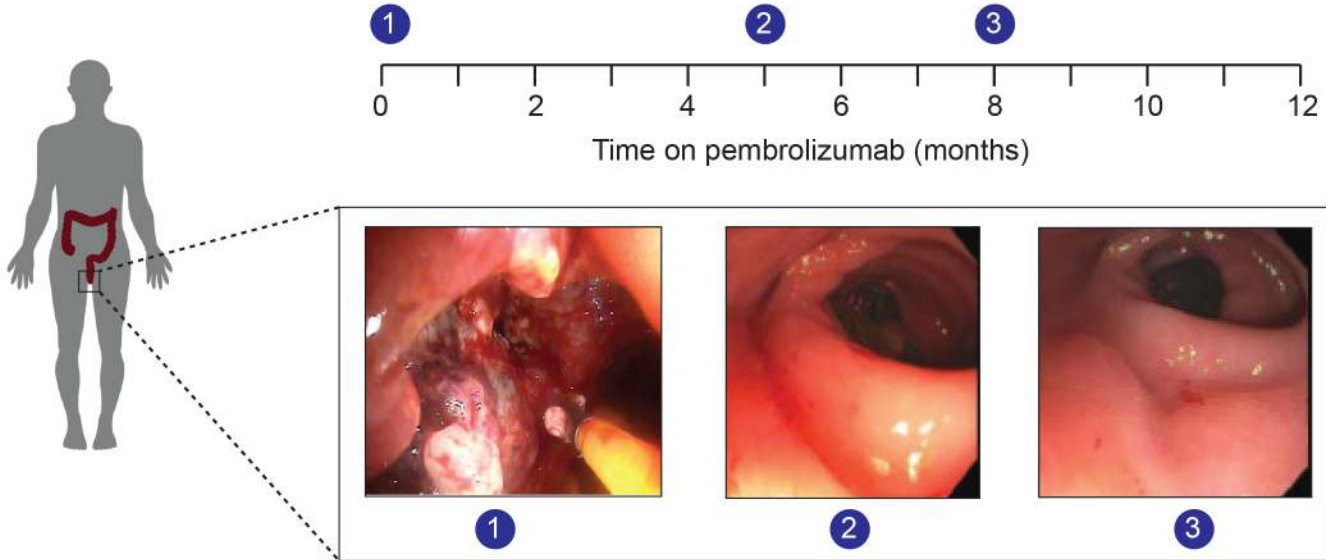
B Treatment and outcome of dMMR/MSI patients treated initially with neoadjuvant FOLFOX




C Treatment and outcome of dMMR/MSI patients treated initially with neoadjuvant chemoradiation



A Endoscopic imaging of a recurrent dMMR/MSI rectal adenocarcinoma pretreatment, 5 and 8 months post initiation of treatment with pembrolizumab.



B Oncoprint and tumor mutation burden in FOLFOX responders and non-responders with dMMR/MSI rectal adenocarcinoma.



C Tumoroid *ex vivo* sensitivity to FOLFOX demonstrating relative sensitivity to FOLFOX in pMMR/MSS tumoroids and resistance in dMMR/MSI tumoroids.

