European Heart Journal (2010) **31**, 330–339
doi:10.1093/eurheartj/ehp423

CLINICAL RESEARCH
Arrhythmia/electrophysiology

Mode of onset of ventricular fibrillation in patients with early repolarization pattern vs. Brugada syndrome

Gi-Byoung Nam[1]*, Kwan-Ho Ko[2], Jun Kim[3], Kyoung-Min Park[4], Kyoung-Suk Rhee[5], Kee-Joon Choi[1], You-Ho Kim[1], and Charles Antzelevitch[6]*

[1]Department of Internal Medicine, Asan Medical Center, University of Ulsan College of Medicine, 138-736, Poongnap-dong 388-1, Songpa-gu, Seoul, Republic of Korea; [2]Health Medicine, Asan Medical Center, University of Ulsan College of Medicine, Seoul, Republic of Korea; [3]Division of Cardiology, Department of Internal Medicine, Pusan National University School of Medicine, Pusan National University Hospital, Busan, Republic of Korea; [4]Department of Internal Medicine, Sanggye Paik Hospital, College of Medicine, Inje University, Seoul, Republic of Korea; [5]Division of Cardiology, Department of Internal Medicine, Chonbuk National University, Chonbuk, Republic of Korea; and [6]Masonic Medical Research Laboratory, 2150 Bleecker Street, Utica, NY 13501-1787, USA

Received 20 December 2008; revised 23 April 2009; accepted 11 June 2009; online publish-ahead-of-print 29 October 2009

Aims The aim of the present study was to identify specific electrocardiogram (ECG) features that predict the development of multiple episodes of ventricular fibrillation (VF) in patients with an early repolarization (ER) pattern and to compare the mode of VF initiation with that observed in typical cases of Brugada syndrome (BrS).

Methods and results The mode of the onset and the coupling intervals of the premature ventricular contractions (PVCs) initiating VF episodes were analysed in patients with BrS ($n = 8$) or ER who experienced sudden cardiac death/syncope or repeated appropriate implantable cardioverter defibrillator shocks. Among the 11 patients with ER, 5 presented with electrical storm (ES, four or more recurrent VF episodes/day). The five ES patients displayed a dramatic but very transient accentuation of J waves across the precordial and limb leads prior to the development of ES. Ventricular fibrillation episodes were more commonly initiated by PVCs with a short–long–short (SLS) sequence in ER (42/58, 72.4%) vs. BrS patients (13/86, 15.1%, $P < 0.01$). Coupling intervals were significantly shorter in the ER group compared with those with BrS [328 (320, 340) ms vs. 395 (350, 404) ms, $P < 0.01$].

Conclusion Our study provides additional evidence in support of the hypothesis that ER pattern in the ECG is not always benign. Transient augmentation of global J waves may be indicative of a highly arrhythmogenic substrate heralding multiple episodes of VF in patients with ER pattern. Ventricular tachycardia/VF initiation is more commonly associated with an SLS sequence, and PVCs display a shorter coupling interval in patients with ER pattern compared with those with BrS.

Keywords Sudden cardiac death • Ventricular fibrillation • Electrocardiography • J waves • Electrical storm

Introduction

The electrocardiographic markers of the primary arrhythmic disorders causing sudden cardiac death include ST-segment elevation in the right precordial leads and prolongation/abbreviation of the QT intervals, especially when accompanied by ventricular premature beats with very short coupling intervals.[1] Early repolarization (ER), consisting of a J point elevation, notching or slurring of the terminal portion of the R wave (J wave), and tall/symmetric T wave, is generally considered to be benign.[2,3] On the basis of preclinical experimental evidence, it was recently suggested that some forms of ER seen in the clinic may not be benign, especially when associated with the occasional appearance of J waves and/or ST segment elevation.[4] Sporadic case reports and basic electrophysiology research have suggested a critical role for the J wave in the pathogenesis of idiopathic ventricular fibrillation (IVF).[5–12]

* Corresponding authors. Tel: +82 2 3010 3159, Fax: +82 2 486 5918, E-mail: gbnam@amc.seoul.kr (G.-B.N); Tel: +1 315 735 2217, Fax: +1 315 735 5648, E-mail: ca@mmrl.edu (C.A.)

A definitive association between ER and IVF has been presented in the recent reports by Haïssaguerre *et al.*[13] and by Viskin and colleagues.[14] In this report, we present specific electrocardiogram (ECG) features that predict the development of multiple episodes of ventricular fibrillation (VF) in patients with no evidence of ECG abnormality other than an ER pattern and contrast the mode of VF initiation with that observed in typical cases of Brugada syndrome (BrS). A preliminary version of this study was published in conjunction with the report by Haïssaguerre *et al.*[13,15]

Methods

Patient selection and diagnostic tests

During the study period from June 1998 to August 2008, 50 patients with VF in the absence of structural heart disease were identified. A total of 19 patients were classified as 'idiopathic' VF after the exclusion of long/short QT syndrome, typical BrS, or catecholamininergic polymorphic ventricular tachycardia (VT). Electrocardiograms at baseline and immediately before the onset of VF were analysed. Among the 19 patients with idiopathic VF, 11 patients showed ER in the baseline ECG, and 5 patients presented with electrical storm (ES, four or more recurrent VF episodes occurring within a day). To compare the prevalence of ER in patients with idiopathic VF and in the general population, the ECGs of the normal controls who visited our Health Promotion Center for annual checkup between 1 May and 15 May 2007 were reviewed. In patients with VF, continuous ECG monitoring was performed in the coronary care unit (CCU), and ECGs were recorded whenever a dynamic repolarization change was observed in the rhythm strip to investigate the transient ECG changes before the onset of VF. The present study is based on the analysis of the dynamic ECG features prior to the development of recurrent VF episodes in those five patients with ES. Because of the similarity in the ECG features with BrS, reversible factors causing precordial ST-segment elevation or J waves were aggressively sought and ruled out.[16] Structural heart disease was excluded by echocardiography, treadmill exercise testing, thallium myocardial single-photon emission computed tomography, coronary angiography, ergonovine stress echocardiography, and in some patients, cardiac magnetic resonance imaging. Electrolyte imbalance, drug history, and other conditions causing J/ST/T wave changes mentioned in the second consensus conference were carefully considered and excluded. Typical Brugada-type ECG (type I) was defined as a coved-type ST-segment elevation in two or more right precordial leads (V_{1-3}) with or without flecainide provocation. Early repolarization was diagnosed on the basis of the criteria described by Wasserburger *et al.*, i.e. (i) ST-segment elevation (>0.1 mV) in two or more precordial or limb leads in the absence of acute ischaemia, pericarditis, or other QRS abnormality that could cause secondary ST-segment elevation, (ii) upward concavity, (iii) notch and/or slur on QRS, and (iv) symmetrical T waves of large amplitudes.[2,3] For the comparison of the distribution of ST elevation, ECG lead areas were grouped as right precordial (V_{1-4}), left precordial (V_{3-6}), lateral (I, aVL), and inferior (II, III, aVF). The exclusion of the structural heart disease and pharmacological provocation using flecainide was performed as described previously.[17] A signal-averaged ECG (SAECG) was recorded using MacVU (Marquette, Milwaukee, WI, USA). The analysis and interpretation of the SAECG were based on the previously defined criteria.[17] The study protocol was reviewed and approved by the Ethics Committee of the University of Ulsan College of Medicine. Each patient gave informed consent.

Electrocardiogram monitoring and ventricular fibrillation management

Continuous ECG monitoring (lead II) was performed with a Centralscope 12 and MARS (Marquette Electronics) system. Ventricular fibrillation was immediately terminated, and if it recurred repeatedly, intravenous isoproterenol (1–4 μm/min) or pacing was initiated. After the confirmation of the absence of reversible factors, implantable defibrillators, a Microjewel II (Medtronic, in one patient), Profile MD (St Jude Medical, in three patients) were implanted. All the devices were capable of storing RR intervals or electrograms recorded from the endocardial leads.

Statistical analysis

Statistical analysis was performed with SAS software (version 8.2). Electrocardiogram interval data are expressed as median (25th, 75th percentile). The Mann–Whitney test and Wilcoxon signed rank-sum test were used for the comparison of unpaired and paired samples, respectively. Discrete variables were analysed by the χ^2 test. A *P*-value <0.05 was regarded as significant. The authors had full access to the data and take responsibility for its integrity. All authors have read and agreed to the manuscript as written.

Results

Prevalence of early repolarization in the general population and in patients with ventricular fibrillation

The incidence of ER among 1395 controls representative of the general population was 3.3% (5.5% among males and 0.3% in females) (*Table 1*). In contrast, the incidence of ER among IVF patients was 57.9% (11/19). The baseline resting ECGs of the IVF patients were normal in 7, showed RBBB in 1, and ER in 11 out of 19 patients. The distribution of ST-segment elevation in patients with IVF and in the general population was shown in *Table 2*. ST elevations in multiple (more than one) ECG regions were more commonly observed in patients with IVF than in the general population (72.7 vs. 15.2%, $P < 0.05$). ST-segment elevations (J waves) >1 mm in amplitude in left + right + inferior/lateral leads (global J waves) were observed in 0% of 46 patients with ER pattern without VF (selected from among 1395 individuals from the general population) and in 45.5% of patients with ER patients who developed VF. Among the five IVF patients with ES, the incidence of ER was 100%. The remainder of this report is focused on these five ES cases.

Clinical characteristics of electrical storm patients

The baseline ECG in all cases displayed an ER pattern as the only or chief distinctive feature. Each of ES patients presented at the emergency department with a cardiovascular collapse due to VF (patients 1, 3, 5) or syncope/nocturnal seizure-like activity (patients 2, 4). The occurrence of VF episodes distributed predominantly at night in four patients, whereas in patient 2, VF episodes were more common during daytime. Patient 1 experienced three separate episodes of ES, whereas the others had single episodes (*Table 3*). A total of 75 VF episodes occurred in the five patients with ES over a period of 59 ± 23 months. Fifty-seven (76%

Table 1 Prevalence of early repolarization in patients with IVF and in the general population

Age	Sex					
	Male		Female		Total	
	Total number	ER[a], *n* (%)	Total number	ER[a], *n* (%)	Total number	ER[a], *n* (%)
20s	56	4 (7.1)	59	1 (1.7)	115	5 (4.3)
30s	101	7 (6.9)	87	0 (0)	188	7 (3.7)
40s	267	18 (6.7)	210	0 (0)	477	18 (3.8)
50s	272	12 (4.4)	179	1 (0.6)	451	13 (2.9)
60s	83	3 (3.6)	56	0 (0)	139	3 (2.2)
70s	19	0 (0)	6	0 (0)	25	0 (0)
Total	798	44 (5.5)	597	2 (0.3)	1395	46 (3.3)

All 1395 patients had their ECG recorded between 1 May 2007 and 15 May 2007 at the Department of Health Medicine, Asan Medical Center.
[a]ER denotes the number of patients with early repolarization.

Table 2 Comparison of electrocardiogram characteristics in the general population and in patients with IVF

	General population	IVF
Number of subjects	1395	19
Early repolarization, *n* (%)	46 (3.3)	11 (57.9)
Location of STE[a], *n* (%)		
Left precordial	12 (26.1)	1 (9.1)
Right precordial	26(56.5)	1 (9.1)
Inferior	1 (2.2)	1 (9.1)
Right + left[b]	0 (0)	3 (27.3)
Left + inferior[b]	5 (10.9)	0 (0.0)
Right + lateral[b]	2 (4.3)	0 (0.0)
Right + left + inferior/lateral[b], *n* (%)	0 (0)	5 (45.5)
ST elevation in multiple ECG regions[b], *n* (%)	7 (15.2)	8 (72.7)

[a]STE denotes ST-segment elevation in patients with early repolarization.
[b]ST elevation in multiple (more than one) ECG regions.

total) occurred as ES and 18 as sporadic VF episodes. Fifty-eight episodes (77% of the total) were documented in the ECG (14 VFs) or in the implantable cardioverter defibrillator (ICD) memory (44 VFs). The mean number of VF episodes per storm was 8.1.

Dynamic electrocardiogram changes in patients with electrical storm

The five ES patients all displayed a mild ER pattern in the admission ECG. During observation in the CCU, however, ECG monitoring showed prominent repolarization changes and frequent bigeminal premature ventricular contraction (PVCs). Electrocardiograms recorded within 30 min of the ES episode exhibited a global appearance of J waves in the precordial and limb leads (*Figures 1* and *3*). These striking ECG features were only recorded in close proximity to the time of the ES episode (*Figures 1C* and *3A*) and were not unmasked by sodium channel blockers. These J-ST-T changes were observed in four of the five ES patients. The fifth patient arrived at the hospital 12 h after the last VF episode, and the 12-lead ECG prior to ES was not available. However, fluctuating global augmentation of J waves was evident in the follow-up ECGs until it finally disappeared 3 days after the last event (*Figure 2*).

Mode of ventricular fibrillation initiation in patients with early repolarization and Brugada syndrome

The VF episodes in ER patients were commonly initiated by PVCs with a short–long–short (SLS) sequence (*Figures 1C* and *D* and *2B*). The mode of VF initiation was compared between the five ES patients and eight BrS patients. A SLS sequence was observed in 42/58 (72.4%) VF episodes in the ES patients of IVF-ER, but in only 13/86 (15.1%) of VF episodes in patients with BrS ($P < 0.01$). The PVCs preceding the VF episodes in the ES group exhibited significantly shorter coupling intervals than in patients with BrS [328 (320, 340) ms vs. 395 (350, 404) ms, $P < 0.01$].

When the ECG parameters close to (<30 min) VF onset were compared with those remote from the episode, there was no significant differences in QT, corrected QT, and T_{peak}–T_{end} intervals during stable sinus rhythm (*Table 4*, from patients 1, 2, 3, and 4). However, QT and T_{peak}–T_{end} intervals associated with the sinus beats following PVCs were greatly increased in the right precordial leads but not in the other ECG leads (patients 1 and 2). This spatial dispersion of repolarization is recorded only after the long compensatory pause following a PVC and was not observed during stable sinus rhythm, even in close temporal proximity to VF onset. This suggests that the electrophysiological milieu of these ES patients is highly dynamic and can be greatly augmented by long pauses following a PVC (*Figure 4*).

Table 3 Clinical characteristics of the patients with electrical storm

Patient	1	2	3	4	5
Age/gender	53/F	39/M	50/M	43/M	31/M
Family history of SCD	N	N	N	N	N
Presenting symptom	SCD	Syncope	SCD	Syncope/seizure	SCD
Diurnal distribution of ES	Mixed (9 p.m.–10 a.m.)	Diurnal (10 a.m.–10 p.m.)	Nocturnal (7 p.m.–1 a.m.)	Nocturnal (2 a.m.– 4 a.m.)	Nocturnal (10 P.M.–3 a.m.)
Number of ESs (number of VF episodes per storm)	3 (11, 5, 16)	1 (7)	1 (9)	1 (4)	1 (5)
Number of VF episodes not as an ES	6	4	0	3	5
ECGs or EGMS, documented at the onset of VF/total VF episodes	31/38	11/11	3/9	4/7	7/8
SAECG	N	N	NA	N	P
Flecainide provocation	N	N	NA	N	N
Suppression of ES	I, Pa	Q	I	I, Q	Spon

SCD, sudden cardiac death; ES, electrical storm; VF, ventricular fibrillation; SAECG, signal-averaged electrocardiogram; N, negative; NA, not assessed; P, positive; I, isoproterenol; Pa, pacing; Q, quinidine; Spon, spontaneous termination.

The SAECGs were negative in three of the four ES ER patients tested, and flecainide provocation tests were negative in all the four ES patients tested.

Management of electrical storms

The occurrence of VF episodes was always accompanied by a prominent accentuation of the J wave. Isoproterenol (1–4 μM/min) or pacing above rates of 90–100 b.p.m. not only abolished these ECG changes (*Figure 3*) but prevented the recurrence of VF. The frequency of the VF decreased dramatically after the introduction of isoproterenol or pacing (*Figure 5*). In patients 2 and 4, quinidine at 200 mg t.i.d.-q.i.d. (alone or in combination with isoproterenol) was administered after they were admitted. Ventricular fibrillation did not recur after the administration of quinidine in these patients. Neither amiodarone nor lidocaine nor magnesium was effective in preventing ES in patients 1, 2, and 3. Four patients underwent ICD implantation, and one (patient 3) was managed with quinidine.

Discussion

We have identified a subgroup of patients with apparently structurally normal hearts who develop VF and ESs in association with a unique electrocardiographic signature consisting of (i) baseline ER pattern, (ii) global transient accentuation of J waves across the precordial and limb leads, (iii) VF precipitated by relatively short-coupled PVCs associated with a SLS sequence of diastolic intervals, and (iv) the suppression of accentuated J waves and VF by the administration of quinidine, isoproterenol, and pacing at faster rates.

The J wave is thought to be due to transmural differences in action potential notch secondary to a transmural gradient of the transient outward current (I_{to}).[12,18] Prominent J waves are typically observed in hypothermia, hypercalcaemia, myocardial ischaemia, brain injury, BrS, and ER. Early repolarization is predominantly found in the healthy young males and has traditionally been regarded as totally benign. The observation that an ER pattern in the arterially perfused wedge preparation can easily convert to one in which phase-2 re-entry gives rise to polymorphic VT/VF prompted the suggestion that ER may predispose to more malignant arrhythmias in the clinic.[4] Recent data from Haïssaguerre *et al.*[13] have provided evidence in support of this hypothesis. The present study provides further support for the hypothesis, presenting a series of clinical cases of recurrent VF in patients whose ECGs at baseline show no more than an ER pattern. The high prevalence of ER in patients with IVF suggests that ER could be a necessary condition for the development of IVF. Although not a sensitive marker for SCD because of its high prevalence in the general population, ER, when observed in patients with syncope or malignant family history of sudden cardiac death, may be prognostic of risk, suggesting that these patients should be followed closely. The available data suggest that transient J wave augmentation portends a high risk for VF in patients with ER and should be closely monitored, since this could signify an imminent risk for the development of VF storm.

The dynamic J wave activity is usually limited to the right precordial leads in common forms of BrS. This is explained by the prominence of I_{to} in right ventricular epicardium.[19] Case reports have occasionally described variants of BrS with ECG changes in the

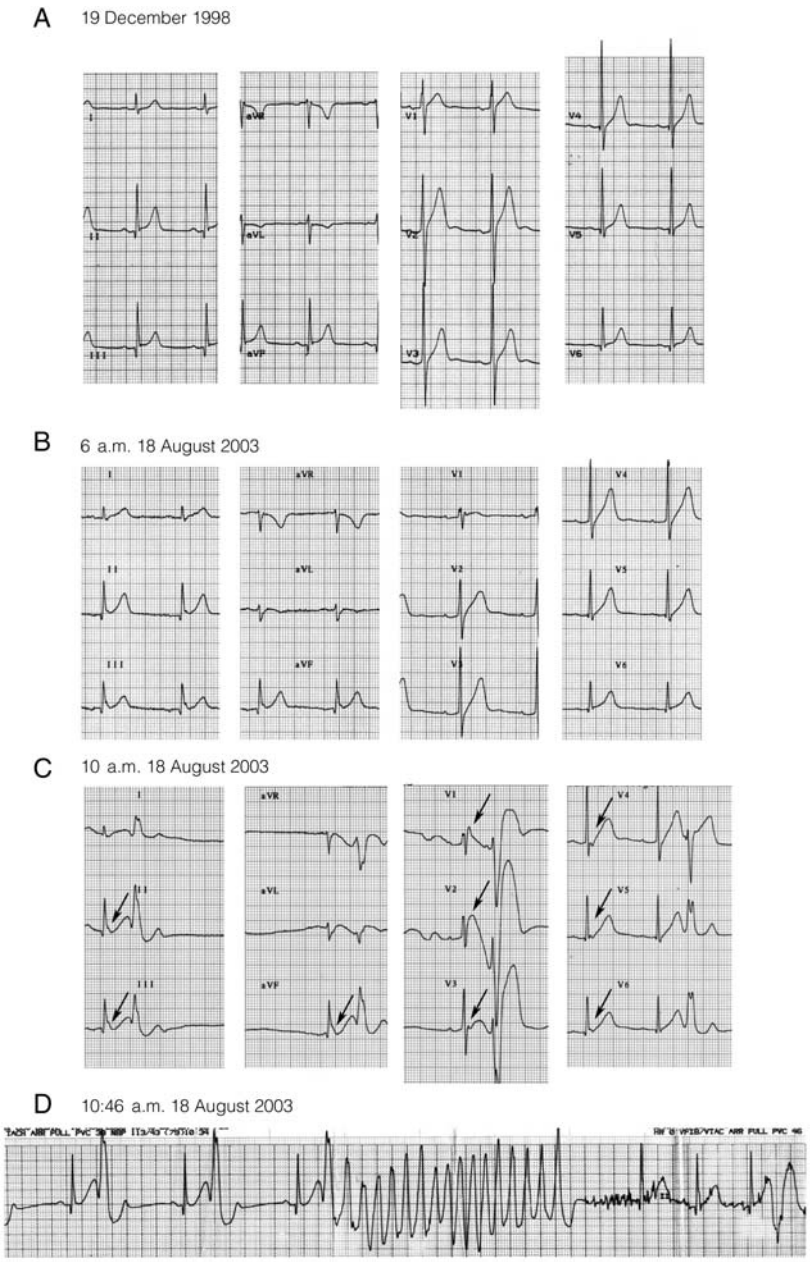

Figure 1 Twelve-lead electrocardiograms showing the changes in the J-ST-T waves before and after an electrical storm in patient 2. The electrocardiograms were obtained on 19 December 1998 (*A*, remote from the electrical storm) and 18 August 2003 (*B*, 4 h before the electrical storm; *C*, 10 min before the electrical storm). The patient underwent an implantable cardioverter defibrillator (ICD) implantation in 1998 for a diagnosis of idiopathic ventricular fibrillation (negative flecainide provocation test). On 17 August 2003, the patient experienced multiple ICD discharges and was admitted to hospital. On analysis of the stored electrograms, five episodes of ventricular fibrillation leading to appropriate shocks were recorded over a period of 15 h. During observation in the coronary care unit on 18 August, six episodes of sustained and non-sustained polymorphic ventricular tachycardia with two ICD discharges were recorded. An electrocardiogram taken 21 h after the last ventricular fibrillation episode (and 10 min before the next ICD shock) revealed prominent J waves all across the precordial and inferior leads (arrows) with R on T premature ventricular contractions in a pattern of bigeminy (C). The electrocardiograms obtained 4 h before that ventricular fibrillation attack (B) and on the next day exhibited only mild upward concave ST-segment elevation. During observation in the coronary care unit, frequent non-sustained polymorphic ventricular tachycardias and two episodes of ventricular fibrillation were recorded (*D*). Polymorphic ventricular tachycardia and ventricular fibrillation were always initiated by premature ventricular contractions with a short-long-short sequence. The coupling interval of the premature ventricular contraction was 380 ms.

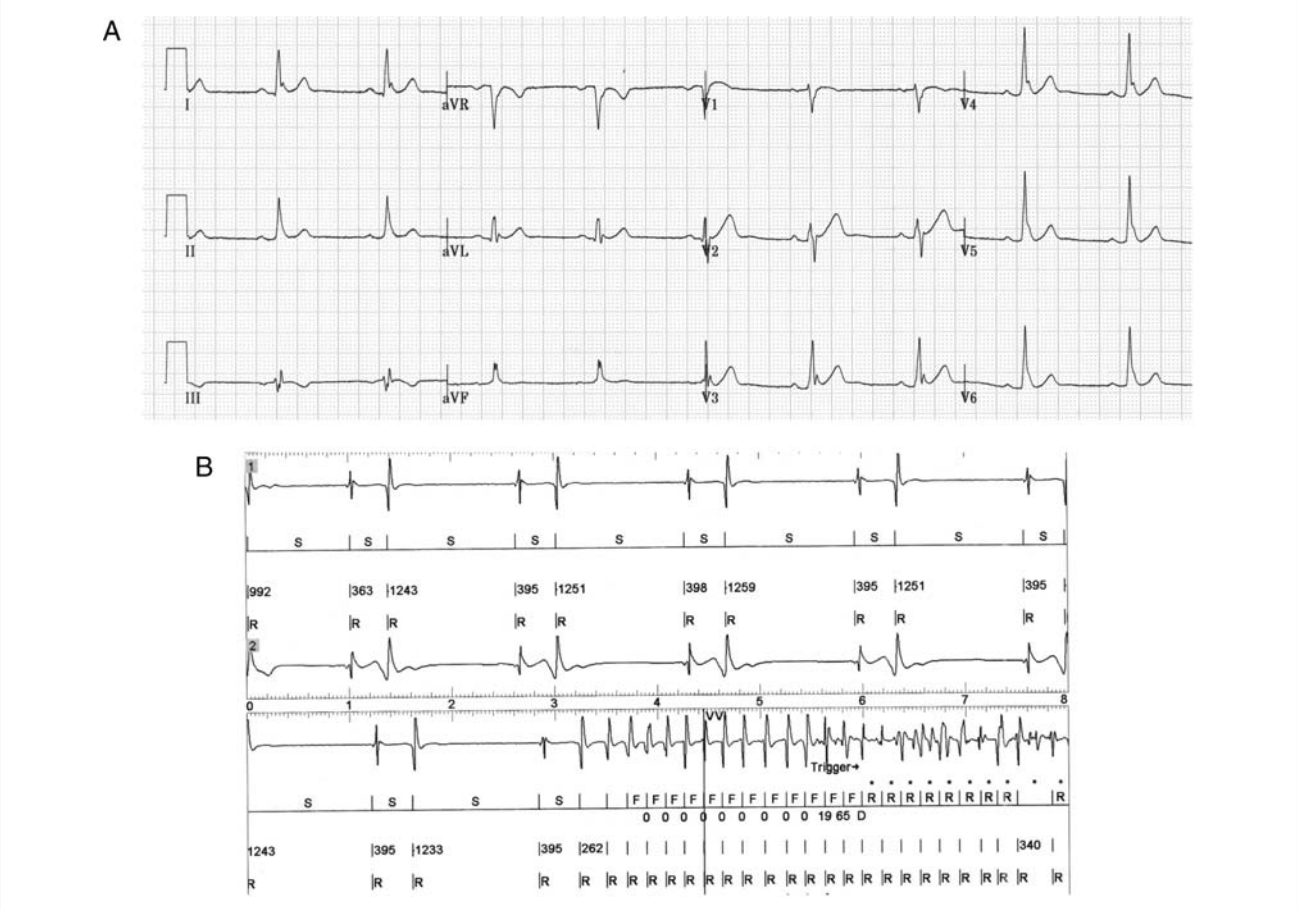

Figure 2 Global J waves in a patient presenting with electrical storm. (*A*) Twelve-lead electrocardiogram of patient who experienced five episodes of ventricular fibrillation during sleep, recorded 12 h after electrical storm. Prominent J waves and J point elevation are apparent in right and left precordial leads as well as inferior/lateral leads. (*B*) Interrogation of the implantable cardioverter defibrillator electrogram revealed five episodes of ventricular fibrillation.

inferior or lateral leads, suggesting that the pathophysiological changes responsible for BrS may not always be confined to the right ventricle.[20,21] The global nature of the ECG changes in our ER-VF patients suggests that ES may be the result of a generalized accentuation of the epicardial notch rendering the entire ventricular myocardium susceptible to the development of fatal re-entrant tachyarrhythmias. The ST-segment elevation observed in ER is thought to be generated by depression of the LV epicardial action potential dome, which by itself may not be sufficient to give rise to repolarization heterogeneities necessary for the development of re-entrant tachycardia. An outward shift in the balance of current responsible for the ER pattern may nevertheless facilitate the development of phase-2 re-entry and polymorphic VT. It is noteworthy that although J waves are globally apparent in ER-VF patients, the accentuation of the J wave and/or ST-segment elevation preceding episodes of VF is most pronounced in the right precordial leads. This dynamic shift of repolarization characteristics was noted in the ECGs of three of the five ES patients (patients 1, 2, and 3). This finding suggests a shift in the balance of current in the early phases of the epicardial action potential, possibly triggered by increased vagal tone and/or reduced sympathetic tone, that is most pronounced in the RVOT, where I_{to} is most prominent. The ER pattern in the ECG may be due to increased vagal tone resulting in augmented acetylcholine (ACh)-sensitive potassium channel current ($I_{K\text{-}ACh}$), activation of adenosine triphosphate (ATP)-sensitive potassium channel current ($I_{K\text{-}ATP}$), or slowed inactivation of I_{to} among other possibilities. Further accentuation of these changes could also account for the prominence of J wave and ST-segment manifestation preceding the development of VT/VF. The accentuation of the ST-segment elevation (J waves) following a compensatory pause (*Figure 4*) is also consistent with the greater availability of I_{to} under these conditions owing to the relatively slow recovery of I_{to} from inactivation.[22,23] The attending accentuation of the epicardial action potential notch, particularly in the right precordial leads, can also account for the inversion of the T wave and the prolongation of $T_{peak}-T_{end}$, following the compensatory pause.[24] These electrocardiographic changes portend the development of phase-2 re-entry and suggest an enhanced spatial dispersion of repolarization, which can give rise to a highly arrhythmogenic substrate. Evidence in support of these hypotheses derives from both experimental[4,25–27] as well as clinical observations.[4,28]

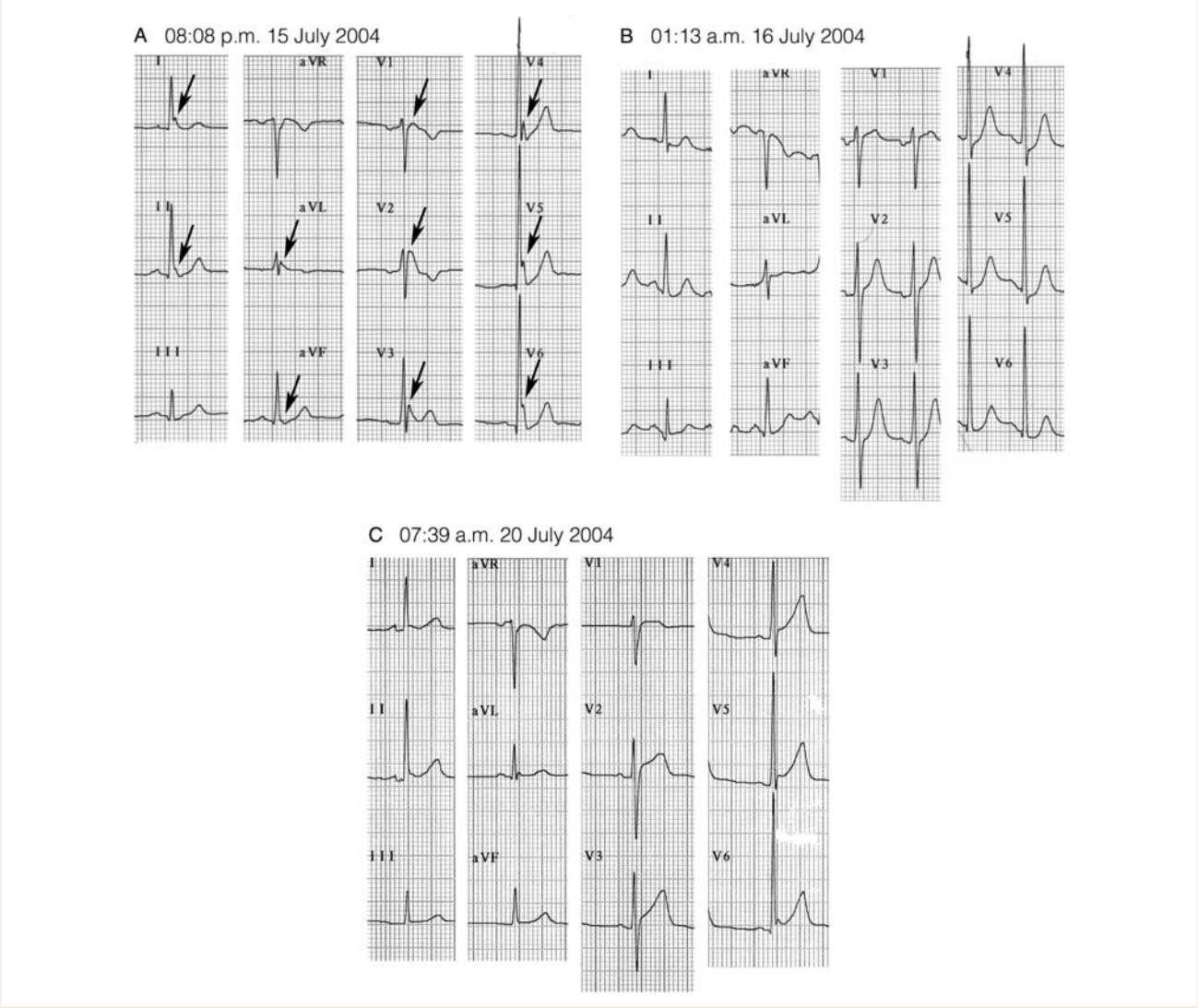

Figure 3 Effect of isoproterenol on the J-ST-T waves in patient 3. (*A*) The first ventricular fibrillation episode in this patient occurred at 7:04 p.m., 15 July 2004. One hour after the first ventricular fibrillation (8:08 p.m.), the appearance of prominent J waves (arrows) was noted across the precordial and limb leads (I, II, aVL, and aVF). About 20 min after this electrocardiogram, the patient developed eight additional episodes of ventricular fibrillation. (*B*) Twelve-lead electrocardiogram recorded 5 h after the electrocardiogram in (*A*) during the infusion of isoproterenol at 4 μM/min. Isoproterenol eliminated the J waves and completely suppressed the ventricular fibrillation. (*C*) A resting 12-lead electrocardiogram recorded five days after the event. Ventricular fibrillation did not recur, and the patient was stabilized. The resting electrocardiogram showed only an early repolarization pattern.

The ECG features, although reminiscent of BrS, do not fully satisfy the proposed diagnostic criteria for BrS[16] in that (i) they appeared only after long pauses (patients 1 and 2); (ii) were $<$2 mm in amplitude (patients 3, 4, and 5). In contrast to BrS patients, where prominent J waves are observed principally in right precordial leads, in our IVF patients, J waves appear globally in nearly all leads. In addition, salient diagnostic features of the BrS such as provocation by sodium channel blockers or positive SAECG were rarely observed in our IVF patients. Although the ECG findings do not fulfil the classic patterns of BrS, they closely match important ECG features of BrS (dynamic nature, J wave, pause dependence). Dynamic electrocardiographic changes and their role in arrhythmogenesis are well appreciated in patients with BrS.[29,30] The most prominent ECG changes appear just before the onset of VF and disappear after a short period.[5,30] A similar dynamicity was observed in our ER-VF patients. The interval from the appearance of the characteristic ECG features to the development of VF averaged 15 min (0, 10, 20, and 30 min for patients 1, 2, 3, and 4, respectively). The ECG patterns were highly variable and sensitive to changes in heart rate. The amplitude of the J waves, barely noticeable under baseline conditions, became progressively augmented by the compensatory pauses that followed each successive PVC. This positive feedback loop likely contributes to the progressive abbreviation of the coupling interval, gradually bringing the extra-systole into the vulnerable window during which re-entry can be initiated. The extra-systole

that triggers VF is relatively short-coupled in our IVF patients, consistent with a phase-2 re-entrant mechanism. Although the distinction between ER and BrS remains somewhat elusive, the mechanisms may not be mutually exclusive. The transition and dynamic nature of the ECG features suggest that some forms of ER may be a 'forme fruste' of the broader J wave syndrome, which includes the BrS.

Suppression of the ECG features by isoproterenol or pacing in our IVF patients further supports the notion that they share common underlying electrophysiological abnormalities with those of BrS patients. Infusion of isoproterenol dramatically suppresses the VF storms in our ES cases. At present, an ICD is the only effective treatment to prevent SCD in patients with BrS or idiopathic VF. Our study suggests that appropriate ICD shocks may be minimized by the elevation of heart rate, infusion of isoproterenol, or administration of I_{to} blockers such as quinidine when accentuated J waves first appear.

Table 4 Comparison of electrocardiogram variables at baseline and before electrical storm

	Baseline	Before ES	*P*-value
PR	172 (162, 184)	161 (155, 177)	>0.05
QT	362 (352, 410)	377 (337, 398)	>0.05
QTc	409 (392, 427)	403 (400, 406)	>0.05
JT	300 (270, 330)	288 (280, 300)	>0.05
$QT_{peak\text{-}end}$	100 (80, 100)	100 (80, 100)	>0.05

ES, electrical storm; PR, PR interval (ms); QT, QT interval (ms); QTc, corrected QT interval (ms, Bazzet formula); JT, JT interval (ms); QTpeak-end, interval from the peak to end of T wave (ms).
All the parameters were measured in ECG lead 2. Intervals were averaged from eight ECGs (two ECGs from each of the four ES patients) and expressed as median (25th, 75th percentile).

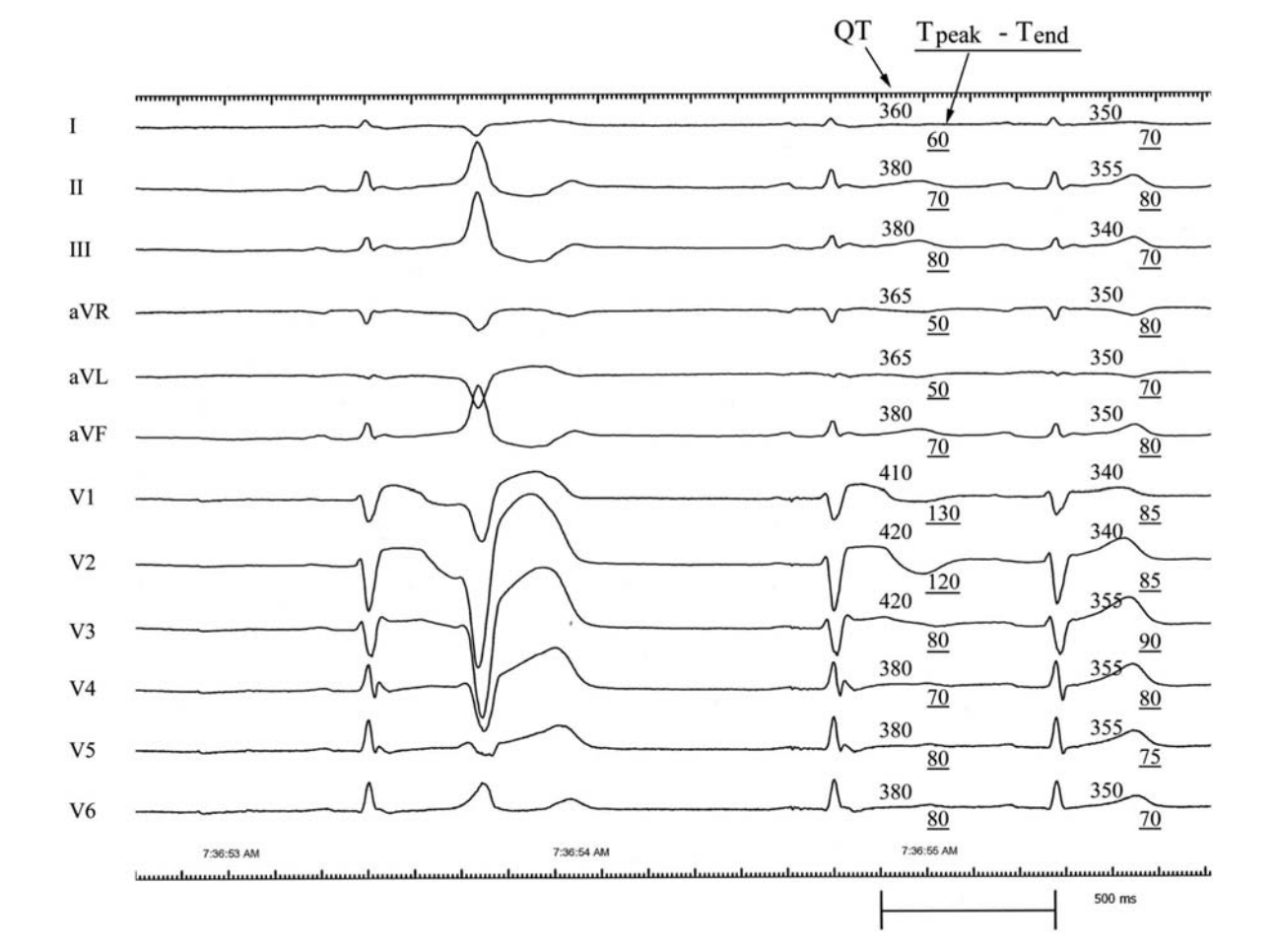

Figure 4 QT and $T_{peak}-T_{end}$ interval changes following post-extra-systolic compensatory pause. This electrocardiogram was recorded from patient 1, 10 min before the onset of ventricular fibrillation. The QT interval and the interval from the peak to the end of T wave ($T_{peak}-T_{end}$) are greatly augmented in the right precordial leads in the sinus beat following post-extra-systolic compensatory pause, but less so in other electrocardiogram leads. This accentuated spatial dispersion of repolarization is recorded only after long pauses and was not observed in stable sinus rhythm, even in close proximity to ventricular fibrillation onset.

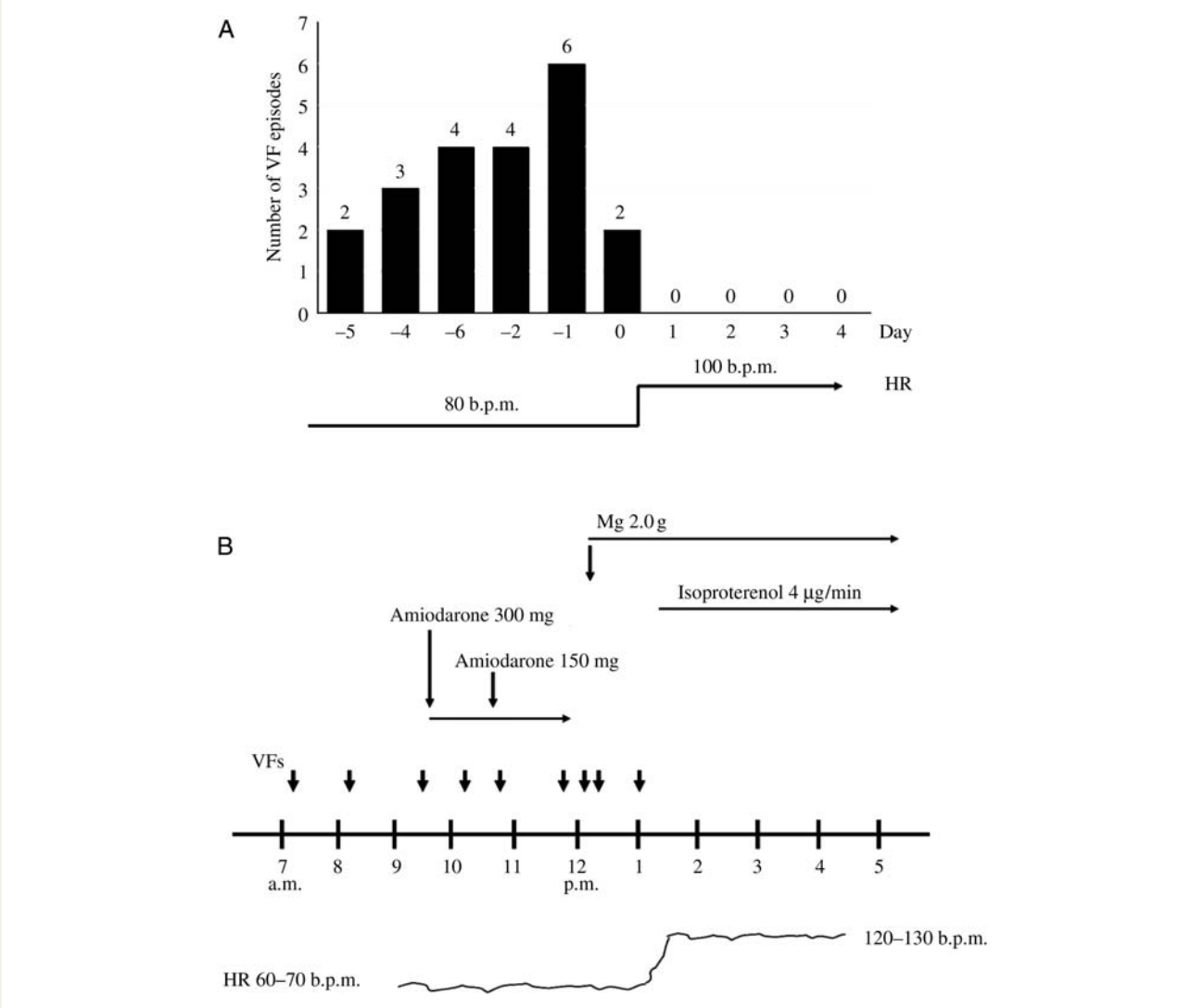

Figure 5 Effect of isoproterenol and pacing on the incidence of ventricular fibrillation (VF). (*A*) Effect of pacing on the incidence of ventricular fibrillation in patient 1. The patient underwent an implantable cardioverter defibrillator (ICD) implantation after an electrical storm in April 2002. Sixteen months later, she was hospitalized for a second electrical storm. On arrival at the emergency room, the ICD interrogation revealed multiple episodes of ventricular fibrillation from days −4 to −1. In the coronary care unit (day 0), the ventricular fibrillation episodes were completely suppressed after increasing the atrial pacing rate from 80 to 100 b.p.m. The bar graph shows the daily incidence of ventricular fibrillation. (*B*) The effects of the intravenous isoproterenol on the incidence of ventricular fibrillation in patient 3. The small thick arrows indicate the episodes of ventricular fibrillation. Amiodarone and magnesium were not effective in suppressing ventricular fibrillation. Infusion of isoproterenol at 4 μM/min increased the heart rate from 60 to 120 b.p.m. and completely suppressed ventricular fibrillation.

That VF episodes are more frequently initiated by SLS sequence or shorter coupling intervals in patients with IVF-ER is also consistent with a BrS phenotype. This important feature of VF initiation mechanism could potentially be applied in ICD programming to incorporate a pause-prevention algorithm.

Limitations

Potential limitations of our study include (i) the number of ER-VF patients is small and it is difficult to extrapolate the incidence of this phenomenon to the general idiopathic VF patient population; (ii) the control patient population used for the comparison of the incidence of ER was not matched with that of IVF patients with respect to age and sex. These limitations notwithstanding, the relatively low incidence of ER in the general population and the high incidence of ER in IVF patients and its dynamic manifestations just prior to the occurrence of ES suggest that this combination is a distinct arrhythmogenic marker of electrical instability.

Conclusions

Global accentuation of electrocardiographic J waves across the precordial and limb leads in patients with baseline ER pattern

can identify a subgroup of patients with structurally normal hearts but a highly arrhythmogenic substrate. Short–long–short sequence and PVCs with short coupling intervals were more frequently observed in these patients compared with those with BrS. These electrocardiographic features presage the occurrence of multiple VF episodes, necessitating the initiation of emergency management, and could also be applied in the ICD programming to prevent VF episodes by suppression of long pauses.

Acknowledgements

We thank Jeong-hae Kwon, Ji-hoi Yoon, and Ji-hyun Kim for their support with the preparation of this manuscript. We are grateful to Michel Haïssaguerre for helpful discussions.

Conflict of interest: none declared.

Funding

This study was supported in part by grants from the Asan Institute for Life Science 2006-232 (G.-B.N.), 2004-174 (Y.-H.K.), grant HL47678 from NIH (C.A.), and New York State and Florida Grand Lodges Free and Accepted Masons.

References

1. Wever EF, Robles de Medina EO. Sudden death in patients without structural heart disease. *J Am Coll Cardiol* 2004;**43**:1137–1144.
2. Wasserburger RH, Alt WJ. The normal RS-T segment elevation variant. *Am J Cardiol* 1961;**8**:184–192.
3. Mehta MC, Jain AC. Early repolarization on scalar electrocardiogram. *Am J Med Sci* 1995;**309**:305–311.
4. Gussak I, Antzelevitch C. Early repolarization syndrome: clinical characteristics and possible cellular and ionic mechanisms. *J Electrocardiol* 2000;**33**:299–309.
5. Geller JC, Reek S, Goette A, Klein HU. Spontaneous episode of polymorphic ventricular tachycardia in a patient with intermittent Brugada syndrome. *J Cardiovasc Electrophysiol* 2001;**12**:1094.
6. Daimon M, Inagaki M, Morooka S, Fukuzawa S, Sugioka J, Kushida S, Tateno K, Ozawa S. Brugada syndrome characterized by the appearance of J waves. *Pacing Clin Electrophysiol* 2000;**23**:405–406.
7. Kalla H, Yan GX, Marinchak R. Ventricular fibrillation in a patient with prominent J (Osborn) waves and ST segment elevation in the inferior electrocardiographic leads: a Brugada syndrome variant? *J Cardiovasc Electrophysiol* 2000;**11**:95–98.
8. Komiya N, Imanishi R, Kawano H, Shibata R, Moriya M, Fukae S, Doi Y, Nakao K, Seto S, Yano K. Ventricular fibrillation in a patient with prominent J wave in the inferior and lateral electrocardiographic leads after gastrostomy. *Pacing Clin Electrophysiol* 2006;**29**:1022–1024.
9. Shinohara T, Takahashi N, Saikawa T, Yoshimatsu H. Characterization of J wave in a patient with idiopathic ventricular fibrillation. *Heart Rhythm* 2006;**3**:1082–1084.
10. Riera AR, Ferreira C, Schapachnik E, Sanches PC, Moffa PJ. Brugada syndrome with atypical ECG: downsloping ST-segment elevation in inferior leads. *J Electrocardiol* 2004;**37**:101–104.
11. Shu J, Zhu T, Yang L, Cui C, Yan GX. ST-segment elevation in the early repolarization syndrome, idiopathic ventricular fibrillation, and the Brugada syndrome: cellular and clinical linkage. *J Electrocardiol* 2005;**38**(Suppl. 4):26–32.
12. Yan GX, Antzelevitch C. Cellular basis for the electrocardiographic J wave. *Circulation* 1996;**93**:372–379.
13. Haïssaguerre M, Derval N, Sacher F, Jesel L, Deisenhofer I, de Roy L, Pasquié JL, Nogami A, Babuty D, Yli-Mayry S, De Chillou C, Scanu P, Mabo P, Matsuo S, Probst V, Le Scouarnec S, Defaye P, Schlaepfer J, Rostock T, Lacroix D, Lamaison D, Lavergne T, Aizawa Y, Englund A, Anselme F, O'Neill M, Hocini M, Lim KT, Knecht S, Veenhuyzen GD, Bordachar P, Chauvin M, Jais P, Coureau G, Chene G, Klein GJ, Clémenty J. Sudden cardiac arrest associated with early repolarization. *N Engl J Med* 2008;**358**:2016–2023.
14. Rosso R, Kogan E, Belhassen B, Rozovski U, Scheinman MM, Zeltser D, Halkin A, Steinvil A, Heller K, Glikson M, Katz A, Viskin S. J-point elevation in survivors of primary ventricular fibrillation and matched control subjects: incidence and clinical significance. *J Am Coll Cardiol* 2008;**52**:1231–1238.
15. Nam GB, Kim YH, Antzelevitch C. Augmentation of J waves and electrical storms in patients with early repolarization. *N Engl J Med* 2008;**358**:2078–2079.
16. Antzelevitch C, Brugada P, Borggrefe M, Brugada J, Brugada R, Corrado D, Gussak I, LeMarec H, Nademanee K, Perez Riera AR, Shimizu W, Schulze-Bahr E, Tan H, Wilde A. Brugada syndrome: report of the second consensus conference: endorsed by the Heart Rhythm Society and the European Heart Rhythm Association. *Circulation* 2005;**111**:659–670.
17. Ikeda T, Sakurada H, Sakabe K, Sakata T, Takami M, Tezuka N, Nakae T, Noro M, Enjoji Y, Tejima T, Sugi K, Yamaguchi T. Assessment of noninvasive markers in identifying patients at risk in the Brugada syndrome: insight into risk stratification. *J Am Coll Cardiol* 2001;**37**:1628–1634.
18. Antzelevitch C. Cellular basis for the repolarization waves of the ECG. *Ann NY Acad Sci* 2006;**1080**:268–281.
19. Di Diego JM, Cordeiro JM, Goodrow RJ, Fish JM, Zygmunt AC, Perez GJ, Scornik FS, Antzelevitch C. Ionic and cellular basis for the predominance of the Brugada syndrome phenotype in males. *Circulation* 2002;**106**:2004–2011.
20. Takagi M, Aihara N, Takaki H, Taguchi A, Shimizu W, Kurita T, Suyama K, Kamakura S. Clinical characteristics of patients with spontaneous or inducible ventricular fibrillation without apparent heart disease presenting with J wave and ST segment elevation in inferior leads. *J Cardiovasc Electrophysiol* 2000;**11**: 844–848.
21. van den Berg MP, Wiesfeld AC. Brugada syndrome with ST-segment elevation in the lateral leads. *J Cardiovasc Electrophysiol* 2006;**17**:1035.
22. Liu DW, Gintant GA, Antzelevitch C. Ionic bases for electrophysiological distinctions among epicardial, midmyocardial, and endocardial myocytes from the free wall of the canine left ventricle. *Circ Res* 1993;**72**:671–687.
23. Litovsky SH, Antzelevitch C. Transient outward current prominent in canine ventricular epicardium but not endocardium. *Circ Res* 1988;**62**:116–126.
24. Antzelevitch C. Brugada syndrome. *Pacing Clin Electrophysiol* 2006;**29**: 1130–1159.
25. Yan GX, Antzelevitch C. Cellular basis for the Brugada syndrome and other mechanisms of arrhythmogenesis associated with ST segment elevation. *Circulation* 1999;**100**:1660–1666.
26. Di Diego JM, Antzelevitch C. Pinacidil-induced electrical heterogeneity and extrasystolic activity in canine ventricular tissues. Does activation of ATP-regulated potassium current promote phase 2 reentry? *Circulation* 1993;**88**:1177–1189.
27. Calloe K, Cordeiro JM, Di Diego JM, Hansen RS, Grunnet M, Olesen SP, Antzelevitch C. A transient outward potassium current activator recapitulates the electrocardiographic manifestations of Brugada syndrome. *Cardiovasc Res* 2009;**81**:686–694.
28. Haïssaguerre M, Chatel S, Sacher F, Weerasooriya R, Probst V, Loussouarn G, Horlitz M, Liersch R, Schulze-Bahr E, Wilde A, Kaab S, Koster J, Rudy Y, Le MH, Schott JJ. Ventricular fibrillation with prominent early repolarization associated with a rare variant of KCNJ8/K_{ATP} channel. *J Cardiovasc Electrophysiol* 2009;**20**:93–98.
29. Kasanuki H, Ohnishi S, Ohtuka M, Matsuda N, Nirei T, Isogai R, Shoda M, Toyoshima Y, Hosoda S. Idiopathic ventricular fibrillation induced with vagal activity in patients without obvious heart disease. *Circulation* 1997;**95**:2277–2285.
30. Matsuo K, Shimizu W, Kurita T, Inagaki M, Aihara N, Kamakura S. Dynamic changes of 12-lead electrocardiograms in a patient with Brugada syndrome. *J Cardiovasc Electrophysiol* 1998;**9**:508–512.