Brain (1999), **122,** 1889–1899

Modified activation of somatosensory cortical network in patients with right-hemisphere stroke

Nina Forss,[1] Marja Hietanen,[2] Oili Salonen[3] and Riitta Hari[1,2]

[1]*Brain Research Unit, Low Temperature Laboratory, Helsinki University of Technology, Espoo and* [2]*Department of Clinical Neurosciences and* [3]*Department of Radiology, Helsinki University Central Hospital, Helsinki, Finland*

Correspondence to: Nina Forss, Brain Research Unit, Low Temperature Laboratory, Helsinki University of Technology, PO Box 2200, FIN-02015 HUT, Espoo, Finland

Summary

To study the effects of parietal lesions on activation of the human somatosensory cortical network, we measured somatosensory evoked fields to electric median nerve stimuli, using a whole-scalp 122-channel neuromagnetometer, from six patients with cortical right-hemisphere stroke and from seven healthy control subjects. In the control subjects, unilateral stimuli elicited responses which were satisfactorily accounted for by modelled sources in the contralateral primary (SI) and bilateral secondary (SII) somatosensory cortices. In all patients, stimulation of the right median nerve also activated the SI and SII cortices of the healthy left hemisphere. However, the activation pattern was altered, suggesting diminished interhemispheric inhibition via callosal connections after right-sided stroke. Responses to left median nerve stimuli showed large interindividual variability due to the different extents of the lesions. The strength of the 20-ms response, originating in the SI cortex, roughly reflected the severity of the tactile impairment. Right SII responses were absent in patients with abnormal right SI responses, whereas the left SII was active in all patients, regardless of the responsiveness of the right SI and/or SII. Our results suggest that the human SI and SII cortices may be sequentially activated within one hemisphere, whereas SII ipsilateral to the stimulation may receive direct input from the periphery, at least when normal input from SI is interrupted.

Keywords: magnetoencephalography; ischaemia; somatosensory system; cortex; human

Abbreviations: g = goodness-of-fit; MEG = magnetoencephalography; SI = primary somatosensory cortex; SII = secondary somatosensory cortex; SEF = somatosensory evoked field

Introduction

Cerebral ischaemia often results in varying degrees of motor and sensory disturbances. Somatosensory evoked potentials have been applied to assess the extent and location of the acute damage and to predict the functional outcome of stroke patients (La Joie *et al.*, 1982; Pavot *et al.*, 1986; Macdonell *et al.*, 1991). These studies have concentrated on changes in the early somatosensory evoked potentials, recorded with a few electrodes on the scalp contralateral to the stimulated limb. Therefore, the observations have been restricted to functions of subcortical pathways and of the primary somatosensory cortex (SI). However, several cortical parietal regions outside the SI cortex participate in the processing of somatosensory information (Penfield and Jasper, 1954; Woolsey *et al.*, 1979; Hyvärinen, 1982; Burton, 1986; Burton *et al.*, 1997), although the functional roles as well as the hierarchical organization of these regions are not yet fully understood. Thus, patients with cortical ischaemic lesions offer a unique opportunity to study the functional connectivity of the human somatosensory cortical areas.

Magnetoencephalographic (MEG) recordings allow non-invasive monitoring of several simultaneously active brain areas all over the cortex with excellent temporal and reasonable spatial resolution. Our prior neuromagnetic recordings have demonstrated activity in the primary and secondary (SII) somatosensory cortices, as well as in the posterior parietal cortex (Hari *et al.*, 1984, 1993; Forss *et al.*, 1994, 1996). In the present study, we employed a whole-scalp 122-channel neuromagnetometer to assess the effects of cortical ischaemic lesions on activation of the somatosensory cortical network.

Material and methods

Patients

Patients gave informed consent to participation in this study, which was approved by the ethical committee of the Department of Clinical Neurosciences at the Helsinki

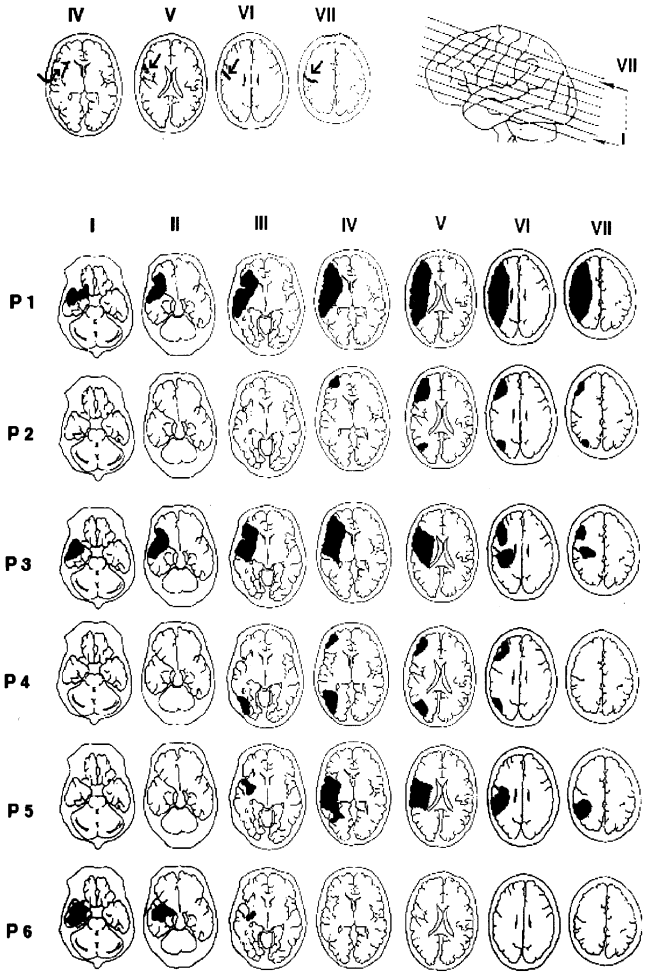

Fig. 1 Schematic drawing of the lesions in each patient. The same sections (I–VII) are shown for all patients. In the upper part of the figure the sites of central (straight arrow, sections V–VII) and sylvian fissures (curved arrow, section IV) are shown. Note that the left side of the brain is shown on the right and vice versa

University Central Hospital. Somatosensory evoked fields (SEFs) were recorded from six patients with right-hemisphere stroke (five males, one female, aged 45–65 years; patient 1 was left-handed, all others were right-handed) and from seven healthy control subjects (three males, four females, aged 46–61 years, all right-handed). The patients were selected in co-operation with the Rehabilitation Division of the Department of Clinical Neurosciences of the Helsinki University Central Hospital. None of the patients had any neurological deficits prior to the stroke. All patients had a lesion in the territory of the right middle cerebral artery; three patients had a stroke and three other patients (patients 1, 3 and 6) had subarachnoidal bleeding caused by a ruptured arterial aneurysm, followed by arterial spasm and cortical ischaemic lesion. MRI or CT was obtained to assess the location and extent of the lesion. Figure 1 illustrates schematically the extent of the lesion in each patient. The schematic drawings were prepared by an experienced neuroradiologist on the basis of CT scans and MR images; the central and sylvian fissures are also identified on the slices.

The patients showed varying degrees of sensorimotor disturbances of the left limbs and suffered from the neglect syndrome, with inattention to the left hemispace. Neglect syndrome was diagnosed by an experienced neuropsychologist on the basis of several visual and visuospatial tests, e.g. clock drawing, block design (subtest of the Wechsler Adult Intelligence Scale) and picture compilation. The somatosensory deficit was assessed by clinical tests routinely used in neurological examination: tests of proprioception, vibration, and light, sharp and dull touch. Table 1 summarizes the clinical data of the patients, and a more detailed description of the patients follows.

Patient 1

This patient was a 44-year-old male who suffered from a ruptured aneurysm of the medial cerebral artery followed by infarction of the right temporoparietal lobes. In the acute stage he was conscious and able to answer questions briefly. Head and gaze were turned to the right, suggesting a neglect syndrome. The left upper limb was totally paralysed, but some proximal activity was preserved in the left lower limb. Proprioceptive and tactile sensitivities were strongly decreased in the left arm, and he only perceived a strong touch of the whole extremity. At the time of the MEG measurement, the patient was able to walk without support, but his left arm was still useless. He was still suffering from neglect syndrome, with difficulty in attending to left-sided stimuli. The tactile sensitivity of the left upper limb was not changed from the acute stage.

Patient 2

This patient was a 63-year-old man who experienced numbness and weakness of the left upper limb. During the acute stage, grip force of left hand was decreased, tactile sensitivity of the left arm and left side of the upper body was reduced and the patient had slight inattention to the left hemispace. There were no symptoms in the lower limbs. At the time of the MEG measurement, the arm strength and tactile sensitivity had returned to the normal levels but fine motor skills were worse in the left than in the right fingers.

Patient 3

This patient was a 45-year-old male who had a ruptured aneurysm of the medial cerebral artery followed by infarction of the right frontotemporoparietal lobes. During the acute stage he was unconscious and had a complete left hemiparesis. After he gained consciousness, his head was turned to the right and he showed signs of neglect syndrome. At the time of the MEG measurements he used a wheelchair but was able to take few steps when aided. Clear inattention to the left side of the body prevailed. Proprioceptive sensitivity was

Table 1 *Neurological symptoms and MRI/CT findings of the patients*

Patient	Age (years)/sex	Lesion	Arm strength	Fine motor control	Tactile sensation
1	44/M	SAV, infarct	↓↓	↓↓	↓↓
2	63/M	Arteria cerebri media infarct	N	↓	N
3	45/M	SAV, infarct	↓	↓↓	↓
4	49/M	Arteria cerebri media infarct	↓	↓	↓
5	57/M	Arteria cerebri media infarct	↓	↓	N
6	61/F	SAV, infarct	N	↓	N

N = normal; ↓ = decreased; ↓↓ = strongly decreased; SAV = subarachnoid haemorrhage.

decreased in the upper limb, and he was able to distinguish touch but not locate it precisely in the distal part of the upper limb.

Patient 4

This patient was a 49-year-old male who suddenly experienced difficulty in using his left hand purposefully. Shortly afterwards, the left upper limb lost its strength and paresis of the left facial nerve developed. Proprioceptive sensitivity of his left upper limb was decreased and he could not reliably locate a light touch. He also showed signs of inattention to the left half of the body. By the time of the MEG measurements neglect was still observable, but the patient coped independently in everyday life. Strength of the left upper limb was improved but the left hand was weaker than the right; it was also clumsy and dyspractic. He still had difficulty in identifying hand postures, and his tactile sensitivity, although improved, was not totally recovered.

Patient 5

This patient was a 57-year-old male who experienced sudden weakness of the left upper arm. During the acute stage, he had paralysis of the left facial nerve and slightly decreased strength, numbness and clumsiness of the left upper limb. He also had inattention to the left hemispace. During the MEG measurements he did not report any disturbances in tactile sensitivity, but otherwise the symptoms were very similar to those in the acute stage.

Patient 6

This patient was a 61-year-old female who suffered from a ruptured aneurysm of the medial cerebral artery followed by infarction of the right temporoparietal lobe. In the acute stage she was unconscious and had complete left hemiparesis. By the time of the MEG measurements she had signs of neglect syndrome but was able to walk unsupported. The strength of her left upper limb was reduced and her left hand was dyspractic and clumsy. She reported no deficits in tactile sensitivity.

MEG recordings

During the MEG recording, the patient was sitting comfortably in a magnetically shielded room with the head supported against the helmet-shaped sensor array of the magnetometer. The left and right median nerves were stimulated in subsequent runs with 0.3-ms constant current pulses, delivered with bipolar electrodes at the wrist with an interstimulus interval of 3 s. Although electric stimuli are non-specific in the sense that they stimulate different fibre types, we used them because they elicit robust and reliable responses with a good signal-to-noise ratio. Subjects were instructed to relax the stimulated hand and to support it on the elbow rest of a chair. Individual stimulus intensities varied from 5 to 10 mA and were adjusted to produce a thumb twist without causing discomfort. The intensity was kept fixed after the initial adjustment throughout the measurement session.

SEFs were recorded with a helmet-shaped Neuromag-122™ magnetometer array, which has 122 planar first-order SQUID gradiometers, placed at 61 measurement sites (Ahonen *et al.*, 1993). Each sensor unit contains a pair of gradiometers that measure two orthogonal tangential derivatives of the magnetic field component normal to the helmet surface at the sensor location. The planar gradiometers detect the largest signal just above the local source area, where the field gradient has its maximum. The exact location of the head with respect to the sensors was found by measuring magnetic signals produced by currents in three head position indicator coils, placed at known sites on the scalp. The locations of the coils with respect to anatomical landmarks on the head were determined with a three-dimensional digitizer to allow alignment of the MEG and MRI coordinate systems.

The signals were bandpass-filtered through 0.03–320 Hz and digitized at 0.9 kHz, and ~200 single responses were averaged on-line. The analysis period of 400–500 ms included a prestimulus baseline of 50–100 ms. Responses coinciding with amplitudes >150 μV in the simultaneously recorded vertical electro-oculogram were automatically rejected from the analysis.

Data analysis

To identify sources of the measured evoked responses, deflections exceeding the noise level (~5 fT/cm) were first

identified visually in order to select the time windows and cortical areas of interest for further analysis. During these time periods (from the beginning of the deflection to its return to the baseline level) the magnetic field patterns were first visually studied in 2-ms steps to create the initial estimate of the number of active sources within that time period and to estimate the stability of the magnetic field pattern. Then the equivalent current dipole that best described a local source current at the peak of the response was found by a least-squares search using a subset of channels (usually 16–18) over the response area. These calculations resulted in the three-dimensional location, orientation and strength of the equivalent current dipole in a spherical conductor. Goodness-of-fit (g) of the model was also calculated to ascertain what percentage of the measured signal variance was accounted for by the dipole; only equivalent current dipoles with $g \geqslant 85\%$ at selected periods of time in the subset of channels were used for the further analysis.

After identifying the single dipoles (3–4 in total for each subject), the analysis was extended to the whole signal duration and all channels were taken into account in computing a time-varying multi-dipole model. The validity of the multi-dipole model was evaluated by comparing the measured signals with responses predicted by the model. If signals of any brain region were inadequately explained by the model, the data were re-evaluated for more accurate estimation of the generator areas. To quantify how well the multi-dipole model accounted for the measured data, the g values were calculated across all 122 channels and over the entire time period, and a comparison was made between different models with the same number of dipoles to find the best possible solution. This approach, explained in detail by Hämäläinen and colleagues (Hämäläinen *et al.*, 1993), has been used successfully in several previous studies of the somatosensory cortical network. For a good example of the stepwise procedure in identifying several, partly overlapping sources, see the study by Forss and colleagues (Forss *et al.*, 1994), which illustrates the identification of SI, SII and posterior parietal cortex sources.

MRIs of control subjects were acquired with a 1.5 T Siemens Magnetom™ scanner. A set of 128 coronal slices (thickness 1.3 mm) was used for rendering the three-dimensional image of the brain's surface.

The statistical significance of the results was tested by Student's paired two-tailed t test.

Results

Figure 2 shows SEFs of two control subjects and patient 1 to right median nerve stimuli. In the control subject, distinct local amplitude extremes at different moments of time suggest several generator areas in the cortex. The earliest signal (N20m) peaked at ~20 ms over the left anterior parietal cortex and was followed by deflections of opposite polarity at ~38 ms (P35m) and 50 ms (P50m). Longer latency responses peaked bilaterally over the temporoparietal cortices and over the left posterior parietal cortex at 80–90 ms.

As illustrated in Fig. 1, patient 1 had a large ischaemic lesion extending from the superior parts of the right parietal lobe to the temporal lobe, and accordingly the SEFs of patient 1 revealed clear abnormalities. The earliest signals peaked over the left anterior parietal cortex, as in the control subject, but there was no clear response over the posterior parts of the parietal cortex. The ipsilateral (right) hemisphere was completely silent, with no activity comparable with that observed in the control subject. On the other hand, the long-latency response over the left temporoparietal cortex (Fig. 2C) was about three times as large as in the control subject.

In agreement with earlier MEG studies, a four-dipole model yielded an adequate explanation of the response patterns. Figure 3 shows, for the control subject, the locations and orientations of the modelled source areas, superimposed on the surface rendering of her brain; note that in the following all sources of MEG signals refer to modelled source locations. The sources of the earliest responses, N20m and P35m, were in the postcentral wall of the central fissure, presumably in area 3b of the SI cortex (Hari *et al.*, 1984, 1990; Wood *et al.*, 1985; Allison *et al.*, 1989*a*; Baumgartner, 1993). The P35m dipole also explained the largest peak at ~50 ms (P50m). The source of the more posterior response was in the wall of the postcentral fissure in the posterior parietal cortex, presumably in Brodmann area 5 or 7 (Forss *et al.*, 1994). The sources of the lateral parietal responses were in the upper lips of the sylvian fissures in the parietal opercula, in line with several earlier MEG studies (Hari *et al.*, 1984, 1990, 1993; Forss *et al.*, 1994, 1996). Although the parietal operculum of the monkey and most likely the human consists of at least two different somatotopic body maps (Robinson and Burton, 1980; Krubitzer *et al.*, 1995), we refer to this source area as SII, mostly because of its bilateral activity and its consistency in location with earlier reports on the location of human SII (Penfield and Jasper, 1954; Woolsey *et al.*, 1979).

Figure 3 also illustrates the magnetic field patterns of the control subject and the patient during the peaks of the responses, and the temporal behaviour of the active areas. Note that these signals illustrate source strengths as a function of time and not the measured magnetic field gradients as in Fig. 2. In the control subject, the signal of the SI cortex dominated during the first 50 ms and was then followed by temporally overlapping SII and posterior parietal cortex signals which reached their peaks at ~90 ms. In the patient, the N20m response was observed with normal latency and amplitude in the intact left hemisphere, but it was clearly prolonged and W-shaped; P35m appeared to be slightly diminished. No dipolar fields were found over the posterior parietal cortex and the ipsilateral SII cortex. On the contrary, the strength of the contralateral (left) SII response was 2.5 times that of the control subject.

In the following we focus on the SI and SII responses, which were found in all subjects, whereas posterior parietal

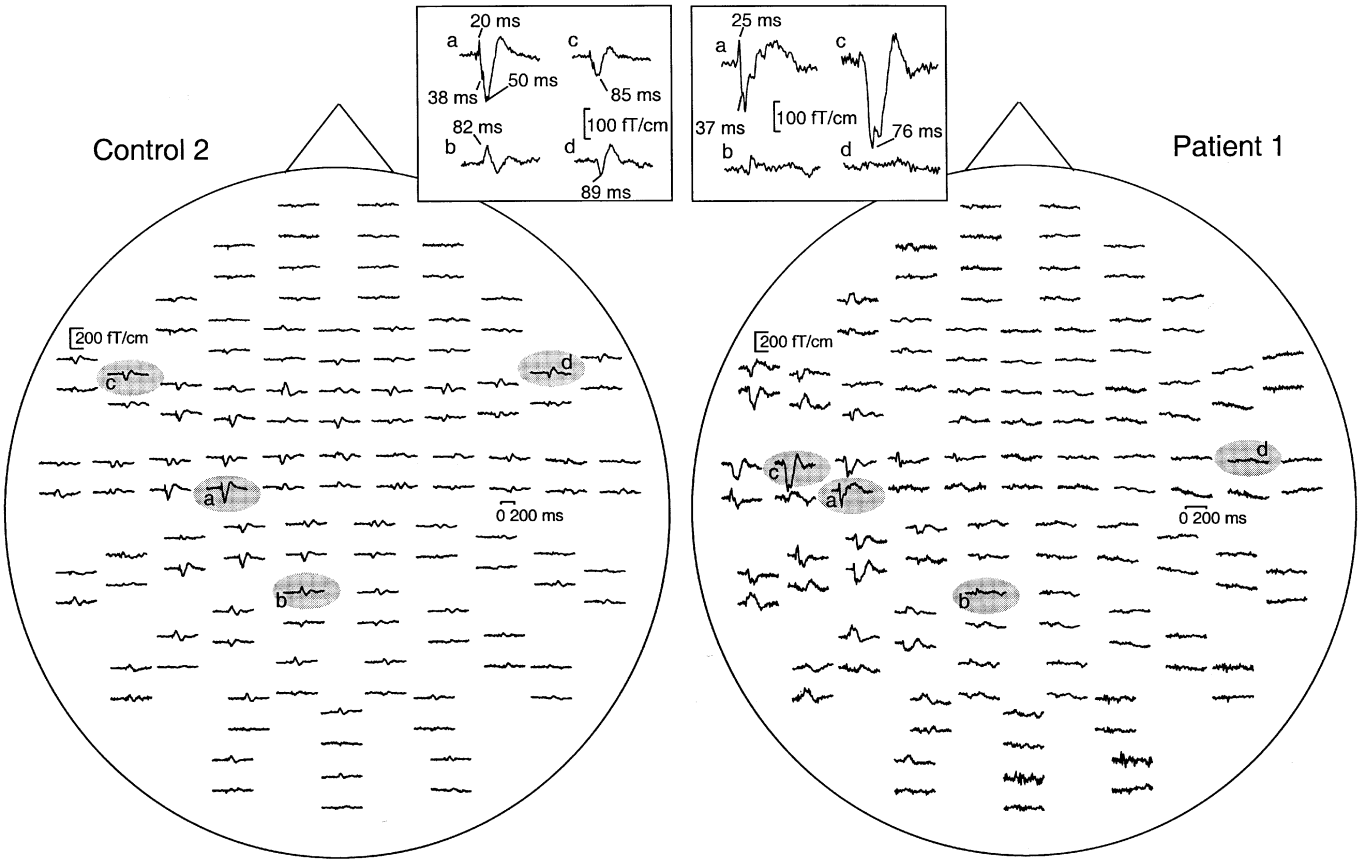

Fig. 2 Diagram of the SEFs of control subject 2 and patient 1 to right median nerve stimuli. The head is viewed from the top, and in each response pair the upper trace illustrates the field derivate along the latitude and the lower trace along the longitude. The inserts show enlarged responses from shaded areas a–d. Interstimulus interval was 3 s, passband 0.03–320 Hz.

cortex responses were reliably found only in five out of seven controls and two out of six patients (patients 3 and 5).

Responses to right median nerve stimuli

Figure 4 shows the temporal behaviour of the sources in the left SI and in both SII cortices after right median nerve stimuli for all control subjects. N20m and P35m were easily identified in all subjects, whereas P50m was highly variable in amplitude and in duration. However, the P35m source consistently explained the P50m in all subjects. All subjects showed both contra- and ipsilateral SII responses to right median nerve stimuli. Table 2 summarizes the mean amplitudes and latencies of the SI and SII responses.

Figure 5 shows the corresponding temporal responses of the SI and SII sources to right median nerve stimuli in patients. The SI responses were altered even in the intact left hemisphere; N20m was observed in all patients, but in three patients (patients 1, 4 and 5) it was wider than usual, lasting 15–25 ms, and interrupted by a small deflection of opposite polarity, resulting in a W-shaped response. In patient 6, all SI components were very strong, and the component following N20m had already peaked at 27 ms; thus its relation to P35m remains uncertain. In patients 1–5, P35m was significantly smaller than in the controls (on average 15.0 versus 32.6 nAm, $P < 0.01$). More detailed comparison of the waveforms of the left SI signals (Fig. 6) shows that N20m and P35m were easily identifiable in the controls, whereas the variance of all SI deflections was obvious in the patient group.

Figure 5 also shows that all patients had contralateral (left) SII responses to right median nerve stimuli, as did the control subjects. The contralateral SII response was exceptionally large (97 nAm) in patient 1 compared with the mean value of the controls (41.7 ± 6 nAm). The ipsilateral (right) SII was activated in four patients (patients 2, 3, 4 and 6); in patient 3 the waveform differed from the usual response and showed merely oscillatory activity in the SII region.

Responses to left median nerve stimuli

As expected, all control subjects showed contralateral SI and bilateral SII responses to left median nerve stimuli, with latencies and amplitudes similar to those of the responses to right median nerve stimuli (Fig. 7, Table 2). In line with earlier observations (Forss *et al.*, 1994), the left hemisphere SII responses were on average 35–77% stronger than right

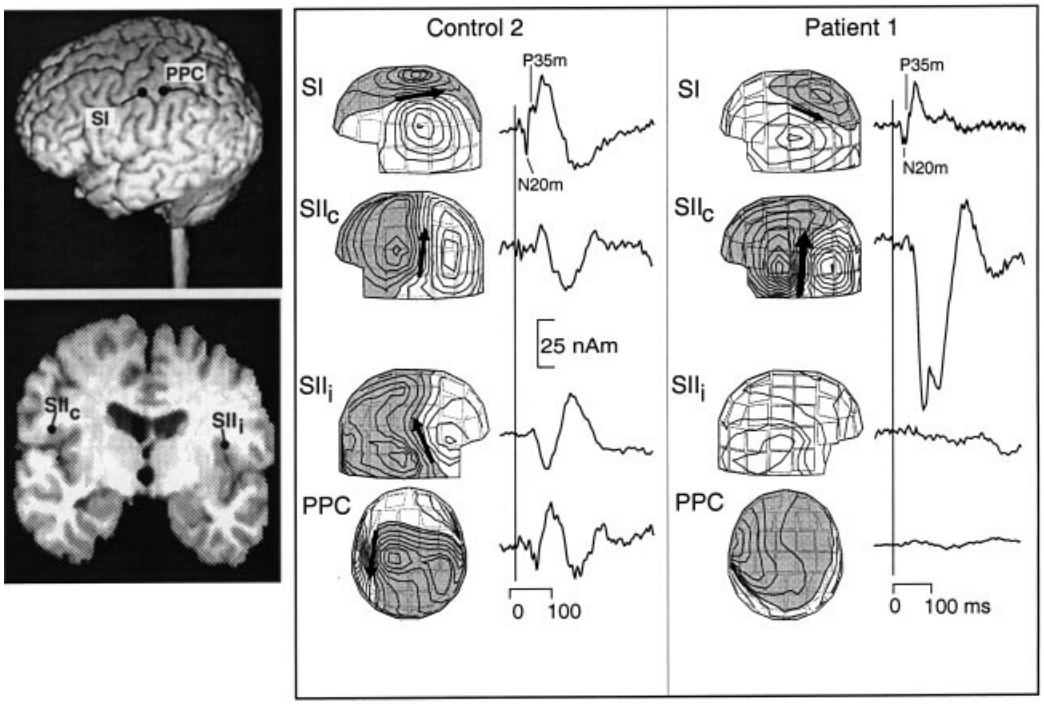

Fig. 3 *Left*: source locations for the control subject 2 superimposed on the three-dimensional rendering of her brain (*top*) and on a sagittal slice of MRI (*bottom*). *Right*: strengths from the SI, contra- and ipsilateral SII and posterior parietal cortex sources of the control subject 2 and of patient 1 as a function of time in nanoampere metres. PPC = posterior parietal cortex; SII_c = contralateral SII; SII_i = ipsilateral SII.

SII responses, regardless of the side of the stimulation (41.7 ± 5 nAm versus 31.0 ± 9 nAm and 42.0 ± 7 nAm versus 23.7 ± 7 nAm to contra- and ipsilateral stimulation, respectively). In patients the situation was different (Fig. 8): both SI and right SII responses showed large variability due to the different extents of the lesions. Patient 1 had no activity in the right SI cortex, whereas in patients 2 and 6, who had lesions sparing the SI hand area, all right-sided SI components were strong. The earliest responses were greatly diminished or deformed in patients 3 and 4, whereas patient 5 had an extended N20m response but no P35m, and instead of P50m a large response was observed at 70 ms.

Although the ischaemic lesion seemed to extend to the right lateral fissure only in patients 1 and 3, the right (contralateral) SII response was present only in patients 2 and 6. The right SII response was consistently lacking in patients with an abnormal or absent right SI response. On the contrary, ipsilateral (left) SII responses were observed in all patients regardless of the absence of contralateral SI and/or SII responses. In patients 2 and 6 the ipsi- and contralateral SII responses, as well as the SI responses, were both comparable with their strengths in control subjects.

Here the data of patient 1 are of particular interest. He had a large ischaemic lesion extending to the right central and sylvian fissures, and thus no signals were observed in the right SI or right SII area. However, a broad left (ipsilateral) SII response peaked at 120 ms with a clearly dipolar field pattern. The orientation and location of this source was very similar to that of the left SII source to right median nerve stimuli, assuring its correspondence to activation of the left SII cortex.

Figure 9 shows the amplitude of the right N20m in all patients plotted against the severity of their tactile impairment. Patient 1, who had severe impairment of tactile sense, had no activity in the right SI cortex. Patients 2 and 6, who had lesions in the parieto-occipital and parietotemporal cortices sparing the SI hand region, showed strong SI components and, correspondingly, at the time of recordings showed no signs of impairment in tactile sensitivity. Patient 5 had slightly reduced amplitude of N20m but he did not report any deficits in tactile sensation. Patients 3 and 4, who had mild to moderate tactile impairments of the left hand, had negligible N20m responses.

Discussion

In the present study we compared the activation of the cortical somatosensory network to median nerve stimuli in healthy controls with that in patients having an ischaemic cortical lesion in the territory of the right middle cerebral artery. Although the lesions and resulting changes in evoked responses showed remarkable interindividual variability, some important information can be extracted from these data.

Source modelling

Source modelling of MEG or EEG response patterns has no unique solution. However, the modelled source locations of

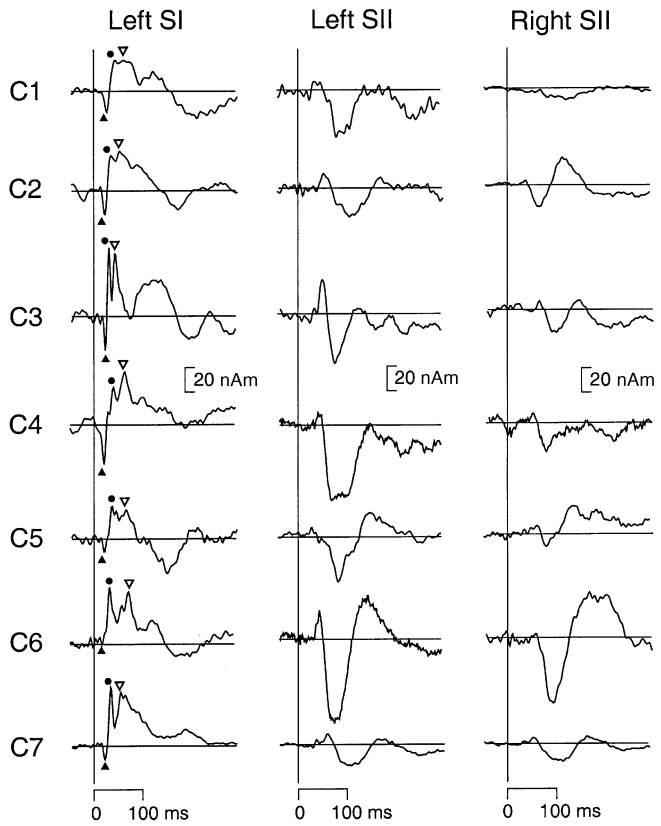

Fig. 4 Source strengths in left SI and both SII cortices (in nanoampere metres) of all control subjects to right median nerve stimuli. Filled triangles = N20m; filled circles = P35m; open triangles = P50m.

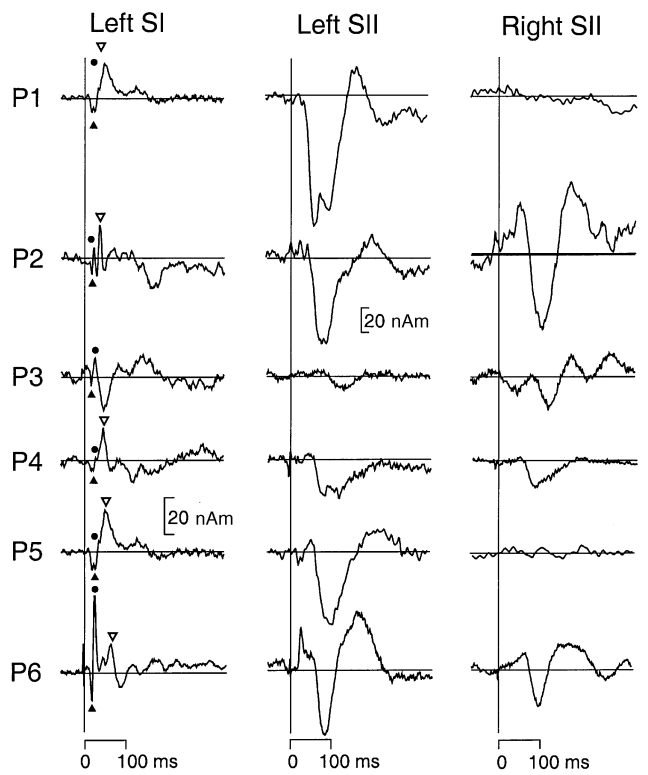

Fig. 5 Source strengths in left SI and both SII cortices (in nAm) of all patients to right median nerve stimuli. In patient 1 the locations of right SI and SII were estimated by mirroring the locations of left-sided SI and SII to the right hemisphere. Filled triangles = N20m; filled circles = P35m; open triangles = P50m.

Table 2 *Mean ± SEM latencies and amplitudes of the SI and SII responses of the control subjects to right and left median nerve stimuli*

	Right median nerve		Left median nerve	
	Latency (ms)	Amplitude (nAm)	Latency (ms)	Amplitude (nAm)
SI				
N20m	21.4 ± 0.7	15.4 ± 2.1	22.1 ± 1.0	15.4 ± 2.2
N35m	35.6 ± 1.5	32.6 ± 4.9	36.8 ± 1.4	33.4 ± 6.4
SII_c	93.0 ± 3.3	41.7 ± 5.6	91.0 ± 4.5	31.0 ± 9.0
SII_j	103.0 ± 6.4	23.7 ± 6.9	96.0 ± 2.8	42.0 ± 7.3

the most prominent responses, consistently reported in several previous MEG studies (Hari *et al.*, 1993; Forss *et al.*, 1994; Kakigi *et al.*, 1995; Huttunen *et al.*, 1996) agree well with the sites of the SI and SII areas found in monkeys (Hyvärinen 1982; Burton, 1986) and in human functional MRI and PET data (Lin *et al.*, 1996; Burton *et al.*, 1997). Moreover, source areas and the temporal behaviour of the magnetic SI and SII responses are in good agreement with human intracranial recordings (Sutherling *et al.*, 1988; Allison *et al.*, 1989*a*, *b*; Baumgartner, 1993, Mauguière, 1997), demonstrating that short-latency activity is generated in SI and long-latency activity both in SI and SII.

In control subjects, unilateral stimuli elicited responses that were consistent with the activation of the contralateral SI cortex and the SII cortices of both hemispheres. The longer-latency SI response P50m was more variable and the field patterns were not as stable as for the earlier SI responses N20m and P35m. Electric recordings have suggested a strong contribution from radial currents to this component, which may explain the variability of the magnetic response.

The absence of the posterior parietal cortex response in most of our neglect patients is an interesting observation and may be linked to the underlying mechanism of the neglect syndrome; however, since this response is not consistently identified in all healthy subjects either (Forss *et al.*, 1994) and was absent in two out of seven control subjects in the

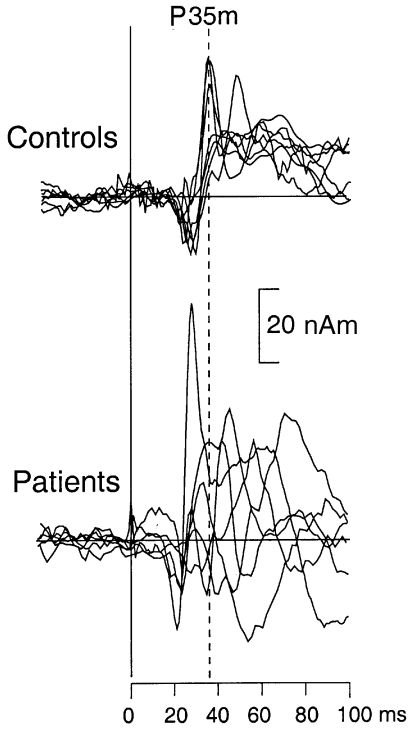

Fig. 6 Superimposed responses from the left SI for all subjects (*top*) and patients (*bottom*) to right median nerve stimuli.

present study, the relevance of this observation in neglect syndrome cannot be ascertained.

Responses of the healthy hemisphere

In all patients, right median nerve stimuli elicited responses consistent with the activation of the SI and SII cortices of the healthy left hemisphere. In patients 2 and 6, both SI and SII responses were similar or enhanced compared with the control subjects; in these two patients the lesion has probably spared both the SI hand area and the right SII. However, N20m was prolonged in three patients and P35m was diminished in five. These changes in the SI responses suggest that unilateral stroke also affects the activity of the healthy hemisphere, for example via callosal connections; decreased activation in the lesioned cortex may result in increased activation in the SI cortex of the other hemisphere, due to decreased callosal inhibition. Similarly, a unilateral stroke has been shown to significantly increase the electric N20–P28 deflection in the healthy hemisphere (Reisecker *et al.*, 1986).

SEFs and tactile disorder

In line with earlier studies (La Joie *et al.*, 1982; Reisecker *et al.*, 1986; Knecht *et al.*, 1996), the strength of the SI component in the affected hemisphere correlated with the severity of the tactile disorder. Normal tactile sense of the left hand was associated with amplitudes of N20m that were comparable with those of controls, whereas diminished amplitudes were related to impaired tactile sensitivity.

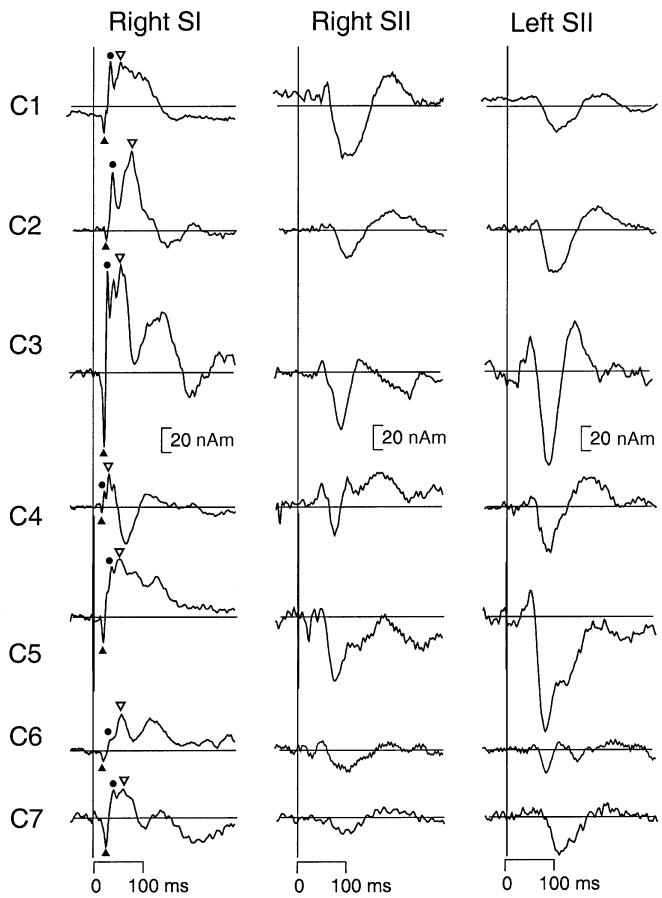

Fig. 7 Source strengths in right SI and both SII cortices (in nAm) of all control subjects to left median nerve stimuli. Filled triangles = N20m; filled circles = P35m; open triangles = P50m.

However, the limited number of patients studied prevents more detailed analysis of this relationship.

SII lesions have been suggested to be associated with impaired tactile recognition of objects (Caselli *et al.*, 1993). On the other hand, somatosensory evoked potentials from the SI cortex are consistently abnormal in patients with tactile agnosia (Mauguière and Isnard, 1995). In the present study SII dysfunction was always associated with abnormal SI responses in the damaged hemisphere, and therefore the specific role of SII in tactile recognition could not be demonstrated.

Functional organization of the somatosensory cortices

In addition to cortical input from the SI cortex, the SII cortex receives input via commissural connections from the contralateral SII (Jones and Powell, 1969; Burton, 1986). Histoanatomical studies have indicated that the SII areas also receive direct input from the periphery via thalamic nuclei (ventroposterolateral and ventroposteroinferior nuclei). The relative importance of direct thalamocortical connections to SII versus intracortical connections from SI has remained

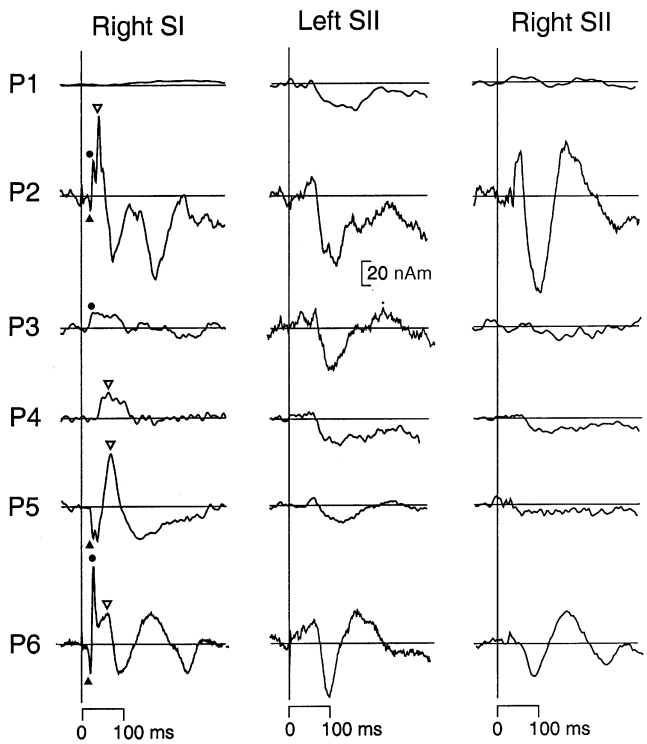

Fig. 8 Source strengths in right SI and both SII cortices (in nA) of all patients to left median nerve stimuli. Other details as in Fig. 5. Filled triangles = N20m; filled circles = P35m; open triangles = P50m.

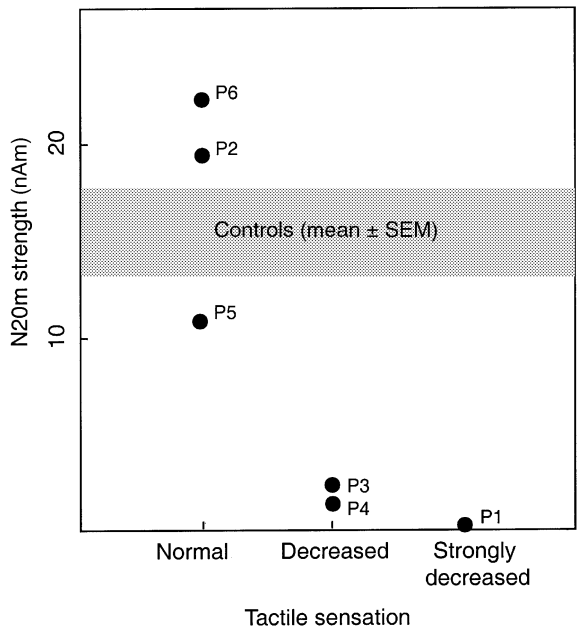

Fig. 9 Strength of the N20m response to left median nerve stimuli plotted against the severity of tactile symptoms in the patients. The stippled band in the middle illustrates the mean ± SEM strength of N20m in controls.

obscure, and therefore serial versus parallel processing of somatosensory information between SI and SII cortices is under extensive debate (Pons *et al.*, 1987, 1992; Rowe *et al.*, 1996). Different species have been shown to have different organization of the somatosensory system, ranging from independent parallel activation of the somatosensory areas in prosimian primates to SI-dependent serial activation in macaque monkeys (Garraghty *et al.*, 1991; Pons *et al.*, 1992). However, conflicting results favouring parallel organization of the monkey SI and SII cortices have been reported recently (Zhang *et al.*, 1996).

In humans, the earliest SI signal typically peaks 20 ms after upper limb stimulation, and may continue for 150 ms. Activation of the SII areas typically begins at ~60–80 ms and continues up to 200 ms (Allison *et al.*, 1989*b*; Forss *et al.*, 1994; Mauguière *et al.*, 1997). Such timing would agree with serial processing of somatosensory information via SI to SII area and, thereafter, to the SII area of the opposite hemisphere. In the present study, right hemisphere SII responses to left median nerve stimuli were absent in all patients with abnormal or absent right SI (patients 1, 3, 4 and 5). As the ischaemic lesion was likely to extend to the right lateral fissure in patients 1 and 3 only, these findings may represent evidence for sequential activation of SI and SII within the same hemisphere.

In contrast, ipsilateral (left) SII responses to left median nerve stimuli were found in all patients, regardless of the responsiveness of the right SI and/or SII; data for four patients (patients 1, 3, 4 and 5) indicate that the human ipsilateral SII areas are not necessarily dependent on activation of the contralateral SII. Further, in patient 1 both SI and SII cortices of the right hemisphere were silent, but a clear ipsilateral (left) SII response was still found. These results imply the possibility of parallel processing of somatosensory information in the human contralateral SI and ipsilateral SII cortices, at least under circumstances in which normal input from the contralateral SI is interrupted.

We therefore suggest that the human SI and SII cortices within one hemisphere are activated sequentially, whereas the SII cortex ipsilateral to the stimulated side receives parallel input directly via thalamic connections.

The present study showed that activity of different parts of the somatosensory cortex can be separated with MEG recordings. As a large cortical network in the parietal lobe participates in the processing of somatosensory input, it is likely that changes in any part of the system are reflected in the clinical symptoms of the patient. Therefore, subsequent studies with a larger number of patients should aim to relate the clinical symptoms to lesions in various parts of the somatosensory network in order to explore the complex functional organization of the entire cortical somatosensory network.

Acknowledgements

We wish to thank Ms Mia Illman for skilful technical assistance. MRIs were obtained from the Department of Radiology of Helsinki University Central Hospital. This study was financially supported by the Academy of Finland.

References

Ahonen AI, Hämäläinen MS, Kajola MJ, Knuutila JET, Laine PP, Lounasmaa OV, et al. 122-channel SQUID instrument for investigating the magnetic signals from the human brain. Physica Scripta 1993; T49: 198–205.

Allison T, McCarthy G, Wood CC, Darcey TM, Spencer DD, Williamson PD. Human cortical potentials evoked by stimulation of the median nerve. I. Cytoarchitectonic areas generating short-latency activity. J Neurophysiol 1989a; 62: 694–710.

Allison T, McCarthy G, Wood CC, Williamson PD, Spencer DD. Human cortical potentials evoked by stimulation of the median nerve. II. Cytoarchitectonic areas generating long-latency activity. J Neurophysiol 1989b; 62: 711–22.

Baumgartner C. Clinical electrophysiology of the somatosensory cortex. Wien: Springer; 1993.

Burton H. Second somatosensory cortex and related areas. In: Jones EG, Peters A, editors. Cerebral Cortex, Vol. 5. New York: Plenum Press; 1986. p. 31–98.

Burton H, MacLeod AM, Videen TO, Raichle ME. Multiple foci in parietal frontal cortex activated by rubbing embossed grating patterns across fingerpads: a positron emission tomography study in humans. Cereb Cortex 1997; 7: 3–17.

Caselli RJ. Ventrolateral and dorsomedial somatosensory association cortex damage produces distinct somesthetic syndromes in humans [see comments]. Neurology 1993; 43: 762–71. Comment in: Neurology 1993; 43: 2423–4.

Forss N, Hari R, Salmelin R, Ahonen A, Hämäläinen M, Kajola M, et al. Activation of the human posterior parietal cortex by median nerve stimulation. Exp Brain Res 1994; 99: 309–15.

Forss N, Merlet I, Vanni S, Hämäläinen M, Mauguière F, Hari R. Activation of human mesial cortex during somatosensory target detection task. Brain Res 1996; 734: 229–35.

Garraghty PE, Florence SL, Tenhula WN, Kaas JH. Parallel thalamic activation of the first and second somatosensory areas in prosimian primates and tree shrews. J Comp Neurol 1991; 311: 289–99.

Hämäläinen M, Hari R, Ilmoniemi RJ, Knuutila J, Lounasmaa OV. Magnetoencephalography—theory, instrumentation, and applications to noninvasive studies of the working human brain. Rev Mod Phys 1993; 65: 413–97.

Hari R, Reinikainen K, Kaukoranta E, Hämäläinen M, Ilmoniemi R, Penttinen A, et al. Somatosensory evoked cerebral magnetic fields from SI and SII in man. Electroencephalogr Clin Neurophysiol 1984; 57: 254–63.

Hari R, Hämäläinen H, Hämäläinen M, Kekoni J, Sams M, Tiihonen J. Separate finger representations at the human second somatosensory cortex. Neurosci 1990; 37: 245—9.

Hari R, Karhu J, Hämäläinen M, Knuutila J, Salonen O, Sams M, et al. Functional organization of the human first and second somatosensory cortices: a neuromagnetic study. Eur J Neurosci 1993; 5: 724–34.

Huttunen J, Wikström H, Korvenoja A, Seppäläinen A-M, Aronen H, Ilmoniemi RJ. Significance of the second somatosensory cortex in sensorimotor integration: enhancement of sensory responses during finger movements. Neuroreport 1996; 7: 1009–12.

Hyvärinen J. The parietal cortex of monkey and man. Berlin: Springer; 1982.

Jones EG, Powell TP. Connexions of the somatic sensory cortex of the rhesus monkey. II. Contralateral cortical connexions. Brain 1969; 92: 717–30.

Kakigi R, Koyama S, Hoshiyama M, Kitamura Y, Shimojo M, Watanabe S. Pain-related magnetic fields following painful CO2 laser stimulation in man. Neurosci Lett 1995; 192: 45–8.

Knecht S, Kunesch E, Schnitzler A. Parallel and serial processing of haptic information in man: effects of parietal lesions on sensorimotor hand function. Neuropsychologia 1996; 34: 669–87.

Krubitzer L, Clarey J, Tweedale R, Elston G, Calford M. A redefinition of somatosensory areas in the lateral sulcus of macaque monkeys. J Neurosci 1995; 15: 3821–39.

La Joie WJ, Reddy NM, Melvin JL. Somatosensory evoked potentials: their predictive value in right hemiplegia. Arch Phys Med Rehabil 1982; 63: 223–6.

Lin W, Kuppusamy K, Haacke EM, Burton H. Functional MRI in human somatosensory cortex activated by touching textured surfaces. J Magn Reson Imaging 1996; 6: 565–72.

Macdonell R, Donnan G, Bladin PF. Serial changes in somatosensory evoked potentials following cerebral infarction. Electroencephalogr Clin Neurophysiol 1991; 80: 276–83.

Mauguière F. Somatosensory and pain evoked responses in the human SII area: from source modelling to intracerebral recordings [abstract]. Electroencephalogr Clin Neurophysiol 1997; 103: 15–6.

Mauguière F, Isnard J. Agnosie tactile et dysfonctionnement de l'aire somato-sensitive primaire: données de l'exploration par les potentiels évoques somesthésiques des déficits de la reconnaissance tactile des objets. Rev Neurol (Paris) 1995; 151: 518–27.

Mauguière F, Merlet I, Forss N, Vanni S, Jousmaki V, Adeleine P, et al. Activation of a distributed somatosensory cortical network in the human brain. A dipole modelling study of magnetic fields evoked by median nerve stimulation. Part I: location and activation timing of SEF sources. Electroencephalogr Clin Neurophysiol 1997; 104: 281–9.

Pavot AP, Ignacio DR, Kuntavanish A, Lightfoote WE. The prognostic value of somatosensory evoked potentials in cerebrovascular accidents. Electromyogr Clin Neurophysiol 1986; 26: 333–40.

Penfield W, Jasper H. Epilepsy and the functional anatomy of the human brain. Boston: Little Brown; 1954.

Pons TP, Garraghty PE, Friedman DP, Mishkin M. Physiological evidence for serial processing in somatosensory cortex. Science 1987; 237: 417–20.

Pons TP, Garraghty PE, Mishkin M. Serial and parallel processing of tactual information in somatosensory cortex of rhesus monkeys. J Neurophysiol 1992; 68: 518–27.

Reisecker F, Witzmann A, Deisenhammer E. Somatosensory evoked potentials (SSEPs) in various groups of cerebro-vascular ischaemic disease. Electroencephalogr Clin Neurophysiol 1986; 65: 260–2.

Robinson CJ, Burton H. Somatic submodality distribution within the second somatosensory (SII), 7b, retroinsular postauditory, and

granular insular cortical areas of M. fascicularis. J Comp Neurol 1980; 192: 93–108.

Rowe MJ, Turman AB, Murray GM, Zhang HQ. Parallel organization of somatosensory cortical areas I and II for tactile processing. [Review]. Clin Exp Pharmacol Physiol 1996; 23: 931–8.

Sutherling WW, Crandall PH, Darcey TM, Becker DP, Levesque MF, Barth DS. The magnetic and electric fields agree with intracranial localizations of somatosensory cortex. Neurology 1988; 38: 1705–14.

Wood CC, Cohen D, Cuffin BN, Yarita M, Allison T. Electric sources in the human somatosensory cortex: identification by combined magnetic and potential recordings. Science 1985; 227: 1051–3.

Woolsey CN, Erickson TC, Gilson WE. Localization in somatic sensory and motor areas of human cerebral cortex as determined by direct recording of evoked potentials and electrical stimulation. J Neurosurg 1979; 51: 476–506.

Zhang HQ, Murray GM, Turman AB, Mackie PD, Coleman GT, Rowe MJ. Parallel processing in cerebral cortex of the marmoset monkey: effect of reversible SI inactivation on tactile responses in SII. J Neurophysiol 1996; 76: 3633–55.

Received February 26, 1999. Revised April 16, 1999.
Accepted April 19, 1999