

# Modified Lung Ultrasound Score for Assessing and Monitoring Pulmonary Aeration

## Modifizierter Lungen-US-Score zur Bewertung und Überwachung der Belüftung der Lunge

### Authors

Silvia Mongodi<sup>1</sup>, Bélaïd Bouhemad<sup>2</sup>, Anita Orlando<sup>3</sup>, Andrea Stella<sup>3</sup>, Guido Tavazzi<sup>3</sup>, Gabriele Via<sup>1</sup>, Giorgio Antonio Iotti<sup>1</sup>, Antonio Braschi<sup>3</sup>, Francesco Mojoli<sup>3</sup>

### Affiliations

- 1 Anesthesiology, Intensive Care and Pain Medicine, Fondazione IRCCS Policlinico San Matteo, Pavia, Italy
- 2 Anesthesia and Intensive care, Centre Hospitalier Universitaire de Dijon, France
- 3 Dipartimento di Scienze Clinico-Chirurgiche, Diagnostiche e Pediatriche, Università degli Studi di Pavia Facoltà di Medicina e Chirurgia, Pavia, Italy

### Key words

lung ultrasound, lung aeration assessment, lung ultrasound score, lung aeration monitoring

received 13.7.2016

accepted 2.10.2016

### Bibliography

DOI <http://dx.doi.org/10.1055/s-0042-120260>

Published online: March 14, 2017 | *Ultraschall in Med* 2017; 37: 530–537

© Georg Thieme Verlag KG Stuttgart · New York

ISSN 0172-4614

### Correspondence

Dr. Silvia Mongodi  
Anesthesiology, Intensive Care and Pain Medicine, Fondazione IRCCS Policlinico San Matteo  
Viale Golgi 19  
27100 Pavia  
Italy  
Tel.: ++39/3 82/50 27 69  
[silvia.mongodi@libero.it](mailto:silvia.mongodi@libero.it)

### ABSTRACT

**Purpose** Lung Ultrasound Score (LUSS) is a useful tool for lung aeration assessment but presents two theoretical limitations. First, standard LUSS is based on longitudinal scan and detection of number/coalescence of B lines. In the longitudinal scan pleura visualization is limited by intercostal space width. Moreover, coalescence of B lines to define severe loss of aeration is not suitable for non-homogeneous lung pathologies where focal coalescence is possible. We therefore compared longitudinal vs. transversal scan and also cLUSS

(standard coalescence-based LUSS) vs. qLUSS (quantitative LUSS based on % of involved pleura).

**Materials and methods** 38 ICU patients were examined in 12 thoracic areas in longitudinal and transversal scan. B lines (number, coalescence), subpleural consolidations (SP), pleural length and pleural involvement (> or ≤ 50 %) were assessed. cLUSS and qLUSS were computed in longitudinal and transversal scan.

**Results** Transversal scan visualized wider (3.9 [IQR 3.8 – 3.9] vs 2.0 [1.6 – 2.5] cm,  $p < 0.0001$ ) and more constant (variance 0.02 vs 0.34 cm,  $p < 0.0001$ ) pleural length, more B lines (70 vs 59 % of scans,  $p < 0.0001$ ), coalescence (39 vs 28 %,  $p < 0.0001$ ) and SP (22 vs 14 %,  $p < 0.0001$ ) compared to longitudinal scan. Pleural involvement > 50 % was observed in 17 % and coalescence in 33 % of cases. Focal coalescence accounted for 52 % of cases of coalescence. qLUSS-transv generated a different distribution of aeration scores compared to cLUSS-long ( $p < 0.0001$ ).

**Conclusion** In unselected ICU patients, variability of pleural length in longitudinal scans is high and focal coalescence is frequent. Transversal scan and quantification of pleural involvement are simple measures to overcome these limitations of LUSS.

### ZUSAMMENFASSUNG

**Ziel** Der Lungen-US-Score (LUSS) ist eine nützliche Methode zur Bewertung der Lungenbelüftung, es gibt jedoch zwei theoretische Beschränkungen. Erstens basiert der Standard-LUSS auf dem Longitudinalschnitt und dem Nachweis der Zahl/Koaleszenz der B-Linien. Auf alle Fälle ist die longitudinale Pleuradarstellung durch den Zwischenrippenabstand eingeschränkt. Darüber hinaus ist die Koaleszenz der B Linien, die einen starken Verlust der Belüftung definiert, bei nicht-homogenen Lungenerkrankungen mit potentieller fokaler Koaleszenz ungeeignet. Deshalb verglichen wir Longitudinal- und Transversalschnitte sowie den cLUSS (Standard-Koaleszenz-basierter LUSS) mit dem qLUSS (quantitativer LUSS basierend auf % involviertem Pleura).

**Material und Methoden** 38 ICU-Patienten wurden in 12 Thoraxbereichen mittels Longitudinal- und Transversalschnitt untersucht. B Linien (Zahl, Koaleszenz), subpleurale Konsolidierungen (SP), Pleuralänge und pleurale Beteiligung (> oder ≤ 50 %) wurden bewertet. cLUSS und qLUSS wurden im Longitudinal- und Transversalschnitt errechnet.

**Ergebnisse** In der transversalen Aufnahme war im Vergleich zum Longitudinalschnitt die Pleuralänge größer (3,9 [IQR 3,8 – 3,9] vs.

2,0 [1,6–2,5] cm,  $p < 0,0001$ ) und konstanter (Varianz 0,02 vs. 0,34 cm,  $p < 0,0001$ ), es gab häufiger B Linien (70 vs. 59 % der Aufnahmen,  $p < 0,0001$ ), Koaleszenz (39 vs. 28 %,  $p < 0,0001$ ) und SP (22 vs. 14 %,  $p < 0,0001$ ). Eine Pleurabeteiligung  $> 50$  % wurde in 17 % und Koaleszenz in 33 % der Fälle beobachtet. Die fokale Koaleszenz machte 52 % der Koaleszenz-Fälle aus. qLUSS-transv. ergab eine andere Verteilung der Belüftungs-Scores im Vergleich zu cLUSS-long. ( $p < 0,0001$ ).

**Schlussfolgerung** In nicht selektierten ICU-Patienten ist die Abweichung der Pleuralänge in Longitudinalschnitten hoch und eine

fokale Koaleszenz tritt häufig auf. Transversalschnitt und Quantifizierung der Pleurabeteiligung sind einfache Methoden, um diese Beschränkungen des LUSS zu überwinden. Am ersten Tag der Aufnahme in das Krankenhaus erkennt die sonografische Messung des RIs der interlobären Arterien mit hoher Treffsicherheit diejenigen zirrhotischen Patienten mit AD, die im Laufe ihres Aufenthalts eine ACLF entwickeln werden.

## Introduction

Interest in lung ultrasound (LUS) has grown in recent years both as a diagnostic [1–3] and monitoring [4–6] tool for pulmonary diseases in the critically ill. Although air is an obstacle to the passage of ultrasound, artefacts from the pleura permit a distinction between normal and pathological patterns [7]. While horizontal reverberation artefacts (A lines) indicate a normal pattern, vertical laser-shaped artefacts (B lines) appear when the ratio between air and water is abnormal [8]. The amount correlates with extravascular lung water (EVLW) [9] and lung density, in vivo [9] and in vitro [10]. Real images are only visualized in pathological contexts (pleural effusion [11], complete lung consolidation [12]).

An experimental-model [13] in one-lung ventilation showed how progression to reabsorption atelectasis in the non-ventilated lung was associated with progressive changes in LUS findings. Thus, a LUS score (LUSS) identifying four progressive steps of loss of aeration has been proposed for semi-quantification of lung aeration and re-aeration [14–16], assigning scores from 0 to 3 in 12 pulmonary areas visualized in longitudinal scan (cranio-caudal direction) [1].

The aim of the present study was to verify two limitations of the traditional LUSS. First, in longitudinal scan the pleura is clearly identified between the ribs but its visualization is limited by the width of the intercostal space, which may vary widely among patients and between the intercostal spaces themselves. This could be a major limitation for a score based on the number of artefacts visualized. We compared longitudinal and transversal scans in terms of length of the visualized pleura and number of visualized LUS signs.

Second, coalescence of B lines is the marker of severe loss of aeration (score 2), being associated with increased lung density in homogeneous disease [13]. However, focal coalescence (i. e. involving only a minority of the visualized pleura) and subpleural consolidations may be seen in diseases with non-homogeneous loss of aeration (ARDS, contusion) [17–19], potentially leading to overestimation of aeration loss by LUS. We therefore examined how often focal coalescence was observed in an unselected ICU population and tested the feasibility of a modified LUS scoring system based on the percentage of pleura involved by B lines and/or subpleural consolidations.

## Materials and methods

### Patient selection and study design

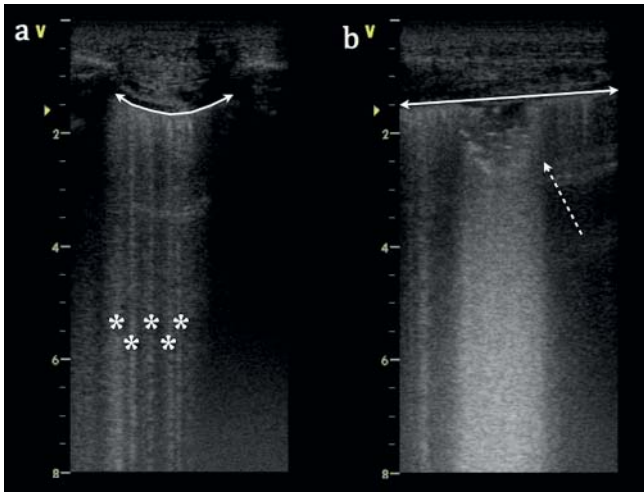
In this prospective observational study we enrolled 38 unselected patients admitted to the Intensive Care Unit 1, Fondazione IRCCS Policlinico S. Matteo University Hospital (Pavia, Italy). The ethics committee approved the study (Comitato Etico referente per l'area di Pavia-n°24474/2013); informed consent for anonymous data publication was obtained from all patients or their surrogates. Patients were considered for the study if they presented any clinical indication for LUS, which is standard practice in our unit. Only patients younger than 18-years of age were excluded.

### Data management

The following data were collected for each patient: age, sex, BMI, medical history, place of origin, Simplified Acute Physiology Score II. Admission diagnoses were classified as post-surgical, major trauma and medical.

### Ultrasound examination

For LUS examination we used a 4 cm wide high-frequency linear probe (7 MHz, Vivid-I™ GE Healthcare–Milwaukee, WI, USA); although no indications on the best probe to assess lung aeration are reported in the International Consensus Conference [1], the linear probe allows the best visualization of the pleura, thanks to its high frequency and high superficial resolution, and for this reason has already been used for lung aeration assessment in previous studies [20, 21]. Patients were examined in semi-recumbent position applying the probe perpendicularly to the chest surface. Six areas per hemithorax were identified, as recommended: on each hemithorax, sternum, anterior and posterior axillary lines identify three regions of interest: anterior, lateral and posterior, each divided into two halves, upper and lower, to identify the six standard areas per hemithorax. One central intercostal space per area was studied in both longitudinal and transversal scans. The longitudinal scan was done first, to correctly identify the pleura; a clip at least as long as one respiratory cycle was stored for off-line analysis. The transversal scan was obtained by a rotation centered on the pleura, until complete disappearance of the ribs; a second clip was stored (► Fig. 1). For each scan the following data were recorded: length of pleural line, presence of A lines, number or coalescence of B lines, subpleural echo-poor



► **Fig. 1** The same intercostal space examined in longitudinal **a** and transversal **b** scan: transversal scan allows visualization of significantly longer pleura and different artefact. (\*: well-spaced B lines; continuous-line arrows: pleural line; dotted-line arrow: subpleural consolidation).

regions (subpleural consolidations – SP), pleural involvement > 50 % or ≤ 50 % and tissue-like patterns (consolidations). For pleural involvement we considered B lines (well-spaced and coalescent) and SP.

### Lung ultrasound score

The new proposed score introduces one main change: score 2 (severe loss of aeration) depending on the percentage of the pleural line occupied by artefacts (clearly > 50 %). We called the classical score, based on B lines coalescence, cLUSS and the new score, based on quantification of the involved pleura, qLUSS. See ► **Table 1**, ► **Fig. 2** for a detailed description of LUS scores.

Images were collected by five operators; image quality was judged in relation to A line identification, if the pleural line was visible. After anonymization, the clips were randomly distributed to the five operators for off-line interpretation. Some of each operator's clips were used to create a pool of 200 clips that was blindly re-distributed to the other operators in order to calculate inter-rater variability.

cLUSS and qLUSS were applied in both longitudinal and transversal scans, obtaining four scores (cLUSS-long, cLUSS-transv, qLUSS-long, qLUSS-transv); cLUSS-long was used as the control score. Examples of images' interpretation are reported in ► **Video 1 – 5** of ESM.

### Statistical analysis

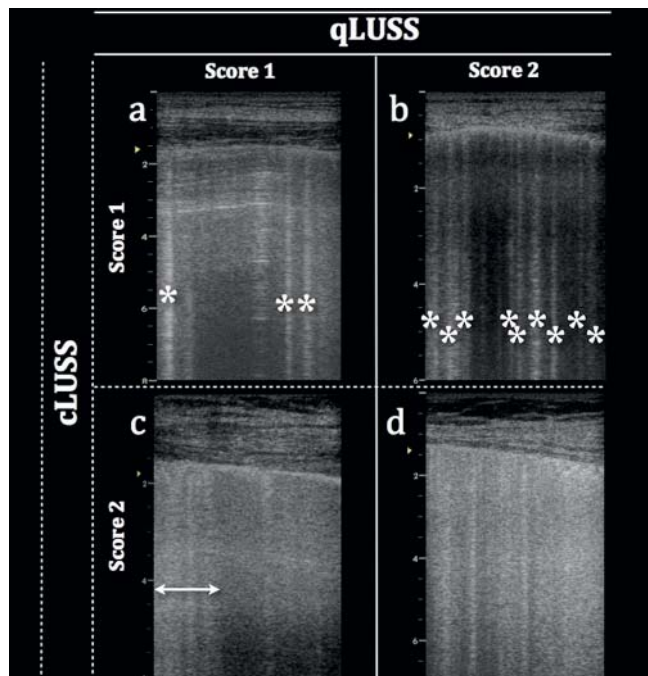
Results are expressed as mean±SD or median (interquartile range–IQR). Wilcoxon's test for paired samples was applied for numerical data analysis. Difference of variance was calculated by a variance ratio test (F-test). McNemar's test was employed to test the difference between paired proportions. To examine the agreement between two classifications we applied the Inter Rater Agreement (optimal agreement was defined by a k value > 0.80). The Inter-Class Correlation Coefficient (ICC) was used to measure

► **Table 1** Parameters of two different lung ultrasound scores.

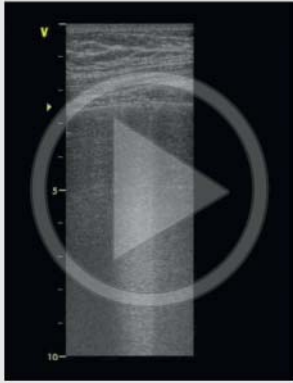
	cLUSS	qLUSS
score 0 – normal aeration	A lines – max 2 B lines	A lines – max 2 B lines
score 1 – moderate loss of aeration	≥ 3 well-spaced B lines	artefacts <sup>1</sup> occupying ≤ 50 % of the pleura
score 2 – severe loss of aeration	coalescent B lines	Artefacts <sup>1</sup> occupying > 50 % of the pleura
score 3 – complete loss of aeration	tissue-like pattern	tissue-like pattern

LUSS: Lung ultrasound score; cLUSS: coalescence score – traditional score where the switch from score 1 to score 2 is determined by the presence of B lines coalescence; qLUSS: quantitative score – the new modified score where the switch from score 1 to score 2 is determined by the percentage of pleura occupied by artefacts.

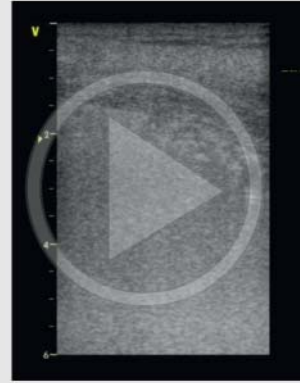
<sup>1</sup> Artefacts considered for the assessment of percentage of occupied pleura: well-spaced B lines if ≥ 3, coalescent B lines, subpleural consolidations.



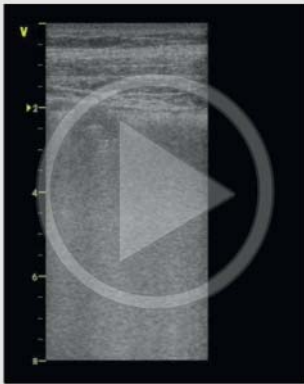
► **Fig. 2** Comparison of score 1 and 2 computation with cLUSS (coalescence-based lung ultrasound score) and qLUSS (quantitative-based lung ultrasound score) of the same longitudinal scans. Panel **a** and **b** correspond to cLUSS score 1; panel **c** and **d** present coalescence and correspond to cLUSS score 2. qLUSS considers the percentage of occupied pleura: panel **a** and **c** have focal artefacts involving < 50 % of the pleura and correspond to qLUSS score 1. Panel **b** and **d** present diffuse artefacts occupying clearly > 50 % of the pleura and correspond to qLUSS score 2. (\*: B lines; continuous-line arrow: focal coalescence).



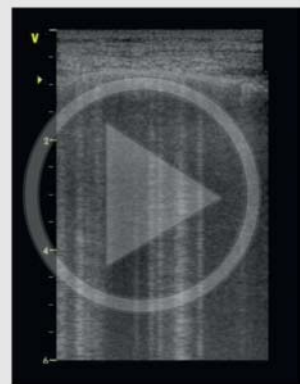
► **Video 1** Transversal scan of left costophrenic sinus of a thoracic trauma patient: a focal coalescence involving < 50 % of the visualized pleura is remarked; this corresponds to a score 2 in cLUSS and a score 1 in qLUSS.



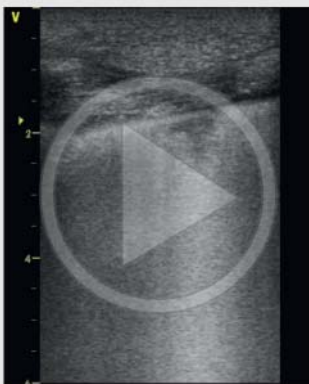► **Video 4** Transversal scan of left lateral field of a severe ARDS: all the pleura is occupied by subpleural consolidations, no A lines are visible. cLUSS gives no specific indications on how to interpret loss of aeration deriving from subpleural consolidations. In qLUSS this corresponds to a score 2 (clearly > 50 % of pleura occupied by US artefacts/signs).



► **Video 2** Transversal scan of left anterior field of a thoracic trauma patient: diffuse coalescence and subpleural consolidations involving > 50 % of the visualized pleura; both cLUSS and qLUSS would give a score 2.



► **Video 5** Transversal scan of the right anterior field of a severe ARDS: multiple well-spaced B lines are visualized with no coalescence but occupying clearly > 50 % of the visualized pleura. This corresponds to a score 1 in cLUSS, whereas to a score 2 in qLUSS.



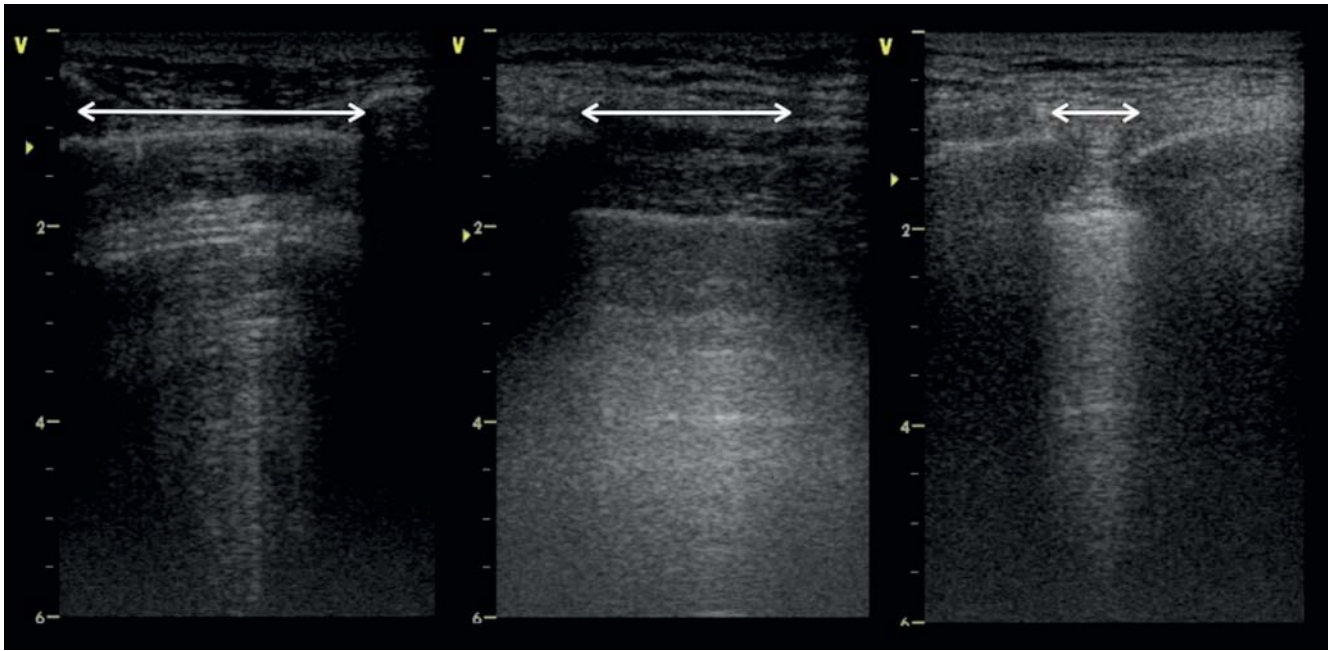
► **Video 3** Transversal scan of right lateral field of a patient affected by ventilator-associated pneumonia: a subpleural consolidation is remarked; cLUSS gives no specific indications on how to interpret loss of aeration deriving from subpleural consolidations. In qLUSS this corresponds to a score 1 (no > 50 % of pleura occupied by US artefacts/signs, as attested by the visible A line).

the reliability of rating (strength of absolute agreement among the operators was considered poor, fair, moderate, strong or almost perfect according to an ICC value < 0.30, 0.3 – 0.49, 0.50 – 0.69, 0.70 – 0.89 and  $\geq 0.90$  respectively).

## Results

### Characteristics of the study population

We prospectively enrolled 38 patients (age  $60.1 \pm 16.1$  years, male 55 %, BMI  $24.9 \pm 4.7$  Kg/m<sup>2</sup>). Admission diagnoses included post-surgical (13 % – abdominal and cardiac), major trauma (11 %) and medical (76 % – post-anoxic coma, whole-lung lavage, respiratory failure, cardiac failure, hepato-renal syndrome, intoxication, meningitis, basilar-artery thrombosis, intracranial hemorrhage).



► **Fig. 3** Pleural length variability in longitudinal scan.

► **Table 2** Effects of modification of probe orientation (A) and of the new lung ultrasound score (qLUSS) application (B) compared to the traditional longitudinal lung ultrasound score (cLUSS). A) In cLUSS, switching from longitudinal to transversal view score 0 decreased (56.1 vs. 43.6% of intercostal spaces;  $p < 0.0001$ ), whereas score 2 increased (27.9 vs. 38.8%;  $p < 0.0001$ ). B) Switching from cLUSS-long to qLUSS-transv, score 1 increased (33.6 vs. 8.6%;  $p < 0.0001$ ) with a concomitant reduction of score 0 (43.2 vs. 56.1%;  $p < 0.0001$ ) and score 2 spaces (15.8 vs. 27.9%;  $p < 0.0001$ ).

A		cLUSS-long				B		cLUSS-long			
		0	1	2	3			0	1	2	3
cLUSS-transv	0	190	3	6	0	qLUSS-transv	0	190	3	4	0
	1	23	12	11	0		1	62	30	61	0
	2	43	24	110	0		2	4	6	62	0
	3	0	0	0	34		3	0	0	0	34

LUSS: Lung ultrasound score; cLUSS: coalescence score – traditional score where the switch from score 1 to score 2 is determined by the presence of B-lines coalescence; qLUSS: quantitative score – the new modified score where the switch from score 1 to score 2 is determined by the percentage of pleura occupied by artefacts.

### Visualization of pleural length and artefacts in transversal and longitudinal views

In 38 patients, a total of 456 intercostal spaces were examined, corresponding to 912 clips (456 transversal and 456 longitudinal scans). A tissue-like pattern was visualized in 34 of these scans (7.5%), with no difference between the two approaches.

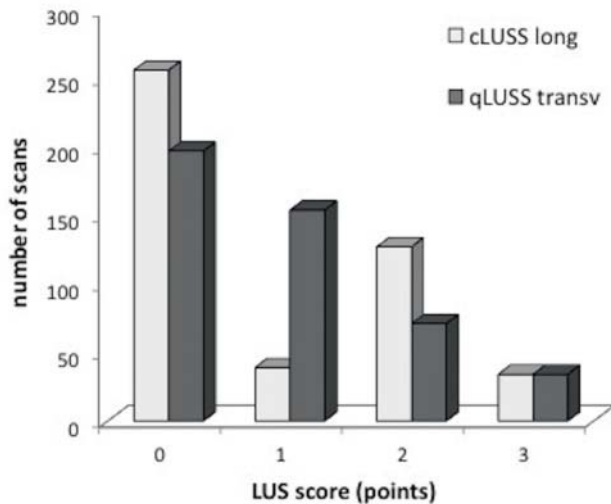
In intercostal spaces where the pleura was visible, we obtained good-quality images without any significant differences in the two techniques: A lines were visible in 69.7% longitudinal and 70.6% transversal scans ( $p = 0.7$ ).

Pleural length differed significantly in the longitudinal and transversal scans: respectively 2.0 cm (IQR 1.6–2.5) and 3.9 cm (3.8–3.9) ( $p < 0.0001$ ) (► **Fig. 3**). Pleural length also gave a signif-

icantly higher variance in longitudinal than transversal scans: 0.34 vs. 0.02 cm ( $p < 0.001$ ). Transversal scans allowed visualization of a significantly larger number of US signs than longitudinal scans (► **Fig. 1**): B lines were visualized in 69.7% vs. 58.6% of intercostal spaces ( $p < 0.0001$ ); coalescence in 39.0 vs. 27.9% ( $p < 0.0001$ ); SP in 21.5 vs. 14.0% ( $p < 0.0001$ ).

### Lung ultrasound scores

cLUSS gave different results with the different probe orientations (► **Table 2A**). Turning the probe transversally, score 0 intercostal spaces decreased from 56.1% to 43.6% ( $p < 0.0001$ ) while score 2 spaces increased from 27.9% to 38.8% ( $p < 0.0001$ ). Thus agree-



► **Fig. 4** Distribution of aeration scores with different techniques. cLUSS: coalescence-based lung ultrasound score; qLUSS: quantitative-based lung ultrasound score. Transv: transversal. Long: longitudinal.

ment between cLUSS-long and cLUSS-transv was sub-optimal:  $K = 0.69$  (95% CI 0.64 to 0.75).

Considering both longitudinal and transversal scans, pleural involvement was  $> 50\%$  in 151 cases (16.6%) and B lines were coalescent in 305 (33.4%). When pleural involvement was  $> 50\%$ , in almost all cases (96.7%) B lines coalesced. In contrast, where there were coalescent B lines, pleural involvement was  $> 50\%$  in only 47.9% of cases; therefore localized coalescence accounted for 52.1% of all cases of coalescent B lines.

As a consequence, cLUSS and qLUSS gave different results. With the transversal probe orientation (► **e-Table 1** of ESM), qLUSS calculation reduced the score 2 intercostal spaces significantly, from 38.8% to 15.8% ( $p < 0.0001$ ) with a corresponding increase in score 1 intercostal spaces – from 10.1% to 33.6% ( $p < 0.0001$ ). Therefore the agreement between cLUSS-transv and qLUSS-transv was sub-optimal:  $K = 0.64$  (95% CI 0.59 to 0.69). Similar results were obtained with the longitudinal probe orientation (► **e-Table 2** of ESM). The effects on qLUSS of probe orientation are shown in ► **e-Table 3** of ESM.

The probe orientation and different scoring system had additive effects when qLUSS-transv and cLUSS-long were directly compared (► **Table 2B**, ► **Fig. 4**): in qLUSS-transv significantly more score 1 intercostal spaces were visualized (33.6 vs. 8.6%;  $p < 0.0001$ ) with a concomitant reduction of score 0 (43.2 vs. 56.1%;  $p < 0.0001$ ) and score 2 spaces (15.8 vs. 27.9%;  $p < 0.0001$ ). Thus here too the agreement between cLUSS-long and qLUSS-transv was sub-optimal:  $K = 0.70$  (95% CI 0.65 to 0.74).

### Inter-operator agreement in the different LUS scoring systems

Absolute agreement was strong among the five operators when rated according to the original scoring system (cLUSS-long): ICC was 0.84 (95% CI 0.79 to 0.88) for the score, 0.88 (0.69–0.98)

for the number of B lines and 0.70 (0.63 to 0.77) for coalescent B lines. Agreement was almost perfect with the modified scoring system (qLUSS-transv): ICC was 0.91 (95% CI 0.88 to 0.94) for the score, 0.87 (0.68 to 0.97) for number of B lines and 0.93 (0.90 to 0.95) for pleural line involvement  $> 50\%$ .

## Discussion

LUS is a very promising tool for lung monitoring in ICU [5, 6], particularly for assessing lung aeration [14–16]. A LUS score has been proposed to semi-quantify lung aeration based on the detection of LUS signs corresponding to variable degrees of loss of aeration [16]. Semi-quantification is essential for accurate and repeatable monitoring of lung aeration and could replace daily chest radiographs, confirming the key role for LUS in ventilated patients monitoring in ICU. Assessment of LUS changes has been applied in different clinical contexts, such as PEEP titration in ARDS patients [14], antibiotic-induced re-aeration in ventilator-associated pneumonia [15] and prediction of weaning failure after a spontaneous breathing trial [16].

This score improves the applicability of LUS, allowing day-by-day monitoring and correlating well with quantitative CT-scan assessment of aeration [22] / re-aeration [15] and EVLW quantification [23]. However, LUS presents two main theoretical limitations, verified in the present study.

First, our results confirm that pleural length is extremely variable in a longitudinal scan (► **Fig. 3**), which is the approach recommended by the International Consensus Conference [1]. This limits the reliability of a score based on the number of visualized artefacts per scan [9]. Restricted visualization of the pleural surface could lead to underestimation of the loss of aeration, limiting the switch from score 0 to score 1.

Transversal scans seem better: pleural length is significantly greater and more constant. Moreover, the wider pleural line examination means that significantly more LUS signs are visualized in these scans (subpleural consolidations, B lines), potentially allowing better assessment of lung aeration. Thus we suggest to first identify the pleural line by detecting the “bath sign” in longitudinal scan [1, 2] and then to obtain a transversal scan by a 90 degrees rotation of the high-frequency linear probe.

Our second aim was to test a modified aeration score. In the traditional score (cLUSS-long), coalescing B lines govern the switch from score 1 to score 2, since they are associated with increased lung density in vivo [9] and in vitro [10]. In cases with homogeneous loss of aeration – as in cardiogenic edema – B lines become more and more numerous with the increase of EVLW [9, 10, 13, 23] and finally tend to merge, involving the entire pleura. This does not happen with non-homogeneous loss of aeration (ARDS, ventilator-associated pneumonia (VAP) or lung contusion), where coalescence is frequently focal and affects variable percentages of the visualized pleura [17–19]. Rating all these coalescences as score 2, regardless of the percentage of pleura involved, can lead to overestimation of loss of aeration when loss of aeration is focal. In our population, coalescence was focal (i.e. “occupying less than 50% of the visualized pleura”) in more than half the cases, confirming its clinical importance.

Moreover, no indications on how to interpret loss of aeration in case of subpleural consolidations have been described so far. However, subpleural consolidations are LUS clues to lung contusion [17], ARDS [18] and VAP diagnosis [19], all conditions requiring daily monitoring of lung aeration.

The modified score in transversal scan indicates normal aeration (score 0) if A lines or no more than two B lines are visible, as with the traditional one. Moderate loss of aeration (score 1) presents  $\geq 3$  well-spaced B lines, coalescent B lines and/or subpleural consolidations involving less than half the length of the pleura; severe loss of aeration is defined by clearly more than half the pleura showing well-spaced B lines, coalescence and/or subpleural consolidations; complete loss of aeration corresponds to a tissue-like pattern.

Transversal scan and quantification of pleural involvement are simple measures to overcome the limitations of LUS due to the variability of pleural length and focal coalescence. Applying these measures to compute LUSS, the scores were distributed differently (► Fig. 4). cLUSS-long presented two peaks corresponding to score 0 and score 2 while score 1 was not seen often. With qLUSS-transv, the scores decreased gradually from 0 (normal aeration) to 3 (complete loss of aeration). This agrees with previous quantitative CT findings [24]; in unselected ICU patients, the percentages decreased progressively from normally aerated lung tissue to poorly aerated to non-aerated, suggesting – although not formally proving – the better performance of qLUSS-transv in semi-quantification of lung aeration.

Finally, cLUSS showed strong absolute agreement among operators, as expected; however, agreement was even stronger with qLUSS, suggesting it would be more reliable for day-by-day monitoring of aeration when different operators are involved in managing the same patient, as frequently happens in ICU.

## Limitations

The main limitation of the present study is that it compared two LUS techniques; validation of the new score would require comparison with the gold standard for lung aeration assessment: quantitative CT scan. However, the traditional score had not been validated with CT scan before its clinical application either.

In order to standardize image collection and focus on the pleura and its artefacts, we only used a 4 cm wide high-frequency linear probe. Thus our results may not be overgeneralized when different probes are used for lung examination. However, all probes (micro-convex, phased-array, convex) if placed in longitudinal scan are limited by the width of the intercostal space. Lichtenstein first described the B lines pattern with a micro-convex probe of an early generation US machine [8]. This probe, with its small footprint, can sometimes fit into the intercostal space, avoiding rib shadows but this very much depends on patient's habitus. Furthermore, despite its versatility, micro-convex is not always available in many ultrasound-equipped settings.

## Conclusions

LUS is useful for lung aeration assessment and monitoring in the critically ill. The traditional LUS score presents some limitations,

mainly due to the variability in pleural length in longitudinal scan and the definition of severe loss of aeration in relation to coalescence of B lines. Transversal orientation of the high-frequency linear probe is confirmed as performing better, allowing visualization of a greater and more constant length of pleura. Moreover, better visualization of LUS signs such as subpleural consolidations can improve diagnosis and monitoring of patients with VAP, ARDS and lung contusions.

The proposed modified score introduces the percentage of involved pleura to establish the severity of loss of aeration; it seems to perform better than the traditional score, distributing the scores more like quantitative CT in the setting of unselected ICU patients; it also offers closer agreement among operators.

Further studies are required to confirm improved lung aeration assessment with the modified quantitative LUS score.

## References

- [1] Volpicelli G, Elbarbary M, Blaivas M et al. International evidence-based recommendations for point-of-care lung ultrasound. *Intensive Care Med* 2012; 38: 577–591
- [2] Lichtenstein D, Mezière GA. Relevance of lung ultrasound in the diagnosis of acute respiratory failure. The BLUE protocol. *Chest* 2008; 134: 117–125
- [3] Ashton-Cleary DT. Is thoracic ultrasound a viable alternative to conventional imaging in the critical care setting?. *Br J Anaesth* 2013; 111: 152–160
- [4] Via G, Storti E, Gulati G et al. Lung ultrasound in the ICU: from diagnostic instrument to respiratory monitoring tool. *Minerva Anestesiol* 2012; 78: 1282–1296
- [5] Bouhemad B, Mongodi S, Via G et al. Ultrasound for “lung monitoring” of ventilated patients. *Anesthesiology* 2015; 122: 437–447
- [6] Pesenti A, Musch G, Lichtenstein D et al. Imaging in acute respiratory distress syndrome. *Intensive Care Med* 2016; 42: 686–698
- [7] Lichtenstein D, Mezière G, Biderman P et al. The comet-tail artifact. An ultrasound sign of alveolar-interstitial syndrome. *Am J Resp Crit Care Med* 1997; 156: 1640–1646
- [8] Lichtenstein DA, Mezière GA, Lagoueyte JF et al. A-lines and B-lines: lung ultrasound as a bedside tool for predicting pulmonary artery occlusion pressure in the critically ill. *Chest* 2009; 136: 1014–1020
- [9] Baldi G, Gargani L, Abramo A et al. Lung water assessment by lung ultrasonography in intensive care: a pilot study. *Intensive Care Med* 2013; 39: 74–84
- [10] Soldati G, Inchingolo R, Smargiassi A et al. Ex vivo Lung sonography: morphologic-ultrasound relationship. *Ultrasound Med Biol* 2012; 38: 1169–1179
- [11] Balik M, Plasil P, Waldauf P et al. Ultrasound estimation of volume of pleural fluid in mechanically ventilated patients. *Intensive Care Med* 2006; 32: 318–321
- [12] Lichtenstein D, Lascols N, Mezière G et al. Ultrasound diagnosis of alveolar consolidation in the critically ill. *Intensive Care Med* 2004; 30: 276–281
- [13] Via G, Lichtenstein D, Mojoli F et al. Whole lung lavage: a unique model for ultrasound assessment of lung aeration changes. *Intensive Care Med* 2010; 36: 999–1007
- [14] Bouhemad B, Brisson H, Le-Guen M et al. Bedside ultrasound assessment of positive end-expiratory pressure-induced lung recruitment. *Am J Respir Crit Care Med* 2011; 183: 341–347
- [15] Bouhemad B, Liu ZH, Arbelot C et al. Ultrasound assessment of antibiotic-induced pulmonary reaeration in ventilator-associated pneumonia. *Crit Care Med* 2010; 38: 84–92
- [16] Soummer A, Perbet S, Brisson H et al. Ultrasound assessment of lung aeration loss during a successful weaning trial predicts postextubation distress. *Crit Care Med* 2012; 40: 2064–2072

- [17] Copetti R, Soldati G, Copetti P. Chest sonography: a useful tool to differentiate acute cardiogenic pulmonary edema from acute respiratory distress syndrome. *Cardiovasc Ultrasound* 2008; 29: 6–16
- [18] Soldati G, Testa A, Silva FR et al. Chest ultrasonography in lung contusion. *Chest* 2006; 130: 533–538
- [19] Mongodi S, Via G, Girard M et al. Lung ultrasound for early diagnosis of ventilator-associated pneumonia. *Chest* 2016; 149: 969–980
- [20] Tushman G, Acosta CM, Nicola M et al. Real-time images of tidal recruitment using lung ultrasound. *Crit Ultrasound J* 2015; 7: 19
- [21] Corradi F, Brusasco C, Vezzani A et al. Computer-aided quantitative ultrasonography for detection of pulmonary edema in mechanically ventilated cardiac surgery patients. *Chest* 2016; 150: 640–651
- [22] Mongodi S, Algieri I, Mojoli F et al. CT-scan and ultrasound comparative assessment of lung aeration in ARDS. *Intensive Care Med* 2014; 40: S127–S128
- [23] Zhao Z, Jiang L, Xi X et al. Prognostic value of extravascular lung water assessed with lung ultrasound score by chest sonography in patients with acute respiratory distress syndrome. *BMC Pulm Med* 2015; 15: 98
- [24] Reske AW, Reske AP, Gast HA et al. Extrapolation from ten sections can make CT-based quantification of lung aeration practicable. *Intensive Care Med* 2010; 36: 1836–1844