

# Molecular and Cellular Mechanisms of Cigarette Smoke-Induced Myocardial Injury: Prevention by Vitamin C

Archita Das<sup>1</sup>, Neekkan Dey<sup>1</sup>, Arunava Ghosh<sup>1</sup>, Shovanendu Das<sup>2</sup>, Dhruva J. Chattopadhyay<sup>1</sup>, Indu B. Chatterjee<sup>1\*</sup>

**1** Department of Biotechnology, Dr. B. C. Guha Centre for Genetic Engineering and Biotechnology, Calcutta University College of Science, Kolkata, India, **2** VLCC Health Care, Jodhpurpark, Kolkata, India

## Abstract

**Background:** Cardiovascular disease (CVD) remains one of the major killers in modern society. One strong risk factor of CVD is cigarette smoking that causes myocardial injury and leads to the genesis of pathological cardiovascular events. However, the exact toxic component(s) of cigarette smoke (CS) and its molecular and cellular mechanisms for causing myocardial injury leading to heart damage and its prevention are largely unknown.

**Methodology/Principal Findings:** Using a guinea pig model, here we show that chronic exposure to CS produces myocardial injury that is prevented by vitamin C. Male guinea pigs were fed either vitamin C-deficient (0.5 mg/day) or vitamin C-sufficient (15 mg/day) diet and subjected to CS exposure from 5 Kentucky Research cigarettes (3R4F)/day (6 days/week) in a smoke chamber up to 8 weeks. Pair-fed sham controls were subjected to air exposure instead of CS exposure under similar conditions. Myocardial injury was produced in CS-exposed marginal vitamin C-deficient guinea pigs as evidenced by release of cardiac Troponin-T and I in the serum, oxidative stress, inflammation, apoptosis, thrombosis and collagen deposition in the myocardium. Treatment of rat cardiomyocyte cells (H9c2) *in vitro* and guinea pigs *in vivo* with p-benzoquinone (p-BQ) in amounts derived from CS revealed that p-BQ was a major factor responsible for CS-induced myocardial damage. A moderately large dose of vitamin C (15 mg/day) prevented CS/p-BQ-induced myocardial injury. Population based studies indicated that plasma vitamin C levels of smokers without disease were significantly lower ( $p = 0.0000$ ) than that of non-smokers. Vitamin C levels of CS-related cardiovascular patients were further lower ( $p = 0.0000$ ) than that of smokers without disease.

**Conclusions/Significance:** The results indicate that dietary supplementation of vitamin C may be a novel and simple therapy for the prevention of pathological cardiovascular events in habitual smokers.

**Citation:** Das A, Dey N, Ghosh A, Das S, Chattopadhyay DJ, et al. (2012) Molecular and Cellular Mechanisms of Cigarette Smoke-Induced Myocardial Injury: Prevention by Vitamin C. PLoS ONE 7(9): e44151. doi:10.1371/journal.pone.0044151

**Editor:** Partha Mukhopadhyay, National Institutes of Health, United States of America

**Received:** March 25, 2012; **Accepted:** July 30, 2012; **Published:** September 6, 2012

**Copyright:** © 2012 Das et al. This is an open-access article distributed under the terms of the Creative Commons Attribution License, which permits unrestricted use, distribution, and reproduction in any medium, provided the original author and source are credited.

**Funding:** This research was supported by Juthika Research Foundation of Calcutta University, Department of Biotechnology, Government of West Bengal and Council of Scientific and Industrial Research, Government of India. Indu B. Chatterjee is INSA (Indian National Science Academy) Honorary Scientist. The funders had no role in study design, data collection and analysis, decision to publish, or preparation of the manuscript.

**Competing Interests:** SD is an In-House Physician in VLCC Health Care. This does not alter the authors' adherence to all the PLoS ONE policies on sharing data and materials.

\* E-mail: ibc123@rediffmail.com

## Introduction

Cardiovascular disease (CVD) including coronary heart disease and myocardial infarction (MI) remains one of the major killers in modern society. CVD is believed to account for about 12 million deaths annually [1,2]. Epidemiologic studies have established worldwide that besides lung cancer and emphysema, cigarette smoking is a strong risk factor of CVD [3–6]. Numerous studies indicate that pathogenesis of most of the cigarette smoke (CS)-induced degenerative diseases is associated with oxidative damage [7]. The existing evidence also support the view that oxidative stress may play a crucial role in cardiac and vascular abnormalities in different types of CVD [8].

While the deleterious effects of cigarette smoke (CS) on cardiovascular morbidity and mortality are well established, the molecular mechanisms and temporal progression of CS-induced pathophysiological disorders are not clear [5,9,10]. Cigarette

smoke (CS) is a complex mixture of about 4000 compounds including free radicals and long-lived radicals [11,12]. It has been indicated that free radical-mediated oxidative stress may play a prominent role in causing myocardial injury and damage of vascular endothelium that leads to the genesis of pathological cardiovascular events [6,13–15]. However, the exact toxic component(s) of CS and its mechanism of action for causing myocardial injury leading to heart damage remain poorly understood.

Earlier we had shown that p-benzoquinone (p-BQ), derived from p-benzoquinone (p-BQ) of CS, produces oxidative damage that is accompanied by inflammation and apoptosis leading to emphysema [16]. p-BQ is also responsible for CS-induced myelodysplastic syndromes (MDS) [17]. p-BQ is present in substantial amounts (100–200 µg/cigarette) in smoke from all commercial cigarettes examined as well as Kentucky Research cigarettes [18,19]. In the smoker's lungs, p-BQ is converted to

p-benzoquinone (p-BQ) apparently through disproportionation and oxidation by transition metal containing proteins [16,20]. We have shown that p-BQ formed in the lungs goes to the blood and alters the structure and function of serum albumin [21]. p-BQ is a redox cycling agent that produces reactive oxygen species (ROS) leading to oxidative damage [22]. We considered that p-BQ carried by the blood to the heart might cause oxidative damage leading to myocardial injury and cardiomyocyte death. Adult cardiomyocytes are terminally differentiated cells, and once destroyed, are rarely replaced. Until recently, the mode of cell death involved was not clear and was attributed to necrosis. However, it is now believed that apoptosis also plays an important role [1].

The available evidence supports the importance of antioxidant mechanisms in cardioprotection [23]. Vitamin C is a strong antioxidant that reduces p-BQ and thereby inactivates it. Smoking reduces the plasma vitamin C level [15,16,24,25]. This may be at least in part due to consumption of vitamin C by p-BQ. Epidemiological studies have shown that low-plasma vitamin C is a risk factor for coronary heart disease and its acute clinical manifestations [26]. Earlier we had reported that a moderately large dose of vitamin C prevents CS-induced oxidative damage, inflammation and apoptosis by reducing and thereby inactivating p-BQ [16,27]. Some studies show the protective effect of vitamin C on cardiomyocyte damage and heart failure [28,29]. We therefore considered that the nutritional status of vitamin C might be a critical determining factor for causing CS-induced myocardial injury.

However, investigations on the effects of CS exposure in vitamin C-deficient subjects leading to myocardial injury in population-base studies are difficult to achieve. Animal models have proven to be valuable tools for the investigation of CS-induced diseases [5,30]. In some laboratories, rat and mouse models have been used for the investigation of CS-induced CVD. Rats and mice synthesize vitamin C that would reduce the toxicity of CS [31,32]. We considered that as used for the studies on CS-induced emphysema [16] and MDS [17], marginal vitamin C-deficient guinea pig would be a better animal model to study the pathophysiology and molecular mechanisms of CS-induced myocardial injury. The guinea pig, like human, is incapable of synthesizing vitamin C and is dependent on the dietary source of the vitamin [31,32]. Thus it is possible to manipulate the nutritional status of vitamin C in the guinea pig through dietary means. Moreover, the guinea pig has anatomical and CS-induced pathophysiological similarities to human [33].

In this paper we show that chronic exposure of CS to marginal vitamin C-deficient guinea pigs produces myocardial injury that is accompanied by oxidative stress, inflammation, thrombosis, apoptosis and collagen deposition. We further show that p-BQ is largely responsible for CS-induced myocardial damage. A moderately large dose of vitamin C prevents CS/p-BQ-induced myocardial injury.

## Results

### Biochemistry and Histopathology of CS-induced Myocardial Injury and its Prevention by Vitamin C

The most preferred biomarker for myocardial injury is cardiac Troponin (T and I), which has nearly absolute myocardial tissue specificity, as well as high sensitivity [34]. Here we show that the levels of cardiac Troponin T and I are markedly elevated in the serum of marginal vitamin C-deficient guinea pigs exposed to CS for 6–8 weeks (Figure 1A). Serum Troponin T and I are absent in CS-exposed vitamin C-sufficient group (Figure 1A). It is known

that CVD, particularly myocardial ischemia, is usually accompanied by reduction of blood and oxygen delivery due to thrombus formation and thereby obstruction of circulation to one or more regions of the heart [35]. Histopathology using H&E shows that in contrast to air-exposed guinea pigs, blood vessel of CS-exposed marginal vitamin C-deficient guinea pig is filled with thrombus that almost blocks the lumen at the end of 8 weeks (Figure 1B, I, II, III, IV, V). Thrombus formation is negligible in CS-exposed vitamin C-sufficient group (Figure 1B, VI). In contrast to normal striated cardiac muscles (Figure 1B, VII) or that observed after 2 weeks of exposure (Figure 1B, VIII), CS exposure after 4 weeks causes loss of striation and the cytoplasm becomes eosinophilic at the end of 6 weeks (Figure 1B, IX, X). After exposure of 8 weeks, there is formation of fibrous tissues (Figure 1B, XI). Fibrous tissue formation has been confirmed by deposition of collagen, as evidenced by marked blue colour taken up after Masson's trichrome staining of the left ventricular part of the heart of the guinea pig (Figure 1B, XVI and XVII). No fibrous tissue formation is observed in the air-exposed or 2–4 weeks of CS-exposed myocardium (Figure 1B, XIII, XIV, XV). Loss of striation, fibrous tissue formation and collagen deposition are very low in CS-exposed vitamin C-sufficient guinea pigs (Figure 1B, XII and XVIII). Figure 1C shows quantitative evaluation of the progression of thrombus formation and fibrous tissue deposition. Collagen deposition is supported by the fact that synthesis of collagen (type I) is markedly increased in myocardial tissue of marginal vitamin C-deficient guinea pigs after exposure to CS for 6–8 weeks (Figure 1D). Collagen (type I) synthesis indicates enhancement of myocardial fibrosis [36]. No such collagen synthesis takes place in CS-exposed vitamin C-sufficient guinea pigs (Figure 1D).

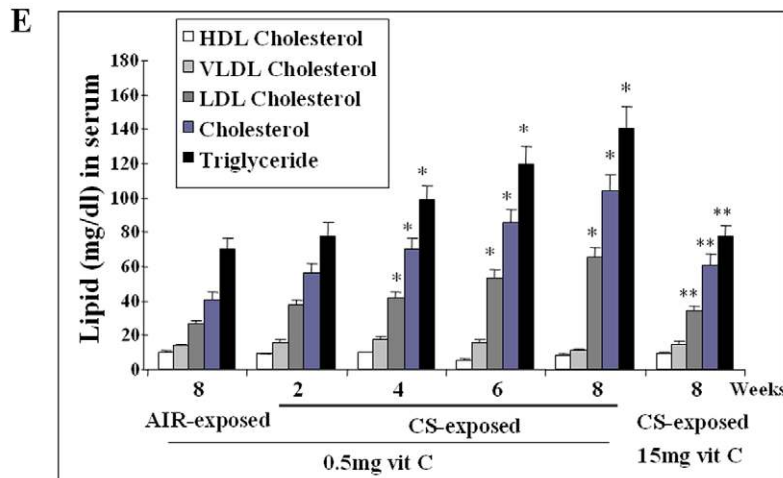
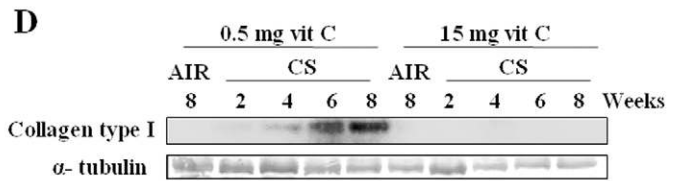
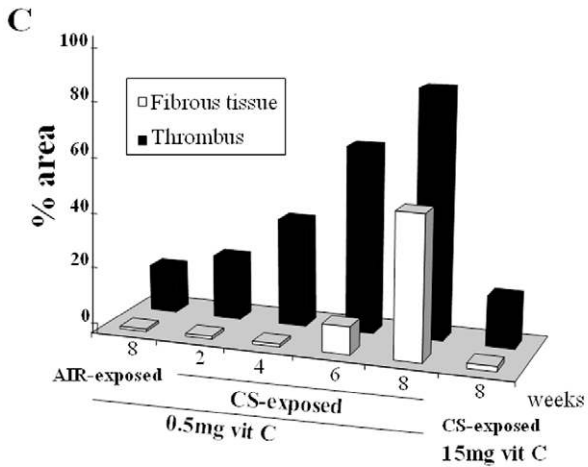
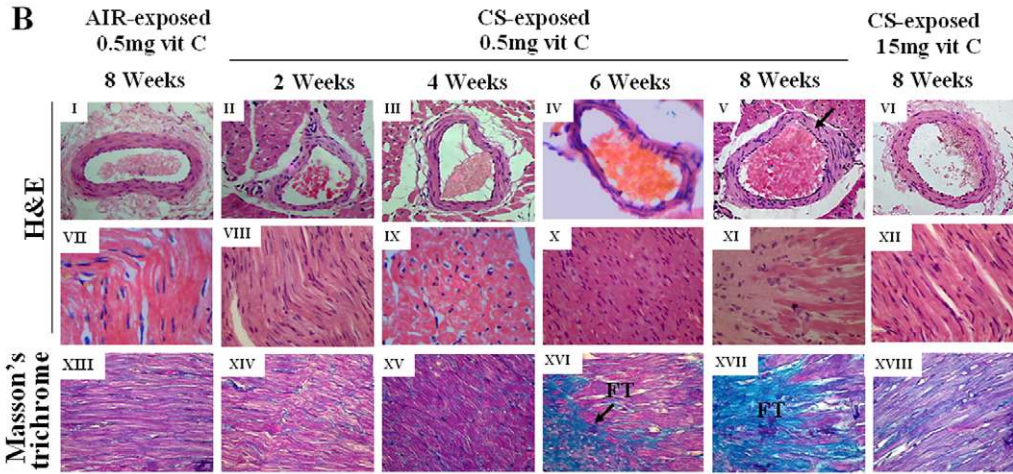
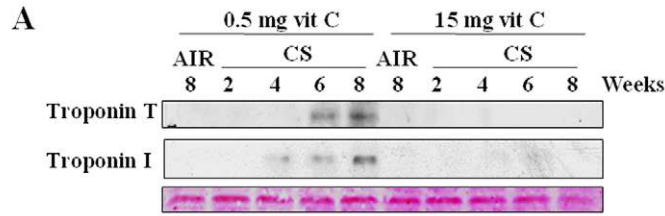
It is reported that smokers have significantly higher serum cholesterol, triglyceride, and low-density lipoprotein levels [37] that appear to be strong and independent predictors of future risk of CVD [38]. Figure 1E shows that in contrast to air-exposed sham controls or CS-exposed vitamin C-sufficient guinea pigs, the levels of serum total cholesterol, LDL cholesterol and triglyceride are gradually and significantly increased ( $p < 0.05$ ) in CS-exposed marginal vitamin C-deficient guinea pigs.

### Vitamin C Status in CS-related Cardiovascular Patients

Earlier we had shown that CS exposure resulted in lowering of plasma vitamin C levels in guinea pigs [17]. This is because CS consumes vitamin C [27]. A total of 24 newly diagnosed smoke-related cardiovascular patients, 25 non-smokers and 25 smokers without disease were used in this study. Here we show that as observed in the CS-exposed guinea pigs, plasma vitamin C levels of human smokers without disease ( $0.18 \pm 0.01$  mg/dL) are significantly lower ( $p = 0.0000$ ) than that of non-smokers ( $0.50 \pm 0.16$  mg/dL) (Table I). Similar observations were also made in other laboratories [24,25]. The plasma vitamin C levels of CS-related cardiovascular patients ( $0.15 \pm 0.01$  mg/dL) are further lower ( $p = 0.0000$ ) than that of smokers without disease (Table I).

### CS-induced Oxidative Stress in the Myocardium

We had previously shown that after exposure to CS, p-BSQ of CS is oxidized to p-BQ in the lungs that gets into the blood stream [16,21]. p-BQ is a strong arylating agent [21] and here we show that p-BQ carried in the blood goes to the heart and forms p-BQ-protein adducts (Figure 2A). Adduct formation is absent in the air-exposed sham controls or negligible in CS-exposed vitamin C-sufficient group (Figure 2A). Besides being an arylating agent, p-BQ is a strong redox cycling agent that produces ROS and oxidative damage [17,22]. It is known that formations of protein



**Figure 1. Progression and detection of myocardial injury in CS-exposed guinea pigs and prevention by vitamin C.** (Panel **A**) Immunoblots of cardiac Troponin T and I in serum. Bottom panel indicates ponceau S staining of the membrane as the loading control. (Panel **B**) Hematoxylin and Eosin (H&E) and Masson's trichrome stain showing histological changes in cardiomyocytes as well as blood vessels; → indicate thrombus formation and fibrous tissue (FT) deposition (magnification 400X). (Panel **C**) Bar graphs depicting progression of thrombus formation (% area within blood vessel by H&E staining) and fibrous tissue deposition (% area in left ventricle by Masson's trichrome staining). (Panel **D**) Detection of collagen type I. (Panel **E**) Lipid profile in serum. Bar over the respective columns represents mean  $\pm$  SEM (n=6), \* indicates significant (p<0.05) increase from AIR-exposed sham control, \*\* indicates significant (p<0.05) decrease in vitamin C-sufficient group. Vit C means vitamin C. doi:10.1371/journal.pone.0044151.g001

carbonyl and 8-oxo-2'-deoxyguanosine (8-oxodG) are hallmarks of oxidative damage. We show that after exposure of CS to the marginal vitamin C-deficient guinea pigs for 2 weeks, both protein carbonyls (Figure 2B) and 8-oxodG (Figure 2C and 2D) are produced in the myocardium that increased with increased exposure to CS up to 8 weeks. It is reported that oxidative stress induces structural damage of cardiac myocytes and plays a key role in the pathophysiology of heart failure [39,40]. Oxidative damage is almost prevented when the CS-exposed guinea pigs are fed 15 mg vitamin C/day (Figure 2).

### CS-induced Inflammation

Oxidative damage has the potential to trigger inflammatory cytokines, such as tumor necrosis factor- $\alpha$  (TNF- $\alpha$ ) and interleukin IL-1 $\beta$  [40,41]. TNF- $\alpha$  and IL-1 $\beta$  activate NF- $\kappa$ B. We demonstrate that oxidative damage is the initial event, which is followed by inflammation. While oxidative damage starts after 2 weeks of CS exposure to marginal vitamin C-deficient guinea pigs, up regulation of both TNF- $\alpha$  and NF- $\kappa$ B takes place after 4 weeks of smoke exposure that persists up to 8 weeks (Figure 3A). We further show that IL-1 $\beta$  is significantly increased (p<0.05) in the serum of guinea pigs, which is apparently released from the injured myocardium (Figure 3B). Inflammation is known to be accompanied by infiltration of neutrophils. Histopathology shows marked neutrophil adhesion to the endothelium of a blood vessel after 4 weeks of CS exposure to marginal vitamin C-deficient guinea pigs. After 6–8 weeks of CS exposure, neutrophil infiltration is observed in the myocardium (Figure 3C). No neutrophil infiltration is observed either in sham control or CS-exposed vitamin C-sufficient group (Figure 3C).

Marginal neutrophils exert potent cytotoxic effects through the release of proteolytic enzymes like matrix metalloproteinases

(MMPs) [41,42]. Figure 3D shows that both MMP-9 and MMP-12 are up regulated in the myocardium of marginal vitamin C-deficient guinea pigs after exposure to CS for 4–8 weeks. No such up regulation is noticed in the sham controls or CS-exposed guinea pigs fed 15 mg vitamin C/day (Figure 3D).

### CS-induced Apoptosis in Injured Myocardium

It is now believed that besides necrosis apoptosis plays an important role in CVD [1]. Over the past few years, there have been several reports of the occurrence of cardiomyocyte apoptosis during myocardial injury [43,44]. According to the earlier reports oxidative stress can trigger either the 'intrinsic' (mitochondrial) or extrinsic (extra mitochondrial) apoptotic pathways via multiple mechanisms [45]. It has been suggested that cytochrome c-mediated apoptosis is important in cardiomyocyte death [46]. Figure 4A indicates that after exposure of marginal vitamin C-deficient guinea pigs to CS for 4 weeks cytochrome c is almost absent in the mitochondria that is accompanied by its marked presence in the cytosol. Figure 4B shows quantitative estimation of both fractions depicting release of cytochrome c in the cytosolic fraction under 'intrinsic' apoptotic condition. Apoptosis of the cardiomyocytes after CS exposure is further confirmed by activation (phosphorylation) of p53, increase in the ratio of Bax/Bcl-2 and activation of caspase 3, as revealed by the formation of cleaved caspase 3 (Figure 4C). Extra mitochondrial apoptosis is evidenced by the up regulation of TNF- $\alpha$  (Figure. 3A, row 1) and activation of caspase 8 (Figure 4D). It is reported that TNF- $\alpha$  plays a role in the progression of CVD [41]. Neither mitochondrial nor extra mitochondrial apoptosis has been observed in CS-exposed vitamin C-sufficient guinea pigs (Figure 4C and 4D).

DNA fragmentation is also a criterion of early apoptosis. TUNEL assay shows that compared to sham controls, there is

**Table 1.** Plasma vitamin C levels in non-smokers, smokers without disease and CS-related cardiovascular patients.

Total Subjects	74						
	Subjects status			Smoker without disease		CS-related cardiovascular patients	
Subjects subgroup	Non-smoker			Heavy smoker	Moderate smoker	Acute myocardial infarction	Other forms of heart diseases
	Subjects number	25					
	4	12	9	14	11	12	12
Age (year)	40–50	50–60	60–70	40–50	50–60	60–70	45–55
Cigarettes/day				25–30	15–20	20–25	15–20
Year of smoking				20	30	30	20
Year since cessation of smoking						$\leq 3$	$\leq 1$
Plasma vitamin C level (mg/dL)	0.50 $\pm$ 0.16			*0.18 $\pm$ 0.01		**0.15 $\pm$ 0.01	

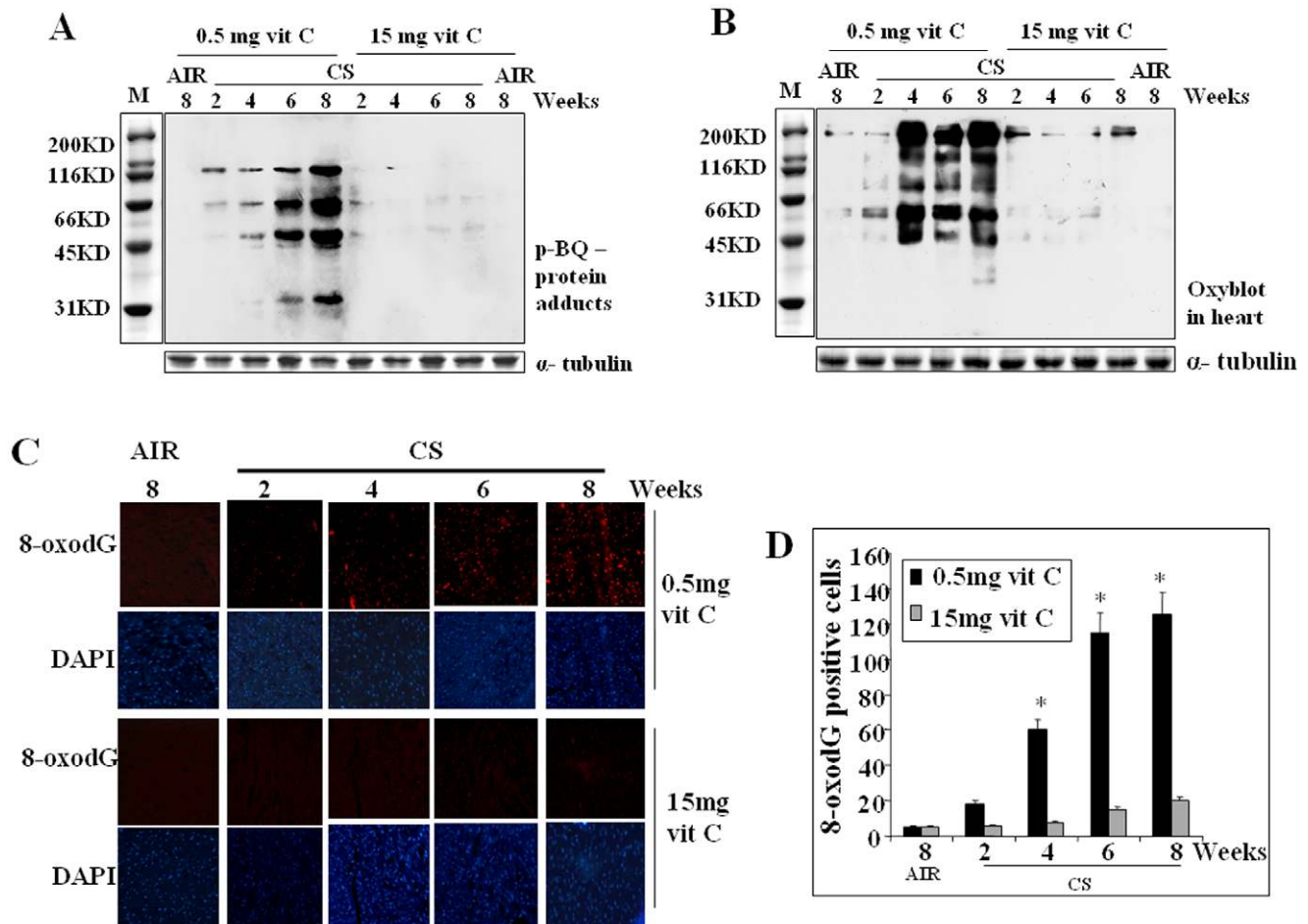
The vitamin C level of plasma was estimated by HPLC; data represent mean  $\pm$  SD.

\*significantly lower (p=0.0000) than non-smokers.

\*\*significantly different from smokers without disease (p=0.0000); 95% CI for mean: Non-smokers, 0.46–0.54; smokers without disease, 0.14–0.22; CS-related cardiovascular patients, 0.11–0.19.

doi:10.1371/journal.pone.0044151.t001





**Figure 2. Identification of p-BQ-protein adducts and detection of oxidative stress in myocardium of CS-exposed guinea pigs and prevention by vitamin C.** (Panel A) p-BQ protein adducts in the myocardial tissue. (Panel B) Protein carbonyl formation by Oxyblot™. (Panel C) DNA oxidation; upper row: red fluorescence indicates formation of 8-oxo-2'-deoxyguanosine (8-oxodG); lower row: stained with 6-diamidino-2-phenylindole (DAPI); (magnification 200X). (Panel D) Quantitative evaluation of 8-oxodG; Bars over the respective columns represent means  $\pm$  SEM (n=6) \* indicates significant ( $p < 0.05$ ) increase from AIR exposed sham control. Vit C means vitamin C. doi:10.1371/journal.pone.0044151.g002

progressive increase in the DNA fragmentation after 4–6 weeks of CS exposure to the marginal vitamin C-deficient guinea pigs (Figure 4E). Figure 4F shows quantitative evaluation of TUNEL positive cells. DNA fragmentation is almost absent in CS-exposed vitamin C-sufficient group.

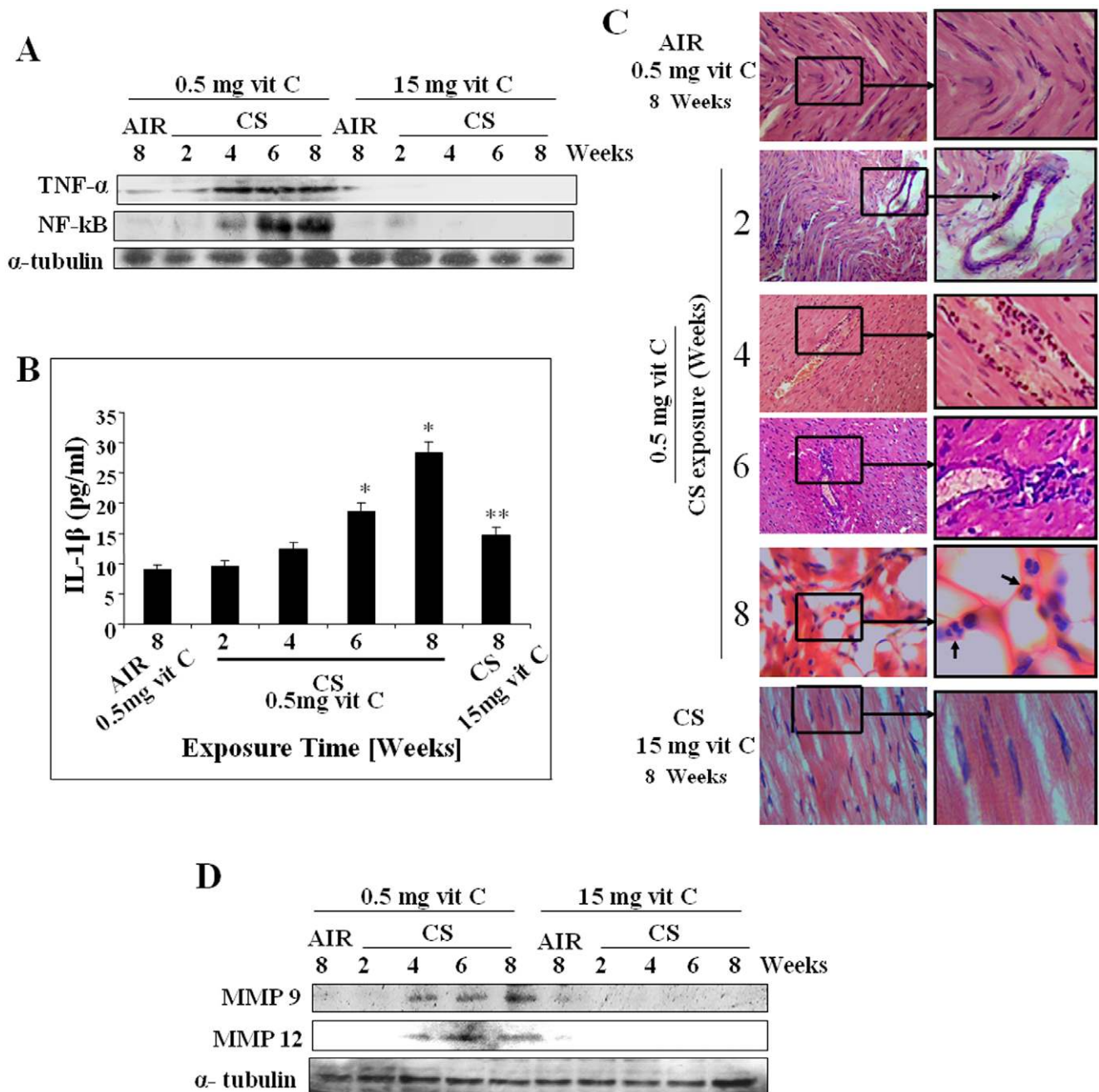
### p-Benzoquinone (p-BQ) Induces Oxidative Damage, Inflammation and Apoptosis Leading to Myocardial Injury in Guinea Pigs *in vivo*

The calculated amount of total p-BQ available from CS exposure/guinea pig/day was 25  $\mu$ g (see Materials and Methods). When CS exposure was replaced by p-BQ treatment (25  $\mu$ g/animal/day), significant release of cardiac Troponin T and I occurred in the serum of marginal vitamin C-deficient guinea pigs (Figure 5A). This was accompanied by myocardial injury and fibrosis, as evidenced by collagen deposition (Figure 5B). Figure 5C depicts quantitative estimation of myocardial injury and deposition of collagen fibres. p-BQ treatment also resulted in up regulation of MMP-9 and MMP-12 as well as increased synthesis of collagen type 1 (Figure 5D). Furthermore, p-BQ produced proteins adducts (Figure 5E) and oxidative damage, as evidenced by the formation of protein carbonyls and 8-oxodG (Figures 5F and 5G). Similar to

that observed by CS exposure, p-BQ treatment caused increase in the inflammatory markers TNF- $\alpha$  and NF- $\kappa$ B (Figure 5H). p-BQ also produced apoptosis as revealed by the overexpression phospho-p53 (pp53), increase in the Bax/Bcl-2 ratio and formation of cleaved caspase 3 (Figure 5I). All the aforesaid pathophysiological events were not produced in the vitamin C-sufficient group (Figure 5).

### p-BQ is Responsible for Aqueous Extract of Cigarette Smoke (AECS)-induced Oxidative Stress and Apoptosis in Rat Cardiomyocytes (H9c2)

AECS (50  $\mu$ l/mL)-induced ROS generation, formation of protein carbonyl and protein adducts in rat cardiomyocytes were not only prevented by antibody to p-BQ but also mimicked by p-BQ in amounts (2.5  $\mu$ g/ml) present in AECS (Figure 6A, 6B and 6C). Also, AECS-mediated apoptosis, as evidenced by Annexin V/PI staining, phosphorylation of p53 as well as activation of caspases 3 and 8, were prevented by antibody to p-BQ and mimicked by p-BQ (Figure 6D, 6E and 6F). The results indicate that p-BQ is responsible for AECS-mediated oxidative stress, formation of protein adduct and apoptosis *in vitro*. Like that



**Figure 3. Detection of inflammatory response, neutrophil infiltration in the injured myocardium, activation of metallo matrix proteinases (MMPs) in CS-exposed guinea pigs and prevention by vitamin C.** (Panel A) Immunoblots of TNF- $\alpha$  and NF-kB in myocardial tissue lysate. (Panel B) ELISA test indicating IL-1 $\beta$  (pg/ml) level in serum. (Panel C) Hematoxylin and Eosin (H&E) stain showing neutrophil infiltration in the injured myocardium;  $\rightarrow$  indicates neutrophils within injured myocardium (magnification 200X) (Panel D) Immunoblots of MMP-9, MMP-12 in myocardial tissue lysate. Vit C means vitamin C.  
doi:10.1371/journal.pone.0044151.g003

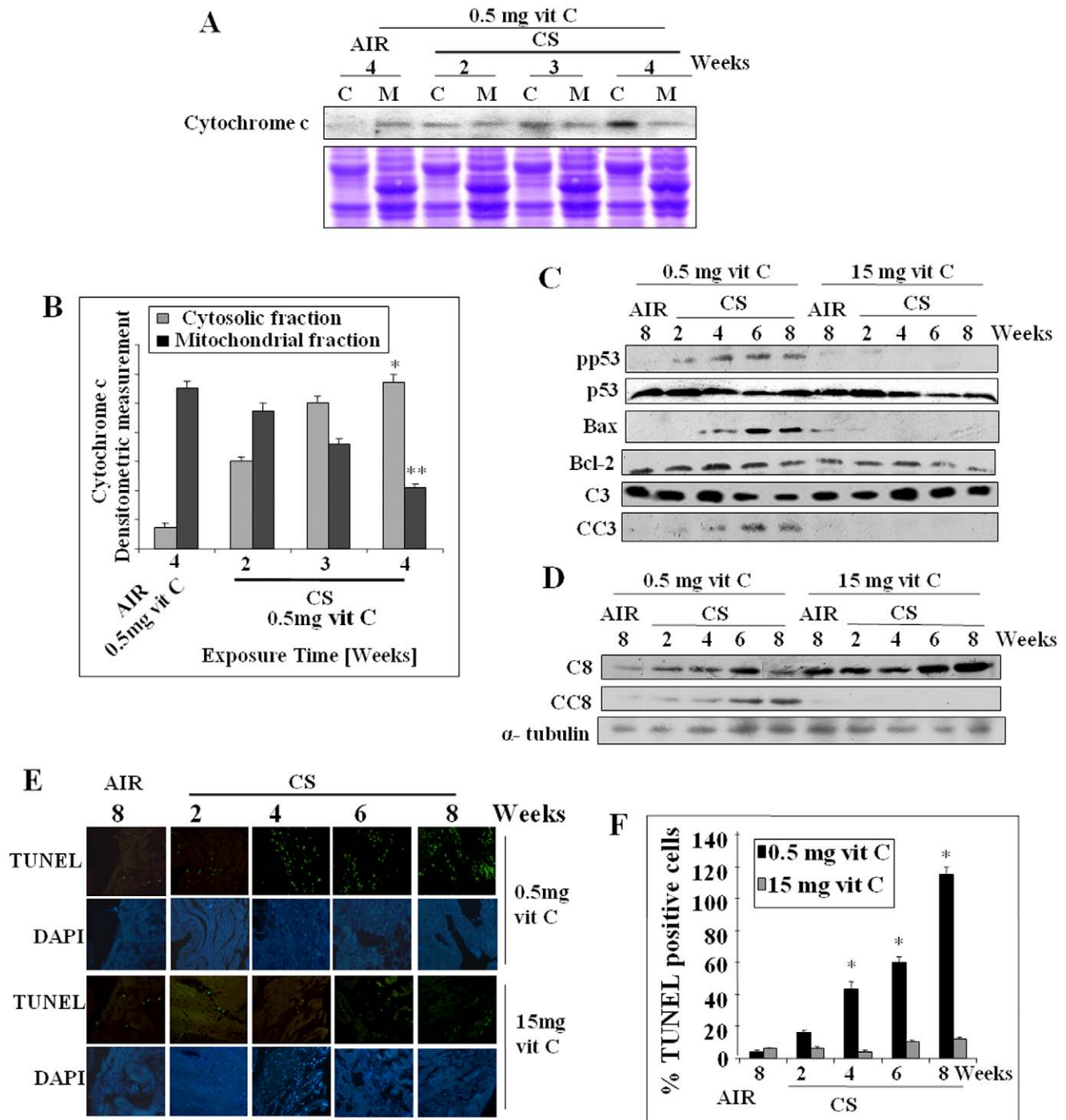
observed *in vivo*, all the aforesaid events were also prevented by addition of vitamin C (40  $\mu$ g/ml) to the incubation medium.

## Discussion

In this paper using a guinea pig model, we have addressed the fundamental questions that remain poorly answered regarding the initiation, molecular mechanisms and temporal progression of CS-induced myocardial injury and its prevention. Myocardial injury has been evidenced by histology indicating

thrombosis, fibrosis of the myocardium and collagen deposition in the left ventricular part of the heart of guinea pigs. Histology is supported by lipid profile that shows increase in triglyceride and LDL cholesterol. Also, release of cardiac Troponin-T and I in serum confirm the onset of myocardial injury [34].

Existing evidence indicate a strong association between CS, oxidative stress and CVD [5]. Here we show both *in vivo* as well as *in vitro* that oxidative stress is the initial event and p-BQ derived from CS is a major factor responsible for CS-induced oxidative

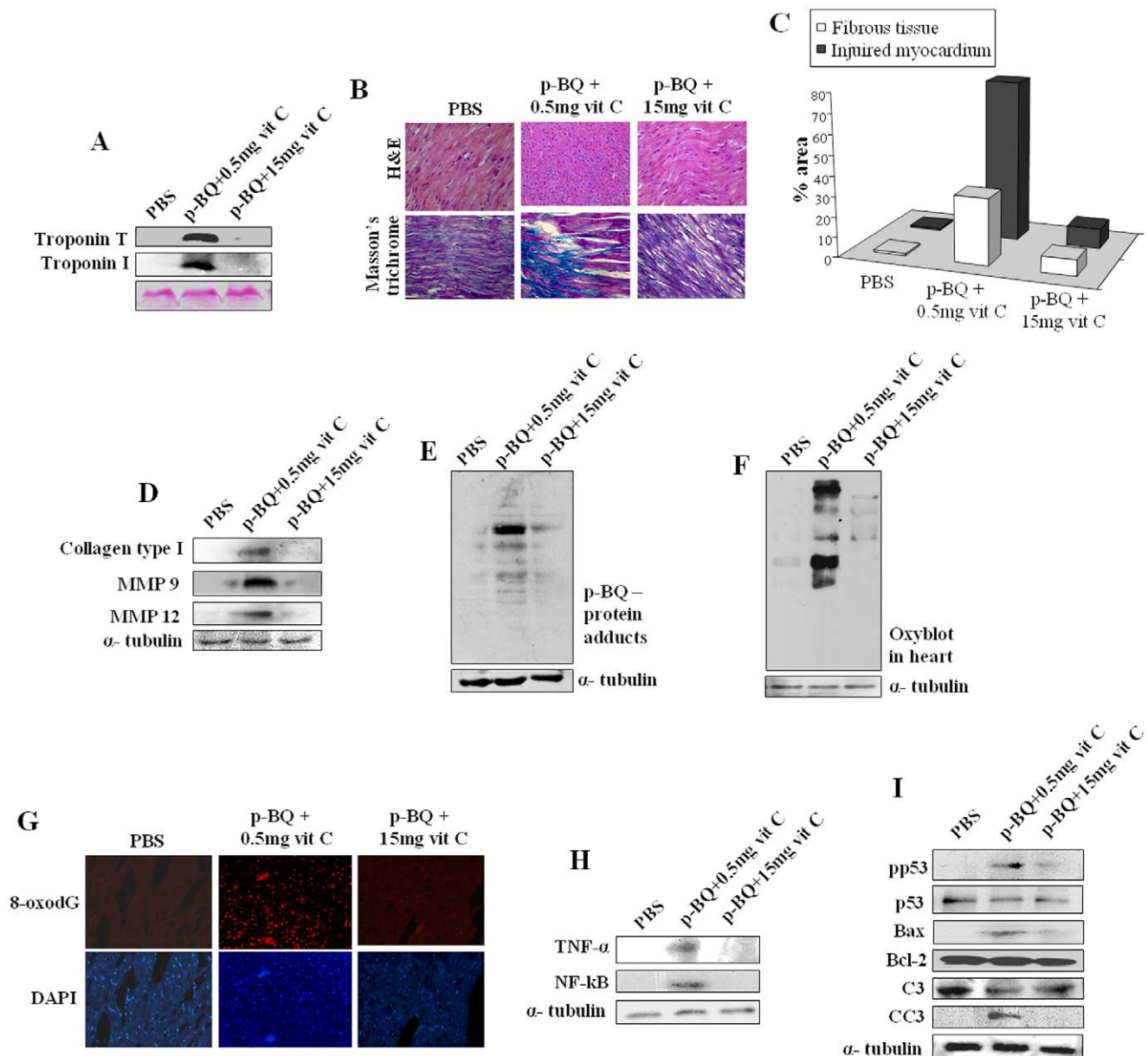


**Figure 4. Assessment of apoptosis in the myocardium of CS-exposed guinea pigs and prevention by vitamin C.** (Panel A) Release of cytochrome c from mitochondria to cytosol. Bottom panel indicates cropped SDS-PAGE with coomassie stain as the loading control. (Panel B) Quantitative estimation of cytochrome c of both fractions; \* significantly increased ( $p < 0.05$ ) in cytosolic fraction with respect to AIR exposed sham controls; \*\* significantly decreased ( $p < 0.05$ ) in mitochondrial fraction with respect to AIR exposed sham controls. (Panel C) Overexpression of pp53 (phospho-p53), Bax, and formation of cleaved caspase 3 (CC3). (Panel D) Formation of cleaved caspase 8 (CC8). (Panel E) TUNEL positive cells in the myocardium (green fluorescence); respective lower rows stained with 6-diamidino-2-phenylindole (DAPI) (magnification 200X). (Panel F) Quantitative evaluation of TUNEL positive cells; bars over the columns indicate means  $\pm$  SEM ( $n = 6$ ); \* significantly increased ( $p < 0.05$ ) with respect to AIR exposed sham controls. Vit C means vitamin C. doi:10.1371/journal.pone.0044151.g004

damage of proteins and DNA in the myocardium. We have also demonstrated that oxidative damage is followed by inflammation and apoptosis that ultimately leads to myocardial injury. All the

pathophysiological events are prevented by oral administration of vitamin C (15 mg/animal/day).





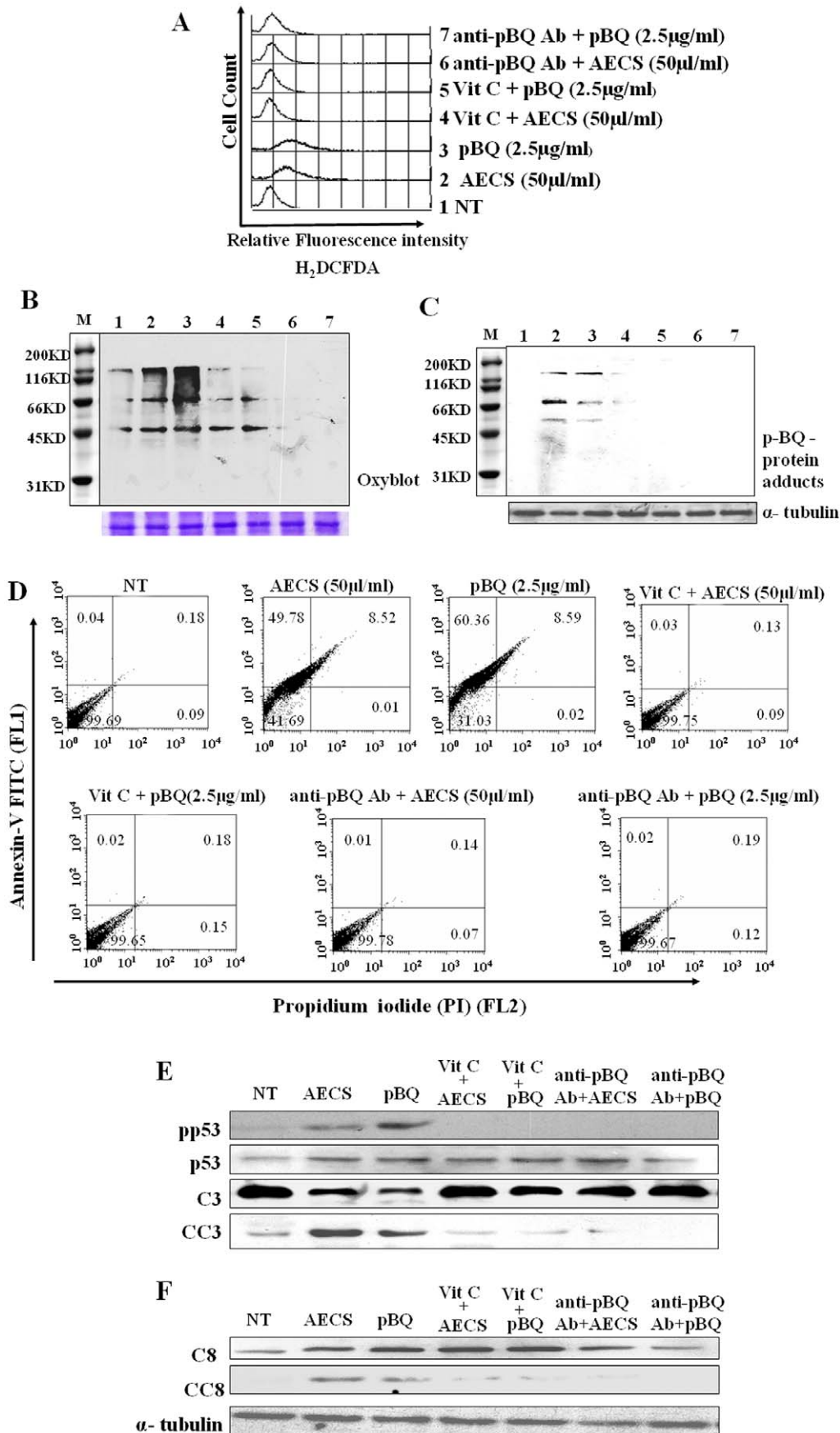
**Figure 5. Detection of myocardial injury in p-BQ-treated guinea pigs and prevention by vitamin C.** (Panel A) Cardiac troponin T and I in the serum. Bottom panel represents ponceau 5 staining of the membrane as the loading control. (Panel B) Histology showing myocardial injury and deposition of collagen fibres (magnification 200X). (Panel C) Quantitative analyses of histological images of panel B. (Panel D) Immunoblots of collagen type1, MMP-9 and MMP-12. (Panel E) p-BQ protein adducts in the myocardial tissue. (Panel F) Protein oxidation as evidenced by Oxyblot™. (Panel G) DNA oxidation as evidenced by the formation of 8-oxo-2'-deoxyguanosine (8-oxodG) (red fluorescence); lower row: stained with 6-diamidino-2-phenylindole (DAPI); (magnification 200X). (Panel H) Immunoblots of TNF- $\alpha$  and NF- $\kappa$ B. (Panel I) Over expression of phospho-p53 (pp53) and Bax and formation of cleaved caspase 3 (CC3). Vit C means vitamin C. doi:10.1371/journal.pone.0044151.g005

We show that inflammation is accompanied by thrombus formation. Thrombosis results in ischemia. In the ischemic region and surrounding myocardium, inflammatory cytokines, such as TNF- $\alpha$ , IL-1 $\beta$  are triggered as a host reaction. TNF- $\alpha$  and IL-1 $\beta$  are inducers of NF- $\kappa$ B, a family of transcription factors that plays a major role in the regulation of diverse genes involved in the inflammatory response [40,41]. Here we show that TNF- $\alpha$  and NF- $\kappa$ B are activated in the myocardium after 4 weeks and persisted up to 8 weeks of the experimental condition of CS exposure. After 6 weeks of CS exposure, IL-1 $\beta$ , apparently secreted by the injured myocardium, is released in the serum.

Previous studies suggest that inflammation is a critical factor in the initiation and progression of CVD [6].

A hall mark of acute inflammation is recruitment of leukocytes including neutrophils to the site of injury. After 4 weeks of CS exposure, neutrophil transmigration occurs into the injured myocardium that continues up to 8 weeks. Activated neutrophils and macrophages release proteolytic enzymes, including collagenolytic matrix metalloproteinases (MMPs), including MMP-9 and MMP-12 [41,42]. Our results indicate that both MMP-9 and MMP-12 are released in the myocardium after 4 weeks of CS





**Figure 6. AECs-induced pathophysiological disorders are mimicked by p-BQ in rat cardiomyocytes (H9c2).** (Panel A) ROS generation. (Panel B) protein oxidation by Oxyblot™. (Panel C) Formation of p-BQ-protein adducts. (Panel D) Apoptosis as evidenced by Annexin V/PI staining. (Panel E) Activation of p53 and caspase3. (Panel F) Activation of caspase 8. doi:10.1371/journal.pone.0044151.g006

exposure. The release of MMPs is accompanied by an increase in collagen type 1 synthesis and its deposition in the myocardium.

Although cardiomyocyte death may occur via necrosis or apoptosis, apoptosis is now emerging as major contributor [1]. The apoptotic signals in mammals may be transduced by “intrinsic” and/or “extrinsic” pathways. The intrinsic pathway is primarily activated in myocytes by ischemic hypoxia and oxidative stress that incite increased permeability of mitochondrial membranes, release of cytochrome c from the mitochondria to the cytosol, and activation of caspase 3, a key effector protein in the execution of downstream event in apoptosis. Extrinsic apoptotic pathway involves transduction of a signal from membrane receptors belonging to the tumor receptor factor such as Fas or TNF receptor 1. Stimulation of death receptors results in activation of caspase 8, which in turn activates caspase 3. We have shown in this paper that exposure of CS to marginal vitamin C-deficient guinea pigs induces both “intrinsic” and “extrinsic” pathways of apoptosis in a time-dependent manner. Besides activation of caspase 8 and caspase 3, CS exposure also resulted in DNA fragmentation, activation of p53 and increase in the Bax/Bcl-2 ratio. Alteration of balance between Bax and Bcl-2 by p-BQ treatment was reported in human lung carcinoma cells (A549) *in vitro* [47]. We have further shown that oral administration of vitamin C (15 mg/day) to the guinea pigs almost completely prevents CS-induced apoptosis. We consider that vitamin C prevents CS-induced myocardial injury by preventing oxidative stress and thereby inflammation and apoptosis.

Previously we had shown that p-BQ, a redox cycling agent produced from p-BSQ of CS, is a major factor that produces ROS, oxidative damage and apoptosis [16,17,22]. Here we show both in the guinea pig *in vivo* and rat cardiomyocytes (H9c2) *ex vivo* that p-BQ is a causative factor responsible for producing CS-induced ROS, oxidative damage, inflammation and apoptosis leading to myocardial injury. Vitamin C is a known scavenger of free radicals that prevents oxidative damage, lipid peroxidation and myocardial injury [48,49]. Vitamin C has also other beneficial effects in smokers. It is known that CS-induced leukocyte aggregation and adhesion to endothelium may lead to thrombosis. It is reported that vitamin C almost entirely prevents CS-induced leukocyte adhesion to micro- and macrovascular endothelium and leukocyte-platelet aggregate formation [50]. This might be one of the reasons how sufficient vitamin C prevents thrombosis in CS-induced guinea pigs.

We have shown in this paper that compared to non-smokers ( $0.50 \pm 0.16$  mg/dL), plasma vitamin C levels of smokers without disease ( $0.18 \pm 0.01$  mg/dL) are very low ( $p = 0.0000$ ). This has also been reported before [24,25]. The plasma vitamin C levels of CS-related cardiovascular patients ( $0.15 \pm 0.01$  mg/dL) are further lower ( $p = 0.0000$ ) than that of smokers without disease. This may be an effect of CVD. Vitamin C ( $E_o \pm 0.08V$ ) is strongly oxidized and thereby consumed by p-BQ ( $E_o \pm 0.71V$ ). We consider that a major part of the decline of plasma vitamin C in smokers is due to consumption of vitamin C by p-BQ. The inverse association between smoking and plasma vitamin C levels occurs independently of dietary intake [17,25].

In a recent report, the effects of N-acetyl cysteine (NAC), an antioxidant and anti-inflammatory agent, was studied in a rat model of MI created by ligation of the left anterior descending artery followed by chronic exposure of CS [51]. NAC, adminis-

tered intraperitoneally, produced significant decrease in oxidative damage, inflammation and circulating levels of cytokines resulting in marked amelioration of the extent of myocardial damage. Previously we examined the efficacy of oral administration of NAC in the treatment of CS-induced emphysema in our guinea pig model. Whereas vitamin C protected CS-induced emphysema almost completely, NAC prevented the extent of lung damage to about 33% [16]. However once CS-induced damage is done, vitamin C cannot ameliorate the injury.

In conclusion we state that p-BQ, derived from CS, is a major risk factor responsible for causing CS-induced oxidative damage, which is followed by inflammation and apoptosis, ultimately leading to myocardial injury (Figure 7). The injury is accompanied by vascular thrombosis, collagen deposition in the left ventricular part of the heart and release of Troponin T and I in the serum. All these events indicate occurrence of MI. However, this needs to be confirmed by doing ECG and echocardiogram. We have shown that dietary supplementation of vitamin C prevents CS-induced myocardial injury apparently by reducing and thereby inactivating p-BQ. In population-based studies, we have observed that plasma vitamin C levels of habitual smokers are very low, which may make them susceptible to CVD. We consider that intake of a moderately large dose of vitamin C may protect the smokers from CS-induced myocardial injury.

CS  $\rightarrow$  p-BSQ  $\rightarrow$  p-BQ

$\downarrow$  Vitamin C Myocardium  $\rightarrow$

Oxidative damage  $\rightarrow$  Inflammation  $\rightarrow$  Apoptosis  $\rightarrow$  Myocardial Injury

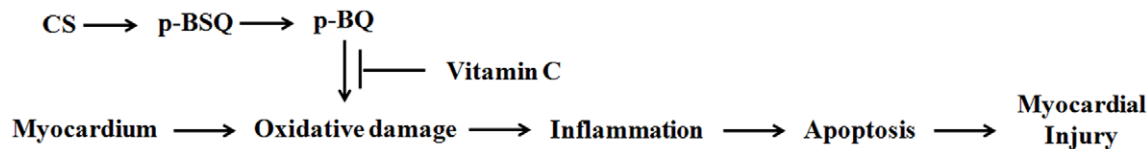
## Materials and Methods

### Ethics Statement

All methods were approved by the Institutional Animal Ethics Committee, Permit No. 797/CPCSEA, University of Calcutta. All efforts were made to minimize suffering of the animals. The collection of human blood and subsequent experiments with plasma were approved by the Institutional Bioethics Committee for animal and human research studies, University of Calcutta, permission No. 1096, following the Code of Ethics of the World Medical Association (Declaration of Helsinki) for experiments involving humans.

### Exposure of Guinea Pigs to CS

Male short hair inbred albino guinea pigs weighing 400–500 g were fed vitamin C-free diet for 7 days to minimize the vitamin C level of tissues [16,27] (see Materials and Methods S1). After 7 days, the guinea pigs were subjected to cigarette smoke exposure from 5 Kentucky research cigarettes 3R4F/day @ 2 puffs/cigarette/animal in a smoke chamber, as described before [16,17,27]. (see Materials and Methods S1). Pair-fed sham controls were subjected to air exposure instead of CS under similar conditions. The guinea pigs were divided into the following weight-matched experimental groups ( $n = 6$ /group). (i) exposed to CS and supplemented with 0.5 mg vitamin C/animal/day (CS-exposed marginal vitamin C-deficient group); (ii) exposed to CS and supplemented with 15 mg vitamin C/animal/day (CS-exposed vitamin C-sufficient group); (iii) exposed to air and fed 0.5 mg vitamin C/animal/day (sham control); exposed to air and fed 15 mg vitamin C/animal/day. At the end of 8 weeks of CS



**Figure 7. Mechanisms of CS-induced myocardial injury and its prevention by vitamin C.**  
doi:10.1371/journal.pone.0044151.g007

exposure, the guinea pigs were euthanized under deep anesthesia using i.p. injection of ketamine hydrochloride (100 mg/kg body weight) and blood, heart and other tissues were collected for further experiments.

#### Treatment of Guinea Pigs with p-BQ

After feeding vitamin C-free diet for 7 days, as mentioned above under “Exposure of guinea pigs to cigarette smoke”, the guinea pigs ( $n = 4$ ) were given intramuscular injection (lumber muscle) of 25  $\mu\text{g}$  p-BQ/animal/day in 100  $\mu\text{l}$  of Milli Q water for 8 weeks. The p-BQ was purchased from Himedia (RM-489) and freshly crystallized from n-hexane before use. The amount of p-BQ injected (25  $\mu\text{g}$ /day/guinea pig, i.m.) was to mimic the calculated amount of total p-BQ available per day/guinea pig inhaled from 5 Kentucky research cigarettes in the smoke chamber (see Materials and Methods S1). The sham controls received injection of only water. After 8 weeks, the guinea pigs were euthanized under deep anesthesia using i.p. injection of ketamine hydrochloride (100 mg/kg body weight) and blood, heart and other tissues were collected for further experiments.

#### Preparation of Aqueous Extract of CS (AECS)

AECS was prepared as before [52] and used without delay (see Materials and Methods S1).

#### Measurement of p-BQ in AECS

p-BQ was measured by HPLC, as described before [52]. (see Materials and Methods S1).

#### Collection of Blood from Human Volunteers

Written consents were obtained from all the volunteers prior to collection of blood. Venous blood ( $\approx 2$  ml) was collected and plasma separated immediately. For estimation of vitamin C, dithiothreitol (DTT) (1 mmol/L final concentration) was added to the plasma to prevent loss of vitamin C by autooxidation.

#### Measurement of Vitamin C in Plasma

Vitamin C was measured by HPLC as described before [16] (see Materials and Methods S1).

#### Histology for Assessing Myocardial Damage and Fibrosis

The left ventricular part of the heart was surgically removed and fixed in 10% neutral buffered formalin for 24 hours, embedded in paraffin and subjected to microtomy (4  $\mu\text{m}$ ) routinely. A part of the cardiac tissue was stored at  $-80^\circ\text{C}$  until processing. The deparaffinized sections were stained with i) conventional hematoxylin-eosin (H&E) (Sigma) to determine the degree of cardiomyocytes damage, neutrophil infiltration and myocardial fibrosis ii) collagen content assessment by Masson’s Trichrome stain. Images were captured with a bright field microscope (Dewinter) equipped with high resolution digital Digieye 330/210 camera and quantified using Dewinter Biowizard 4.1 software.

#### Lipid Profile in Serum of CS-exposed Guinea Pigs

Blood samples were collected from CS-exposed guinea pigs by cardiac puncture and serum separated. Total cholesterol, HDL, LDL, VLDL, and triglyceride were measured in serum in a fully automated analyzer, Model: XL-300 (Eeba Mannheim).

#### Myocardial Marker Analysis

The serum of CS-exposed guinea pigs was used immediately for the detection of cardiac troponin-T and troponin-I by immunoblots using cardiac anti-troponin-T and I antibody (abcam, UK.).

#### Lysate Preparation

Frozen heart tissues were homogenized, first by pestle and then glass homogenizer in cold lysis buffer (50 mmol/L Tris-HCl; 1 mmol/L DTT, 1mmol/L EDTA (in place of 100 AMo-phenanthroline), 0.2% Nonidet P-40, pH 7.4) supplemented with protease inhibitor cocktail (Sigma, USA), phosphatase inhibitor cocktail (Sigma, USA) [53]. Rat cardiomyocytes (H9c2) were also extracted in the same lysis buffer. Samples were spun at 19,000 g at  $4^\circ\text{C}$  for 15 minutes and the supernatants collected.

#### Collagen Type 1 Synthesis

Synthesis of collagen (type 1) was measured by immunoblot using antibody to collagen type 1 (Santa Cruz biotechnology, Inc., California, USA).

#### Identification of p-BQ-protein Adduct

Tissue/cell lysates were immunoblotted using antibody against p-BQ (rabbit, polyclonal; Abexome Biosciences, Bangalore, India) [17].

#### Detection of Oxidative Damage in Myocardial Tissue

Protein oxidation was measured by the formation of protein carbonyls by immunoblot using antibody to 2, 4-dinitrophenylhydrazine (DNPH) as per Oxyblot™ protein oxidation detection kit (Intergen, NY) [17]. DNA oxidation was detected by immunofluorescence using antibody to 8-oxodG as per manufacturer’s (Abcam, UK) instruction [16].

#### Inflammation and Quantification of Cytokine Level

Cytokine (IL-1 $\beta$ ) was analyzed using a sandwich ELISA kit (Human IL-1 $\beta$  ELISA Kit II, BD optEIA™). Other inflammatory markers like TNF- $\alpha$ , NF- $\kappa\text{B}$ , MMP-9 and MMP-12 were measured by immunoblot using respective antibodies (TNF- $\alpha$  and NF- $\kappa\text{B}$ : Cell Signaling Technology, USA; MMP-9 and MMP-12: Santa Cruz biotechnology, Inc., California, USA).

#### Assessment of Apoptosis

Thirty  $\mu\text{g}$  protein/lane were separated on 10% SDS-PAGE, blotted on PVDF membrane, and probed with respective antibodies against p53, phospho-p53, Bax, Bcl-2, caspase 3, cleaved caspase 3, caspase 8, cleaved caspase 8,  $\alpha$ -tubulin (Cell Signaling Technology, USA). Preparation of mitochondrial extract

and immunoblot of cytochrome c (Cell Signaling Technology, USA) were carried out as described previously [16]. Quantitative estimation of cytochrome c was made by densitometric scanning using Image Quant TL software. Apoptosis was also measured by the terminal deoxynucleotidyl transferase-mediated dUTP nick end labeling (TUNEL) assay using “In situ cell death detection kit, fluorescein” (Roche, USA) according to the manufacturer’s instruction [16]. Two fields per section of 6 independent sections in each group were evaluated.

### Cell Culture

Rat cardiomyocyte (H9c2) cells (source: National Centre for Cell Science, India) were grown to 50–60% confluence in Dulbecco’s Modified Eagle Medium (DMEM) containing 10% fetal calf serum ((GIBCO)-BRL, USA), 100 units/ml penicillin and 100 µg/ml streptomycin.

### Detection of Reactive Oxygen Species (ROS) and Protein Oxidation in H9c2 Cells

ROS was measured by flow cytometry (FACS Caliber, Becton Dickinson, USA) using dichlorodihydrofluorescein diacetate (H2DCFDA) (Sigma-Aldrich) as per manufacturer’s instruction. Data were acquired and analyzed using the CELL Quest Programme. Protein oxidation was measured by the formation of protein carbonyls as described previously [16,52].

### Assessment of Apoptosis in H9c2 Cells by FACS

Cultured cells ( $3 \times 10^6$ ), after treatment with/without AECS (50 µL/mL) for 1 hour [52] were washed with PBS solution (Hyclone, Thermo Scientific) and incubated in fresh culture medium for 12 hours. Apoptosis was assessed by Annexin V and

propidium iodide (PI) staining according to manufacturer’s protocol (Becton Dickinson), and analyzed using the FACS Calibur-Cell Quest software (Becton Dickinson) as described earlier [52]. A total of 10,000 events were acquired and dual parameter dot plot of FL-2 (X-axis; PI-fluorescence, log scale) vs. FL-1 (Y-axis; Annexin V-FITC-fluorescence, log scale) was recorded. Immunoblots were also done to confirm apoptosis.

### Statistical Analyses

All values are expressed as mean  $\pm$  SEM except in human patients where the values are given as mean  $\pm$  SD. Statistical significance was carried out using a two factor ANOVA, with factors being CS and vitamin C, or one way ANOVA as needed. The p-values were calculated using appropriate F-tests. Difference with p-values <0.05 was considered significant.

### Supporting Information

#### Materials and Methods S1 (DOC)

### Acknowledgments

We gratefully acknowledge Dr. Prakash Mandal, M.D. and Prof. Gourisankar Ghosh of UCSD, USA for critically reading the manuscript before submission. We thank Dr. Arun Bandopadhyay, IICB, India for kindly providing the H9c2 cell line.

### Author Contributions

Conceived and designed the experiments: IBC. Performed the experiments: AD ND AG SD DJC. Analyzed the data: AD ND IBC. Wrote the paper: IBC AD.

### References

- Gill C, Mestrl R, Samali A (2002) Losing heart: the role of apoptosis in heart disease – a novel therapeutic target? *FASEB J* 16: 135–146.
- Dept of Health and Human Services (2005) Reducing the Health Consequences of Smoking: 25 Years of Progress. A Report of the Surgeon General. US Department of Health and Human Services, Public Health Service, Centers for Disease Control, Center for Chronic Disease Prevention and Health Promotion, Office on Smoking and Health; (1989). DHHS Publication (CDC) 89–8411.
- Giovino GA (2007) The tobacco epidemic in the United States. *Am J Prev Med* 33(6S): S318–S326.
- Burns DM (2003) Epidemiology of smoking-induced cardiovascular disease. *Progress in Cardiovascular Diseases* 46: 11–29.
- Talukder MAH, Johnson WM, Varadharaj S, Lian J, Kearns PN, et al. (2011) Chronic cigarette smoking causes hypertension, increased oxidative stress, impaired NO bioavailability, endothelial dysfunction, and cardiac remodeling in mice. *Am J Physiol Heart Circ Physiol* 300: H388–H396.
- Ambrose JA, Barua RS (2004) The Pathophysiology of cigarette smoking and cardiovascular disease. *An Update J Am Coll Cardiol* 43: 1731–1737.
- Panda K Chatterjee IB (2007) Failure of Alpha-Tocopherol to Prevent Cigarette Smoke-Induce Protein Oxidation: Comparison with Other Antioxidant Vitamins. Victor R. editor, *Encyclopedia of Vitamin E*. Oxford University Press (CABI), Oxfordshire, UK. Preedy, King’s College, London, UK. Chapter 63. p-883–893.
- Dhalla NS, Temsah RM, Netticadan T (2000) Role of oxidative stress in cardiovascular diseases. *J Hypertens*, 18: 655–73.
- Ezzati M, Henley SJ, Thun MJ, Lopez AD (2005) Role of smoking in global and regional cardiovascular mortality. *Circulation* 112: 489–497.
- White WB (2007) Smoking-related morbidity and mortality in the cardiovascular setting. *Prev Cardiol* 10: 1–4.
- Stewart BW, Kleihues P (2003) World cancer report. In *International Agency for Research on Cancer Lyon, France* 21–28.
- Pryor WA, Stone K, Zang L-Y, Bermudez E (1998) Fractionation of aqueous cigarette tar extracts: fractions that contain the tar radical cause DNA damage. *Chem Res Toxicol* 1: 441–448.
- Barbieri SS, Zacchi E, Amadio P, Gianellini S, Mussoni L, et al. (2011) Cytokines present in smokers’ serum interact with smoke components to enhance endothelial dysfunction. *Cardiovascular Research* 90: 475–483 doi:10.1093.
- Bernhard D, Wang XL (2007) Smoking, oxidative stress and cardiovascular diseases—do anti-oxidative therapies fail? *Curr Med Chem* 14: 1703–1712.
- Csordas A, Wick G, Laufer G, Bernhard D (2008) An evaluation of the clinical evidence on the role of inflammation and oxidative stress in smoking-mediated cardiovascular disease. *Biomarker Insights* 3: 127–139.
- Banerjee S, Chattopadhyay R, Ghosh A, Koley H, Panda K, et al. (2008) Cellular and molecular mechanisms of cigarette smoke-induced lung damage and prevention by vitamin C. *Journal of Inflammation* 5: 21.
- Das A, Dey N, Ghosh A, Das T, Chatterjee IB (2011) NAD(P)H: Quinone Oxidoreductase 1 deficiency conjoint with marginal vitamin C deficiency causes cigarette smoke induced myelodysplastic syndromes. *PLoS ONE* 6(5).
- Chatterjee IB. (2005) Process for the isolation of a major harmful oxidant from cigarette smoke.; US Patent No 6,929, 012.
- Dey N, Das A, Ghosh A, Chatterjee IB (2010) Activated charcoal filter effectively reduces p-benzoquinone from the mainstream cigarette smoke and prevents emphysema. *J Biosci* 35(2): 217–230.
- Sullivan AB, Reynolds GF (1976) Substituent effects on the rate of decay of p-benzoquinone anion radicals. *The Journal of Physical Chemistry* 80: 2671–2674.
- Ghosh A, Choudhury A, Das A, Chatterjee NS, Das T, et al. (2012) Cigarette smoke induces p-benzoquinone-albumin adduct in blood serum: Implications on structure and ligand binding properties. *Toxicology* 292: 78–89.
- Bolton JL, Trush MA, Penning TM, Dryhurst G, Monks TJ (2000) Role of quinones in toxicology. *Chem Res Toxicol* 13: 135–160.
- Dhalla NS, Elmoselhi AB, Hata T, Makino N (2000) Status of myocardial antioxidants in ischemia–reperfusion injury. *Cardiovascular Research* 47: 446–456.
- Preston AM, Rodriguez C, Rivera CE, Sahai H (2003) Influence of environmental tobacco smoke on vitamin C status in children 1–3. *Am J Clin Nutr* 77: 167–72.
- Schectman G, Byrd JC, Gruchow HW (1989) The Influence of Smoking on Vitamin C Status in Adults. *Am J Public Health* 79: 158–162.
- Guaiquil VH, Golde DW, Beckles DL, Mascareno EJ, Siddiqui MA (2004) Vitamin C inhibits hypoxia-induced damage and apoptosis signaling pathways in cardiomyocytes and ischemic hearts. *Free Radic Biol Med* 37: 1419–1429.
- Panda K, Chattopadhyay R, Chattopadhyay DJ, Chatterjee IB (2000) Vitamin C prevents cigarette smoke-induced oxidative damage in vivo. *Free Radic Biol Med* 29: 115–24.
- Valkonen MM, Kuusi T (2000) Vitamin C prevents the acute atherogenic effects of passive smoking. *Free Radical Biology & Medicine* 28: 428–436.



29. Kim H, Kang JS, Maeng HG, Bae SY, Lee NE, et al. (2009) The protective effect of vitamin C on cardiomyocyte damage and heart failure. *J Immunol.* 182: 98.22.
30. Wright JL, Cosio M, Churg A (2008) Animal models of chronic obstructive pulmonary disease. *Am J Physiol Lung Cell Mol Physiol.* 295: 1–15.
31. Chatterjee IB (1973) Evolution and the biosynthesis of ascorbic acid. *Science*;182: 1271–1272.
32. Chatterjee IB, Kar NC, Ghosh NC, Guha BC (1961) Biosynthesis of L-ascorbic acid: missing steps in animals incapable of synthesizing the vitamin. *Nature.* 192: 163–164.
33. Wright JL, Churg A (2002) A model of tobacco smoke-induced airflow obstruction in the guinea pig. *Chest.* 121: 188S–191S.
34. PJ (2008) Cardiac troponin is the most effective translational safety biomarker for myocardial injury in cardiotoxicity. *Toxicology* 206–218.
35. Winniford MD, Wheelan KR, Kremers MS (1986) Smoking-induced coronary vasoconstriction in patients with atherosclerotic coronary artery disease: evidence for adrenergically mediated alterations in coronary artery tone. *Circulation.* 73: 662–667.
36. Querejeta R, López B, González A, Sánchez E, Larman M, et al. (2004) Increased collagen type I synthesis in patients with heart failure of hypertensive origin relation to myocardial fibrosis. *Circulation.* 110(10): 1263–8.
37. Craig WY, Palomaki GE, Haddo JE (1989) Cigarette smoking and serum lipid and lipoprotein concentrations: an analysis of published data. *BMJ.* 298: 784–788.
38. MJ, Krauss RM, Ma J, Blanche PJ, Holl LG, et al. (1996) A Prospective Study of Triglyceride Level, Low-Density Lipoprotein Particle Diameter, and Risk of Myocardial Infarction. *JAMA.* 276(11): 882–888.
39. Takano H, Zou Y, Hasegawa H, Akazawa H, Nagai T, et al. (2003) Oxidative stress-induced signal transduction pathways in cardiac myocytes: involvement of ROS in heart diseases. *Antioxid Redox Signal* 5: 789–794.
40. Hori M, Nishida K (2009) Oxidative stress and left ventricular remodeling after myocardial infarction. *Cardiovascular Research* 81: 457–464.
41. Frangogiannis NG, Smith CW, Entman ML (2002) The inflammatory response in myocardial infarction. *Cardiovascular Research.* 53: 31–47.
42. Lu L, Gunja-Smith Z, Woessner JF, Ursell PC, Nissen T, et al. (2000) Matrix metalloproteinases and collagen ultrastructure in moderate myocardial ischemia and reperfusion in vivo. *Am J Physiol Heart Circ Physiol.* 2: H601–H609.
43. McCully JD, Wakiyama H, Hsieh YJ, Jones M, Levitsky S (2004) Differential contribution of necrosis and apoptosis in myocardial ischemia-reperfusion injury. *Am J Physiol Heart Circ Physiol.* 286(5): H1923–35.
44. Saraste A, Pulkki K, Kallajoki M, Henriksen K, Parvinen M, et al. (1997) Apoptosis in human acute myocardial infarction. *Circulation.* 95: 320–323.
45. von Harsdorf R, Li PF, Dietz R (1999) Signaling pathways in reactive oxygen species-induced cardiomyocyte apoptosis. *Circulation.* 99: 2934–41.
46. Narula J, Pandey P, Arbustini E, Haider N, Narula N, et al. (1999) Apoptosis in heart failure: release of cytochrome c from mitochondria and activation of caspase-3 in human cardiomyopathy. *Proc. Natl. Acad. Sci. USA* 96: 8144–8149.
47. Das A, Chakrabarty S, Choudhury D, Chakrabarti G (2010) 1,4- Benzoquinone (PbQ) induced toxicity in lung epithelial cells is mediated by the disruption of the microtubule network and activation of caspase-3. *Chem. Res. Toxicol.* 23: 1054–1066.
48. Niki E (1991) Action of ascorbic acid as a scavenger of active and stable oxygen radicals. *Am J Clin Nutr.* 54: 1119S–1124S.
49. Chakraborty S, Nandi A, Mukhopadhyay C, Chatterjee IB (1992) Protective role of ascorbic acid against lipid peroxidation and myocardial injury. *Mol Cell Biochem* 111: 41–47.
50. Lehr HA, Frei B, Arfors KE (1994) Vitamin C prevents cigarette smoke-induced leukocyte aggregation and adhesion to endothelium in vivo. *Proc Natl Acad Sci U S A.* 91: 7688–7692.
51. Khanna AK, Xu J, Mehra MR (2011) Antioxidant N-acetyl cysteine reverses cigarette smoke-induced myocardial infarction by inhibiting inflammation and oxidative stress in a rat model. *Laboratory Investigation.* 1–12.
52. Dey N, Chattopadhyay DJ, Chatterjee IB (2011) Molecular mechanism of Cigarette smoke induced proliferation of lung cells and prevention by vitamin C. *Journal of Oncology.* Article ID 561862, doi:10.1155/2011/561862.
53. Gillesa S, Zahler S, Welsch U, Sommerhoff CP, Beckera BF (2003) Release of TNF- $\alpha$  during myocardial reperfusion depends on oxidative stress and is prevented by mast cell stabilizers. *Cardiovascular Research.* 60: 608–616.