



Original Article

Molecular detection of *Pneumocystis* in the lungs of cats

Patrizia Danesi^{1,*}, Michela Corrò¹, Christian Falcaro¹, Antonio Carminato¹, Tommaso Furlanello², Monia Cocchi¹, Mark B. Krockenberger³, Wieland Meyer⁴, Gioia Capelli¹ and Richard Malik⁵

¹Istituto Zooprofilattico Sperimentale delle Venezie, Legnaro (PD), Italy, ²Clinica Veterinaria San Marco, Padua, Italy, ³Veterinary Pathology Diagnostic Services, Sydney School of Veterinary Science, University of Sydney, Sydney, New South Wales, Australia, ⁴Molecular Mycology Research Laboratory, Centre for Infectious Diseases and Microbiology, Faculty of Medicine and Health, Westmead Clinical School, Marie Bashir Institute for Emerging Infectious Diseases and Biosecurity, University of Sydney, Westmead Hospital, Westmead Institute for Medical Research, Sydney, Australia and ⁵Centre for Veterinary Education, B22, University of Sydney, Sydney, New South Wales, Australia

*To whom correspondence should be addressed. Patrizia Danesi, DVM, PhD, Istituto Zooprofilattico Sperimentale delle Venezie, Legnaro (PD), Italy. Tel: +0039 049 8084476; E-mail: pdanesi@izsvenezie.it

Received 4 September 2018; Revised 9 November 2018; Accepted 16 November 2018; Editorial Decision 11 November 2018

Abstract

The genus *Pneumocystis* comprises potential pathogens that reside normally in the lungs of a wide range of mammals. Although they generally behave as transient or permanent commensals, they can occasionally cause life-threatening pneumonia (*Pneumocystis* pneumonia; PCP) in immunosuppressed individuals. Several decades ago, the presence of *Pneumocystis* morphotypes (trophic forms and cysts) was described in the lungs of normal cats and cats with experimentally induced symptomatic PCP (after immunosuppression by corticosteroids); yet to date spontaneous or drug-induced PCP has not been described in the clinical feline literature, despite immunosuppression of cats by long-standing retrovirus infections or after kidney transplantation. In this study, we describe the presence of *Pneumocystis* DNA in the lungs of normal cats (that died of various unrelated causes; $n = 84$) using polymerase chain reactions (PCRs) targeting the mitochondrial small and large subunit ribosomal RNA gene (mtSSU rRNA and mtLSU rRNA). The presence of *Pneumocystis* DNA was confirmed by sequencing in 24/84 (29%) cats, with evidence of two different sequence types (or lineages). Phylogenetically, lineage1 (L1; 19 cats) and lineage 2 (L2; 5 cats) formed separate clades, clustering with *Pneumocystis* from domestic pigs (L1) and carnivores (L2), respectively. Results of the present study support the notion that cats can be colonized or subclinically infected by *Pneumocystis*, without histological evidence of damage to the pulmonary parenchyma referable to pneumocystosis. *Pneumocystis* seems most likely an innocuous pathogen of cats' lungs, but its possible role in the exacerbation of chronic pulmonary disorders or viral/bacterial coinfections should be considered further in a clinical setting.

Key words: *Pneumocystis*, cat, mtLSU rRNA, mtSSU rRNA.

Introduction

The genus *Pneumocystis* is used to describe related fungi that have evolved to live in the lower respiratory tract of mammals.¹ They are transmitted by aerosols, with animals typically becoming infected during the neonatal period, resulting in persistent, sometimes lifelong infections.^{2,3} They generally are believed to

be transient or permanent commensals, colonizing very limited portions of the lungs, while causing minimal or no damage to the host.^{4,5} *Pneumocystis* is highly adapted for an existence in host lung, with strict dependence on its mammalian host for nutrients and a stable environment, while utilizing efficient strategies for immune evasion, thereby facilitating persistence in its host. The

Pneumocystis genomes sequenced to date have all demonstrated a contracted genome compared to those of other closely related fungi, revealing adaptive mechanisms to live exclusively in mammalian hosts, very similar to a parasite/host relationship.^{6,7}

This group of fungi does, however, have the potential to behave as an opportunistic pathogen in certain settings, such as severe malnutrition (e.g., in child refugees after the Second World War), immunosuppressive drug therapy (e.g., after solid organ transplantation) or inherited or acquired immunodeficiency states (including AIDS due to long-standing human immunodeficiency virus (HIV) infection).^{3,8} Generally, *Pneumocystis* species show great host selectivity, such that every mammalian group studied has only one or two specific *Pneumocystis* species with which it is strongly associated.^{6,9}

Pneumocystis has the capacity to cause life-threatening pneumonia (*Pneumocystis* pneumonia; PCP) in immunosuppressed individuals, including human transplant recipients, patients receiving immunosuppressive drugs (corticosteroids, methotrexate, azathioprine, calcineurin inhibitors, tumor necrosis factor α [TNF α] antagonists, etc.) and patients with HIV/AIDS.^{10–12} The parallelism between HIV/AIDS in human patients and feline leukemia virus (FeLV) infection in cats has been considered in relation to the pathogenesis of feline pneumocystosis, although no association could be established.¹³ Perhaps more surprisingly, the same is true of the feline immunodeficiency virus (FIV).¹⁴ Spontaneous PCP in cats has not been reported. Cats receiving renal transplants, for example, have never developed PCP despite being susceptible to numerous other opportunistic pathogens such as *Toxoplasma gondii* and *Cryptococcus neoformans*/*Cryptococcus gattii* because of prednisone and cyclosporine administration.¹⁵ PCP can, however, be produced in contrived experimental settings.¹⁶

Pneumocystis in cats was first described by investigators in Mexico and Denmark from 1950 to 1980^{17–19} (reviewed in Table 1) based on characteristic morphology of trophic forms and cysts in feline lung specimens. There was no evidence of symptomatic PCP in these cats, which therefore were considered to be colonized or infected subclinically. Later, a small number of studies investigated cats as potential animal models for *Pneumocystis* infection, probably drawing upon the notion that cats might be susceptible to recrudescence *Pneumocystis* infection, as they are to toxoplasmosis following reactivation of *Toxoplasma gondii* bradyzoite cysts. In these studies, cats were administered extremely high doses of corticosteroids, and as a result, a proportion of them developed PCP pneumonia^{16,20} (Table 1).

Although lower airway disease in cats has been studied extensively in companion animal medicine using modalities including radiology, computed tomography, bronchoalveolar lavage (BAL) cytology, microbiology, and examination of lung tissues at biopsy or necropsy, no clinical cases of pneumonia due to *Pneumocystis* occurring in cats have been described in the clinical veterinary literature to the best of our knowledge. There

are, however, currently no molecular tools to assist the diagnosis of pneumocystosis in cats with atypical lung disease, or to determine if *Pneumocystis* may play a role in exacerbating clinical signs in cats with comorbid lung disease, for example, viral pneumonia (feline calicivirus, feline herpesvirus type 1, pox virus, etc.), “feline asthma” and mycoplasma disease of the lower airways. In addition, studying *Pneumocystis* in cats affords us the opportunity of determining the taxonomy of feline *Pneumocystis* in relation to *Pneumocystis* species encountered in the full range of mammalian species.

The aim of this study was to establish if *Pneumocystis* DNA could be detected in the lungs of normal cats using a molecular protocol targeting mitochondrial gene targets and to describe its prevalence and significance as a potential pathogen. Further, we sought to determine the genetic relatedness of feline *Pneumocystis* isolates with those of rodents, dogs, ferrets, pigs, and other species.

Methods

Sampling

Lung tissue from 84 cats (*Felis catus*) were screened for *Pneumocystis* DNA at the Mycology Unit of the Parasitology Laboratory, Istituto Zooprofilattico Sperimentale delle Venezie (IZSVe–Italy). Lung specimens were obtained from necropsy examinations by the Diagnostic Department of IZSVe, from cats that died because of cancer, acute viral disease, chronic kidney disease, or following vehicular trauma. The right lung of each cat was weighed. The mean weight of the right lung was 30 g (range 15–45 g). The specimen size investigated further (1.0–1.1 g in total) represented approximately 3% of the weight of the right lung, including an equal portion from each of the cranial, middle and caudal lung lobes, respectively. Bronchoalveolar lavage (BAL) specimens were obtained from cats presented to the Clinica Veterinaria San Marco (Padua–Italy), including patients with “labored breathing” or “respiratory distress.” BAL fluid and lung tissue samples were preserved at -20°C prior to DNA extraction and polymerase chain reaction (PCR) testing. Signalment and clinical findings of cats are summarized in Table 2, Supplementary Table 1 (lungs), and Supplementary Table 2 (BAL fluid specimens).

DNA extraction from lung tissue and BAL fluid specimens

Lung tissue

For each cat, lung specimens were placed into a 2 ml tube with 800 μl phosphate-buffered saline (PBS) and 1 tungsten bead (5 mm diameter), and lysed in a Tissue-Lyser (Qiagen, Hilden, Germany) for 1.5 min at 30 Hz. From each tube, 50 μl was transferred into a new 1.5 ml tube. A total of 150 μl of homogenated tissue (made up from the three portions of right lung) was used for DNA extraction.

Table 1. Review of feline *Pneumocystis* studies reported in the literature, including investigations in "norma" cats, FeLV-positive cats, and experimentally immunosuppressed cats.

Prevalence of <i>Pneumocystis</i> positivity	Number of cats studied	FeLV	Immune-suppression	Histology (H&E-stained lung tissue specimens)	Cysts (asci)	Trophic forms	PCP	Reference
4/100 (4.0%)	100	N/R	-	Normal	+	N/R	-	17
10/79 (12.6%)	79	N/R	-	Normal	+	+	-	18
3/75 (4.0%)	75	N/R	-	Normal	+	N/R	-	19
0/5 (0%)	5	+	-	Acute bronchopneumonia	-	-	-	13
0/5 (0%)	5	+	-	Leukemic infiltrates	-	-	-	13
0/3 (0%)	3	+	-	Interstitial pneumonitis	-	-	-	13
0/1 (0%)	1	+	-	Adenomatosis	-	-	-	13
0/19 (0%)	19	-	-	Interstitial pneumonitis	-	-	-	13
6/10 (60%)	10	-	Betamethasone Na PO ₄ 2mg/cat twice weekly	Inconspicuous inflammatory changes, except alveolar macrophages often seen. Foamy or vacuolated alveolar exudate was not observed.	+	+	+ Light PCP infection	16
6/7 (86%)	7	-	Prednisolone acetate 10–12 mg/cat weekly	Inconspicuous inflammatory changes, except alveolar macrophages often seen. Foamy or vacuolated alveolar exudate was not observed.	+	-	+ PCP infection	16
3/3 (100%)	3	N/R	Methyl-prednisolone 30 mg for 2 weeks, follow by 15 mg for 6 weeks	N/R	-	-	-	28
5/5 (100%)	5	N/R	Methyl-prednisolone 10 mg/kg for 5–10 weeks	N/R	-*	-*	-	20

Reference numbers in the table correspond to the references at the end of the manuscript. N/R, not recorded.

* DiffQuik-stained.

Table 2. Clinical and necropsy data from PCP PCR-positive cats presented for necropsy examination. DSH = domestic short-haired cat; M = male; F = female; MN = male neutered; FN = female neutered; Young animals (age ≤ 1 year); Adult (age > 1 year); BCS – body condition score; n/a = not available; nd = not done. –ve = negative; +ve = positive.

No.	Lifestyle	Origin (Province)	Breed	Age*	Sex	BCS	Lung - Macroscopic	Lung - Histology (H&E)	Corona-virus (qPCR)	FPV (IHM)	FeLV	FIV	Presumptive cause of death	<i>Pneumocystis</i> lineage
1	Family	Padua	Maine Coon	Young	F	Good	Inflamed areas with pulmonary consolidation in both lungs. Fibrin exudation. Presence of foam and whitish material in bronchi.	Focal granulomatous pneumonia with fibrinous exudation, abundant bacterial and congestive pneumonia. Rare fibrin thrombus in blood vessels.	nd	+ve	nd	nd	Gastro-enteritis	Lineage 1
2	Family	Padua	Scottish Fold	Young	M	Poor	Oedema and pulmonary congestion at apical lobes	Atelectasis. Emphysema and alveolar oedema.	+ve	-ve	nd	nd	Peritonitis	Lineage 1
3	Street	Padua	Italian DLH	Young	F	Good	Congestion of parenchyma.	Congestion of parenchyma. Alveolar oedema foci.	-ve	-ve	nd	nd	Catarrhal enteritis	Lineage 1
4	Street	Padua	Italian DSH	Young	M	Poor	Lung collapsed. Fibrino-purulent bronchopneumonia	Fibrino-purulent necrotic bacterial pneumonia	nd	+ve	nd	nd	Pneumonia	Lineage 1
5	Street	Padua	Italian DSH	Young	M	Good	Pulmonary congestion	nd	nd	nd	nd	nd	Catarrhal enteritis	Lineage 1
6	Street	Padua	Italian DSH	Young	M	Poor	Absence of lung alterations	nd	+ve	+ve	nd	nd	Catarrhal-haemorrhagic enteritis	Lineage 1
7	Street	Padua	Italian DSH	Young	M	Poor	Not reported	Autolysis. Presence of numerous bacteria.	-ve	+ve	nd	nd	Catarrhal haemorrhagic gastritis and enteritis	Lineage 1
8	Street	Padua	Italian DSH	Young	M	Poor	Congestion of parenchyma. Atelectasis apical lobe	Pyogranulomatous pneumonia.	nd	nd	nd	nd	Pneumonia	Lineage 1
9	Family	Rovigo	Italian DSH	Young	M	Good	Pneumonia and emphysema	Lymphocytic Interstitial pneumonia and fibrinopurulent thrombo-embolic dissemination.	-ve	nd	nd	nd	Pneumonia	Lineage 1
10	Street	Padua	Italian DSH	Young	F	Good	Abdominal haemorrhage and hemoperitoneum	nd	nd	nd	nd	nd	Vehicle trauma	Lineage 1

Table 2. (Continued).

No.	Lifestyle	Origin (Province)	Breed	Age*	Sex	BCS	Lung - Macroscopic	Lung - Histology (H&E)	Corona-virus (qPCR)	FPV (IHM)	FcLV	FIV	Presumptive cause of death	<i>Pneumocystis</i> lineage
11	Family	Palermo	Italian DSH	Young	F	Good	Bilateral pleural effusion	Alveolar atelectasis, presence of bacteria in the alveoli.	+ve	-ve	-ve	-ve	Necrotic enteritis	Lineage 1
12	n/a	n/a	n/a	Young	F	Good	Presence of coagulated blood in trachea. Haemorrhagic areas.	nd	nd	nd	nd	nd	Vehicular trauma	Lineage 1
13	Street	Padua	Italian DSH	Adult	MN	Good	Pulmonary congestion	nd	nd	nd	nd	nd	Hepatic adenocarcinoma	Lineage 1
14	Family	Venice	Italian DSH	Adult	MN	Good	Not reported	Alveolar oedema.	nd	nd	-ve	-ve	Hepatitis and catarrhal haemorrhagic enteritis	Lineage 1
15	Street	Rovigo	Italian DSH	Adult	F	Poor	Not reported	nd	nd	nd	nd	nd	Vehicular trauma	Lineage 1
16	Street	Venice	Italian DSH	Adult	F	Good	Pulmonary congestion and oedema	Oedema and alveolar congestion.	-ve	-ve	nd	nd	Necrotic superficial enteritis.	Lineage 1
17	Street	Venice	Italian DSH	Adult	F	Poor	Pulmonary congestion and oedema	nd	nd	+ve	nd	nd	Chronic nephritis.	Lineage 1
18	Street	Padua	Italian DLH	Adult	F	Good	Congestion of parenchyma.	Alveolar oedema.	nd	nd	nd	nd	Vehicular trauma	Lineage 1
19	Family	Padua	Italian DSH	Adult	M	Good	Pulmonary congestion and haemorrhage at apical lobes	Diffuse haemorrhage.	nd	nd	nd	nd	Vehicular trauma	Lineage 1
20	Street	Padua	Italian DSH	Young	F	Good	Pleural and pericardial serum-hematic effusion; pulmonary congestion.	nd	-ve	-ve	nd	nd	Enteritis	Lineage 2
21	Street	Venice	Italian DSH	Young	M	n/a	Pulmonary congestion	Lymphocytic interstitial pneumonia.	+ve	-ve	nd	nd	Vehicular trauma	Lineage 2
22	Street	Padua	Italian DSH	Adult	M	Poor	Pulmonary congestion	Partial destruction of the parenchyma consisting of interstitial infiltration of round cells of lymphoid origin.	-ve	nd	+ve	-ve	Lymphoma	Lineage 2
23	Family	Rovigo	Italian DSH	Adult	MN	Good	Pulmonary consolidation	Low preservation of cells due to freezing storage.	nd	nd	nd	nd	Enteritis	Lineage 2
24	Street	Venice	Italian DSH	Adult	FN	n/a	Absence of lung alterations	nd	-ve	+ve	-ve	-ve	Haemorrhagic gastritis and catarrhal enteritis	Lineage 2

BAL fluid specimens

BAL fluid (1 ml) was transferred to a 2 ml microcentrifuge tube containing 1 tungsten bead (5 mm diameter). A bead-beating step was applied for 1 min at 30 Hz to maximize DNA yield.

DNA extraction

For both lung tissue and BAL fluid, DNA extraction was performed using the DNeasy Blood & Tissue kit (Qiagen, Courtaboeuf, France) following the manufacturer's instructions, with minor modifications. Each homogenized sample (150 μ l of homogenized lung tissue and 100 μ l of BAL fluid) was transferred into a 1.5 ml tube with 200 μ l buffer (ATL lysis buffer) and 20 μ l proteinase K and incubated overnight at 56°C. DNA was eluted in 100 μ l of elution buffer. A negative control (sterile water) was systematically included in each series of DNA extractions.

PCR amplification protocols

Lung tissues and BAL fluid specimens were investigated for *Pneumocystis* DNA by using:

(i) mtSSU rRNA nested-PCR

A 320–340 bp fragment of the mtSSU rRNA gene was amplified by nested PCR with two primer pairs (Paz 112-10F and Paz 112-10R as external primers; Paz 112-13 and Paz112-14 as internal primers) and PCR conditions as reported previously.²¹

(i) mtLSU rRNA real-time PCR

The nested mtLSU rRNA PCR protocol reported previously²¹ did not amplify *Pneumocystis* DNA from any feline lung specimens (including mtSSU rRNA *Pneumocystis* PCR-positive cats). Accordingly, a new set of primers (PneumoLSU 74–94 FOR 5'-AGGATATAGCTGGTTTTCTGC-3' and PneumoLSU 325-308 REV 5'-TRTTCTGGGCTGTTYCCC-3') was designed, targeting a short segment (210–230 bp) of the mtLSU rRNA gene. This region is included between the internal primers of the nested mtLSU rRNA PCR (pAZ102-X 5'-GTGAAATACAAATCGGACTAGG-3' and pAZ102-Y 5'-TCACTTAATATTAATTGGGGAGC-3'²² (Fig. 1). Primers were designed manually, according to general primer design rules,²³ based on a sequence alignment of reference sequences from different *Pneumocystis* spp. available from the NCBI database (<http://www.ncbi.nlm.nih.gov>). The sequence specificity of the primers used was confirmed in a BLASTn search²⁴ against GenBank.

Negative and positive "*Pneumocystis carinii* DNA" controls were included in each PCR experiment, to monitor for possible contamination and determine the correctness of the amplification. Part of the *Felis catus interphotoreceptor retinoid-binding protein* (IRBP) gene was amplified as an internal control to monitor for DNA-inhibition.²⁵ Samples were considered as positive for *Pneumocystis* presence when a PCR product of the expected size was amplified and sequenced. Nested PCR was

performed using AmpliTaq Gold DNA Polymerase (Life Technologies, Foster City, CA, USA) on the Veriti Thermal Cycler (Life Technologies). Real-time PCR (qPCR) was performed using the StepOnePlus™ Real-time PCR Systems (Applied Biosystems, Foster City, CA, USA).

Sequencing and phylogenetic analysis

Sequencing reactions were performed from both ends, as reported previously.²⁶ The sequence alignment was performed using the ClustalW algorithm, integrated in MEGA 6.1,²⁷ which was then refined manually. Molecular phylogeny was performed using the Maximum likelihood (ML) approach on the mtLSU rRNA and mtSSU rRNA data sets. Hasegawa-Kishino-Yano or Tamura 3 parameter and G distribution were determined as best model in MEGA 6.1. We also added to our dataset, *Pneumocystis* sequences isolated from dogs, pigs, non-human primates, humans and rodents available from GenBank. Sequences of *P. wakefieldiae*, *P. carinii*, and *P. murina* isolated from rodents were used as an outgroup. Accession numbers of the *Pneumocystis* sequences used, including sequences produced in the study, are presented in Table 3.

Histology and cytology

Lung tissue specimens (a small portion of cranial right lung lobe) were obtained from unfrozen feline carcasses presented to our institute. After fixation in neutral buffered formalin, paraffin embedding and routine sectioning at 4 μ m, selected tissue sections were stained with hematoxylin and eosin (H&E), according to clinical suspicions. Additional histological preparations, stained with Grocott-Gomori's methenamine silver stain (GMS) and Toluidine Blue, were performed from lungs of 15 cats confirmed as being *Pneumocystis* DNA-positive by molecular investigations. Cytology of cytocentrifuged BAL specimens were prepared and stained using Diff-Quik® at the Clinica Veterinaria San Marco, a specialist centre where cats were admitted for veterinary investigation and treatment.

Statistical analysis

Epidemiologic data pertaining to cats (age, breed, sex, neuter status, provenance) and other data collected concerning their health status (nutritional history, lung alterations, presence of parasites or other infectious diseases, causes of death) were tested for statistical association with *Pneumocystis* prevalence using the Chi-square test or Fisher's exact test, as appropriate (software SPSS for Windows, version 13.0).

Results

PCR data

Pneumocystis DNA was amplified only from the lung tissue specimens. All feline BAL fluid specimens tested negative for *Pneumocystis* DNA. Overall, *Pneumocystis* DNA was detected

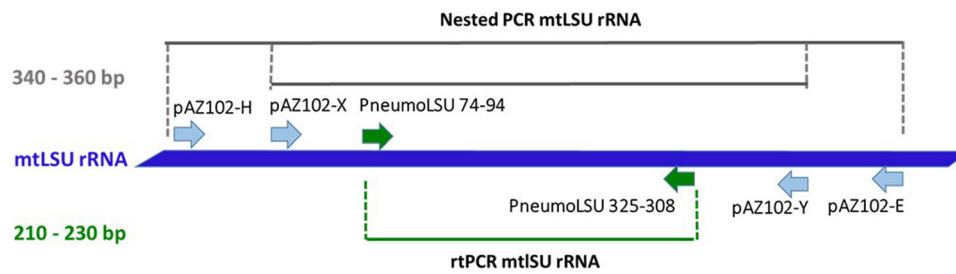


Figure 1. Schematic diagram indicating qPCR protocol and primers designed for the mtLSU rRNA fragment. The names of the new forward and reverse primers are provided in green (arrows). On the left, length of amplification products (bp) is provided. This Figure is reproduced in color in the online version of *Medical Mycology*.

Table 3. GenBank accessions of *Pneumocystis* used for phylogeny.

Host species	<i>Pneumocystis</i> species	mtLSU rRNA	mtSSU rRNA
<i>Canis lupus familiaris</i> (dog)	<i>Pneumocystis</i> sp.	KU985306	KU986906
<i>Felis catus</i> (cat)	<i>Pneumocystis</i> sp. (L1)	MH818398	MH818401
	<i>Pneumocystis</i> sp. (L1)	MH818399	MH818402
	<i>Pneumocystis</i> sp. (L2)	MH818400	MH818403
<i>Homo sapiens</i> (man)	<i>Pneumocystis jirovecii</i>	KX017566	HQ228547
<i>Indian Macaca rhesus</i> (Rhesus monkey)	<i>Pneumocystis</i> sp.	AF461784	AF395573
<i>Mus musculus</i> (house mouse)	<i>Pneumocystis murina</i>	–	AB626627
<i>Mustela putorius furo</i> (ferret)	<i>Pneumocystis</i> sp.	S42921	–
<i>Rattus norvegicus</i> (brown rat)	<i>Pneumocystis wakefieldiae</i>	FJ475121	–
	<i>Pneumocystis carinii</i>	M58604	–
	<i>Pneumocystis</i> sp.	JN887823	KC454437

Dash (–), sequence not available; mtLSU rRNA, mtSSU rRNA, mitochondrial large and small subunit of ribosomal RNA, respectively. Sequences produced in the current study are reported in boldface.

in 24/84 (29%) of fresh feline lung specimens using both the mtSSU rRNA nested PCR and the mtLSU rRNA real-time PCR (qPCR).

Among the 24 PCR-positive cats, 14 were young, and 16 cases were from cats living in “cat colonies.” Domestic short haired cats comprised 22 of these cats, with a single Main Coon and a single Scottish Fold. Statistically, no feline characteristics were associated with occurrence of *Pneumocystis*, except for age, that is, cats younger than 1 year showed higher PCP prevalence (54%) compared to older individuals (13%) (Pearson χ^2 15.2; $P < .0001$). There was no statistical association between *Pneumocystis* DNA presence (colonization) and sex, neuter status, plane of nutrition/body condition score, or lifestyle (family vs street cats).

The causes for death or euthanasia in this group was enteritis (11 cats), vehicular trauma (6 cats), feline infectious peritonitis (1 cat), pneumonia (3 cats), cancer (2 cats), and nephritis (1 cat). A total of 6/12 cats tested were infected by feline panleukopenia virus, while 4/11 tested were feline enteric Coronavirus-positive. Of the 24 PCP-positive cats, only four cats were tested for retroviruses (i.e., FIV and FeLV). Of these 4 cats, there was one FeLV-positive individual (no. 22; Table 2).

Pulmonary coinfection with bacteria was detected in 9/24 cats, the isolates consisting of a *Corynebacterium* spp. and *Enterobacter* spp. (1 cat), *Staphylococcus* spp. (3 cats), *Escherichia coli* and *Enterococcus* (2 cats), *Enterococcus* alone (1 cat), *Streptococcus canis* (1 cat), and polymicrobial (1 cat). Three of 24 PCP-positive cats were coinfecting by intestinal helminths; two cats were coinfecting with *Taenia taeniaeformis* and *Toxocara cati*, whereas ascarids alone were identified in a single cat.

At necropsy, lungs for the 24 PCP PCR-positive cats were described as having no gross alterations (2 cats), congestion (13 cats), fibrinopurulent bronchopneumonia (1 cat), pulmonary consolidation (1 cat), fibrin exudation and presence of foam and whitish material in bronchial lumen (1 cat), and pneumonia and emphysema (1 cat). Pleural effusion was reported in two cats with severe enteritis (no. 20 and no. 11; Table 2), and data was unavailable for 3 cats. Abdominal and thoracic hemorrhage were evident in cats that died following vehicular trauma.

Lung histology

Lung histology largely reflected the cause of death for cats recruited opportunistically for this study. H&E- stained sections

were available for 15 of 24 cats PCR-positive for *Pneumocystis*. Of the younger cats ($n = 9$), two cats had granulomatous pneumonia with fibrinous exudation and abundant bacterial (no. 1, no. 8; Table 2), two had pulmonary congestion and alveolar edema (no. 2, no. 3; Table 2), one had fibrinopurulent necrotizing bacterial pneumonia (no. 4; Table 2), and two cats had lymphocytic interstitial pneumonia (no. 9, no. 21; Table 2). Atelectasis and autolysis with presence of numerous bacteria was described in two cats (no. 7, no. 11; Table 2).

Of the six adult cats, one had diffuse hemorrhage following vehicular trauma (no. 19; Table 2), another was uninterpretable due to freezing artifact (no. 23; Table 2), and three cats had alveolar edema (no. 14, no. 16, no. 18; Table 2). Histology of the cat (no. 22; Table 2) with lymphoma showed partial invasion of the parenchyma consisting of interstitial infiltration with round neoplastic lymphoid cells.

Critically, none of the cats had microscopic changes consistent with PCP pneumonia, although only representative sections of lung were examined. Additional Gomori methenamine silver (GMS) and Toluidine Blue stained preparations were performed from blocks of lung tissues PCR-positive for *Pneumocystis* DNA, but there was no evidence for asci (cysts) or trophic forms (trophozoites) in any of the lung specimens examined from these seven cats.

Molecular biology and phylogeny

The presence of *Pneumocystis* DNA was determined using two different mitochondrial genome targets, mtSSU rRNA amplified using nested PCR and mtLSU rRNA amplified by Sybr Green qPCR. Alignments discriminated two separate lineages (or sequence types [ST]) in the mtSSU rRNA *Pneumocystis* sequences and two lineages in the mtLSU rRNA sequences. This distinction between ST was consistent irrespective of which PCR protocol was adopted, for all 24 cats in which results for both PCR assays were available for comparison.

For the mtSSU rRNA gene, lineage 1 (SSU-L1) consisted of a 345 bp amplicon, which was identical in all instances (19 cats) with respect to sequence length, nucleotide composition, and position. Lineage 2 (SSU-L2) consisted of a 281 bp amplicon, identical in all instances (five cats) in terms of nucleotide composition and position. Comparison of the two lineages based on the mtSSU rRNA gene (SSU-L1 and SSU-L2) estimated a sequence divergence of 0.314.²⁷

For the mtLSU rRNA gene, lineage 1 (LSU-L1) consisted of an identical sequence of 207 bp from 19 cats. Lineage 2 (LSU-L2) consisted of an identical 201 bp amplicon from the five remaining cats. Comparison of LSU-L1 and LSU-L2 estimated a sequence divergence of 0.398.²⁷

Lineage 1 was identified in the same 19 cats for both mtSSU rRNA and mtLSU rRNA gene targets, while lineage 2 was identified in the same five cats, and again, for both gene targets. Thus,

only a single lineage (lineage 1 or lineage 2) was identified in any given cat.

Two rooted trees were constructed using mtSSU rRNA and mtLSU rRNA sequences (Fig. 2, 3). In the mtSSU rRNA tree, lineages SSU-L1 and SSU-L2 grouped into separate clades of *Pneumocystis*, from the Artyodactyla (SSU-L1) and the Carnivora (SSU-L2). The SSU-L1 lineage clustered in the same group as *Pneumocystis* isolated from pigs, whereas SSU-L2 clustered with *Pneumocystis* from dogs (Fig. 2). In the mtLSU rRNA tree, the ST LSU-L1 grouped in the clades isolated from the Artyodactyla, while LSU-L2 was grouped with the Carnivora clade, showing greater similarity to dog *Pneumocystis* than ferret *Pneumocystis* (Fig. 3). In both mtSSU rRNA and mtLSU rRNA dendrograms, Carnivora and Artyodactyla were paraphyletic and well separated from primate and rodent clades, used as outgroups. The backbone showed good support for the deepest nodes, but terminal clades were resolved at bootstrap values of $\geq 90\%$.

Discussion

The molecular findings of this study support earlier cytological and histological observations suggesting that cats can harbor *Pneumocystis* in their lower respiratory tract. Our results suggest that young cats (< 1 year) are more likely to be infected by *Pneumocystis* than older cats, even though naturally occurring *Pneumocystis* pneumonia has yet to be reported in feline patients of any age. The presence of *Pneumocystis*, determined by the visualization of cysts and/or trophic forms in microscopic preparations of feline lung,^{17–19} are consistent with the present work, where *Pneumocystis* gene targets were amplified from a finite proportion of lung specimens from normal cats that died following vehicular trauma, chronic kidney disease or systemic viral illness.

Cats investigated subsequent to those early reports were drawn mostly from urban areas (comparable to the “cat colonies” in our study), with lung appearing normal on macroscopic examination, with no inflammatory changes consistent with *Pneumocystis* pneumonia evident macroscopically or microscopically despite trophic forms and cysts being present in some alveolar spaces.¹⁹ *Pneumocystis* prevalence in naturally colonized cats ranged from 0 to 13% based on conventional light or electron microscopy,^{13,17–19,28} which is in reasonable agreement with the 29% prevalence based on PCR data in our study. A higher observed prevalence using sensitive DNA detection tools is to be expected compared to cytological and histological methods. Unlike some of the original work, we were unable to find evidence of *Pneumocystis* morphotypes in histological preparations, most probably due to the poor storage of animal carcasses (freeze thaw artifact, autolysis, etc.).

The absence of *Pneumocystis* morphotypes in histological sections might also be influenced by a low absolute presence of cysts and trophic forms. *Pneumocystis* cysts are easily visualized using

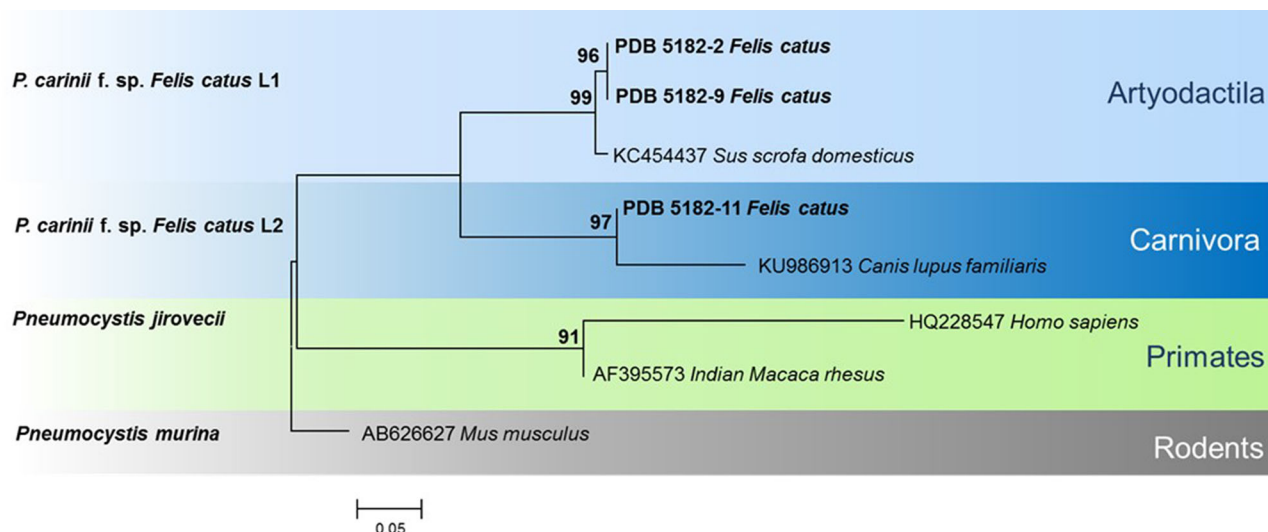


Figure 2. Phylogenetic maximum likelihood tree of *Pneumocystis* sequences of mitochondrial small subunit of ribosomal RNA (mtSSU rRNA). Tamura 3 parameter and G distribution was determined to be the best model. *Pneumocystis murina* is used as an outgroup. Bootstrap values (>90) are shown at the internal nodes. This Figure is reproduced in color in the online version of *Medical Mycology*.

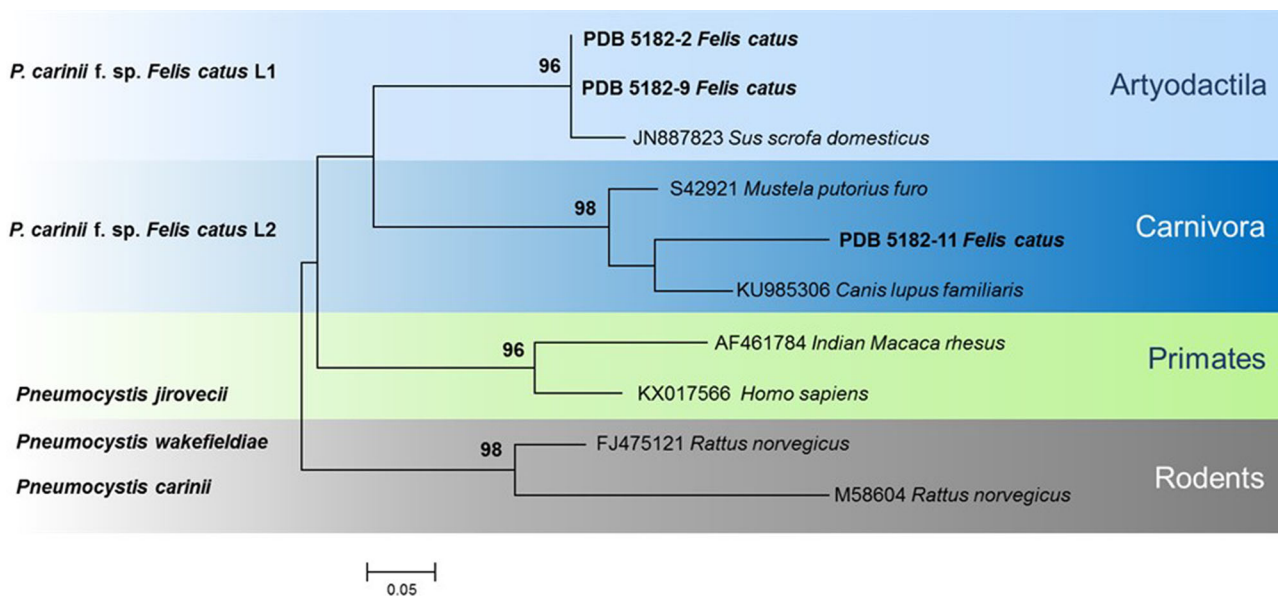


Figure 3. Phylogenetic maximum likelihood tree of *Pneumocystis* sequences of mitochondrial large subunit of ribosomal RNA (mtLSU rRNA). Hasegawa-Kishino-Yano and G distribution was determined as best model. *Pneumocystis wakefieldiae* and *P. carinii* are used as outgroups. Bootstrap values (>90) are shown at the internal nodes. This Figure is reproduced in color in the online version of *Medical Mycology*.

GMS, but trophozoites remain unstained with silver impregnation methods. Thus, trophozoites are difficult or impossible to visualize in histological sections from modestly colonized lung, unless *in situ* hybridization (ISH) is used, as has been recently described for pig lungs.²⁹

In histology preparations of *Pneumocystis* PCR-positive cats, we also did not detect lung damage referable to *Pneumocystis* infection. The same observations have been made in human autopsy studies, in which *Pneumocystis jirovecii* can

be detected without observation of obvious pulmonary lesions in immunocompetent infants.^{2,30} This might be a reflection of our study representing a single time-point analysis, whereas a sequential analysis using detailed microscopic morphometry to follow the course of *Pneumocystis* infection, including younger kittens during the primary stage of infection, would permit detection of *Pneumocystis*-associated pathology. Indeed, a recent rodent model study documented that subclinical primary *Pneumocystis* infection can induce progressive pathologic

changes characteristic of airway disease in immunocompetent hosts, such as increased mucus production and thickening of the airway epithelium.³¹

To the best of our knowledge, this is the first molecular genetic investigation that describes *Pneumocystis* in cats or other felids using sequence-based PCR methodology. In 1999, Cho and colleagues²⁰ established that there were at least three distinct karyotype groups of *Pneumocystis* among mammals in Korea. Furthermore, it was shown that chromosomal band size for cat isolates resembled dog isolates but were larger than rat isolates (730 bp for cat/dog vs 300–700 bp for rat). The chromosomal band in cats and dogs was therefore the first band of *Pneumocystis* over 700 bp to be described.²⁰

Finding two distinct *Pneumocystis* lineages in cats is consistent with the heterogeneity seen in other animal species, where co-infection with different *Pneumocystis* ST (or species) in each mammalian host is well described, especially in rodents.³² Only one ST lineage was found in any given cat. The two novel *Pneumocystis* lineages represented by our phylogenetic trees do not correspond to known *Pneumocystis* species or ST. In terms of genetic relatedness, *Pneumocystis* from rodents remain distantly related, while the two new feline *Pneumocystis* lineages appear to be closer to those of the Artiodactyla (even-toed ungulates) and Carnivora groups, respectively.

In phylogenetic studies of mammals, the Rodentia order is often suggested to be an outgroup, compared with lagomorph (rabbit), primate, artiodactyl and carnivore orders.³³ We cannot exclude that additional *Pneumocystis* lineages might eventually be characterized from feline lung. One difficulty in studying this organism is the poor availability of *Pneumocystis* sequences in well-curated public databases for use in phylogenetic analyses. For example, no *Pneumocystis* sequences from cats or other Felidae were present in Genbank. It would be of great interest to extend the present work to pulmonary tissue specimens from domestic cats to the rest of the Felidae, perhaps using archived formalin-fixed paraffin embedded tissues from lions, tigers, cheetahs, and so forth, as such animals living in zoological collections are typically subjected to terminal necropsy after death or euthanasia.

In addition, whole genome sequencing studies on *Pneumocystis* from different mammalian species, facilitated by the description of *Pneumocystis* metabolic pathways by Ma et al. (2016),⁶ would help provide additional insights into key differences between *Pneumocystis* isolated from disparate mammalian species. This might provide insights into why species specificity is such a pronounced feature of this genus.

We cannot exclude that one of the lineages found in cats (lineage 1 or 2) are not exclusively feline-associated, but shared among several host species (i.e., weaker host specificity), as has been described for wild rodents.^{26,32} In nature, this proposition is teleologically unattractive, as cats for most of their evolutionary history experience a mostly solitary life, functioning as

territorial predators. Thus, the natural route for transmission of *Pneumocystis* is most likely queen (mother) to kitten, and this would impact on the evolution of *Pneumocystis* in cats. On the other hand, it seems plausible that *Pneumocystis* from rodents (rats and mice), the natural prey of cats, might “cross over” during predation, although our data and the generally accepted species specificity of *Pneumocystis* argue against such a proposition. This is of course quite different from the situation when cats live in domesticated or semidomesticated life situations in close association with human society, where cat-to-cat transmission within households, or in areas where cats congregate outside (e.g., rubbish tips, cat shelters, and free-roaming colonies) is also possible.

In mammals, most *Pneumocystis* infections seem to consist of benign colonization, perhaps occasionally extending to sub-clinical disease as a co-pathogen to bacterial or viral primary respiratory pathogens. This type of scenario occurs for example in rats, where Sendai virus, sialodacryoadenitis virus, and pneumonia virus of rats potentially act in concert with mycoplasmas or *Pneumocystis* spp. to cause disease.^{34,35} Symptomatic PCP has been shown to occur in cats under artificial experimental conditions, usually using enormous doses of corticosteroids given repeatedly to suppress immune responses. However, clinical PCP, analogous to what is described for man, dog and horse,^{19,36,37} is yet to be described for any cat despite widespread use of immunosuppressive drug regimens (corticosteroids, chlorambucil, cyclosporine), renal transplantation, and comorbid viral infections such as pox, FeLV, FIV, FIP *Felis catus* gamma herpesvirus 1. Our failure to detect any PCP PCR-positive BAL fluid specimens from cats with a wide range of lower respiratory conditions suggests *Pneumocystis* is not likely to be an important player in infectious diseases of the airways and lung parenchyma of cats.

In humans, the occurrence of clinical PCP with fulminant multiplication of the agent is clearly linked with immunosuppression (e.g., long-standing HIV infection with CD4-cytopenia); however, this association is less evident in various animal species.^{28,38} In the dog and horse, clinical PCP is generally seen in young animals and related to inherited immunodeficiency states, for example, combined immunodeficiency in Arabian horses³⁷ and PCP in Cavalier King Charles Spaniels and miniature dachshunds, and their hybrids.^{21,36,39,40}

Rare spontaneous cases of *Pneumocystis* pneumonia (PCP) in pigs (adult and piglets) are mostly linked with immunosuppression from adverse environmental conditions (stressful farming conditions, overcrowding, high ambient ammonia concentrations, perhaps complicated by suboptimal nutrition) and/or genetic predispositions.^{41–43} In pigs, *Pneumocystis* is generally eliminated from the lungs or constrained to small quiescent foci unless such immunosuppressive conditions are present.^{43,44}

The concurrent presence of other opportunistic pathogens such as *Bordetella bronchiseptica* in the airways and demodicosis in the skin of dogs,⁴⁰ and porcine circovirus type

2 (PCV-2) and *Mycoplasma hyopneumoniae* in pigs²⁹ with *Pneumocystis* has been well established. The same is true also for macerobats, where, for example, *Histoplasma capsulatum* co-exists with *Pneumocystis* spp. in many individuals.⁴⁵ In contrast, in pigs there seems to be a general tendency that concurrent viral and bacterial infections are less frequently observed in *Pneumocystis*-positive cases than in *Pneumocystis*-negative individuals.²⁹ A negative association between the presence of *P. jirovecii* and bacterial colonization was also shown in patients with idiopathic interstitial pneumonia.⁴⁶ Thus, which factor(s) trigger multiplication of trophic forms and whether a simple infection with *Pneumocystis* (without the presence of other infectious agents) can induce lung injury and dysfunction appears to be unique in different host-environment-pathogen systems.

In the 1980s, cats affected by FeLV, an oncogenic feline retrovirus capable of causing severe acquired immunodeficiency, were studied as a potential animal model for the development of opportunistic infection in AIDS patients. In one study of FeLV-infected cats, acute bronchopneumonia, leukemic infiltrates, interstitial pneumonitis, and adenomatosis were all observed¹³ (Table 1), but despite a concerted search, there was no microscopic evidence for *Pneumocystis* infection. These findings suggested that *Pneumocystis* is not commonly a complication of FeLV infection, nor a cause of lethal interstitial pneumonia in cats¹³ (Table 1). Along similar lines, FIV is a very well-studied lentivirus of cats, and despite great scrutiny in both experimental and naturally occurring settings, no association has ever been made between development of PCP and long-standing FIV infection in cats with greatly reduced numbers of circulating CD4 cells.¹⁴

Results of the present study support the notion that cats can be asymptotically infected by *Pneumocystis* spp. Such cats are likely to be colonized or subclinically infected but *not* in association with substantial tissue destruction or injury, and thus with no discernible lung dysfunction.⁴⁷ None of the cats investigated in the current study were thought to have pathological pulmonary changes referable to pneumocystosis. As in humans, young cats seem more likely to be *Pneumocystis*-positive, but no other factors (sex, lifestyle, cause of death, etc.) in this study were associated with colonized cats. In experimental animal model studies, cats have been shown to be less susceptible to *Pneumocystis* infection when compared with rodents²⁸ (Table 1). Indeed, corticosteroid treated cats generally developed only a mild *Pneumocystis* infection, in marked contradistinction with the heavy symptomatic PCP that developed in corticosteroid treated rats,²⁸ suggesting that cats are less susceptible to *Pneumocystis* disease than other mammals. Without evidence of *Pneumocystis* in a specimen (BAL or lung biopsy) from a cat with respiratory distress and radiological findings consistent with PCP, we cannot confirm or deny any role for *Pneumocystis* in the pathogenesis of feline lung disease. In addition, modern metagenomics tools open the possibility to hypothesize that the presence/absence of

Pneumocystis might be affected not only by the microbiota of lungs, but also of intestinal microbial community interfering in metabolic pathways,^{46,48,49} a field of research yet to be well explored in veterinary patients.

Supplementary material

Supplementary data are available at [MMYCOL](https://www.mycologyonline.com) online.

Acknowledgments

We thank Giorgia Monetti and Erika Melchiotti for technical support. The work was partially supported by the Italian Ministry of Health (project RC IZSVe 01/2015). R.M. is supported by the Valentine Charlton Bequest of the Centre of Veterinary Education at the University of Sydney.

Declaration of interest

The authors report no conflicts of interest. The authors alone are responsible for the content and the writing of the paper.

References

1. Aliouat-Denis CM, Chabé M, Demanche C et al. *Pneumocystis* species, co-evolution and pathogenic power. *Infect Genet Evol.* 2008; 8: 708–726.
2. Vargas SL, Hughes WT, Santolaya ME et al. Search for primary infection by *Pneumocystis carinii* in a cohort of normal, healthy infants. *Clin Infect Dis.* 2001; 32: 855–861.
3. Rojas P, Friaiza V, García E et al. Early acquisition of *Pneumocystis jirovecii* colonization and potential association with respiratory distress syndrome in preterm newborn infants. *Clin Infect Dis.* 2017; 65: 976–981.
4. Alanio A, Bretagne S. *Pneumocystis jirovecii* detection in asymptomatic patients: what does its natural history tell us? *F1000Research.* 2017; 6: 739.
5. Morris A, Norris KA. Colonization by *Pneumocystis jirovecii* and its role in disease. *Clin Microbiol Rev.* 2012; 25: 297–317.
6. Ma L, Chen Z, Huang DW et al. Genome analysis of three *Pneumocystis* species reveals adaptation mechanisms to life exclusively in mammalian hosts. *Nat Commun.* 2016; 7: 10740.
7. Ma L, Cissé OH, Kovacs JA. A molecular window into the biology and epidemiology of pneumocystis spp. *Clin Microbiol Rev.* 2018; 31: e00009–18.
8. Chabé M, Dei-Cas E, Creusy C et al. Immunocompetent hosts as a reservoir of *Pneumocystis* organisms: histological and rt-PCR data demonstrate active replication. *Eur J Clin Microbiol Infect Dis.* 2004; 23: 89–97.
9. Demanche C, Berthelemy M, Petit T et al. Phylogeny of *Pneumocystis carinii* from 18 primate species confirms host specificity and suggests coevolution. *J Clin Microbiol.* 2001; 39: 2126–2133.
10. Limper AH, Adenis A, Le T, Harrison TS. Fungal infections in HIV/AIDS. *Lancet Infect Dis.* 2017; 17: e334–e343.
11. Phipps LM, Chen SC-A, Kable K et al. Nosocomial *Pneumocystis jirovecii* pneumonia: lessons from a cluster in kidney transplant recipients. *Transplantation.* 2011; 92: 1327–1334.
12. Chapman JR, Marriott DJ, Chen SC-A, MacDonald PS. Post-transplant *Pneumocystis jirovecii* pneumonia a re-emerged public health problem? *Kidney Int.* 2013; 84: 240–243.
13. Hagler DN, Kim CK, Walzer PD. Feline leukemia virus and *Pneumocystis carinii* infection. *J Parasitol.* 1987; 73: 1284–1286.
14. Miller C, Abdo Z, Ericsson A, Elder J, VandeWoude S. Applications of the FIV model to study HIV pathogenesis. *Viruses.* 2018; 10: E206.
15. Kadar E, Sykes JE, Kass PH, Bernstein L, Gregory CR, Kyles AE. Evaluation of the prevalence of infections in cats after renal transplantation: 169 cases (1987–2003). *J Am Vet Med Assoc.* 2005; 227: 948–953.
16. Shiota T, Shimada Y, Kurimoto H, Oikawa H. *Pneumocystis carinii* infection in corticosteroid-treated cats. *J Parasitol.* 1990; 76: 441–445.

17. Davalos Mata A. Latent infection produced by *Pneumocystis carinii* in domestic animals in Mexico. *Salud Publica Mex.* 1963; 5: 975–977.
18. Zavala J, Rosado R. *Pneumocystis carinii* in domestic animals of the city of Mexico, Yucatan. *Salud Publica Mex.* 1972; 14: 103–106.
19. Settnes OP, Hasselager E. Occurrence of *Pneumocystis carinii* Delanoë & Delanoë, 1912 in dogs and cats in Denmark. *Nord Vet Med.* 1984; 36: 179–181.
20. Cho SR, Park YG, Moon HN, Lee SH, Hong ST. Karyotypes of *Pneumocystis carinii* derived from several mammals. *Korean J Parasitol.* 1999; 37: 271–275.
21. Danesi P, Ravagnan S, Johnson LR et al. Molecular diagnosis of *Pneumocystis pneumonia* in dogs. *Med Mycol.* 2017; 55: 828–842.
22. Wakefield AE. DNA sequences identical to *Pneumocystis carinii* f. sp. *carinii* and *Pneumocystis carinii* f. sp. *hominis* in samples of air spora. *J Clin Microbiol.* 1996; 34: 1754–1759.
23. Dieffenbach CW, Lowe TM, Dveksler GS. General concepts for PCR primer design. *PCR Methods Appl.* 1993; 3: S30–S37.
24. Madden TL, Tatusov RL, Zhang J. Applications of network BLAST server. *Methods Enzymol.* 1996; 266: 131–141.
25. Ferreira EC, Gontijo CM, Cruz I, Melo MN, Silva AM. Alternative PCR protocol using a single primer set for assessing DNA quality in several tissues from a large variety of mammalian species living in areas endemic for leishmaniasis. *Mem Inst Oswaldo Cruz.* 2010; 105: 895–898.
26. Danesi P, da Rold G, Rizzoli A et al. Barcoding markers for *Pneumocystis* species in wildlife. *Fungal Biol.* 2016; 120: 191–206.
27. Tamura K, Stecher G, Peterson D, FilipSKI A, Kumar S. MEGA6: Molecular Evolutionary Genetics Analysis Version 6.0. *Mol Biol Evol.* 2013; 30: 2725–2729.
28. Hong ST, Park KH, Lee SH. Susceptibility of various animals to *Pneumocystis carinii* infection. *Kisaengchungbak Chapchi.* 1992; 30: 277–281.
29. Binanti D, Mostegl MM, Weissenbacher-Lang C, Nedorost N, Weissenböck H. Detection of *Pneumocystis* infections by in situ hybridization in lung samples of Austrian pigs with interstitial pneumonia. *Med Mycol.* 2014; 52: 196–201.
30. Vargas SL, Ponce CA, Hughes WT et al. Association of primary *Pneumocystis carinii* Infection and sudden infant death syndrome. *Clin Infect Dis.* 1999; 29: 1489–1493.
31. Iturra PA, Rojas DA, Pérez FJ et al. Progression of type 2 helper T Cell–type inflammation and airway remodeling in a rodent model of naturally acquired subclinical primary pneumocystis infection. *Am J Pathol.* 2018; 188: 417–431.
32. Latinne A, Bezé F, Delhaes L et al. Genetic diversity and evolution of *Pneumocystis* fungi infecting wild Southeast Asian murid rodents. *Parasitology.* 2018; 145: 885–900.
33. Li WH, Gouy M, Sharp PM, O’HUigin C, Yang YW. Molecular phylogeny of Rodentia, Lagomorpha, Primates, Artiodactyla, and Carnivora and molecular clocks. *Proc Natl Acad Sci U S A.* 1990; 87: 6703–6707.
34. Albers TM, Simon MA, Clifford CB. Histopathology of naturally transmitted “rat respiratory virus”: progression of lesions and proposed diagnostic criteria. *Vet Pathol.* 2009; 46: 992–999.
35. Easterbrook JD, Kaplan JB, Glass GE, Watson J, Klein SL. A survey of rodent-borne pathogens carried by wild-caught Norway rats: a potential threat to laboratory rodent colonies. *Lab Anim.* 2008; 42: 92–98.
36. Lobetti RG, Leisewitz AL, Spencer JA. *Pneumocystis carinii* in the miniature dachshund: case report and literature review. *J Small Anim Pract.* 1996; 37: 280–285.
37. Ainsworth DM, Weldon AD, Beck KA, Rowland PH. Recognition of *Pneumocystis carinii* in foals with respiratory distress. *Equine Vet J.* 1993; 25: 103–108.
38. Kondo H, Taguchi M, Abe N, Nogami Y, Yoshioka H, Ito M. Pathological changes in epidemic porcine *Pneumocystis carinii* pneumonia. *J Comp Pathol.* 1993; 108: 261–268.
39. Lobetti R. Common variable immunodeficiency in miniature dachshunds affected with *Pneumocystis carinii* pneumonia. *J Vet Diagn Invest.* 2000; 12: 39–45.
40. Furuta T, Nogami S, Kojima S, Fujita M, Kamata H, Kuwabara M et al. Spontaneous *Pneumocystis carinii* infection in the dog with naturally acquired generalised demodicosis. *Vet Rec.* 1994; 134: 423–424.
41. Esgalhado R, Esteves F, Antunes F, Matos O. Study of the epidemiology of *Pneumocystis carinii* f. sp. *suis* in abattoir swine in Portugal. *Med Mycol.* 2013; 51: 66–71.
42. Kureljušič B, Weissenbacher-Lang C, Nedorost N, Stixenberger D, Weissenböck H. Association between *Pneumocystis* spp. and co-infections with *Bordetella bronchiseptica*, *Mycoplasma hyopneumoniae* and *Pasteurella multocida* in Austrian pigs with pneumonia. *Vet J.* 2016; 207: 177–179.
43. Weissenbacher-Lang C, Nedorost N, Knecht C, Hennig-Pauka I, Weissenböck H. Establishment of a quantitative real-time PCR for the detection of *Pneumocystis carinii* f. sp. *suis* in bronchoalveolar lavage samples from pigs. *J Vet Diagn Invest.* 2016; 28: 257–262.
44. Weissenbacher-Lang C, Nedorost N, Knecht C et al. Comparison of *Pneumocystis* nucleic acid and antibody profiles and their associations with other respiratory pathogens in two Austrian pig herds. *PLoS One.* 2017; 12: e0185387.
45. González-González AE, Aliouat-Denis CM, Ramírez-Bárceñas JA et al. *Histoplasma capsulatum* and *Pneumocystis* spp. co-infection in wild bats from Argentina, French Guyana, and Mexico. *BMC Microbiol.* 2014; 14: 23.
46. Friaza V, de la Horra C, Rodríguez-Domínguez MJ et al. Metagenomic analysis of bronchoalveolar lavage samples from patients with idiopathic interstitial pneumonia and its antagonistic relation with *Pneumocystis jirovecii* colonization. *J Microbiol Methods.* 2010; 82: 98–101.
47. Casadevall A, Pirofski LA. Host-pathogen interactions: basic concepts of microbial commensalism, colonization, infection, and disease. *Infect Immun.* 2000; 68: 6511–6518.
48. Samuelson DR, Charles TP, De La Rua NM et al. Analysis of the intestinal microbial community and inferred functional capacities during the host response to *Pneumocystis* pneumonia. *Exp Lung Res.* 2016; 42: 425–439.
49. Kehrmann J, Veckollari B, Schmidt D et al. The lung microbiome in patients with pneumocystosis. *BMC Pulm Med.* 2017; 17: 170.