

Molecular genetics and pathophysiology of 17 beta-hydroxysteroid dehydrogenase 3 deficiency. — Source link

Stefan Andersson, Wayne M. Geissler, Ling Wu, D L Davis ...+11 more authors

Institutions: Merck & Co.

Published on: 01 Jan 1996 - The Journal of Clinical Endocrinology and Metabolism (The Endocrine Society)

Topics: Mutation, Missense mutation, Androgen, Molecular genetics and Gene mutation

Related papers:

- [Male pseudohermaphroditism caused by mutations of testicular 17 \$\beta\$ -hydroxysteroid dehydrogenase 3](#)
- [17Beta-hydroxysteroid dehydrogenase-3 deficiency: diagnosis, phenotypic variability, population genetics, and worldwide distribution of ancient and de novo mutations.](#)
- [A \(R80Q\) mutation in 17 beta-hydroxysteroid dehydrogenase type 3 gene among Arabs of Israel is associated with pseudohermaphroditism in males and normal asymptomatic females.](#)
- [Familial male pseudohermaphroditism with gynecomastia due to a testicular 17-ketosteroid reductase defect. I. Studies in vivo.](#)
- [Phenotypic variability in 17beta-hydroxysteroid dehydrogenase-3 deficiency and diagnostic pitfalls](#)

Share this paper:    

View more about this paper here: <https://typeset.io/papers/molecular-genetics-and-pathophysiology-of-17-beta-1u5fncbcmp>

Molecular Genetics and Pathophysiology of 17 β -Hydroxysteroid Dehydrogenase 3 Deficiency*

STEFAN ANDERSSON, WAYNE M. GEISSLER, LING WU, DAPHNE L. DAVIS, MELVIN M. GRUMBACH, MARIA I. NEW, HANS P. SCHWARZ, SANDRA L. BLETHEN, BERENICE B. MENDONCA, WALTER BLOISE, SELMA F. WITCHEL, GORDON B. CUTLER, JR., JAMES E. GRIFFIN, JEAN D. WILSON, AND DAVID W. RUSSELL

Department of Biochemistry, Merck Research Laboratories (S.A., W.M.G., L.W.), Rahway, New Jersey 07065; Department of Pediatrics, University of California (M.M.G.), San Francisco, California 94143; the Department of Pediatrics, New York Hospital/Cornell University Medical Center (M.I.N.), New York, New York 10021; the Department of Pediatrics, Ludwig-Maximilians-University of Munich (H.P.S.), Munich, Germany; the Department of Pediatrics, State University of New York (S.L.B.), Stony Brook, New York; the Department of Medicine, University of Sao Paulo (B.B.M., W.B.), Sao Paulo, Brazil; the Department of Pediatrics, University of Pittsburgh (S.F.W.), Pittsburgh, Pennsylvania; National Institute of Child Health and Human Development (G.B.C.), Bethesda, Maryland 20892; and the Departments of Molecular Genetics (D.L.D., D.W.R.) and Internal Medicine (J.E.G., J.D.W.), University of Texas Southwestern Medical Center, Dallas, Texas 75235

ABSTRACT

Autosomal recessive mutations in the 17 β -hydroxysteroid dehydrogenase 3 gene impair the formation of testosterone in the fetal testis and give rise to genetic males with female external genitalia. Such individuals are usually raised as females, but virilize at the time of expected puberty as the result of increases in serum testosterone. Here we describe mutations in 12 additional subjects/families with this disorder. The 14 mutations characterized to date include 10 missense mutations, 3 splice junction abnormalities, and 1 small deletion that results in a frame shift. Three of these mutations have occurred in more than 1 family. Complementary DNAs incorporating

9 of the 10 missense mutations have been constructed and expressed in reporter cells; 8 of the 9 missense mutations cause almost complete loss of enzymatic activity. In 2 subjects with loss of function, missense mutations testosterone levels in testicular venous blood were very low. Considered together, these findings strongly suggest that the common mechanism for testosterone formation in postpubertal subjects with this disorder is the conversion of circulating androstenedione to testosterone by one or more of the unaffected 17 β -hydroxysteroid dehydrogenase isoenzymes. (*J Clin Endocrinol Metab* 81: 130–136, 1996)

THE ESTABLISHMENT of the male phenotype during embryogenesis is dependent on two hormones secreted by the fetal testes. The peptide hormone Mullerian inhibiting hormone is responsible for regression of the Mullerian ducts, and the steroid hormone testosterone mediates development of the male urogenital tract and external genitalia (reviewed in Ref. 1). Disorders that disrupt the synthesis or action of testosterone impair male phenotypic development and cause the condition of human intersex termed male pseudohermaphroditism. Defects in androgen action are the most common of these disorders and include mutations in the androgen receptor gene and mutations in the steroid 5 α -reductase 2 gene, which encodes an enzyme responsible for the conversion of testosterone to dihydrotestosterone in the urogenital tract (2). Autosomal recessive mutations have also been described that impair each of the

five enzymatic reactions involved in the conversion of cholesterol to testosterone, including the side-chain cleavage reaction, 3 β -hydroxysteroid dehydrogenase (3 β HSD), 17 α -hydroxylase/17,20-lyase, and 17 β HSD (3). We identified the defect in the latter disorder as the consequence of mutations in the 17 β HSD-3 gene and described six different mutations in five unrelated affected individuals (three homozygotes and two compound heterozygotes) (4).

17 β HSD deficiency was originally described by Saez and his colleagues (5, 6); the characteristic phenotype is that of a 46,XY individual with testes and male Wolffian duct-derived urogenital structures (epididymides, vas deferentia, seminal vesicles, and ejaculatory ducts) but female external genitalia (7–9). Such individuals are usually classified as female at birth and raised as females, but at the time of expected puberty, plasma testosterone rises to levels that in some instances approximate the normal male range. As a consequence, many such individuals undergo a marked virilization during the teenage years. Two explanations have been proposed to explain the fact that the impairment of testosterone synthesis is more severe during embryogenesis than in later life, namely that testosterone can be formed in extraglandular tissues from the circulating precursor androstenedione that accumulates in the disorder (10) and that the

Received June 30, 1995. Accepted July 30, 1995.

Address all correspondence and requests for reprints to: David W. Russell, Ph.D., Department of Molecular Genetics, University of Texas Southwestern Medical Center, 5323 Harry Hines Boulevard, Dallas, Texas 75235-9046.

* This work was supported by Grants GM-43753, DK-03892, and M01-RR-01271 from the NIH and a grant from the Perot Family Foundation.

impairment of the enzyme is incomplete, so the testis can secrete some testosterone (11).

In the present study, we characterized the mutations in 12 additional individuals/families with 17βHSD-3 deficiency and studied the functional consequences of some of the mutant enzymes expressed in reporter cells. Most of these mutations cause either single amino acid substitutions or disrupt splice acceptor sites, and all but 1 of the missense mutations characterized to date impair enzyme function completely. This latter finding is in agreement with studies in 2 of the subjects, in whom we show that negligible amounts of testosterone are secreted by the testes. We conclude that circulating testosterone in most individuals with this disorder is derived from extraglandular conversion of androstenedione to testosterone by 1 or more of the unaffected 17βHSD isoenzymes.

Subjects and Methods

Subjects

Four of the subjects/families shown in Table 1 were previously reported in detail, namely 17HSD-3-Gaza (11-14), 17HSD-3-Sao Paulo 3 (15), 17HSD-3-Syria (10), and 17HSD-3-New York (16). Two others (17HSD-3-Dallas and 17HSD-3-Sao Paulo 1) have been described in capsule form (4). The remaining 11 subjects/families have not previously been reported.

17HSD-3-San Francisco 1. This girl was evaluated at University of California-San Francisco at age 15 yr. The external genitalia had been considered normal at birth, but at 7 months of age she was noted to have a mass in the right labia majora. Beginning at age 13 yr, she noted breast enlargement, deepening of the voice, and enlargement of the clitoris. The family history was uninformative, and two siblings were normal. On physical examination she had facial hirsutism, 6 × 6-cm breast tissue, a 3 × 1.5-cm clitoris, scrotalization of the labia majora, and a blind-ending vagina. The karyotype was 46,XY. Endocrine findings are summarized in Table 2. Gonadectomy was performed; the testes measured 3 × 2 cm, and by microscopic examination the seminiferous tubules contained mostly Sertoli cells and a few germ cells. DNA was prepared from tissue blocks.

17HSD-3-San Francisco 2. This girl was thought to be normal at birth, but was evaluated at age 13 yr at University of California-San Francisco because of a deepening voice, hirsutism, male musculature, and an enlarged clitoris. The family history was uninformative, and a 15-yr-old sister was normal. Breasts were Tanner stage III, and pubic hair was Tanner stage IV. The vagina was blind-ending, and masses (3.5 × 2.5 cm) were palpable in the labia majora. The karyotype was 46,XY. Plasma androgen levels are summarized in Table 2. After extensive psychiatric and social evaluation, she underwent bilateral gonadectomy and partial resection of the clitoris; spermatic venous blood was obtained at the time of surgery, and the levels of testosterone and androstenedione were compared with those previously reported in normal men (17, 18) (Table 2). The epididymides were hypoplastic. The seminiferous tubules contained Sertoli cells but no germ cells. DNA was prepared from tissue blocks.

17HSD-3-Munich. This female infant was thought to be normal until age 3 weeks, when she was found to have masses in the labia majora bilaterally; these masses were shown by biopsy to be testes. The karyotype was 46,XY. A hCG stimulation test was performed at 6 months of age; plasma testosterone rose from less than 20 to 26 ng/dL, and plasma androstenedione rose from 50 to 161 ng/dL. Bilateral gonadectomy was performed at age 8 months. DNA was prepared from peripheral blood.

17HSD-3-Stony Brook. This newborn infant with ambiguous genitalia was the product of a 35-week twin gestation; the other twin is 46,XX and has a normal female phenotype. The parents are first cousins of German descent; a 12-yr-old half-brother is normal. On physical examination the

TABLE 1. Subjects with 17β-HSD-3 deficiency

Designation	Ethnic background	Age at diagnosis (yr)/gynecomastia	Consanguinity/positive family history	Molecular lesion		Comments	Ref. no.
				Type	Location		
Class I homozygotes							
1) 17HSD3-Gaza ^c	Lebanese	Variable/?	Yes/yes	Missense	Exon 3	R80Q	Residual enzyme activity
2) 17HSD3-Sao Paulo 3	White Brazilian	4, 10/no	No/yes	Missense	Exon 3	R80Q	Residual enzyme activity
3) 17HSD3-Syria ^c	Syria	17/yes	No/no	Splice junction	Intron 8	655-1,G-A	Disrupts splice acceptor
4) 17HSD3-New York	Greek	12/?	No/yes	Splice junction	Intron 8	655-1,G-A	Disrupts splice acceptor
5) 17HSD3-San Francisco	White American	15.5/yes	No/no	Splice junction	Intron 3	325-4,A-T	Disrupts splice donor
6) 17HSD3-San Francisco 2	White American	13.5/yes	No/no	Splice junction	Intron 3	325-4,A-T	Disrupts splice donor
7) 17HSD3-Munich	German	0.5/no	No/no	Splice junction	Intron 3	325-4,A-T	Disrupts splice donor
8) 17HSD3-Stony Brook	German	16/?	Yes/no	Missense	Exon 9	F2081	Inactivates enzyme
9) 17HSD3-San Antonio	Iranian	16/?	No/no	Missense	Exon 2	S655L	Inactivates enzyme
10) 17HSD3-Bethesda	Polish	16/yes	No/no	Deletion	Exon 10	A777 through	Frame shift truncates protein
11) 17HSD3-Sao Paulo 2 ^a	African-Brazilian	13/no	No/no	Missense	Exon 9	A203V	Inactivates enzyme
12) 17HSD3-Sao Paulo 4	White Brazilian	21/no	Yes/yes	Missense	Exon 9	E215D	Inactivates enzyme
Class II compound heterozygotes							
13) 17HSD3-Dallas ^c	African-American	18/no	No/no	Missense	Exon 10	S232L	Both inactivate enzyme
14) 17HSD3-San Francisco 3	White American	12,14/no	No/yes	Splice junction	Intron 3	M235V	Disrupts splice donor
15) 17HSD3-Sao Paulo 1 ^c	White Brazilian	15/no	No/yes	Missense	Exon 11	P282L	Inactivates enzyme
16) 17HSD3-Pittsburgh	Italian German-Irish	13/yes	No/no	Splice junction	Exon 3	R80Q	Residual enzyme activity
				Splice junction	Intron 3	326-1,G-T	Disrupts splice acceptor
				Missense	Exon 8	Q176P	Disrupts splice donor
Class III heterozygote							
17) 17HSD-Indianapolis	White American	NB/-	No/no	Missense	Exon 9	V205E	Inactivates enzyme

^cSubjects in whom one or more 17β-HSD-3 mutations were previously described (4).

TABLE 2. Endocrine findings in four subjects with 17 β HSD-3 deficiency

Subject	Peripheral vein		Spermatic vein			Estimated testicular testosterone secretion (mg/day) ^a
	Testosterone (ng/dL)	Androstenedione (ng/dL)	Testosterone (ng/dL)	Androstenedione (ng/dL)	T/A	
17HSD-San Francisco 1	209	883	3,678 5,198	R 43,450 L 55,870	0.09 0.09	0.2
17HSD-San Francisco 3 (subject 2)	148	344	993 1,206	R >44,440 L >44,440	.02 .03	0.05
Normal adult male values	491–1089	85–242				
Kelch <i>et al.</i> (18)			71,200 \pm 7,900	2,230 \pm 1,360	32	4.1
Weinstein <i>et al.</i> (17)			75,100 \pm 11,400	3,070 \pm 790	24	4.3

^a Testosterone secretion (ng/d) = testicular volume (g) \times 0.1 mL plasma flow/g \cdot min \times 1442 min/day \times [T_{testicular vein plasma} - T_{peripheral vein plasma}] ng/mL.

Plasma flow approximates 0.1 mL/g \cdot min in a variety of species, including man (29). For the two 17HSD subjects, testicular volume was estimated by a testiculometer, and for the normal adult males, an average testicular volume of 20 mL was assumed.

infant had clitoromegaly (1.5 cm) and posterior fusion and scrotalization of the labia majora, which contained palpable masses bilaterally. The karyotype was 46,XY. At 9 h of life, serum testosterone was 86 ng/dL, dihydrotestosterone was 12 ng/dL, and androstenedione was 215 ng/dL. DNA was prepared from peripheral blood.

17HSD-3-San Antonio. This 16-yr-old Iranian girl was evaluated at Wilfred Hall U.S. Air Force Hospital because of hirsutism, clitoromegaly, and failure to menstruate. The karyotype was 46,XY. A diagnosis of 17 β HSD-3 deficiency was made on the basis of a male level of testosterone and an elevated level of androstenedione (exact values not available). DNA was prepared from cultured skin fibroblasts.

17HSD-3-Bethesda. This girl was thought to be normal until age 10 yr, when a testis was discovered in a right herniorrhaphy sac. Breast enlargement was noted by age 13 yr, but because of failure to menstruate she was evaluated at age 15 yr in Portland, ME, where a diagnosis of 17 β HSD-3 deficiency was made. This diagnosis was confirmed at the NIH, where she was found to have a serum testosterone level of 221 ng/dL and a serum androstenedione level of 1031 ng/dL. The parents are from Poland; a sister and two brothers are normal, and two sisters are dead. In May 1980, a bilateral gonadectomy and clitoroplasty were performed. She was subsequently treated with estrogen and medroxyprogesterone (with successful feminization) and underwent a vaginoplasty to enlarge a 5-cm blind-ending vagina. DNA was prepared from tissue blocks.

17HSD-3-Sao Paulo 2. This woman was evaluated at age 21 yr because of absent breast development and failure to menstruate. Facial hirsutism and clitoromegaly were noted by age 13 yr. The parents are first cousins, and she has two brothers with ambiguous genitalia. On physical examination, she had temporal hair regression and hirsutism of the lips, chin, areolae, and abdomen. The clitoris measured 9 \times 2 cm, and a 6-cm blind-ending vagina was present. Gonads were palpable in the inguinal canals. No breast tissue was palpable. The karyotype was 46,XY. Serum testosterone was 330 ng/dL, and androstenedione was 1010 ng/dL. Serum LH was 27 U/L, and serum FSH was 29 U/L. After psychological and psychiatric examination, bilateral orchidectomy and clitoral resection were performed. Histological examination of the testes revealed abundant Leydig cells and seminiferous tubules that contained Sertoli cells but no germ cells. She is currently receiving estrogen replacement therapy. DNA was prepared from peripheral blood.

17HSD-3-Sao Paulo 4. This subject was born with ambiguous genitalia and was registered and raised as a female until age 10 yr, at which time he began to function as a male. By age 16 yr, increased body hair, male pattern muscle development, and penile growth were prominent. At age 21 yr, psychological testing confirmed that he had a male gender identity. He is the offspring of a first cousin marriage and is one of seven siblings, including a similarly affected younger brother. Physical examination revealed a male habitus, no palpable breast tissue, and male pattern facial and chest hair. The penis measured 6.8 \times 2.5 cm with perineoscrotal hypospadias; the scrotum was bifid, and a blind-ending vagina was present. Testes (5 \times 3 cm) were palpable in the inguinal canals. Endocrine findings included serum testosterone of 285 ng/dL and serum androstenedione of 480 ng/dL; these values increased to 525

and 1800 ng/dL, respectively after hCG administration and did not change significantly after 4 days of dexamethasone administration. Serum LH was 38 U/L, and serum FSH was 64 U/L. He subsequently underwent surgical repair of the hypospadias.

17HSD-3-Dallas. This 17-yr-old girl with known hemoglobinopathy (SC disease) was evaluated because of clitoromegaly (4 cm) and failure to menstruate. The family history was uninformative. On physical examination a blind-ending vagina was present, testes were palpable in the inguinal canals bilaterally, no breast tissue was palpable, and there was no hirsutism. No uterus was identified by ultrasonography. The karyotype was 46,XY. Serum testosterone was 740 ng/dL, serum androstenedione was 880 ng/dL, and serum dihydrotestosterone averaged 35 ng/dL. Serum LH was 27 U/L, and FSH was 51 U/L. The decision was made to remove the testes. At surgery, the testes measured 3 \times 1.8 cm with separate epididymis, and vasography revealed vasa deferentia, seminal vesicles, and ejaculatory ducts that terminated in the position of Gartner's ducts adjacent to the vaginal orifice. On histological examination, Leydig cells were abundant, and the seminiferous tubules contained Sertoli cells and occasional spermatocytes, but no spermatids or spermatozoa. Shortly after surgery she died in an accident. DNA was prepared from cultured skin fibroblasts.

17HSD-3-San Francisco 3. These two sisters were the products of a non-consanguineous marriage. Subject 1 was seen at age 13 yr because of failure of breast development and deepening of the voice. No breast tissue was palpable. The clitoris measured 4.5 \times 1 cm, and 3 \times 1.4-cm masses were present in the inguinal areas. The vagina was blind-ending and shallow. The karyotype was 46,XY. Endocrine values are given in Table 2. Bilateral orchidectomy was performed; the seminiferous tubules contained Sertoli cells and rare germ cells. She was treated with conjugated estrogens and medroxyprogesterone. DNA was prepared from cultured skin fibroblasts. Subject 2 was evaluated at age 12 yr; an enlarged clitoris in an otherwise normal female infant had been noted at birth, but she was not evaluated until the sister was diagnosed. No breast tissue was palpable. The clitoris measured 4 \times 1 cm, and the blind-ending vagina was 2.5 cm in depth. Testis-like masses (4 \times 2 cm) were palpable in the inguinal regions. The karyotype was 46,XY. The endocrine findings are shown in Table 2. Bilateral orchidectomy and a clitoral resection were performed, and the testicular veins were cannulated for measurement of androstenedione and testosterone levels at the time of surgery (Table 2). The seminiferous tubules contained Sertoli cells and occasional spermatocytes, and the epididymis was histologically normal. She was treated with premarin/medroxyprogesterone, and at age 16 yr she underwent vaginal dilatation via the Frank procedure. DNA was prepared from tissue blocks.

17HSD-3-Sao Paulo 1. This 15-yr-old girl was evaluated because of the absence of breast development and failure to menstruate. The family history was uninformative, and four siblings were normal. On physical examination she had a deep voice; coarse hair over the lip, chin, and abdomen; clitoromegaly (8 \times 2 cm); a blind-ending vagina (6 cm in depth); and no palpable breast tissue. A 4 \times 2.5-cm mass was palpable in the left inguinal canal. Serum testosterone was 620 ng/dL, and serum androstenedione was 980 ng/dL; these values increased to 810 and 1810

ng/dL after hCG administration and changed very little after dexamethasone administration. LH was 29 U/L, and FSH was 30 U/L. After careful psychological testing she underwent bilateral orchidectomy (the right testis was intraabdominal) and clitoral resection. Histological examination of the testes revealed abundant Leydig cells and seminiferous tubules that contained predominately Sertoli cells. She now receives estrogen replacement. DNA was prepared from peripheral blood.

17HSD-3-Pittsburgh. This 13-yr-old girl was referred to the Children's Hospital of Pittsburgh because of clitoromegaly and coarsening of the voice. The family history was incomplete, but she has four normal brothers. Physical examination revealed no palpable breast tissue, clitoromegaly (4 × 3 cm), scrotalization of the labia majora, and bilateral masses in the inguinal regions. Karyotype was 46,XY. Serum androstenedione was 512 ng/dL, and serum testosterone was 212 ng/dL. After hCG stimulation, the androstenedione level was 817 ng/dL, and testosterone was 344 ng/dL. After LH-releasing hormone administration, the androstenedione level was 675 ng/dL, and testosterone was 377 ng/dL. After careful evaluation, the decision was made to remove the gonads and administer estrogen. The right undescended testis exhibited Leydig cell hyperplasia and seminiferous tubules lined with Sertoli cells, but no germ cells, and the left partially descended testis had tubules with germ cell hyperplasia and a maturation arrest. DNA was prepared from peripheral blood.

17HSD-3-Indianapolis. This infant was noted at birth to have perineo-scrotal hypospadias with a single orifice on the perineum and a bifid scrotum with rugated labioscrotal folds. The karyotype was 46,XY. After a hCG stimulation test at 4 months of age, the plasma testosterone level was 430 ng/dL, and the plasma dihydrotestosterone level was 12 ng/dL. Steroid 5 α -reductase activity in cultured genital skin fibroblasts was low (0.6 pmol/h-mg protein; normal range, 1–100), and the androgen receptor level was normal (20 fmol/mg protein; normal, >15). A tentative diagnosis of steroid 5 α -reductase 2 deficiency was made, but the coding sequence for this gene was normal. It was decided to raise this child as a female, and she was gonadectomized. She was subsequently treated with conjugated estrogen and underwent vaginal dilatation at age 13 yr.

Genomic DNA isolation

Genomic DNA was extracted from cultured fibroblasts and white blood cells as described previously (19) using an Applied Biosystems model 340A Nucleic Acids Extractor. In some cases genomic DNA was extracted from embedded and formalin-fixed tissue specimens. Briefly, small sections of the tissue block were deparafinized with xylene and then rehydrated by rinsing in a graded series of ethanol solutions. The

tissue was treated twice with proteinase K [250 μ g/mL in 10 mmol/L Tris-chloride (pH 8.0) and 1 mmol/L ethylenediamine tetraacetate-1% (wt/vol) SDS; 55 C; 1–16 h], and DNA was isolated using a kit (IsoQuick Nucleic Acid Extractor Kit, MicroProbe Corp., Garden Grove, CA). The purified DNA was then used as a template in PCR, as described below.

Mutation detection

Mutations in the 17HSD 3 gene were detected by amplification of individual exons using the PCR and single strand DNA conformation polymorphism analysis, as previously described (4). The DNA sequences of the oligonucleotide pairs used to amplify the 11 exons of the gene are shown in Table 3. Exons 1, 3, 4, 5, 7, 9, and 11 were amplified with a thermocycler program consisting of 30 cycles of 94 C for 30 s, 65 C for 15 s, and 72 C for 30 s. Exons 2, 6, 8, and 10 were amplified using a thermocycler program consisting of 30 cycles of 94 C for 30 s, 62 C for 15 s, and 72 C for 30 s. The nucleotide sequence of exons suspected of harboring mutations on the basis of single strand DNA conformation polymorphism analysis were determined by cycle sequencing using a thermostable DNA polymerase (20).

Expression analysis in transfected 293 cells

Site-directed mutagenesis reactions in which individual missense mutations were introduced into an expressible complementary DNA (cDNA) vector were performed with a Mutagen Kit (Bio-Rad Laboratories, Richmond, CA). The mutagenic oligonucleotide primers were 21 bases in length. Manipulated DNA fragments were subjected to DNA sequence analysis and then transfected into cultured human embryonic kidney 293 cells (CRL 1573, American Type Culture Collection, Rockville, MD) using a calcium phosphate precipitation protocol (21). Forty-eight hours after transfection, cells were analyzed for 17 β HSD activity as previously described (4, 22).

Immunoblotting of transfected cell extracts was carried out using an antipeptide antibody directed against residues 303–310 of the 17 β HSD-3 isoenzyme. A polyclonal antibody was raised in rabbits by standard methods (23) after coupling the synthetic peptide to bovine thyroglobulin. Peptide-specific antibodies were purified by chromatography on antigen-agarose beads and used directly in the immunoblotting reactions. Aliquots of transfected cell extracts (5 μ g protein) were separated by electrophoresis through 12% (wt/vol) polyacrylamide gels containing 0.1% (wt/vol) SDS. Separated proteins were transferred to nitrocellulose filters (Novex Corp., San Diego, CA) by electroblotting and subjected to a standard immunoblotting protocol (23). Enhanced chemi-

TABLE 3. Sequence and locations of oligonucleotides in 17 β HSD3 gene used for PCRs

Oligonucleotide	Location	Amplification target	Sequence 5' → 3'
1	5'-Untranslated, Exon 1	Exon 1	ACGGCCAGGGCTGAAACAGTCTGT
2	Intron 1		AGTAACAAGCAGGAACAACAGCAG
3	Intron 1	Exon 2	TGAATTACTGTCTTTAAAAGCA
4	Intron 2		AATACAAGGGAGGAGAAAGTCCCCA
5	Intron 2	Exon 3	GCTCATCATCCTTGTCTCTGGTTT
6	Intron 3		GAGGGCTCCACACACATCTCCCTTA
7	Intron 3	Exon 4	TGGATCCCTGTTTCATTAATAAAACT
8	Intron 4		GATGTATGACAACAAGCTTTGCATC
9	Intron 4	Exon 5	CTGATCTTCTGACACATTTTGGTTT
10	Intron 5		AGCCAGGGGACCCAGAACCCTGGG
11	Intron 5	Exon 6	GAGAATTTCTCTAATCATCCGGCTG
12	Intron 6		ACATGTTAATGCATTTTCGACA
13	Intron 6	Exon 7	AGTTCCTTGTGGGCTTACCTTGG
14	Intron 7		AGGGCAGGGAGGCCATGTTGCTCCA
15	Intron 7	Exon 8	CAACAAAGCCATGGGAAC
16	Intron 8		AAGGAAGAGACTTGGAAAGTCATGAC
17	Intron 8	Exon 9	AGTCACTCTGGGGCTCAGGTGTC
18	Intron 9		GATGACAAGGACTCCACAGCTG
19	Intron 9	Exon 10	GATTGCTTCTGTGCCATGGTCTTTG
20	Intron 10		TTCAAGAAAAGGAGAAGTT
21	Intron 10	Exon 11	GATGAACTGAGGTACTTGTATTCC
22	3'-Untranslated, exon 11		GAGGAAAAGGTTGTGCTGGACTCCT

luminescence reagents (Amersham Corp., Arlington Heights, IL) were used to detect antigen-antibody complexes.

Results

Subjects

The geographical, clinical, and genetic characteristics of the subjects studied are summarized in Table 1; these individuals comprise about 45% of all subjects reported to date with 17 β HSD deficiency. The affected individuals are from 17 families and represent diverse ethnic groups. In all instances, except 1, the diagnosis of 17 β HSD deficiency was based on characteristic clinical features, namely 46,XY males with pseudohermaphroditism, measurable or male serum testosterone levels, and elevated androstenedione levels. In 1 instance (17HSD-3-Indianapolis), an infant with ambiguous genitalia was misdiagnosed as having 5 α -reductase 2 deficiency, and the correct diagnosis was only made after molecular genetic analysis. Interestingly, only a single mutant allele was identified in the 17 β HSD-3 gene in this individual; we assume that the other allele probably contains a mutation outside the coding sequence of the gene, as heterozygous males with other mutations of the gene are phenotypically and endocrinologically normal. Alternatively, the individual might be a heterozygous carrier of the mutation and have some unidentified cause of ambiguous genitalia. Of the subjects in Table 1, all have been raised as female except for 17HSD-3-Stony Brook, who is being raised as a male, and 17HSD-3-Gaza, some of whom are raised as males and some as females (11–14).

In two subjects studied at the University of California-San Francisco, androstenedione and testosterone were measured in spermatic venous blood obtained by cannulation at the time of orchidectomy, and the levels were compared with normal spermatic vein measurements from the same laboratory (Table 2). Androstenedione levels in spermatic venous blood were elevated 15- to 20-fold, and testosterone levels were decreased 15- to 70-fold. The testosterone to androstenedione levels in these two subjects were 0.09 and 0.03, in contrast to normal ratios of 24–32.

Mutations

The mutations in this cohort are summarized in Table 1 and Fig. 1. Fourteen different mutations have been identified

in 12 homozygotes, 4 compound heterozygotes, and 1 presumed compound heterozygote. These mutations occur in or affect the splicing of 7 exons and consist of 1 small deletion, 3 splice site mutations, and 10 missense mutations that cause single amino acid substitutions in the protein. Three of these mutations were identified in more than 1 family. The R80Q mutation, originally identified in homozygous form in 17HSD-3-Gaza and in heterozygous form in 17HSD-3-Sao Paulo 1 (4), was found in homozygous form in 17HSD-3-Sao Paulo 3. Likewise, the 655–1,G \rightarrow A splice acceptor site mutation previously described in 17HSD-3-Syria (4) is present in homozygous form in 17HSD-New York, and the 325+4,A \rightarrow T splice acceptor site mutation was present in homozygous form in 3 families and in heterozygous form in 2 others (Table 1).

Expression analysis of missense mutations

To confirm that the coding sequence mutations are deleterious, five of the missense mutations that cause single amino acid substitutions (S65L, V205E, F208I, E215D, and P282L) were introduced into expressible cDNA vectors by site-directed mutagenesis, and the enzyme activity was assessed after transfection into cultured cells by measuring the conversion of radioactive androstenedione to testosterone (Fig. 2A). The fact that the mutant cDNAs were expressed in the transfected cells was shown by immunoblotting using an antibody directed to a specific epitope of 17 β HSD-3 (Fig. 2B). In each of the mutations studied, the substitution mutation appeared to inactivate enzyme activity almost completely (Fig. 2A). Thus, of the nine substitution mutations analyzed by this technique to date (4), only the R80Q mutation appears to possess residual enzyme activity when studied in this manner, namely approximately 20% of the normal activity.

DISCUSSION

17 β HSD-3 deficiency is a rare autosomal recessive cause of male pseudohermaphroditism. The typical subject with this disorder is a 46,XY male who is born with a female external phenotype (but with testes located in the inguinal canals or labia majora) and who undergoes considerable virilization at the time of expected puberty associated with elevated levels of blood androstenedione and either low or normal male

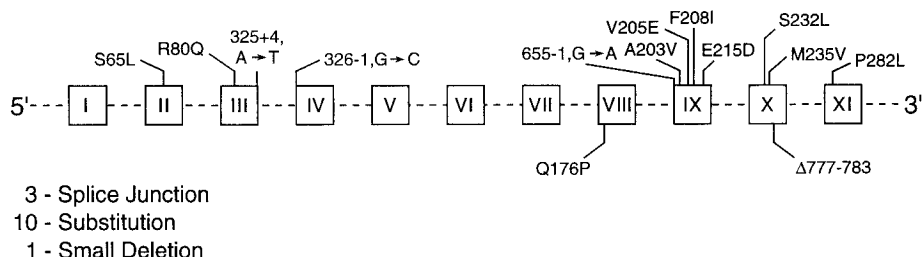


FIG. 1. Mutations in steroid 17 β HSD-3 gene in subjects with 17 β HSD deficiency. Exons are numbered with Roman numerals and are indicated by *open squares* connected by introns (*dashed lines*). Neither introns nor exons are drawn to scale. Substitution mutations in the different exons are indicated above the diagram by the single letter code. The normal amino acid appears first, followed by the residue number in the proenzyme and the mutant amino acid. Δ , A small deletion in exon 10 of the gene. The locations of splice junction mutations are indicated by the closest nucleotide in the exon \pm the number of nucleotides to the mutation. For example, the mutation 325+4,A \rightarrow T is an A to T transversion mutation located four nucleotides downstream of the exon 3/intron 3 boundary. Nucleotide number 325 is the last base of exon 3 in the sequenced cDNA (4).

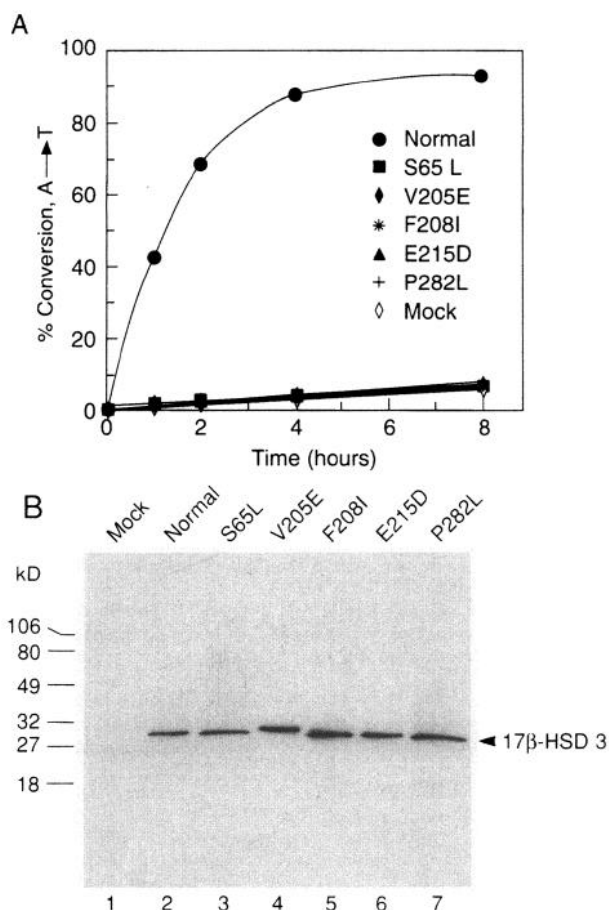


FIG. 2. Expression analysis of normal and mutant 17 β HSD-3 isoenzymes. cDNAs encoding the normal type 3 isoenzyme or a protein harboring the indicated amino acid substitution mutation were transfected into cultured human embryonic kidney 293 cells on day 0. On day 2, the medium was supplemented with 2 μ mol/L [14 C]androstenedione (53 mCi/mmol), and the incubation was continued for the indicated time period. Thereafter, the medium was harvested, and the conversion of androstenedione to testosterone was monitored by thin layer chromatography (A). In B, 5- μ g aliquots of total cell lysate on day 3 of the experiment were analyzed by immunoblotting using an antipeptide antibody directed against the 17 β HSD-3 isoenzyme. The protein migrates with an apparent mol wt of 30,000 and is present in all transfected cells at approximately the same levels.

levels of testosterone (7–9). [Occasional individuals have ambiguous genitalia at birth (24), and two late-onset variants of uncertain pathophysiology have been described, one manifest by gynecomastia in boys (25, 26) and the other as polycystic disease in women (27).]

It has been recognized for approximately 25 yr that this disorder is the result of a defect in the final step in testosterone synthesis in the testes, namely the conversion of androstenedione to testosterone (5, 6). We have shown that the molecular basis of this disorder is any of several mutations in the 17 β HSD-3 gene, a gene that appears to be expressed predominately or exclusively in testes (4). In the present report we describe 9 additional mutations in this gene to make a total of 14 different mutations in 17 subjects/families. Twelve are present in homozygous form, 4 are compound heterozygotes, and 1 is a presumed compound heterozygote.

These mutations consist of a 7-nucleotide deletion that causes a frame shift, 3 splice site abnormalities, and 10 missense mutations that cause amino acid substitutions. Three of these mutations (R80Q, 655–1, G \rightarrow A, and 325+4, A \rightarrow T) have been identified in more than 1 family; we do not know at present whether this recurrence is due to a founder effect or to recurrent new mutations.

Two characteristic features of the disorder are particularly puzzling: 1) the defect in virilization and the deficiency in testosterone synthesis are usually more complete during embryogenesis than in later life, implying that an alternate route for testosterone synthesis must be activated at the time of expected puberty; and 2) the external genitalia at birth are usually female in character, but the Wolffian duct structures (epididymides, vasa deferentia, and seminal vesicles) virilize normally, indicating that androgen must act by an alternate mechanism in these tissues *in utero*.

The findings in the present study provide insight into the source of circulating testosterone after the time of expected puberty in this disorder. Two theories have been proposed to explain this phenomenon. First, Akesson and his colleagues (10) concluded on the basis of studies of the metabolism of radioactive precursors in a single affected subject (17HSD-3-Syria) that testosterone is formed from circulating androstenedione by extraglandular conversion. Second, on the basis of studies of the hormone concentrations in testicular venous blood from several related subjects from the Gaza strip (17HSD-3-Gaza), Eckstein *et al.* (11) demonstrated that considerable amounts of testosterone can be secreted by the testes of affected members of that kindred. Using site-directed mutagenesis and transient transfection assays, we demonstrated that eight of the nine missense mutations inactivate enzyme activity almost completely. Furthermore, in two of the individuals with inactive missense mutations, assessment of testosterone and androstenedione levels in testicular venous blood indicated that these individuals secrete only 5% as much testosterone from the testes as normal controls. This finding is in keeping with the fact that the expressed enzyme from the subject described by Akesson *et al.* (10) (17HSD-3-Syria) was also inactive when transiently expressed in reporter cells (4). As the other mutations characterized to date, the frame-shift mutation and the splice acceptor site abnormalities, are predicted to preclude the formation of functional protein, we conclude that the common mechanism for testosterone synthesis (and for the resulting virilization) after the time of expected puberty in this disorder is by extraglandular formation. It is of interest in this regard that in the one exception to this generalization (subjects from the Gaza family who carry the R80Q mutation), not only was testosterone secreted by the testes (11), but in addition, the expression of the reconstructed DNA containing this mutation caused the formation of an enzyme with about 15–20% of normal enzyme activity at high substrate concentrations (4).

Whether the enzyme responsible for extraglandular conversion of androstenedione to testosterone is isoenzyme 1 or 2 or some other 17 β HSD enzyme is, at present, unclear, nor is it understood why this process seems to be more efficient in later life than during embryogenesis. The enhancement of testosterone synthesis at the time of expected puberty may be the consequence of the increased output of androstenedione by the testes after the pubertal surge of LH secretion and,

hence, the availability of more substrate for testosterone synthesis in extraglandular sites by other isoenzymes.

The present studies also leave unexplained the virilization of the Wolffian ducts in these subjects during fetal life. At the simplistic level, virilization in the absence of circulating testosterone could be due to the presence in the tissue of an embryonic receptor mechanism that lacks the specificity of the mature androgen receptor or to the presence in the tissue of an alternate mechanism for the conversion of circulating androstenedione. So far as can be ascertained, the embryonic Wolffian duct androgen receptor is identical to the receptor in other tissues (28), and we, therefore, conclude that this tissue must contain an alternate pathway for testosterone formation, possibly the same 17 β HSD responsible for extraglandular testosterone formation in later life. The mechanism by which the Wolffian ducts virilize in this disorder is now under scrutiny.

Extraglandular testosterone formation may also be responsible for one other unexpected finding in the present study. Namely, 1 of the 16 homozygotes/compound heterozygotes in the present study (17HSD-3-Stony Brook) had clear-cut ambiguous genitalia at the time of birth, implying considerable testosterone formation during embryogenesis. It was, therefore, unexpected that when the reconstructed DNA containing this mutation (F208I) was expressed in reporter cells, the mutant 17 β HSD was totally inactive. It is possible that there is considerable genetic variability among individuals in the capacity for extraglandular testosterone formation.

References

- George FW, Wilson JD. 1994 Sex determination and differentiation. In: Knobil E, Neill JD, eds. *The physiology of reproduction*. New York: Raven Press; 3–28.
- Griffin JE, McPhaul MJ, Russell DW, Wilson JD. 1995 The androgen resistance syndromes: steroid 5 α -reductase 2 deficiency, testicular feminization, and related disorders. In: Scriver CR, Beaudet AL, Sly WS, Valle D, eds. *The metabolic and molecular bases of inherited disease*, 7th ed. New York: McGraw-Hill; 2967–2998.
- Griffin JE, Wilson JD. 1992 Disorders of sexual differentiation. In: Walsh PC, Resnik AB, Stamey TA, Vaughan Jr ED, eds. *Campbell's urology*, 6th ed. Philadelphia: Saunders; 1509–1542.
- Geissler WM, Davis DL, Wu L, et al. 1994 Male pseudohermaphroditism caused by mutations of testicular 17 β -hydroxysteroid dehydrogenase 3. *Nature Genet.* 7:34–39.
- Saez JM, de Peretti E, Morera AM, David M, Bertrand J. 1971 Familial male pseudohermaphroditism with gynecomastia due to a testicular 17-ketosteroid reductase defect. *J Clin Endocrinol Metab.* 32:604–610.
- Saez JM, Morera AM, de Peretti E, Bertrand J. 1972 Further *in vivo* studies in male pseudohermaphroditism with gynecomastia due to a testicular 17-ketosteroid reductase defect (compared to a case of testicular feminization). *J Clin Endocrinol Metab.* 34:598–600.
- Forest MG. 1981 Inborn errors of testosterone biosynthesis. In: *The intersex child: pediatric adolescent endocrinology*. Basel: Karger; vol 8:133–155.
- Peterson RE, Imperato-McGinley J. 1984 Male pseudo-hermaphroditism due to inherited deficiencies of testosterone biosynthesis. In: Serio M, ed. *Sexual differentiation: basic and clinical aspects*. New York: Raven Press; 301–319.
- Virdis R, Saenger P. 1984 17 β -Hydroxysteroid dehydrogenase deficiency. In: *Adrenal diseases in childhood: pediatric adolescent endocrinology*. Basel: Karger; vol 13:110–124.
- Akesode FA, Meyer III WJ, Migeon CJ. 1977 Male pseudohermaphroditism with gynaecomastia due to testicular 17-ketosteroid reductase deficiency. *Clin Endocrinol (Oxf)*. 7:443–452.
- Rosler A, Belanger A, Labrie F. 1992 Mechanisms of androgen production in male pseudohermaphroditism due to 17 β -hydroxysteroid dehydrogenase deficiency. *J Clin Endocrinol Metab.* 75:773–778.
- Eckstein B, Cohen S, Farkas S, Rosler A. 1989 The nature of the defect in familial male pseudohermaphroditism in Arabs of Gaza. *J Clin Endocrinol Metab.* 64:477–485.
- Kohn G, Lasch EE, El Shawwa R, Litvin Y, Rosler A. 1985 Male pseudohermaphroditism due to 17 β -hydroxysteroid dehydrogenase deficiency (17 β HSD) in a large Arab kinship. Studies on the natural history of the defect. *J Pediatr Endocrinol.* 1:30–37.
- Rosler A, Kohn G. 1983 Male pseudohermaphroditism due to 17 β -hydroxysteroid dehydrogenase deficiency: studies on the natural history of the defect and effect of androgens on gender role. *J Steroid Biochem.* 19:663–674.
- Arnhold IJP, Mendonca BB, Diaz JAP, et al. 1988 Prepubertal male pseudohermaphroditism due to 17-ketosteroid reductase deficiency: diagnostic value of a hCG test and lack of HLA association. *J Endocrinol Invest.* 11:319–322.
- Virdis R, Saenger P, Senior B, New MI. 1978 Endocrine studies in a pubertal male pseudohermaphroditism with 17-ketosteroid reductase deficiency. *Acta Endocrinol (Copenh)*. 87:212–224.
- Weinstein RL, Kelch RP, Jenner MR, Kaplan SL, Grumbach MM. 1974 Secretion of unconjugated androgens and estrogens by the normal and abnormal human testis before and after human chorionic gonadotropin. *J Clin Invest.* 53:1–6.
- Kelch RP, Jenner MR, Weinstein RL, Kaplan SL, Grumbach MM. 1972 Estradiol and testosterone secretion by human, simian, and canine testes, in males with hypogonadism and in male pseudohermaphrodites with the feminizing testis syndrome. *J Clin Invest.* 51:824–830.
- Thigpen AE, Davis DL, Milatovich A, et al. 1992 Molecular genetics of steroid 5 α -reductase 2 deficiency. *J Clin Invest.* 90:799–809.
- Lee J-S. 1991 Alternative dideoxy sequencing of double-stranded DNA by cyclic reactions using *Taq* polymerase. *DNA Cell Biol.* 10:67–73.
- Gorman CM, Gies DR, McCray G. 1990 Transient production of proteins using an adenovirus transformed cell line. *DNA Protein Engin Techniques.* 2:3–10.
- Wu L, Einstein M, Geissler WM, Chan HK, Elliston KO, Andersson S. 1993 Expression cloning and characterization of human 17 β -hydroxysteroid dehydrogenase 2, a microsomal enzyme possessing 20 α -hydroxysteroid dehydrogenase activity. *J Biol Chem.* 268:12964–12969.
- Harlow E, Lane D. 1988 *Antibodies—a laboratory manual*. Cold Spring Harbor: Cold Spring Harbor Laboratory; 1–176.
- Levine LS, Lieber E, Pang S, New MI. 1980 Male pseudohermaphroditism due to 17-ketosteroid reductase deficiency diagnosed in the newborn period. *Pediatr Res.* 14:480.
- Rogers DG, Chasalow FI, Blethen SL. 1985 Partial deficiency of 17-ketosteroid reductase presenting as gynecomastia. *Steroids.* 45:195–200.
- Castro-Magana M, Angulo M, Uy J. 1993 Male hypogonadism with gynecomastia caused by late-onset deficiency of testicular 17-ketosteroid reductase. *N Engl J Med.* 328:1297–1301.
- Pang S, Softness B, Sweeney WJ, New MI. 1987 Hirsutism, polycystic ovarian disease, and ovarian 17-ketosteroid reductase deficiency. *N Engl J Med.* 316:1295–1301.
- Bentvelsen FM, McPhaul MJ, Wilson JD, George FW. 1994 The androgen receptor of the urogenital tract of the fetal rat is regulated by androgen. *Mol Cell Endocrinol.* 105:21–26.
- Mieusset R, Sowerbutts SF, Zupp JL, Setchell BP. 1992 Increased flow of testicular blood plasma during local heating of the testes of rams. *J Reprod Fertil.* 94:345–352.