

SHORT COMMUNICATION

Open Access



Molecular imaging of fibroblast activation in multiple non-ischemic cardiomyopathies

Jingnan Wang^{1,2}, Li Huo^{1,2}, Xue Lin³, Ligang Fang³, Marcus Hacker⁴, Na Niu^{1,2*}  and Xiang Li^{4*}

Abstract

Background This pilot study is aimed to perform a pilot visualization study to investigate in vivo fibroblast activation in non-ischemic cardiomyopathies by ⁶⁸Ga-FAPI-04 PET/CT.

Methods Twenty-nine consecutive patients with symptomatic non-ischemic cardiomyopathies who underwent ⁶⁸Ga-FAPI-04 PET/CT were prospectively recruited. Clinical characteristics and echocardiographic parameters were recorded. Cardiac uptake was quantified by standardized uptake values (SUV_{max}, SUV_{mean}, SUVR) and left ventricular metabolism volume. The relationship between ⁶⁸Ga-FAPI-04 uptake with clinical and echocardiography parameters was investigated.

Results Heterogeneous ⁶⁸Ga-FAPI-04 uptake was observed in different subtypes of non-ischemic cardiomyopathies. Twenty-two (75.9%) patients showed elevated ⁶⁸Ga-FAPI-04 uptake in the left ventricle, and 10 (34.5%) patients also showed slightly diffuse elevated uptake in the right ventricle. Cardiac uptake values were significantly correlated with enlarged ventricular volume evaluated by echocardiography.

Conclusion FAPI PET/CT presents a potential value for in vivo visualization and quantification of fibroblast activation on the molecular level. Further study is warranted for investigating the theranostic and prognostic value of elevated FAP signal.

Keywords ⁶⁸Ga-FAPI-04, PET imaging, Non-ischemic cardiomyopathy

Introduction

Non-ischemic cardiomyopathy (NICM) is an essential risk factor for developing heart failure and sudden cardiac death. NICMs include a variety of myocardial disorders and could be classified according to morphofunctional

phenotype, organ involvement, genetic inheritance pattern, etiological annotation, and functional status into different subtypes [1]. Activation of cardiac fibroblasts plays a substantial role in the pathogenesis of various cardiomyopathy and occurs early in the progression of the disease [2]. Identifying and characterizing NICM-associated fibroblast activation potentially be helpful for both diagnosis and therapy, eventually improving clinicians to stratify the risk of potential clinical complications.

A recently developed PET tracer ⁶⁸Gallium-labeled fibroblast activation protein inhibitor presented great potential in specific detection and characterization of cardiac fibroblasts activation [3]. A pilot quantification of fibroblast activation protein inhibitor (FAPI) activity using ⁶⁸Gallium-labeled FAPI PET ligand was demonstrated in patients with acute myocardial infarction [4]. In vivo FAPI signal was also elevated in myocarditis after

*Correspondence:

Na Niu

niunayy@sina.com

Xiang Li

xiang.li@meduniwien.ac.at

¹ Department of Nuclear Medicine, Peking Union Medical College Hospital, Chinese Academy of Medical Sciences & Peking Union Medical College, 1# Shuaifuyuan, Dongcheng District, Beijing 100730, China

² Beijing Key Laboratory of Molecular Targeted Diagnosis and Therapy in Nuclear Medicine, Beijing, China

³ Department of Cardiology, Peking Union Medical College Hospital, Chinese Academy of Medical Sciences & Peking Union Medical College, Beijing, China

⁴ Division of Nuclear Medicine, Department of Biomedical Imaging and Image-Guided Therapy, Medical University of Vienna, Vienna, Austria

immune checkpoint inhibitors treatment, hypertensive heart disease, cardiac sarcoidosis, pulmonary hypertension, etc. [5]. Nowadays, the evidence of the potential utility of FAPI PET in NICMs is limited.

In this prospective pilot study, we aimed to perform a pilot visualization study to investigate in vivo myocardial fibroblast activation in different subtypes of NICMs. It would allow us to provide a preliminary mapping of multiple NICMs and investigate whether myocardial FAPI activity is an independent biomarker of myocardial dysfunction or myocardial remodeling, irrespective of the types of cardiomyopathy. We hope our findings can inspire potential readers and researchers to perform further studies on the mechanisms of these diseases and the identification of new therapeutic agents.

Materials and methods

This study was approved by the Institutional Ethics Committee of Peking Union Medical College Hospital (ZS1810), and all subjects provided written informed consent. Twenty-nine consecutive patients with distinct subtypes of NICMs were recruited. The diagnosis of NICMS was made by cardiology department based on the contemporary definitions and classification of cardiomyopathies [6]. Besides, the diagnosis of coronary atherosclerotic disease (CAD) was excluded according to electrocardiogram, coronary artery CTA, or coronary angiography. These patients had never received cardiotoxic therapy.

All patients underwent ^{68}Ga -FAPI-04 PET/CT scans (Polestar m660, SinoUnion) 60 min after intravenous injection of 157.3 ± 25.2 MBq of the tracer. One bed position was acquired (20 min, 3D mode), and the heart was set at the center of the view. Visual analysis was evaluated, and increased cardiac ^{68}Ga -FAPI-04 activity than blood pool (descending thoracic aorta) was considered as elevated tracer uptake. Quantification analysis of myocardial ^{68}Ga -FAPI-04 uptake was performed using PMOD package 4.1. The standardized uptake value (SUV) of the myocardium was measured by drawing the contour of the whole left ventricle and right ventricle on PET images. Maximal SUV (SUV_{max}) and mean SUV (SUV_{mean}) were recorded. SUV_R is defined as the SUV_{mean} of the myocardial VOI divided by the SUV_{mean} of the blood pool of descending thoracic aorta VOI (1 cm^3). The left ventricular metabolism volume (LVMV) was automatically calculated as the sum of all voxels with $\text{SUV} > 50\%$ of the SUV_{max} . In those patients absenting visible uptake (cardiac activity lower than descending thoracic aorta blood pool), SUV was recorded by drawing a 1-cm circle at the middle of the left ventricle wall.

Pearson's correlation analysis was conducted to demonstrate the relationship of ^{68}Ga -FAPI-04 PET/CT

parameters with echocardiography parameters. A P value < 0.05 was considered statistically significant.

Results

Twenty-nine consecutive patients (12 men and 17 women, with a mean age of 43.1 ± 16.9 years) with different subtypes of NICMs were included. Among these 29 patients, the diagnosis included dilated cardiomyopathy (DCM) ($n=10$), inflammatory cardiomyopathies (IC) with connective tissue disorders ($n=10$), hypertrophic cardiomyopathy (HCM) ($n=3$), left ventricular noncompaction (LVNC) ($n=3$), restrictive cardiomyopathy (RCM) ($n=1$), hyperthyroidism-induced cardiomyopathy (HTC) ($n=1$) and immune checkpoint inhibitor-related myocarditis (ICIM) ($n=1$). Baseline clinical characteristics and echocardiographic parameters are presented in Table 1.

Twenty-two (75.9%) patients showed heterogeneous elevated ^{68}Ga -FAPI-04 uptake in the left ventricle. Among them, 10 (34.5%) patients showed slightly diffuse activity in the right ventricle, including 1 RCM patient, 2 DCM patients, 3 HCM patients and 4 IC patients. The myocardial uptake in ^{68}Ga -FAPI-04-avid patients ($n=22$) was $\text{SUV}_{\text{max}} = 4.16 \pm 2.75$, $\text{SUV}_{\text{mean}} = 2.09 \pm 1.31$, $\text{SUV}_R = 1.92 \pm 1.18$, along with the diverse radioactive volume of $\text{LVMV} = 196.13 \pm 64.93$, respectively. Since patient numbers were not sufficient to compare tracer

Table 1 Characteristics of NICM patients

	All patients ($n=29$)
<i>Clinical characteristics</i>	
Male/female	12/17
Age (years)	43.14 ± 16.94
cTnI (pg/ml)	128.63 ± 168.39
CK (U/L)	106.83 ± 125.79
CK-MB ($\mu\text{g/L}$)	2.77 ± 2.99
NT-proBNP (pg/ml)	1819.36 ± 2660.61
Disease duration (months)	41.00 ± 35.00
<i>Baseline echocardiographic parameters</i>	
LVEDD (mm)	60.79 ± 10.78
LVESD (mm)	47.69 ± 12.45
LVEF (%)	42.93 ± 14.66
<i>^{68}Ga-FAPI-04 uptake</i>	
SUV_{max}	4.16 ± 2.75
SUV_{mean}	2.09 ± 1.31
SUV_R	1.92 ± 1.18
LVMV (mL)	196.13 ± 64.93

Values are mean \pm SD for continuous variables. cTnI Cardiac troponin I; CK Creatine kinase; CK-MB Creatine kinase-MB; NT-proBNP N-terminal fragment of pro-hormone brain natriuretic peptide; LA Left atrium; LVEDD Left ventricular end diastolic diameter; LVESD Left ventricular end systolic diameter; LVEF Left ventricular ejection fraction; SUV Standardized uptake value; LVMV Left ventricular metabolism volume

uptake among different subtypes of NICMs, we demonstrated the data in a pooled fashion (Fig. 1). PET images of representative patients are shown in Figs. 2 and 3. The correlation between ^{68}Ga -FAPI-04 uptake results with echocardiographic parameters was also analyzed. Cardiac uptake parameters were associated with enlarged ventricular volume. SUV_{max} , SUV_{mean} , and LVMV were significantly correlated with LVEDD ($r=0.407$, $P=0.031$; $r=0.424$, $P=0.025$; and $r=0.636$, $P=0.002$, respectively), and LVMV was significantly correlated with LVESD ($r=0.545$, $P=0.011$).

Discussion

Molecular characterization of the extracellular matrix (ECM) in NICM may help identify therapeutic pathways to attenuate cardiomyocyte dysfunction and enhance myocardial regeneration. Fibroblast activation protein is one of the matricellular ECM proteins, which is involved in fibroblast activation and myofibroblast generation underlying myocyte injury. Cardiac fibroblasts activation

and expansion significantly contribute to the pathogenesis of multiple cardiac diseases [2]. Pioneering basic and clinical research demonstrated intensive focal FAPI signals in the infarcted myocardium, which showed good agreement with the affected coronary territory [7]. Nowadays, the evidence of FAPI imaging in the evaluation of non-ischemic cardiomyopathies (NICM) was limited, so we aimed to quantify and characterize fibroblast activation in multiple NICMs and investigate whether the cardiac FAPI activity is a surrogate biomarker of myocardial dysfunction.

In this study, we observed in vivo molecular imaging of ^{68}Ga -FAPI-04 PET targeting FAP in different subtypes of NICM patients. We found that most enrolled patients presented elevated myocardial uptake with heterogeneous patterns and FAPI signal density is associated with cardiac contractility. In our previous cohort conducting ^{68}Ga -FAPI-04 PET in patients with noncardiovascular indications, we did not observe elevated cardiac FAPI signal [8].

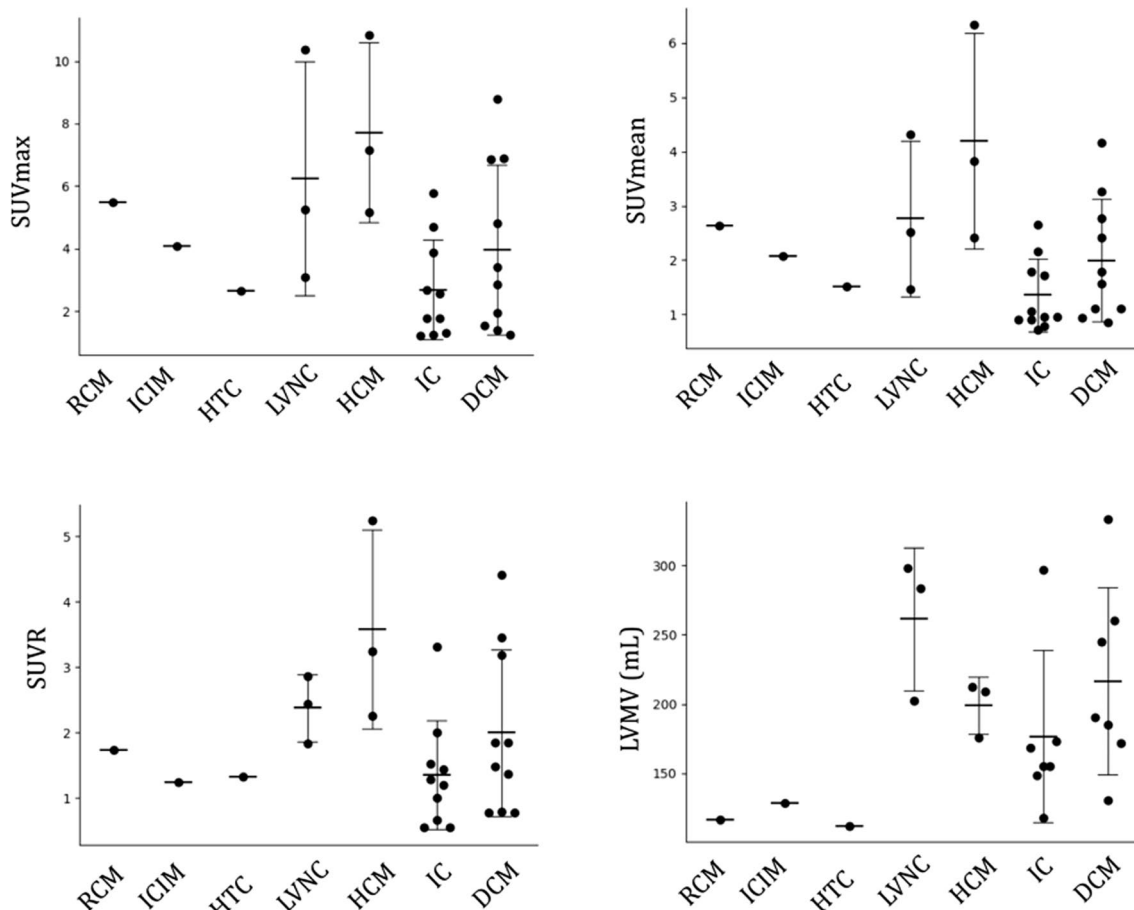


Fig. 1 ^{68}Ga -FAPI-04 uptake (SUV_{max} , SUV_{mean} , SUV_{r} , and LVMV) in different subtypes of NICMs. RCM Restrictive cardiomyopathy; ICIM Immune checkpoint inhibitor-related myocarditis; HTC, Hyperthyroidism-induced cardiomyopathy; LVNC Left ventricular noncompaction; HCM Hypertrophic cardiomyopathy; IC Inflammatory cardiomyopathies; DCM Dilated cardiomyopathy

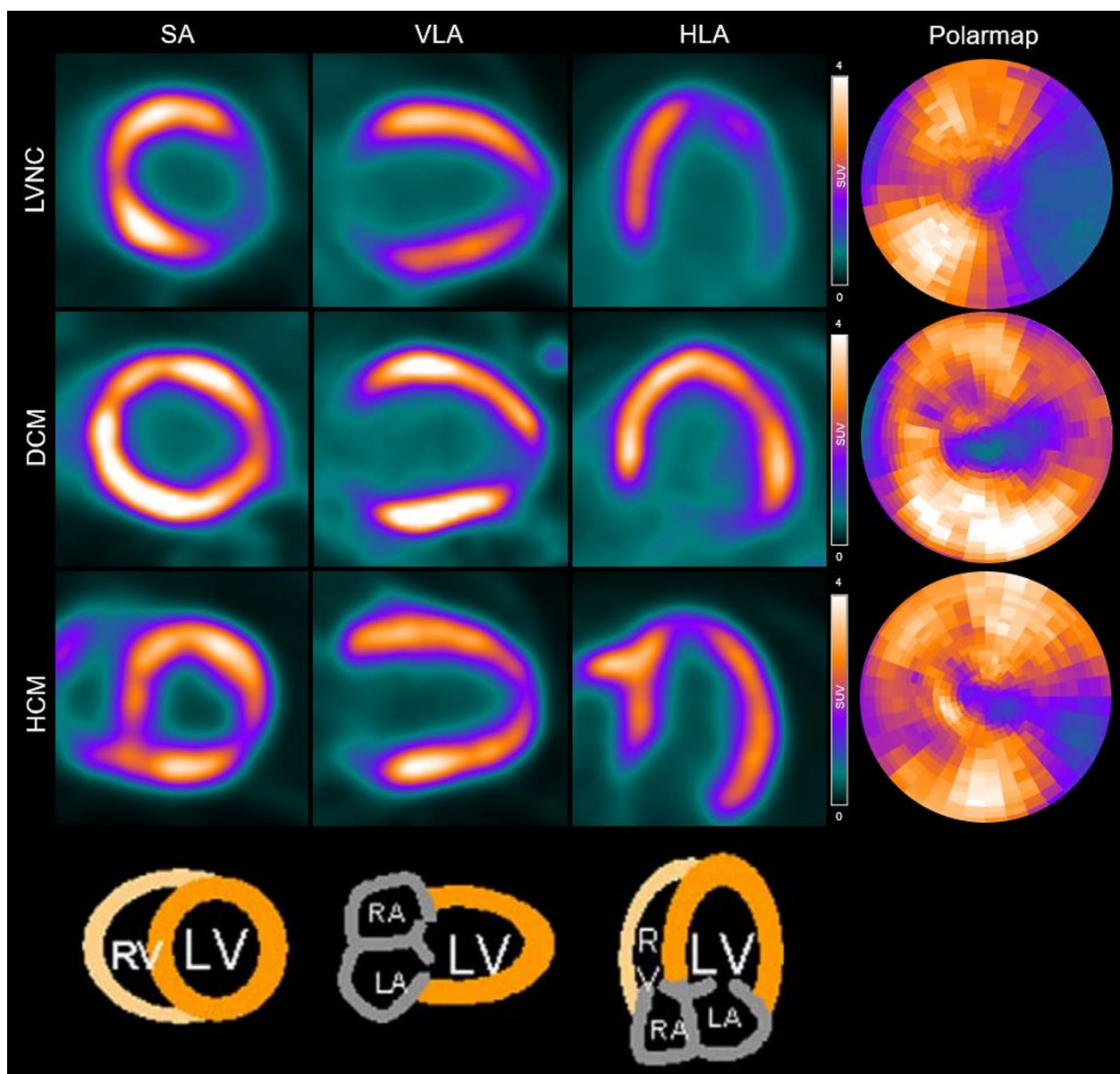


Fig. 2 Example of ^{68}Ga -FAPI-04 PET images in representative patients. *LVNC* Left ventricular noncompaction; *DCM* Dilated cardiomyopathy; *HCM* Hypertrophic cardiomyopathy; *SA* Short axis; *HLA* Horizontal long axis; *VLA* Vertical long axis; *RV* Right ventricle; *LV* Left ventricle; *RA* Right atrium; *LA* Left atrium

In this preliminary study, we found heterogeneous diffused elevated FAPI signals within the left ventricular wall in different subtypes of NICM patients, and a distinct FAPI uptake value was observed within the same category of disease. We thought various disease pathogeny might be an explanation. For instance, for the enrolled inflammatory cardiomyopathies patients, the underlying diseases include inflammatory myopathy, vasculitis, systemic sclerosis, and systemic lupus erythematosus. Although inflammatory cardiomyopathies are

associated with inflammatory cell infiltration into the myocardium, the underlying mechanism of the autoimmune response might be different [9]. FAPI signal could be transient and not associated with disease staging. In addition, DCM is a heterogeneous disease that presents the manifestation of multiple non-ischemic disorders, e.g., genetic mutations, metabolic and endocrine disturbances, exposure to alcohol, drugs, and toxins [10]. The disease severity and duration were also different. These could eventually lead to different FAPI signals in the

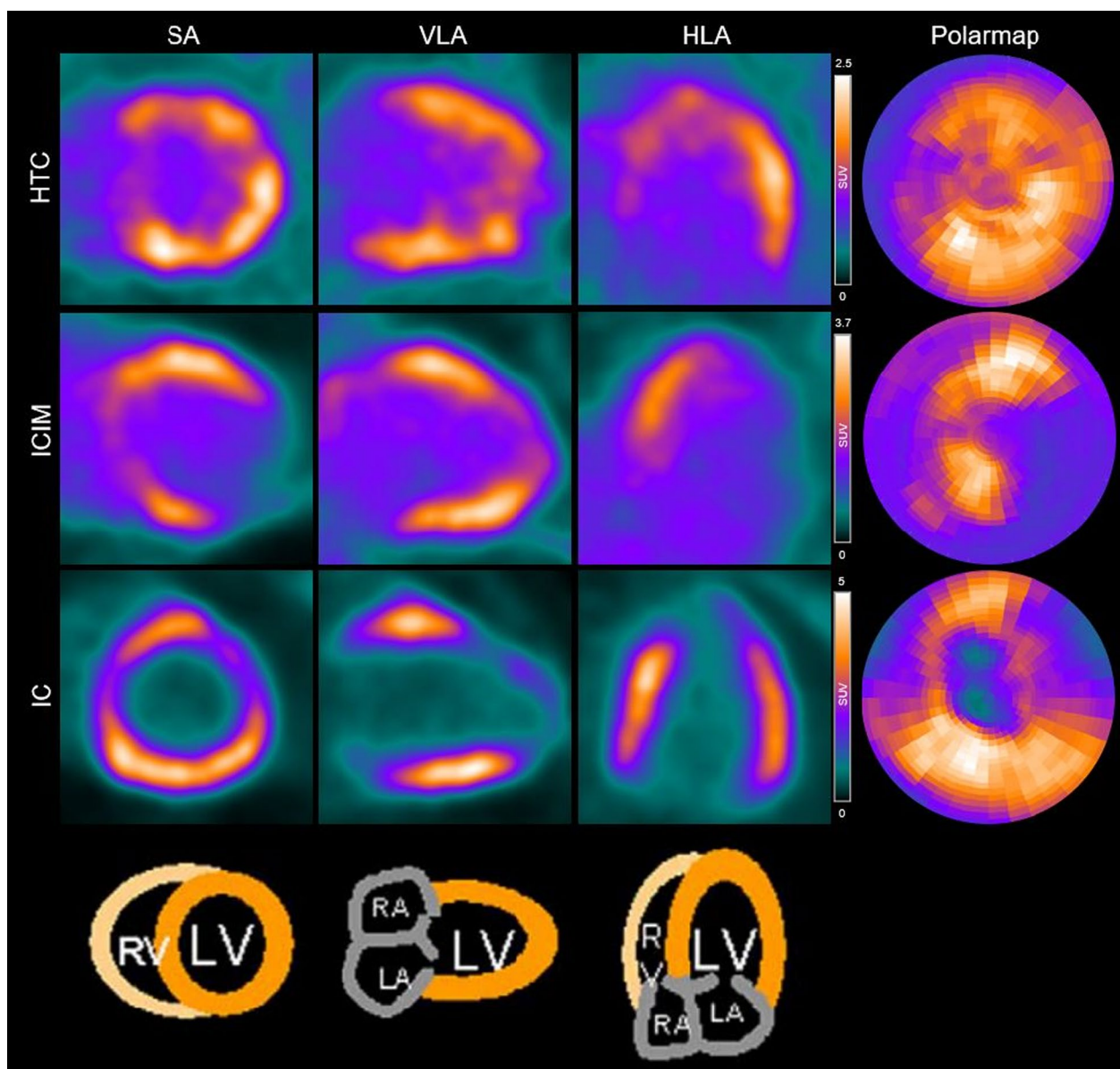


Fig. 3 Example of ^{68}Ga -FAPI-04 PET images in representative patients. *HTC* Hyperthyroidism-induced cardiomyopathy; *ICIM* Immune checkpoint inhibitor-related myocarditis; *IC* Inflammatory cardiomyopathies; *SA* Short axis; *HLA* Horizontal long axis; *VLA* Vertical long axis; *RV* Right ventricle; *LV* Left ventricle; *RA* Right atrium; *LA* Left atrium

same type of disease. Interestingly, we observed elevated right ventricular uptake in a few patients, including 1 RCM patient, 2 DCM patients, all 3 HCM patients, and 4 inflammatory cardiomyopathy patients. This might indicate that disease-related fibrotic activation could also occur in the entire heart. In the correlation analysis, the cardiac uptake parameters were significantly associated with enlarged ventricular volume. Due to the limited patient number in our data, further subgroup analysis could not be achieved.

All in all, NICMs are essential and heterogeneous groups of diseases. Conventional imaging features for defined describing disease entities of cardiomyopathies may be limited with low sensitivity. FAPI PET imaging might provide essential information regarding the derivation and function of cardiac tissue or disease severity, potentially implicating a preferable strategy for visualizing cardiac diseases. The prognostic value of cardiac FAPI PET imaging in multiple NICMs post-systemic or targeted therapy also needs to be investigated. Although our

study has some limitations, including a relatively small sample size and lack of a control group, we believe it provides important preliminary data on the potential use of the FAPI signal as a noninvasive biomarker for NICMs and warrants further investigation in larger and more diverse patient populations. Another limitation is that the fibro-activation signal in cardiac disease is transient, disease-dependent, and cannot be accurately associated with disease staging. The limitations of FAPI imaging underscore the need for a more comprehensive and nuanced approach to evaluating cardiac disease, which takes into account the dynamic changes in macrophage and fibroblast activity over time.

Conclusion

To summarize, in this preliminary study, FAPI PET presented promising sensitivity in the detection of different subtypes of NICM diseases. As quantified by ⁶⁸Ga-FAPI-04 cardiac PET, myocardial fibroblast activation density showed a significant correlation with ventricular function and remodeling. Thereby, this novel diagnostic strategy might be expected to further clinical validation and translation.

Acknowledgements

Not applicable.

Author contributions

JNW contributed to conduction, investigation and writing—original draft, review and editing. LH was involved in methodology, writing—review and editing and funding acquisition. XL contributed to conceptualization, methodology and writing—review and editing. LGF was involved in conceptualization, resources and writing—review and editing. MH was involved in formal analysis and supervision. NN contributed to conceptualization, formal analysis, writing—review and editing, and supervision. XL was involved in formal analysis, writing—review and editing, project administration and supervision. All authors read and approved the final manuscript.

Funding

This work was supported in part by the CAMS Innovation Fund for Medical Sciences (CIFMS 2021-I2M-1-003, 2022-I2M-JB-001), National Natural Science Foundation of China (Beijing, No. 82071967).

Availability of data and materials

The datasets used and analyzed during the current study are available from the corresponding author on reasonable request.

Declarations

Ethics approval and consent to participate

All procedures performed in studies involving human participants were in accordance with the ethical standards of the institutional research committee and with the 1964 Helsinki Declaration and its later amendments or comparable ethical standards. The study was approved by the institutional review board (IRB) of Peking Union Medical College Hospital (No. ZS1810). The informed consent was obtained from the patient for publication of this case study/report and accompanying images.

Consent for publication

Not applicable.

Competing interests

The authors declare that they have no competing interests.

Received: 14 December 2022 Accepted: 19 April 2023

Published online: 08 May 2023

References

- Arbustini E, Narula N, Dec GW, Reddy KS, Greenberg B, Kushwaha S, et al. The MOGE(S) classification for a phenotype-genotype nomenclature of cardiomyopathy: endorsed by the World Heart Federation. *Glob Heart*. 2013;8(4):355–82. <https://doi.org/10.1016/j.gheart.2013.11.001>.
- Cojan-Minzat BO, Zlibut A, Agoston-Coldea L. Non-ischemic dilated cardiomyopathy and cardiac fibrosis. *Heart Fail Rev*. 2021;26(5):1081–101. <https://doi.org/10.1007/s10741-020-09940-0>.
- Siebermair J, Kohler MI, Kupusovic J, Nekolla SG, Kessler L, Ferdinandus J, et al. Cardiac fibroblast activation detected by Ga-68 FAPI PET imaging as a potential novel biomarker of cardiac injury/remodeling. *J Nucl Cardiol*. 2021;28(3):812–21. <https://doi.org/10.1007/s12350-020-02307-w>.
- Diekmann J, Koenig T, Zwadlo C, Derlin T, Neuser J, Thackeray JT, et al. Molecular imaging identifies fibroblast activation beyond the infarct region after acute myocardial infarction. *J Am Coll Cardiol*. 2021;77(14):1835–7. <https://doi.org/10.1016/j.jacc.2021.02.019>.
- Niu N, Huo L, Zhang S, Liu Y, Li X. Immune checkpoint inhibitor-associated cardiotoxicity detected by 68Ga-DOTATATE PET/CT and 68Ga-FAPI PET/CT. *Eur Heart J Cardiovasc Imaging*. 2022;23(3):e123. <https://doi.org/10.1093/ehjci/jeab189>.
- Maron BJ, Towbin JA, Thiene G, Antzelevitch C, Corrado D, Arnett D, et al. Contemporary definitions and classification of the cardiomyopathies: an American Heart Association scientific statement from the council on clinical cardiology, heart failure and transplantation committee; quality of care and outcomes research and functional genomics and translational biology interdisciplinary working groups; and council on epidemiology and prevention. *Circulation*. 2006;113(14):1807–16. <https://doi.org/10.1161/CIRCULATIONAHA.106.174287>.
- Varasteh Z, Mohanta S, Robu S, Braeuer M, Li Y, Omidvari N, et al. Molecular imaging of fibroblast activity after myocardial infarction using a (68) Ga-labeled fibroblast activation protein inhibitor, FAPI-04. *J Nucl Med*. 2019;60(12):1743–9. <https://doi.org/10.2967/jnumed.119.226993>.
- Wu M, Ning J, Li J, Lai Z, Shi X, Xing H, et al. Feasibility of in vivo imaging of fibroblast activation protein in human arterial walls. *J Nucl Med*. 2022;63(6):948–51. <https://doi.org/10.2967/jnumed.121.262863>.
- Comarmond C, Cacoub P. Myocarditis in auto-immune or auto-inflammatory diseases. *Autoimmun Rev*. 2017;16(8):811–6. <https://doi.org/10.1016/j.autrev.2017.05.021>.
- Weintraub RG, Semsarian C, Macdonald P. Dilated cardiomyopathy. *Lancet*. 2017;390(10092):400–14. [https://doi.org/10.1016/S0140-6736\(16\)31713-5](https://doi.org/10.1016/S0140-6736(16)31713-5).

Publisher's Note

Springer Nature remains neutral with regard to jurisdictional claims in published maps and institutional affiliations.