

Molecular mechanisms and phenotypic variation in *RYRI*-related congenital myopathies

Haiyan Zhou,^{1,*} Heinz Jungbluth,^{1,2,*} Caroline A. Sewry,^{1,3} Lucy Feng,¹ Enrico Bertini,⁴ Kate Bushby,⁵ Volker Straub,⁵ Helen Roper,⁶ Michael R. Rose,⁷ Martin Brockington,¹ Maria Kinali,¹ Adnan Manzur,¹ Stephanie Robb,¹ Richard Appleton,⁸ Sonia Messina,^{4,9} Adele D'Amico,⁴ Ros Quinlivan,³ Michael Swash,¹⁰ Clemens R. Müller,¹¹ Susan Brown,¹ Susan Treves¹² and Francesco Muntoni¹

¹Dubowitz Neuromuscular Centre, Imperial College, Hammersmith Hospital, London W12 0NN, UK, ²Department of Paediatric Neurology, Evelina Children's Hospital, St Thomas' Hospital, London SE1 7EH, UK, ³Centre for Inherited Neuromuscular Disorders, Robert Jones & Agnes Hunt Orthopaedic Hospital, Oswestry, UK, ⁴Unit of Molecular Medicine, Ospedale Bambino Gesù, Rome, Italy, ⁵Institute for Human Genetics, International Centre for Life, University of Newcastle upon Tyne, Newcastle upon Tyne, UK, ⁶Department of Paediatrics, Birmingham Heartlands Hospital, UK, ⁷Department of Neurology, King's College Hospital, London, UK, ⁸Alder Hey Children's Hospital, Liverpool, UK, ⁹Department of Neurosciences, Psychiatry and Anaesthesiology, University of Messina, Messina, Italy, ¹⁰Department of Neurology, The Royal London Hospital, London, UK, ¹¹Institute für Humangenetik, Universität Würzburg, Biozentrum am Hubland, Germany and ¹²Departments of Anaesthesia and Research, Basel University Hospital, 4031 Basel, Switzerland

*These authors contributed equally to this work.

Correspondence to: Professor Francesco Muntoni, Dubowitz Neuromuscular Centre, Imperial College, Hammersmith Hospital, Du Cane Road, London W12 0NN.

E-mail: f.muntoni@imperial.ac.uk

Dominant mutations in the skeletal muscle ryanodine receptor (*RYRI*) gene are well-recognized causes of both malignant hyperthermia susceptibility (MHS) and central core disease (CCD). More recently, recessive *RYRI* mutations have been described in few congenital myopathy patients with variable pathology, including multi-minicores. Although a clinical overlap between patients with dominant and recessive *RYRI* mutations exists, in most cases with recessive mutations the pattern of muscle weakness is remarkably different from that observed in dominant CCD.

In order to characterize the spectrum of congenital myopathies associated with *RYRI* mutations, we have investigated a cohort of 44 patients from 28 families with clinical and/or histopathological features suggestive of *RYRI* involvement. We have identified 25 *RYRI* mutations, 9 of them novel, including 12 dominant and 13 recessive mutations. With only one exception, dominant mutations were associated with a CCD phenotype, prominent cores and predominantly occurred in the *RYRI* C-terminal exons I01 and I02. In contrast, the 13 recessive *RYRI* mutations were distributed evenly along the entire *RYRI* gene and were associated with a wide range of clinicopathological phenotypes.

Protein expression studies in nine cases suggested a correlation between specific mutations, RyRI protein levels and resulting phenotype: in particular, whilst patients with dominant or recessive mutations associated with typical CCD phenotypes appeared to have normal RyRI expression, individuals with more generalized weakness, multi-minicores and external ophthalmoplegia had a pronounced depletion of the RyRI protein. The phenomenon of protein depletion was observed in some patients compound heterozygous for recessive mutations at the genomic level and silenced another allele in skeletal muscle, providing additional information on the mechanism of disease in these patients.

Our data represent the most extensive study of *RYRI*-related myopathies and indicate complex genotype-phenotype correlations associated with mutations differentially affecting assembly and function of the RyRI calcium release channel.

Keywords: skeletal muscle ryanodine receptor gene (*RYRI*); central core disease (CCD); multi-minicore disease (MmD); genotype–phenotype correlations

Abbreviations: CCD = central core disease; CNM = centronuclear myopathy; MHS = malignant hyperthermia susceptibility; MmD = multi-minicore disease; RYR1 = skeletal muscle ryanodine receptor gene; SEPNI = selenoprotein N gene

Received December 22, 2006. Revised March 23, 2007. Accepted March 28, 2007. Advance Access publication May 4, 2007

Introduction

The congenital myopathies are a heterogeneous group of inherited neuromuscular disorders characterized by the predominance of a particular histopathological feature—central cores, nemaline rods, multi-minicores and central nuclei—on muscle biopsy. Recent genetic advances concerning the most common of these myopathies—central core disease (CCD), nemaline myopathy (NM), multiminicore disease (MmD) and centronuclear myopathy (CNM)—have demonstrated genetic, phenotypic and histopathological overlap between different entities, and marked phenotypic variability (Jungbluth *et al.*, 2003).

The skeletal muscle ryanodine receptor (RYR1) gene encodes the principal sarcoplasmic reticulum (SR) Ca²⁺-release channel (RyR1) with a crucial role in excitation–contraction (E–C) coupling. RYR1 mutations have been associated with the malignant hyperthermia susceptibility (MHS) trait, an abnormal pharmacogenetic response to muscle relaxants and volatile anaesthetics, and various congenital myopathy phenotypes including CCD and specific subgroups of MmD (Quane *et al.*, 1993; Jungbluth *et al.*, 2002). More recent studies suggest that the histopathological spectrum associated with RYR1 mutations is much wider, comprising central cores, multiple cores, central nuclei, nemaline rods and marked type 1 predominance or uniformity without additional structural changes (Monnier *et al.*, 2000; Sewry *et al.*, 2002).

Typical CCD is a dominantly inherited condition with a consistent clinical phenotype characterized by hip girdle weakness with frequent orthopaedic complications, such as dislocation of the hips and scoliosis, but usually absence of significant bulbar and respiratory involvement. The disorder is named after the prominent core areas devoid of oxidative enzyme activity that may be central or peripheral and run a substantial length along the longitudinal fibre axis. In contrast, MmD is a recessively inherited condition with diverse clinical phenotypes: the most common subgroup of MmD patients is characterized by severe spinal rigidity, early scoliosis and respiratory impairment, and is associated with recessive mutations in the selenoprotein N (SEPNI) gene (Ferreiro *et al.*, 2002*b*). Other variants of MmD are associated with recessive RYR1 mutations and clinical manifestations include a distribution of weakness which may resemble CCD, or a predominantly axial myopathy with external ophthalmoplegia, or pronounced distal weakness and wasting (Jungbluth *et al.*, 2005). The pathological hallmark of MmD associated with recessive SEPNI mutations are multiple focal areas devoid of oxidative enzyme activity ('minicores'). While the clinico-pathological features associated with classical CCD

and SEPNI-related MmD are quite distinct, it has been suggested that in some families dominant RYR1-related CCD and recessive RYR1-related MmD may represent a clinico-pathologic continuum rather than separate entities (Ferreiro *et al.*, 2002*a*). In addition, some muscle samples from typical cases of CCD do not show prominent cores (Sewry *et al.*, 2002) but it is not clear if this may relate to age or sampling, as a significant feature of CCD is differential involvement of muscles.

The molecular basis of the wide phenotypic spectrum associated with dominant and recessive RYR1 mutations is slowly emerging. Dominant RYR1 mutations affecting the cytoplasmic N-terminal (MHS/CCD region 1, amino acids 35–614) and central (MHS/CCD region 2, amino acids 2163–2458) domains of the RyR1 protein give rise predominantly to the MHS phenotype, whereas the classical CCD phenotype is closely associated with dominant RYR1 C-terminal mutations (MHS/CCD region 3, amino acids 4550–4940). Whilst more than 100 dominant RYR1 mutations have been described to date (Treves *et al.*, 2005; Robinson *et al.*, 2006), only nine RYR1 mutations have been reported in association with MmD phenotypes (Ferreiro *et al.*, 2002*a*; Monnier *et al.*, 2003; Jungbluth *et al.*, 2005; Zhou *et al.*, 2006*b*; for a recent review see Zorzato *et al.*, 2007).

In order to provide further insight into the correlation between RYR1 mutations and congenital myopathies with cores, we have characterized a large cohort of patients' with clinical, histopathological and/or muscle imaging features suggestive of RYR1 involvement. Twenty-five causative RYR1 mutations have been identified in 44 patients from 28 unrelated families, including nine novel mutations. These data feature the largest cohort of recessive RYR1 mutations reported and provide new insight into the complex genotype–phenotype correlations associated with mutations affecting the RyR1 protein.

Patients and methods

Patient selection

Patients were selected on the basis of clinical presentation, muscle histopathological features and, when available, muscle imaging findings. Inclusion criteria for the study were (i) clinical features of a congenital myopathy, (ii) histopathological features suggestive of RYR1 involvement, in particular central cores, multiple cores or significant unevenness of stain with techniques for oxidative enzyme or (iii) other histopathological features suggestive of RYR1 involvement such as type 1 predominance or uniformity, or increased central nuclei; cases with the latter histopathological findings but no central or multiple cores on muscle biopsy were only included if clinical findings and features on muscle MRI were suggestive of RYR1 involvement as previously reported (Jungbluth *et al.*, 2004). Mutations in

genes involved in conditions with similar clinico-pathological features, in particular the *SEPN1* gene (Ferreiro *et al.*, 2002b), were excluded whenever appropriate.

Histopathological studies

Histopathological studies were performed on all patients where skeletal muscle biopsies were available. Muscle biopsies were obtained from the quadriceps. Cryostat sections were stained with haematoxylin and eosin (H&E), periodic acid Schiff (PAS), nicotinamide dehydrogenase tetrazolium reductase (NADH-TR), succinate dehydrogenase (SDH) and cytochrome oxidase (COX), according to standard procedures (Dubowitz and Sewry, 2007). Fibre typing was assessed by immunolabelling of fast and slow myosin heavy chain isoforms.

Muscle magnetic resonance imaging

Muscle MRI images were obtained from the thigh and lower legs; all patients were fully cooperative and no sedation or general anaesthesia was required for the MRI examination. Muscle MRI was performed using conventional T1 weighted spin echos (TR = 500 ms, TE = 20 ms) on a 1.0-Tesla HPQ system (Marconi Medical Systems, Cleveland, OH). Non-contrast enhanced images were obtained from pelvis and thighs and calves. The axial plane was selected with respect to the long axis of the body. This involved two sequential scans. We obtained 15 slices from each site. Slices were 5 mm thick and the gap between slices varied from 10 to 50 mm depending on the site and on the size of the patient. Scanning time averaged 20 min for each patient.

Genetic studies

Total RNA was extracted from patients' frozen skeletal muscle tissue, and complementary DNA was synthesized by using SuperScript III first strand synthesis system kit (Invitrogen). The entire coding sequence was amplified by 27 overlapping fragments followed by the direct sequencing in both directions. Genomic DNA was extracted from peripheral blood lymphocytes following the manufacturer's instructions (Nucleon). The C-terminal *RYR1* mutational hot spot (Davis *et al.*, 2003) including exon 95 to exon103 were screened by PCR and direct sequencing by using genomic DNA as template. For patients who had no mutations in the C-terminal hot spot and from whom muscle cDNA was not available, we also studied exons 1, 4, 12, 14, 33, 39, 44, 45, 46, 47, 48, 49, 50, 51, 52, 53, 57, 68, 73, 79, 90, 91 and 92 using genomic DNA as a template. Once a sequence change was identified, a panel of >200 chromosomes from the normal control population were screened to establish whether the variant detected was likely to be a polymorphism or a pathogenic mutation.

Western blotting

Skeletal muscle proteins from nine patients were extracted in sample buffer consisting of 75 mM Tris-HCl, 1% SDS, plus a cocktail of protease inhibitors (antipain, aprotinin and leupeptin). Twenty micrograms of protein was resolved using a NuPAGE Pre-cast gel (3–8% Tris-acetate, Invitrogen) and then transferred electrophoretically to a nitrocellulose membrane (Hybond-ECL, Amersham). The nitrocellulose membrane was blocked in 10% semi-skimmed milk in Tris-buffered saline buffer and then probed with mouse anti-RyR1 monoclonal antibody (Abcam) (1 : 2500) and mouse anti-desmin monoclonal antibody (DAKO) (1 : 1000)

at room temperature for 1 h. After washing, the membrane was incubated with peroxidase-conjugated donkey anti-mouse IgG (Jackson) (1 : 50 000) for 1 h at room temperature and visualized using chemiluminescence (ECL+ Plus, Amersham).

Results

Clinical features

There was marked variability in distribution and severity of weakness and associated clinical findings. The largest group of patients demonstrated clinical findings previously associated with typical central core disease, comprising proximal weakness affecting predominantly the hip girdle, mild facial weakness, with sparing of extraocular muscles and absence of significant respiratory or bulbar involvement. Scoliosis and congenital dislocation of the hips were frequent complications. The second largest group of patients featured more generalized muscle weakness and wasting and associated extraocular muscle involvement; bulbar involvement was also pronounced in this group and two patients required gastrostomy insertion. Respiratory involvement was more pronounced compared to patients with features of classical CCD but none required nocturnal ventilation. The third group comprised three severely affected neonates from three families. In all three groups, CK was normal or only mildly elevated. A total of four patients suffered malignant hyperthermia reactions. The main clinical features are summarized in Table 1.

Muscle MR imaging

Muscle MR imaging of the thigh and the lower leg was performed in 13 patients, and the characteristic MR images are shown in Figure 1.

In nine patients with typical clinical features of CCD and dominant *RYR1* mutations, there was a consistent pattern of selective muscle involvement characterized by relative sparing of rectus femoris, gracilis and adductor longus within the thigh (Figure 1A and B), and sparing of the tibialis anterior and gastrocnemii within the lower leg but increased signal within the vasti, adductor magnus and soleus (Jungbluth *et al.*, 2004). In four patients with more generalized weakness and wasting, extraocular muscle involvement and recessive *RYR1* mutations, there was diffuse involvement of the thigh and lower-leg muscles, with some residual selectivity corresponding to that observed in the first group (Figure 1C); the latter pattern was also observed in one single case with features of centronuclear myopathy (Figure 1D).

Histopathological features

The main pathological features related to the size of the areas devoid of oxidative enzyme activity (cores), alterations in fibre type proportions and the presence of central and/or internal nuclei. Most cases with dominant mutations had large cores that were central or peripheral. They were

usually single in cross section but occasionally more than one per fibre was seen. In one family (case 14), clear cores were not a feature on oxidative stains in either the mother (who had two muscle biopsies 30 years apart) or in her child; however, cores were apparent with electron microscopy in the mother. In the majority of cases, irrespective of the type of mutation, fibre typing was indistinct or uniform with oxidative enzymes. Myosin immunolabelling showed that most fibres expressed slow myosin, with a few co-expressing fast myosin. In the recessive cases, oxidative activity showed unevenness of stain or multiple small areas devoid of activity (minicores). Internal nuclei, some of which were central were increased in 19 cases. In one severely affected case (case 16), the pathological features resembled centronuclear myopathy with abundant central nuclei and central NADH-TR activity; cores were not apparent in the first biopsy taken at 1 year of age but were apparent in a sample from a different muscle taken at age 9 years (Jungbluth *et al.*, 2007). In one severely affected neonate (case 1), connective tissue and fat were pronounced. The pathological features observed in this cohort of patients are summarized in Table 1.

Genetic studies

Mutation screening

Twenty-five different nucleotide variations were identified in 44 patients from 28 unrelated families, including 22 exonic missense mutations, two splice-site mutations and one genomic in frame deletion (Table 1). Sequence comparison across different RyR isoforms and throughout different species suggested that the changes identified were significant as they affected evolutionary conserved domains (Table 2). All novel variations were also excluded from >200 control chromosomes by either specific restriction enzyme digestion or direct sequencing.

Twelve mutations were dominant heterozygous (Figure 2). Eight of them had arisen *de novo*, in keeping with the sporadic occurrence of the condition, and four variations were inherited from the affected parents, three of them paternally transmitted and one of them maternally transmitted.

Thirteen substitutions were recessive (Figure 2), consisting of four compound heterozygous, three homozygous and six monoallelically expressed mutations which exerted their pathogenicity only in association with non-transcription of another allele (see later).

The four compound heterozygous substitutions identified in two unrelated patients were inherited from both clinically asymptomatic parents. No muscle samples were available for histological studies from the parents of these two patients. Two of the three homozygous missense mutations were identified in consanguineous families, except for p.R2435L, which was found in a non-consanguineous family originating from the same village in Italy.

In six families, we were able to demonstrate silencing of one allele associated with inheritance of a missense mutation on the other allele, as recently reported (Zhou *et al.*, 2006a). In these patients the observed sequence change was clearly heterozygous in genomic DNA from patients but transcription analysis using skeletal muscle derived cDNA showed monoallelic expression, and the only allele which was transcribed was the mutant one (Zhou *et al.*, 2006a). Segregation analysis studies in informative families demonstrated that the mutant allele was inherited from an asymptomatic father whilst the non-transcribed allele was of maternal origin, suggesting the possibility of epigenetic silencing of the *RYR1* gene in these cases (Zhou *et al.*, 2006a).

Characterization of novel *RYR1* mutations

Nine of the *RYR1* mutations were novel, including four dominant and five recessive changes, while 16 have been reported previously (Table 1).

Four novel dominant mutations comprised of p.S4112L in exon 90; p.L4665P in exon 95; p.R4825P in exon100; and an alternative splice-site mutation c.14667C>G in exon102. The *de novo* p.S4112L mutation was identified in a patient in whom the main histopathological features on initial muscle biopsy were those of centronuclear myopathy (Jungbluth *et al.*, 2007). p.L4665P was identified in a neonate with a severe CCD variant. This *de novo* mutation resulted from the variation of two consecutive nucleotides at residues c.13994T>C and c.13995C>T, a unique change probably caused by two nucleotides inversion which has never been reported before and not found in the parents or in >200 control chromosomes. The p.R4825P change associated with typical CCD is a novel mutation; however, substitution of the arginine residue at position p.R4825 by another amino acid has been previously reported in another CCD family (Monnier *et al.*, 2001). The substitution c.14667C>G was predicted at the genomic level to cause a stop codon, yet RNA studies showed the creation of an alternative splice site in exon 102 resulting in the deletion of the first 21 base pairs of the exon (r.14647_14667del), corresponding to the in-frame amino acid deletion p.C4883_Y4889del. The deleted seven amino acids are located in the pore region of the calcium ion release channel of RyR1 protein. The affected mother carried the same change as the proband, indicating dominant inheritance.

Five novel recessive mutations included one homozygous recessive (p.R3772Q), and four heterozygous missense mutations in combination with monoallelic expression in muscle (p.M402T, p.R2939K, p.A4329D and p.T4709M). The variants p.S71Y in exon 3, recently identified in a MH pedigree (Galli *et al.*, 2006), and p.N2283H in exon 42, occurring in MHS domain 1 and 2, respectively, were identified in a patient with a myopathy and central cores and had been inherited from the asymptomatic parents.

Table 1 Summary of pathological and clinical features and mutations details of patients with *RYR1* mutations

Case [▲]	Affected members	RYR1 mutations			Specific comments	Clinical features						Pathological features			references	
		Exon	Nt change	AA change		MW	Sc	Oph	FD	RI	MH	C	FTU	IN		
AD	1	1	95	c.I3994T>C	p.L4665P	De novo heterozygous	G	–	–	+	+	+	+++	+	+	This study
	2	2	95	c.I3995C>T c.I3913G>A	p.G4638D	Familial heterozygous	F	+	–	–	–	+	+++	+	+	Davis et al. (2003)
	3	1	100	c.I4474G>C	p.R4825P	De novo heterozygous	P	–	–	–	–	–	NA	NA	NA	This study
	4	1	101	c.I4582G>A	p.R4861H	De novo heterozygous	G, F	–	–	–	–	–	+	+	+	Davis et al. (2003)
	5	1	101	c.I4582G>A	p.R4861H	Familial heterozygous	D	–	–	–	–	–	+++	+	+	This study
	6	1	101	c.I4581C>T	p.R4861C	De novo heterozygous	P	–	–	–	–	–	+++	+	–	Davis et al. (2003)
	7	1	101	c.I4581C>T	p.R4861C	De novo heterozygous	P	+	–	–	–	–	+++	+	–	Davis et al. (2003)
	8	1	101	c.I4581C>T	p.R4861C	De novo heterozygous	P	–	–	–	–	–	+++	+	–	Davis et al. (2003)
	9	1	101	c.I4581C>T	p.R4861C	De novo heterozygous	G	+	–	–	–	–	+++	+	+	Davis et al. (2003)
	10	2	101	c.I4588.I4606 del18	p.F4863.D4869 delinsT	De novo heterozygous	P	+	–	–	–	–	+++	+	+	Zorzato et al. (2003)
	11	3	102	c.I4678G>A	p.R4893Q	Familial heterozygous	P	–	–	–	–	–	+++	+	+	Davis et al. (2003)
	12	3	102	c.I4741G>C	p.R4914T	De novo heterozygous	P	–	–	–	–	–	+	–	–	Davis et al. (2003)
	13	1	102	c.I4740A>G	p.R4914Q	De novo heterozygous	P	+	–	–	–	–	+++	+	–	Davis et al. (2003)

	14	2	102	c.14667C>G	p.C4883X [#]	Familial heterozygous	P, F	-	-	-	-	-	+	+	+	This study
	15	1	47	c.7523G>A	p.R2508H	De novo heterozygous	D	+	-	-	-	+	+	+	-	Wu <i>et al.</i> (2006)
	16	1	90	c.12335C>T	p.S4112L	De novo heterozygous	P	+	+	+	+	-	+++*	+*	+++	Jungbluth <i>et al.</i> (2007)
AR	17	1	3	c.212C>A	p.S71Y	Compound heterozygous	P	+	-	-	-	-	+++	+	-	Zhou <i>et al.</i> (2006b)
	18	1	42	c.6847A>C	p.N2283H	Compound heterozygous	P	+	-	-	-	-	++	+	+	This study
	19	2	45	c.7304G>T	p.R2435L	Compound heterozygous	P, F	-	+	-	-	-	+++	+	+++	Jungbluth <i>et al.</i> (2005)
			68	c.10343C>T	p.S3448F	Compound heterozygous	P, F	-	+	-	-	-	+++	+	+++	Jungbluth <i>et al.</i> (2005)
			100	c.14365-2 A>T	acceptor splice site ^δ	in frame										
	20	1	101	c.14545G>A	p.V4849I	Homozygous [§]	P	+	-	-	-	-	+	+	+	Jungbluth <i>et al.</i> (2002)
	21	5	79	c.11315G>A	p.R3772Q	Homozygous [§]	P, F	-	-	+	-	-	+	+	++	This study
	22	1	79	c.11315G>A	p.R3772Q	Homozygous [§]	P	-	-	-	-	+	++	+	+	This study
	23	2	4	c.325C>T	p.R109W	Monoallelic	G, F	-	+	+	+	-	++	+	+	Zhou <i>et al.</i> (2006b)
	24	1	12	c.1205T>C	p.M402T	Monoallelic	P	-	-	-	-	-	+	+	-	This study
	25	4	45	c.7268T>A	p.M2423K	Monoallelic	G, F	-	+	-	-	-	++	+	+	Jungbluth <i>et al.</i> (2005)
	26	1	96	c.14126C>T	p.T4709M	Monoallelic	F, P	+	+	-	+	-	++	+	+	This study
	27	1	57	c.8816G>A	p.R2939K	Monoallelic	G, F	-	+	-	-	-	+	+	+++	This study
	28	1	91	c.12986C>A	p.A4329D	Monoallelic	G	-	-	+	+	-	+++	+	+++	This study

[▲]The data presented here are from the proband of each family. ^δAt the RNA level the altered acceptor splice site was found to cause the deletion of first 102 nucleotides of exon 100.

[§]Consanguineous. [#]Predicted to create a stop codon although at the RNA level an alternative splice site was created. *Initial biopsy resembled centronuclear myopathy; cores were only identified on 2nd biopsy (Jungbluth *et al.*, 2007).

Abbreviations: AD = autosomal dominant; AR = autosomal recessive; Nt = nucleotide; AA = amino acid; MW = muscle weakness; G = generalized weakness; P = predominant proximal weakness; F = marked facial weakness; D = predominant distal weakness; Sc = scoliosis; Oph = ophthalmoplegia; FD = marked feeding difficulties; RI = respiratory impairment; MH = malignant hyperthermia.

C = cores; + = unevenness of stain; ++ = multiple cores; +++ = central cores; FTU = fibre type uniformity or type I predominance; IN = increased internal or centrally located nuclei. NA: Histopathological slides are not available to be viewed.

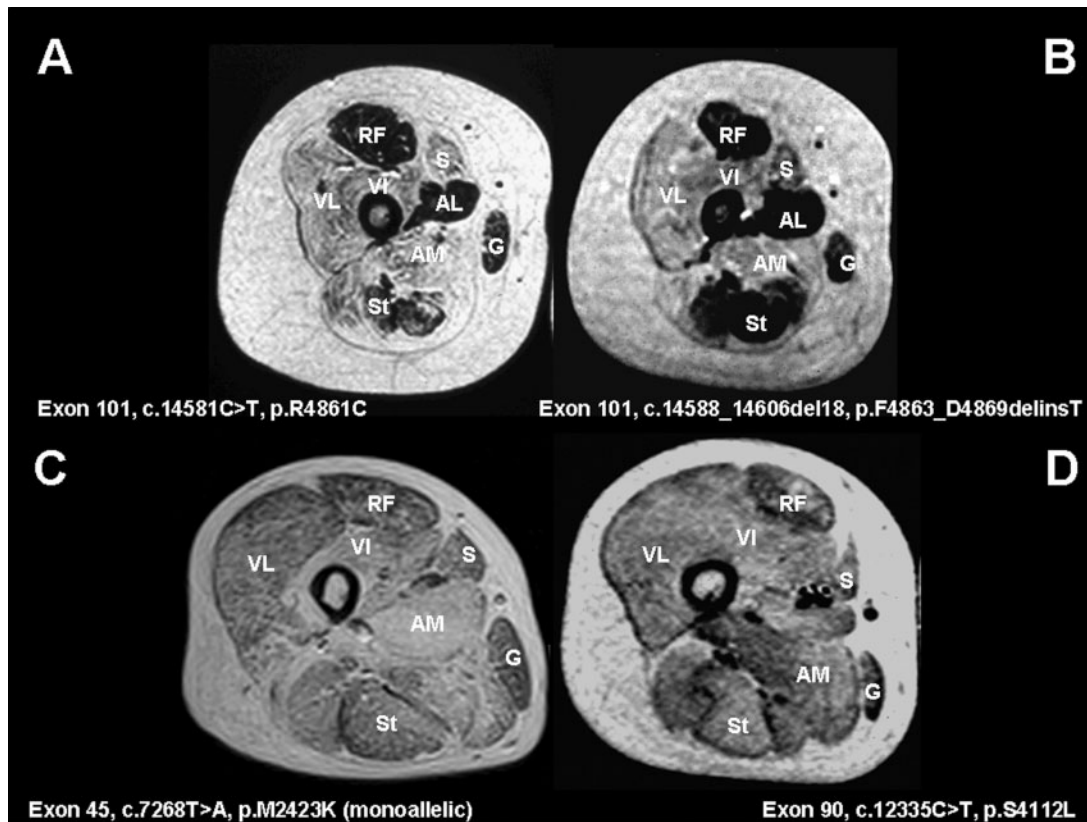


Fig. 1 Muscle MRI in *RYR1*-related congenital myopathies. T1-weighted MR images, transverse sections through the proximal thigh in an 11-year old boy (**A**) (case 6) and a 12-year old girl (**B**) (case 10) with central core disease (CCD), a 41-year old male with multi-minicore disease (MmD) and external ophthalmoplegia (**C**) (case 25) and a 9-year old girl with centronuclear myopathy (CNM) and external ophthalmoplegia (**D**) (case 16). In patients with typical CCD due to heterozygous dominant mutations affecting C-terminal exons 100–102 (**A–B**), there is a consistent pattern of selective muscle involvement characterized by marked increase in abnormal signal within vasti (VL, VI), sartorius (S) and adductor magnus (AM) and relative sparing of rectus femoris (RF), adductor longus (AL), gracilis (G) and semitendinosus (St). In patients with MmD and external ophthalmoplegia due to recessive *RYR1* mutations (**C**) and CNM and external ophthalmoplegia due to a heterozygous dominant *RYR1* mutation (**D**), there is more diffuse involvement (corresponding to more generalized weakness and wasting on clinical examination) but persistent relative sparing of the rectus femoris (RF) compared to the vastus intermedius (VI) and the gracilis (G) compared to the sartorius (S).

Table 2 Amino acid sequence alignment of ryanodine receptor I (RyR1) in mammals and other human RyR isoforms, RyR2 and RyR3

Amino acid position	71	109	402*	2283	2423	2435	2508	2939	3448	3772	4112	4329	4638	4665	4709	4825	4849	4861	4893	4914
Substitutions	Y	W	T	H	K	L	H	K	F	Q	L	D	D	P	M	P	I	C/H	Q	T/Q
Human RyR1	S	R	M	N	M	R	R	R	S	R	S	A	G	L	T	R	V	R	R	R
Pig RyR1	S	R	M	N	M	R	R	R	S	R	S	A	G	L	T	R	V	R	R	R
Rabbit RyR1	S	R	M	N	M	R	R	R	S	R	S	A	G	L	T	R	V	R	R	R
Mouse RyR1	S	R	M	N	M	R	R	R	S	R	S	A	G	L	T	R	V	R	R	R
Chicken RyR1	S	R	M	N	M	R	R	R	S	R	S	A	G	L	T	R	V	R	R	R
Frog RyR1	S	R	M	N	M	R	R	R	S	R	S	A	G	L	T	R	V	R	R	R
Human RyR2	S	R	V	N	M	R	R	R	S	R	S	A	G	L	T	R	V	R	R	R
Human RyR3	S	R	I	N	M	R	R	R	S	R	S	A	G	L	T	R	V	R	R	R

*The residue is conserved among mammals in RyR1 but not in human RyR2 and RyR3.

The homozygous p.R3772Q mutation affects a well-conserved arginine residue in two consanguineous families where all affected members have multiple cores. The mutations p.M402T, p.R2939K, p.A4329D and p.T4709M

were monoallelically transcribed in skeletal muscle. Whilst substitutions p.R2939K, p.A4329D and p.T4709M all affect highly conserved residues, the methionine residue at position p.M402 affected by the p.M402T mutation is

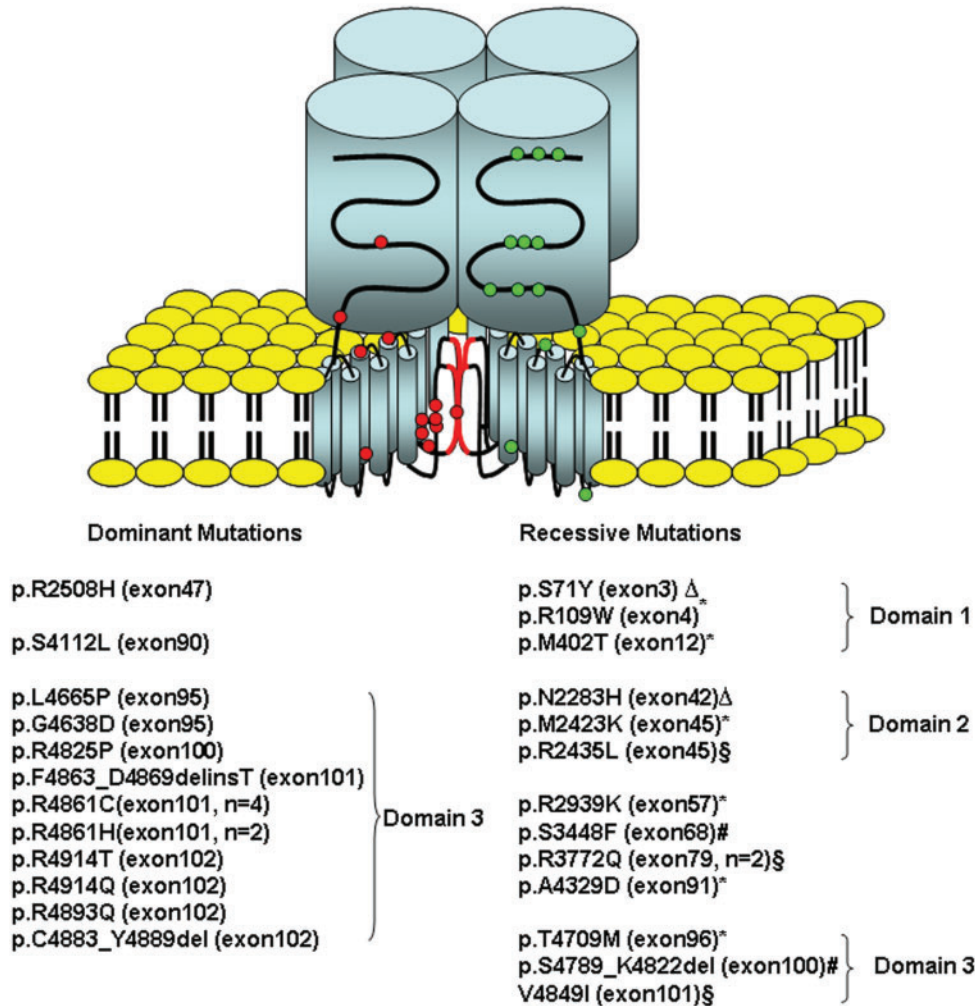


Fig. 2 Schematic representation of the skeletal muscle ryanodine receptor tetramer taken from Treves *et al.*, 2005, with permission showing the position of the dominant and recessive *RYR1* mutations identified in the patients presented in this report. Dominant and recessive mutations are shown with circles in red and green, respectively. All dominant mutations, except mutations p.R2508H and p.R4112L which were associated with atypical myopathy with MH and CNM, are located in domain 3. Recessive mutations are distributed evenly throughout the gene. Monoallelically expressed mutations are marked by an asterisk; two pairs of compound heterozygous mutations are indicated by symbols Δ and #, respectively; homozygous recessive mutations were labelled with symbol \S .

conserved across species only in RyR1 but not in RyR2 and RyR3 isoforms (Table 2); however, two nearby residues p.R401 and p.I403 have been implicated in MHS/CCD (Quane *et al.*, 1993; Galli *et al.*, 2002; Monnier *et al.*, 2005) indicating the significance of this region in the pathogenesis of those conditions.

Recurrent *RYR1* mutations and associated phenotype

p.R4861 is the residue most commonly mutated in core myopathy patients. In our study, four CCD patients carried a c.14581C>T (p.R4861C) transition and two patients harboured a c.14582G>A (p.R4861H) change. Substitutions at R4861 were also reported to be common in a cohort of Japanese patients with central cores on muscle biopsy, where they also had occurred *de novo* (Wu *et al.*, 2006).

The p.R2508H substitution, reported at high frequency in the Japanese population, was also found in one of our patients with a MHS history, scoliosis and progressive muscle weakness but no visible cores on muscle biopsy (case 15).

We identified a homozygous p.R2435L change in an Italian CCD patient (case 18); this mutation has been previously reported as a dominant mutation in an Italian MH family (Barone *et al.*, 1999), while another heterozygous substitution of the same residue (p.R2435H) has been reported in a large Canadian pedigree with MHS and variable expression of clinical myopathic features (Shuaib *et al.*, 1987; Zhang *et al.*, 1993). In our study, we found that the mutation p.R2435L caused a typical congenital core myopathy only when inherited at the homozygous state, while the heterozygous carrier parents were clinically asymptomatic.

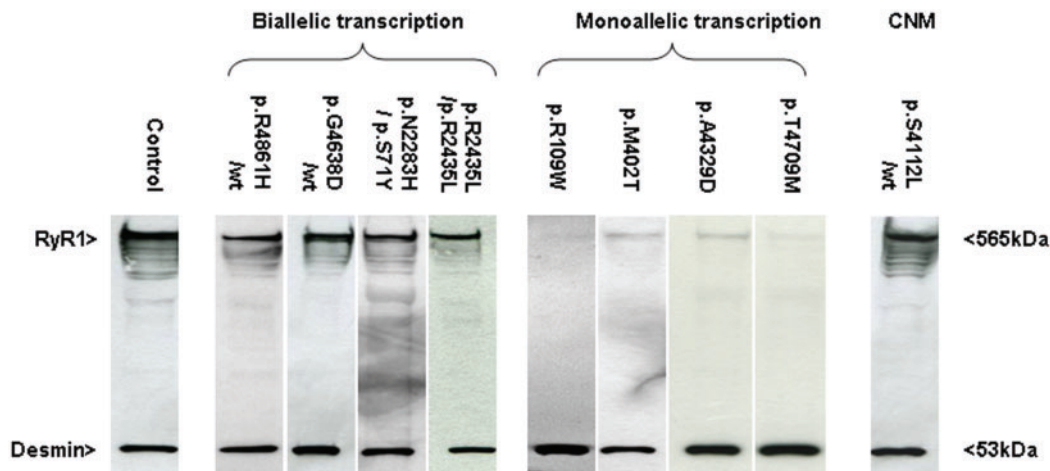


Fig. 3 The effect of *RYR1* mutations on protein expression. Western blot analysis of skeletal muscle biopsies from patients described in this study. Patients carrying mutations p.R4861H (heterozygous), p.G4638D (heterozygous), p.S71Y+p.N2283H (compound heterozygous) and p.R2435L (homozygous) with normal biallelic transcription showed normal levels of RyR1 expression as compared to control muscle. In contrast patients carrying mutations p.R109W, p.M402T, p.A4329D and p.T4709M with monoallelic transcription had dramatically decreased levels of RyR1. The patient with CNM carrying mutation p.S4112L (heterozygous) showed normal level of expression of RyR1. Desmin immunoreactivity was used as a muscle-specific loading control.

The homozygous p.R3772Q mutation has been identified in two unrelated consanguineous families from North Africa and Asia, respectively. One patient developed a MH reaction during an orthopaedic operation for bilateral clubfeet (case 22). Another highly consanguineous family where both parents and all offspring (case 21) were homozygous for the same change showed features of a moderate congenital myopathy but had not developed any MH reaction.

Skeletal muscle RyR1 protein expression in patients with *RYR1* mutations

Investigation of the consequences of individual mutations on the expression of the RyR1 protein clearly showed a differential effect on the level of protein present in skeletal muscle. In particular in three patients with dominant *RYR1* mutations (two with classical CCD phenotype carrying p.G4638D and p.R4861H, one carrying p.S4112L associated with a centronuclear myopathy phenotype), in one patient with compound heterozygous MH changes (p.S71Y+p.N2283H) and one patient with homozygous MH/CCD change (p.R2435L), RyR1 protein levels were similar to control (Figure 3). In contrast, in four patients carrying recessive mutations (p.R109W, p.M402T, p.A4329D and p.T4709M) associated with monoallelic transcription of RyR1 protein levels as determined by western blot analysis (Figure 3).

Discussion

We report 12 dominant and 13 recessive *RYR1* mutations in a cohort of 44 congenital myopathy patients from

28 families, representing the largest series of recessive *RYR1* mutations reported to date. Our findings suggest potential molecular mechanisms implicated in the marked phenotypic variability associated with dominant and recessive *RYR1* mutations.

Dominant *RYR1* mutations

These were mainly found in the C-terminal and only in one case in the central domain of the *RYR1* gene. In more than 80% of cases dominant *RYR1* mutations involved exons 100 to 102 of the *RYR1* coding sequence. Our findings lend support to the idea that the C-terminal is a mutational hotspot for CCD and suggest that focusing on *RYR1* exons 100 to 102 could be a highly efficient screening strategy in patients with typical features. In contrast to other recent mutational studies on CCD (Wu *et al.*, 2006), we identified only one single dominant mutation outside the C-terminal hotspot (Exon 47, c.7523G>A, p.R2508H); this discrepancy is likely to reflect different inclusion criteria between the two studies, as our cohort only included patients with a congenital myopathy phenotype, while the presence of central or multiple cores on muscle biopsy without any associated muscle weakness, a criterion used in the recent study from Wu *et al.* (2006), was considered insufficient for inclusion.

Most CCD-related dominant *RYR1* mutations resulted in the substitution of a charged polar residue, typically arginine, with an uncharged polar residue. When mapped to the transmembrane topology of the RyR1 protein (Du *et al.*, 2002, 2004), most dominant CCD-related *RYR1* mutations localize to the M8/M10 loop surrounding the pore helix region, demonstrating the unique role of this part of the protein in the pathogenesis of CCD; another

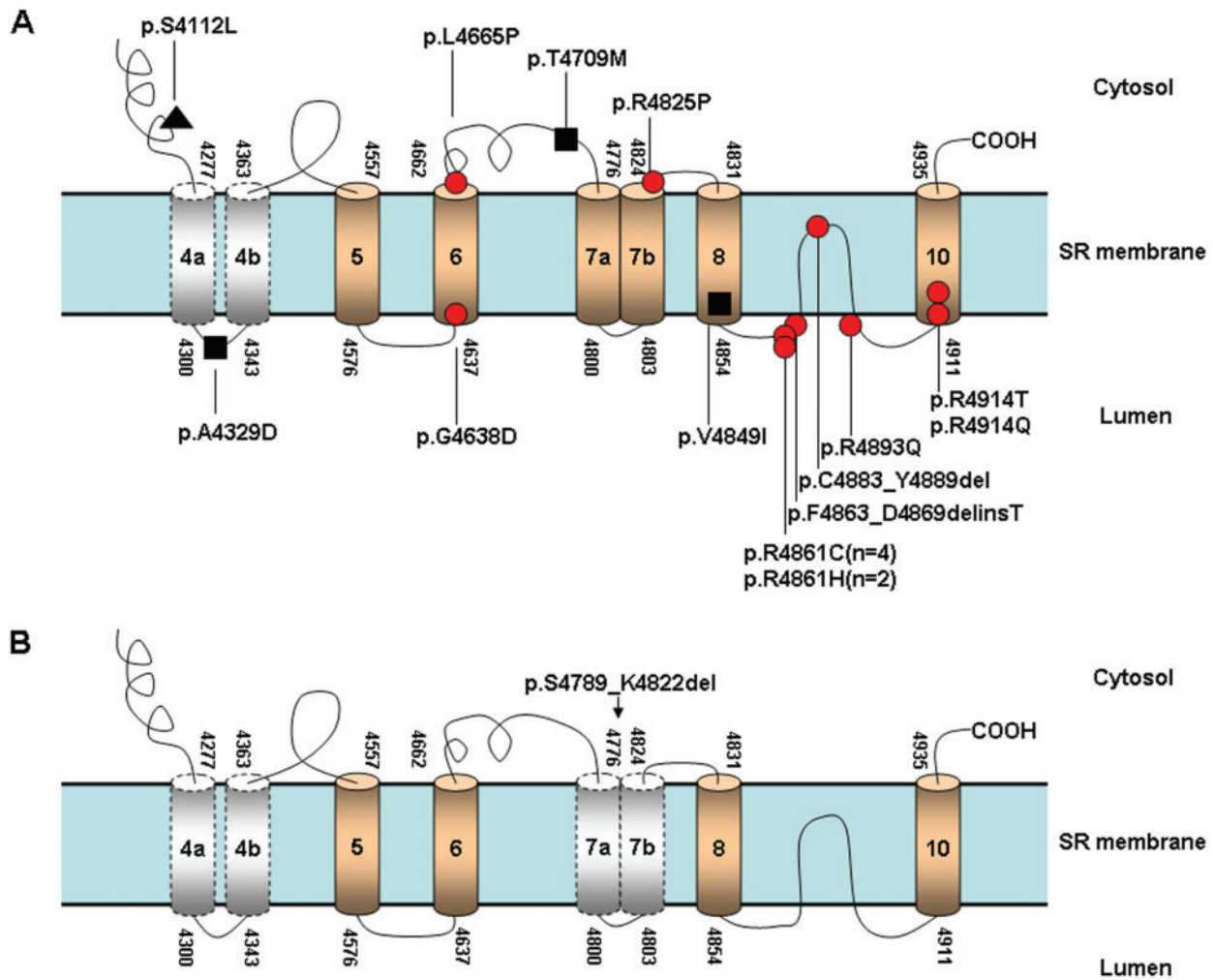


Fig. 4 Schematic diagram showing the distribution of mutations associated with congenital myopathies in the C-terminal region of *RYR1*. **(A)** Closed circles signify mutations which are dominant and are associated with the CCD phenotype ●; closed squares signify mutations which are recessive and associated with the MmD phenotype ■ and the closed triangle signifies the mutation associated with the CNM phenotype ▲. **(B)** A 34-amino-acid deletion p.S4789.K4822del, affecting most of the transmembrane segments M7a and M7b, did not cause any phenotype when expressed in the heterozygous state. The schematic diagram is based on the proposed model of Du's (Du *et al.*, 2002).

two dominant CCD mutations localized in or close to M6, implying the potential importance of this transmembrane domain for proper channel function and stability (Figure 4A).

Most patients with dominant C-terminal mutations had the classical CCD phenotype, characterized by variable degrees of proximal weakness pronounced in the hip girdle and absence of significant bulbar, respiratory or extraocular involvement; orthopaedic complications, namely congenital dislocation of the hips and scoliosis, were common features. In this group of patients, muscle MRI showed a highly consistent pattern of selective muscle involvement; this was even more reproducible than the associated histopathological changes. Interestingly, some patients carrying the same amino acid substitution showed marked variation in age of onset and severity, suggesting either a non-stochastic distribution of mutant and wild-type

RyR1 proteins or other modifying genetic factors. Although most patients had typical central cores on muscle biopsy, in one family harbouring a seven amino acid deletion (p. C4883_Y4889del), clear cores were not present at the light microscopy level, although they could be seen on electron microscopy performed on the second muscle biopsy from the affected mother 30 years after the first, non-diagnostic biopsy. The profound muscle weakness present in this family confirms the lack of direct correlation between muscle weakness and the propensity to develop cores in *RYR1*-related myopathies.

Two cases harbouring C-terminal mutations presented with unusual clinical and/or histopathological features: one infant who had a unique nucleotide inversion (c.13994T>C, c.13995C>T) in exon 95, resulting in a p.L4665P substitution, presented with an unusually severe neonatal phenotype and marked increase in connective tissue, leading to

an initial suspicion of congenital muscular dystrophy; this patient also had a severe MH reaction when the muscle biopsy was taken. Another patient with a heterozygous missense mutation in exon 90 (p.S4112L) had a phenotype suggestive of centronuclear myopathy with more severe muscle involvement and external ophthalmoplegia (Jungbluth *et al.*, 2007). In contrast to CCD-related mutations, this change does not localize to the RyR1 channel pore but to a previously identified calmodulin-like binding site (Xiong *et al.*, 2006). In contrast to recessive *RYR1* mutations associated with a similar clinical phenotype including external ophthalmoplegia (see later), the dominant p.S4112L substitution did not affect the amount of protein present in the muscle, as indicated by western blot analysis; this may indicate an alternative pathogenic mechanism, for example disturbed protein–protein interactions, with similar functional consequences despite normal protein quantity.

Recessive *RYR1* mutations

In contrast to dominant *RYR1* mutations, recessive *RYR1* mutations were evenly distributed throughout different domains. Clinical manifestations associated with recessive *RYR1* mutations were variable, ranging from a typical CCD phenotype to generalized muscle weakness and wasting with associated external ophthalmoplegia, variable degrees of bulbar involvement and respiratory impairment.

Recessive RYR1 mutations previously associated with MHS

A typical CCD phenotype was found in two families carrying apparently recessive *RYR1* missense mutations affecting the N-terminal (MHS/CCD region 1, p.S71Y) and central (MHS/CCD region 2, p.N2283H and p.R2435L) domains of the protein; these mutations were previously associated with dominantly inherited MHS phenotypes; recently performed functional studies indicate that the MHS phenotype was due to the p.N2283H mutation (Zhou *et al.*, 2006b). Interestingly, the fact that dominant MHS-associated *RYR1* mutations may give rise to a congenital myopathy phenotype in the compound heterozygous or homozygous state is novel and suggests a combined deleterious effect on the tetrameric RyR1 protein. The hypothesis of a cooperative effect is further supported by the previous finding of a more severe IVCT response in individuals homozygous for MHS-related *RYR1* mutations (Lynch *et al.*, 1997), and the observation of a congenital myopathy phenotype in the offspring of parents both presenting with genetically unresolved MH (Deufel *et al.*, 1992).

Recessive RYR1 mutations with monoallelic expression and protein depletion

Our data support and extend our recent observation that different mutations affect the amount of mutant RyR1

proteins present in skeletal muscle (Zhou *et al.*, 2006b). Whilst the amount of expressed RyR1 protein was normal in patients with a typical CCD phenotype associated with both recessive and dominant *RYR1* missense mutations, we found a marked reduction of RyR protein in muscle biopsies from patients with more severe clinical phenotypes including generalized muscle weakness and wasting and external ophthalmoplegia. The more diffuse involvement in these patients was also apparent on muscle MRI which showed only remnants of the pattern of selectivity characteristic of CCD patients. In these patients a heterozygous *RYR1* missense mutation was expressed on the background of a second non-transcribed allele, confirming *RYR1* epigenetic silencing as an important aetiological mechanism in *RYR1*-related congenital myopathies (Zhou *et al.*, 2006a).

While some of the recessive *RYR1* missense mutations identified were expected to result in severe disruption of the RyR1 protein structure, these did not cause a clinical phenotype in the heterozygous state, suggesting either that the domains concerned are not crucial to the formation of a functional RyR1 channel, or that only a small amount of functional RyR1 is required to maintain a normal phenotype. For example, the heterozygous carrier state of the intron99 splice-site mutation (c.14365-2A>T) leading to a 34-amino-acid deletion p.S4789_K4822del did not cause any clinical phenotype in the patient's asymptomatic father, despite affecting most of the transmembrane segments M7a and M7b (Figure 4B); this corresponds to observations in one consanguineous family reported previously where homozygosity for an intronic *RYR1* splice-site mutation caused marked protein depletion and a severe phenotype with external ophthalmoplegia in the proband but no symptoms in the carrier parents (Monnier *et al.*, 2003).

Functional effects of *RYR1* mutations

Functional consequences of individual *RYR1* mutations at the cellular level are currently only partially understood, and five of the mutations reported in this paper (p.F4863_D4869delinsT, p.V4849I, p.R109W and p.S71Y+p.N2283H) have been previously studied *in vitro* (Zorzato *et al.*, 2003; Ducreux *et al.*, 2006; Zhou *et al.*, 2006b). Whilst it is widely accepted that dominant *RYR1* mutations causing MH increase the sensitivity of the RyR1 protein to activation and dominant CCD-mutations are associated with a reduction of stimulated calcium release, the scarce data available on recessive *RYR1* mutations and those associated with allele silencing suggest the possibility of altogether different pathogenic mechanisms. In contrast to the heterozygous dominant p.F4863_D4869delinsT mutation implicated in a typical CCD phenotype and associated with reduction of sarcoplasmic reticulum calcium stores ('leaky' channel) commonly seen in this phenotype, the homozygous recessive p.V4849I substitution did not exhibit any differences in stimulated or

spontaneous calcium release. The recombinant channels with compound heterozygous p.S71Y+p.N2283H substitutions lost activity upon isolation, whilst the p.R109W substitution expressed in the homozygous state leads to complete loss of calcium conductance (Zhou *et al.*, 2006b). These findings in conjunction with the observation of reduced RyR1 protein levels suggest that some recessive RYR1 mutations may affect protein assembly or protein stability in a manner not detectable in commonly applied *in vitro* models, and that the quantitative lack of functional RyR1 protein causes phenotypes more severe than those associated with simple RyR1 malfunction. Future functional studies on the emerging spectrum of RYR1 mutations will further clarify interactions and function of this complex protein assembly, while protein studies might provide an additional tool to investigate patients with recessive RYR1 mutations.

Acknowledgements

The initial part of this work was supported by a grant from the Muscular Dystrophy Campaign to FM, HJ and CAS. The authors also wish to thank the National Specialist Commissioning Advisory Group (NSCAG) support to the Hammersmith Hospital Neuromuscular Centre for rare congenital myopathies and muscular dystrophies.

References

- Barone V, Massa O, Intravaia E, Bracco A, Di Martino A, Tegazzin V, et al. Mutation screening of the RYR1 gene and identification of two novel mutations in Italian malignant hyperthermia families. *J Med Genet* 1999; 36: 115–8.
- Davis MR, Haan E, Jungbluth H, Sewry C, North K, Muntoni F, et al. Principal mutation hotspot for central core disease and related myopathies in the C-terminal transmembrane region of the RYR1 gene. *Neuromuscul Disord* 2003; 13: 151–7.
- Deufel T, Muller-Felber W, Pongratz DE, Hubner G, Johnson K, Iaizzo PA, et al. Chronic myopathy in a patient suspected of carrying two malignant hyperthermia susceptibility (MHS) mutations. *Neuromuscul Disord* 1992; 2: 389–96.
- Du GG, Avila G, Sharma P, Khanna VK, Dirksen RT, MacLennan DH. Role of the sequence surrounding predicted transmembrane helix M4 in membrane association and function of the Ca²⁺ release channel of skeletal muscle sarcoplasmic reticulum (ryanodine receptor isoform 1). *J Biol Chem* 2004; 279: 37566–74.
- Du GG, Sandhu B, Khanna VK, Guo XH, MacLennan DH. Topology of the Ca²⁺ release channel of skeletal muscle sarcoplasmic reticulum (RyR1). *Proc Natl Acad Sci USA* 2002; 99: 16725–30.
- Dubowitz V, Sewry CA. edn. *Muscle biopsy: a practical approach*, 3rd edn., Sanders/Elsevier, Edinburgh; 2007.
- Ducreux S, Zorzato F, Ferreiro A, Jungbluth H, Muntoni F, Monnier N, et al. Functional properties of ryanodine receptors carrying three amino acid substitutions identified in patients affected by multi-minicore disease and central core disease, expressed in immortalized lymphocytes. *Biochem J* 2006; 395: 259–66.
- Ferreiro A, Monnier N, Romero NB, et al. A recessive form of central core disease, transiently presenting as multi-minicore disease, is associated with a homozygous mutation in the ryanodine receptor type 1 gene. *Ann Neurol* 2002a; 51: 750–9.
- Ferreiro A, Quijano-Roy S, Pichereau C, Moghadaszadeh B, Goemans N, Bonnemann C, et al. Mutations of the selenoprotein N gene, which is implicated in rigid spine muscular dystrophy, cause the classical phenotype of multimicore disease: reassessing the nosology of early-onset myopathies. *Am J Hum Genet* 2002b; 71: 739–49.
- Galli L, Orrico A, Cozzolino S, Pietrini V, Tegazzin V, Sorrentino V. Mutations in the RYR1 gene in Italian patients at risk for malignant hyperthermia: evidence for a cluster of novel mutations in the C-terminal region. *Cell Calcium* 2002; 32: 143–51.
- Galli L, Orrico A, Lorenzini S, Censini S, Falciani M, Covacci A, et al. Frequency and localization of mutations in the 106 exons of the RYR1 gene in 50 individuals with malignant hyperthermia. *Hum Mutat* 2006; 27: 830.
- Jungbluth H, Davis MR, Muller C, Counsell S, Allsop J, Chattopadhyay A, et al. Magnetic resonance imaging of muscle in congenital myopathies associated with RYR1 mutations. *Neuromuscul Disord* 2004; 14: 785–90.
- Jungbluth H, Muller CR, Halliger-Keller B, Brockinton M, Brown SC, Feng L, et al. Autosomal recessive inheritance of RYR1 mutations in a congenital myopathy with cores. *Neurology* 2002; 59: 284–7.
- Jungbluth H, Sewry CA, Muntoni F. What's new in neuromuscular disorders? The congenital myopathies. *Eur J Paediatr Neurol* 2003; 7: 23–30.
- Jungbluth H, Zhou H, Hartley L, Halliger-Keller B, Messina S, Longman C, et al. Minicore myopathy with ophthalmoplegia caused by mutations in the ryanodine receptor type 1 gene. *Neurology* 2005; 65: 1930–5.
- Jungbluth H, Zhou H, Sewry CA, Robb S, Treves S, Bitoun M, et al. Centronuclear myopathy due to a de novo dominant mutation in the skeletal muscle ryanodine receptor (RYR1) gene. *Neuromuscul Disord* 2007; 17: 338–45.
- Lynch PJ, Krivosic-Horber R, Reyford H, Monnier N, Quane K, Adnet P, et al. Identification of heterozygous and homozygous individuals with the novel RYR1 mutation Cys35Arg in a large kindred. *Anesthesiology* 1997; 86: 620–6.
- Monnier N, Ferreiro A, Marty I, Labarre-Vila A, Mezin P, Lunardi J. A homozygous splicing mutation causing a depletion of skeletal muscle RYR1 is associated with multi-minicore disease congenital myopathy with ophthalmoplegia. *Hum Mol Genet* 2003; 12: 1171–8.
- Monnier N, Kozak-Ribbens G, Krivosic-Horber R, Nivoche Y, Qi D, Kraev N, et al. Correlations between genotype and pharmacological, histological, functional, and clinical phenotypes in malignant hyperthermia susceptibility. *Hum Mutat* 2005; 26: 413–25.
- Monnier N, Romero NB, Lerale J, Landrieu P, Nivoche Y, Fardeau M, et al. Familial and sporadic forms of central core disease are associated with mutations in the C-terminal domain of the skeletal muscle ryanodine receptor. *Hum Mol Genet* 2001; 10: 2581–92.
- Monnier N, Romero NB, Lerale J, Nivoche Y, Qi D, MacLennan D, et al. An autosomal dominant congenital myopathy with cores and rods is associated with a neomutation in the RYR1 gene encoding the skeletal muscle ryanodine receptor. *Hum Mol Genet* 2000; 9: 2599–608.
- Quane KA, Healy JM, Keating KE, Manning BM, Couch FJ, Palmucci LM, et al. Mutations in the ryanodine receptor gene in central core disease and malignant hyperthermia. *Nat Genet* 1993; 5: 51–5.
- Robinson R, Carpenter D, Shaw MA, Halsall J, Hopkins P. Mutations in RYR1 in malignant hyperthermia and central core disease. *Hum Mutat* 2006; 27: 977–89.
- Sewry CA, Muller C, Davis M, Dwyer JS, Dove J, Evans G, et al. The spectrum of pathology in central core disease. *Neuromuscul Disord* 2002; 12: 930–8.
- Shuaib A, Paasuke RT, Brownell KW. Central core disease. Clinical features in 13 patients. *Medicine (Baltimore)* 1987; 66: 389–96.
- Treves S, Anderson AA, Ducreux S, Divet A, Bleuven C, Grasso C, et al. Ryanodine receptor 1 mutations, dysregulation of calcium homeostasis and neuromuscular disorders. *Neuromuscul Disord* 2005; 15: 577–87.
- Wu S, Ibarra MC, Malicdan MC, Murayama K, Ichihara Y, Kikuchi H, et al. Central core disease is due to RYR1 mutations in more than 90% of patients. *Brain* 2006; 129: 1470–80.

- Xiong L, Zhang JZ, He R, Hamilton SL. A Ca^{2+} -binding domain in RyR1 that interacts with the calmodulin binding site and modulates channel activity. *Biophys J* 2006; 90: 173–82.
- Zhang Y, Chen HS, Khanna VK, De Leon S, Philips MS, Schappert K, et al. A mutation in the human ryanodine receptor gene associated with central core disease. *Nat Genet* 1993; 5: 46–50.
- Zhou H, Brockington M, Jungbluth H, Monk D, Stanier P, Sewry CA, et al. Epigenetic allele silencing unveils recessive *RYR1* mutations in core myopathies. *Am J Hum Genet* 2006a; 79: 859–68.
- Zhou H, Yamaguchi N, Xu L, Wang Y, Sewry C, Jungbluth H, et al. Characterization of recessive *RYR1* mutations in core myopathies. *Hum Mol Genet* 2006b; 15: 2791–803.
- Zorzato F, Yamaguchi N, Xu L, Meissner G, Muller CR, Pouliquin P, et al. Clinical and functional effects of a deletion in a COOH-terminal luminal loop of the skeletal muscle ryanodine receptor. *Hum Mol Genet* 2003; 12: 379–88.
- Zorzato F, Jungbluth H, Zhou H, Muntoni F, Treves S, et al. Functional effects of mutations identified in patients with multimimicore disease. *IUBMB Life* 2007; 59: 14–20.