

Clinical Article

Morbidity in 201 patients with small sized meningioma treated by microsurgery

M. Reinert¹, M. Babey¹, J. Curschmann², I. Vajtai³, R. W. Seiler¹, and L. Mariani¹

¹ Department of Neurosurgery, Inselspital Bern, University of Bern, Bern, Switzerland

² Department of Radio-Oncology, University of Bern, Bern, Switzerland

³ Institute of Pathology, University of Bern, Bern, Switzerland

Received March 21, 2006; accepted August 28, 2006; published online November 9, 2006

© Springer-Verlag 2006

Summary

Background. The management of patients with small, often asymptomatic meningiomas is controversial and includes observation, microsurgery (MS) and stereotactic radiosurgery (SRS). The purpose of this retrospective study was to analyze the morbidity and the extent of removal after MS for small (≤ 3 cm) intracranial meningiomas and compare these results to those of SRS reported in the literature.

Methods. All patients with an intracranial meningioma with a maximum diameter up to 3 cm operated on in our institution over a 10 year period (1992–2002) were included in the study and retrospectively analyzed. Patients were grouped into asymptomatic and symptomatic and according to tumor location as: group I (cranial vault, parasagittal, lateral sphenoid), group II (falx, frontobasal, medial sphenoid, parasellar and tentorial), group III (cavernous sinus, petroclival, petrosal, CPA and foramen magnum).

Findings. There were a total of 201 patients, of whom 102 were asymptomatic and 99 were symptomatic. The overall risk of permanent neurological morbidity was 4.9% in asymptomatic and 23.2% in symptomatic patients. The combined risk in asymptomatic and symptomatic patients was 5.4% in group I, 11.5% in group II, and 39.9% in group III lesions. Radical removal was achieved in all patients in group I, in 93.7% of group II, and 80% of group III lesions. There was no disease related mortality.

Conclusions. MS provides excellent efficacy and morbidity results in groups I and II meningiomas, especially in asymptomatic patients and might therefore be considered the first choice of treatment for these patients. The results of MS in group III were worse than those of SRS reported in the literature.

Keywords: Meningioma; microsurgery; morbidity; size; symptoms.

Introduction

The clinical presentation and management of patients with meningiomas have changed significantly in the last

ten to fifteen years. First, the liberal use of computer tomography and magnetic resonance imaging (MRI) has led to diagnosis of more asymptomatic small and medium sized tumors [30, 50]. Second, modern techniques of radiation therapy, in particular stereotactic radiosurgery (SRS), have been developed and are increasingly being used to treat these lesions.

Meningiomas are typically treated primarily by surgery [1–6, 9, 11–15, 17–19, 24, 29, 40, 42, 47–49, 52]. In recent years, SRS has gained an important role also as a primary treatment option for meningiomas smaller than 3 cm in diameter, mainly for those located in the skull base [4–6, 8, 9, 11, 12, 14, 15, 17, 18, 20–22, 24, 25, 27, 28, 33, 35, 37, 40–46, 48, 49, 51, 52]. The efficacy and the risks of MS are related to tumor size, tumor location and to the pre-operative symptom status [10]. However, data on the efficacy and morbidity of MS for small tumors tend to be buried in series including all tumor sizes and locations regardless of the pre-operative symptom status [7, 24, 29, 34]. The results of most surgical series are therefore not comparable to those in radiosurgical reports. The uncertainties about the natural course of the disease make also observation until clinical and/or radiological progression to a reasonable management option for small meningiomas, especially in asymptomatic patients. The large majority of asymptomatic patients monitored by serial scans will typically not become symptomatic, even if their tumor grows. Also, it is not demonstrated that the results of delayed treatment

are worse than those of early treatment [34]. Tumor growth is reported to occur in 12–43% of patients over a mean observation period of 2.3–6.1 years [31]. The growth rate may be variable over time and spans from 1 cm in diameter per year to no growth over years [16, 30–32, 34]. Some radiological characteristics may help in the decision making: tumor calcifications are associated with a low proliferative potential and may suggest observation, whereas a lobulated shape or an irregular tumor surface associated with peritumoral edema (hyperintensity in T2 weighted MRI) are associated with high proliferative indices and might suggest treatment upfront [31, 32].

Observation, MS, and SRS are therefore potentially all reasonable management options in patients with small intracranial, meningiomas. The purpose of our retrospective analysis was to provide data on the efficacy and morbidity of MS for meningiomas theoretically amenable to radiosurgical treatment, to analyze the data according to tumor location and the pre-operative symptom status, and to compare our surgical results with radiosurgical data from the literature.

Patients and methods

All patients with a meningioma smaller or equal to 3 cm in diameter operated on between 1992 and 2002 were included in this retrospective study. Treatment strategy was defined by one of the authors (RWS) and consisted in attempting radical removal of the tumor and of its dural attachments whenever possible without sacrificing important structures, the loss of which would entail worsening of a pre-existing or development of a new neurological deficit. The operations were performed by or under the supervision of the board certified staff. Outcome data were assessed using the patient case-history chart, patient interviews, personal physician interview and radiological studies.

Registered parameters

Demographic data, duration of the hospitalization and operation procedure were noted. Maximum cross-sectional diameter of the meningiomas was measured based on pre-operative scans. Meningiomas were further categorized into three groups according to their location and the assumed risk of resection and feasibility of radical removal (Table 1, Fig. 1).

Patients were categorized as being asymptomatic or symptomatic. Surgical morbidity and mortality were registered for all patients and analyzed according to the localization group. Morbidity lasting for more than 6 months was recorded as permanent. Worsening of pre-operative symptoms was also registered as surgical morbidity. Mortality occurring

Table 1. Subgroup of meningioma according to location

Group I	Group II	Group III
convexity	falx	cavernous sinus
parasagittal	frontobasal	petroclival
lateral sphenoid	medial sphenoid	petrosal
	parasellar	cerebellopontine angle
	tentorium	foramen magnum

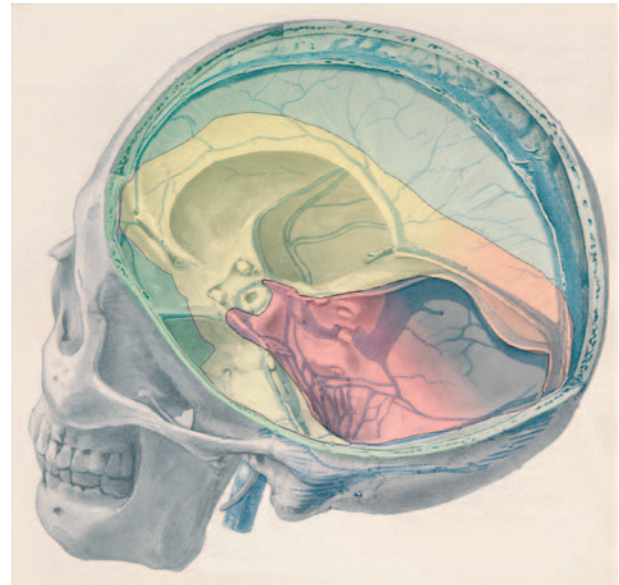


Fig. 1. Three dimensional drawing of the opened skull, showing the three locations correlating with the surgical risk location: group I (green), II (yellow) and III (red) in analogy to Table 1. (Adapted after Meningiomas: Harvey Cushing 1938, Charles C Thomas Publisher, with permission)

within the 6 months following the intervention was registered as operation related, when a possible correlation was demonstrated. Complete resection was defined as no visible tumor on postoperative scans. Resection was defined as incomplete whenever a residual tumor was visible on postoperative imaging performed within the first three months after surgery. All data were registered and processed in Access® (Microsoft Corporation, USA).

Histological diagnosis and tumor grading

The complete histological documentation of all cases was retrieved from the files of the Institute of Pathology, University of Bern. All microscopic slides were reviewed by a board certified neuropathologist with special expertise in brain tumor pathology and classified according to the current World Health Organization Classification of Tumors of the Nervous System [26]. The issue of “brain invasive, otherwise benign” tumors was specifically addressed according to the criteria defined by Perry *et al.* [36].

Statistical analysis

Statistical analysis was performed using two tailed Fisher’s Exact Test for analysis of the group specific morbidity and the unpaired *t*-test for analysis of the relationship between the pre-operative symptom status and tumor size. The cut-off level for significance was set at $p < 0.05$. The statistical analysis was performed using SPSS® 12.0 (SPSS, Chicago, IL, USA) and InStat (Graphpad Software, San Diego, CA, USA). Data are given in means \pm standard deviation, unless otherwise specified.

Results

A total of 201 patients harbouring a meningioma smaller or equal to 3 cm in diameter were treated by MS during the study period and were therefore included. The mean age of 57.6 years was identical and the age

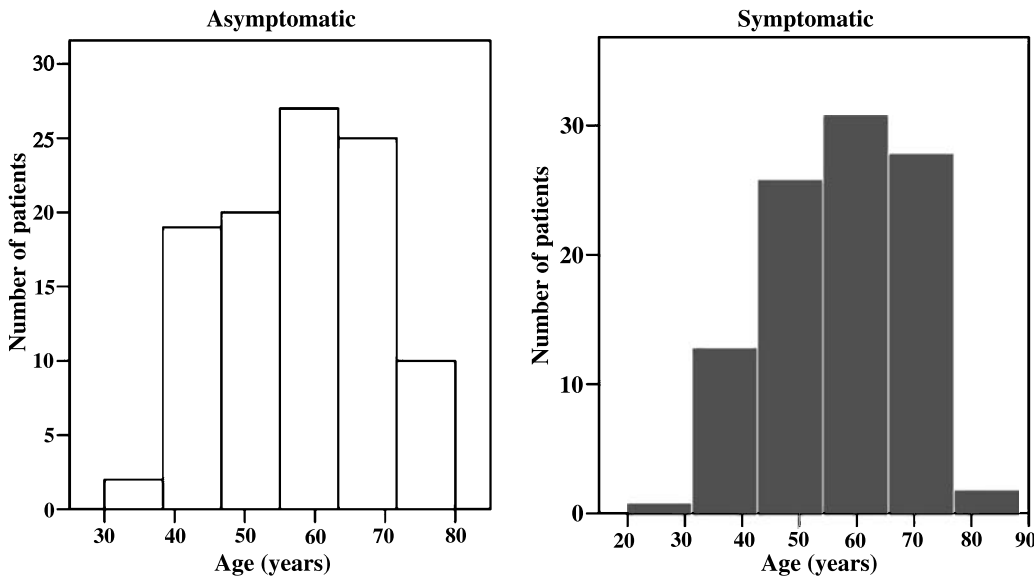


Fig. 2. Age distribution in asymptomatic and symptomatic patients. The mean age is identical in both categories (57.6 years)

distribution was not statistically different in asymptomatic and symptomatic patients (Fig. 2). One hundred and fifty nine patients (79.1%) were female and 42 (20.9%) were male. The hospital stay was 10 ± 3 days for the whole study period. It dropped from 13.5 days in 1992 to 8 days in 2002. The operating time (skin to skin) was $2.7 \text{ h} \pm 1.1$, $3.9 \text{ h} \pm 1.3$ and $4.9 \text{ h} \pm 1.7$ in groups I, II, and III, respectively.

WHO-grading

One hundred and ninety four meningiomas were WHO grade I and 7 meningiomas were WHO grade II. Of the latter, 4 were bonafide atypical meningiomas, and

3 were “brain invasive, otherwise benign” meningiomas of either transitional or fibrous type. There was no location group or symptom specific WHO grade distribution.

Table 2. Transient morbidities in asymptomatic and symptomatic patients according to localization groups I–III

I	II	III
<i>Asymptomatic</i>		
2 headache	visual disturbance	cerbrospinal fluid leak
bone flap instability	abducens nerve palsy	
respiratory distress	facial nerve palsy	
	anosmia	
	seizure	
	bone flap instability	
	sinusitis	
	pneumonia	
<i>Symptomatic</i>		
2 facial numbness	anosmia	3 cerebellar signs
2 paresthesias right arm	2 hearing loss and facial nerve palsy ipsilatera	brainstem dysfunction
peripheral facial nerve palsy	hearing loss	3 hearing loss
aphasia	oculomotor nerve palsy	2 facial nerve palsy
seizure	hemiparesis	2 abducens nerve palsy
boneflap instability	paresis leg	amaurosis
leg thrombosis	frontal brain syndrome	3 facial hypesthesia
	aphasia	hypoglossal nerve palsy
	2 cerebrospinal fluid leak	visual disturbance
	bone flap instability	tuberculous meningio-encephalitis
	seizure	pneumonia
	meningitis	
	thrombosis leg	

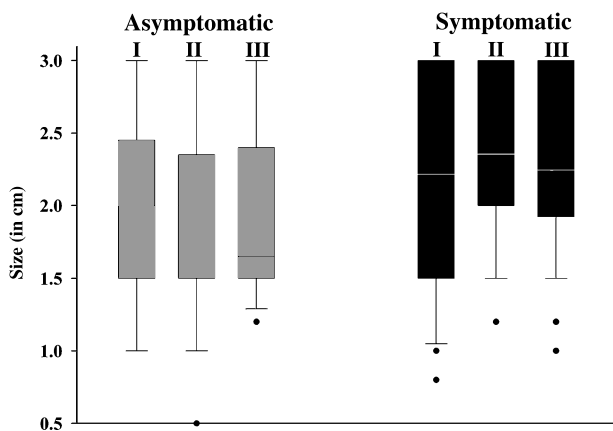


Fig. 3. The overall tumor size in patients with asymptomatic meningiomas was significantly smaller than in the patients with symptomatic meningiomas ($p < 0.001$). The different sizes with their median and standard deviation and the 95th percentile are given. The dots represent the outliers

Asymptomatic and symptomatic patients

One hundred and two patients were asymptomatic before surgery, 99 were symptomatic. The mean size of the meningiomas in asymptomatic patients was slightly but significantly smaller than in symptomatic patients, 1.90 ± 0.6 cm versus 2.25 ± 0.6 cm, respectively ($p < 0.001$) (Fig. 3). Tumor location also differed between asymptomatic and symptomatic patients. Among asymptomatic patients there were 47 in group I, 48 in group II and 7 in group III, whereas among symptomatic patients 26 were in group I, 47 in group II and 26 in group III.

Mortality

There was no mortality within 6 months after surgery in the whole study group.

Morbidity

Transient neurological morbidity

The transient morbidity including all groups was significantly lower in the pre-operatively asymptomatic (12.7%) versus pre-operatively symptomatic patients (43.4%, $p < 0.0001$ for the difference). The relative risk

in pre-operatively asymptomatic patients to suffer *transient* morbidity was 8.5% (4/47), 16.6% (8/48) and 14.2% (1/7) in groups I, II, and III, respectively and 34.6% (9/26), 31.9% (15/47) and 73.0% (19/26) in symptomatic patients. The nature of the transient morbidity is specified in Table 2. and significances between the groups are given in Table 3.

Permanent neurological morbidity

The permanent morbidity for all groups was significantly lower in the pre-operatively asymptomatic (4.9%) versus pre-operatively symptomatic patients (23.2%, $p < 0.0001$ for the difference) (Fig. 4). The risk of permanent morbidity in pre-operatively asymptomatic was 0% (0/47), 8.3% (4/48) and 14.3% (1/7) in groups I, II, and III, respectively; the risk was 15.3% (4/26), 14.9% (7/47) and 46.1% (12/26) in symptomatic patients (Fig. 4). The nature of the permanent morbidity is specified in Table 4, and the significances between the groups are given in Table 3.

Completeness of resection

Complete resection was achieved in 100% (47/47), 95.8% (46/48) and 71.4% (5/7) in asymptomatic groups

Table 3. Significance (*p*-values) of appearance of morbidity in patient subgroups between location groups I, II and III

Groups	Asymptomatic			Symptomatic		
	I	II	III	I	II	III
<i>Transient morbidity</i>						
Asymptomatic	I	x	n.s.			
	II	n.s.	x			
	III	n.s.	n.s.			x
Symptomatic	I			x	n.s.	<0.01
	II			n.s.	x	<0.001
	III			<0.01	<0.001	x
	combined asymptomatic and symptomatic					
	I	II	III			
	I	x	n.s.			<0.001
	II	n.s.	x			<0.001
	III	<0.001	<0.001			x
<i>Permanent morbidity</i>						
Asymptomatic	I	x	<0.05			<0.01
	II	<0.05	x			n.s.
	III	<0.01	n.s.			x
Symptomatic	I			x	n.s.	<0.025
	II			n.s.	x	<0.01
	III			<0.025	<0.01	x
	combined asymptomatic and symptomatic					
	I	II	III			
	I	x	n.s.			<0.001
	II	n.s.	x			<0.001
	III	<0.001	<0.001			x

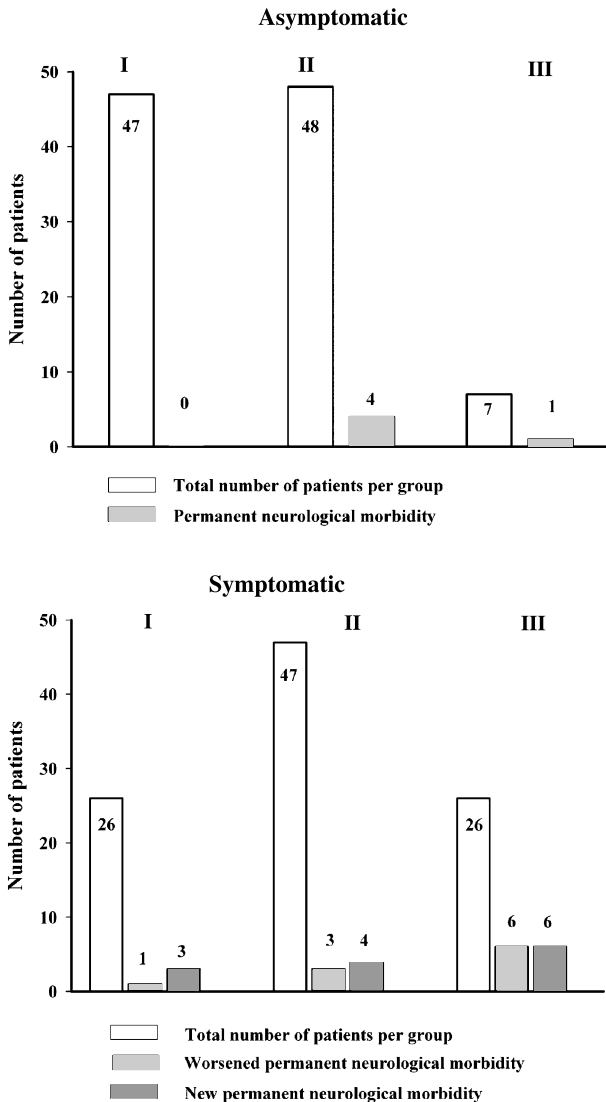


Fig. 4. Permanent morbidity in pre-operatively asymptomatic (upper part) and symptomatic patients (lower part). The overall morbidity was significantly increased in the symptomatic versus the asymptomatic patients ($p < 0.0001$)

I, II, and III, respectively (overall rate of complete resection 96.0%). In symptomatic patients complete resection was achieved in 100% (26/26), 85.1% (40/47) and 80.7% (21/26) in groups I, II, and III respectively (overall rate of complete resection 87.8%) (Fig. 5 and Table 5). Incomplete resection was significantly higher in group III compared to group I, in both asymptomatic ($p < 0.014$) and symptomatic ($p = 0.05$) patients. A total of 16 patients had incomplete resections (7.9%). Nine patients showed no progression of the residual meningioma. Seven patients necessitated secondary treatment during the observation period of the study period, of whom 5 patients with residual tumor received immediate adjuvant radiotherapy and 2 patients received radio-

Table 4. Permanent morbidity in asymptomatic and symptomatic patients according to localization groups I–III

I	II	III
<i>Asymptomatic</i>		
none	abducens nerve palsy boneflap instability facial nerve palsy anosmia	facial nerve palsy
<i>Symptomatic</i>		
2 facial numbness 2 paresthesias arm	anosmia hearing loss oculomotor nerve palsy paresis of the leg hemiparesis frontal brain syndrome seizure	2 cerebellar signs brainstem dysfunction 3 hearing loss facial nerve palsy abducens nerve paresis hypoglossal nerve palsy amaurosis

therapy after demonstration of progression. Two patients had tumor recurrence after complete resection: one was treated by surgery and the second by radiation therapy.

Discussion

In the present study of patients treated by MS for meningioma, we included only tumors theoretically amenable to radiosurgical treatment (smaller than 3 cm in diameter). Pre-operative symptom status correlated to the extent of tumor removal and with morbidity. Morbidity was significantly higher in group III compared to group I and group II patients. Also, in the subgroup of asymptomatic patients there was a significantly higher morbidity rate in group II compared to group I patients. The correlation between outcome and pre-operative symptom status and tumor locations in groups I, II and III validated our classification and is therefore an important finding. Classifying tumor locations according to the estimated risk of surgery may be a matter of endless debate. Also, our distinction between groups II and III lesions is not always obvious since some tumors violate the boundaries of these locations (e.g. an anterior clinoid meningioma involving the cavernous sinus). Nevertheless, this classification is relatively simple and corresponds to risk groups of MS according to our data. We suggest that these classification criteria (pre-operative symptom status and tumor location) should be considered for patients' stratification in future studies comparing MS and SRS.

Microsurgery in asymptomatic meningiomas

With a policy of removing any asymptomatic meningioma at the time of diagnosis, we could achieve a com-

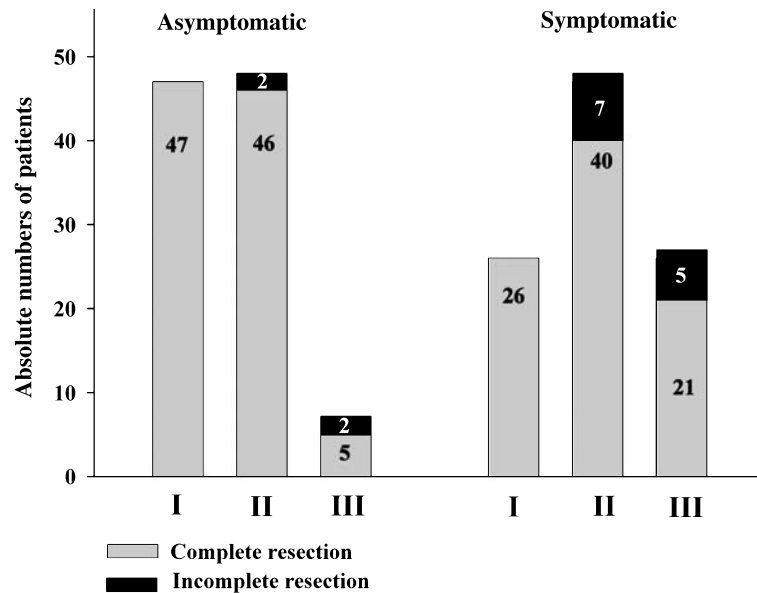


Fig. 5. Rates of complete and incomplete resection over the groups I, II and III in asymptomatic and symptomatic patients

Table 5. Distribution of number of cases according to the analysis criteria: morbidity, symptoms, resection grade and tumor location

		Permanent morbidities	
		Complete resection	Incomplete resection
Asymptomatic	I	0 out of 47	na
	II	4 out of 46	0 out of 2
	III	1 out of 5	0 out of 2
Symptomatic	I	4 out of 26	na
	II	4 out of 40	3 out of 7
	III	8 out of 21	4 out of 5

plete removal in all convexity lesions (group I) without permanent neurological morbidity. This figure could favour an aggressive surgical attitude in managing these patients, since they are likely to be cured after surgery and they do not need a long postoperative imaging follow-up, which has obvious favourable consequences. Our results were less good in patients with more deeply seated tumors on the falx, tentorium, medial sphenoid wing and frontal skull base (group II). Complete tumor removal was possible in more than 96% but the toll in terms of permanent morbidity was rather high (8.3% of the patients). Only 7 of asymptomatic patients in our series had tumors located in high-risk regions (petroclival, cerebellopontine angle, foramen magnum). One patient suffered permanent morbidity after surgery and two were not amenable to complete resection. The present study provides important figures of efficacy and morbidity in asymptomatic patients with small meningiomas according to the tumor location and may represent a reference for future studies with which to contrast them.

Microsurgery in symptomatic meningiomas

In our series, the risk for permanent neurological deficits after surgery was significantly higher in symptomatic patients (overall risk 23.7%) compared to their asymptomatic counterparts (4.9%), regardless of tumor location. The difference may be in part related to the larger size of symptomatic meningiomas and to the higher proportion of group III lesions among symptomatic patients. In fact, the risk of surgery increased significantly in more critical areas, in particular for tumors in group III (46.1% compared to 15.3 and 14.9%, in groups I and II, respectively). The association between meningioma location and surgical outcome has already been described by Harvey Cushing in his impressive opus magnum [10]. In most series of the literature however, the analysis of morbidity was not performed according to symptoms, tumor size and tumor location which limits the comparability of the results. The rate of 15.3% new or worsened permanent morbidity for group I lesions in the present series is relatively high. We did not find a comparable series focussing on the results obtained for symptomatic patients with convexity meningioma (our group I) in the literature. Our 18.7% rate of permanent morbidity in group II patients is comparable to that of Puchner *et al.*, who published in 1998 a series of 50 patients with suprasellar meningiomas and reported 22% of permanent morbidity [40]. The high rate of permanent morbidity (46.1%) in group III lesions in the present series is also in accordance with the literature [3, 25, 41]. Roberti *et al.* reported a 41% rate of permanent neurological deficits in a series of 161 menin-

Table 6. The overall percentage of permanent morbidity in series of microsurgically (MS) and with stereotactic radiosurgery (SRS) treated meningiomas reported in the literature arranged according to our localization groups (I–III)

Author	Year	MS/SRS	Number of patients	Localization I, II, III	% of permanent morbidity
Puchner <i>et al.</i>	1998	MS	50	II	22%
Roberti <i>et al.</i>	2001	MS	161	III	41%
Bassiouni <i>et al.</i>	2004	MS	51	III	44.2%
Lobato <i>et al.</i>	2004	MS	80	III	na (67.5% transient)
Pollock <i>et al.</i>	2005	MS	136	(I), II , III	22.0%
Reinert <i>et al.</i>	2006	MS	201	I, II, III	5.4% (I), 11.5% (II), 39.9% (III)
Kondziolka <i>et al.</i>	1999	SRS	85	(II), III	6%
Flickinger <i>et al.</i>	2003	SRS	219	(II), III	8.8%
Pollock <i>et al.</i>	2003	SRS	38	III	13.70%
Pollock <i>et al.</i>	2005	SRS	62	(I), II, III	10%
Friedmann <i>et al.</i>	2005	SRS	210	(I), II, III	2.30%

Localization of the meningiomas were standardized according to the localization criteria used in the present report (see Table 1). Localization group in parenthesis () means less than 5% of cases. Localization in bold means more than 75% of cases.

giomas in the posterior fossa [41]. In a similar location, Bassiouni *et al.* reported a 9.8% rate of permanent facial palsy, a deterioration of the hearing function in 18.4%, and an additional 16% postoperative permanent neurological morbidity, thus a permanent morbidity rate of 44.2% [3]. Lobato *et al.* reported a 67.5% rate of transient neurological morbidity, with subsequent improvement in most cases, in a series of posterior fossa meningiomas [25]. No exact figures were provided for permanent morbidity.

The completeness of resection was lower in symptomatic (85.1%) compared to the asymptomatic patients (95.8%) in group II. The reason for this difference, that did not reach statistical significance, is unclear.

A comparison with the radiosurgery data from the literature

Since intracranial tumors treated by SRS are usually smaller than 3 cm, our results may be compared with those of radiosurgical series. However, the comparison between retrospective radiosurgical and surgical series has critical limitations. Radiosurgical series invariably include a larger proportion of skull base meningiomas and a lower number of superficial lesions compared to surgical series (Table 6). Deep and superficial lesions differ in several important aspects, like the clinical presentation (e.g. cranial nerve deficit and epilepsy), in the sensitivity of the adjacent neural tissue to ionizing radiations and potentially also in their biology.

In their series of 219 cases of meningiomas treated with the gamma knife and diagnosed with imaging criteria alone, Flickinger *et al.* reported an overall incidence of postradiosurgical injury of 8.8%. An improvement from 22.9 to 5.3% was registered over time, and

was attributed to the shift from a CT- to an MRI-based dosage planning. The actuarial tumor control rate was 93% at both 5 and 10 years. Forty-five percent of the tumors were located in the cavernous sinus or in the petroclival region [14]. In a series of cavernous sinus meningiomas treated by SRS, Pollock *et al.* reported a morbidity rate of 13.7 and a 100% tumor control rate [38]. In the series of Kondziolka *et al.* with 85 patients harbouring a meningioma, 5 patients (6.1%) were reported to suffer permanent morbidity using the same criteria as in the present study [21, 23]. In a LINAC-SRS based study, Friedman *et al.* reported transient complications in 6.2% and permanent complications in 2.3% of 210 meningioma patients [15]. If one considers that a large proportion or even the majority of the tumors in radiosurgical series are located in the skull base, one can easily conclude that SRS provides better results than MS for this group of patients, especially for those with a group III meningioma. In fact, for these lesions the morbidity of surgery is excessively high (46% in the present study) and the resection is often incomplete (in approximately 80% of the patients in the present series).

These conclusions can not be generalized for all patients with small meningiomas. Our best results were obtained in group I tumors, especially in asymptomatic patients. The overall rate of permanent neurological morbidity of 5% (4/73 patients) in that group is comparable to that of modern radiosurgical series. All 73 patients (asymptomatic and symptomatic patients with small convexity meningiomas) were potentially cured, although we do not provide long-term follow-up on the rate of recurrence, which is a clear limitation of the present series. Kim *et al.* specifically addressed the question of GKS of small superficial convexity meningiomas and reported a high complication rate of 43%

(10/23 patients) with headache in all 10 and hemiparesis in three cases [20]. Postirradiation peritumoral edema was found in all cases. The symptoms appeared 1 to 12 months after SRS and resolved after steroids. Flickinger *et al.* did not provide the specific rate of complications and the size of the tumors in their subgroup of superficial meningiomas (81 patients according to our calculation) [14]. They reported a total of 12 patients with radiosurgical complications: 4 with edema and headache, 2 with hemiparesis, 2 with mental changes, 3 with trigeminal dysfunction and 1 with a temporary visual deficit. A significant proportion of that morbidity might have occurred in patients with superficial meningiomas. Pollock *et al.* reviewed 198 patients with a newly diagnosed meningioma smaller than 35 mm in average diameter who were treated by MS ($n = 136$) or SRS ($n = 62$) between 1990 and 1997. The authors underscored two aspects of their results: 1) the excellent tumor control rate of SRS (actuarial progression-free survival of 95% at 7 years) compared to radical MS (actuarial progression-free survival of 96% at 7 years in 57 patients with Simpson grade 1 resections); and 2) the lower overall morbidity of SRS compared to MS (10 versus 22%, $p = 0.06$) [39]. However the two treatment groups (SRS and MS) were different: there were significantly more cranial nerve deficits and skull base meningiomas in the radiosurgical group compared with the surgical group. Vice versa, there were more epileptic seizures and convexity lesions in the surgical group compared with the SRS group. This selection bias does not allow any conclusion about which method is superior e.g. for the treatment of convexity meningiomas. Important aspects of efficacy, e.g. epilepsy control, and of morbidity, e.g. edema and cortical dysfunction, are indeed strongly related to tumor location and can only be addressed in appropriately designed studies [24].

Conclusion

The clinical implications of our findings and of those in the literature are not clear cut. It is reasonable to observe some asymptomatic patients until evidence of tumor growth prior to treatment, especially if the meningioma is calcified and the patient is old. In terms of efficacy and procedure related morbidity, the results of microsurgical treatment of small sized (<3 cm) meningiomas strongly depends on tumor location and on the pre-treatment symptom status at diagnosis. The results of surgery are excellent for convexity lesions (group I). It seems therefore appropriate to propose surgery to

patients with growing or symptomatic small convexity meningiomas as a first-line treatment. The histological verification of the tumor and its radical removal are obvious advantages of surgery in these patients. The results of surgery are fair for group II lesions (falx, frontal skull base, tentorium, medial sphenoid wing, parasellar), especially in asymptomatic patients. Some of these lesions are in contact with structures with a low tolerance to radiation (e.g. the optic nerves and chiasm), suggesting that MS might still be the treatment of choice. The results of MS are worse in group III lesions (petrous apex, clivus, cavernous sinus, cerebellopontine angle) where aggressive microsurgical treatment has a rate of permanent neurological morbidity up to 50% in symptomatic and up to 15% in asymptomatic patients.

Comparative studies assessing the relative potential of MS versus SRS for subgroups of patients with small meningiomas are lacking. However, data from the literature indicate that SRS is likely to yield results superior to those obtained by MS in patients who are at high surgical risk, such as the majority of patients with skull base meningiomas.

References

1. Alvernia JE, Sindou MP (2004) Preoperative neuroimaging findings as a predictor of the surgical plane of cleavage: prospective study of 100 consecutive cases of intracranial meningioma. *J Neurosurg* 100: 422–430
2. Arienta C, Caroli M, Crotti F, Villani R (1990) Treatment of intracranial meningiomas in patients over 70 years old. *Acta Neurochir (Wien)* 107: 47–55
3. Bassiouni H, Hunold A, Asgari S, Stolke D (2004) Tentorial meningiomas: clinical results in 81 patients treated microsurgically. *Neurosurgery* 55: 108–116
4. Black P, Kathiresan S, Chung W (1998) Meningioma surgery in the elderly: a case-control study assessing morbidity and mortality. *Acta Neurochir (Wien)* 140: 1013–1016
5. Black PM, Villavicencio AT, Rhoudou C, Loeffler JS (2001) Aggressive surgery and focal radiation in the management of meningiomas of the skull base: preservation of function with maintenance of local control. *Acta Neurochir (Wien)* 143: 555–562
6. Chamberlain MC (2004) Intracerebral Meningiomas. *Curr Treat Options Neurol* 6: 297–305
7. Chan RC, Thompson GB (1984) Morbidity, mortality, and quality of life following surgery for intracranial meningiomas. A retrospective study in 257 cases. *J Neurosurg* 60: 52–60
8. Chang JH, Chang JW, Choi JY, Park YG, Chung SS (2003) Complications after gamma knife radiosurgery for benign meningiomas. *J Neurol Neurosurg Psychiatry* 74: 226–230
9. Condra KS, Buatti JM, Mendenhall WM, Friedman WA, Marcus RB Jr, Rhoton AL (1997) Benign meningiomas: primary treatment selection affects survival. *Int J Radiat Oncol Biol Phys* 39: 427–436
10. Cushing H (1962) Meningiomas, their classification regional behaviour, life history and surgical end results. Hafner Publishing, New York, pp 1–387

11. De Jesus O, Toledo MM (2001) Surgical management of meningioma en plaque of the sphenoid ridge. *Surg Neurol* 55: 265–269
12. Dimeco F, Li KW, Casali C, Cicceri E, Filippini G, Broggi G, Solero CL (2004) Meningiomas invading the superior sagittal sinus: surgical experience in 108 cases. *Neurosurgery* 55: 1263–1274
13. Drummond KJ, Zhu JJ, Black PM (2004) Meningiomas: updating basic science, management, and outcome. *Neurologist* 10: 113–130
14. Flickinger JC, Kondziolka D, Maitz AH, Lunsford LD (2003) Gamma knife radiosurgery of imaging-diagnosed intracranial meningioma. *Int J Radiat Oncol Biol Phys* 56: 801–806
15. Friedman WA, Murad GJ, Bradshaw P, Amdur RJ, Mendenhall WM, Foote KD, Bova FJ (2005) Linear accelerator surgery for meningiomas. *J Neurosurg* 103: 206–209
16. Go RS, Taylor BV, Kimmel DW (1998) The natural history of asymptomatic meningiomas in Olmsted County, Minnesota. *Neurology* 51: 1718–1720
17. Goel A, Muzumdar D (2004) Conventional posterior fossa approach for surgery on petroclival meningiomas: a report on an experience with 28 cases. *Surg Neurol* 62: 332–338
18. Goldsmith BJ, Wara WM, Wilson CB, Larson DA (1994) Post-operative irradiation for subtotally resected meningiomas. A retrospective analysis of 140 patients treated from 1967 to 1990. *J Neurosurg* 80: 195–201
19. Kallio M, Sankila R, Hakulinen T, Jaaskelainen J (1992) Factors affecting operative and excess long-term mortality in 935 patients with intracranial meningioma. *Neurosurgery* 31: 2–12
20. Kim DG, Kim C, Chung HT, Paek SH, Jeong SS, Han DH, Jung HW (2005) Gamma knife surgery of superficially located meningioma. *J Neurosurg* 102 [Suppl]: 255–258
21. Kondziolka D, Levy EI, Niranjan A, Flickinger JC, Lunsford LD (1999) Long-term outcomes after meningioma radiosurgery: physician and patient perspectives. *J Neurosurg* 91: 44–50
22. Kondziolka D, Lunsford LD, Coffey RJ, Flickinger JC (1991) Stereotactic radiosurgery of meningiomas. *J Neurosurg* 74: 552–559
23. Kondziolka D, Nathoo N, Flickinger JC, Niranjan A, Maitz AH, Lunsford LD (2003) Long-term results after radiosurgery for benign intracranial tumors. *Neurosurgery* 53: 815–821
24. Linskey ME, Davis SA, Ratanatharathorn V (2005) Relative roles of microsurgery and stereotactic radiosurgery for the treatment of patients with cranial meningiomas: a single-surgeon 4-year integrated experience with both modalities. *J Neurosurg* 102 [Suppl]: 59–70
25. Lobato RD, Gonzaez P, Alday R, Ramos A, Lagares A, Alen JF, Palomino JC, Miranda P, Perez-Nunez A, Arrese I (2004) Meningiomas of the basal posterior fossa. Surgical experience in 80 cases. *Neurocirugia (Astur.)* 15: 525–542
26. Louis DN, Scheithauer BW, Budka H, von Deimling A, Kepes JJ, Kleihues P, Cavenee WK (2006) Meningiomas. *Tumors of the Nervous System Pathology and Genetics*. IARC Press Lyon, pp 176–189
27. Marosi C, Hassler M, Roessler K (2003) Guidelines to the treatment of meningioma. *Forum (Genova)* 13: 76–89
28. Maruyama K, Shin M, Kurita H, Kawahara N, Morita A, Kirino MDT (2004) Proposed treatment strategy for cavernous sinus meningiomas: a prospective study. *Neurosurgery* 55: 1068–1075
29. Mirimanoff RO, Dosoretz DE, Linggood RM, Ojemann RG, Martuza RL (1985) Meningioma: analysis of recurrence and progression following neurosurgical resection. *J Neurosurg* 62: 18–24
30. Nakamura M, Roser F, Mirzai S, Matthies C, Vorkapic P, Samii M (2004) Meningiomas of the internal auditory canal. *Neurosurgery* 55: 119–127
31. Nakasu S, Fukami T, Nakajima M, Watanabe K, Ichikawa M, Matsuda M (2005) Growth pattern changes of meningiomas: long-term analysis. *Neurosurgery* 56: 946–955
32. Niiro M, Yatsushiro K, Nakamura K, Kawahara Y, Kuratsu J (2000) Natural history of elderly patients with asymptomatic meningiomas. *J Neurol Neurosurg Psychiatry* 68: 25–28
33. O'Sullivan MG, van Loveren HR, Tew JM Jr (1997) The surgical resectability of meningiomas of the cavernous sinus. *Neurosurgery* 40: 238–244
34. Olivero WC, Lister JR, Elwood PW (1995) The natural history and growth rate of asymptomatic meningiomas: a review of 60 patients. *J Neurosurg* 83: 222–224
35. Palma L, Celli P, Franco C, Cervoni L, Cantore G (1997) Long-term prognosis for atypical and malignant meningiomas: a study of 71 surgical cases. *J Neurosurg* 86: 793–800
36. Perry A, Scheithauer BW, Stafford SL, Lohse CM, Wollan PC (1999) "Malignancy" in meningiomas: a clinicopathologic study of 116 patients, with grading implications. *Cancer* 85: 2046–2056
37. Pieper DR, Al Mefty O, Hanada Y, Buechner D (1999) Hyperostosis associated with meningioma of the cranial base: secondary changes or tumor invasion. *Neurosurgery* 44: 742–746
38. Pollock BE, Stafford SL (2005) Results of stereotactic radiosurgery for patients with imaging defined cavernous sinus meningiomas. *Int J Radiat Oncol Biol Phys* 62: 1427–1431
39. Pollock BE, Stafford SL, Utter A, Giannini C, Schreiner SA (2003) Stereotactic radiosurgery provides equivalent tumor control to Simpson Grade 1 resection for patients with small- to medium-size meningiomas. *Int J Radiat Oncol Biol Phys* 55: 1000–1005
40. Puchner MJ, Fischer-Lampsatis RC, Herrmann HD, Freckmann N (1998) Suprasellar meningiomas – neurological and visual outcome at long-term follow-up in a homogeneous series of patients treated microsurgically. *Acta Neurochir (Wien)* 140: 1231–1238
41. Roberti F, Sekhar LN, Kalavakonda C, Wright DC (2001) Posterior fossa meningiomas: surgical experience in 161 cases. *Surg Neurol* 56: 8–20
42. Roser F, Nakamura M, Dormiani M, Matthies C, Vorkapic P, Samii M (2005) Meningiomas of the cerebellopontine angle with extension into the internal auditory canal. *J Neurosurg* 102: 17–23
43. Samii M, Rosahl SK, Tatagiba MS (2001) Microsurgical removal of a petrous apex meningioma after stereotactic radiation: technical case report. *Neurosurgery* 49: 216–219
44. Shuto T, Inomori S, Fujino H, Nagano H, Hasegawa N, Kakuta Y (2005) Cyst formation following gamma knife surgery for intracranial meningioma. *J Neurosurg* 102 [Suppl]: 134–139
45. Simpson D (1957) The recurrence of intracranial meningiomas after surgical treatment. *J Neurochem* 20: 22–39
46. Sindou M (2001) Meningiomas invading the sagittal or transverse sinuses, resection with venous reconstruction. *J Clin Neurosci* 8 [Suppl 1]: 8–11
47. Sindou MP, Alaywan M (1998) Most intracranial meningiomas are not cleavable tumors: anatomic-surgical evidence and angiographic predictability. *Neurosurgery* 42: 476–480
48. Stafford SL, Perry A, Suman VJ, Meyer FB, Scheithauer BW, Lohse CM, Shaw EG (1998) Primarily resected meningiomas: outcome and prognostic factors in 581 Mayo Clinic patients, 1978 through 1988. *Mayo Clin Proc* 73: 936–942
49. Stafford SL, Pollock BE, Foote RL, Link MJ, Gorman DA, Schomberg PJ, Leavitt JA (2001) Meningioma radiosurgery: tumor control, outcomes, and complications among 190 consecutive patients. *Neurosurgery* 49: 1029–1037
50. Urbanczyk C, Desal H, Ibrahim MR, Guillon B (2005) The finding of incidental intracranial lesions with magnetic resonance imaging. *Rev Neurol (Paris)* 161: 862–867
51. Whittle IR, Smith C, Navoo P, Collie D (2004) Meningiomas. *Lancet* 363: 1535–1543
52. Zentner J, Meyer B, Vieweg U, Herberhold C, Schramm J (1997) Petroclival meningiomas: is radical resection always the best option? *J Neurol Neurosurg Psychiatry* 62: 341–345

Comment

Primary treatment of small (≤ 30 mm) meningiomas – microsurgery (MS) or stereotactic radiotherapy (SRT) given in one session ('radio-surgery' or SRS)? Small meningiomas are problematic in two ways. Firstly, MRI and CT cover European aging populations and increasingly disclose incidental meningiomas that are quite frequent in population, found in 1.4% of autopsies [1]. Secondly, neurosurgeons have to admit that, taken all variables together, there are cases which SRS serves equally or better than MS – but which cases and in whose hands?

Personally, doing microsurgery and radiosurgery, the distinction is clear in meningiomas that affect the optic nerve(s): primary MS in the suprasellar (planum sphenoidale, tuberculum sellae, clinoid process) meningiomas – fractionated SRT in the optic nerve sheath meningiomas. I also favour MS in the foramen magnum meningiomas that dangerously pinch eloquent neural tissue. In small convexity tumours, I resent the idea of SRS over MS, if the patient has symptoms (e.g., epilepsy), or he or she is expected to live long, or there is a hyperdense signal in the adjacent brain in T2 images, or the meningioma is not calcified. Having been the darling subject of many a neurosurgical congress over less showy topics, meningiomas involving the cavernous sinus and the clival area have become a grey area because MS, even in the best of hands, appears to endanger the cranial nerves while tumour tissue often left behind. In our population-based practice, we do not go inside the cavernous sinus but leave that compartment for postoperative or primary SRS.

In a retrospective analysis, the authors compared the results of MS in small meningiomas in their institute (201 patients between 1992 and

2002) to those of SRS in the literature. This is not a randomized trial of adequate power, nor free of selection if the author's institute does not hermetically serve a given population. Nevertheless, the authors are to be congratulated for a purposeful analysis, with the presence of preoperative symptoms (–/+) and the location (group I: convexity, parasagittal, lateral sphenoid; group II: falx, frontobasal, medial sphenoid, parasellar, tentorial; group III: cavernous sinus, petroclival, petrosal, CP angle, foramen magnum) as the main variables. There was no mortality, and MS provided excellent results in small groups I and II meningiomas – which are what we should expect from the European services. In small group III meningiomas, however, permanent neurological morbidity developed in 40%, and the removal was not complete in 20%.

This is a timely analysis to be further masticated by the microsurgeons and the radiosurgeons – future skull base neurosurgeons should master the both roles. Cell and molecular biology should reveal targets for future therapies that would take care of the worst of meningiomas.

Reference

1. Rausing A, Stenflo J (1970) Intracranial meningioma – a population study of ten years. *Acta Neurol Scand* 46: 102–110

Juha E. Jääskeläinen
Kuopio, Finland

Correspondence: Michael Reinert, Department of Neurosurgery, Inselspital Bern, University of Bern, 3010 Bern, Switzerland. e-mail: michael.reinert@neurochirurgie-bern.ch