

Morphological and morphometric features of scaphoid bone in north eastern population, India

C Purushothama,¹ RK Sarda,¹ A Konuri,¹ BK Tamang,¹ C Gupta² and BV Murlimanju³

Department of Anatomy, ¹Sikkim Manipal institute of Medical Sciences, 5th Mile, Tadong, East Sikkim, India, ²Kasturba Medical College, Manipal, Karnataka, India, ³Kasturba Medical College, Mangalore, Karnataka, India.

Corresponding author: Dr. Chethan P, Assistant Professor, Department of Anatomy, Sikkim Manipal Institute of Medical Sciences, 5th Mile, Tadong, East Sikkim, India; e-mail; chethanpster@gmail.com

ABSTRACT

A study was performed to analyse the morphometry and morphological variants of adult scaphoid bone in Sikkimese population of North Eastern India. The study included 100 dry human scaphoid bones. The bones which had previous signs of fracture were excluded. The morphometric parameters were measured with vernier caliper of 0.02 mm accuracy; the circumferences were measured by placing a thread around them and measuring its length. A magnifying lens was used to observe the number of foramina. From our observations, 22 (44%) of the left scaphoid were having conical shape and 28 (56%) were pyramidal in shape. On the right side, 36 (72%) had conical shape and 14 (28%) were pyramidal. All the bones had waist, except one right sided scaphoid (2%) in which the waist was absent. The scaphoid had main dorsal sulcus in 63% of cases, 29% had two dorsal sulci and 6% had Y shaped sulci. The dorsal sulcus was absent in 3 cases (1 on left side and 2 on the right side). All the scaphoids had a minimum of one foramen in the main dorsal sulcus and 92% had more than one foramen. The present study has provided the additional information on morphology and morphometry of adult human scaphoid bones in north eastern population, India. We believe that the data obtained from the present study are important for the hand surgeons and radiologists. The details obtained will also be helpful for the morphologists and clinical anatomists.

Keywords: scaphoid, morphology, morphometry, shape, tubercle

INTRODUCTION

A literature search revealed limited documentation of normal, variant morphological and morphometric measurements and there was no validation of scaphoid anatomy in north eastern population, India. The scaphoid is a carpal bone which is unique in its shape and function. It has a three-dimensionally oblique orientation and performs a unique function as a mechanical link between the distal and proximal carpal rows on the radial aspect.¹ The scaphoid fracture occurs in young healthy individuals² and is the most commonly fractured bone of the wrist (50%-80% of all carpal bone injury).³ The complex shape of scaphoid and its orientation within the carpus makes the radiological interpretation of scaphoid anatomy difficult.⁴ The goals of reconstructive surgery for scaphoid fracture nonunions include restoration of normal scaphoid length and shape by use of the contralateral scaphoid bone as a geometric model.⁵ The Osteological description of the scaphoid bone in anatomical texts are virtually confined to the articular facets.⁶ Surgical reconstruction of scaphoid non union aims to restore the bone's normal shape, but there is no definition of the normal scaphoid or its variation.⁷ As there is limited data available on the morphology and morphometry of scaphoid in sikkimese population, this study was undertaken.

MATERIALS AND METHODS

The study included one hundred dry human scaphoid bones (50 left and 50 right) which were obtained from the department of anatomy, Sikkim Manipal institute of medical sciences, Sikkim, India. The scaphoid bones were of unknown sex, age, religion and race. The bones which had previous signs of fracture were excluded from the present study. The side determination of the bones was done by anatomical features. The morphometric parameters were measured using a vernier caliper of 0.02 mm accuracy. The circumferences were measured by placing a thread around the scaphoid and measuring the threads length. A hand lens was used to count the number of foramina. All the parameters were assessed by two observers to avoid any bias in the measurements.

Morphological parameters: The scaphoid tubercle was assessed based on its shape (either conical or pyramidal) (Fig. 1). The presence of tubercle, waist, dorsal sulcus, ridge for the origin of scaphocapitate ligament (SCIL) and the sulcus for flexor carpi radialis (FCR) were noted (Fig. 2). Dorsal sulcus was assessed by its presence, shape and number (primary or secondary sulci). The foramina in the main sulcus and secondary sulcus were noted. The foramina in the proximal and distal regions were counted as well. The shapes of the scapholunate joint surface were recorded as half moon or crescent (Fig. 3).

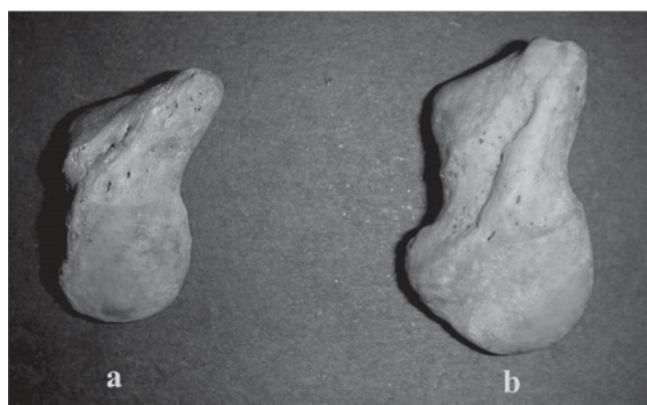
Table-1: Showing the frequency of shape of the tubercle

	left (n=50)	right (n=50)
conical	22	36
pyramidal	28	14
total	50	50

Morphometric parameters: The length of the scaphoid was calculated by distance between the most prominent points of proximal articular surface and the tubercle (Fig.2). The width of scaphoid was measured at three different regions (proximal, waist and distal). The proximal width was defined as the maximum width towards the proximal articular surface distal to the waist. Width of the waist were calculated at the narrowest angle of the waist. The distal width were calculated at the widest part of the distal part of the bone. The length and width of the dorsal sulci were also measured. The circumference of the waist were measured at its narrowest point, circumference of the tubercle were measured at its base. The primary and secondary heights of the tubercle were measured. Primary height of the tubercle was defined as the distance between the most prominent point of tubercle and the intersection of the anterior and superior ridges of the scapholunate articular surface. The secondary height of the tubercle was defined as the most prominent point of the tubercle and the deepest point of the waist. The statistical analysis of the morphometric parameters was performed using the chi-square test, paired t test and by cross tabulation, each variable was investigated and correlated individually with reference to the side.

RESULTS

Morphological parameters: The tubercle was present in all the scaphoid bones. Among the left scaphoid bones, 22 were of conical shape and 28 were pyramidal shape. Similarly 36 right scaphoid tubercles were of conical shape and 14 were of pyramidal shape (Table-1). Tubercles were compared on both sides by Chi-square Test (8.046) and p value was significant (0.005). The

**Fig. 1.** Shape of the tubercle. (a) conical. (b) pyramidal

waist was absent in 1 scaphoid of right side, rest all the bones had waist (Fig.4). The presence or absence of dorsal sulcus was observed, it was absent in 1 scaphoid of left side and 2 on the right side (Table-2).

The shape of scapholunate articular surface was noted as either half moon or crescentic shape. Among them, 38 scaphoids of left side had the shape of half moon and 12 were of crescentic. Similarly 36 of right side were of half moon and 14 were of crescentic. The shape and variations of the dorsal sulcus were noted. Most of the scaphoid had main dorsal sulcus 63%. In contrast, 29% had two dorsal sulci and 6% had a Y shaped sulcus (Fig. 4). Foramina in the dorsal sulcus were counted, all the scaphoids had a minimum of one foramen in the main dorsal sulcus and 92% had more than one foramen (Fig. 5). All scaphoids which presented with secondary sulci had a foramen in it. The ridges for the origin of scapholunate interosseous ligament were present in 41 scaphoids of left side and 40 of right side. Sulci of flexor carpi radialis were also seen and it was present in 38 scaphoids of left side and 42 of right side. Comparison of other morphological features were not significant ($p=0.996$).

Morphometric parameters: The morphometrical comparison was done on both sides of the bone (Table-3). The circumference of waist was statistically significant ($p=0.041$). The secondary height of the tubercle ($p=0.018$), dorsal length ($p=0.009$) and width of the dorsal sulcus ($p=0.001$) were significant. The mean values and standard deviation for the Morphometric parameters are shown in Table-3.

DISCUSSION

The present study observed that tubercles were present in all scaphoids and the height and circumference of base of the tubercle were strongly correlating with each other. This may explain the relatively low incidence of fractures of tubercles,⁷ which provides insertion for the flexor retinaculum and few fibres of abductor pollicis brevis muscle.⁸ Ceri *et al*,⁷ in their study found all the

Table-2: Presence of morphological features

	Left (n=50)	Right (n=50)	Total (n=100)
Tubercle	50	50	100
Waist	50	49	99
Dorsal sulcus	49	48	97
Ridge for the origin of SCIL	41	40	81
Sulcus of FCR	38	42	80

SCIL: Scaphocapitate interosseous ligament, FCR: Flexor carpi radialis tendon

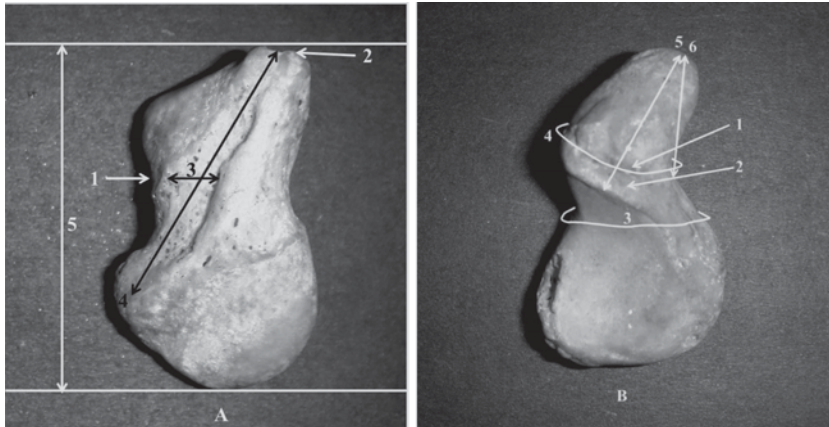


Fig. 2. Some of the morphological and morphometric parameters used in this study. A (1) scaphoid waist. (2) tubercle. (3) width of dorsal sulcus. (4) length of dorsal sulcus. (5) scaphoid length. B (1) ridge for the origin of scaphocapitate ligament. (2) sulcus for flexor carpi radialis. (3) waist circumference. (4) tubercle circumference. (5) primary height of the tubercle. (6) secondary height of the tubercle.

scaphoids to have tubercles and dorsal sulcus. The scaphoid waist was absent in one specimen of right side. The waist serves as an important anchoring point for several ligamentous attachments.⁹ As the waist provides several ligamentous attachments in its absence the attachments could be weak, this may explain in the absence of waist there could be more ligamentous injuries.

The dorsal sulcus contains numerous nutrient foramina,¹⁰ the foramina in the dorsal sulcus are thought to be related to the vascular supply of scaphoid.⁷ All the scaphoid had a minimum of one foramen in the main dorsal sulcus and 92% had more than one foramen. The scaphoids presented with secondary sulci had more than one foramen in it. The foramina which were assessed at proximal region were present only in 15%, this may explain the occurrence of non union and avascular

necrosis after proximal fracture.¹¹ Ceri *et al*,⁷ in their study found at least one foramen in the main dorsal sulcus and 88% had more than five foramen, 18% had no foramen in the proximal region. The ridges for origin of scaphocapitate interosseous ligament were present in 41 scaphoids of left side and 40 of right side. Ceri *et al*,⁷ observed SCIL ridge in 80 specimens of right and 83 in left side of a total of 200 scaphoids. The absence of ridge could indicate weak attachment of SCIL ligament or absence of this ligament, further making the scaphocapitate joint weak. Sulci of flexor carpi radialis were present in 38 scaphoids of left side and 42 of right side. Comparison of morphological

features of both sides other than shape of tubercles were not significant ($p=0.996$).

The mean length of the scaphoids of left side was 22.33 mm and of right side was 22.65 mm with a standard deviation of 2.406 and 2.067 respectively. Internal fixation has become a well-established alternative to casting for acute scaphoids fractures.¹² Screw design has evolved and several different types of screws of varying sizes are now available. Knowing the mean length in a population helps in knowing to assess the screw length for internal fixation pre operatively. Considering the fact that most population are right dominant, this may also explain the mean length of right scaphoids to be more than left in the present study. Similarly the waist circumference was statistically significant and relatively more than left thus explaining greater force transmission on dominant side according to Wolfe's law.⁷

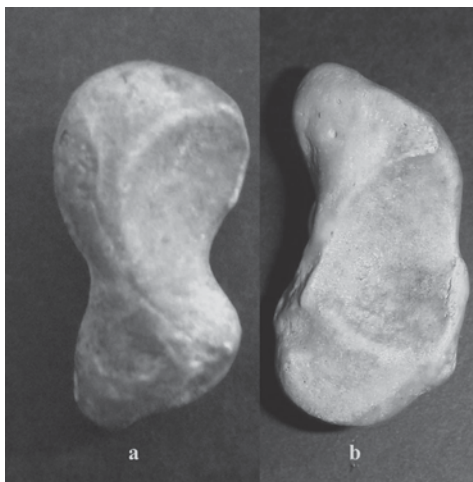

Fig. 3. Shape of the scapholunate joint surface. (a) crescent (b) half moon

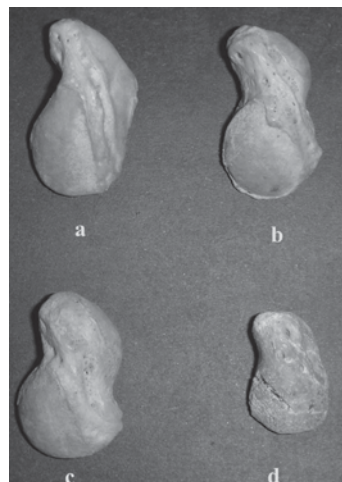


Fig. 4. Variations of dorsal sulci. (a) single main dorsal sulcus. (b) two separate sulci. (c) Y shaped sulci. (d) absence of sulci

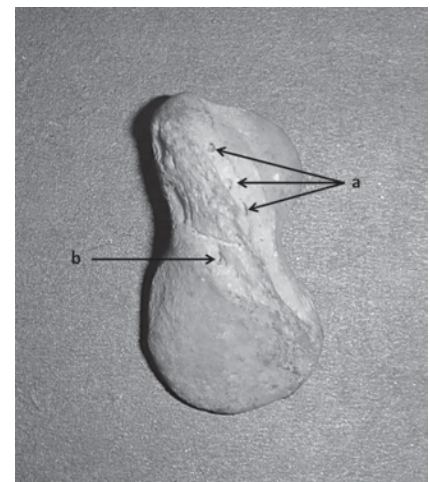


Fig. 5. Nutrient foramina in sulci. (a): nutrient foramina in main dorsal sulci, (b): nutrient foramina in secondary sulci.

Table-3: Morphometric parameters (mean \pm SD in mm)

	Left	Right
Length	22.33 (2.406)	22.65 (2.067)
Waist circumference*	30.06 (3.016)	31.35 (3.104)
Tubercle circumference	25.67 (4.339)	26.22 (3.139)
Proximal width	11.53 (1.725)	12.00 (1.442)
Waist width	06.88 (1.583)	07.06 (1.448)
Distal width	10.92 (1.383)	10.69 (1.643)
Primary height of tubercle	09.41 (1.359)	09.18 (1.322)
Secondary height of tubercle*	06.45 (1.222)	05.96 (1.183)
Length of Dorsal sulcus*	16.12 (3.037)	17.92 (3.078)
Width of dorsal sulcus*	01.86 (0.872)	02.53 (0.946)

*significantly different

Future implications of the present study include clinical and biomechanical correlation with the living subjects. The radiological morphometry can be done with the CT scans and the data of the present study can be compared with that of radiological. The limitation of the present study includes the lack of knowledge about age and sex of the bones. However, present study has provided additional information on morphology and morphometry of adult human scaphoid bones in Sikkimese population of North Eastern India. The data obtained from the present study are important for the, orthopedicians, hand surgeons and radiologists. The details obtained will also be helpful for the morphologists and clinical anatomists.

REFERENCES

1. Patterson R, Moritomo H, Yamaguchi S *et al.* Scaphoid anatomy and mechanism: update and review. *Operative Tech Orthoped* 2003; 13: 2-10.
2. Bretlau T, Christensen OM, Edstrom P *et al.* Diagnosis of scaphoid fracture and dedicated extremity MRI. *Acta Orthopaedica Scandinavica* 1999; 70: 504-8.
3. Larsen CF, Brondum V, Skov O. Epidemiology of Scaphoid Fracture in Odense, Denmark. *Acta Orthopaedica Scandinavica* 1992; 63: 216-8.
4. Compson JP, Waterman JK, Heatley FW. The radiological anatomy of the scaphoid: Part 2: Radiology. *J Hand Surg Brit* 1997; 22: 8-15.
5. Smith DK. Anatomic features of the carpal scaphoid: validation of biometric measurements and symmetry with three-dimensional MR imaging. *Radiol* 1993; 187: 187-91.
6. Williams PL, Bannister LH, Berry MM *et al.* (eds) Gray's anatomy, 38th edn. Edinburgh: Churchill Livingstone 1995; 648.
7. Ceri N, Korman E, Gunal I *et al.* The Morphological and morphometric features of the scaphoid. *J Hand Surg* 2004; 29: 393-8.
8. Clemente CD. Gray's anatomy, 30th ed. Philadelphia: Lea, Febiger 1985: 251.
9. Berger RA. The Ligaments of the wrist. A current overview of anatomy with considerations of their potential functions. *Hand Clin* 1997; 13: 63-82.
10. Bongumill G. Anatomy of the wrist. In: Lichtman D (edit). The wrist and its disorders, Philadelphia: WB Saunders 1988; 14-26.
11. Oblez BE, Halbstein BM. Non-union of fractures of carpal navicular. *J Bone Joint Surg* 1938; 20: 424-8.
12. Heinzeimann AD, Archer G, Bindra RR. Anthropometry of Human Scaphoid. *J Hand Surg* 2007; 32: 1005-8.