

Research article

MORPHOLOGICAL FEATURES AND KIT RECEPTOR EXPRESSION IN CANINE CUTANEOUS MAST CELL TUMOR AND SYSTEMIC MASTOCYTOSIS

MARINKOVIĆ Darko^{1*}, MILČIĆ-MATIĆ Natalija², JOVANOVIĆ Milan², VUČIĆEVIĆ Ivana¹, NEŠIĆ Slađan¹, ANIČIĆ Milan¹, ALEKSIĆ-KOVAČEVIĆ Sanja¹

¹Department of Pathology, Faculty of Veterinary Medicine, University of Belgrade; ²Department of Equine, Small Animals, Poultry and Wild Animal Diseases, Faculty of Veterinary Medicine, University of Belgrade

(Received 30th March; Accepted 23th April 2015)

Mast cell neoplasia in dogs can occur in two different forms: common as cutaneous tumor, or less common as a systemic form of neoplastic mast cell proliferation – systemic mastocytosis. The aim of this study was to compare the histological and cytological features, KIT receptor expression and presence of c-KIT proto-oncogene mutations in neoplastic cells of dogs with canine cutaneous mast cell tumor (CMCT) and systemic mastocytosis. Microscopical examination of the cytological smears obtained from all selected dogs revealed that cellular specimens were constituted mostly of round cells with a central nuclei and fine to coarse purple cytoplasmic granules. Histopathological examination of skin samples of dogs with CMCT and a dog with systemic mastocytosis showed proliferation of the neoplastic mast cells in the superficial and/or deep dermis. Similar findings were observed in tissue samples derived from lymph nodes, spleen, liver, myocardium and kidneys of a dog with systemic mastocytosis. Three dogs with high grade CMCT as well as one dog with systemic mastocytosis showed cytoplasmic CD117 expression, while 3 dogs with low grade CMCT, had membranous expression of CD117. Based on our study, histological features and cytoplasmic CD117 expression in neoplastic cells of dogs with systemic mastocytosis are similar to those in dogs with high grade CMCTs. Nevertheless, mutations of c-KIT proto-oncogene were not found in tumor samples either from dogs with CMCT or dog with systemic mastocytosis.

Key words: dog, systemic mastocytosis, cutaneous mast cell tumor, KIT receptor expression, histopathology, cytology

INTRODUCTION

Mast cell disorders have been documented both in humans and animals and are defined as an abnormal accumulation of mast cells in one or more organs. Neoplastic disorders of mast cells are rare and almost always benign in humans [1] comparing to animals in

*Corresponding author: e-mail: darko@vet.bg.ac.rs

which they represent ubiquitous neoplasms with species variation of localization and biological behavior. They are common neoplasms in dogs, most often seen in older animals. Boxers, Pugs, Boston terriers, Weimaraners, Labrador retrievers and Golden retrievers have a high propensity for cutaneous mast cell tumors (CMCT) [2]. Systemic mastocytosis (systemic mast cell neoplasia) is a term used to describe the proliferation and invasion of neoplastic mast cells in several tissues, such as subcutis, lymph nodes, internal organs and bone marrow, with or without concurrent mast cell leukemia. This type of mast cell neoplasia is less frequent comparing to cutaneous mast cell neoplasia, which represents one of the commonest skin tumors in dogs [3]. Mast cell tumors were most often graded histologically according to the grading system described by Patnaik *et al.* [4], and nowadays more often by the grading system proposed by Kiupel *et al.* [5]. Patnaik grading system is based on level of differentiation, cellularity, cellular morphology, mitotic index and tissue reaction and it has been widely used [6].

According to the Kiupel grading system, high-grade MCTs include neoplasms with at least one of the following features: at least 7 mitotic figures in 10 high power fields (hpf); at least 3 multinucleated cells in 10 hpf; at least 3 bizarre nuclei in 10 hpf; or at least 10% karyomegalic neoplastic cells. All other tumors are considered low grade [5].

Recently, the KIT receptor expression is considered to be the most useful predictive marker [7,8]. Non-neoplastic mast cells as well as some neoplastic mast cells have only membranous KIT localization while in many neoplastic mast cells KIT accumulates in the cytoplasm [8-10]. The correlation between the expression of the KIT receptor and the histologic grade of CMCTs seems to be very important [11,12] and some authors believe that there is a correlation between the degree of CMCT differentiation and KIT expression pattern [9]. A significant association between the aberrant KIT localization and presence of c-KIT proto-oncogene mutations was identified in dogs with CMCTs. However, mutations were not present in all CMCT samples with aberrant KIT expression [13].

The aim of this study was to compare the histological and cytological features, KIT receptor expression and presence of c-KIT proto-oncogene mutations in neoplastic cells of dogs with CMCT and systemic mastocytosis.

MATERIAL AND METHODS

Animals

A 12-year-old intact female mixed breed dog with multiple cutaneous masses and six dogs of different breeds, sex and age with single cutaneous mast cell tumor were selected from the Faculty of Veterinary Medicine, University of Belgrade (Table 1). Skin without dermal lesions sampled at necropsy from 3 adult dogs was used as the control.

Table 1. Breed, gender, age and type of examined dogs with MCT

Dog No.	Breed	Gender	Age, years	Type of MCT
1.	Mixed breed	female	12	Systemic mastocytosis
2.	German boxer	male	8.5	CMCT
3.	Golden retriever	female	8	CMCT
4.	Golden retriever	male	11	CMCT
5.	Maltese	female	8	CMCT
6.	American bulldog	male	10	CMCT
7.	Golden retriever	female	11	CMCT

DNA Isolate

A known dog DNA isolate containing the c-KIT⁺ mutation was used as the positive control. DNA isolate originates from the College of Veterinary Medicine, Department of Pathobiology and Diagnostic Investigation from the Michigan State University, USA.

Clinical examination

Complete clinical evaluation (anamnesis, physical and dermatological examination) was done. Informed consent was obtained from all the dog owners as well as anamnestic data. An ultrasonographic evaluation of the abdomen was performed in all animals included in this study.

Haematology

Complete blood analysis was performed on the blood sample with EDTA from the dog with systemic mastocytosis. Analysis was conducted on the ProCyte DX Hematology Analyzer (IDEXX Laboratories, USA). Biochemical analyses of blood serum were performed using the VetTest Chemistry Analyzer (IDEXX Laboratories, USA).

Fine needle aspiration

Fine needle aspiration biopsy for each patient was preliminarily performed on the skin nodule using a 22 gauge needle. Cytological smears were made, dried and stained with Diff Quick (Hemacolor® Merck) and Toluidine blue staining methods.

Histopathology

Skin samples obtained with punch biopsy as well as skin or other tissue samples obtained by surgical removal or on necropsy were fixed in 10% buffered formalin for 48 hours. After standard processing in an automated tissue processor, tissue samples were embedded in paraffin blocks. Initial diagnosis and grading of tumors had been undertaken on hematoxylin and eosin (HE) stained sections. Toluidine blue staining

(TB) was performed on all sections as the confirmative histochemical method. Mast cell tumor histopathological features, such as number of mitotic figures, presence of multinucleated cells, bizarre nuclei and karyomegaly were evaluated on the HE stained sections. Each parameter was observed on 10 high power (400x) fields (hpf).

Immunohistochemical staining

Formalin fixed and paraffin embedded tissue samples were cut to a 4 µm sections and deparaffinized in xylene, rehydrated in graded alcohol and rinsed in distilled water. Immunohistochemical methods were performed with CD117 polyclonal rabbit anti-human antibody (DAKO, A4502). Antigen retrieval was achieved by heating with buffer citrate pH 6.0 for 20 minutes [14]. Endogenous peroxidase activity was blocked by treating slides with hydrogen peroxide in methanol (3%) for 15 minutes. Nonspecific binding of secondary antibodies was minimized by incubation with 50% normal goat serum in PBS for 20 minutes. After antigen retrieval and inactivation of endogenous peroxidase, the sections were incubated with primary antibody at dilution 1 : 400 in PBS for 1 hour in a moist chamber at 22±3°C. A streptavidin–immunoperoxidase staining procedure was used for immunolabeling. The immunoreaction was visualized with DAB+ (3,3'-diaminobenzidine tetrahydrochloride, DAKO, K3468). Sections were counterstained with Mayer's hematoxylin. Aqueous medium glycergel (DAKO, C563) was used on the stained sections for mounting. Finally, the CD117 positive cells were observed under the light microscope in hpf. Skin sections not treated with the primary antibody were used as the negative control. The positive immunohistochemical control included the already confirmed canine MCT.

Polymerase chain reaction (PCR)

DNA was extracted from the paraffin blocks using the commercial set „KAPA Express Extract Kit” (Cat. No KK7152, Kapa Biosystems, Cape Town, South Africa) according to the manufacturer's instructions. PCR amplification was performed as previously described by Jones *et al.* [15]. A known dog DNA isolate containing c-KIT mutation was used as the positive control.

RESULTS

Clinical findings in dog with systemic mastocytosis

Past medical history did not include any major illnesses and vaccination was routinely performed. One month after surgical removal of a 2 cm wide red hairless lump from the tarsal region of the hind right leg, similar skin changes, first in the head and neck region, and later in other body regions, particularly on the ventral part of the abdomen and thorax appeared. These changes were extremely prone to hemorrhages. At that time the dog was treated with local and systemic antibiotics and corticosteroids which improved the condition. After exclusion of the corticosteroids the condition got

worse. Routinely performed skin swabs and scarification did not reveal any pathogen microbes or skin parasites. After constant antibiotic therapy and local treatment of the lesions, the condition did not improve.

Physical examination revealed fairly normal levels of several parameters: body temperature of 38.2°C, heart rate 96, respiration rate 32 and capillary filling time 2 seconds. All visible mucosal surfaces were hyperemic and a mild swelling of nasal and oral mucosa was evident. Whitish vaginal discharge was also present. The dog was oriented with no signs of aggression. Peripheral lymph nodes were palpable, the size of submandibular lymph node was 1x2 cm, and the prescapular, axillary, inguinal and popliteal lymph nodes were 1x1 cm large. Lung auscultation revealed a sharp vesicular respiration sound, and heart auscultation revealed a rhythmic pace without heart murmurs. On the entire body surface (head, neck, thorax and abdomen) nodules and plaques of different size were present, and a number of them were hemorrhagic (Fig. 1a). Also on the ventral part of the thorax and abdomen in the mammary region one large hard fused plaque was palpable. After hair clipping these skin changes were extremely erythematous and prone to hemorrhage.

Blood testing showed mild anemia (erythrocytes $4.05 \times 10^{12}/l$, Hg 86g/l, HT 25.86%) while other erythrocytic indices were in the physiological range for an adult dog (MCV 64fl, MCH 21.2pg, MCHC 332g/l, RDW 23.7%). Also a low platelet count was recorded (platelets $112 \times 10^9/l$). White blood count was within the physiological range (total WBC $5.74 \times 10^9/l$), while the leukocyte formula showed distinctive lymphocytosis (lymphocytes $0.1 \times 10^9/l$).

Biochemical analysis of blood serum revealed that values of all parameters were in the physiological levels characteristic for adult dogs.

Homogenous enlargement of the spleen, enlargement of the abdominal lymph nodes, presence of anechogenic accumulation of liquid content in the left uterine horn and echogenic accumulation in the region of the mammary complexes were noticed ultrasonographically.

Cytological findings

Microscopical examination of the cytological smears obtained from all selected dogs (one with systemic mastocytosis and six with CMCT) revealed that the cellular specimen constituted mostly of round cells with central nuclei and fine to coarse purple cytoplasmic granules. A large number of eosinophils and degenerated neutrophils were also present in the cytological smears.

Macroscopic changes

On necropsy of the dog with systemic mastocytosis, multiple nodules were observed on various regions of the skin and subcutis. Most of those nodules were hyperemic and often with hemorrhages. Peripheral, abdominal and mesenteric lymph nodes were enlarged, and marked swellings of the subcutis on head, neck and mammary region

were noticed. Nodules of different size were also observed on the myocardium. The spleen was diffusely enlarged (Fig. 1b) and the liver and kidneys were enlarged, pale and fragile. The lungs were edematous and hyperemic. Multiple ulcerations were noticed on the pyloric region of the stomach. The uterus was enlarged and filled with pus.

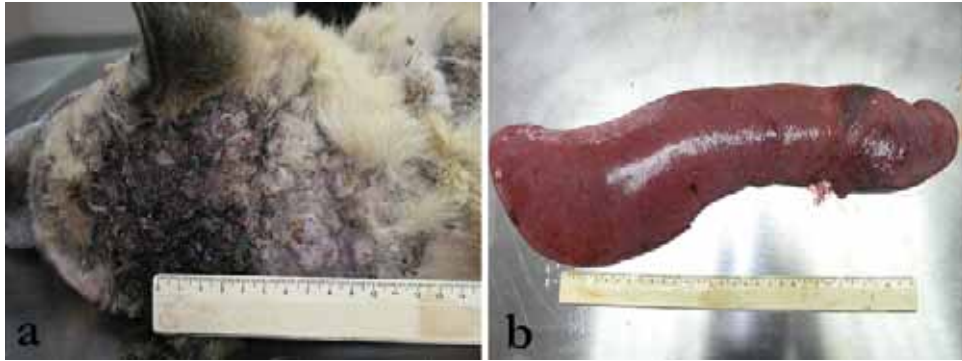


Figure 1. Macroscopic changes of the skin and spleen of the dog with systemic mastocytosis: **a)** Neoplastic nodules on the skin; **b)** Enlarged spleen

Skin nodules from all dogs included in this study, as well as other tissue samples from the dog with suspected systemic mastocytosis, were collected for histopathology.

Histopathological and immunohistochemical findings

Histopathological examination of skin samples of dogs with CMCT and of the dog with systemic mastocytosis showed proliferation of neoplastic mast cells in the superficial and/or deep dermis. Similar findings were observed in tissue samples derived from lymph nodes, spleen, liver, myocardium and kidneys of the dog with systemic mastocytosis. These cells were round to polygonal with a round central to slightly eccentric nuclei, sometimes with several nuclei. Pale pink cytoplasm was filled with light gray/bluish granules in HE stained samples, or purple granules in TB stained samples. Mitotic figures were also observed. According to these facts the dog was diagnosed with systemic mast cell neoplasia, a mast cell tumor of high grade malignancy (grade III Patnaik system, or high grade Kiupel system) (Fig. 2a, b, c). Out of 6 dogs with cutaneous mast cell tumor, 3 dogs had low grade malignancy tumors (Fig. 3a) and 3 dogs had high grade malignancy tumors (Fig. 4a) according to Kiupel grading system.

Three dogs with high grade CMCT as well as one dog with systemic mastocytosis showed both membranous and cytoplasmic CD117 expression (Fig. 2d, 4b), while another 3 dogs with low grade CMCT, had only the membranous expression of CD117 (Fig. 3b). The presence of two bands of ~191 bp and of ~250bp, characteristic for the samples with the mutation, was not detected in any of the tested CMCT samples. The lack of two bands indicates the absence of c-KIT mutations in dogs with CMCTs as well as in the dog with systemic mastocytosis.

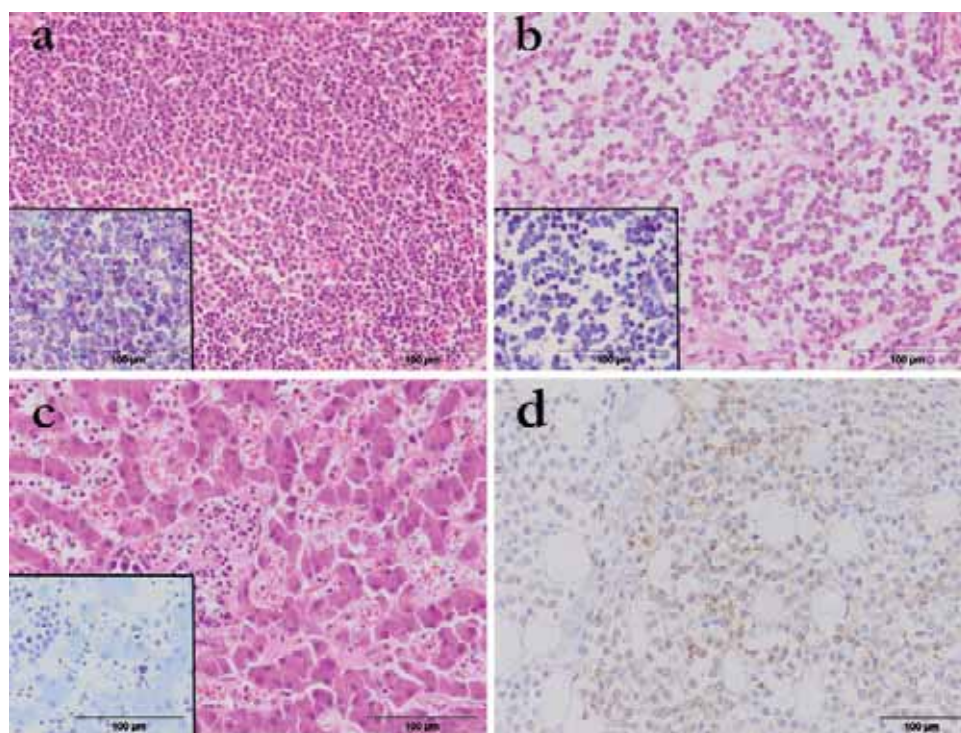


Figure 2. Microscopic and immunohistochemical changes in the visceral organs and subcutis of the dog with systemic mastocytosis: **a)** Tumor cells in the spleen, HE. Insert: Cytoplasmic granules in the mast cells, TB; **b)** Tumor cells in the lymph node, HE. Insert: Cytoplasmic granules in the mast cells, TB; **c)** Tumor cells in the liver, HE. Insert: Cytoplasmic granules in the mast cells, TB; **d)** Cytoplasmic KIT-staining pattern in tumor cells of the subcutis, CD117, LSAB2.

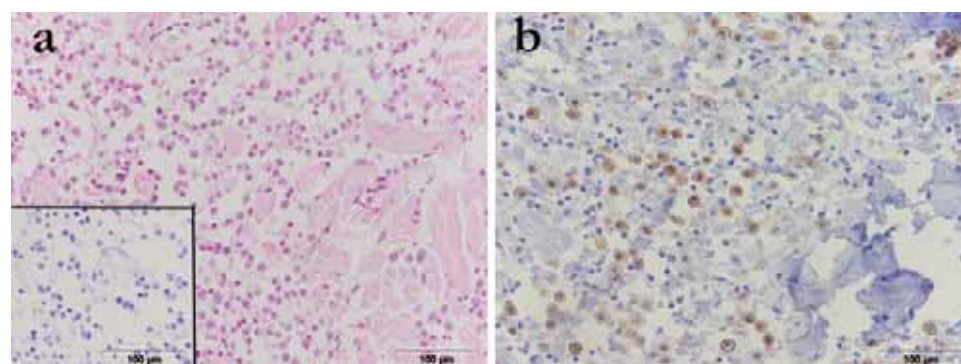


Figure 3. Microscopic and immunohistochemical changes in the dog skin with low grade mast cell tumor: **a)** Tumor cells are loosely arranged and separated by collagen bundles, HE. Insert: Cytoplasmic granules in the mast cells, TB; **b)** Membranous KIT-staining pattern, CD117, LSAB2

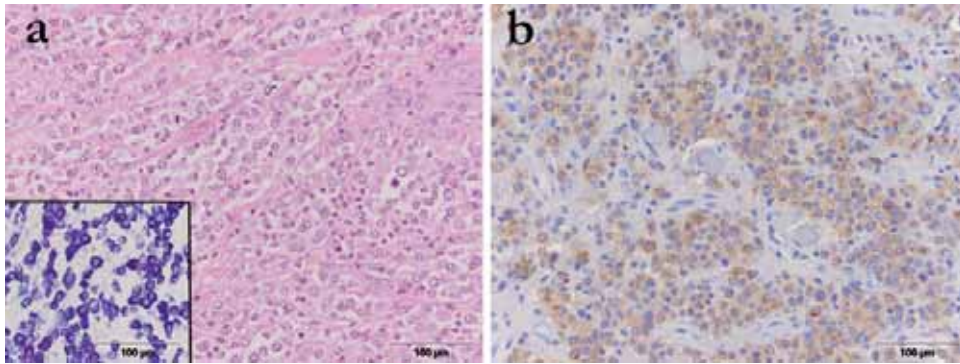


Figure 4 Microscopic and immunohistochemical changes in the dog skin with high grade mast cell tumor: **a)** Pleomorphic low granulated cells with mitotic figures, HE. Insert: Degranulated mast cells, TB; **b)** Cytoplasmic KIT-staining pattern, CD117, LSAB2

DISCUSSION

In domestic animals mast cell neoplasia manifests basically in two forms, as a cutaneous neoplasia in the skin and subcutis, or as a systemic mast cell neoplasia (systemic mastocytosis), i.e. the form in which neoplastic mast cells invade different internal organs. The cutaneous form is common in older dogs with breed predisposition of Boxers, Pugs, Boston terriers, Weimaraners, Labrador retrievers and Golden retrievers [2,16] and the second, systemic form is more frequent in cats, but it can also occur in dogs. However, this systemic form can be associated with concurrent mast cell leukemia [17]. In some cases mastocytosis can occur in dogs with the cutaneous form, but more often it occurs in dogs with the systemic form of mast cell neoplasia [17,18]. Macroscopic examination of the dog with systemic mastocytosis revealed multiple nodules on various regions of the skin and subcutis, often hyperemic and with hemorrhages. Beside findings on the skin and subcutis, generalized lymphadenopathy, diffuse enlargement of the spleen, liver and kidneys as well as nodules on the myocardium were observed as reported previously [18,19]. However, findings of neoplastic mast cells in other organs (such as lymph nodes, liver, spleen, myocardium and kidneys), with or without concurrent mastocytosis, is characteristic for systemic mastocytosis. Different clinical signs and paraneoplastic syndrome can occur as a consequence of releasing bioactive substances (histamine, heparin, enzymes, prostaglandins, hemotactic factor for eosinophiles etc.) from the granules of the mast cells [20,21]. These signs can include hemorrhagic diathesis, tissue erythema and/or oedema, allergic reactions, anorexia, and gastrointestinal ulceration (especially gastric) followed by haematemesis and diarrhea as well as abdominal pain [18,22]. Subsequently, multiple gastric ulcerations were present in the dog with systemic mastocytosis in our study. This type of lesion occurs as a consequence of constant stimulation of H_2 receptors of parietal cells in the gastric mucosa by a high level of histamine released from the cytoplasmic granules of mast cells [23,24].

Usually, suspicion of mast cell tumor is made, as in this case, based on clinical signs, and especially on the characteristic appearance of mast cells on the Diff Quick stained cytological smears obtained from skin nodules [25]. Nevertheless, definitive diagnosis of the mast cell tumor is based on the histopathological examination of tissue samples of the skin and different organs as was observed in the dog with systemic mastocytosis from our study. All neoplastic cells showed signs of marked polymorphism. Based on our results, in all three cases of well differentiated CMCTs, the prominent findings were: round and monomorphic mast cells arranged in rows or small groups, separated by collagen fibers, the nuclei were round with condensed chromatin and intracytoplasmic granules were evident. Mitotic cells were absent or rarely present and eosinophilic granulocytes were observed in the neoplastic tissue. On the other hand, the other three dogs had less differentiated mast cell tumors (grade III Patnaik system, or high grade Kiupel system) that showed a high degree of cellular pleomorphism. The neoplastic, often multinucleated cells were arranged in closely packed sheets. The nuclei were large, irregularly shaped and intracytoplasmic granules were fewer. In order to differentiate mast cell tumors from other round cell tumors, additional staining with TB provides accurate diagnosis due to the fact that cytoplasmic granules of mast cells stain purple [26,27].

Nonneoplastic mast cells expressed only membranous KIT staining pattern, whereas CMCTs histologically graded as II or III according to Patnaik *et al.* (or high grade malignancy according Kiupel system) predominantly express KIT in their cytoplasm [9,11]. Both in the case of the dog with systemic mastocytosis and dogs with CMCTs of high grade malignancy the cytoplasmic KIT staining pattern was observed. However, dogs with CMCTs of low grade malignancy had only the membranous KIT staining pattern. Despite the cytoplasmic KIT staining patterns are being considered as characteristic of higher grade malignancy CMCTs [9,12] they could just reflect an alteration in biological behavior of mast cells instead of indicating a histopathological grade [28].

As in our case, systemic distribution of mast cell tumors is usually connected with the presence of cutaneous nodules, because it is in most cases secondary to cutaneous tumor [29]. Nevertheless, there are described cases of systemic mastocytosis without the presence of primary cutaneous lesion [30,31].

Based on our study, histological features and cytoplasmic CD117 expression in neoplastic cells of dogs with systemic mastocytosis are similar to those in dogs with high grade CMCTs. Nevertheless, mutations of c-KIT proto-oncogene were not found in tumor samples either from dogs with CMCT or dog with systemic mastocytosis.

Acknowledgements

Thanks to Dr. Matti Kiupel (College of Veterinary Medicine, Department of Pathobiology and Diagnostic Investigation from the Michigan State University, USA)

for providing paraffin embedded tissue sample of canine mast cell tumor whose DNA isolate contains c-KIT mutation.

This study was supported by the Ministry of Education, Science and Technological Development of the Republic of Serbia, Grant TP 31087 and III 46002.

REFERENCES

1. Fulciniti F, Di Mattia D, Curcio MP, Bove P, Rota AM, Botti G: Canine mastocytoma: Report of 8 cases diagnosed by fine needle cytology and clinicopathologic correlations. *Acta Cytol* 2007, 51(4):616-620.
2. Goldschmidt MH, Hendrick MJ: Tumour of the skin and soft tissues. In DJ. Meuten, *Tumors in domestic animals*. Iowa State Press 2002, 45-118.
3. Welle MM, Rohrer CB, Howard J, Rüfenacht S: Canine mast cell tumors: a review of the pathogenesis, clinical features, pathology and treatment. *Veterinary Dermatology* 2008, 19(6):321-339.
4. Patnaik AK, Ehler WY, MacEwen EG: Canine cutaneous mast cell tumors: morphologic grading and survival time in 83 dogs. *Vet Path* 1984, 21(5):496-474.
5. Kiupel M, Webster JD, Bailey KL, Best S, Delay J, Detrisac CJ, Fitzgerald SD: Proposal of a 2-tier histologic grading system for canine cutaneous mast cell tumors to more accurately predict biological behaviour. *Vet Path* 2011, 48(1):147-155.
6. Hosseini E, Pedram B, Bahrami AM, Moghaddam MHJ, Javanbakht J, Ghomi FE, Moghaddam NJ, Koohestani M, Shafiee R: Cutaneous mast cell tumor (Mastocytoma): Cyto-histopathological and haematological investigations. *Diagnostic pathology* 2014, 9:9.
7. Webster JD, Yuzbasiyan-Gurkan V, Miller RA, Kaneene JB, Kiupel M: Cellular proliferation in canine cutaneous mast cell tumors: associations with c-KIT and its role in prognostication. *Veterinary Pathology* 2007, 44(3):298-308.
8. Thompson JJ: Canine Mast Cell Tumors: Characterization of Subcutaneous Tumors and Receptor Tyrosine Kinase Profiling. PhD Thesis, Guelph, Ontario, Canada 2012.
9. Kiupel M, Webster JD, Kaneene JB, Miller R, Yuzbasiyan-Gurkan V: The use of kit and tryptase expression patterns as prognostic tools for canine cutaneous mast cell tumors. *Vet Pathol* 2004, 41(4):371-377.
10. Gil da Costa RM, Matos E, Rema A, Lopes C, Pires MA, Gartner F: CD117 immunoexpression in canine mast cell tumors: correlations with pathological variables and proliferation markers. *BMC Veterinary Research* 2007, 21(3):19.
11. Reguera MJ, Rabanal RM, Puigdemont A, Ferrer L: Canine mast cell tumors express stem cell factor receptor. *Am J Dermatopathol* 2000, 22:49-54.
12. Preziosi R, Morini M, Sarli G: Expression of the kit protein (CD117) in primary cutaneous cell tumors of the dog. *J Vet Diagn Invest* 2004, 16(6):554-561.
13. Webster JD, Yuzbasiyan-Gurkan V, Kaneene JB, Miller R, Resau JH, Kiupel M: The role of c-KIT in tumorigenesis: evaluation in canine cutaneous mast cell tumors. *Neoplasia* 2006, 8(2):104-111.
14. Kukolj V: Myofibroblasts in normal and fibrotic liver in different animal species. *Acta Veterinaria* 2014, 64 (4):397-412.

15. Jones CL, Grahn RA, Chien MB, Lyons LA, London CA: Detection of c-KIT mutations in canine mast cell tumors using fluorescent polyacrylamide gel electrophoresis. *J Vet Diagn Invest* 2004, 16(2):95-100.
16. Aleksić-Kovačević S, Kukolj V, Jelesijević T, Jovanović M: Retrospective analysis of canine mesenchymal tumors of skin and soft tissues. *Acta Veterinaria* 2005, 55(5-6):521-529.
17. Plier M, MacWilliams: Systemic Mastocytosis and Mast Cell Leukemia, In Feldman BF, Zinkl JG, Jain NC, Schalm's Veterinary Haematology. fifth edition, Blackwell Publishing Limited 2000, 747-755.
18. Grano FG, Silva JES, Melo GD, Schweigert A, Ciarlini P, Machado GF: Visceral Mast Cell Tumor and Mastocytemia in a Dog. *Braz j Vet Pathol* 2012, 5(3):142-145.
19. Gross TL, Ihrke P, Walder EJ, Affolter VK: Mast cell tumors, *Skin Diseases of the Dog and Cat: Clinical and Histopathologic Diagnosis*. 2nd edition, Oxford: UK, Blackwell Science Ltd 2005, 853-865.
20. Kovačević-Filipović M: The blood is rich in different types of mesoderm derived stem and progenitor cells. *Acta Veterinaria* 2014, 64 (2):156-178.
21. Hijová E, Szabadosova V, Štofilová J, Salaj R, Bomba A: Inulin diet intervention on chemopreventive and inflammatory markers in tumorigenesis of colorectal cancer. *Acta Veterinaria* 2014, 64 (4): 519-525.
22. Muraesan C, Bolfă P, Catoi C, Gal A, Taulescu M, Tabaran F, Nagy A: Clinical and Pathological Aspects in 2 Cases of Canine Mastocytoma. *Lucrari Stiintific Medicina Veterinara* 2009, vol XLII (2):240-244.
23. Dobson JM, Scase TJ: Advances in the diagnosis and management of cutaneous mast cell tumours in dogs. *J Small Anim Pract* 2007, 48(8):424-431.
24. London CA, Segium B: Mast cell tumors in dog. *Vet Clin Small Anim* 2003, 33(3):473-489.
25. De Nicola D: Round Cells. In Cowell RL, Tyler RD, Meinkoth JH, DeNicola DB, 3rd edition, Mosby Elsevier 2008, 69-72.
26. Yager JA, Wilcock BP: Color atlas and text of surgical pathology of dog and cat: dermatopathology and skin tumors. 1st edition, London: Mosby-Year Book 1994, 273-286.
27. Hendrick MJ, Mahaffey EA, Moore FM, Vos JH, Walder EJ: World Health Organisation. Histological classification of mesenchymal tumors of skin and soft tissues of domestic animals. 2nd edition, Washington: Armer Forces Institute of Pathology 1998, 29.
28. Sailasuta A, Ketpun D, Piyaviriyakul P, Theerawatanasirikul S, Theewasutrakul P, Rungsipipat A: The Relevance of CD117-Immunocytochemistry Staining Patterns to Mutational Exon-11 in c-kit Detected by PCR from Fine-Needle Aspirated Canine Mast Cell Tumor Cells. *Veterinary Medicine International* 2014, ID 787498.
29. Thamm DH, Vail DM: Mast cell tumors, In Withrow SJ, Vail DM Withrow & MacEwen's Small Animal Clinical Oncology. Eds, 4th edition, St. Louis, MO:Saunders Elsevier 2007, 402-424.
30. Davies AP, Hayden DW, Perman V: Noncutaneous systemic mastocytosis and mast cell leukemia in a dog: case report and literature review. *J Am Anim Hosp Assoc* 1981, 17:361-368.
31. Pollack MJ, Flanders JA, Johnson RC: Disseminated malignant mastocytoma in a dog. *J Am Anim Hosp Assoc* 1991, 27:435-440.

MORFOLOŠKE KARAKTERISTIKE I EKSPRESIJA KIT RECEPTORA KOD KUTANIH MASTOCITOMA I SISTEMSKE MASTOCITOZE PASA

MARINKOVIĆ Darko, MILČIĆ-MATIĆ Natalija, JOVANOVIĆ Milan, VUČIĆEVIĆ Ivana, NEŠIĆ Slađan, ANIČIĆ Milan, ALEKSIĆ-KOVAČEVIĆ Sanja

Neoplazme poreklom od mastocita mogu da se jave u dva različita oblika: uobičajeno kao kožni tumori – kutani mastocitomi ili ređe kao sistemska forma neoplastične proliferacije mastocita – sistemska mastocitoza. Svrha ovog istraživanja je da se uporede histološke i citološke karakteristike, ekspresija KIT receptora i prisustvo mutacija *c-KIT* proto-onkogeni u neoplastičnim ćelijama kod pasa sa kutanim mastocitomima i sistemskom mastocitozom. Mikroskopskim pregledom citoloških razmaza svih ispitanih pasa utvrđeno je da se ćelijska populacija sastoji uglavnom od okruglih ćelija koje imaju centralno postavljeno jedro i sitne ljubičaste citoplazmatske granule. Histopatološkim pregledom uzoraka kože pasa sa kutanim mastocitomima i sistemskom mastocitozom zapaženo je umnožavanje mastocita u površinskom i/ili dubokom dermisu. Sličan nalaz uočen je i u isečcima tkiva limfnih čvorova, slezine, jetre, miokarda i bubrega psa sa sistemskom mastocitozom. Kod tri psa sa kutanim mastocitomima visokog stepena maligniteta, kao i kod psa sa sistemskom mastocitozom zapažena je citoplazmatska ekspresija CD117, dok je kod tri psa sa kutanim mastocitomima niskog stepena maligniteta uočena membranska ekspresija CD117. Na osnovu našeg istraživanja, histološke karakteristike i citoplazmatska ekspresija CD117 na neoplastičnim ćelijama su slične kod pasa sa sistemskom mastocitozom i pasa sa kutanim mastocitomima visokog stepena maligniteta. I pored toga, mutacije *c-KIT* proto-onkogeni nisu uočene ni kod pasa sa kutanim mastocitomima, ni kod psa sa sistemskom mastocitozom.