

Morphological Variation of Hypaxial Musculature in Salamanders (Lissamphibia: Caudata)

RACHEL S. SIMONS* AND ELIZABETH L. BRAINERD

Department of Biology, Morrill Science Center, University of Massachusetts Amherst, Amherst, Massachusetts

ABSTRACT Despite the acknowledged importance of the locomotory and respiratory functions associated with hypaxial musculature in salamanders, variation in gross morphology of this musculature has not been documented or evaluated within a phylogenetic or ecological context. In this study, we characterize and quantify the morphological variation of lateral hypaxial muscles using phylogenetically and ecologically diverse salamander species from eight families: Ambystomatidae (*Ambystoma tigrinum*), Amphiumidae (*Amphiuma tridactylum*), Cryptobranchidae (*Cryptobranchus alleganiensis*), Dicamptodontidae (*Dicamptodon* sp.), Plethodontidae (*Gyrinophilus porphyriticus*), Proteidae (*Necturus maculosus*), Salamandridae (*Pachytriton* sp.), and Sirenidae (*Siren lacertina*). For the lateral hypaxial musculature, we document 1) the presence or absence of muscle layers, 2) the muscle fiber angles of layers at mid-trunk, and 3) the relative dorsoventral positions and cross-sectional areas of muscle layers. Combinations of two, three, or four layers are observed. However, all species retain at least two layers with opposing fiber angles. The number of layers and the presence or absence of layers vary within species (*Necturus maculosus* and *Siren lacertina*), within genera (e.g., *Triturus*), and within families. No phylogenetic pattern in the number of layers can be detected with a family-level phylogeny. Fiber angle variation of hypaxial muscles is considerable: fiber angles of the *M. obliquus externus* range from 20–80°; *M. obliquus internus*, 14–34°; *M. transversus abdominis*, 58–80° (acute angles measured relative to the horizontal septum). Hypaxial musculature comprises 17–37% of total trunk cross-sectional area. Aquatic salamanders show relatively larger total cross-sectional hypaxial area than salamanders that are primarily terrestrial. *J. Morphol.* 241:153–164, 1999. © 1999 Wiley-Liss, Inc.

KEY WORDS: salamanders; Urodela; Caudata; hypaxial muscle; axial muscle; trunk musculature; *M. obliquus externus*; *M. obliquus internus*; *M. transversus abdominis*

Layers of lateral hypaxial musculature wrap around the lateral aspect of the trunk of salamanders and other tetrapods. The actions of the lateral hypaxial musculature include bending, stabilizing, and compressing the body, and are associated with complex behaviors such as breathing and locomotion. Recent work by Carrier ('93) showed that lateral hypaxial muscles (*Mm. obliquus externus superficialis*, *obliquus externus profundus*, *obliquus internus*, *transversus abdominis*) are associated with bending and stabilizing the trunk of a terrestrial salamander, *Dicamptodon ensatus*, during aquatic and terrestrial locomotion. In studies of lung ven-

tilation, Brainerd and colleagues (Brainerd et al., '93; Brainerd, '98; Brainerd and Monroy, '98) have demonstrated that hypaxial musculature, particularly the *M. transversus abdominis*, is responsible for compression of the trunk during exhalation in aquatic salamanders. Despite the acknowledged importance of the locomotory and respiratory functions associated with this musculature

Contract grant sponsor: NSF; Contract grant number: IBN 9419892.

*Correspondence to: Rachel S. Simons, Department of Biology, Morrill Science Center, University of Massachusetts Amherst, Amherst, MA 01003. E-mail: rsimons@bio.umass.edu

in salamanders, variation in gross morphology of the lateral hypaxial musculature has not previously been documented or evaluated within a phylogenetic or ecological context.

Textbooks and dissection guides generally show three layers of lateral hypaxial musculature in salamanders and provide a highly schematic view of the position and muscle fiber angles of these layers (e.g., Barker and Breland, '80; Rosenzweig, '88; Walker and Homberger, '92; Wischnitzer, '93; Kardong and Zalisko, '98). A few sources mention some interspecific variation of the number of hypaxial muscle layers. For example, Duellman and Trueb ('86) noted that some species of Hynobiidae have only two layers; Noble ('31) observed that species of *Salamandra* show four muscle layers as juveniles and three layers as adults, while *Cryptobranchus* species have only three layers. Little has been published in the primary literature about these muscles, and most accounts rely on a single study of three species (Maurer, '11). It is clear, however, that this musculature is more variable and complex than has been generally appreciated. For example, Table 1 shows data compiled from an unpublished thesis (Naylor, '78) demonstrating considerable variation in the presence or absence of hypaxial muscle layers in 59 species of salamanders.

In this study, we investigate further the morphological variation of hypaxial musculature in salamanders. Documentation of this variation is the first step toward gaining a better understanding of this important and complex musculature. Salamanders are a useful group in which to examine the morphology and function of the hypaxial musculature because salamanders compose an ecologically and phylogenetically diverse taxon. Their habitats range from fully aquatic to primarily terrestrial and their locomotor behaviors include both swimming and walking. Our objective in this study is to characterize and quantify the morphological variation of lateral hypaxial muscles using species from eight families: Ambystomidae (*Ambystoma tigrinum*), Amphiumidae (*Amphiuma tridactylum*), Cryptobranchidae (*Cryptobranchus alleganiensis*), Dicamptodontidae (*Dicamptodon* sp.), Plethodontidae (*Gyrinophilus porphyriticus*), Proteidae (*Necturus maculosus*), Salamandridae (*Pachytriton* sp.), and Sirenidae (*Siren lacertina*). Specifically, for oblique and

TABLE 1. Presence and absence of muscle layers¹ in 10 salamander families

Family	n ²	External layers ³			Internal layers ³		
Hynobiidae ⁴	3	—	OE	—	—	OI/TA	—
Hynobiidae ⁵	1	OES	—	OEP	OI	—	TA
Cryptobranchidae ⁶	1	—	OE	—	OI	—	TA
Amphiumidae ⁷	1	OES	—	OEP	OI	—	TA
Dicamptodontidae ⁸	1	OES	—	OEP	OI	—	TA
Rhyacotritonidae ⁹	1	OES	—	OEP	OI	—	TA
Ambystomatidae ¹⁰	4	OES	—	OEP	OI	—	TA
Ambystomatidae ¹¹	3	OES	—	OEP	—	OI/TA	—
Proteidae ¹²	2	OES	—	OEP	OI	—	TA
Proteidae ¹³	1	—	OE	—	OI	—	TA
Plethodontidae ¹⁴	23	OES	—	OEP	—	OI/TA	—
Salamandridae							
true salamander ¹⁵	1	—	OE	—	—	OI/TA	—
newt ¹⁶	8	OES	—	OEP	OI	—	TA
newt ¹⁷	3	OES	—	OEP	—	OI/TA	—
newt ¹⁸	1	—	OE	—	OI	—	TA
newt ¹⁹	3	—	OE	—	—	OI/TA	—
Sirenidae ²⁰	1	OES	—	OEP	OI	—	TA
Sirenidae ²¹	1	—	OE	—	OI	—	TA

¹OES, *M. obliquus externus superficialis*; OEP, *M. obliquus externus profundus*; OE, *obliquus externus* (homology with OES or OEP is uncertain); OI, *M. obliquus internus*; TA, *transversus abdominis*. All but six of the species listed in this table showed presence of *M. rectus abdominis* (RA), *M. rectus lateralis* (RL), *M. rectus superficialis* (RS), and *M. rectus profundus* (RP). For three species, the RL was absent: *Hemidactylum scutatum*, *Batrachoseps attenuatus*, and *Salamandrina terdigitata*. Neither RS nor RP was observed in the following three species: *Notophthalmus viridescens*, *Taricha torosa*, and *Triturus vulgaris*.

²Number of species investigated that showed this pattern. Not an exhaustive search. Compiled from Naylor ('78).

³Line = muscle layer absent.

⁴*Hynobius retardatus*, *H. naevius*; *H. boulengeri*.

⁵*Onychodactylus japonicus*.

⁶*Cryptobranchus alleganiensis*.

⁷*Amphiuma tridactylum*.

⁸*Dicamptodon* sp.

⁹*Rhyacotriton* sp.

¹⁰*Ambystoma maculatum*, *A. gracile*, *A. jeffersonianum*, *A. tigrinum*.

¹¹*Ambystoma macrodactylum*, *A. opacum*, *A. talpoideum*.

¹²*Necturus maculosus*, *Proteus anguinus*.

¹³*Necturus maculosus* (intraspecific variation).

¹⁴*Plethodon jordani*, *P. glutinosus*, *P. cinereus*, *P. vehiculum*, *P. neomexicanus*, *Ensatina eschscholtzii*, *Aneides lugubris*, *Hemidactylum scutatum*, *Batrachoseps attenuatus*, *Bolitoglossa subpalmata*, *Pseudoeurycea cephalica*, *Chiropoterotriton chiropoterus*, *C. chondrostega*, *C. xolocalca*, *Hydromantes brunus*, *Eurycea bislineata*, *E. quadridigitata*, *Typhlotriton spelaes*, *Stereochilus marginatus*, *Gyrinophilus porphyriticus*, *Pseudotriton ruber*, *Desmognathus fuscus*, *D. marmoratus*.

¹⁵*Salamandra salamandra*.

¹⁶*Notophthalmus viridescens*, *Cynops pyrrhogaster*; *C. ensicauda*; *Paramesotriton hongkongensis*, *Triturus cristatus*, *T. alpestris*, *T. vittatus*, *T. vulgaris*.

¹⁷*Euproctus asper*, *Taricha torosa*, *Pleurodeles waltl*.

¹⁸*Triturus marmoratus*.

¹⁹*Typhlotriton andersoni*, *Salamandrina terdigitata*, *Triturus helveticus*.

²⁰*Siren intermedia*.

²¹*Siren lacertina*.

transverse hypaxial musculature, we examine 1) the presence or absence of layers, 2) the fiber angles of layers, and 3) the relative dorsoventral positions and cross-sectional areas of muscle layers.

MATERIALS AND METHODS

Material examined

We examined the trunk morphology of adult salamanders. Specimens were fixed in straight body positions using 10% formaldehyde and maintained in a 65% ethanol solution. Specimens have been deposited in the University of Massachusetts Museum of Natural History. The museum number and snout-vent length follows the species name. *Ambystoma tigrinum* (n = 3): UMA-A0868, 12.3 cm; UMA-A0864, 13.0 cm; UMA-A0863, 12.0 cm; *Dicamptodon* sp. (n = 2): UMA-A0869, 13.8 cm; UMA-A0870, 12.0 cm; *Cryptobranchus alleganiensis* (n = 3): UMA-A0862, 25.0 cm; UMA-A0860, 28.0 cm; UMA-A0861, 19.9 cm. *Amphiuma tridactylum* (n = 3): UMA-A0858, 69.0 cm; UMA-A0854, 57.5 cm; UMA-A0871, 59.0 cm; *Gyrinophilus porphyriticus* (n = 3): UMA-A0263, 8.71 cm; UMA-A0265, 9.3 cm; UMA-A0266, 7.2 cm; *Pachytriton* sp. (n = 2) UMA-A0865, 7.95 cm; UMA-A0866, 7.3 cm; and *Siren lacertina* (n = 3): UMA-A0851, 26.5 cm; UMA-A0859, 31.0 cm; UMA-A0856, 35.9 cm; UMA-A0855, 38.5 cm; UMA-A0857, 40.0 cm. *Necturus maculosus* (n = 3) specimens were obtained from a University of Massachusetts anatomy teaching laboratory: snout-vent lengths 25.5, 26.6, 24.0 cm. An additional *Dicamptodon* sp. specimen was borrowed from the University of Michigan Museum of Zoology: field tag series number 10102; snout-vent length, 11.4 cm.

Presence or absence of layers

In order to determine the presence or absence of muscle layers, we compiled data on 59 species in ten families (Table 1) from an unpublished dissertation (Naylor, '78). We then compared these results with our dissections of salamander species in eight of those families. Our dissections concentrated on lateral hypaxial muscles: *Mm. obliquus externus*, *obliquus externus superficialis*, *obliquus externus profundus*, *obliquus internus*, and *transversus abdominis*. A second group of hypaxial muscles, the rectus group, includes the *Mm. rectus lateralis*, *rectus abdominis*, *rectus superficialis*, and *rectus profundus*. We comment briefly on the presence and

absence of these muscles (Table 1), but devote our attention to the lateral group because it is more variable than the rectus group, and the muscle function of the lateral group has been tested empirically in several salamander species (Brainerd et al., '93; Carrier, '93; Brainerd, '98; Brainerd and Monroy, '98).

Fiber angles

To characterize and quantify the variation of muscle fiber angles, we dissected hypaxial muscles in eight salamander species, listed above (between two and five individuals were examined in each species). For each dissection, we created two or three "windows" exposing hypaxial musculature close to the dorsoventral and craniocaudal midpoint of the trunk. Morphological measurements were taken at this location in order to avoid the confluence of muscles at the pectoral and pelvic girdles and because this site provides a definable and identifiable region in all specimens. Each window was confined to a single myomere. Using a dissecting scope (x6–12 magnification) and camera lucida, a minimum of ten fibers were drawn and measured from each muscle within each window. All fiber angles were measured as acute angles with respect to the horizontal septum.

Cross-sectional measurements

For single individuals of *Ambystoma tigrinum*, *Cryptobranchus alleganiensis*, *Amphiuma tridactylum*, and *Siren lacertina*, we cut cross-sections at 50% of the distance along the trunk between the pectoral and pelvic girdles. Images of cross-sections were drawn using a microscope and camera lucida, as well as captured with a video camera, Scion frame-grabber board, and NIH Image software. In order to make morphological comparisons among species, we used NIH Image software to measure muscle cross-sectional areas, trunk diameter, and body wall thickness. The area of each hypaxial muscle layer was expressed as a percent of total hypaxial muscle area. We calculated the ratio of hypaxial body wall thickness to total body diameter, and the ratio of hypaxial to epaxial muscle cross-sectional areas.

RESULTS

Muscle layer organization

The lateral hypaxial musculature wraps around the lateral aspect of the trunk and

generally lies ventral to the epaxial muscle. In *Ambystoma tigrinum*, four muscle layers are present (Fig. 1). The two most superficial layers are the *M. obliquus externus superficialis* and the *M. obliquus externus profundus*. The muscle fibers of both of these layers slope from craniodorsal toward caudoventral. With respect to the horizontal axis, the fiber angles of the *M. o. e. superficialis* are steeper than those of the *M. o. e. profundus* (fiber angles are discussed below). The two innermost hypaxial muscles, the *M. obliquus internus* and the *M. transversus abdominis*, slope from cranioventral toward caudodorsal. The fiber angles of the *M. transversus abdominis* are steeper than those of the *M. obliquus internus*.

For all the species examined here, the *M. obliquus externus superficialis* and *M. obliquus externus profundus* (or *M. obliquus externus*) as well as the *M. obliquus internus*

originate and insert primarily upon the transversely oriented myosepta, which are highly vascularized, membranous divisions between body segments. In addition, in all the salamanders we examined the skin attaches firmly to the underlying *M. obliquus externus* musculature. Based on dissections of fixed specimens, this attachment seems strongest in *Siren lacertina* and *Amphiuma tridactylum*, which are highly aquatic species. In *S. lacertina*, in particular, a strong, fibrous layer of fascia connects the skin and underlying external oblique muscle. The angle of these collagen fibers is approximately 50–55° with respect to the horizontal septum.

With the exception of *Siren lacertina* and *Amphiuma tridactylum*, the fibers of the *M. transversus abdominis* originate and insert on the peritoneum or on an aponeurosis closely associated with the peritoneum. In *S.*

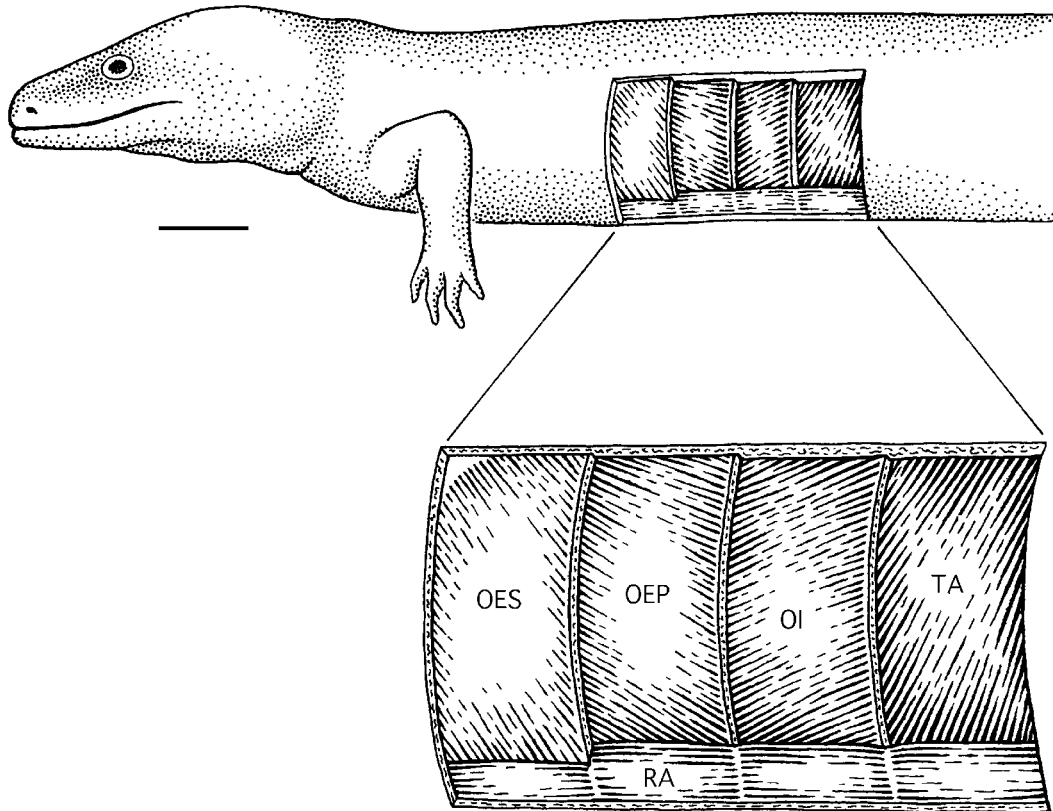


Fig. 1. Left lateral view of hypaxial musculature of *Ambystoma tigrinum*. The musculature shown in situ in the upper drawing is enlarged in the lower panel. The muscle fiber angles are drawn approximately to scale.

OES, *M. obliquus externus superficialis*; OEP, *M. obliquus externus profundus*; OI, *M. obliquus internus*; RA, *M. rectus abdominis*; TA, *M. transversus abdominis*. Scale bar = 1 cm.

lacertina, the *M. transversus abdominis* attaches dorsally to an obliquely oriented aponeurosis that lies medial to the *M. obliquus internus* (Fig. 2). In *A. tridactylum*, the *M. transversus abdominis* fibers attach dorsally, via an aponeurosis, to the horizontal septum, merging with the epimysium surrounding the epaxial musculature. In both species, the *M. transversus abdominis* fibers attach ventrally onto the peritoneum.

Three hypaxial muscle layers of *Siren lacertina* are shown in lateral view (Fig. 2). Three of five *S. lacertina* specimens show three hypaxial muscle layers (*Mm. obliquus externus*, *obliquus internus*, and *transversus abdominis*; Fig. 2), whereas the remaining two specimens have four layers (*Mm. obliquus externus superficialis*, *obliquus externus profundus*, *obliquus internus*, and *transversus abdominis*). In the four-layered specimens, the *M. o. e. superficialis* is thin—only a few muscle fibers thick. In *S. lacertina*, the *Mm. o. e. superficialis*, *o. e. profun-*

us (or, *obliquus externus*), *obliquus internus*, and *transversus abdominis* are confined, dorsoventrally, to a relatively narrow, midtrunk position between the epaxial and rectus abdominis muscles (Fig. 2).

Mean fiber angles

The mean fiber angles of the lateral hypaxial muscles (*Mm. obliquus externus*, *obliquus externus superficialis*, *obliquus externus profundus*, *obliquus internus*, *transversus abdominis*) for eight species of salamanders are shown in Table 2. The fiber angles of the external layers, *M. o. e. superficialis* and *M. o. e. profundus* (or *M. obliquus externus*), range from 20–80°. For salamander species that have two external oblique layers such as *Ambystoma tigrinum*, *Amphiuma tridactylum*, *Dicamptodon sp.*, *Gyrinophilus porphyriticus*, and *Pachytriton sp.*, the angle of the superficialis (46–80°) is always greater than that of the profundus (20–33°). For the three species that have

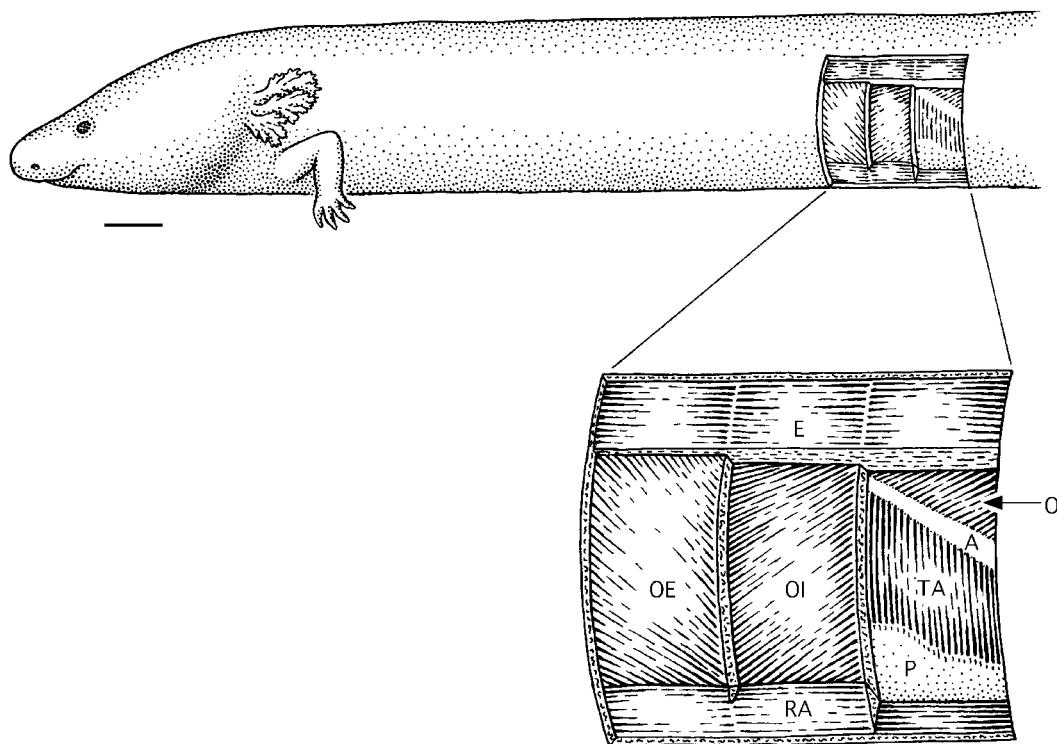


Fig. 2. Left lateral view of hypaxial musculature of *Siren lacertina*. The musculature shown in situ in the upper drawing is enlarged in the lower panel. The muscle fiber angles are drawn approximately to scale. E, ep-

axial muscle; OE, *M. obliquus externus*; OI, *M. obliquus internus*; TA, *M. transversus abdominis*; RA, *M. rectus abdominis*; P, peritoneum; A, aponeurosis into which the TA inserts. Scale bar = 1 cm.

TABLE 2. Hypaxial muscle¹ fiber angles² measured at midtrunk

Species	n	OES	OE ³	OEP	OI	TA	Ecological habit ⁴
<i>Ambystoma tigrinum</i>	3	49.5 (2.2)	—	20.4 (2.3)	31.8 (2.1)	67.7 (3.6)	T
<i>Amphiuma tridactylum</i>	3	66.4 (5.7)	—	32.5 (1.3)	25.9 (4.4)	68.0 (3.8)	A
<i>Cryptobranchus alleganiensis</i>	3	—	36.9 (3.0)	—	14.2 (1.9)	68.5 (1.8)	A
<i>Dicamptodon sp.</i>	3	65.9 (3.4)	—	23.7 (3.1)	36.6 (7.5)	63.6 (3.9)	T
<i>Gyrinophilus porphyriticus</i>	3	79.9 (1.4)	—	28.2 (2.2)	33.6 (2.7)	57.7 (3.6)	T
<i>Necturus maculosus</i>	3	—	28.7 (1.1)	—	34.1 (2.4)	77.4 (3.3)	A
<i>Pachytriton sp.</i>	2	50.9 (5.0)	—	24.2 (4.9)	32.3 (3.3)	69.3 (1.0)	A
<i>Siren lacertina</i>	3	—	41.0 (3.6)	—	18.0 (2.5)	80.0 (0.7)	A
<i>Siren lacertina</i>	2	45.9 (2.0)	—	22.5 (1.5)	13.8 (2.5)	74.0 (9.0)	A

¹OES, *M. obliquus externus superficialis*; OE, *M. obliquus externus*; OEP, *M. obliquus externus profundus*; OI, *M. obliquus externus*; TA, *M. transversus abdominis*.

²Acute angle with respect to the horizontal axis (zero). Angles measured in degrees; standard error shown in parentheses.

³Single external layer classified as OE; homology with OES or OEP is uncertain.

⁴Predominant ecological habit of metamorphosed adult salamanders (Duellman and Trueb, 1986; Bishop, 1943).

only a single external oblique layer, *Siren lacertina*, *Cryptobranchus alleganiensis*, and *Necturus maculosus*, the angle of the fibers ranges from 29–41° (Table 2). The muscle fiber angles of the internal layers, *M. obliquus internus* and *M. transversus abdominis*, range from 14–80°. Fiber angles of the *M. obliquus internus* range from 14° in *C. alleganiensis* and *S. lacertina* to 36° in *D. ensatus* (Table 2). The fiber angle of the *M. transversus abdominis* ranges from 58° in *G. porphyriticus* to 80° in *S. lacertina*.

The *Gyrinophilus porphyriticus* specimens examined in this study have a partial *M. obliquus internus* muscle layer. This layer is a single muscle fiber thick and is restricted to the dorsal region of the hypaxial musculature. The fiber angle of this partial *M. obliquus internus* muscle (33.6° ± 2.7 s.e.) is similar to the angles of other species' *M. obliquus internus* (Table 2). *Gyrinophilus porphyriticus* shows the steepest fiber angle for the *M. obliquus externus superficialis* muscle (79° ± 1.4 s.e.) whereas the fiber angle of the *M. obliquus externus profundus* (28° ± 2.2 s.e.) is similar to the *M. o. e. profundus* of other species (Table 2). For the *M. transversus abdominis* muscle, both *G. porphyriticus* and *Dicamptodon sp.* show relatively low fiber angles of 58° and 64°, respectively (Table 2). The muscle fiber angle of the *M. o. e. profundus* of *Pachytriton sp.* is 24.2° ± 4.9 s.e. at midtrunk. However, in this species, along a dorsoventral gradient, the *M. obliquus externus profundus* fiber angle changes from approximately 5° dorsally to 32° ventrally.

The fibers of the *M. obliquus externus superficialis* layer in *Siren lacertina* are relatively steep, with an angle of 45.9° ± 2.0 s.e. The fiber angle of the thicker, underlying *M. obliquus externus profundus* is relatively low (22.5° ± 1.5 s.e.), compared with the angle of the single *M. obliquus externus* layer of the other siren specimens (41.0° ± 3.6 s.e.). In contrast to the *M. obliquus externus* fiber angle at the dorsoventral midpoint (41–46°), the angle of the *M. obliquus externus* fibers of *S. lacertina* becomes more horizontal in the dorsal and ventral-most regions.

In agreement with Maurer ('11), we observed that the ventral portions of the *M. obliquus internus* and *M. obliquus externus profundus* in *Amphiuma tridactylum* grade into the *M. rectus abdominis* such that it is not possible to distinguish the dorsal portion of the *M. rectus abdominis* from the ventral portion of the *M. obliquus internus* or *M. obliquus externus profundus*. Similarly, in *Necturus maculosus*, the ventral portion of the *M. obliquus internus* grades into the *M. rectus abdominis* (in agreement with Maurer, '11; Walker and Homberger, '92). In contrast, for *Cryptobranchus alleganiensis* and *Ambystoma tigrinum*, these muscles remain distinct. Lateral views of *C. alleganiensis*, *N. maculosus*, and *A. tridactylum* are consistent with illustrations in Maurer ('11) and Brainerd et al. ('93) (for *N. maculosus*) and our results for these species and are not illustrated here. Similarly, illustrations of *Dicamptodon sp.* in Carrier ('93) are in agreement with our results from this species.

Cross sections

Figure 3 shows the relative contributions of the hypaxial and epaxial musculature to the midtrunk musculature for four species of salamanders: *Siren lacertina*, *Ambystoma tigrinum*, *Cryptobranchus alleganiensis*, *Amphiuma tridactylum*. The ratio of the cross-sectional areas of the hypaxial to epaxial muscles is 0.99 in both *S. lacertina* and *C. alleganiensis* (Table 3). For *A. tigrinum* and *A. tridactylum*, the ratio of hypaxial to epaxial muscle is 0.70 and 0.85, respectively (Table 3).

Figure 3 also shows the variation of the relative thickness of the hypaxial body wall.

The fully aquatic salamanders that are specialized for swimming such as *Siren lacertina* and *Amphiuma tridactylum* have relatively thick hypaxial musculature such that 51% and 34%, respectively, of the total trunk diameter is comprised of hypaxial muscle (Fig. 3, Table 3). *Cryptobranchus alleganiensis*, a fully aquatic species but with robust limbs for walking on stream bottoms, shows hypaxial musculature that composes 25% of total trunk diameter. In contrast, the body wall of the more terrestrial species, *Ambystoma tigrinum*, is relatively thin: hypaxial muscle accounts for 20% of the trunk diameter (Table 3). Consistent with these mea-

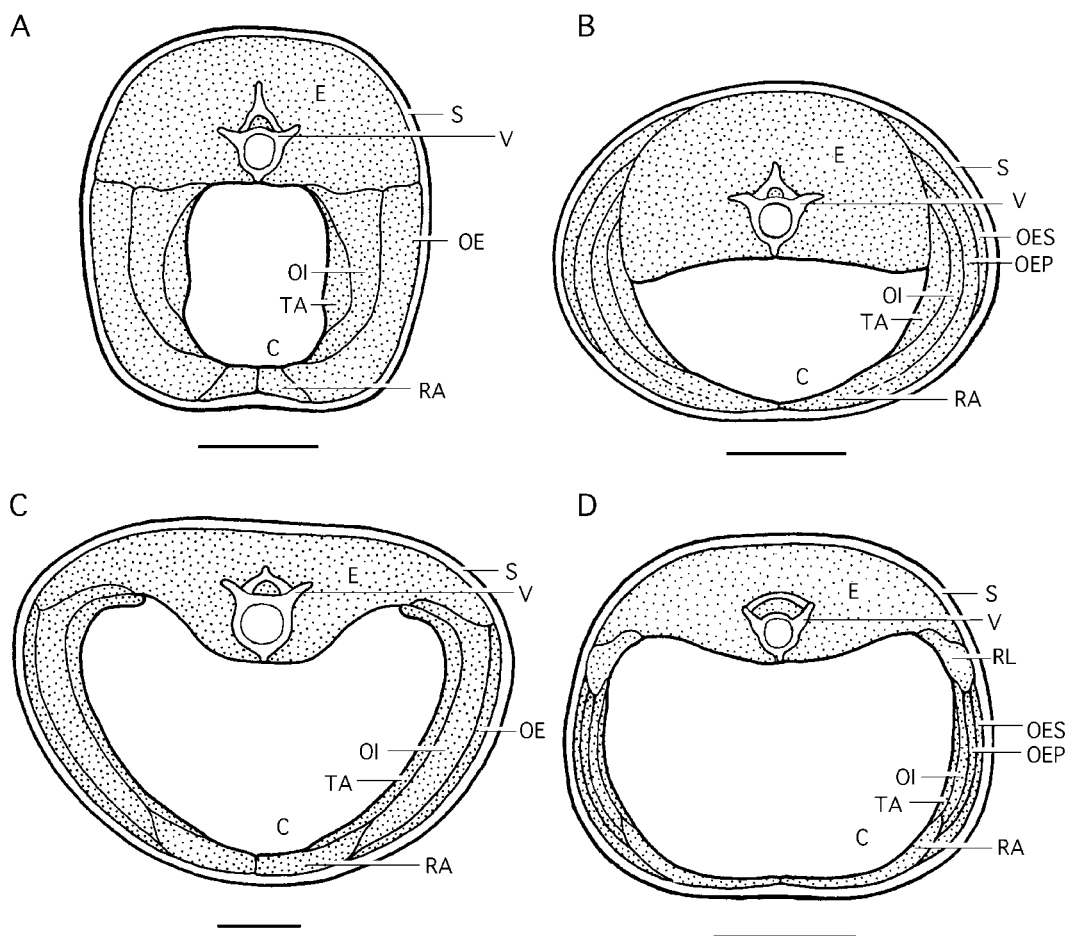


Fig. 3. Cross sections through the midtrunk of *Siren lacertina* (A); *Amphiuma tridactylum* (B); *Cryptobranchus alleganiensis* (C); and *Ambystoma tigrinum* (D). The variation of the relative muscle placement, thickness, and cross-sectional area across species is shown. Neural spine is not visible in D due to cross-sectional

cut. C, coelom; E, epaxial muscle; OE, *M. obliquus externus*; OES, *M. obliquus externus superficialis*; OEP, *M. obliquus externus profundus*; OI, *M. obliquus internus*; RA, *M. rectus abdominis*; RL, *M. rectus lateralis*; S, skin; TA, *M. transversus abdominis*; V, vertebra. Scale bar = 1 cm.

TABLE 3. Morphological measurements¹ from midtrunk² cross sections

Measurement ³	<i>Ambystoma tigrinum</i>	<i>Amphiuma tridactylum</i>	<i>Cryptobranch alleganiensis</i>	<i>Siren lacertina</i>
OE area (cm ²)	—	—	1.22	1.54
OES area (cm ²)	0.22	0.80	—	—
OEP area (cm ²)	0.16	0.70	—	—
OI area (cm ²)	0.14	0.46	1.38	0.82
TA area (cm ²)	0.08	0.36	0.86	0.20
RA area (cm ²)	0.22	0.24	0.58	0.16
Total hypax area (cm ²)	0.94	2.56	4.04	2.72
Total epax area (cm ²)	1.34	3.02	4.06	2.76
Total body area (cm ²)	5.58	7.82	16.82	7.40
Coelom area (cm ²)	3.28	2.06	8.10	1.68
Height (cm)	2.29	2.58	3.74	3.03
Diameter (cm)	2.91	3.60	5.30	2.82
Total body wall thickness (cm)	0.58	1.24	1.32	1.44
Hypax/epax ⁴	0.70	0.85	0.99	0.99
Hypax/total body	0.17	0.33	0.24	0.37
OE/hypax	—	—	0.30	0.57
OES/hypax	0.23	0.31	—	—
OEP/hypax	0.17	0.27	—	—
OI/hypax	0.15	0.18	0.34	0.30
TA/hypax	0.85	0.14	0.21	0.74
RA/hypax	0.23	0.94	0.14	0.59
Total body wall/diameter	0.20	0.34	0.25	0.51
Coelom/total body	0.59	0.26	0.48	0.23

¹n = 1 for each species. Accuracy ± 0.03 cm.

²Midtrunk = 50% of the distance between the pectoral and pelvic girdles.

³Epax, epaxial muscle group; hypax, hypaxial muscle group; OE, *M. obliquus externus*; OES, *M. obliquus externus superficialis*; OEP, *M. obliquus externus profundus*; OI, *M. obliquus internus*; RA, *M. rectus abdominis*; TA, *M. transversus abdominis*.

⁴All calculations expressed as a ratio.

surements, the relative size of the body cavity is largest in *A. tigrinum* (Table 3). Cross-sectional views also reveal that the hypaxial muscles in *A. tridactylum* originate considerably more dorsally than those of any other salamander examined here, including *S. lacertina*, another fully aquatic, swimming salamander.

Table 3 lists cross-sectional areas of the hypaxial muscles (*Mm. obliquus externus, obliquus externus superficialis, obliquus externus profundus, obliquus internus, transversus abdominis, rectus abdominis*). For *Ambystoma tigrinum, Amphiuma tridactylum*, and *Cryptobranchus alleganiensis*, the *M. o. e. superficialis* and *M. o. e. profundus* (or *M. obliquus externus*) muscles make up between 17 and 31% of all the hypaxial muscle area. In contrast, for *Siren lacertina* the *M. obliquus externus* composes approximately 57% of the hypaxial muscle area. The *M. obliquus internus* muscle is relatively thickest in *S. lacertina* and *C. alleganiensis* (30 and 34% of the hypaxial body wall, respectively; Table 3). As a percentage of total hypaxial muscle cross-sectional area, the *M. transversus abdominis* muscle cross-sectional area is twice as great in *C. alleganiensis*

and *A. tigrinum* than in *S. lacertina* and *A. tridactylum*.

DISCUSSION

Previously undocumented variation and complexity are present in the hypaxial musculature of different species of salamanders. This musculature shows striking variation of 1) the presence or absence of hypaxial muscle layers; 2) fiber angles of the hypaxial muscles (*Mm. obliquus externus, obliquus externus superficialis, obliquus externus profundus, obliquus internus, and transversus abdominis*); 3) the layer organization and relative positions of these muscles; and 4) the cross-sectional areas of the hypaxial muscles. Variation was observed at the familial, generic, specific, and intraspecific levels.

The presence or absence of hypaxial layers is variable such that it was possible to have various combinations of two, three, or four layers (Table 1). However, all species retain at least two layers, of which one layer has fibers that run from craniodorsal to caudoventral (the external layer) and one layer that runs from caudodorsal to cranioventral (the internal layer) (Naylor, '78). For example, *Hynobius retardus* shows two oppos-

ing hypaxial layers, *M. obliquus externus* and *M. obliquus internus*/*M. transversus abdominis* (Table 1).

For all eight species of salamanders examined, the range of fiber angles for each hypaxial muscle layer was measured: *M. obliquus externus*, 29–41°; *M. obliquus externus superficialis*, 46–80°; *M. obliquus externus profundus*, 20–34°; *M. obliquus internus*, 14–33°; *M. transversus abdominis*, 58–80° (Table 2). The ranges for *M. o. e. superficialis* and *M. o. e. profundus*, as well as *M. obliquus internus* and *M. transversus abdominis*, do not overlap. Therefore, in combination with the general fiber angle direction, fiber angles usefully characterize these muscle layers.

The fiber angles of these layers suggest that, together, the external layers (*M. obliquus externus superficialis* and *M. obliquus externus profundus*) may form a functional unit. Similarly, the internal layers (*M. obliquus internus* and *M. transversus abdominis*) may form a functional unit. Support for this hypothesis comes from the observation that, where a species has only a single muscle layer comprising an external or internal "unit," the fiber angles of the single layer are intermediate between angles measured for specimens with two layers. For example, *Necturus maculosus* and *Cryptobranchus alleganiensis*, as well as three specimens of *Siren lacertina*, show only a single *M. obliquus externus* muscle layer. The angles of the fibers in the single external oblique layer are intermediate to the angles reported for the *M. o. e. superficialis* muscles and *M. o. e. profundus* muscles of other species (Table 2). Similarly, the angle of the *M. obliquus externus* muscle fibers for *Necturus maculosus* in this study ($28.7^\circ \pm 1.1$ s.e.) is intermediate between the angles for the *M. o. e. superficialis* ($34^\circ \pm 3.1$ s.e.) and *M. o. e. profundus* ($12^\circ \pm 4.5$ s.e.) of *N. maculosus* reported by Brainerd et al. ('93). Further support for the hypothesis that the external and internal layers may form functional units comes from a study of hypaxial muscle activity in *Dicamptopneustes ensatus*. Carrier ('93) determined that the hypaxial muscles fired in pairs during walking such that *M. o. e. superficialis* and *M. o. e. profundus* were active simultaneously and *M. obliquus internus* and *M. transversus abdominis* were active together.

Cross sections

Comparison of hypaxial muscles in cross-section at the midtrunk region revealed that interspecific variation exists in muscle location and relative thickness (Fig. 3, Table 3). Our cross sections are consistent with those published by Maurer ('11) for *Amphiuma* and *Cryptobranchus* and in agreement with illustrations from Naylor ('78) for *Siren*. Cross sections showed that thicker hypaxial musculature is associated with the fully aquatic, swimming salamanders and thinner hypaxial musculature is associated with the more terrestrial species (Fig. 3, Table 3). This trend within salamanders matches a general trend across classes; a comparison of trunk cross sections of teleost fishes, salamanders, and lizards, shows a reduction in relative body wall thickness as well as a decrease in relative size and more dorsal placement of the epaxial musculature with increasing terrestrial behavior (Romer, '70).

Intraspecific variation

Intraspecific variation in the presence and absence of hypaxial muscle layers was observed in three of the salamander species examined here. *Siren lacertina* shows either three or four layers. Intraspecific variation of muscle layers has not been documented previously for this species. Interestingly, this variation (three vs. four hypaxial muscle layers) is also observed between species; Naylor ('78) reported that *S. lacertina* has three layers of hypaxial muscle while *S. intermedia* has four layers.

Some observations have been made on intraspecific variation of the number of hypaxial muscle layers in *Necturus maculosus*. Although all three specimens examined in this study had only three layers, other studies have documented four hypaxial layers (the addition of an external oblique layer) in *N. maculosus* specimens (Naylor, '78; Brainerd et al., '93).

Naylor ('78) described only three hypaxial muscle layers for adult *Gyrinophilus porphyriticus*: *M. obliquus externus superficialis*, *M. obliquus externus profundus*, and *M. transversus abdominis*. However, the three *G. porphyriticus* specimens examined in this study have a partial fourth, *M. obliquus internus* layer of muscle. In these specimens, the *M. obliquus internus* is thin and restricted to the mid-lateral region, not extending ventrally.

Intraspecific variation of hypaxial muscle morphology may have been underestimated in this report and by Naylor ('78) due to the relatively small sample size of each species examined. Furthermore, interspecific variation may also be underrepresented within genera or families as the surveys of salamander musculature (Naylor '78; this study) are not comprehensive.

Phylogeny and ecology

We observed morphological variation of the hypaxial musculature at the familial, generic, and specific levels. Both across and within families, salamander species showed two, three, or four layers of hypaxial muscle (Table 1). Moreover, within the family Salamandridae, for example, although both *Triturus marmoratus* and *Euproctus asper* have three layers of hypaxial muscle, the layers are different; *T. marmoratus* has three layers that include the *M. obliquus externus*, *M. obliquus internus*, and *M. transversus abdominalis*, while *E. asper* has three layers that include the *M. obliquus externus superficialis*, *M. obliquus externus profundus*, and *M. obliquus internus/M. transversus abdominalis* (Table 1). Variation was also observed at the intrageneric level: *T. cristatus* has four layers (*Mm. o. e. superficialis*, *o. e. profundus*,

obliquus internus, *transversus abdominalis*); *T. marmoratus* has three layers, as described above; *T. helveticus* has two layers (*M. obliquus externus* and *M. obliquus internus/M. transversus abdominalis*) (Naylor, '78; Table 1). The number of hypaxial muscle layers also varied intraspecifically (e.g., *Necturus maculosus* and *Siren lacertina*) (Table 1).

When mapped onto a family-level phylogeny for Caudata (Larson and Dimmick, '93), variation in the number of layers is not explained by the phylogenetic affinities of the families (Fig. 4). Given that the full range of two, three, or four layers is seen within some genera, it is perhaps not surprising that there is no phylogenetic signal at the family level.

Character polarization regarding the presence or absence of hypaxial muscles is difficult to assess due to the lack of informative outgroups (fishes and amniotes) and the fact that the phylogenetic relationships between the three groups of extant amphibians (Anura, Gymnophiona, and Caudata) remain uncertain. Frogs have only two layers of lateral hypaxial musculature which are generally identified as the *M. obliquus externus* and *M. transversus abdominalis* (Noble, '31; Duellman and Trueb, '86). However, de

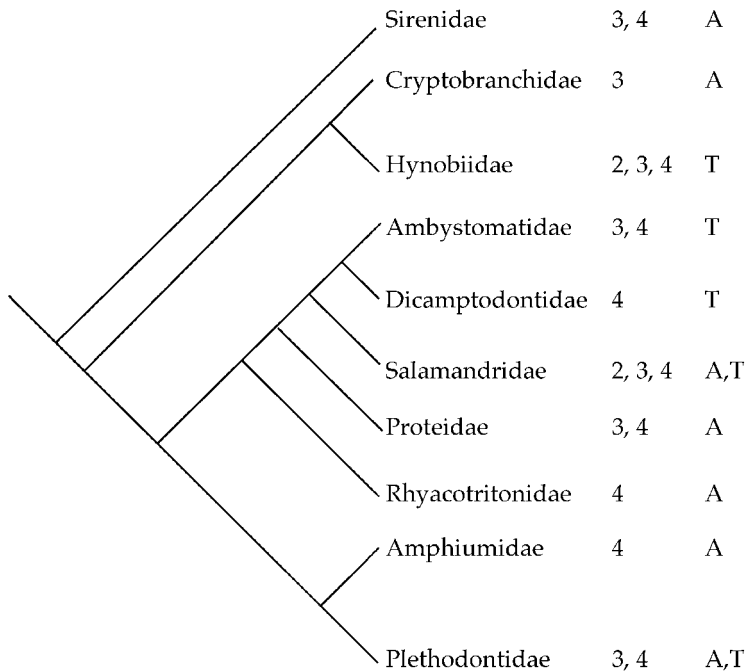


Fig. 4. A phylogenetic hypothesis (Larson and Dimmick, '93) describes the relationship of ten salamander families. The numbers of layers of lateral hypaxial musculature observed in each family are mapped onto the cladogram. Aquatic (A) or terrestrial (T) describes the predominant ecological habit of the adult (metamorphosed) salamanders that were examined in each family (Duellman and Trueb, '86; Bishop, '43).

Jongh and Gans ('69) classified the two hypaxial muscle layers of the bullfrog (*Rana catesbeiana*) as the *M. obliquus externus* and the transverse muscle, with no particular homology of the inner layer implied. Caecilians have four layers of lateral hypaxial musculature, and, as in salamanders, the relative thickness and locations of muscles are variable (Naylor and Nussbaum, '80; Nussbaum and Naylor, '82).

The ecology (aquatic or terrestrial) and predominant locomotor mode (swimming or walking) of salamanders do not appear to be strongly associated with the number or fiber angle of hypaxial muscle layers (Table 2, Fig. 4). However, some patterns may exist as we observe a weak tendency for aquatic species to have a single external oblique (Table 2). In addition, the *M. obliquus internus* often has a lower fiber angle in the aquatic species, and the *M. transversus abdominis* tends to have a lower fiber angle in the terrestrial species (Table 2). These patterns and their association with body form are addressed in ongoing work (Brainerd and Simons, '99, submitted).

Ecology and locomotor mode are associated with the overall thickness of the lateral hypaxial muscles. As discussed above, relatively thick lateral hypaxial layers are associated with aquatic, swimming salamanders while relatively thinner hypaxial muscles are found in the more terrestrial species (Table 3).

Metamorphosis, homology, and terminology

According to Noble ('31), two layers of lateral hypaxial muscle each give rise to an additional layer during ontogeny. The original outer layer gives rise to an additional outermost layer while the original inner layer gives rise to an innermost layer (i.e., the *M. obliquus externus profundus* and *M. obliquus internus* appear earliest in development). The orientation of the fibers of these muscle layers suggests that in cases in which salamander species exhibit only two layers, the laterally placed layer (*M. obliquus externus*) is homologous with the *M. obliquus externus superficialis*, *M. o. e. profundus*, or both, while the more medial layer (*M. obliquus internus*/*M. transversus abdominis*) is homologous with the *M. obliquus internus*, *M. transversus abdominis*, or both. But further discrimination of the layer homologies remains undocumented.

Naylor ('78) observed that the general larval condition is to have four layers of hyp-

axial musculature, and that some species lose one or even two layers during metamorphosis. Yet few larval species have, in fact, been examined and the homology of layers across metamorphosis, as well as across species, is not well substantiated in the literature. This leads us to suggest careful use of nomenclature to avoid misrepresentation of muscle homology. We suggest that a single external layer should be called *M. obliquus externus*, and a single internal layer should be called *M. obliquus internus*/*M. transversus abdominis*. The designations *Mm. obliquus externus superficialis*, *obliquus externus profundus*, *obliquus internus*, and *transversus abdominis* should only be applied in cases where evidence (such as four layers) suggests these homologies are likely.

CONCLUSIONS

This study has exposed unexpected variability within the lateral hypaxial musculature of salamanders. Variation of the number of muscle layers, fiber angles of muscles, and cross-sectional area is observed at the family, genus, species, and intraspecific levels. This study sets the groundwork for further investigation of this complex muscle group, and poses a variety of questions for further research. What is the functional significance of this variation? Are four layers, rather than two or three layers, associated with more complex breathing or locomotor behaviors? Is morphological variation of the hypaxial musculature correlated with ecology or locomotion? The function of the hypaxial muscle group is likely to be complex, and there may be many ways to achieve the same locomotor or breathing actions. Until functional studies address these questions directly, we must be careful about drawing overly simplified conclusions regarding hypaxial muscle form and function.

ACKNOWLEDGMENTS

We thank D. Homberger and D. Wake for useful discussions on the complexity of salamander hypaxial musculature. We also thank W. Bennett, N. Kley, M. Mahoney, and J. O'Reilly for helpful comments on the manuscript, B. Shurtleff for data collection, and B. Moon and the University of Michigan Museum of Zoology for providing a *Dicamptodon* sp. specimen. This work was supported by NSF IBN 9419892 to E.L.B.

LITERATURE CITED

- Barker KR, Breland OP. 1980. A laboratory manual of comparative anatomy. New York: McGraw-Hill.
- Bishop SC. 1943. Handbook of salamanders. Ithaca: Cornell University Press.
- Brainerd EL. 1998. Mechanics of lung ventilation in a larval salamander, *Ambystoma tigrinum*. *J Exp Biol* 201:2891–2901.
- Brainerd EL, Monroy JA. 1998. Mechanics of lung ventilation in a large aquatic salamander, *Siren lacertina*. *J Exp Biol* 201:673–682.
- Brainerd EL, Simons RS. 1999. Evolutionary morphology of lateral hypaxial musculature in tetrapods. *Am Zool* 38:176A.
- Brainerd EL, Ditelberg JS, Bramble, DM. 1993. Lung ventilation in salamanders and the evolution of vertebrate air-breathing mechanisms. *Biol J Linn Soc* 49:163–183.
- Carrier DR. 1993. Action of the hypaxial muscles during walking and swimming in the salamander *Dicamptodon ensatus*. *J Exp Biol* 180:75–83.
- de Jongh HJ, Gans C. 1969. On the mechanism of respiration in the bullfrog *Rana catesbeiana*: a reassessment. *J Morphol* 127:259–290.
- Duellman WE, Trueb L. 1986. Biology of amphibians. Baltimore: Johns Hopkins University Press.
- Kardong KV, Zalisko EY. 1998. Comparative vertebrate anatomy. Boston: WCB McGraw-Hill.
- Larson A, Dimmick WW. 1993. Phylogenetic relationships of the salamander families: an analysis of congruence among morphological and molecular characters. *Herp Monogr* 7:77–93.
- Maurer F. 1911. Die ventrale Rumpfmuskulatur von *Menobranchus*, *Menopoma* und *Amphiuma*. *Morph Jb* 22:225–264. *Jena Zeits Naturwiss* 47:1–42.
- Naylor BG. 1978. The systematics of fossil and recent salamanders with special reference to the vertebral column and trunk musculature. Ph.D. Thesis, Edmonton: University of Alberta.
- Naylor BG, Nussbaum RA. 1980. The trunk musculature of caecilians (Amphibia: Gymnophiona). *J Morphol* 166:259–273.
- Noble GK. 1931. The biology of the amphibia. New York: McGraw-Hill.
- Nussbaum RA, Naylor BG. 1982. Variation in the trunk musculature of caecilians (Amphibia: Gymnophiona). *J Zool Lond* 198:383–398.
- Romer AS. 1970. The vertebrate body. 4th ed. Philadelphia: WB Saunders.
- Rosenzweig LY. 1988. The anatomy of *Necturus*. Dubuque, IA: Wm C Brown.
- Walker WF, Homberger DG. 1992. Vertebrate dissection, 8th ed. Orlando: Harcourt Brace.
- Wischnitzer S. 1993. Atlas and dissection guide for comparative anatomy. 5th ed. New York: WW Freeman.