

Morphometric Analysis of Bruch's Membrane, the Choriocapillaris, and the Choroid in Aging

Raan S. Ramrattan,* Theo L. van der Schaft,* Cornelia M. Mooy,*†
Wim C. de Bruijn,† Paul G. H. Mulder,‡ and Paulus T. V. M. de Jong*

Purpose. To quantify changes in choriocapillary density and in thickness of Bruch's membrane, the choriocapillaris, and the choroid in 95 unpaired, histologically normal human maculae aged 6 to 100 years and in 25 maculae with advanced age-related macular degeneration.

Methods. Light microscopic, computer-aided, morphometric quantitative analysis.

Results. In ten decades, Bruch's membrane thickness increased by 135%, from 2.0 to 4.7 μm ; the choriocapillary density decreased by 45%; the diameter of the choriocapillaris decreased by 34%, from 9.8 to 6.5 μm ; and the choroidal thickness decreased by 57%, from 193.5 to 84 μm in normal maculae. In maculae with basal laminar deposit, geographic atrophy, or disciform scarring, the density of the choriocapillaris was 63%, 54%, and 43% of normal and the choriocapillary diameter was 81%, 73%, and 75% of normal, respectively. Choroidal thickness remained unchanged.

Conclusions. Thickness of Bruch's membrane was only related to age ($r_s = 0.63$) and not to age-related atrophy of the choriocapillaris. Age was also the strongest factor related to choriocapillary density ($r_s = -0.58$). In advanced stages of age-related macular degeneration, the decrease in choriocapillary density and diameter was significantly larger than in normal maculae, but the thickness of the choroid and Bruch's membrane was the same. The latter was significantly thinner (81% of normal) in disciform scarring. *Invest Ophthalmol Vis Sci.* 1994;35:2857-2864.

Age-related macular degeneration (AMD) is considered to be multifactorial in origin.^{1,2} However, the factors that initiate these changes have not yet been identified.

Histologically, AMD has been described as the presence of multiple or confluent hard drusen, soft drusen, a thick layer of basal laminar deposit (BLD),³⁻⁵ atrophy of both the retinal pigment epithelium (RPE) and photoreceptors (geographic atrophy), or subretinal neovascularization with the subsequent formation of a disciform scar.⁶ Drusen were defined as deposits that contain cellular fragments and were located between the RPE basement membrane and the inner col-

lagenous zone of Bruch's membrane (BrM). The main differences between hard and soft drusen were the size and the composition of the contents. BLD is an accumulation of deposits, mainly consisting of long-spacing collagen and some cellular fragments. BLD is located between the RPE plasma membrane and its basement membrane.⁵ The term geographic atrophy was used when there was a profound atrophy of the RPE and the overlying photoreceptors without the presence of a subretinal hemorrhage or fibrovascular scar, as is seen in disciform macular degeneration. To describe BrM, the current concept of three layers was used, which involves the inner and outer collagenous zone and the elastic layer. Thus, the histopathologic changes mentioned above were located outside BrM.

It has been postulated that atrophy of the choriocapillaris in the macula, characterized light microscopically by a decrease in the number and diameter of capillaries, might be an important factor in the pathogenesis of AMD.⁷ Histologically, it has been demonstrated that patches of atrophy of the RPE usually correspond to the lobular structure of the chorioca-

From the Departments of *Ophthalmology, †Clinical Pathology, and ‡Epidemiology and Biostatistics, Erasmus University, Rotterdam, The Netherlands.

Supported by the Haags Oogheekundig Fonds Foundation, The Hague, The Netherlands.

Submitted for publication May 14, 1993; revised September 21, 1993; accepted December 6, 1993.

Proprietary interest category: N.

Reprint requests: Paulus T.V.M. de Jong, MD, PhD, FRCOphth, Department of Ophthalmology, Erasmus University, P.O. Box 1738, 3000 DR Rotterdam, Rotterdam, The Netherlands.

pillaris,^{8,9} which is functionally (but not anatomically) an endarterial system.^{10,11} Atrophy with a reduced perfusion of the choriocapillaris has been identified as a separate cause of visual impairment in eyes with geographic atrophy.¹² Biochemical investigations have shown both a trophic and an inhibiting interaction between the RPE and the choriocapillaris.¹³⁻¹⁵

These observations make it conceivable that atrophy of the choriocapillaris, possibly in combination with changes in the thickness¹⁶ or composition^{17,18} of BrM, may initiate or aggravate impairment of metabolism in the RPE and subsequently in the photoreceptor cells.¹⁹ The degree to which changes in the choriocapillaris and choroid^{3,20} can be attributed to normal aging and in which sense these changes differ from those characteristic of the various stages of AMD, is still uncertain. Furthermore, the correlation between age-related atrophy of the choriocapillaris and the choroid and thickening of BrM has not been examined systematically in a large group of eyes.

In this investigation, the range of variations in the thickness of BrM, atrophy of the choriocapillaris, and the choroidal thickness and their mutual relationships were studied quantitatively in a series of 95 normal human maculae of all ages and 25 maculae with various histologic stages of AMD.

METHODS

We obtained 120 unpaired human eye bank and autopsy eyes, consisting of 112 phakic and eight pseudophakic eyes. Eyes from subjects with a history of diabetes mellitus or panretinal photocoagulation were excluded from this study.

The eyes were processed as previously described.²¹ In short, after formaldehyde fixation (4% vol/vol), a horizontal tissue block, including the optic disc and the macula, was cut from the hemisectioned globe, dehydrated with graded alcohols, and embedded in paraffin. At least three sections (7 μm thick at 140 μm intervals) were cut and stained with the Mallory stain for light microscopy.

In each histologic section, four variables were measured (Fig. 1): the thickness of BrM, the length of the lumen of each capillary in the choriocapillaris, the luminal diameter of the capillaries, and the choroidal thickness in the foveal area.

The thickness of BrM was defined as the distance between the RPE side of the inner collagenous zone and the choriocapillaris side of the outer collagenous zone. The thickness of BrM was not assessed in the intercapillary pillars, which have indistinct borders on the choroidal side. For each macula, the ratio of the sum of the lengths of the lumina of the capillaries to the length of the zone in which measurements were made was computed. This ratio, which theoretically

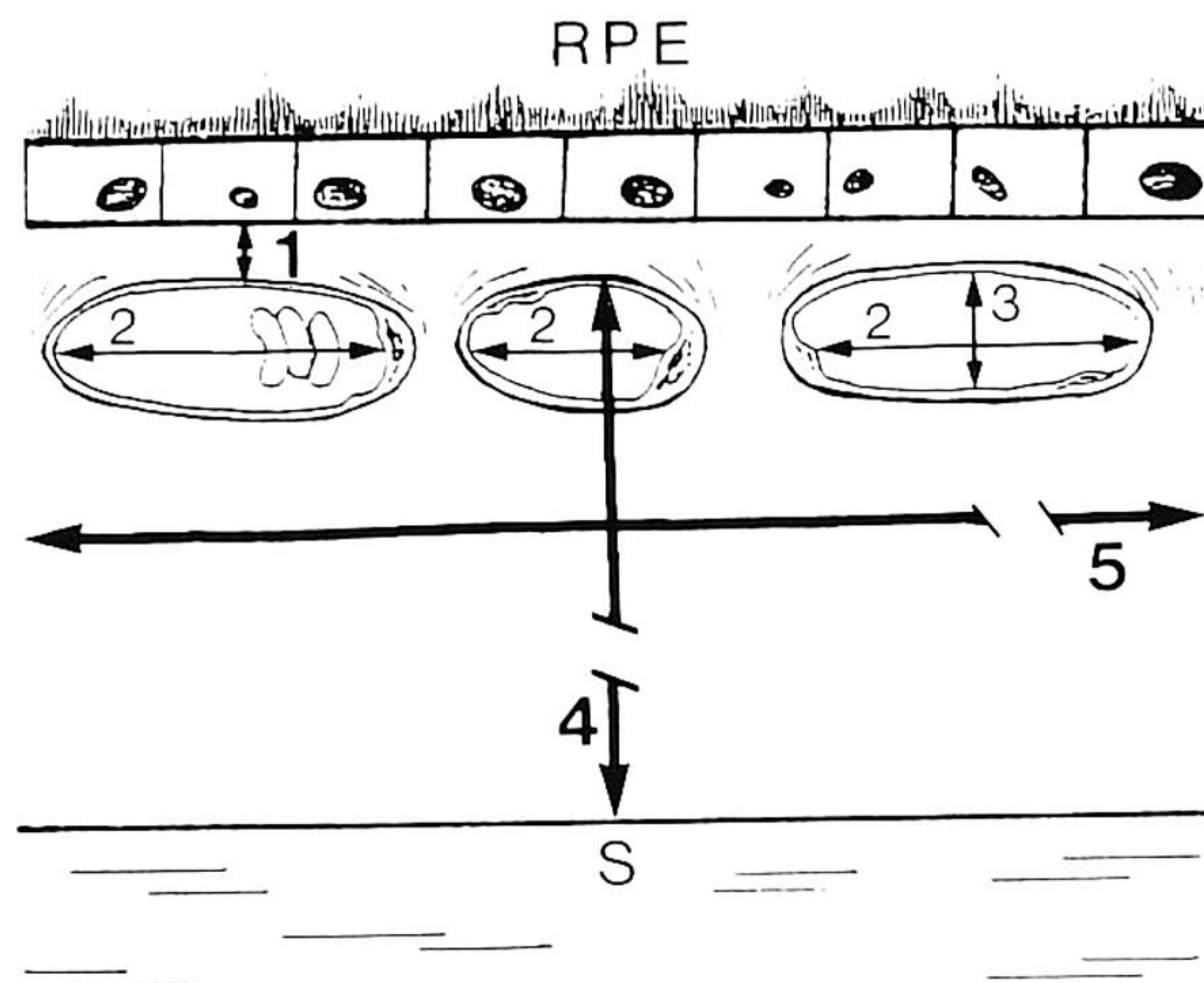


FIGURE 1. Diagram illustrating the way in which measurements were performed in histologic sections of the maculae. For instructional purposes, the thickness of Bruch's membrane has slightly been exaggerated: 1 = thickness of Bruch's membrane; 2 = length of capillary lumen measured parallel to Bruch's membrane; 3 = cross-sectional diameter of capillary lumen measured perpendicular to Bruch's membrane; 4 = choroidal thickness including the choriocapillaris; 5 = total distance (1120 μm) along Bruch's membrane within which measurements were made. RPE = retinal pigment epithelium. S = sclera.

can range from 0 to 1, will subsequently be referred to as the capillary density of the choriocapillaris. The capillary luminal diameter was measured perpendicular to BrM. The thickness of BrM and the capillary diameter were measured eight times in each histologic section at regularly spaced intervals of 140 μm (see below). These values were averaged. Choroidal thickness was defined as the distance between the outer border of BrM and the inner border of the sclera in the foveal area, thus including the choriocapillaris.

Measurements were performed using a digital image-processing system (IBAS 2000 system, Kontron, München, Germany) with a final on-screen magnification of 1295 \times and a spatial resolution of 0.2710 μm .

Measurements were taken exactly in the center of the maculae in a standardized zone measuring 1120 μm along BrM and including the fovea and foveola. The distance of 1120 μm (divided in $8 \times 140 \mu\text{m}$) was chosen because of practical limitations involving the image-processing system.

Local variations in the four measured variables were determined by comparing the measurements obtained from two sections from 10 normal maculae, one representing each decade.

Intraobserver variation was assessed by comparing the results of measuring the same section from 10 normal maculae, one representing each decade, twice

in a masked way at a 3-month interval. To determine the interobserver variation, 10 maculae, one representing each decade, were examined by the first two authors independently of each other.

The histologic changes were examined in 95 of the 120 maculae without late stages of AMD. In these maculae, which for the purposes of this study will be called normal maculae,^{3,21,22} the number of small, hard drusen could be classified as class 0 (no drusen) or class 1 (1 to 3 drusen), as previously described.²¹ Either there was no BLD (class 0) or small patches of BLD were present (class 1). The age of the subjects ranged from 6 to 100 years (mean, 61 years). On the other hand, 25 of the 120 maculae were selected on the basis of histopathologic changes such as hard drusen class 2 or 3 (4 to 10 or many or confluent drusen), BLD class 2 or 3 (thin continuous layer or thick layer of half the height of the RPE),²¹ geographic atrophy or disciform scarring. This group of pathologic maculae was subdivided into seven maculae demonstrating only BLD class 3, 10 maculae exhibiting geographic atrophy, and eight maculae from pseudophakic eyes with disciform scarring. The age of the subjects ranged from 40 to 98 years (mean, 85 years) in the group of pathologic maculae from phakic eyes, and from 65 to 90 years (mean, 81 years) in the group of pathologic maculae from pseudophakic eyes.

Statistical Analysis

For statistical analysis, Spearman's rank-correlation test was used to determine monotonic relationships between any two of the variables: age, thickness of BrM, choriocapillaris density, choriocapillaris diameter, and choroidal thickness in sections from normal maculae. Partial correlation analyses, which adjust the correlation between two variables for the confounding influence of a third variable, were also performed to clarify observed rank correlations between variables. The relationship between age and either thickness of BrM, choriocapillaris density, choriocapillaris diameter, or choroidal thickness were quantified using linear regression analysis. Multiple log-linear regression analysis was applied to compare normal and pathologic maculae while adjusting for age. In the group of pathologic maculae from phakic eyes, the data of the histologically abnormal part of the sections (that is, BLD class 3, geographic atrophy) were first pooled before comparison with the measurements of normal maculae. The data on pseudophakic eyes with disciform scarring were analyzed separately from the data on the phakic eyes. To detect significant local variations in the measured variables within the same macula, Wilcoxon matched-pair signed rank tests were applied. This test was also used to evaluate the statistical significance of intraobserver and interobserver variation. Intraobserver and interobserver variation could not

be expressed as kappa-values because kappa-values only pertain to (ordered) categorical variables, whereas our measurements resulted in continuous variables. *P* values below 0.01 for Spearman's rank-correlation test and below 0.05 for the other tests were considered to be significant.

RESULTS

Normal Maculae

The thickness of BrM in normal maculae increased by 135% from 2.0 μm in the first decade to 4.7 μm in the tenth decade (Fig. 2). With increasing age, a skewed distribution toward higher values was observed.

The choriocapillaris density in normal maculae decreased in a linear fashion from 0.75 in the first decade to 0.41 in the tenth decade (Fig. 3). However, high age was not invariably related to low choriocapillaris density. With increasing age, the variability of the choriocapillaris density increased, and in several aged subjects, the choriocapillaris density appeared to be comparable to that found for much younger subjects.

The choriocapillaris diameter in normal maculae decreased from 9.8 μm in the first decade of life to 6.5 μm in the tenth decade (Fig. 4).

The choroidal thickness in normal maculae decreased linearly from 193.5 μm in the first decade to

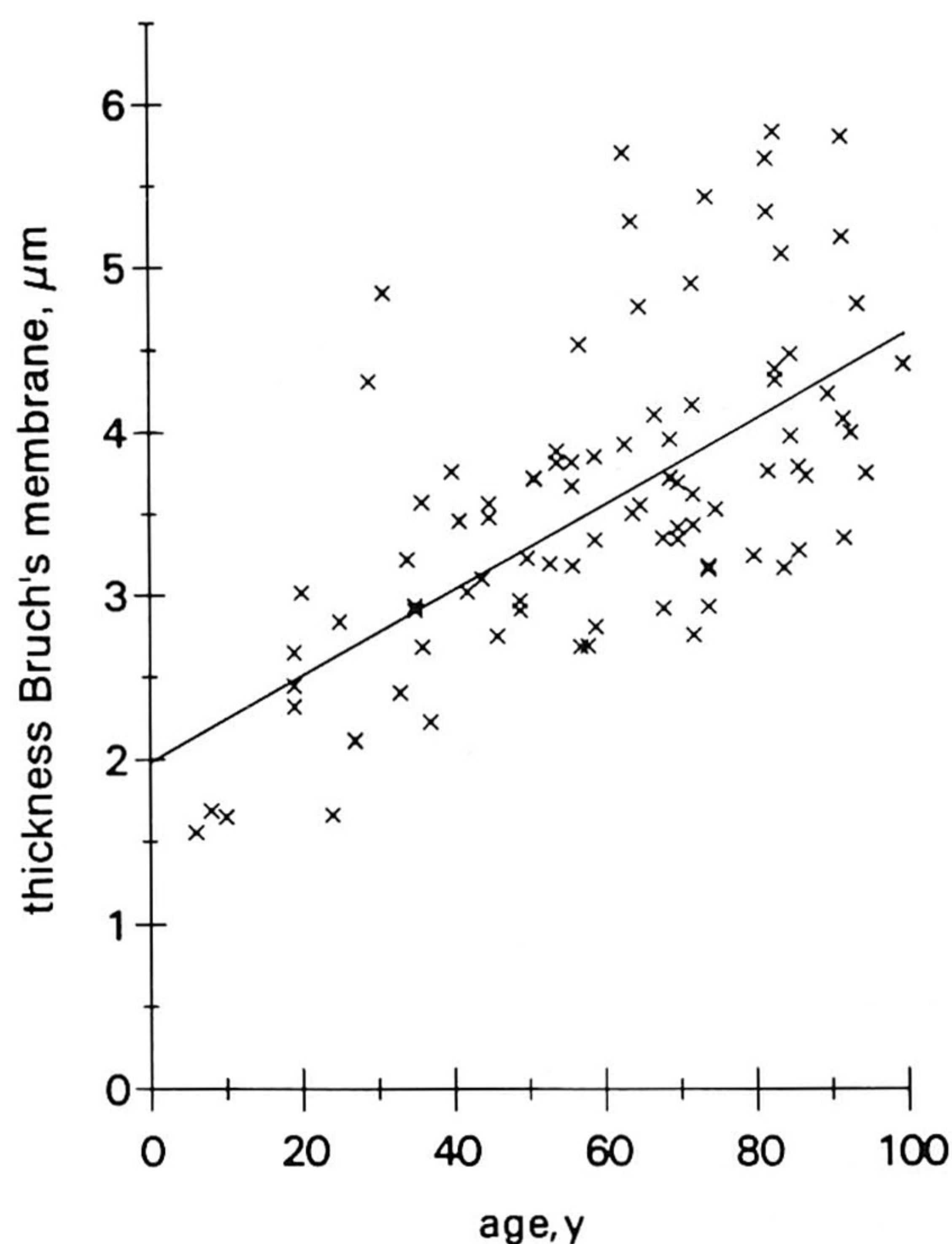


FIGURE 2. Thickness of Bruch's membrane in 95 histologically normal maculae plotted against age. The solid line represents the best linear fit to the data. Thickness of Bruch's membrane = $2.00 + 0.027 \times \text{age}$ ($r^2 = 0.42$, $P < 0.00005$).

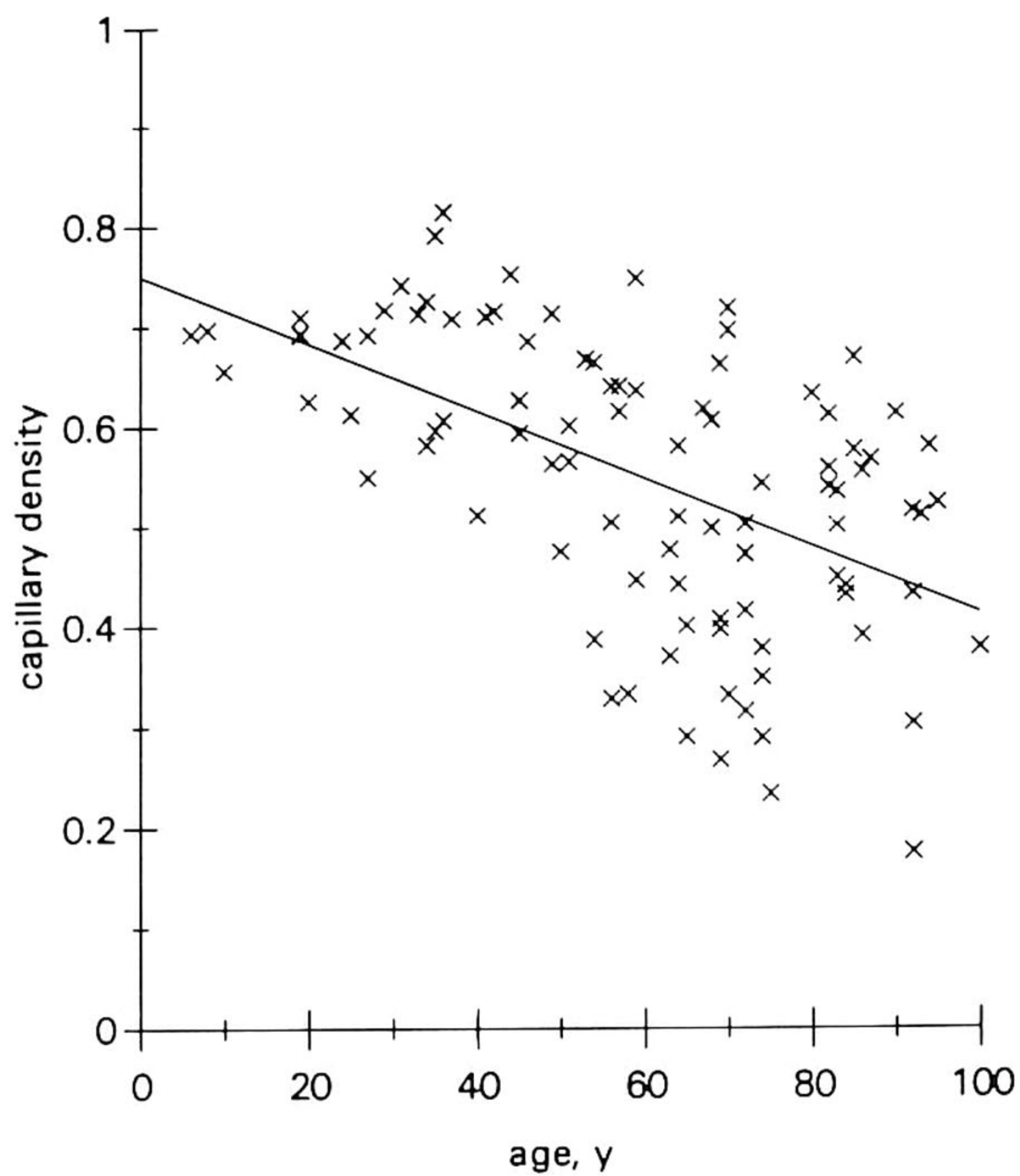


FIGURE 3. Capillary density of choriocapillaris in 95 histologically normal maculae plotted against age. The solid line represents the best linear fit to the data. Capillary density = $0.75 - 0.0034 \times \text{age}$ ($r^2 = 0.31$, $P < 0.00005$).

84 μm in the tenth decade (Fig. 5). Variations in choroidal thickness were, however, large for all ages.

The rank correlations between age, thickness of BrM, choriocapillaris density, choriocapillaris diameter, and choroidal thickness in normal maculae are presented in Table 1. Capillary density was closely correlated with capillary diameter ($r_s = 0.64$), which may reflect the fact that both parameters are affected by choriocapillaris atrophy. Capillary density exhibited a moderate negative correlation with the thickness of BrM ($r_s = -0.36$) and a moderate positive correlation with choroidal thickness ($r_s = 0.34$). There was no statistically significant correlation between the choroidal thickness and the thickness of Bruch's membrane ($r_s = -0.22$, $P = 0.19$). Thus, the correlations between the histologic parameters in Table 1 confirm what was to be expected from earlier qualitative histologic observations:³ If there is some degree of choriocapillaris atrophy, BrM is often thickened and the choroidal thickness is often decreased. However, qualitative observations in this transversal study of the relationship between these histologic parameters and their quantification by correlation coefficients cannot sufficiently distinguish between direct links and indirect links, whereas quantification by partial correlation coefficients can do so.

When partial correlation coefficients were calculated, it appeared that changes in choriocapillaris den-

sity in normal maculae could significantly be explained only by age ($r = 0.56$, $P < 0.00005$) and not by either thickness of BrM ($r = -0.07$, $P = 0.49$) or choroidal thickness ($r = 0.15$, $P = 0.16$). The rank correlations of choriocapillaris density with thickness of the choroid and BrM were therefore substantially mediated by age, which consequently appeared to be the strongest factor directly related to choriocapillaris density.

Partial correlation calculations for choriocapillaris diameter showed a direct positive correlation with choroidal thickness ($r = 0.52$, $P < 0.00005$) and, to a much lesser extent, a direct negative correlation with age ($r = -0.18$, $P = 0.04$). The thickness of BrM was only directly related to age ($r = 0.61$, $P < 0.00005$) and not directly related to choriocapillaris diameter. The observed negative rank correlation (Table 1) between thickness of BrM and choriocapillaris diameter was thus confounded by age.

Comparison With Pathologic Maculae

In Table 2, the results of the age-adjusted comparison of normal maculae and pathologic maculae are presented. The total number (N) of pathologic maculae in Table 2 exceeds the 25 maculae mentioned in the Methods section because in several cases both BLD and geographic atrophy were present in one macula,

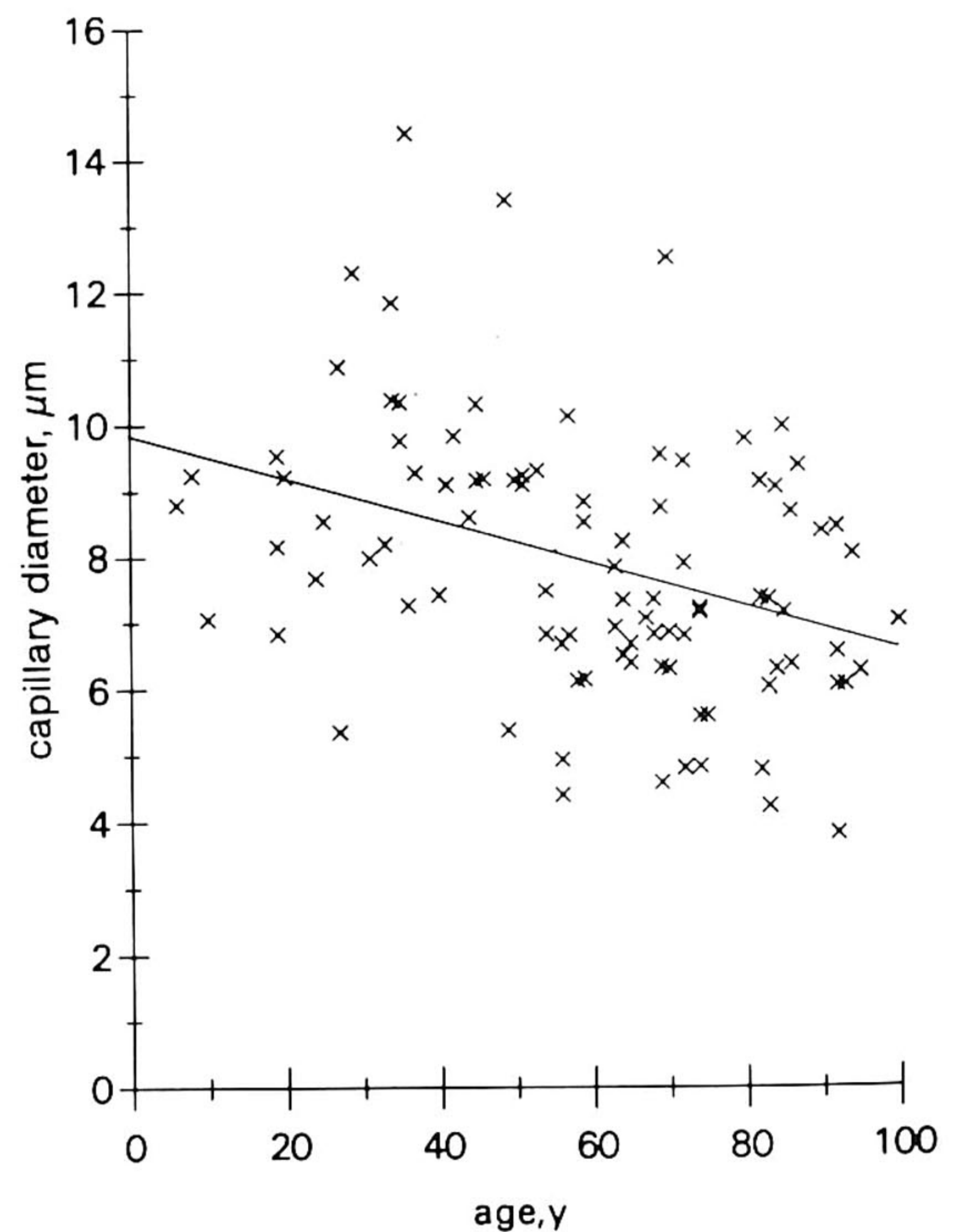


FIGURE 4. Choriocapillary lumen diameter in 95 histologically normal maculae plotted against age. The solid line represents the best linear fit to the data. Capillary diameter = $9.85 - 0.033 \times \text{age}$ ($r^2 = 0.14$, $P = 0.0001$).

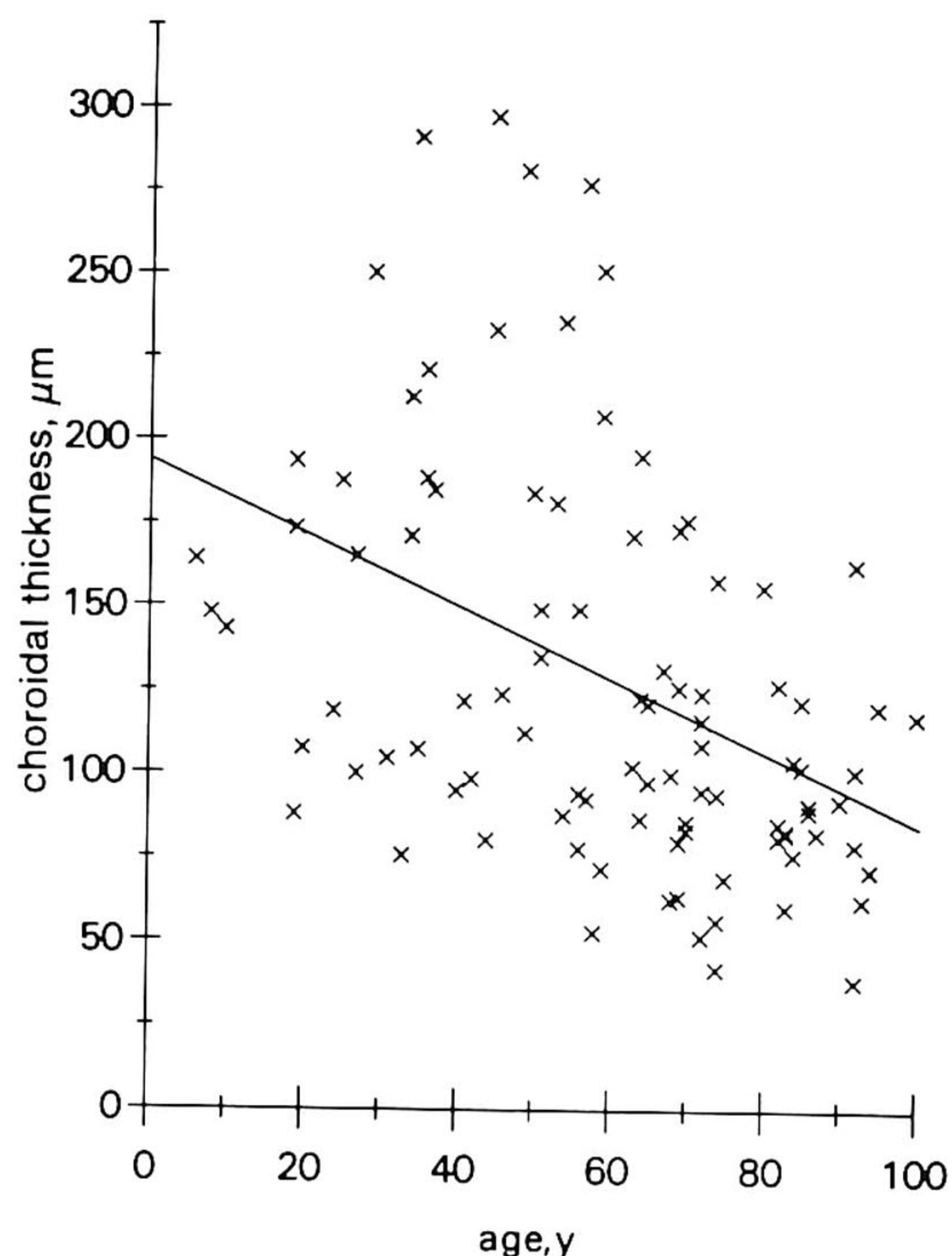


FIGURE 5. Choroidal thickness in 95 histologically normal maculae plotted against age. The solid line represents the best linear fit to the data. Choroidal thickness = $193.5 - 1.10 \times \text{age}$ ($r^2 = 0.18$, $P < 0.00005$).

albeit in different parts of the macula. Therefore, the results of measurements related to BLD were not influenced by the measurements related to geographic atrophy. The thickness of BrM did not significantly differ from normal in areas with BLD or geographic atrophy. In areas with disciform scarring, however, BrM was significantly thinner (81% of normal). The choriocapillaris density was lower in areas with disciform scarring (43% of normal) than in areas underlying geographic atrophy (54% of normal) or BLD (63% of normal). The choriocapillaris diameter was also significantly decreased, but to an equal extent in maculae with geographic atrophy or disciform degeneration and slightly less in maculae with a thick layer of BLD (class 3).

In maculae demonstrating BLD, geographic atrophy or disciform scarring (Table 2), choroidal thickness was not found to be different from that in normal maculae.

There was no significant local variation in the thickness of BrM, choriocapillaris density, choriocapillaris diameter, and choroidal thickness between two sections of the same macula taken at 140 μm intervals (Table 3), nor was there between interobserver and intraobserver differences of statistical significance because all Wilcoxon test P values were larger than 0.05 (Table 4).

DISCUSSION

In this study, we quantified the changes in capillary density of the choriocapillaris for all decades and found that it diminished in a linear fashion from approximately 0.75 in the first decade to approximately 0.40 in the tenth decade. Partial correlation calculations revealed a close correlation with age ($r = 0.56$, $P < 0.00005$). These results confirm a previous study, in which planimetric evaluation of choroidal casts was used for morphometry of the choriocapillaris.²³ The intercapillary space, which is apart from the choriocapillaris wall thicknesses the complement of the added choriocapillaris lumina, was found to increase from 25% in four young subjects (21 to 50 years) to 60% in four old subjects (80 to 97 years).²³

The close correlation between the choriocapillaris density and choriocapillaris diameter (Table 1) is partially influenced by the fact that a decrease in diameter automatically results in a relatively small decrease in choriocapillaris density.

The cause of the age-related decrease in capillary density of the choriocapillaris is unknown. Apart from the skin²⁴ and testes,²⁵ for which an age-related decrease in capillary density has also been described, knowledge of the age-related changes in capillary meshworks in other tissues, as well as the possible causes, is scarce. However, an increase in periodic acid Schiff staining of capillary basement membranes and the surrounding extracellular matrix in the fifth decade has been reported for many body tissues, such as

TABLE 1. Rank Correlations Coefficients (r_s) for a Number of Variables in 95 Normal Maculae

	Thickness BrM*	Capillary Density	Capillary Diameter	Choroidal Thickness
Age	0.63	-0.58	-0.40	-0.48
Thickness BrM		-0.36	-0.27	-0.22†NS
Capillary density			0.64	0.34
Capillary diameter				0.52

* BrM = Bruch's membrane.

† NS = not significant. For all other correlation coefficients, $P < 0.0005$.

TABLE 2. Age-Adjusted Percentages (\pm SEM) of Measured Variables for Pathologic Maculae Relative to the Values of the Measured Variables for Normal Maculae

	<i>Pathologic Maculae</i>		
	<i>Basal Laminar Deposit</i> (<i>n</i> = 9)	<i>Geographic Atrophy</i> (<i>n</i> = 13)	<i>Disciform Scarring</i> (<i>n</i> = 10)
Thickness BrM* (%)	102 (\pm 7.9) <i>P</i> = 0.83	100 (\pm 6.9) <i>P</i> = 0.77	81 (\pm 8.0) <i>P</i> = 0.02†
Capillary density (%)	63 (\pm 11) <i>P</i> = 0.006†	54 (\pm 10) <i>P</i> < 0.00005†	43 (\pm 10) <i>P</i> < 0.00005†
Capillary diameter (%)	81 (\pm 9.7) <i>P</i> = 0.02†	73 (\pm 8.7) <i>P</i> = 0.005†	75 (\pm 9.0) <i>P</i> = 0.003†
Choroidal thickness (%)	85 (\pm 18) <i>P</i> = 0.82	81 (\pm 14) <i>P</i> = 0.46	89 (\pm 15) <i>P</i> = 0.54

* BrM = Bruch's membrane.

† Value of measured variable is significantly different from normal maculae, which values were put at 100%.

the brain, muscle, skin, and intestinal wall.²⁶ In the macula, the age-related decline in choriocapillaris density is also accompanied by an increase in periodic acid Schiff staining of BrM and widening of the intercapillary pillars.^{21,27} Thus, the age-related reduction of choriocapillaris density may have a systemic basis. The increase in the range of values of the choriocapillaris density with increasing age in normal maculae illustrates that a wide range in the age-related changes can still be considered normal. In the maculae with features of advanced AMD, the choriocapillaris density was significantly decreased in the presence of BLD, geographic atrophy, or disciform degeneration. This might be one of the causal factors in AMD, or it may be secondary to atrophy of the RPE. Biochemical alterations in the composition of the extracellular matrix between the choriocapillaris endothelium and the

RPE and in BrM could modify the diffusion characteristics of extracellular modulating factors produced by the RPE^{13,28} and choriocapillaris,²⁹ thereby causing atrophy of the choriocapillaris and damage to the RPE.

It has been postulated that a progressively thickened BrM could mechanically compress the choriocapillaries and cause a decrease in choriocapillaris diameter.^{3,30,31} The results of our study indicate, however, that the choriocapillaris diameter is directly correlated in normal maculae with choroidal thickness and age. Calculation of partial correlations showed that the thickness of BrM was of no importance in explaining the variation in choriocapillaris diameter. This is also consistent with our finding that in pathologic maculae with BLD, geographic atrophy or disciform degeneration in which a decrease in choriocapillaris diameter was found, the thickness of BrM did not differ from that in normal maculae of the same age groups. The presumed compressing properties of BrM inducing a decrease in choriocapillaris diameter in AMD could not be confirmed in our study. On the other hand, the hypothesis that an age-related decrease in choriocapillaris diameter could cause an increase in the thickness of BrM in normal maculae, for example, by not sufficiently clearing away RPE-derived debris,^{3,31} was also not substantiated by our results, as no direct relationship between the thickness of BrM and the choriocapillaris diameter was found in partial correlation calculations. Our results thus suggest that there is no relationship between age-related atrophy of the choriocapillaris and changes in thickness of BrM.

Our observation that the thickness of BrM does not differ between maculae with BLD or geographic atrophy and normal maculae suggests that accumulation of cellular debris in BrM is not significantly increased in these stages of AMD compared to normal aging. However, it might be possible that the chemical

TABLE 3. Absence of Significant Local Variability in Two Sections From One Macula in a Series of 10 Normal Maculae*

	<i>Mean Difference</i> (\pm <i>SD</i>) <i>P</i> Value
Thickness Bruch's membrane (μ m)	0.13 (\pm 0.40) <i>P</i> = 0.69
Capillary density	0.017 (\pm 0.031) <i>P</i> = 0.92
Capillary diameter (μ m)	0.55 (\pm 0.93) <i>P</i> = 0.07
Choroidal thickness (μ m)	14.15 (\pm 20) <i>P</i> = 0.19

* Tested for significant differences with Wilcoxon matched-pairs signed ranks test.

TABLE 4. Absence of Significant Interobserver and Intraobserver Variation: Mean Differences (\pm SD) Between Measured Values*

	<i>Interobserver Variation</i> †	<i>Intraobserver Variation</i> †
Thickness Bruch's membrane (μ m)	0.23 (\pm 0.64) <i>P</i> = 0.32	0.08 (\pm 0.16) <i>P</i> = 0.16
Capillary density	0.059 (\pm 0.10) <i>P</i> = 0.14	0.015 (\pm 0.05) <i>P</i> = 0.38
Capillary diameter (μ m)	0.22 (\pm 0.84) <i>P</i> = 0.45	0.13 (\pm 0.99) <i>P</i> = 0.70
Choroidal thickness (μ m)	7.03 (\pm 23) <i>P</i> = 0.32	4.76 (\pm 25) <i>P</i> = 0.59

* Tested for significant differences with Wilcoxon matched-pairs signed ranks test.

† N = 10 normal maculae.

composition of substances in BrM are altered in AMD, which could hamper the free diffusion of solutes between the RPE and choriocapillaris.³¹

The measured reduction in the thickness of BrM in disciform scarring, which has been suggested to result from the phagocytic action of macrophages directed against the outer collagenous zone of BrM, confirms the histopathologic observations made by others.³² We must keep in mind that the maculae with a disciform scar came from pseudophakic eyes in which other processes are involved, such as the mechanical trauma of cataract extraction, implantation of an intraocular lens and the presence of a foreign body in the eye. However, similar macrophage activity has been described in normal phakic eyes.³²

We could not confirm previous observations³ that the choroidal thickness is reduced in geographic atrophy and increased in disciform degeneration. A progressive decrease in choroidal thickness was found with advancing age.

The statistically nonsignificant interobserver and intraobserver variations in the measurements were almost completely within the normal range of the measured parameters in several histologic sections from the same macula and were negligible in comparison with the normal variation between maculae of the same decade. The nonsignificant interobserver and intraobserver variation are a reflection of the reproducibility of the applied measuring methods.

There was no significant local variation in the measured histologic parameters between two sections from the same macula in normal maculae. The 1120- μ m zone of the fovea, in which the measurements were taken, was sufficiently large to obtain representative results.

In conclusion, with advancing age, histologically normal maculae show a decrease in the density and diameter of the capillaries in the choriocapillaris, a decrease in choroidal thickness, and an increase in the

thickness of BrM. Atrophy of the choriocapillaris is not related to changes in thickness of BrM in normal maculae. In eyes with various stages of AMD, the decrease in capillary density and diameter was significantly larger than in normal maculae. In maculae with AMD, the thickness of both the choroid and BrM was not significantly different from that in normal maculae except for maculae with a disciform scar, which had a significantly thinner BrM.

Key Words

Bruch's membrane, choriocapillaris, choroid, age-related macular degeneration, morphometry

Acknowledgments

The authors thank the Eurotransplant Foundation, Leiden, and the Eye Bank of the Dutch Ophthalmic Research Institute, Amsterdam (Head, E. Pels, PhD) for providing most of the eyes.

References

1. Tso MOM. Pathogenic factors of age-related macular degeneration. *Ophthalmology*. 1985;92:628-635.
2. Young RW. Pathophysiology of age-related macular degeneration. *Ophthalmology*. 1987;31:291-306.
3. Sarks SH. Ageing and degeneration in the macular region: a clinico-pathological study. *Br J Ophthalmol*. 1976;60:324-341.
4. Löffler KU, Lee WR. Basal linear deposit in the human macula. *Graefe's Arch Clin Exp Ophthalmol*. 1986;224:493-501.
5. van der Schaft TL, de Bruijn WC, Mooy CM, Ketaars DAM, de Jong PTVM. Is basal laminar deposit unique for age-related macular degeneration? *Arch Ophthalmol*. 1991;109:420-425.
6. Bressler NM, Bressler SB, Fine SL. Age-related macular degeneration. *Surv Ophthalmol*. 1988;32:375-413.
7. Gass JDM. Pathogenesis of disciform detachment of the neuroepithelium. III. Senile macular degeneration. *Am J Ophthalmol*. 1967;63:617-644.

8. Weiter J, Fine BS. A histologic study of regional chorioidal dystrophy. *Am J Ophthalmol*. 1977;83:741-750.
9. Maguire P, Vine AK. Geographic atrophy of the retinal pigment epithelium. *Am J Ophthalmol*. 1986;102:621-625.
10. Krey HF. Segmental vascular patterns of the choriocapillaris. *Am J Ophthalmol*. 1975;80:198-202.
11. Torczynski E, Tso MOM. The architecture of the choriocapillaris at the posterior pole. *Am J Ophthalmol*. 1976;81:428-440.
12. Chen JC, Fitzke FW, Pauleikhoff D, Bird AC. Poor choroidal perfusion is a cause of visual impairment in age-related macular degeneration. ARVO Abstracts. *Invest Ophthalmol Vis Sci*. 1989;30(suppl):153.
13. Korte GE, Reppucci V, Henkind P. RPE destruction causes choriocapillary atrophy. *Invest Ophthalmol Vis Sci*. 1984;25:1135-1145.
14. Korte GE, Bellhorn RW, Burns MS. Remodelling of the retinal pigment epithelium in response to intracapillary capillaries: evidence that capillaries influence the polarity of epithelium. *Cell Tissue Res*. 1986;245:135-142.
15. Korte GE, Burns MS, Bellhorn RW. Epithelium-capillary interactions in the eye: the retinal pigment epithelium and the choriocapillaris. *Int Rev Cytol*. 1989;114:221-248.
16. Mancini MA, Frank RN, Keirn RJ, Kennedy A, Khoury JK. Does the retinal pigment epithelium polarize the choriocapillaris? *Invest Ophthalmol Vis Sci*. 1986;27:336-345.
17. Hewitt AT, Nakazawa K, Newsome DA. Analysis of newly synthesized Bruch's membrane proteoglycans. *Invest Ophthalmol Vis Sci*. 1989;30:478-486.
18. Pauleikhoff D, Marshall J, Bird AC. Histochemical and morphological correlation of aging changes in Bruch's membrane. ARVO Abstracts. *Invest Ophthalmol Vis Sci*. 1989;30(suppl):153.
19. Green WC, McDonnell PJ, Yeo JH. Pathologic features of senile macular degeneration. *Ophthalmology*. 1985;92:615-627.
20. Friedman E, Ivry M, Ebert E, Glynn R, Gragoudas E, Seddon J. Increased scleral rigidity and age-related macular degeneration. *Ophthalmology*. 1989;96:104-108.
21. van der Schaft TL, Mooy CM, de Bruijn WC, Oron FG, Mulder PGH, de Jong PTVM. Histologic features of the early stages of age-related macular degeneration. A statistical analysis. *Ophthalmology*. 1992;99:278-286.
22. Killingsworth MC. Age-related components of Bruch's membrane in the human eye. *Graefes Arch Clin Exp Ophthalmol*. 1987;225:406-412.
23. Olver J, Pauleikhoff D, Bird A. Morphometric analysis of age changes in the choriocapillaris. ARVO Abstracts. *Invest Ophthalmol Vis Sci*. 1991;31(suppl):47.
24. Yan Y. Age-related microvascular changes in skin. *Chung-Kuo-I-Hsueh-Yuan-Hsueh-Pao*. 1990;12:9-12.
25. Takizawa T, Hatakeyama S. Age-associated changes in microvasculature of human adult testis. *Acta Path Jap*. 1978;28:541-554.
26. Sobin SS, Bernick S, Ballard KW. Histochemical characterization of the aging microvasculature in the human and other mammalian and nonmammalian vertebrates by the periodic acid-schiff reaction. *Mech Ageing Dev*. 1992;63:183-192.
27. Friedman E, Smith TR. Pathogenesis: senile changes of the choriocapillaris of the posterior pole. *Transact Am Acad Ophthalmol Oto-Laryngol*. 1965;69:652-661.
28. Glaser BM, Campochiaro PA, Davis JL, Sato M. Retinal pigment epithelial cells release an inhibitor of neovascularization. *Arch Ophthalmol*. 1985;103:1870-1875.
29. Campochiaro PA, Glaser BM. Endothelial cells release a chemoattractant for retinal pigment epithelial cells in vitro. *Arch Ophthalmol*. 1985;103:1876-1880.
30. Friedman E, Smith TR, Kuwabara T. Senile choroidal vascular patterns and drusen. *Arch Ophthalmol*. 1963;69:220-230.
31. Pauleikhoff D, Chen JC, Chisholm IH, Bird AC. Choroidal perfusion abnormality with age-related changes in Bruch's membrane. *Am J Ophthalmol*. 1990;109:211-217.
32. Killingsworth MC, Sarks JP, Sarks SH. Macrophages related to Bruch's membrane in age-related macular degeneration. *Eye*. 1990;4:613-621.