

# Morphometry of the Human Lamina Cribrosa Surface

Jost B. Jonas, Christian Y. Mardin, Ursula Schlötzer-Schrehardt, and Gottfried O.H. Naumann

**The lamina cribrosa is a sieve-like perforation in the posterior part of the sclera, that allows passage of the retinal ganglion cell axons and central retinal vessels and preserves a pressure gradient between the intraocular and extraocular space. It has been termed the primary site of glaucomatous damage to the optic nerve. Using electron microscopy, the authors morphometrically evaluated the inner surface of the lamina cribrosa in 40 normal human donor eyes. There were 14 men and 21 women with a mean age of  $52 \pm 22$  yr (10–82 yr). Mean single pore area ( $0.004 \pm 0.001$  mm<sup>2</sup>) and summed pore area were significantly ( $P < 0.05$ ) larger and the ratio of summed pore area to lamina area was higher in the inferior and superior regions than in the temporal and nasal regions. The ratio decreased with increasing lamina cribrosa size. Count, size, form, and density of the pores were statistically independent of age, sex, side, and lamina cribrosa form. Pore count and summed pore area (mean:  $0.92 \pm 0.22$  mm<sup>2</sup>) increased significantly with enlarging lamina cribrosa size. The area of the lamina cribrosa openings for passage of the central retinal vessels was independent of the lamina cribrosa size. The high ratio of summed pore area to lamina area and the large single pore area may be pathogenetically important for the increased glaucoma susceptibility in the inferior and superior disc regions. The lack of a correlation between lamina cribrosa size and the area of the lamina cribrosa openings for the retinal vessels may explain why central retinal vessel occlusions occur independently of optic disc size. Invest Ophthalmol Vis Sci 32:401–405, 1991**

The lamina cribrosa in the posterior sclera, the site of entrance and exit of the retinal vessels and nerve fibers, respectively, is believed to help preserve a pressure gradient between the extraocular and intraocular space. Related on its inner surface to intrapapillary structures of the optic nerve head, the optic cup and the neuroretinal rim, ie, the optic nerve fibers emerging from its outer surface, become myelinated by oligodendrocytes to form the retrobulbar part of the optic nerve. The lamina cribrosa is condensed<sup>1</sup> in glaucomatous eyes, with increased intraocular pressure leading to an abnormally elevated trans-lamina-cribrosa pressure gradient. Based on morphologic studies and investigations of the rapid axoplasmic transport in eyes with artificially raised intraocular pressure, the lamina cribrosa has been labeled the site at which the damage in glaucoma occurs.<sup>2</sup>

Morphologic study of the lamina cribrosa showed larger pores and less connective tissue in the superior and inferior parts of the lamina cribrosa than its tem-

poral and nasal parts.<sup>3–7</sup> These studies were descriptive and did not measure the lamina cribrosa pores in absolute size units, ie mm, and/or they used cross sections of the lamina cribrosa and did not evaluate the inner lamina cribrosa surface. Dandona, Quigley, and coworkers<sup>7</sup> morphometrically examined cross sections at the midpoint level between the anterior and posterior limits of the lamina cribrosa and confirmed their results of earlier qualitative studies on the vitread surface of the lamina cribrosa.<sup>3,5</sup> They found that “the least connective tissue support was present in the inferior temporal quadrant of the lamina cribrosa, which may be related to the greater frequency of superior field defects in glaucoma.” Despite a larger lamina cribrosa area, pore count, and a presumably higher susceptibility to glaucoma, the connective tissue proportion and pore size distribution in black patients did not vary from those in whites.

Because of the normal, slightly bowed shape, cross sections of the entire lamina cribrosa of the lamina cribrosa were difficult to obtain on the same histologic slide.<sup>7</sup> Furthermore, the morphologic characteristics of the lamina cribrosa morphology vary at different levels,<sup>6</sup> so the ophthalmoscopic features found at the inner surface of the lamina cribrosa may not correlate with the anatomy in the deeper lamina cribrosa layers. Therefore, we evaluated morphometrically the vitread aspect of the lamina cribrosa in an

From the Department of Ophthalmology and Eye Hospital, University Erlangen-Nürnberg, FRG

Supported by Dr. Helmut und Margarte Meyer-Schwartzung Stiftung, and Deutsche Forschungsgemeinschaft DFG Jo 155/2-1.

Submitted for publication: February 16, 1990; accepted July 30, 1990.

Reprint requests: Dr. Jost B. Jonas, University Eye Hospital, Schwabachanlage 6, D-8520 Erlangen, FRG.

effort to quantitatively confirm the results of the previous studies<sup>3-7</sup> performed qualitatively on the inner lamina cribrosa surface or quantitatively in deeper lamina cribrosa layers. We sought to find morphometrical correlates of the typical configuration of the normal neuroretinal rim that is significantly larger in the inferior temporal disc sector followed by the superior temporal disc sector, the nasal and finally the temporal horizontal disc region<sup>8</sup>; the lack of a correlation between optic disc size and frequency of occlusions of the central retinal artery and vein in spite of a considerable interindividual variability of the optic disc size<sup>8</sup>; and a possible correlation between count of retrobulbar optic nerve fibers and optic disc size.<sup>9</sup>

### Materials and Methods

Forty human normal donor eyes (24 right eyes, 16 left eyes) of 35 white subjects (14 men, 21 women), with a mean age of 52 yr and SD  $\pm$  22 yr (range 10–82 yr), were included in the study. Eyes were considered normal if no signs of visible ocular surgery, retinal disease, or optic nerve damage were detected by gross examination and light microscopy. One randomly selected eye per subject was taken for interindividual comparison. The globes had been enucleated between 5 and 36 hr postmortem. They were refrigerated at a temperature of  $-85^{\circ}\text{C}$ . After thawing, the optic nerve was cut behind the globe. A  $6 \times 6$ -mm piece of the posterior eye wall, including the optic disc, was removed. The superior and nasal poles were marked, and the retina and choroid were removed mechanically. The remaining intralaminar nerve fibers were digested by incubation in a 3% trypsin solution at  $38^{\circ}\text{C}$  for 2.5 days. The tissue debris was cleared by ultrasound treatment in Ringer's solution for 10 min, soft mechanical removal of larger tissue parts, and repeated application of ultrasound for 10 min. The specimens, which consisted mainly of sclera and lamina trabecula, were fixed in 1% glutaraldehyde/4% formaldehyde solution. The optic disc border, that projected into the cleared optic cup, was cut away before the specimens were dried by a critical point method and shadowed with a gold-palladium mixture. Micrographs were taken with an electron microscope (Fig. 1). The lamina cribrosa was divided into a peripheral and central part by a circle that halved the radius. Twelve  $30^{\circ}$  clockwise sectors were defined. The total lamina cribrosa surface and each of the lamina cribrosa pores were outlined on a transparent foil and evaluated morphometrically.

To test the significance of differences, the nonparametric tests of Wilcoxon and Mann-Whitney were used. The shrinkage of the lamina cribrosa tissue was evaluated by measuring the optic disc area on macro-

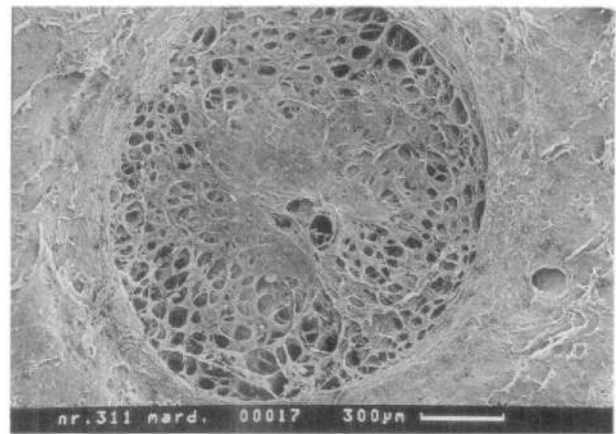


Fig. 1. Scanning electron micrograph of the lamina cribrosa of a right eye. Pore size and summed pore area in the inferior and superior regions larger than in the nasal and temporal regions; pore size increases with increasing distance from the center of the lamina cribrosa; the largest pores are located close to the lamina margin.

photographs before and after preparation of six additional optic discs with an aligned millimeter scale. In these eyes, the overlapping optic disc border was not removed. The linear shrinkage factor was averaged 0.81. For the upcoming data, the shrinkage was factored in to convert the measurements obtained on the prepared specimens to the original values before preparation.

### Results

Lamina cribrosa area ( $2.88 \pm 0.84 \text{ mm}^2$ ; mean:  $\pm$  S.D.) ranged from  $1.60 \text{ mm}^2$  to  $5.62 \text{ mm}^2$ , indicating an interindividual area variability of 1:3.5. The vertical diameter ( $1.58 \pm 0.21 \text{ mm}$ ) was about 2.5% longer than the horizontal one ( $1.54 \pm 0.22 \text{ mm}$ ). These data were independent of age ( $P = 0.74$ ) and right or left eye. They were not significantly ( $P = 0.78$ ) different in men (area:  $2.78 \pm 0.79 \text{ mm}^2$ ) and women (area:  $2.93 \pm 0.93 \text{ mm}^2$ ). The maximal diameter ( $2.03 \pm 0.28 \text{ mm}$ ) was usually 14% larger than the minimal diameter ( $1.78 \pm 0.29 \text{ mm}$ ).

Total count of the lamina cribrosa pores averaged  $227 \pm 36$  (168–292), with no significant difference between men ( $241 \pm 45$ ) and women ( $218 \pm 31$ ) ( $P = 0.16$ ). Pore count increased significantly with total lamina cribrosa area (correlation coefficient  $R = 0.50$ ; linear regression line  $Y = 0.22X + 164$ ;  $P = 0.005$ ). Pore count was not significantly correlated with age ( $P = 0.90$ ), right or left eye, and lamina cribrosa form ( $P = 0.87$ ).

Mean single pore area and summed pore area were significantly ( $P < 0.05$ ) larger in the superior and inferior regions than in the temporal and nasal sectors. In all sectors, the pores were larger in the periph-

eral region than in the central region and they were largest close to the lamina cribrosa border (Fig. 1).

Single pore area (mean:  $0.004 \pm 0.001 \text{ mm}^2$ ) and total pore area (mean:  $0.92 \pm 0.22 \text{ mm}^2$ ; minimum:  $0.60 \text{ mm}^2$ ; maximum:  $1.54 \text{ mm}^2$ ) showed the tendency to increase with lamina cribrosa size. This correlation was not significant for the single pore area (correlation coefficient  $R = 0.33$ ;  $P = 0.07$ ). It was statistically significant for the summed pore area (Fig. 2). Due to the increasing interpore tissue area, the ratio of summed pore area to lamina cribrosa area decreased with enlarging lamina cribrosa (Fig. 3). This ratio, ranging interindividually from 19.5% to 51.9% (mean:  $34.5\% \pm 7.6\%$ ), was independent of age, sex, and side. In the fixed specimens not yet prepared for scanning electron microscopy the ratio was larger in the inferior temporal and superior temporal sectors than in the temporal horizontal and nasal regions parallel to the greater pores and larger summed pore area in the same regions. The density of the supporting interpore tissue was higher in the temporal horizontal and nasal regions than in the inferior temporal and superior temporal parts. After the specimens were dried and shadowed with gold-palladium, these regional differences were detectable only in those specimens of superior quality (Fig. 1).

Size of the lamina cribrosa openings for passage of the central retinal vessels (mean:  $0.02 \pm 0.01 \text{ mm}^2$  [artery];  $0.02 \pm 0.02 \text{ mm}^2$  [vein]) was independent of the total lamina cribrosa area ( $P = 0.14$  [artery] and  $P = 0.59$  [vein]). In all eyes, the artery was located nasally to the vein. The artery was located an averaged  $0.15 \pm 0.09 \text{ mm}$  nasal to the middle vertical lamina cribrosa axis and  $0.02 \pm 0.11 \text{ mm}$  superior to the middle horizontal axis. Mean position of the vein was  $0.07 \pm 0.14 \text{ mm}$  nasal to the middle vertical lamina cribrosa axis and  $0.046 \text{ mm} \pm 0.09 \text{ mm}$  superior to the middle horizontal axis. This finding indicated a

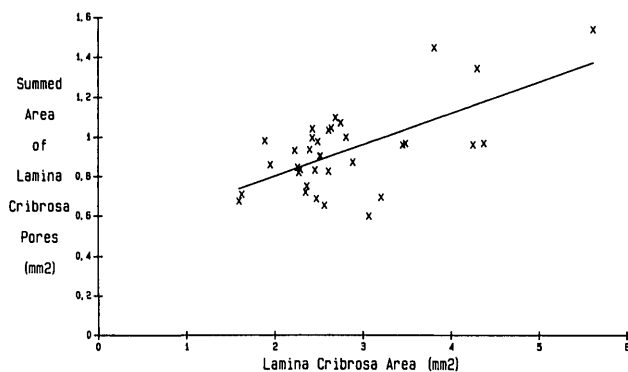


Fig. 2. Scattergram showing the correlation between the lamina cribrosa area and the summed pore area; correlation coefficient  $R = 0.64$ ; linear regression line  $Y = 0.16X + 0.47$ ;  $P < 0.0001$ .

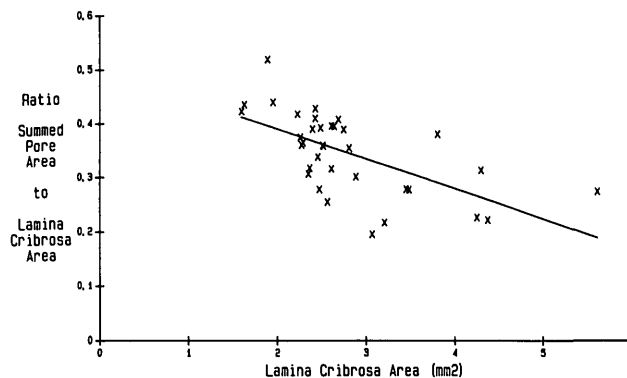


Fig. 3. Scattergram showing the correlation between the lamina cribrosa area and the ratio of summed pore area to lamina cribrosa area; correlation coefficient  $R = -0.62$ ; linear regression line:  $Y = -0.06X + 0.50$ ;  $P < 0.001$ .

decentering into the nasal upper quadrant of the lamina cribrosa.

### Discussion

This study confirms qualitative investigations of the inner lamina cribrosa surface and reports the least amount of interpore connective tissue in the inferior temporal and superior temporal disc regions and the highest percentage in the temporal and nasal parts of the lamina cribrosa.<sup>3-7</sup> It supports the concept that the higher susceptibility to glaucomatous damage in the inferior temporal and superior temporal optic disc regions<sup>8</sup> is associated with larger pores and a higher percentage of pore area to interpore tissue area. The hypothesis is strengthened by the occurrence of the largest pores close to the lamina cribrosa border. The axons located there originate from the fundus periphery, which includes the region of the temporal fundus raphe and corresponds with the site of early glaucomatous visual field defects.

The ratio of pore area to lamina cribrosa area varied interindividually by a factor of 1:2.3. This may be one factor associated with the interindividually varying susceptibility to glaucomatous damage for a given intraocular pressure. The ratio decreased significantly with increasing lamina cribrosa size (Fig. 3). Contrarily, Quigley and co-workers<sup>10</sup> did not find a varying percentage of pore area on lamina area in black and white subjects, despite the lamina cribrosa being larger in black subjects. With only white subjects being evaluated in this study, racial differences may explain the discrepancy between Quigley's results and ours. Considering the hypothesis that the susceptibility to glaucoma is greater in regions with a higher ratio of pore area to lamina area, the relationship of a lower ratio in larger laminae cribrosae would indicate

that glaucomatous damage is less likely to develop in ocular hypertensive subjects with large optic nerve heads than in subjects with small optic discs. However, deducing from mechanical factors, the pressure gradient across the lamina cribrosa would produce a larger displacement of the central lamina cribrosa part in larger optic discs.<sup>10</sup> This factor and other additional parameters may explain why, intraclinically, a correlation has not been found between the optic disc size and frequency of and susceptibility to glaucoma.

The single lamina cribrosa pores and their summed area were larger in the inferior and superior lamina cribrosa regions than in the temporal and nasal parts. This distribution correlates with the configuration of the normal neuroretinal rim, which is significantly wider in the inferior and superior disc regions than in the nasal and temporal disc sectors<sup>8</sup>; the visibility of retinal nerve fiber bundles, which are more clearly detectable on red-free photographs in the inferior temporal and superior temporal fundus regions than in the temporal horizontal and nasal regions<sup>8</sup>; the morphologic features of the retinal nerve fiber layer in monkeys, with the thickest parts close to the superior and inferior disc poles and the thinnest parts located temporal and nasal to the optic disc border<sup>11</sup>; and the higher retinal nerve fiber count in the inferior and superior disc regions than in the temporal and nasal disc areas<sup>12</sup> requiring more lamina cribrosa pore area in the superior and inferior disc regions.

Total area and count of the lamina pores increased significantly with the size of the lamina cribrosa (Fig. 2). Assuming that during embryology all lamina pores were once traversed by retinal ganglion cell axons, this relationship points to a positive correlation between the number of embryologic optic nerve fibers and optic disc area. In contrast to adult human eyes, such a correlation among the count of retrobulbar optic nerve fibers and optic nerve head size has not been found.<sup>9</sup> Quigley et al<sup>10</sup>, and other authors,<sup>9</sup> described a significant correlation between the nerve fiber count, the nerve fiber bundle area, and the optic nerve area. The regression lines were similar to the regression line when the neuroretinal rim area and the optic disc area were compared. With a direct comparison of optic disc area and nerve fiber count still missing, however, it remains unclear whether a relationship between these two parameters exists in adults. This correlation might become insignificant due to the embryologic loss of retinal ganglion cells.<sup>13</sup> If the ganglion cells that have axons predominantly in the center of the primitive papilla regress, the extent of this embryologic process would be reflected in the size of the optic cup in the adult. This hypothesis is

supported by the presence of pores in the central region of the lamina cribrosa that correspond intravittally to the physiologic optic cup.

With the nerve fibers digested and the interpore tissue left alone, no correlation was detected between the summed pore area and age. This is in contrast to the findings of Ogden and co-workers,<sup>6</sup> who did not subject the nerve fibers to digestion before examining cross sections of the lamina cribrosa. They described a significant decrease in the proportion of the scleral part of the lamina cribrosa occupied by pores, and presumably by nerve fibers. They suggested that this decrease reflected the loss of nerve fiber with age.<sup>9</sup>

Mean, minimal, and maximal values of the lamina cribrosa area were slightly higher than those reported for normal optic nerve heads ( $2.69 \pm 0.70 \text{ mm}^2$ ;  $0.86 \text{ mm}^2 - 5.86 \text{ mm}^2$ ) evaluated intravittally using Littmann's method.<sup>8</sup> The discrepancy may be explained by the applied preparation procedure that involved the removal of the inner aspect of the optic disc, to permit the view of the entire surface of the lamina cribrosa. The interindividual variability of the lamina cribrosa area of 1:3.5 and the variability in the optic disc area of about 1:7, emphasize the importance of the optic disc size as a parameter in the examination of patients with optic nerve anomalies and diseases.

Occlusions of the central retinal artery and vein have been found to be independent of optic disc area, in spite of the considerable interindividual variability of the optic nerve head size.<sup>8</sup> This finding may be due to the lack of a correlation between the area of the lamina cribrosa and size of the lamina cribrosa openings for passage of the central retinal vessels. Presuming that a small lamina cribrosa opening is a risk factor for vessel occlusions and considering that eyes with small as well as large optic discs can have lamina cribrosa openings of similar size, eyes with small as well as large discs will statistically have an equal chance of being affected by central retinal vessel occlusions.

**Key words:** glaucoma, lamina cribrosa, neuroretinal rim, optic disc, retinal nerve fibers

### Acknowledgment

Mrs. C. Rummelt took the scanning electron micrographs.

### References

1. Quigley HA, Hohmann RM, Addicks EM, Massof RW, and Green RW: Morphologic changes in the lamina cribrosa correlated with neural loss in open-angle glaucoma. *Am J Ophthalmol* 95:673, 1983.
2. Anderson DR and Hendrickson A: Effect of intraocular pres-

- sure on rapid axoplasmatic transport in monkey optic nerve. *Invest Ophthalmol Vis Sci* 13:771, 1974.
3. Quigley HA, Addicks EM, Green WR, and Maumenee AE: Optic nerve damage in human glaucoma. II. The site of injury and susceptibility to damage. *Arch Ophthalmol* 99:635, 1981.
  4. Radius RL: Regional specificity in anatomy at the lamina cribrosa. *Arch Ophthalmol* 99:478, 1981.
  5. Quigley HA and Addicks EM: Regional differences in the structure of the lamina cribrosa and their relation to glaucomatous optic nerve damage. *Arch Ophthalmol* 99:137, 1981.
  6. Ogden TE, Duggan J, Danley K, Wilcox M, and Minckler DS: Morphometry of nerve fiber bundle pores in the optic nerve head of the human. *Exp Eye Res* 46:559, 1988.
  7. Dandona L, Quigley HA, Brown AE, and Enger C: Quantitative regional structure of the normal human lamina cribrosa. A racial comparison. *Arch Ophthalmol* 108:393, 1990.
  8. Jonas JB: *Biomorphometrie des Nervus opticus*. Stuttgart, Enke-Verlag, 1989.
  9. Jonas JB, Müller-Bergh JA, Schlötzer-Schrehardt UM, and Naumann GOH: Histomorphometry of the human optic nerve. *Invest Ophthalmol Vis Sci* 31:736, 1990.
  10. Quigley HA, Brown AE, Morrison JC, and Drance SM: The size and shape of the optic disc in normal human eyes. *Arch Ophthalmol* 108:51, 1990.
  11. Ogden TE: Nerve fiber layer of the primate retina: morphometric analysis. *Invest Ophthalmol Vis Sci* 25:19, 1984.
  12. Sanchez RM, Dunkelberger GR, and Quigley HA: The number and diameter distribution of axons in the monkey optic nerve. *Invest Ophthalmol Vis Sci* 27:1342, 1986.
  13. Rajic P and Riley KP: Overproduction and elimination of retinal axons in the fetal rhesus monkey. *Science* 219:1441, 1983.