

# Motile sperm organelle morphology examination (MSOME) and sperm head vacuoles: state of the art in 2013

Anne Perdrix\* and Nathalie Rives

Reproductive Biology Laboratory—CECOS, EA 4308 "Gametogenesis and gamete quality", IRIB, University of Rouen, Rouen University Hospital, 1 rue de Germont, 76031 Rouen Cedex, France

Correspondence address. Tel: +33-2-32-888225; Fax: +33-2-35-982007; E-mail: [anneperdrix@yahoo.fr](mailto:anneperdrix@yahoo.fr)

Submitted on March 1, 2013; resubmitted on March 29, 2013; accepted on April 9, 2013

---

## TABLE OF CONTENTS

---

- Introduction
  - Methods
  - Results
    - Sperm vacuole characterization
      - What are sperm vacuoles?*
      - Sperm head abnormalities associated with vacuoles*
    - Sperm vacuoles: clinical consequences
      - Sperm vacuoles: a novel parameter for the diagnosis of male infertility?*
      - Towards the use of MSOME for diagnosis?*
      - IMSI: a therapeutic tool for male infertility?*
      - IMSI: to propose in particular indications?*
  - Conclusion
- 

**BACKGROUND:** Approximately 10 years after the first publication introducing the motile sperm organelle morphology examination (MSOME), many questions remained about sperm vacuoles: frequency, size, localization, mode of occurrence, biological significance and impact on male fertility potential. Many studies have tried to characterize sperm vacuoles, to determine the sperm abnormalities possibly associated with vacuoles, to test the diagnostic value of MSOME for male infertility or to question the benefits of intracytoplasmic morphologically selected sperm injection (IMSI).

**METHODS:** We searched PubMed for articles in the English language published in 2001–2012 regarding human sperm head vacuoles, MSOME and IMSI.

**RESULTS:** A bibliographic analysis revealed consensus for the following findings: (i) sperm vacuoles appeared frequently, often multiple and preferentially anterior; (ii) sperm vacuoles and sperm chromatin immaturity have been associated, particularly in the case of large vacuoles; (iii) teratozoospermia was a preferred indication of MSOME and IMSI.

**CONCLUSION:** The high-magnification system appears to be a powerful method to improve our understanding of human spermatozoa. However, its clinical use remains unclear in the fields of male infertility diagnosis and assisted reproduction techniques (ARTs).

**Key words:** IMSI / male infertility / MSOME / sperm vacuoles

## Introduction

Since the 20th century and the observation of normal and pathological sperm forms in semen samples (Menkveld, 2010), sperm morphology has become an area of intense interest in the evaluation of male infertility. To improve the diagnosis and treatment of male infertility, several methods have been proposed to objectively assess sperm morphology: light microscopy, transmission electron microscopy (TEM) and scanning electron microscopy (SEM). In 2001, Bartoov *et al.* introduced the motile sperm organelle morphology examination (MSOME), which is based on a morphological analysis of isolated motile spermatozoa in real-time at high magnification (up to  $\times 6600$ ). MSOME is able to identify not only conventional morphological sperm alterations with a definition close to that of SEM, but also more specifically sperm head vacuoles, considered by Bartoov *et al.* (2001) as nuclear defects. The MSOME method has been applied to sperm injection, giving rise to intracytoplasmic morphologically selected sperm injection (IMSI). The first publications demonstrated an increase in the pregnancy rate using IMSI compared with ICSI (Bartoov *et al.*, 2001, 2003). The impact of normal nuclear morphology in sperm on ICSI success has been highlighted (Berkovitz *et al.*, 2005), while the impact of sperm vacuoles observed with MSOME in assisted reproduction techniques (ARTs) has been questioned (Berkovitz *et al.*, 2006a).

The variable presentation of sperm vacuoles (size, number, localization and frequency), their mode of occurrence, their biological significance and their impact on the quality and fertilization ability of human spermatozoa have been described. Several studies have tried to characterize sperm vacuoles, determine the sperm abnormalities associated with the presence of vacuoles, test the diagnostic value of MSOME for male infertility or question the benefits of IMSI. Approximately 10 years after the introduction of the MSOME and IMSI procedures, several questions concerning sperm vacuoles remained without clear answers. Therefore, we proposed here to summarize the published data concerning sperm head vacuoles and their clinical consequences to better characterize sperm head vacuoles and identify the potential benefits of IMSI regarding male infertility.

## Methods

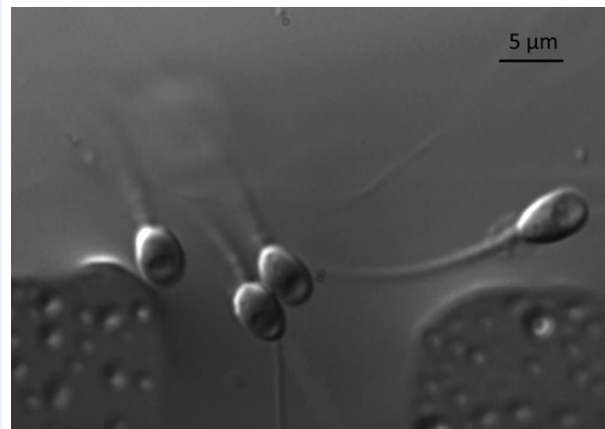
This review focused on vacuoles in sperm heads, MSOME and IMSI. We searched for English-language publications in PubMed published during the period of 2001–2012 using the following keywords: sperm vacuoles, MSOME, IMSI, human sperm head morphology and high magnification. Only publications reporting on human spermiogenesis and human-assisted reproduction were selected.

## Results

Since 2001, 62 articles dealing with human sperm vacuoles and high-magnification sperm observations have been published in PubMed.

### Sperm vacuole characterization

To better understand the biological significance of sperm vacuoles (Fig. 1), the characteristics that define a vacuole need to be clarified, and the sperm abnormalities associated with the presence of vacuoles must be identified.



**Figure 1** Human spermatozoa with head vacuoles observed using MSOME, at  $\times 6600$  magnification.

### What are sperm vacuoles?

Currently, the precise origin of sperm vacuoles remains unknown. However, several studies used an indirect approach to assess the biological composition of sperm head vacuoles.

**Vacuole prevalence, number and localization.** Independently of their size, vacuoles seemed relatively common in the sperm heads from (i) fertile men [95.8% of spermatozoa with vacuoles (Watanabe *et al.*, 2011)], (ii) infertile men with normal semen parameters (97.7% (Tanaka *et al.*, 2012) to 98.4% (Perdrix *et al.*, 2012) of spermatozoa with vacuoles), (iii) or infertile men with abnormal semen parameters [98.8% (Tanaka *et al.*, 2012) to 99.4% (Perdrix *et al.*, 2012) of spermatozoa with vacuoles].

While a high frequency of vacuoles in sperm was observed consistently, the proportion of 'large' vacuoles was relatively contradictory and involved more discussion. Indeed, the definition of this vacuole subpopulation remains variable. An initial estimate indicated that 30–40% of the spermatozoa from patients with ICSI indication presented large vacuoles (a vacuole area  $>4\%$  of the head area) (Berkovitz *et al.*, 2006a). Using the same definition of large vacuoles, Monqaut *et al.* (2011) observed that 61.8% of spermatozoa had large vacuoles in infertile patients. One common definition of the large sperm head vacuole is a vacuole area occupying  $>50\%$  of the sperm head area. Using this criterion, spermatozoa with large vacuoles represented  $25.2 \pm 19.2\%$  (Oliveira *et al.*, 2010b),  $28.0 \pm 22.4\%$  (Komiya *et al.*, 2013) or  $30.1 \pm 17.8\%$  (Franco *et al.*, 2012) of the semen samples from unselected infertile patients and 15% of the semen samples from fertile and infertile men combined (Tanaka *et al.*, 2012). However, in the mentioned studies, the vacuole area was evaluated subjectively by eye. Large vacuoles, defined as vacuoles  $>13\%$  of the sperm head area, were precisely measured using an objective method, and such large vacuoles were observed in  $9.2 \pm 7.2\%$  of the spermatozoa in samples from fertile men (Gatimel *et al.*, 2013a) and in  $38 \pm 5.1\%$  of the spermatozoa from asthenoteratozoospermic semen samples (Perdrix *et al.*, 2011). Furthermore, Watanabe *et al.* (2011) identified large vacuoles in 4.6% of spermatozoa from infertile men and 4.2% of spermatozoa from fertile

men, considering vacuoles as large when they presented a diameter of  $> 1.5 \mu\text{m}$  and were visible at  $\times 400$  magnification.

The median reported numbers of vacuoles per spermatozoa were 1.49 (Tanaka *et al.*, 2012), 1.6 (Perdrix *et al.*, 2013) and 1.8 (Perdrix *et al.*, 2012) in patients with normal semen parameters. The median numbers of vacuoles per spermatozoa were 1.59 (Tanaka *et al.*, 2012), 1.8 (Perdrix *et al.*, 2013) and 1.9 (Perdrix *et al.*, 2012) in abnormal semen samples.

Considering vacuole localization within sperm heads, most publications reported a minority of vacuoles in the posterior part: globally,  $< 10\%$  of the vacuoles were posterior in spermatozoa from fertile men (Watanabe *et al.*, 2011) or infertile patients with abnormal semen parameters (Watanabe *et al.*, 2011; Tanaka *et al.*, 2012). For infertile men, only Tanaka *et al.* (2012) demonstrated that a majority of vacuoles were situated in the anterior part of sperm heads (88.3%), whereas other researchers observed a more homogenous distribution of vacuoles in the anteromedian region of the sperm heads.

*Genesis of sperm head vacuoles: initially occurring during spermiogenesis or later during epididymal transit or after ejaculation?* Two mechanisms have been proposed to explain the genesis of sperm head vacuoles. Vacuoles have been described in spermatids during the early step of spermiogenesis. Using testicular biopsies from healthy, young patients who were undergoing operations for hydrocoel or with proven brain death, Auger and Dadoune. (1993) observed spermatid vacuoles from step 6 of spermiogenesis (Hostein and Roosen-Rünge, 1981), and the vacuole area remained constant during the subsequent steps. More recently, the presence of vacuoles has been confirmed in round and elongated spermatids obtained from obstructive and non-obstructive azoospermic patients (Tanaka *et al.*, 2012). Tanaka *et al.* (2012) reported that the number of vacuoles increased during spermiogenesis (from 0.19 vacuoles per cell in spermatid S<sub>b1</sub> to 1.4 vacuoles per cell in spermatid S<sub>d2</sub>), and the vacuole area decreased (large vacuoles were mainly found in spermatids, whereas small vacuoles were mainly found in ejaculated sperm). However, the MSOME method had been modified in this study, and motile spermatozoa were stopped by the addition of glutaraldehyde (0.2%), introducing a possible bias. The hypothesis of the genesis of sperm head vacuoles during spermiogenesis was also proposed by Zamboni (1987), who described a frequent association between intranuclear vacuoles, hypoplastic acrosomes and abnormal chromatin condensation in spermatozoa. The triad, abnormal acrosomes, intranuclear vacuoles and immature sperm chromatin, confirmed by Mundy *et al.* (1994), evokes indeed the main transformations occurring during the Golgi phase, the cap phase, the acrosome phase and the maturation phase of spermiogenesis.

The appearance of sperm head vacuoles during epididymal passage represents an additional hypothesis. Immature sperm chromatin, which stabilizes during epididymis transit by the addition of  $-S-S-$  crosslinks (Bedford *et al.*, 1973), appears to be more susceptible to damage in epididymis.

In contrast to the hypothesis that sperm head vacuoles are first formed in the male genital tract, several authors proposed that vacuoles reflect modifications that occur in sperm after ejaculation. Indeed, sperm vacuoles were more frequent when sperms were incubated at  $37^\circ\text{C}$  compared with  $21^\circ\text{C}$ , and when the duration of incubation at  $37^\circ\text{C}$  increased (Peer *et al.*, 2007). This observation has been confirmed by Schwarz *et al.* (2012) for washed sperm but not after swim-up preparation. To explain vacuole formation after spermiogenesis, a possible mechanism could be

the complex ergonomic changes undergone by spermatozoa during capacitation: indeed, capacitation, as the epididymal transit, appears to be the moment of dramatic alterations in the membrane architecture (loss, modification and redistribution of sterols, fatty acids, and proteins on the sperm surface) (Leahy and Gadella, 2011).

*Vacuole origin: acrosomal or nuclear?* The anterior localization of vacuoles in the sperm head and the classical TEM data associating vacuoles, abnormal chromatin compaction and abnormal acrosomes, were the source of questions about the origins of vacuoles.

The hypothesis that sperm head vacuoles originated from acrosomes has been explored by assessing vacuole parameters after induction of the acrosome reaction. A significantly decreased presence of vacuoles was observed after induction of the acrosome reaction (Kacem *et al.*, 2010; Montjean *et al.*, 2012). However, contradictory results have been published recently. After induction of the acrosome reaction, after freeze thawing without cryoprotectants, or after demembration with a detergent, the prevalence of vacuoles in sperm heads remained unchanged (Tanaka *et al.*, 2012). Therefore, the conclusion that vacuoles result from acrosomal or plasma membrane residues is consequently questioned (Tanaka *et al.*, 2012).

These functional sperm studies presented a problem; the acrosome status and vacuole parameters have been analysed in different spermatozoa. The association between acrosomes and vacuoles was tested statistically but acrosomes and vacuoles were not examined together within the same sperm cell (Montjean *et al.*, 2012; Tanaka *et al.*, 2012).

To explore a nuclear origin of sperm vacuoles, MSOME-selected spermatozoa have been observed with confocal microscopy, TEM (Perdrix *et al.*, 2011) and atomic force microscopy (Boitrelle *et al.*, 2011). The vacuoles appeared to be strictly nuclear, and covered by acrosomal and plasmic membranes of the sperm head. These observations have been confirmed recently using MSOME in two patients presenting total globozoospermia, in which sperm head vacuoles were present even when acrosomal and Golgi residues could not be detected (Gatimel *et al.*, 2013b).

Chemes and Alvarez Sedo (2012) considered that vacuoles observed in MSOME were chromatin lacunae, not membrane bound. These lacunae could correspond to areas of uncondensed chromatin or to 'nuclear pockets' that function as proteolytic centres to eliminate protein residues in sperm nuclei.

*Different types of vacuoles?* The uncertainties concerning the genesis of sperm vacuoles were also reported in studies exploring the biological composition of sperm head vacuoles. Consequently, a hypothesis suggesting that different types of vacuole exist has been proposed. Vacuole heterogeneity was first observed after TEM analysis (Zamboni, 1987). More recently, a case report on one infertile patient with 100% of spermatozoa containing vacuoles described four types of vacuoles: 'vacuoles with granular and filament-like low-electron-density inclusion bodies and with a clear margin; high-electron-density vacuoles with no concrete structure and an unclear margin; vacuoles containing a lot of membranous vesicles and myeloid inclusions; vacuoles containing circular layers of membranous myeloid body' (Zhang *et al.*, 2012).

This vacuole heterogeneity is also seen when assessing the relationship between vacuoles observed using MSOME and DNA fragmentation. A significant decrease in the DNA fragmentation rate was observed in MSOME-selected spermatozoa with anterior vacuoles compared with

unselected spermatozoa, and no difference was observed in MSOME-selected spermatozoa with posterior vacuoles (Hammoud *et al.*, 2012). These observations confirmed the vacuole heterogeneity and indicated that the degree of heterogeneity depends on the vacuole's position within the sperm head.

In conclusion, vacuoles are highly prevalent, often multiple within one spermatozoon and preferentially localized to the anterior part of the sperm head; however, the mechanism of vacuole formation remains a subject of discussion.

#### *Sperm head abnormalities associated with vacuoles*

Several studies have been performed to assess more precisely the sperm defects related to the presence of sperm head vacuoles. However, only a few studies attempted to characterize the sperm abnormalities associated with sperm head vacuoles at the level of individual spermatozoa. Most studies chose the model of spermatozoa containing large vacuoles, but the definition of a large vacuole was not consistent [vacuole area >4% (Kacem *et al.*, 2010; Wilding *et al.*, 2011), 13% (Perdrix *et al.*, 2011), 25% (Boitrelle *et al.*, 2011) or 50% (Franco *et al.*, 2008) of the head area; vacuole area >1.5  $\mu\text{m}$  and visible at  $\times 400$  magnification (Watanabe *et al.*, 2011) or not precisely defined (Garolla *et al.*, 2008)]. The patients included in these previous studies were sometimes fertile (Watanabe *et al.*, 2011), often infertile (Franco *et al.*, 2008; Kacem *et al.*, 2010; Boitrelle *et al.*, 2011; Watanabe *et al.*, 2011) or with semen parameter alterations (Garolla *et al.*, 2008; Boitrelle *et al.*, 2011; Perdrix *et al.*, 2011, 2013; Watanabe *et al.*, 2011).

*Acrosome abnormalities.* MSOME vacuoles have been associated with a dysfunction of acrosomes, unable to undergo the acrosome reaction (Kacem *et al.*, 2010; Montjean *et al.*, 2012), and abnormal acrosome morphology with absent, small, irregular and heterogeneous acrosomes (Perdrix *et al.*, 2011).

*Chromatin compaction abnormalities.* The chromatin in spermatozoa with large vacuoles was abnormally decondensed and had an increased level of chromatin immaturity, independently of the large vacuole definition, the sperm origin or the methods used for chromatin compaction assessment (Franco *et al.*, 2008, 2012; Garolla *et al.*, 2008; Boitrelle *et al.*, 2011; Perdrix *et al.*, 2011; Cassuto *et al.*, 2012) (Table I).

*Sperm DNA fragmentation.* Studies exploring sperm DNA fragmentation in spermatozoa with large vacuoles using the TUNEL assay (terminal deoxynucleotidyl transferase-mediated dUTP nick end labelling) revealed conflicting results (Table II). An increase in DNA fragmentation was observed in spermatozoa with large vacuoles compared with MSOME normal spermatozoa (Franco *et al.*, 2008; Garolla *et al.*, 2008; Wilding *et al.*, 2011; Hammoud *et al.*, 2012), but this result was not confirmed in two other publications (Boitrelle *et al.*, 2011; Watanabe *et al.*, 2011). Different hypotheses have been proposed to explain this discrepancy between the studies. First, the TUNEL assay is a subjective method (Sergerie *et al.*, 2005). Second, the population of explored males varied from one study to another [sperm donors (Watanabe *et al.*, 2011), infertile patients with semen parameter alterations (Garolla *et al.*, 2008; Perdrix *et al.*, 2011; Cassuto *et al.*, 2012) or infertile patients presenting high DNA fragmentation rates (Hammoud *et al.*, 2012)], and this variation could influence the rate of sperm DNA fragmentation independently of the presence of sperm head vacuoles. Finally, sperm

preparation was not standardized; acetic acid fixation (Franco *et al.*, 2008; Hammoud *et al.*, 2012) could increase DNA fragmentation rates non-specifically (Watanabe *et al.*, 2011).

Comparing large vacuole spermatozoa with native, i.e. untreated, semen sample (Perdrix *et al.*, 2011), a methodology bias might be introduced for DNA fragmentation analysis: the absence of a significant difference might be due to the accumulation of dead spermatozoa in the native sample, independently of the vacuole status. However, this hypothesis cannot justify the absence of a significant difference in DNA fragmentation between score 0 spermatozoa and unselected spermatozoa obtained using a density gradient (Cassuto *et al.*, 2012).

*Sperm chromosome abnormalities.* The chromosome content of large vacuole spermatozoa has been explored using fluorescence *in situ* hybridization (FISH). However, Watanabe *et al.* (2011) used sperm karyotypes obtained after mouse oocyte injection to examine the sperm chromosome content.

Four studies compared the aneuploidy rate between spermatozoa with large vacuoles and normal spermatozoa after MSOME (Garolla *et al.*, 2008; Boitrelle *et al.*, 2011; Watanabe *et al.*, 2011; Perdrix *et al.*, 2013). All studies reported an increase in aneuploid spermatozoa associated with the presence of vacuoles, but the results were either non-significant (Boitrelle *et al.*, 2011; Watanabe *et al.*, 2011; Perdrix *et al.*, 2013) or the *P* value was not reported (Garolla *et al.*, 2008). However, the aneuploidy rate increased significantly when large vacuole spermatozoa were compared with spermatozoa in a native semen sample (Perdrix *et al.*, 2011). In addition, the absence of vacuoles after MSOME analysis was not a guarantee of normal chromosome content in patients with macrocephalic sperm head syndrome (Chelli *et al.*, 2010).

In patients carrying a reciprocal translocation or a Robertsonian translocation, the presence of vacuoles was not correlated with modes of segregation. The absence of vacuoles in MSOME was not sufficient to avoid spermatozoa with an unbalanced chromosomal content (Cassuto *et al.*, 2011).

Chromosome positioning has also been compared between spermatozoa with large vacuoles and normal spermatozoa after MSOME. A modification in the chromosomal architecture has been demonstrated for chromosomes X, Y and 18 in the presence of vacuoles, and the X, Y and 18 centromeres tended to be localized to a more posterior and central location in spermatozoa with large vacuoles (Perdrix *et al.*, 2013).

At the level of the sperm cell, a relationship exists between large vacuoles and chromatin immaturity. However, DNA fragmentation and aneuploidy in association with large sperm head vacuoles remain areas of further study. Finally, acrosome abnormalities have not been sufficiently explored within the context of sperm head vacuoles.

## **Sperm vacuoles: clinical consequences**

To improve ICSI results, the choice of the injected spermatozoon seems essential. Several sperm selection methods have been successively proposed, based on sperm ability to bind hyaluronic acid, to pass cumulus oophorus, to bind with zona pellucida, to respond to hypo-osmotic stress, or based on sperm membrane surface charge, birefringence or surface markers (Nasr-Esfahani *et al.*, 2012). Among these techniques, MSOME was initially proposed as a novel ART tool for male infertility (Bartoov *et al.*, 2001), based on sperm organellar morphology. The impact of the vacuoles on fertilization and embryo development was addressed subsequently (Berkovitz *et al.*, 2006a), and nowadays, this

**Table I** Evaluation of sperm chromatin compaction in large vacuole spermatozoa, isolated using MSOME.

Studies	Studied population	Definition of large vacuoles	Sperm chromatin compaction analysis	Abnormal sperm chromatin compaction (mean $\pm$ s.e.m.) (%)		P
				MSOME normal spermatozoa (n)	Large vacuole spermatozoa (n)	
Franco <i>et al.</i> (2008)	30 Infertile patients	>50% of the sperm head area	Orange Acridine	33.1% (354)	67.9% (371)	<0.0001
Garolla <i>et al.</i> (2008)	10 Infertile patients, oligozoospermia	Not defined	Orange Acridine	5.3 $\pm$ 3.0% (100)	71.9 $\pm$ 11.1% (100)	<0.001
Boitrelle <i>et al.</i> (2011)	15 Infertile patients	>25% of sperm head area	Aniline blue	7.6 $\pm$ 1.3% (450)	36.2 $\pm$ 1.9% (450)	<0.0001
Perdrix <i>et al.</i> (2011)	20 Infertile patients Teratozoospermia	>13% of sperm head area	Aniline blue	Unselected spermatozoa from native sample 26.5 $\pm$ 2.57% (9980)	50.4 $\pm$ 3.1% (460)	<0.0001
Cassuto <i>et al.</i> (2012)	26 Infertile patients oligoasthenoteratozoospermia Previous IVF failures	Score 0 spermatozoa (Cassuto <i>et al.</i> , 2009)	Aniline blue	Unselected spermatozoa after density gradient 10.1 $\pm$ 6.0% (2600)	19.5 $\pm$ 8.7% (2600)	<0.0001
Franco <i>et al.</i> (2012)	66 Infertile patients	>50% of sperm head area	CMA3	40.3% (835)	53.2% (1351)	<0.0001

(n): number of analysed spermatozoa; MSOME: motile sperm organellar morphology examination.

issue remains at the heart of numerous studies concerning the role of IMSI in ART.

#### *Sperm vacuoles: a novel parameter for the diagnosis of male infertility?*

To determine the diagnostic potential of MSOME, the relationships between sperm vacuoles and some conventional male infertility factors have been explored. Moreover, MSOME methodology and vacuole parameters need to be standardized for routine use in infertility diagnostics.

#### *Correlations between sperm vacuoles and conventional male infertility factors.*

Using correlation studies, the occurrence of spermatozoa presenting head vacuoles has been associated with different male infertility factors (patient's age, conventional semen parameters, sperm nucleus analysis, etc.) (Table III). Using this methodology, the spermatozoa which were evaluated by MSOME and the spermatozoa that were classically assessed (conventional semen analysis, aniline blue staining, TUNEL or FISH) were distinct, i.e. the same sample was not simultaneously explored. This approach should be distinguished from the methodology developed on the scale of the sperm cell that was presented in the section 'Sperm head abnormalities associated with vacuoles', in which different explorations were performed in a single cell.

#### Patient's age

The rate of vacuolated spermatozoa increases with the patient's age, regardless of vacuole size (occupying less or more than 4% of the sperm head area) (de Almeida Ferreira Braga *et al.*, 2011). The rate of spermatozoa containing large vacuoles (>50% of sperm head area) also increases with patient's age (Silva *et al.*, 2012).

#### Conventional semen parameters

A positive correlation has been observed between normal MSOME spermatozoa and normal spermatozoa using Tygerberg criteria ( $r =$

0.83,  $P < 0.0001$ ) (Oliveira *et al.*, 2009). Conversely, the frequency of abnormal MSOME spermatozoa was negatively correlated with sperm concentration, sperm motility, and the percentage of spermatozoa with normal morphology (Cassuto *et al.*, 2012).

The vacuole area increased significantly when semen parameters were impaired. These impairments included a decrease in sperm concentration ( $r = -0.27$ ,  $P < 10^{-4}$ ), altered vitality ( $r = -0.31$ ,  $P < 10^{-4}$ ) and a reduced number of spermatozoa with normal morphology ( $r = -0.53$ ,  $P < 10^{-4}$ ) (Perdrix *et al.*, 2012).

The relationships between spermatozoa with large vacuoles and conventional semen parameters have been more debated. Low sperm concentration, low sperm motility (Komiya *et al.*, 2013) or high teratozoospermia (Perdrix *et al.*, 2011) have been associated with large vacuoles. Nonetheless, no correlation was reported between the rate of spermatozoa with large vacuoles and sperm concentration or motility in the study by Watanabe *et al.* (2011); however, their conclusion was not justified statistically.

#### Chromatin compaction abnormalities

A positive but insignificant correlation between the rate of abnormal spermatozoa assessed using MSOME and sperm chromatin decondensation has been observed ( $r = 0.36$ ) in infertile men with altered semen parameters: chromatin immaturity increased when the proportion of spermatozoa with poor morphology, according to MSOME, increased (Cassuto *et al.*, 2012).

#### DNA fragmentation

The rate of normal spermatozoa after MSOME correlated negatively with the rate of spermatozoa with DNA fragmentation. DNA fragmentation decreased when the proportion of normal spermatozoa observed in MSOME increased (Oliveira *et al.*, 2010a). Additionally, a relationship

**Table II** Evaluation of sperm DNA fragmentation in large vacuole spermatozoa, isolated using MSOME.

Studies	Studied population	Large vacuole definition	Sperm DNA fragmentation analysis	Percentage of spermatozoa with fragmented DNA (mean ± s.e.m.) (%)		P	
				MSOME normal spermatozoa (n)	Large vacuole spermatozoa (n)		
Franco <i>et al.</i> (2008)	30 Infertile patients	>50% of the sperm head area	TUNEL (fixation: methanol–acetic acid)	15.9% (410)	29.1% (382)	<0.0001	
Garolla <i>et al.</i> (2008)	10 Infertile patients oligozoospermia	Not defined	TUNEL (fixation: paraformaldehyde 4%)	9.3 ± 4.8% (100)	40.1 ± 11.6% (100)	<0.001	
Wilding <i>et al.</i> (2011)	8 Infertile patients	>4% of the sperm head area	TUNEL (fixation: paraformaldehyde 4%)	6.1 ± 7.2% (331)	14.7 ± 7.2% (529)	=0.031	
Boitrelle <i>et al.</i> (2011)	15 Infertile patients	>25% of the sperm head area	TUNEL (fixation: ethanol 95%)	0.7 ± 0.4% (450)	1.3 ± 0.4% (450)	NS (=0.25)	
Perdrix <i>et al.</i> (2011)	20 Infertile patients Teratozoospermia	>13% of the sperm head area	TUNEL (fixation: methanol)	Unselected spermatozoa from native sample 11.5 ± 1.22% (10040)	14.5 ± 3.45% (560)	NS (=0.68)	
Watanabe <i>et al.</i> (2011)	10 Infertile patients 2 Sperm donors	>1.5 µm and visible at ×400 magnification	TUNEL (fixation: paraformaldehyde 4%)	3.5% (2252) 2.3% (398)	3.3% (209) 0% (18)	NS NS	
Hammoud <i>et al.</i> (2012)	8 Infertile patients with high DNA fragmentation rates >13%	>4% of the sperm head area	TUNEL (fixation: methanol–acetic acid)	4.1 ± 1.1% (191)	Anterior vacuoles 15.9 ± 2.9% (368) (a)	Posterior vacuoles 22.5 ± 3.6% (402)(b)	(a): P = 0.013 (b): P = 0.0007
				Unselected spermatozoa from native sample 26.1 ± 1.5% (8000)			(a): P = 0.02 (b): P = 0.44
Cassuto <i>et al.</i> (2012)	26 Infertile patients, Oligoasthenoteratozoospermia, Previous IVF failures	Score 0 spermatozoa (Cassuto <i>et al.</i> , 2009)	TUNEL	Unselected spermatozoa after density gradient 3.7 ± 6.7% (2600)	Score 0 4.2 ± 5.5% (2600)	NS	

(n): number of analysed spermatozoa.

TUNEL: Terminal deoxynucleotidyl transferase-mediated dUTP nick end labelling.

Sem: standard error of the mean; MSOME: motile sperm organellar morphology examination; FIV: Fécondation *In Vitro*; NS: non-significant.

**Table III** Analysis of correlation between presence of large vacuole spermatozoa and male infertility factors.

Studies	Studied population	Definition of large vacuole	Correlation analysis between large vacuole spermatozoa and several male infertility factors						
			Patient age	Sperm concentration	Sperm motility	Sperm morphology	Sperm DNA fragmentation	Sperm abnormal chromatin compaction	Sperm aneuploidy
De Almeida <i>et al.</i> (2011)	50 infertile patients, with ICSI indication	>4% of the sperm head area	Slope = 0.065 R <sup>2</sup> = 0.118 P < 0.001				Slope = 0.004 R <sup>2</sup> = 0.067 P = 0.029		Slope = 0.0029 R <sup>2</sup> = 0.009 P = 0.805
Oliveira <i>et al.</i> (2010a)	538 infertile patients						R = 0.10 P < 0.05		
Perdrix <i>et al.</i> (2011)	20 infertile patients Teratozoo-spermia	>13% of the sperm head area				Teratozoospermia: R = 0.49 P = 0.03			
Cassuto <i>et al.</i> (2012)	26 infertile patients OAT and previous IVF failures	Score 0 spermatozoa (Cassuto <i>et al.</i> , 2009)		R = -0.41 P = 0.03	R = -0.42 P = 0.03	Normal sperm morphology: R = -0.63 P = 0.0008	R = -0.23 NS	R = 0.36 NS	
Silva <i>et al.</i> (2012)	975 infertile patients	>50% of the sperm head area	R = -0.10 P < 0.05						
Boitrelle <i>et al.</i> (2012)	25 infertile patients	Grade III or IV spermatozoa (Vanderzwalmen <i>et al.</i> , 2008)						R = 0.49 P < 0.001	
Komiya <i>et al.</i> (2013)	142 infertile patients	>50% of the sperm head area		R = -0.38 P < 10 <sup>-4</sup>	R = -0.24 P < 0.01	R = -0.17 NS			

OAT: Oligoastheno-teratozoospermia.  
R: coefficient of correlation.

between increased sperm DNA fragmentation and the presence of large vacuoles was reported (Oliveira *et al.*, 2010a; de Almeida Ferreira Braga *et al.*, 2011). However, recent results published by Cassuto *et al.* (2012) seem to be contradictory: in this study of 26 infertile men with ICSI indication, no association was observed between DNA fragmentation and abnormal MSOME spermatozoa with a score of 0 (a spermatozoon with an abnormal base, a nuclear asymmetrical extrusion and/or invagination of the nuclear membrane and at least one large vacuole).

#### Aneuploidy

No correlation was observed between the rate of large vacuole spermatozoa and the rate of sperm aneuploidy, assessed in a native semen sample (de Almeida Ferreira Braga *et al.*, 2011).

Sperm vacuoles observed using MSOME have been compared between infertile patients according to their age, body mass index or social habits (Wogatzky *et al.*, 2012). Individually, each factor had little impact on the sperm criteria explored using MSOME. Surprisingly, stress, smoking and a short duration of sexual abstinence positively affected the vacuole profile. Combining these different male infertility factors, a negative impact on MSOME criteria has been proposed.

These different studies performed with infertile patients demonstrated a higher frequency of large vacuole spermatozoa in older patients, and in sperm with abnormal chromatin compaction and DNA fragmentation. However, classical sperm alterations (oligozoospermia, asthenozoospermia and teratozoospermia) appeared not to be associated with an increased percentage of large vacuole spermatozoa.

#### Towards the use of MSOME for diagnosis?

At the level of the sperm cell, the presence of large sperm head vacuoles can be considered a potential indicator of sperm nuclear abnormalities (in particular, chromatin immaturity). At the level of the male population, these vacuoles relate to particular male infertility factors (the patient's age, abnormal chromatin compaction, increased DNA fragmentation and abnormal conventional semen parameters). However, the evaluation of sperm head vacuoles in daily practice remains non-standardized, with varying methods being used.

To use MSOME as a diagnostic tool, normal values of vacuole parameters need to be defined, guidelines for MSOME should be proposed, and the reliability of this analysis must be demonstrated.

**Definition of MSOME normal values.** Bartoov *et al.* (2002) described a normal spermatozoon using TEM and SEM observations of spermatozoa from 100 infertile men with an ICSI indication. The following criteria were proposed to define a normal spermatozoon: head length =  $4.75 \pm 0.28 \mu\text{m}$ ; head width =  $3.28 \pm 0.20 \mu\text{m}$ ; a smooth, symmetric and oval-shaped nucleus; the absence of vacuoles or the presence of vacuoles occupying <4% of the normal nuclear area; normal acrosome, postacrosomal lamina, neck, tail, and mitochondria; and no cytoplasmic droplets or cytoplasm around the head. These criteria have not been confirmed using MSOME.

Most ART researchers have adopted this definition with some adjustments. For example, a vacuole area has been considered normal when occupying <5.9% (Perdrix *et al.*, 2012; Gatimel *et al.*, 2013b) or 6.5% of the head area (Perdrix *et al.*, 2011, 2013; Gatimel *et al.*, 2013a) after objective and precise measurement.

In contrast to this semi-consistent definition of normal MSOME spermatozoa, the classification of abnormal MSOME spermatozoa is more variable.

#### MSOME classifications.

- (1) An initial classification was proposed by Vanderzwalmen *et al.* (2008) using 67 patients with ICSI indications:
  - (a) Grade I: absence of vacuoles,
  - (b) Grade II: maximum of two small vacuoles,
  - (c) Grade III: more than two small vacuoles or at least one large vacuole,
  - (d) Grade IV: large vacuoles associated with abnormal head shapes or other abnormalities.
- (2) Cassuto *et al.* (2009) used MSOME to assess more than 15 000 spermatozoa from 100 randomly chosen patients to define six parameters of interest; a complementary study was also performed to identify the more informative parameters. Finally, their classification proposed an analysis of the sperm head shape (normal score = 1, abnormal score = 0), vacuoles (absence score = 1, presence score = 0), and head base (normal score = 1, abnormal score = 0). For each parameter, a coefficient was assigned (two for sperm head shape, three for vacuoles and one for head base). The total score obtained per spermatozoon [score per spermatozoon = (2\*head) + (3\*vacuole) + (base)] varies between 0 and 6 and is used for the spermatozoa classification as follows:
  - (a) Class 1: high-quality spermatozoon with a calculated score of 4–6,
  - (b) Class 2: medium-quality spermatozoon with a calculated score of 1–3,
  - (c) Class 3: low-quality spermatozoon with a calculated score of 0.
- (3) After assessing 30 patients with altered semen analysis and two previous ICSI failures, Mauri *et al.* (2010) defined five grades of spermatozoa:
  - (a) Grade I: normal spermatozoa, using the definition of Bartoov *et al.* (2001)
  - (b) Grade II: spermatozoa with an abnormal head, described as large oval (>5.31  $\mu\text{m}$ ), small oval (<4.19  $\mu\text{m}$ ), wide (>3.7  $\mu\text{m}$  width) or narrow (<2.9  $\mu\text{m}$  width)
  - (c) Grade III: presence of sperm head regional disorders
  - (d) Grade IV: presence of large vacuoles occupying 5–50% of the head area
  - (e) Grade V: presence of large vacuoles occupying >50% of the head area.
- (4) Using MSOME assessment of 109 men with normal semen analysis and 331 patients with altered semen analysis, a novel classification was proposed (Perdrix *et al.*, 2012):
  - (a) Type 0: absence of vacuoles,
  - (b) Type 1: presence of vacuoles occupying <6% of the sperm head area,
  - (c) Type 2: presence of vacuoles occupying 6–12.4% of the sperm head area,
  - (d) Type 3: presence of vacuoles occupying >12.4% of the sperm head area.

The classifications mentioned above were designed considering different objectives. Some studies were aimed at rapid screening, using a



subjective evaluation by eye of a large sample of spermatozoa for immediate use for oocyte injection (Vanderzwalmen *et al.*, 2008; Cassuto *et al.*, 2009; Mauri *et al.*, 2010). On the contrary, an objective and precise method based on a digital measurement of randomly photographed spermatozoa has been proposed and, consequently, requires a smaller sample of spermatozoa (Perdrix *et al.*, 2012). The validation of the different proposed classifications would depend on either IMSI results or correlation to several male fertility parameters. Finally, one classification would be preferentially chosen and used for either spermatozoa selection during IMSI or a detailed exploration of spermatozoa quality.

*Validity of MSOME analysis.* One unique study reported an assessment of MSOME reproducibility. None of the previously presented MSOME classifications were used, but only the proportions of MSOME normal spermatozoa and large vacuole spermatozoa (>50% of the sperm head area) were evaluated. By comparing two MSOME analyses performed on two separate semen samples from one individual collected after a time interval, the authors observed no differences between normal MSOME spermatozoa and spermatozoa with large vacuoles (Oliveira *et al.*, 2010b).

*MSOME indications.* Few authors have proposed a systematic MSOME before ICSI (Oliveira *et al.*, 2010a; Silva *et al.*, 2012). This proposition raises two questions:

- (1) first, the interest in a systematic MSOME for patients with normal semen analysis (Watanabe *et al.*, 2011)
- (2) second, the feasibility in daily practice. MSOME requires a specific system [(an inverted microscope equipped with high-power differential interference contrast (Nomarski/DIC) optics enhanced by digital imaging] and is time consuming. Confronted with these technical issues, MSOME methodology (Simon *et al.*, 2013) based on an analysis of motile cells using a high-magnification system could be modified. Spermatozoa could be stopped by the addition of glutaraldehyde (Tanaka *et al.*, 2012, Gatimel *et al.*, 2013a), fixed with 1% formaldehyde (Schwarz *et al.*, 2012), smeared on a glass slide, air dried and rehydrated before morphology assessment (Falagaro *et al.*, 2012) or observed at lower magnification (Watanabe *et al.*, 2011).

Specific indications for using MSOME have been proposed: (i) in the case of teratozoospermia, isolated or associated with sperm nuclear abnormalities (Perdrix *et al.*, 2012); (ii) for spermatozoa evaluation after freezing (Boitrelle *et al.*, 2012) and (iii) as a predictive factor of pregnancy after intrauterine insemination (Akl *et al.*, 2011).

#### *IMSI: a therapeutic tool for male infertility?*

The first results of IMSI demonstrated the benefit of spermatozoa preselection using MSOME on ART outcomes. Today, studies comparing IMSI with ICSI are rare and lead to contradictory conclusions. IMSI appears to be an ART procedure that should be limited to specific indications.

*IMSI: non-randomized, retrospective studies.* Initially, high-magnification microscopy analysis of sperm was proposed for couples with ART failures, resulting in a significant increase in pregnancy rates (Bartoov *et al.*, 2001). Next, several authors, using non-random retrospective studies, reported an impact of IMSI on different ART parameters (Table IV).

- (1) Except for two studies (Nadalini *et al.*, 2009; Delaroche *et al.*, 2012), the fertilization rates appeared not to improve with IMSI compared with ICSI (Bartoov *et al.*, 2001, 2003; Hazout *et al.*, 2006; Berkovitz *et al.*, 2006b; Vanderzwalmen *et al.*, 2008; de Almeida Ferreira Braga *et al.*, 2011; Oliveira *et al.*, 2011). The type of sperm abnormality observed with MSOME could explain the different impact on the fertilizing potential of spermatozoa (Berkovitz *et al.*, 2005). For example, Cassuto *et al.* (2009) reported that sperm head vacuoles interfered with fertilization, whereas the morphology of the base of the sperm head appeared to be a major factor that might affect embryo quality.
- (2) The impact of IMSI on embryo quality was explored for early embryos and blastocysts. Except for the studies of Berkovitz *et al.* (2006b), Setti *et al.* (2012a) and Delaroche *et al.* (2012), no effect on the quality of early embryos was observed using IMSI compared with ICSI (Bartoov *et al.*, 2003; Hazout *et al.*, 2006; Berkovitz *et al.*, 2006a; Vanderzwalmen *et al.*, 2008; de Almeida Ferreira Braga *et al.*, 2011; Oliveira *et al.*, 2011). However, an increase in blastocyst quality using IMSI has been demonstrated (Vanderzwalmen *et al.*, 2008; Cassuto *et al.*, 2009; Delaroche *et al.*, 2012; Setti *et al.*, 2012a).
- (3) IMSI appeared to significantly enhance the pregnancy rates (Bartoov *et al.*, 2001, 2003; Hazout *et al.*, 2006; Berkovitz *et al.*, 2006b; Nadalini *et al.*, 2009), particularly highlighting a deleterious effect of large vacuoles on pregnancy rates (Berkovitz *et al.*, 2006a, b). Except for one study (Berkovitz *et al.*, 2006a), each of these studies was performed in couples with previous ART failures, which might introduce a potential bias.

*IMSI versus ICSI: prospective, randomized trials.* To our knowledge, ten randomized prospective trials and one meta-analysis (Souza Setti *et al.*, 2010) have been published (Table V) with contradictory conclusions. Considering the fertilization rates, none of the published data revealed an advantage of IMSI over ICSI (Mauri *et al.*, 2010; Balaban *et al.*, 2011; Figueira Rde *et al.*, 2011; Knez *et al.*, 2011; Setti *et al.*, 2011, 2012b; Wilding *et al.*, 2011; De Vos *et al.*, 2013). The role of IMSI in embryo quality appeared to be more debated. In early cleavage embryos, only one study observed an improvement in embryo quality after IMSI (Wilding *et al.*, 2011), but these results were not confirmed in three supplementary studies (Mauri *et al.*, 2010; Balaban *et al.*, 2011; Setti *et al.*, 2011) and were rejected by De Vos *et al.* (2013). Investigating late embryos, Knez *et al.* (2011) found a reduced proportion of arrested embryos after IMSI, but this positive impact of IMSI on blastocysts was not confirmed by De Vos *et al.* (2013). The implantation rates increased using IMSI according to a few authors (Antinori *et al.*, 2008; Wilding *et al.*, 2011), but the rates appeared to be unaffected in other studies (Knez *et al.*, 2011; Setti *et al.*, 2011, 2012b). The spontaneous abortion rates did not vary significantly between IMSI and ICSI (Antinori *et al.*, 2008; Setti *et al.*, 2011). Finally, the pregnancy rates improved after IMSI in some studies (Antinori *et al.*, 2008; Wilding *et al.*, 2011; Knez *et al.*, 2012), but did not improve in others (Balaban *et al.*, 2011; Knez *et al.*, 2011; Setti *et al.*, 2011, 2012b; De Vos *et al.*, 2013).

An analysis of the populations included in the different trials could explain the discrepancy between the published studies. Indeed, the authors seem to demonstrate an advantage of IMSI when patients presented semen parameter alterations and when semen impairment was the main aetiological factor in the diagnosis of the couple's infertility

**Table IV** Retrospective studies comparing IMSI and ICSI impact according to different ART parameters.

Studies	Studied population	Methodology	IMSI parameters			Clinical pregnancy rate	Spontaneous abortion rate
			Fertilization	Embryo quality			
				% of good quality early cleaved embryos	% of good quality blastocysts		
Bartoov <i>et al.</i> (2001)	24 couples, male infertility Woman <37 years At least three retrieved oocytes At least five IVF-ICSI failures	Comparison with previous ICSI attempt	NS			IMSI = 58% (versus 3% expected with ICSI)	
Bartoov <i>et al.</i> (2003)	62 couples, altered semen analysis Woman <37 years At least three retrieved oocytes At least two ICSI failures	Comparison to 50 control couples, paired according to the number of previous ICSI failures	NS	NS		IMSI = 66% ICSI = 30% <i>P</i> < 0.01	IMSI = 9% ICSI = 33% <i>P</i> < 0.01
Hazout <i>et al.</i> (2006)	125 couples Woman <38 years 37 patients with normal semen analysis 88 patients with altered semen analysis At least two ICSI failures	Comparison with previous ICSI attempt	NS	NS		IMSI = 40.8% ICSI = 6.4% <i>P</i> < 0.001	
Berkovitz <i>et al.</i> (2006a)	28 couples Woman <40 years At least three retrieved oocytes	Comparison of 28 IMSI with large vacuoles spermatozoa injection (a), to 28 paired IMSI with normal spermatozoa injection(b)	NS	NS		IMSI (a) = 18% <sup>a</sup> IMSI (b) = 50% <sup>a</sup> <i>P</i> = 0.01	IMSI (a) = 80% IMSI (b) = 7% <i>P</i> = 0.01
Berkovitz <i>et al.</i> (2006b)	80 couples At least 2 ICSI failures	Comparison to 80 control couples, paired according to the number of previous ICSI failures Comparison of 70 IMSI with first choice spermatozoa injection (a), to 70 paired IMSI with second choice spermatozoa injection (b)	NS	IMSI = 38.7% ICSI = 25.7% <i>P</i> < 0.05	IMSI(a) = 26.7% IMSI(b) = 16.2% <i>P</i> < 0.05	IMSI = 60% <sup>b</sup> ICSI = 25% <sup>b</sup> <i>P</i> < 0.05	IMSI = 14% ICSI = 40% <i>P</i> < 0.05
Vanderzwalmen <i>et al.</i> (2008)	25 couples, male infertility Woman <40 years At least 8 retrieved oocytes	Comparison of the results obtained according to the type of spermatozoon injected: Grade I(a), Grade II(b), Grade III(c) or Grade IV(d)	NS	NS		IMSI (a) = 37.5% IMSI (b) = 37.1% IMSI (c) = 1.7% IMSI (d) = 0% <i>P</i> < 0.001	
Cassuto <i>et al.</i> (2009)	27 couples, male infertility Woman <36 years At most, 2 IVF-ICSI failures Semen alterations	Comparison of the results obtained according to the type of spermatozoon injected: Class 1 (a), Class 2 (b), or Class 3 (c)	IMSI (a) = 84% IMSI (b) = 73% IMSI (c) = 61% <i>P</i> < 0.04			IMSI (a) = 15% IMSI (b) = 9% IMSI (c) = 0% <i>P</i> < 0.03	
Nadalini <i>et al.</i> (2009)	20 couples Woman <38 years Male infertility factor and/or more than 1 ICSI failure At least 5 mature retrieved oocytes	Comparison with 37 ICSI paired couples	IMSI = 91.67% ICSI = 78.33% <i>P</i> = 0.043			IMSI = 40.00% <sup>b</sup> ICSI = 16.21% <sup>b</sup> <i>P</i> = 0.05	NS

de Almeida <i>et al.</i> (2011)	35 couples Sperm DNA fragmentation $\geq$ 30%	Comparison of the results obtained during a unique attempt, between oocyte injected using ICSI or IMSI,	NS		NS		
Oliveira <i>et al.</i> (2011)	100 couples Woman <39 years At least 2 ICSI failures, with a satisfying embryo quality	Comparison with 100 ICSI paired couples	NS	NS		NS	NS
Setti <i>et al.</i> (2012a)	332 couples >4 and <30 oocytes retrieved Exclusion of semen samples presenting < 1 million/ml of spermatozoa or <20% of motile spermatozoa	Comparison to 332 ICSI paired couples	NS	<0.001	0.001		
Delaroche <i>et al.</i> (2013)	75 couples At least 2IVF or ICSI failures	Comparison with previous IVF or ICSI attempt	IMSI = 72.2% Control cycle = 63.3% $P = 0.02$	IMSI = 89.8% Control cycle = 79.8% $P = 0.009$	IMSI = 1.5 <sup>c</sup> Control cycle = 1 <sup>c</sup> $P = 0.03$	NS	
Klement <i>et al.</i> (2013)	1302 couples Male infertility factor First IVF treatment 449 couples Male infertility factor Second IVF treatment (post ICSI failure)	Comparison of 269 IMSI with 1033 ICSI  Comparison of 127 IMSI with 322 ICSI				NS	IMSI = 56% ICSI = 38% $P = 0.002$

ART: assisted reproduction techniques.

IMSI: intracytoplasmic morphologically selected sperm injection.

<sup>a</sup>Clinical pregnancy rates per cycle.

<sup>b</sup>Clinical pregnancy rates per embryo transfer.

<sup>c</sup>Number of blastocysts obtained.

**Table V** Prospective studies comparing IMSI and ICSI according to different ART parameters.

Studies	Studied population	Comparison between IMSI and ICSI											
		Fertilization rate (%)			Embryo quality (% of good quality early cleaved embryos)			Clinical pregnancy rate <sup>a</sup> /cycle (%)			Spontaneous abortion rate (%)		
		ICSI	IMSI	P	ICSI	IMSI	P	ICSI	IMSI	P	ICSI	IMSI	P
Antinori <i>et al.</i> (2008)	446 couples (219 ICSI, 227 IMSI) OAT Primary infertility <3 years Woman <35 years After randomization, complementary study, according to ART history: Subgroup (A): no previous failure of ICSI Subgroup (B): one previous failure of ICSI Subgroup (C): two previous failures of ICSI, or more							26.5	39.2	0.04	24.1	16.9	NS
							(C): 12.9	(C): 29.9	(C): 0.017				
Mauri <i>et al.</i> (2010)	30 couples At least two semen parameters altered or implantation failure in ICSI Randomized oocytes	70.9	70.4	NS	(D2): 57.8	(D2): 52.2	NS						
Figueira <i>et al.</i> (2011)	120 couples with IVF associated with preimplantation genetic screening for advanced maternal age (60 ICSI, 60 IMSI) Exclusion: less than six retrieved oocytes	84.3	76.7	NS				47.1	53.8	NS			
Wilding <i>et al.</i> (2011)	232 couples (110 ICSI, 122 IMSI) Infertility during 1–3 years Sperm concentration [1–20] millions/ml Exclusion: -cryopreserved spermatozoa and surgical spermatozoa -female infertility factors	65.9	68.0	NS	(D3): 66.0	(D3): 98.6	0	40.0 <sup>b</sup>	65.6 <sup>b</sup>	0			
Setti <i>et al.</i> (2011)	500 couples (250 ICSI, 250 IMSI) Isolated male infertility, with altered semen parameters Exclusion: -cryopreserved spermatozoa -less than 6 retrieved oocytes	78.9	79.2	NS	37.3	44.4	NS	36.8	37.2	NS	17.9	18.4	NS
Balaban <i>et al.</i> (2011)	168 couples (87 ICSI, 87 IMSI) Male, female or combined infertility	80.9	81.6	NS	(D3): 63.9	(D3): 66.4	NS	44.4	54.0	NS			
Knez <i>et al.</i> (2011)	57 couples (37 ICSI, 20 IMSI) Male infertility, with altered semen parameters All arrested embryos following a prolonged 5-day culture in previous ICSI cycles	52.7	51.2	NS				8	25	NS			
Setti <i>et al.</i> (2012b)	160 couples with IVF associated with preimplantation genetic screening for advanced maternal age (80 ICSI, 80 IMSI) Exclusion: -severe sperm alterations -less than six retrieved oocytes	84	80	NS	48.5	54.5	NS	47.4 <sup>c</sup>	54.4 <sup>c</sup>	NS			

Knez et al. (2012)	122 couples (70 ICSI, 52 IMSI) Isolated teratozoospermia	77.3	79.1	NS	(D2): 35	24	48	<0.05
De Vos et al. (2013)	350 couples Isolated male infertility Randomized oocytes Exclusion: - cryopreserved spermatozoa and surgical spermatozoa -female infertility factors				(D2): 38.5	36.7	34.4	NS

OATS: severe oligoasthenoteratozoospermia; IMSI: intracytoplasmic morphologically selected sperm injection.  
<sup>a</sup>clinical pregnancy defined by a positive  $\beta$ -hCG assay and the presence of a fetal heartbeat by transvaginal ultrasound examination.  
<sup>b</sup>pregnancy rate (positive  $\beta$ -hCG assay) per embryo transfer.  
<sup>c</sup>clinical pregnancy rate per embryo transfer.  
(D2): embryo quality assessed on Day 2.  
(D3): embryo quality assessed on Day 3.

(Antinori et al., 2008; Wilding et al., 2011; Knez et al., 2012). This positive use of IMSI within the context of male infertility treatment was first described by Balaban et al. (2011), who demonstrated a significant increase in the implantation rates using IMSI in the male infertility subgroup. This result was confirmed by Setti et al. (2011), who reported an advantage of IMSI over ICSI in the case of oligoasthenoteratozoospermia.

In addition, some studies should be questioned regarding the legitimacy of their evaluation of IMSI. Two of these prospective randomized studies, performed for preimplantation genetic screening in the case of advanced maternal age, were designed 'to minimize the influence of male factor infertility' (Figueira Rde et al., 2011; Setti et al., 2012b), excluding severe spermatogenic alterations. This study design seems to be inappropriate for evaluating IMSI, initially proposed as a spermatozoa selection method.

Two of these randomized prospective studies proposed novel concerns regarding the impact of IMSI on embryos. A lower incidence of sex chromosome aneuploidy occurred in embryos obtained after IMSI (Figueira Rde et al., 2011). A higher incidence of XX embryos was obtained after IMSI (Figueira Rde et al., 2011; Setti et al., 2012b).

#### IMSI: to propose in particular indications?

With no consensus regarding the effect of IMSI on embryo quality, implantation rates or pregnancy rates, IMSI is most likely a procedure in ART to be reserved for specific cases. Initially, IMSI was performed in couples with ART failures (Bartoov et al., 2001, 2003). Nevertheless, recent findings challenged this indication. Oliveira et al. (2011) and Knez et al. (2011) did not demonstrate an advantage for IMSI, but De Vos et al. (2013) and Klement et al. (2013) highlighted an improvement in embryo quality when IMSI was used compared with ICSI. However, the interest in IMSI was enhanced in the case of multiple semen alterations (Setti et al., 2011), severe semen alterations (Antinori et al., 2008; Wilding et al., 2011) and morphological semen alterations (Knez, et al., 2012), polymorphous or specific (Sermondade et al., 2011; Kashir et al., 2012). Finally, IMSI should be tested in randomized prospective trials when sperm DNA fragmentation is increased (Hammoud et al., 2012) or when cryopreserved semen samples are used in ART (Boitrelle et al., 2012).

## Conclusion

A bibliographic analysis reported some consistent observations about sperm vacuoles, MSOME and IMSI. Sperm vacuoles occur frequently, are present in multiple copies per cell and preferentially localize to the anterior part of the sperm head. An association between vacuoles, particularly large vacuoles, and sperm chromatin immaturity has been clearly demonstrated. Despite conflicting published results, teratozoospermia has been proposed as a preferential indication for MSOME and IMSI, to be confirmed in future studies.

Several hypotheses remained unresolved: the origin of vacuoles, their relationship with the acrosome/DNA fragmentation/chromosome content, their use for male infertility diagnosis, and their impact in ART. Fundamental research on vacuolated spermatozoa and clinical prospective trials comparing MSOME with classical semen analysis, or IMSI with ICSI, are absolutely necessary to optimize the use of this high-magnification observation system.

## Authors' roles

AP performed the bibliographic analysis and drafted the manuscript. NR analysed the data and critically revised the manuscript.

## Funding

The research was funded by the Reproductive Biology Laboratory—CECOS, EA 4308 'Gametogenesis and gamete quality', IRIB, University of Rouen, Rouen University Hospital.

## Conflict of interest

AP and NR report no conflict of interest.

## References

- Akl LD, Oliveira JB, Petersen CG, Mauri AL, Silva LF, Massaro FC, Baruffi RL, Cavagna M, Franco JG Jr. Efficacy of the motile sperm organelle morphology examination (MSOME) in predicting pregnancy after intrauterine insemination. *Reprod Biol Endocrinol* 2011;**9**:120.
- Antinori M, Licata E, Dani G, Cerusico F, Versaci C, d'Angelo D, Antinori S. Intracytoplasmic morphologically selected sperm injection: a prospective randomized trial. *Reprod Biomed Online* 2008;**16**:835–841.
- Auger J, Dadoune JP. Nuclear status of human sperm cells by transmission electron microscopy and image cytometry: changes in nuclear shape and chromatin texture during spermiogenesis and epididymal transit. *Biol Reprod* 1993;**49**:166–175.
- Balaban B, Yakin K, Alatas C, Oktem O, Isiklar A, Urman B. Clinical outcome of intracytoplasmic injection of spermatozoa morphologically selected under high magnification: a prospective randomized study. *Reprod Biomed Online* 2011;**22**:472–476.
- Bartoov B, Berkovitz A, Eltes F. Selection of spermatozoa with normal nuclei to improve the pregnancy rate with intracytoplasmic sperm injection. *N Engl J Med* 2001;**345**:1067–1068.
- Bartoov B, Berkovitz A, Eltes F, Kogosovsky A, Yagoda A, Lederman H, Artzi S, Gross M, Barak Y. Pregnancy rates are higher with intracytoplasmic morphologically selected sperm injection than with conventional intracytoplasmic injection. *Fertil Steril* 2003;**80**:1413–1419.
- Bartoov B, Berkovitz A, Eltes F, Kogosowski A, Menezo Y, Barak Y. Real-time fine morphology of motile human sperm cells is associated with IVF-ICSI outcome. *J Androl* 2002;**23**:1–8.
- Bedford JM, Calvin H, Cooper GW. The maturation of spermatozoa in the human epididymis. *J Reprod Fertil Suppl* 1973;**18**:199–213.
- Berkovitz A, Eltes F, Yaari S, Katz N, Barr I, Fishman A, Bartoov B. The morphological normalcy of the sperm nucleus and pregnancy rate of intracytoplasmic injection with morphologically selected sperm. *Hum Reprod* 2005;**20**:185–190.
- Berkovitz A, Eltes F, Ellenbogen A, Peer S, Feldberg D, Bartoov B. Does the presence of nuclear vacuoles in human sperm selected for ICSI affect pregnancy outcome? *Hum Reprod* 2006a;**21**:1787–1790.
- Berkovitz A, Eltes F, Lederman H, Peer S, Ellenbogen A, Feldberg B, Bartoov B. How to improve IVF-ICSI outcome by sperm selection. *Reprod Biomed Online* 2006b;**12**:634–638.
- Boitrelle F, Ferfour F, Petit JM, Segretain D, Tourain C, Bergere M, Bailly M, Vialard F, Albert M, Selva J. Large human sperm vacuoles observed in motile spermatozoa under high magnification: nuclear thumbprints linked to failure of chromatin condensation. *Hum Reprod* 2011;**26**:1650–1658.
- Boitrelle F, Albert M, Theillac C, Ferfour F, Bergere M, Vialard F, Wainer R, Bailly M, Selva J. Cryopreservation of human spermatozoa decreases the number of motile normal spermatozoa, induces nuclear vacuolization and chromatin decondensation. *J Androl* 2012;**33**:1371–1378.
- Cassuto NG, Bouret D, Plouchart JM, Jellad S, Vanderzwalmen P, Balet R, Larue L, Barak Y. A new real-time morphology classification for human spermatozoa: a link for fertilization and improved embryo quality. *Fertil Steril* 2009;**92**:1616–1625.
- Cassuto NG, Le Foll N, Chantot-Bastarud S, Balet R, Bouret D, Rouen A, Bhouri R, Hyon C, Siffroi JP. Sperm fluorescence *in situ* hybridization study in nine men carrying a Robertsonian or a reciprocal translocation: relationship between segregation modes and high-magnification sperm morphology examination. *Fertil Steril* 2011;**96**:826–832.
- Cassuto NG, Hazout A, Hammoud I, Balet R, Bouret D, Barak Y, Jellad S, Plouchart JM, Selva J, Yazbeck C. Correlation between DNA defect and sperm-head morphology. *Reprod Biomed Online* 2012;**24**:211–218.
- Chelli MH, Albert M, Ray PF, Guthausen B, Izard V, Hammoud I, Selva J, Vialard F. Can intracytoplasmic morphologically selected sperm injection be used to select normal-sized sperm heads in infertile patients with macrocephalic sperm head syndrome? *Fertil Steril* 2010;**93**:1347e1341–1345.
- Chemes HE, Alvarez Sedo C. Tales of the tail and sperm headaches: changing concepts on the prognostic significance of sperm pathologies affecting the head, neck and tail. *Asian J Androl* 2012;**14**:14–23.
- de Almeida Ferreira Braga DP, Setti AS, Figueira RC, Nichi M, Martinhago CD, Iaconelli A Jr, Borges E Jr. Sperm organelle morphologic abnormalities: contributing factors and effects on intracytoplasmic sperm injection cycles outcomes. *Urology* 2011;**78**:786–791.
- De Vos A, Van de Velde H, Bocken G, Eylenbosch G, Franceus N, Meersdom G, Tistaert S, Vankelecom A, Tournaye H, Verheyen G. Does intracytoplasmic morphologically selected sperm injection improve embryo development? A randomized sibling-oocyte study. *Hum Reprod* 2013;**28**:617–626.
- Delaroché L, Yazbeck C, Gout C, Kahn V, Oger P, Rougier N. Intracytoplasmic morphologically selected sperm injection (IMSI) after repeated IVF or ICSI failures: a prospective comparative study. *Eur J Obstet Gynecol Reprod Biol* 2012;**167**:76–80.
- Falagario D, Bruculeri AM, Depalo R, Trerotoli P, Cittadini E, Ruvolo G. Sperm head vacuolization affects clinical outcome in ICSI cycle. A proposal of a cut-off value. *J Assist Reprod Genet* 2012;**29**:1281–1287.
- Figueira Rde C, Braga DP, Setti AS, Iaconelli A Jr, Borges E Jr. Morphological nuclear integrity of sperm cells is associated with preimplantation genetic aneuploidy screening cycle outcomes. *Fertil Steril* 2011;**95**:990–993.
- Franco JG Jr, Baruffi RL, Mauri AL, Petersen CG, Oliveira JB, Vagnini L. Significance of large nuclear vacuoles in human spermatozoa: implications for ICSI. *Reprod Biomed Online* 2008;**17**:42–45.
- Franco JG Jr, Mauri AL, Petersen CG, Massaro FC, Silva LF, Felipe V, Cavagna M, Pontes A, Baruffi RL, Oliveira JB *et al*. Large nuclear vacuoles are indicative of abnormal chromatin packaging in human spermatozoa. *Int J Androl* 2012;**35**:46–51.
- Garolla A, Fortini D, Menegazzo M, De Toni L, Nicoletti V, Moretti A, Selice R, Engl B, Foresta C. High-power microscopy for selecting spermatozoa for ICSI by physiological status. *Reprod Biomed Online* 2008;**17**:610–616.
- Gatimel N, Leandri RD, Parinaud J. Sperm vacuoles are not modified by freezing-thawing procedures. *Reprod Biomed Online* 2013a;**26**:240–246.
- Gatimel N, Leandri RD, Foliguet B, Bujan L, Parinaud J. Sperm cephalic vacuoles: new arguments for their non acrosomal origin in two cases of total globozoospermia. *Andrology* 2013b;**1**:52–56.
- Hammoud I, Boitrelle F, Ferfour F, Vialard F, Bergere M, Wainer B, Bailly M, Albert M, Selva J. Selection of normal spermatozoa with a vacuole-free head (x6300) improves selection of spermatozoa with intact DNA in patients with high sperm DNA fragmentation rates. *Andrologia* 2012;**45**:163–170.
- Hazout A, Dumont-Hassan M, Junca AM, Cohen Bacrie P, Tesarik J. High-magnification ICSI overcomes paternal effect resistant to conventional ICSI. *Reprod Biomed Online* 2006;**12**:19–25.
- Hostein AF, Roosen-Rünge EC. *Atlas of Human Spermatogenesis*. Berlin, Germany: Grosse Verlage, 1981.
- Kacem O, Sifer C, Barraud-Lange V, Ducot B, De Ziegler D, Poirot C, Wolf J. Sperm nuclear vacuoles, as assessed by motile sperm organellar morphological examination, are mostly of acrosomal origin. *Reprod Biomed Online* 2010;**20**:132–137.
- Kashir J, Semondade N, Sifer C, Oo SL, Jones C, Mounce G, Turner K, Child T, McVeigh E, Coward K. Motile sperm organelle morphology evaluation-selected globozoospermic human sperm with an acrosomal bud exhibits novel patterns and higher levels of phospholipase C zeta. *Hum Reprod* 2012;**27**:3150–3160.
- Klement AH, Koren-Morag N, Itsykson P, Berkovitz A. Intracytoplasmic morphologically selected sperm injection versus intracytoplasmic sperm injection: a step toward a clinical algorithm. *Fertil Steril* 2013;**99**:1290–1293.

- Knez K, Zorn B, Tomazevic T, Vrtacnik-Bokal E, Virant-Klun I. The IMSI procedure improves poor embryo development in the same infertile couples with poor semen quality: a comparative prospective randomized study. *Reprod Biol Endocrinol* 2011;**9**:123.
- Knez K, Tomazevic T, Zorn B, Vrtacnik-Bokal E, Virant-Klun I. Intracytoplasmic morphologically selected sperm injection improves development and quality of preimplantation embryos in teratozoospermia patients. *Reprod Biomed Online* 2012;**25**:168–179.
- Komiya A, Watanabe A, Kawauchi Y, Fuse H. Sperm with large nuclear vacuoles and semen quality in the evaluation of male infertility. *Syst Biol Reprod Med* 2013;**59**:13–20.
- Leahy T, Gadella BM. Sperm surface changes and physiological consequences induced by sperm handling and storage. *Reproduction* 2011;**142**:759–778.
- Mauri AL, Petersen CG, Oliveira JB, Massaro FC, Baruffi RL, Franco JG Jr. Comparison of day 2 embryo quality after conventional ICSI versus intracytoplasmic morphologically selected sperm injection (IMSI) using sibling oocytes. *Eur J Obstet Gynecol Reprod Biol* 2010;**150**:42–46.
- Menkveld R. Clinical significance of the low normal sperm morphology value as proposed in the fifth edition of the WHO laboratory manual for the examination and processing of human semen. *Asian J Androl* 2010;**12**:47–58.
- Monqaut AL, Zavaleta C, Lopez G, Lafuente R, Brassesco M. Use of high-magnification microscopy for the assessment of sperm recovered after two different sperm processing methods. *Fertil Steril* 2011;**95**:277–280.
- Montjean D, Belloc S, Benkhalifa M, Dalleac A, Menezo Y. Sperm vacuoles are linked to capacitation and acrosomal status. *Hum Reprod* 2012;**27**:2927–2932.
- Mundy AJ, Ryder TA, Edmonds DK. A quantitative study of sperm head ultrastructure in subfertile males with excess sperm precursors. *Fertil Steril* 1994;**61**:751–754.
- Nadalini M, Tarozzi N, Distratis V, Scaravelli G, Borini A. Impact of intracytoplasmic morphologically selected sperm injection on assisted reproduction outcome: a review. *Reprod Biomed Online* 2009;**19**:45–55.
- Nasr-Esfahani MH, Deemeh MR, Tavalae M. New era in sperm selection for ICSI. *Int J Androl* 2012;**35**:475–484.
- Oliveira JB, Massaro FC, Mauri AL, Petersen CG, Nicoletti AP, Baruffi RL, Franco JG Jr. Motile sperm organelle morphology examination is stricter than Tygerberg criteria. *Reprod Biomed Online* 2009;**18**:320–326.
- Oliveira JB, Massaro FC, Baruffi RL, Mauri AL, Petersen CG, Silva LF, Vagnini LD, Franco JG Jr. Correlation between semen analysis by motile sperm organelle morphology examination and sperm DNA damage. *Fertil Steril* 2010a;**94**:1937–1940.
- Oliveira JB, Petersen CG, Massaro FC, Baruffi RL, Mauri AL, Silva LF, Ricci J, Franco JG Jr. Motile sperm organelle morphology examination (MSOME): intervariation study of normal sperm and sperm with large nuclear vacuoles. *Reprod Biol Endocrinol* 2010b;**8**:56.
- Oliveira JB, Cavagna M, Petersen CG, Mauri AL, Massaro FC, Silva LF, Baruffi RL, Franco JG Jr. Pregnancy outcomes in women with repeated implantation failures after intracytoplasmic morphologically selected sperm injection (IMSI). *Reprod Biol Endocrinol* 2011;**9**:99.
- Peer S, Eltes F, Berkovitz A, Yehuda R, Itsykson P, Bartoov B. Is fine morphology of the human sperm nuclei affected by *in vitro* incubation at 37 degrees C? *Fertil Steril* 2007;**88**:1589–1594.
- Perdrix A, Travers A, Chelli MH, Escalier D, Do Rego JL, Milazzo JP, Mousset-Simeon N, Mace B, Rives N. Assessment of acrosome and nuclear abnormalities in human spermatozoa with large vacuoles. *Hum Reprod* 2011;**26**:47–58.
- Perdrix A, Saidi R, Menard JF, Gruel E, Milazzo JP, Mace B, Rives N. Relationship between conventional sperm parameters and motile sperm organelle morphology examination (MSOME). *Int J Androl* 2012;**35**:491–498.
- Perdrix A, Travers A, Clatot F, Sibert L, Mitchell V, Jumeau F, Mace B, Rives N. Modification of chromosomal architecture in human spermatozoa with large vacuoles. *Andrology* 2013;**1**:57–66.
- Schwarz C, Koster M, van der Ven K, Montag M. Temperature-induced sperm nuclear vacuolisation is dependent on sperm preparation. *Andrologia* 2012;**44**:126–129.
- Sergerie M, Laforest G, Bujan L, Bissonnette F, Bleau G. Sperm DNA fragmentation: threshold value in male fertility. *Hum Reprod* 2005;**20**:3446–3451.
- Sermondade N, Hafhouf E, Dupont C, Bechoua S, Palacios C, Eustache F, Poncelet C, Benzacken B, Levy R, Sifer C. Successful childbirth after intracytoplasmic morphologically selected sperm injection without assisted oocyte activation in a patient with globozoospermia. *Hum Reprod* 2011;**26**:2944–2949.
- Setti AS, Figueira Rde C, Braga DP, Iaconelli A Jr, Borges E Jr. Intracytoplasmic morphologically selected sperm injection benefits for patients with oligoasthenoospermia according to the 2010 World Health Organization reference values. *Fertil Steril* 2011;**95**:2711–2714.
- Setti AS, Braga DP, Figueira RC, Iaconelli A Jr, Borges E Jr. The predictive value of high-magnification sperm morphology examination on ICSI outcomes in the presence of oocyte dysmorphisms. *J Assist Reprod Genet* 2012a;**29**:1241–1247.
- Setti AS, Figueira RC, Braga DP, Iaconelli A Jr, Borges E Jr. Gender incidence of intracytoplasmic morphologically selected sperm injection-derived embryos: a prospective randomized study. *Reprod Biomed Online* 2012b;**24**:420–423.
- Silva LF, Oliveira JB, Petersen CG, Mauri AL, Massaro FC, Cavagna M, Baruffi RL, Franco JG Jr. The effects of male age on sperm analysis by motile sperm organelle morphology examination (MSOME). *Reprod Biol Endocrinol* 2012;**10**:19.
- Simon L, Wilcox A, Carrell DT. Intracytoplasmic morphology-selected sperm injection. *Methods Mol Biol* 2013;**927**:247–256.
- Souza Setti A, Ferreira RC, Paes de Almeida Ferreira Braga D, de Cassia Savio Figueira R, Iaconelli A Jr, Borges E Jr. Intracytoplasmic sperm injection outcome versus intracytoplasmic morphologically selected sperm injection outcome: a meta-analysis. *Reprod Biomed Online* 2010;**21**:450–455.
- Tanaka A, Nagayoshi M, Tanaka I, Kusunoki H. Human sperm head vacuoles are physiological structures formed during the sperm development and maturation process. *Fertil Steril* 2012;**98**:315–320.
- Vanderzwalmen P, Hiemer A, Rubner P, Bach M, Neyer A, Stecher A, Uher P, Zintz M, Lejeune B, Vanderzwalmen S et al. Blastocyst development after sperm selection at high magnification is associated with size and number of nuclear vacuoles. *Reprod Biomed Online* 2008;**17**:617–627.
- Watanabe S, Tanaka A, Fujii S, Mizunuma H, Fukui A, Fukuhara R, Nakamura R, Yamada K, Tanaka I, Awata S et al. An investigation of the potential effect of vacuoles in human sperm on DNA damage using a chromosome assay and the TUNEL assay. *Hum Reprod* 2011;**26**:978–986.
- Wilding M, Coppola G, di Matteo L, Palagiano A, Fusco E, Dale B. Intracytoplasmic injection of morphologically selected spermatozoa (IMSI) improves outcome after assisted reproduction by deselecting physiologically poor quality spermatozoa. *J Assist Reprod Genet* 2011;**28**:253–262.
- Wogatzky J, Wirleitner B, Stecher A, Vanderzwalmen P, Neyer A, Spitzer D, Schuff M, Schechinger B, Zech NH. The combination matters—distinct impact of lifestyle factors on sperm quality: a study on semen analysis of 1683 patients according to MSOME criteria. *Reprod Biol Endocrinol* 2012;**10**:115.
- Zamboni L. The ultrastructural pathology of the spermatozoon as a cause of infertility: the role of electron microscopy in the evaluation of semen quality. *Fertil Steril* 1987;**48**:711–734.
- Zhang S, Wang N, He B, Cheng J, Xi S, Wang SM, Gao Y, Wang J. Sperm head vacuoles—light microscopic and ultrastructural observations: a case report. *Ultrastruct Pathol* 2012;**36**:185–188.