mTOR Signaling in Epilepsy: Insights from Malformations of Cortical Development

Peter B. Crino

Shriners Hospital Pediatric Research Center and Department of Neurology, Temple University, Philadelphia, Pennsylvania 19140

Correspondence: peter.crino@temple.edu

Cold Spring Harbor Perspectives in Medicine
www.perspectivesinmedicine.org

Over the past decade enhanced activation of the mammalian target of rapamycin (mTOR)-signaling cascade has been identified in focal malformations of cortical development (MCD) subtypes, which have been collectively referred to as "mTORopathies." Mutations in mTOR regulatory genes (e.g., *TSC1*, *TSC2*, *AKT3*, *DEPDC5*) have been associated with several focal MCD highly associated with epilepsy such as tuberous sclerosis complex (TSC), hemimegalencephaly (HME; brain malformation associated with dramatic enlargement of one brain hemisphere), and cortical dysplasia. mTOR plays important roles in the regulation of cell division, growth, and survival, and, thus, aberrant activation of the cascade during cortical development can cause dramatic alterations in cell size, cortical lamination, and axon and dendrite outgrowth often observed in focal MCD. Although it is widely believed that structural alterations induced by hyperactivated mTOR signaling are critical for epileptogenesis, newer evidence suggests that mTOR activation on its own may enhance neuronal excitability. Clinical trials with mTOR inhibitors have shown efficacy in the treatment of seizures associated with focal MCD.

Malformations of cortical development (MCD) are highly associated with medically intractable epilepsy as well as intellectual disability and autism-spectrum disorders (Sisodiya 2004; Aronica et al. 2012). There is a broad spectrum of MCD, including small focal cortical dysplasias (FCD: focal developmental brain malformations with several subtypes, e.g., I and II, highly associated with intractable epilepsy) that are identified on pathological examination of a resected epileptogenic focus to multifocal or diffuse structural abnormalities including polymicrogyria and lissencephaly (see Guerrini and Dobyns 2014). A rapid expansion in our knowledge of molecular genetic abnormalities leading to MCD over the past two decades has identified single gene defects that cause MCD and has clearly shown how MCD can provide invaluable insights into mechanisms governing normal cortical development. Although identification of new genes responsible for MCD is ongoing and fast-paced, and functional links between these mutations and their structural effects in the cortex are clarified, the exact mechanisms through which these molecular events lead to epilepsy remains a mystery.

Perhaps the biggest conceptual advance over the past 10 years has been that abnormal activation or inhibition of several cell-signaling cascades are pathogenic and likely responsible for

Editors: Gregory L. Holmes and Jeffrey L. Noebels
Additional Perspectives on Epilepsy: The Biology of a Spectrum Disorder available at www.perspectivesinmedicine.org

 doi: 10.1101/cshperspect.a022442
Cite this article as *Cold Spring Harb Perspect Med* 2015;5:a022442

MCD. Furthermore these same cascades likely contribute to the seizure phenotype characteristic of these malformations. Identification of abnormal signaling in a variety of cellular cascades has served as a bellwether for new therapeutic advances in the treatment of epilepsy. For example, many of MCD subtypes show abnormal and enhanced activation of the mammalian target of rapamycin (mTOR) pathway, a cellular cascade that modulates cell proliferation, growth, motility, migration, and death. The mTOR cascade plays a critical role in normal cortical development and remains functionally active during adulthood maintaining cell metabolism, synaptic re-organization, and autophagy. A collection of neurodevelopmental disorders characterized by focal MCD including tubers in tuberous sclerosis complex (TSC), FCDs, hemimegalencephaly (HME), several megalencephaly (ME) subtypes, ganglioglioma (GG), polyhydramnios-megalencephaly-symptomatic-epilepsy (PMSE) or Pretzel syndrome (neurodevelopmental disorder resulting from mutation in *STRADA*), and familial focal epilepsy with variable foci (FFEVF) have been linked to aberrant mTOR signaling (Fig. 1) (see Baybis et al. 2004; Miyata et al. 2004; Crino et al. 2006; Ljungberg et al. 2006; Dibbens et al. 2013). This review will focus on focal MCD grouped as "mTORopathies" (Crino 2007, 2011), unified by clinical phenotype of epilepsy, a spectrum of developmental delay, abnormal cortical cytoarchitecture, and hyperactivated mTOR signaling.

CLASSIFICATION OF FOCAL MCD

The description of several focal MCD subtypes such as HME and TSC dates back to the 1800s (Sims 1835; Bourneville 1880), whereas focal cortical dysplasia was first described in the 1970s (Taylor et al. 1971). With the accessibility of more advanced neuroimaging in the 1990s, specifically brain MRI, it became apparent that focal MCD were more common than thought previously in patients with intractable epilepsy. These imaging modalities showed that MCD were radiographically heterogeneous, with distinct signal characteristics, extent, and location. However, in some instances, focal MCD could not be seen and were only found on histopathological examination of resected tissue specimens (see Colombo et al. 2009).

Distinct classification schemes have been proposed to define for the relevant imaging and histological features of FCD (Mischel et al. 1995; Barkovich et al. 1996). The "Palmini classification system" (Palmini et al. 2004) was restructured and further subdivided FCD into type IA, IB, IIA, and IIC. Recently, a task force extended the classification system for FCD into types IA, IB, IIA, or IIB dysplasias, and introduced a new type III dysplasia to account for the detection of FCD in association with other brain pathology such as vascular malformations or tumors (Blumcke et al. 2011). Individual classification schemes for HME and tubers have not yet been established. A new and comprehensive classification scheme approaches all types of MCD as resulting from distinct developmental and molecular genetic etiologies with direct effects on cortical development at distinct epochs and within distinct cell types (Barkovich et al. 2012).

NEUROPATHOLOGICAL FEATURES

Focal MCDs show a range of cytoarchitectural alterations, from subtle cortical dyslamination with malpositioned or heterotopic neurons to grossly disorganized or absent cortical lamination and abnormal cell morphology (Krsek et al. 2008; Blumcke and Muhlebner 2011; Muhlebner et al. 2012). All focal MCDs show some degree of disorganized cortical lamination. For example, in FCDIA or IB, the laminar architecture is disrupted in subtle radial (FCDIA) or tangential (FCDIB) patterns, whereas in FCDIIB and tubers, laminar structure is typically lost. Variable numbers of reactive astrocytes may be seen in each subtype. The neuropathological findings in HME can be highly variable with some specimens showing relatively preserved gyral, lobar, and laminar architecture, whereas others show dramatic alterations in hemispheric architecture, with no remaining visible normal structure. The mechanisms accounting for these variations are unknown but are likely linked to the effects of specific gene mutations or other

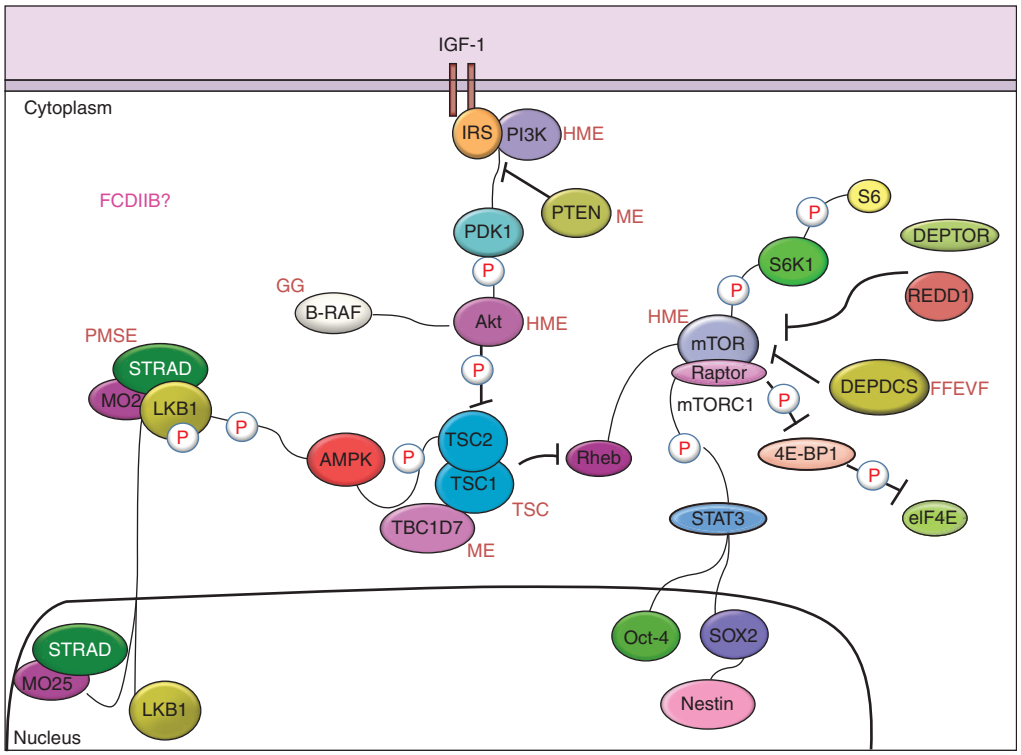

Figure 1. Schematic depicting the mammalian target of rapamycin (mTOR)-signaling cascade. Pathways show a signaling link between the insulin-like growth factor-1 (IGF-1) receptor at the cell surface, as well as possible links to the epidermal growth factor (EGF) receptor, and the downstream canonical cascade through PI3 kinase (PI3K), phosphoinositide-dependent kinase-1 (PDK-1), and Akt onto the TSC1:TSC2:TBC1D7 complex. This heteromeric complex is also modulated by the LKB1:STRADA:MO25 complex via AMPK. The TSC1:TSC2:TBC1D7 complex serves to constitutively inhibit mTOR via Rheb transduction (only mTORC1 is depicted). Note numerous downstream targets of mTORC1 including p70S6kinase (S6K1), elongation-binding protein1 (4E-BP1), and STAT3 (which may modulate neural stem cell protein expression, e.g., SOX2, nestin) REDD1 and DEPTOR are interacting proteins with mTOR. Each malformation of cortical development (MCD) is placed in the diagram at the point of mutation: polyhydramnios-megalencephaly-symptomatic-epilepsy (PMSE) (*STRADA*), hemimegalencephaly (HME), megalencephaly (ME) (MPPH, MCAP; *PI3K*, *AKT*, *MTOR*), ME/intellectual disability (ID) (*TBC1D7*), tuberous sclerosis complex (TSC) (*TSC1*, *TSC2*), ganglioglioma (GG) (*B-RAF*). A gene mutation causing focal cortical dysplasias type IIB (FCDIIB) has not been identified.

molecular events occurring in select cell populations at defined developmental epochs.

FCDIIB, tubers, GG, and to a variable extent, HME, show large (cytomegalic) cells in which the cell soma is 1.5 to 2 times greater than normal neurons. For example, dysmorphic neurons (DNs) show a neuronal morphology but very large cell soma and aberrant dendrites. DNs may be found in any cortical layer and in the subcortical white matter. Balloon cells (BCs) show a characteristic enlarged ovoid shape, a laterally displaced nucleus, and limited dendritic or axonal projections. BCs are the pathognomonic cell type of FCDIIB, cortical tubers in TSC (also referred to as "giant cells," GCs), and in HME. In GG, atypical ganglion cells (ATGC) are morphologically similar to BCs.

mTOR SIGNALING AND FOCAL MCD

There is now solid evidence that hyperactivated mTOR signaling is a feature of several focal

MCD subtypes and likely provides a common pathogenic mechanism for the cytoarchitectural abnormalities seen in these MCD. mTOR is a serione/threonine kinase that is highly conserved across many organisms (i.e., yeast, *Drosophila melanogaster*, *Caenorhabditis elegans*, rodents, and humans). The mTOR-signaling cascade is involved in maintaining cellular homeostasis and energy metabolism, nutrient cues and oxidative stress, proliferation and survival, response to growth factors, differentiation and migration, cytoskeletal organization, and autophagy (Menon and Manning 2008; Dobashi et al. 2011; Zoncu et al. 2011). mTOR functions as a kinase in two independent heteromeric complexes, mTOR complex 1 (mTORC1) and mTORC2 (mTORC: mammalian target of rapamycin complex) (Loewith et al. 2002). mTORC1 is modulated primarily through growth factor-PI3K (phosphoinositide-3-kinase)-AKT-mTOR-signaling cascade, and rapamycin, a macrolide antibiotic, is a specific mTORC1 inhibitor functioning through the binding protein FKBP12 (Sabers et al. 1995). mTORC2 plays an indirect regulatory role over mTORC1 by way of AKT signaling and is a relatively rapamycin-insensitive complex. mTORC2 is linked to actin-mediated cytoskeletal assembly and organization. mTORC1 uniquely contains raptor and PRAS40, whereas mTORC2 is composed of rictor, protor, and Sin1. Both complexes consist of mTOR and mLST8 proteins. DEPTOR directly interacts with and inhibits mTOR in both complexes.

mTORC1 is modulated upstream by TSC1 (protein product of the chromosome 9q34 *TSC1* gene) and TSC2 (protein product of the chromosome 16p13 *TSC2* gene) via Ras homolog enriched in brain (Rheb). The upstream effectors from insulin-dependent and growth factor receptors, cellular energy metabolism, and hypoxia-inducible factors converge on the TSC1/TSC2 complex (Weber and Gutmann 2012). Insulin-like growth factor receptors signal through PI3K, then PDK1, and then AKT to inhibit the TSC1/TSC2 complex and thereby release inhibition of (i.e., activate) mTORC1. TSC2 acts as a GTPase-activating protein toward Rheb, which results in inhibition of mTOR signaling. TSC1 protein stabilizes TSC2 by binding to it and prevents its ubiquitination. TBC1 domain family member 7 (TBC1D7) is a third component of the complex that modulates the GAP activity exerted on Rheb by TSC2 although binding to TSC1 (Dibble et al. 2012). TBC1D7 knockdown diminishes the association between TSC1 and TSC2 leading to decreased Rheb-GAP activity and increased mTORC1 signaling.

Several other cellular proteins impact mTOR signaling. For example, PTEN (phosphatase and tensin homolog deleted in chromosome ten) inhibits the PI3K/PDK1/AKT pathway and releases the inhibition on TSC1/TSC2 and promotes mTOR activity. In the setting of hypoxia-ischemia, REDD1 is expressed and serves to dampen mTOR signaling via interactions with TSC2. Ambient cellular ATP levels signal to mTOR via AMPK (AMP kinase; LKB1 substrate; upstream regulator of TSC2 and mTORC1), which phosphoactivates TSC2 when energy stores are replete. Levels of amino acids, in particular leucine, modulate mTOR activation through several heteromeric-signaling complexes (Ragulator, GATOR 1, GATOR2) that include DEPDC5, MIOS, and WDR53 and function at the lysosome (Menon et al. 2014). Thus, there are numerous regulatory nodes that can enhance or inhibit mTOR signaling in response to myriad of cellular states.

The mTORC1 complex modulates the ribosomal translational machinery and ribosome biogenesis. When mTORC1 phosphorylates 4E-BP1 (eukaryotic initiation factor 4E-binding protein), this releases eIF4E to bind to the 5′-mRNA cap and allows for mRNA translation. Protein translation is further fostered by mTORC1 signaling via phosphorylation of p70S6Kinase (p70S6K) to phosphoactivate the ribosomal protein S6, a component of the 40S ribosomal subunit. Finally, phosphoproteomic analyses reveal that mTORC1 may modulate phosphorylation of numerous downstream proteins, thus positing TSC1:TSC2:mTORC1 as a pivotal signaling node in many cell types (Hsu et al. 2011). In addition, mTORC1 and mTORC2 regulate mRNA translation via recognition of 5′TOP (terminal oligopyrimidine re-

peats) consensus domains. These domains are present in the 5′UTR of most components of the translational apparatus. A recent study showed that a central function of mTOR is to regulate pyrimidine synthesis via signaling to p70S6-kinase and carbamoylphosphate synthetase 2, aspartate transcarbamoylase, dihydroorotase (Ben-Sahra et al. 2013). mTORC2 modulates AKT and serves to control cytoskeletal organization and cell mobility through both mTORC1 and PKCa. mTORC2 acts through RhoA GTPases and Rac1 to regulate actin cytoskeleton and plays an important role in F-actin stress fibers and lamellipodia (Jacinto et al. 2004). Thus, alterations in mTORC1 and mTORC2 signaling could be linked to aberrant cell structure that in turn impacts motility, migration, and lamination, all of which are affected in mTORopathies.

FOCAL CORTICAL DYSPLASIA AND TUBEROUS SCLEROSIS: PARADIGM mTORopathies

FCD and tubers in TSC are among the most common pathological substrates associated with medically intractable pediatric epilepsy (Tassi et al. 2002; Krsek et al. 2008). TSC is an autosomal dominant, multisystem disorder resulting from mutations in either *TSC1* or *TSC2* characterized by a spectrum of neurological deficits including autism, intellectual disability, and intractable epilepsy (Chu-Shore et al. 2010). Identification of the *TSC1* and *TSC2* genes and the links to mTOR signaling has provided critical insights into mechanisms of focal MCD and, in fact, has provided the paradigm to study other focal MCD subtypes.

The molecular mechanisms leading to tuber formation during brain development reflect the effects of loss-of-function mutations in either *TSC1* or *TSC2*, leading to constitutive mTOR activation and altered development of the cerebral cortex (see Orlova and Crino 2010). Numerous studies have shown activated mTORC1 substrates phospho-p70S6 kinase, phospho-S6, and phospho-4E-BP1 in resected and postmortem TSC tuber samples (Baybis et al. 2004; Miyata et al. 2004; Talos et al. 2008). Indeed, two recent studies have shown mTORC1 activation in fetal tubers (Tsai et al. 2012; Prabowo et al. 2013). However, because inactivation of the TSC1-TSC2 functional complex is required to activate mTOR, it is apparent that both alleles will need to be affected in TSC lesions. Renal and pulmonary lesions in TSC follow a "two-hit" mutational model in which a somatic inactivating mutation including loss of heterozygosity or a point mutation, in the unaffected allele, is superimposed on the existing germline mutation. Two recent reports suggest that tubers contain both germline and somatic mutations, suggesting a mechanism of biallelic gene inactivation (Crino et al. 2010; Qin et al. 2010). Mouse models that show abnormal cortical structure have required full *Tsc1* or *Tsc2* knockout (e.g., Feliciano et al. 2011); heterozygous mice do not show neuropathological changes.

In contrast, over the past two decades, potential pathogenic mechanisms have been proposed for FCD, a sporadic disorder with few defined family pedigrees, including somatic gene mutation, in utero hypoxia-ischemia, or a toxic insult to the developing brain (e.g., Bosnjak et al. 2011). The pathological similarities between FCDIIB and tubers suggested a mechanistic link between these lesions, and even that FCD represented a sporadic, somatic mosaic form of TSC. Studies have identified *TSC1* and *TSC2* gene sequence changes polymorphisms, but not somatic mutations, in FCDIIB (Becker et al. 2002; Gumbinger et al. 2009). The discovery of FCD in association with *DEPDC5* mutations (see below) suggests that somatic mutations in mTOR regulatory genes are likely causative in FCD. Recently, the high-risk human papillomavirus type 16 the most common cause of cervical cancer in women, was detected in resected FCDIIB specimens (Chen et al. 2012a), suggesting a possible role for viral infection. Thus, although FCDIIB and tubers are histologically similar, they appear to be formed by distinct molecular mechanisms. Ongoing work to define the precise pathogenesis of FCD is in progress.

Enhanced mTOR signaling was first identified in FCDIIB (Baybis et al. 2004; Miyata et al. 2004), and sets the stage for subsequent studies (see below) showing mTOR activation in HME (Ljungberg et al. 2006; Aronica et al. 2007) and

GG (Samadani et al. 2007). Phospho-p70S6K and phospho-S6 isoforms were detected by immunohistochemistry in resected FCDIIB specimens. The central hypothesis of these studies was that molecular events leading to abnormal brain development resulted in mTOR activation evidenced by hyperphosphorylation of mTOR, p70S6K, and S6 proteins. As in tubers, p70S6K and S6 phosphoisoforms were identified in cells with enlarged somas (i.e., DNs and BCs in FCDIIB). Interestingly, the cellular profile of mTOR activation was often heterogeneous both within and across samples. For example, it has been shown that in tubers or FCDIIB, >80% of morphologically defined BCs show phospho-S6 labeling (Baybis et al. 2004; Orlova et al. 2010b). Furthermore, within any one tuber or FCDIIB specimen, there can be tremendous variability in the number and the distribution of GCs/BCs in the white matter and through the depth of the lesion. There has been to date little explanation for how particular mutations in individual MCD genes directly cause specific types of malformations; however, it is likely that the underlying molecular cause for these malformations leads to alterations in cell motility, directionality, polarity, differentiation, and laminar destination.

Enhanced mTOR signaling is further supported by altered expression of up- and downstream components of the mTOR pathway in focal MCD. For example, activation of mTOR signals via HIF1α, initiates vascular endothelial growth factor (VEGF) expression in cortical tubers (Parker et al. 2011) and in FCDIIB (Boer et al. 2008a,b). Phosphoactivation of STAT3, a transcription factor regulated by mTOR is identified in FCDIIB and tubers (Baybis et al. 2004; Ma et al. 2010). Interestingly, the profiles of phosphorylated proteins in tubers versus FCDIIB are not identical, suggesting potentially different roles for mTOR signaling in the formation of these lesions. For example, phosphoactivation of the upstream cascade proteins p-PDK1 (S241), p-Akt (S473), and p-tuberin (T1462) in FCDIIB is distinct from tubers (Schick et al. 2007a,b). Interestingly, recent studies have shown a defect in autophagy in FCDIIB and TSC, as evidenced by the detection of autophagic vacuoles and expression of ATG component proteins and p62 (Yasin et al. 2013). These findings show that enhanced mTOR signaling may have diverse functional effects during brain development. In contrast, enhanced p70S6Kinase and S6 phosphorylation (e.g., mTOR activation) is not observed in FCD Type IA or IB (Orlova et al. 2010b).

Germline knockout models of *Tsc1* or *Tsc2* are embryonic lethal (Kwiatkowski et al. 2002), and thus conditional mouse Tsc1 or Tsc2 knockout strains driven by cell-specific promoters (e.g., GFAP for astrocytes, nestin for progenitor cells, synapsin for neurons) (e.g., see Meikle et al. 2007) have provided invaluable information about the role of these genes in brain development. A uniform histopathological feature of all of these strains is activation of the mTOR-signaling pathway as evidenced by phosphorylation of p70S6K and S6. Perhaps most interesting and clinically relevant is that manipulation of mTOR with rapamycin or other mTOR inhibitors abrogates the seizure phenotype and in several reports, improves cognitive performance as well in the mice. Indeed, the seminal paper providing translational relevance to mTOR signaling in TSC showed that the seizure phenotype in *Tsc1* cKO mice was abrogated following treatment with rapamycin before the onset of seizures (Zeng et al. 2008). Subsequent studies confirmed seizure relief in several mouse TSC models (for review, see Feliciano et al. 2013). Three recent preclinical studies have also shown that in utero prenatal treatment with rapamycin can prevent or significantly diminish the morphological consequences of Tsc1 or Tsc2 loss in the mouse (Anderl et al. 2011; Tsai et al. 2012b; Way et al. 2012). These findings suggest that in utero rapamycin could be used in the setting of a prenatal TSC diagnosis; however, rapamycin alone may have deleterious effects of fetal brain development that may warrant further consideration (Tsai et al. 2013).

The effects of rapamycin on pathological and behavioral deficits suggest again that the neurological features of TSC are intimately linked to aberrant mTOR signaling. In humans, the mTOR inhibitor everolimus was shown to be beneficial by reducing tumor volume for

nonsurgical cases of subependymal giant astrocytomas (SEGA) in TSC (Krueger et al. 2010). In this cohort of 26 patients, 16 suffered from seizures, and everolimus treatment modestly benefitted nine patients with seizure reduction. A more recent study showed that seizure frequency was reduced in TSC patients treated with everolimus (Krueger et al. 2013). In their cohort of 20 patients treated with everolimus, seizure frequency was reduced by $\geq$50% in 12 of 20 subjects. Significant reductions in seizure duration and improvement in parent-reported behavior and quality of life were also observed (Krueger et al. 2013). Clearly, mTOR inhibition may provide a novel cell-signaling cascade target in refractory epilepsy.

PRETZEL SYNDROME: A RECESSIVE mTORopathy

Pretzel syndrome (PS) is an autosomal recessive neurodevelopmental disorder identified among the old order Mennonite children in the Lancaster, PA area (Fig. 2) (Puffenberger et al. 2007). PS is characterized by severe intellectual disability, intractable epilepsy, dysmorphic facial features, and megalencephaly with 100% penetrance. In the initial report, 38% of children with PS died by age 8 (Puffenberger et al. 2007), typically from renal failure or status epilepticus. PS results from a homozygous deletion of exons 9–13 in the *STRADα* (*STRADA*) gene identified as a founder mutation in all

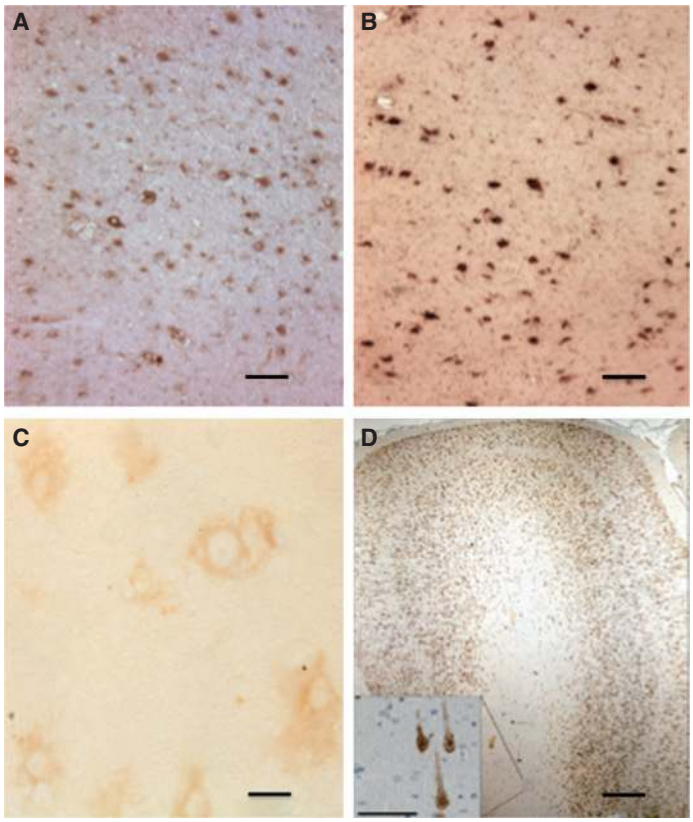

Figure 2. Histopathology of mammalian target of rapamycin (mTOR) activation in focal malformations of cortical development (MCD). (*A*) Focal cortical dysplasias type IIB (FCDIIB) showing phospho-S6 labeling. (*B*) Tuber showing phospho-S6 labeling. (*C*) Bottom-of-the-sulcus dysplasia showing phospho-S6 labeling. (*D*) Heterotopic neurons in white matter in Pretzel syndrome. (Adapted from Orlova et al. 2010a.) Scale bars, 300 μm (*A*,*B*); 80 μm (*C*); 1 mm (*D*); 50 μm (*inset*).

affected children. STRADA functions as a pseudokinase within a heteromeric protein complex comprised of the serine/theorine kinase (STK11), liver kinase B (LKB1), and a binding subunit, MO25, which serves an upstream regulatory role of mTOR via signaling through AMPK and TSC1/TSC2. Loss of STRADA function leads to diminished AMPK activation, which, in turn, decreases TSC2 inhibition of mTORC1 and results in enhanced mTORC1 activation. PS postmortem brain tissue contains enlarged dysmorphic neurons as well as heterotopic neurons within the subcortical white matter show numerous phospho-S6- and phospho-p70S6-kinase-labeled neurons, similar to FCDIIB and tubers. STRADA shRNA knockdown in vivo in fetal mouse brain induces mTORC1 activation, neuronal enlargement, laminar disorganization, and subcortical white matter heterotopias similar to human PS (Orlova et al. 2010a; Parker et al. 2013). Furthermore, there are severe impairments in cell motility, directionality, and polarity in mouse neural progenitor cells lacking STRADA (Orlova et al. 2010a; Parker et al. 2013). Treatment with the mTOR inhibitor rapamycin in both the mouse model and cell lines rescued the phenotype caused by loss of STRADA. These preclinical data led to a small open trial of rapamycin (sirolimus in clinical parlance) in five PS children for 8 months to 4 years, which showed prevention of seizures in these patients (Parker et al. 2013). This was the first study to show epilepsy prevention with an mTOR inhibitor and suggested that early treatment could dramatically alter clinical seizure onset.

HEMIMEGALENCEPHALY: A SOMATIC mTORopathy

HME may occur de novo, as a sporadic disorder, or may be identified as part of a syndrome (e.g., hypomelanosis of Ito or linear nevus syndrome) (Flores-Sarnat 2003; Tinkle et al. 2005). The neuropathological features of HME are heterogeneous (Manoranjan and Provias 2010). For example, some severe HME subtypes show massive hemispheric enlargement, marked laminar disorganization, altered gyral patterning, and consist of DNs, heterotopic neurons, and BCs (Flores-Sarnat 2002). Alternatively, milder forms are characterized by preservation of gyral patterning and less severe disorganization of the affected cortex.

Enhanced mTOR signaling in HME was first shown in BCs and DNs (Ljungberg et al. 2006; Aronica et al. 2007). In both studies, the specimens did not show enhanced mTOR activation in every cell (mTOR activation was observed in DNs and BCs), and, thus, it was postulated that HME forms as a consequence of somatic mutations in mTOR regulatory genes during brain development (Fig. 3) (Aronica et al. 2007; Crino 2007, 2011). In fact, recent studies have defined somatic activating mutations in mTOR regulatory genes such as *AKT3* (Poduri et al. 2012), *PI3K*, or *MTOR* (Lee et al. 2012) in a subset of HME cases. In the first study, Poduri and colleagues identified somatic trisomy 1q in DNA extracted from two HME brain specimens. The estimated copy numbers for the trisomy in one specimen was 3 with ~40% of the cells containing the trisomy 1q. They then identified an activating mutation in *AKT3* (c.49G → A, p.E17K), a known mTOR-signaling regulator (located on 1q) in another case and estimated that the mutation exists in the heterozygous state in 35% of cells. Lee and colleagues found mutations in *PI3K*, *MTOR*, and *AKT3* in 8%–40% of sequenced alleles in various brain regions. The neurodevelopmental implications of these two reports are pivotal. First, somatic mutations occurring in the embryonic brain clearly provide a mechanism for focal MCD and likely account for additional MCD subtypes (Fig. 4) . Second, only a portion of cells within one MCD express the somatic mutation, and thus each MCD is itself a mosaic of cells containing a mutation and cells with a normal gene complement. This observation suggests that some of the cytoarchitectural abnormalities represent cell-autonomous effects (i.e., a direct result of the mutation), and others may be non-cell autonomous (i.e., because of effects on bystander cells). Third, there is heterogeneity and variability in the somatic mutational burden within each MCD, with some areas containing high numbers of mutated alleles, whereas others

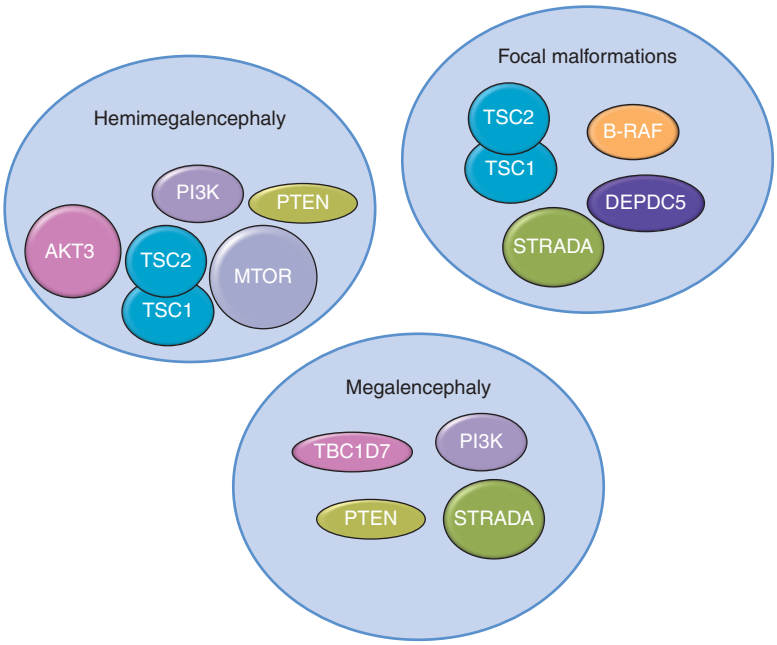

Figure 3. Select known genes for distinct focal malformations of cortical development (MCD) subtypes. Note similarity between the groups, each having a regulatory effect on mammalian target of rapamycin (mTOR). Mutations in *PI3K*, *AKT3*, and *MTOR* causing hemimegalencephaly are activating.

contain low numbers. This conclusion has potential ramifications for epileptogenesis, because differential mutation load could in theory more significantly affect excitability within an MCD. Of note, aberrant mTOR pathway signaling is not the only cause of HME, because other loci have been postulated for HME (Baybis et al. 2009). Thus, investigation of other regulatory pathways that govern hemispheric size is warranted.

The findings in HME suggest that the mTOR pathway serves as a pivotal regulator of brain size. For example germline mutations in *PI3K3R2*, *PI3KCA*, and *AKT* have been reported in megalencephaly-capillary malformation (MCAP) and megalencephaly-polymicrogyria-polydactyly-hydrocephalus (MPPH) syndromes (Riviere et al. 2012; see Mirzaa and Dobyns 2013). As discussed above, *STRADA* mutations cause megalencephaly in PMSE via activation of mTOR (Puffenberger et al. 2007). Recently, megalencephaly and intellectual disability (ME/intellectual disability [ID]) was reported in a consanguinous family with a *TBC1D7* mutation (Capo-Chici et al. 2013). Interestingly, although PTEN is far upstream from TSC1/TSC2, PTEN mutations have been found in patients with macrocephaly, seizures, and autism (Butler et al. 2005). *Pten* knockout mice show macrocephaly, neuronal soma hypertrophy, abnormal dendritic arborization, seizures, and impaired social learning (Kwon et al. 2003).

GG: TUMOR OR MALFORMATION?

GG is a most common neoplasm associated with pediatric epilepsy, representing about 5% of brain tumors of childhood (Southwell et al. 2012). Approximately 30% of GGs may be associated with an adjacent or adjoined FCD and are thus classified as FCDIIIB according to the recent ILAE classification (Blumcke et al. 2011). CD34-positive cells are also seen in BCs (characteristic enlarged cell found in TSC, FCDIIB, and HME) of FCDIIB suggesting a possible molecular link between GG and FCDIIB (Blumcke

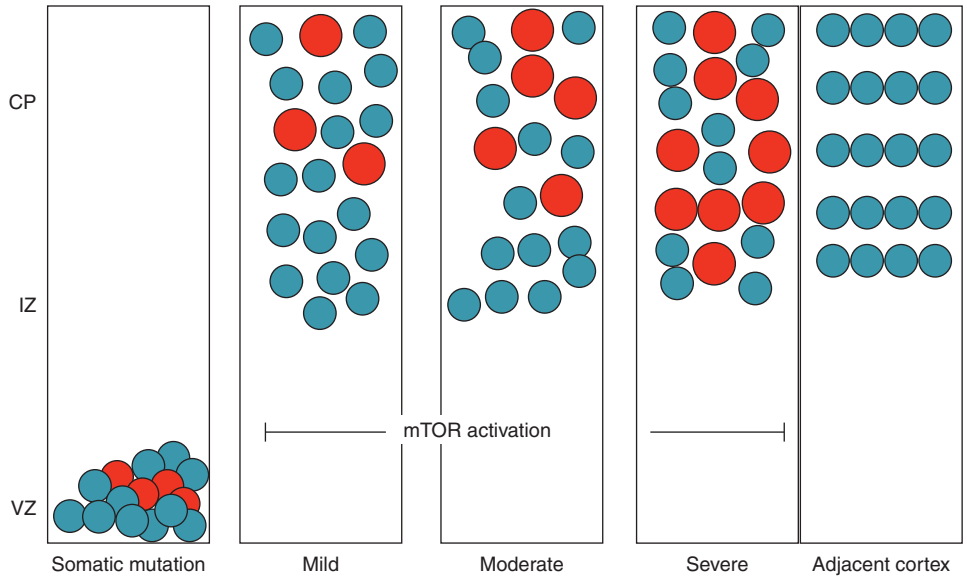

Figure 4. Schematic depiction of how somatic mutations cause focal malformations of cortical development (MCD) during fetal brain development. Neuroglial progenitor cells (as early as 8- to 10-week gestation) sustaining a somatic mutation undergo an early cytopathic change (red cells). The effect of the mutation is to cause mammalian target of rapamycin (mTOR) pathway activation (red cells). These cell-signaling changes lead to cellular enlargement (cytomegaly: enhanced cell soma size) and altered migration into the cortical plate (red cells). The admixture of affected cells (red) and adjacent cells (teal) form the focal MCD, surrounded by the unaffected cortex (all teal cells, far *right*). As shown in hemimegalencephaly (HME), there may be differential somatic mutational load within individual MCDs causing mild, moderate, or severe pathological changes. Similarly, across subjects, there may be different levels of mosaicism for each MCD subtype.

et al. 1999; Becker 2006; Marucci et al. 2013) and the inclusion of GG as an mTORopathy.

Enhanced mTOR signaling has been reported in GG as evidenced by p70S6kinase and S6 phosphorylation (largely in ATGCs), suggesting that GG shares similar mTOR-signaling pathology with FCDs and cortical tubers (Samadani et al. 2007). Moreover, the profile of phosphorylated-PDK1, -AKT, -mTOR, -4E-BP1, -eIF4G, -p70S6K, and -S6, are nearly identical to FCDIIB (Boer et al. 2010). Interestingly, a somatic V600E mutation in B-RAF, a known pathogenic gene for melanoma, has been identified in 18% (Schindler et al. 2011) and 58% (Koelsche et al. 2013) of resected GG specimens. The V600E mutation is detected primarily in the neuronal and ATGC cell component of GG (Koelsche et al. 2013). B-RAF has been linked to enhanced mTOR signaling (Faustino et al. 2012) via LKB1 and via mTORC2/Akt (Chen et al. 2012b), suggesting a functional link between the molecular etiology and consequent observed changes in mTOR signaling. Some GGs, however, do not express the V600E mutation and, thus, like HME, it is likely that other molecular etiologies for GGs will be defined in future studies.

FAMILIAL FOCAL EPILEPSY WITH VARIABLE FOCI: A NEW AND PROTEAN mTORopathy

As previously suggested, new focal MCD syndromes will likely be identified that result from mutations in novel or known mTOR regulatory genes (Crino 2005, 2011). Most recently, nonsense and missense mutations were identified in *DEPDC5* encoding a protein with tandem amino-terminal DEP (dishevelled, egl-10, pleckstrin) domains across several large Australian

pedigrees in which the clinical phenotype was characterized by focal epilepsies arising from distinct lobar locations in different family members (Dibbens et al. 2013). FFEVF shows recurrent and at times intractable seizures in association with variable intellectual and neuropsychiatric disorders (e.g., depression, anxiety) with an autosomal dominant inheritance pattern. A subset of these patients shows radiographically apparent focal MCD seen on brain MRI suggesting a link between *DEPDC5* mutations and altered brain development (Baulac et al. 2015). These focal MCDs often appear to be "bottom-of-the-sulcus" dysplasias, although, in a few cases, more expansive malformations were detected (e.g., focal band heterotopia) (Scheffer et al. 2014). Interestingly, in another report, *DEPDC5* mutations were associated with nonlesional focal epilepsies (Lal et al. 2014). DEPDC5 is an important component of the GATOR complex, which regulates mTORC1 activity in response to cellular levels of amino acid levels. Several studies have shown that, like TSC1 and TSC2, knockdown of DEPDC5 leads to enhanced mTORC1 signaling, and, thus, the mechanism of altered brain development in the setting of DEPDC5 mutation is likely mediated through the mTOR pathway. Further studies will be needed to define the role of DEPDC5 in cortical lamination and epileptogenesis and whether mTOR inhibitors can alter seizure frequency in FFEVF.

mTOR, MALFORMATIONS, AND EPILEPTOGENESIS: DISTINCT MECHANISTIC EFFECTS?

The mechanism of seizure initiation and propagation in focal MCD has not been fully defined (see Wong 2008; Wong and Crino 2012; Lasarge and Danzer 2014). Despite the known association between focal MCD and intractable seizures, distinguishing the differential contributions of altered brain structure, the effects of mutations on downstream gene, and protein expression, mTOR hyperactivation to epileptogenesis has been a challenge (see Aronica and Crino 2013). Although enhanced mTOR signaling is detected in knockout mouse models of mTOR regulatory genes associated with spontaneous seizures (e.g., *Tsc1*, *Tsc2*, *Pten*), hyperactive mTOR signaling is also found in animal models of seizures such as kainate treatment (Zeng et al. 2009; Sha et al. 2012) or electrical brain stimulation (van Vliet et al. 2012) in the absence of structural changes in the neocortex. Enhanced mTOR activation has been linked to mouse models of infantile spasms (see Raffo et al. 2011) and seizures induced in a hypoxia model lead to enhanced expression of genes-encoding components of the mTOR pathway (Theilhaber et al. 2013). There is PI3K- and Akt-dependent mTOR activation in a rat hippocampal organotypic culture model of post-traumatic epilepsy, and inhibition of PI3K, mTOR, or both (using a dual inhibitor) mitigated ictal activity and cell death (Berdichevsky et al. 2013). Enhanced mTOR activation is found in human temporal lobe epilepsy specimens (Sha et al. 2012; Sosunov et al. 2012), and a recent study showed enhanced mTOR signaling in a variety of epilepsy-associated structural lesions including mesial temporal sclerosis, FCD type IIIa, FCD type IIIc, and Rasmussen's encephalitis (Liu et al. 2014).

Enhanced mTOR signaling in neurons is associated with alterations in dendritic morphology, changes in dendritic spine density and structure, and diminished long-term depression, all of which can be linked to enhanced excitability and diminished seizure threshold (for comprehensive review, see Lasarge and Danzer 2014). mTORC1 hyperactivity contributes to early hippocampal-dependent spatial learning and memory deficits and dendritic dysregulation associated with status epilepticus (Brewster et al. 2013). Interestingly, the evolution of seizures and autistic behaviors following neonatal brain injury may be mTOR dependent (Talos et al. 2012). Transgenic *Pten* deletion in dentate granule cells (DGCs) induces mTOR activation and leads to spontaneous seizures (Pun et al. 2012). Interestingly, a recent study suggested that in Tsc1 knockout cells, although the frequency of mESPCs was increased, excitability of the network resulted from diminished inhibitory drive with decreased amplitude and frequency of miniature inhibitory postsynaptic

currents (Bateup et al. 2013). Loss of Tsc1 or Pten in hippocampal neurons in vitro lead to an increase in the ratio of excitation to inhibition at the network level, although through divergent mechanisms (Weston et al. 2014). These findings provide experimental support to observations in human tuber and FCDIIB specimens, which show reduced numbers of GABAergic inhibitory interneurons (White et al. 2001; Calcagnotto et al. 2005; Lamparello et al. 2007).

Mutations in *MTOR* have been recently identified in epileptic encephalopathies in the absence of MCD (Epi4K Consortium 2013), suggesting that enhanced mTOR signaling in the absence of structural abnormalities may lead to epileptogenesis by an as-yet-undefined mechanism. Indeed, in a compelling study, Abs and colleagues engineered biallelic Tsc1 gene deletion in adult Tsc1 heterozygous and wild-type mice using a tamoxifen inducible cre system (Abs et al. 2013). The mice developed seizures a few days after biallelic Tsc1 deletion in the absence of distinct histological changes, but showed acute mTORC1 pathway activation, enhanced neuronal excitability, and decreased threshold for protein-synthesis-dependent long-term potentiation preceding the onset of seizures. Rapamycin treatment after seizure onset diminished mTORC1 activity and fully abolished the seizures in this strain. Thus, it appears that enhanced mTOR signaling on its own may be a critical activation step even in the absence of overt neuropathological changes as well as in a number of distinct epilepsy-associated pathologies. However, conflicting data suggests that mTOR activation is not a universal finding in epilepsy, because several studies fail to show a benefit of rapamycin in mouse epilepsy models such as amygdalar stimulation (Sliwa et al. 2012) and pilocarpine-induced seizures (Buckmaster and Lew 2011). Future studies to more fully define how mTOR signaling fosters epileptogenesis may provide hope for using mTOR inhibitors as antiepileptogenic drugs to prevent the onset of seizures and/or halt the regression of behavioral development in select clinical scenarios (Cho 2011; Galanopolou et al. 2012).

FOCAL MCD AS mTORopathies: A UNIFIED PERSPECTIVE, NEW DIRECTIONS, AND QUESTIONS YET UNANSWERED

Enhanced mTOR signaling in TSC, FCD, HME, GG, PS, and FFEVF strongly supports the theory that that hyperactivation of the mTOR cascade during brain development leads to abnormal cortical lamination, cell size, and cell lineage in association with intractable epilepsy. There are several mechanisms by which mTOR activation can occur including inherited or spontaneous mutation, somatic mutation, and intrauterine infection. TSC and FFEVF occur by dominant inheritance or de novo mutation, and PS by recessive inheritance, of loss-of-function mutations in known mTOR inhibitors (e.g., *TSC1*, *TSC2*, *DEPDC5*, or *STRADA*). HME and GG result from somatic mutational events in known mTOR regulatory genes, which thus far are gain-of-function mutations in activators (e.g., *PI3K*, *AKT3*, *B-RAF*). The detection of HPV16 in FCDIIB suggests an infectious etiology, but clearly other molecular etiologies are possible. The logical next experimental steps will be to understand how mTOR activation disrupts cortical development in each mutation type, and to define other factors that contribute to the heterogeneous features of each focal MCD subtype.

From a clinical translational perspective, it seems that assay of phosphorylated mTOR-signaling proteins such as phosho-p70S6K or phospho-S6 in brain tissue resected during epilepsy surgery could be included in standard pathological evaluations as an approach to define tubers, FCD, GG, and HME. The mTOR pathway provides new avenues for clinical investigation including the development of new neuroimaging approaches such as new sequences to detect the byproducts of mTOR activation, new PET ligands to detect functional activation of mTOR, blood assays to define mTOR-signaling levels, and potentially new approaches to stratify patients for clinical trials.

Perhaps the most significant progress will come from designing targeted epilepsy therapies through inhibition of mTOR (Galanopolou et al. 2012; Wong 2013). Current data suggests that mTOR inhibitors can improve seizure

frequency in TSC and PS. Furthermore, mTOR inhibitors in mouse mTORopathy models can improve neurocognitive deficits, and thus these agents could yield novel therapeutic strategies to improve neurobehavioral disabilities. Larger trials with mTOR inhibitors as well as drugs that target multiple nodes in the mTOR cascade (e.g., PI3K and mTOR) may yield new treatment strategies.

ACKNOWLEDGMENTS

This work is supported by The National Institute of Neurological Disease and Stroke at the National Institutes of Health (NINDS R01NS082343-01), Citizens United for Research in Epilepsy (CURE).

REFERENCES

Abs E, Goorden SM, Schreiber J, Overwater IE, Hoogeveen-Westerveld M, Bruinsma CF, Aganović E, Borgesius NZ, Nellist M, Elgersma Y. 2013. TORC1-dependent epilepsy caused by acute biallelic Tsc1 deletion in adult mice. *Ann Neurol* **74:** 569–579.

Anderl S, Freeland M, Kwiatkowski DJ, Goto J. 2011. Therapeutic value of prenatal rapamycin treatment in a mouse brain model of tuberous sclerosis complex. *Hum Mol Genet* **20:** 4597–4604.

Aronica E, Crino PB. 2014. Epilepsy related to developmental tumors and malformations of cortical development. *Neurotherapeutics* **11:** 251–268.

Aronica E, Boer K, Baybis M, Yu J, Crino P. 2007. Co-expression of cyclin D1 and phosphorylated ribosomal S6 proteins in hemimegalencephaly. *Acta Neuropathol* **114:** 287–293.

Aronica E, Becker AJ, Spreafico R. 2012. Malformations of cortical development. *Brain Pathol* **22:** 380–401.

Barkovich AJ, Kuzniecky RI, Dobyns WB, Jackson GD, Becker LE, Evrard P. 1996. A classification scheme for malformations of cortical development. *Neuropediatrics* **1996:** 9–63.

Barkovich AJ, Guerrini R, Kuzniecky RI, Jackson GD, Dobyns WB. 2012. A developmental and genetic classification for malformations of cortical development: Update 2012. *Brain* **135:** 1348–1369.

Bateup HS, Johnson CA, Denefrio CL, Saulnier JL, Kornacker K, Sabatini BL. 2013. Excitatory/inhibitory synaptic imbalance leads to hippocampal hyperexcitability in mouse models of tuberous sclerosis. *Neuron* **78:** 510–522.

Baulac S, Ishida S, Marsan E, Miquel C, Biraben A, Nguyen DK, Nordli D, Cossette P, Nguyen S, Lambrecq V, et al. 2015. Familial focal epilepsy with focal cortical dysplasia due to DEPDC5 mutations. *Ann Neurol* doi: 10.1002/ana.24368.

Baybis M, Yu J, Lee A, Golden JA, Weiner H, McKhann G II, Aronica E, Crino PB. 2004. mTOR cascade activation distinguishes tubers from focal cortical dysplasia. *Ann Neurol* **56:** 478–487.

Baybis M, Aronica E, Nathanson KL, Crino PB. 2009. Deletion of 15q11.2-15q13.1 in isolated human hemimegalencephaly. *Acta Neuropathol* **118:** 821–823.

Becker LE. 1995. Central neuronal tumors in childhood: Relationship to dysplasia. *J Neurooncol* **24:** 13–19.

Becker AJ, Urbach H, Scheffler B, Baden T, Normann S, Lahl R, Pannek HW, Tuxhorn I, Elger CE, Schramm J, et al. 2002. Focal cortical dysplasia of Taylor's balloon cell type: Mutational analysis of the TSC1 gene indicates a pathogenic relationship to tuberous sclerosis. *Ann Neurol* **52:** 29–37.

Becker AJ, Blumcke I, Urbach H, Hans V, Majores M. 2006. Molecular neuropathology of epilepsy-associated glioneuronal malformations. *J Neuropathol Exp Neurol* **65:** 99–108.

Ben-Sahra I, Howell JJ, Asara JM, Manning BD. 2013. Stimulation of de novo pyrimidine synthesis by growth signaling through mTOR and S6K1. *Science* **339:** 1323–1328.

Berdichevsky Y 1, Dryer AM, Saponjian Y, Mahoney MM, Pimentel CA, Lucini CA, Usenovic M, Staley KJ. 2013. PI3K-Akt signaling activates mTOR-mediated epileptogenesis in organotypic hippocampal culture model of post-traumatic epilepsy. *J Neurosci* **33:** 9056–9067.

Blumcke I, Muhlebner A. 2011. Neuropathological work-up of focal cortical dysplasias using the new ILAE consensus classification system—Practical guideline article invited by the Euro-CNS Research Committee. *Clin Neuropathol* **30:** 164–177.

Blumcke I, Giencke K, Wardelmann E, Beyenburg S, Kral T, Sarioglu N, Pietsch T, Wolf HK, Schramm J, Elger CE, et al. 1999. The CD34 epitope is expressed in neoplastic and malformative lesions associated with chronic, focal epilepsies. *Acta Neuropathol* **97:** 481–490.

Blumcke I, Thom M, Aronica E, Armstrong DD, Vinters HV, Palmini A, Jacques TS, Avanzini G, Barkovich AJ, Battaglia G, et al. 2011. The clinicopathologic spectrum of focal cortical dysplasias: A consensus classification proposed by an ad hoc Task Force of the ILAE Diagnostic Methods Commission. *Epilepsia* **52:** 158–174.

Boer K, Troost D, Spliet WG, Redeker S, Crino PB, Aronica E. 2007. A neuropathological study of two autopsy cases of syndromic hemimegalencephaly. *Neuropathol Appl Neurobiol* **33:** 455–470.

Boer K, Troost D, Jansen F, Nellist M, van den Ouweland AM, Geurts JJ, Spliet WG, Crino P, Aronica E. 2008a. Clinicopathological and immunohistochemical findings in an autopsy case of tuberous sclerosis complex. *Neuropathology* **28:** 577–590.

Boer K, Troost D, Spliet WG, van Rijen PC, Gorter JA, Aronica E. 2008b. Cellular distribution of vascular endothelial growth factor A (VEGFA) and B (VEGFB) and VEGF receptors 1 and 2 in focal cortical dysplasia type IIB. *Acta Neuropathol* **115:** 683–696.

Boer K, Troost D, Timmermans W, van Rijen PC, Spliet WG, Aronica E. 2010. PI3K-mTOR signaling and AMOG expression in epilepsy-associated glioneuronal tumors. *Brain Pathol* **20:** 234–244.

Bosnjak VM, Dakovic I, Duranovic V, Lujic L, Krakar G, Marn B. 2011. Malformations of cortical development in children with congenital cytomegalovirus infection—A study of nine children with proven congenital cytomegalovirus infection. *Coll Antropol* **35:** 229–234.

Bourneville D. 1880. Sclérose tubéreuse des circonvolutions cérébrales: Idiotie et épilepsie hémiplégique. *Arch Neurol (Paris)* **1:** 81–91.

Brewster AL 1, Lugo JN, Patil VV, Lee WL, Qian Y, Vanegas F, Anderson AE. 2013. Rapamycin reverses status epilepticus-induced memory deficits and dendritic damage. *PLoS ONE* **8:** e57808.

Buckmaster PS, Lew FH. 2011. Rapamycin suppresses mossy fiber sprouting but not seizure frequency in a mouse model of temporal lobe epilepsy. *J Neurosci* **31:** 2337–2347.

Butler MG, Dasouki MJ, Zhou XP, Talebizadeh Z, Brown M, Takahashi TN, Miles JH, Wang CH, Stratton R, Pilarski R, et al. 2005. Subset of individuals with autism spectrum disorders and extreme macrocephaly associated with germline PTEN tumour suppressor gene mutations. *J Med Genet* **42:** 318–321.

Calcagnotto ME 1, Paredes MF, Tihan T, Barbaro NM, Baraban SC. 2005. Dysfunction of synaptic inhibition in epilepsy associated with focal cortical dysplasia. *J Neurosci* **25:** 9649–9657.

Capo-Chichi JM, Tcherkezian J, Hamdan FF, Décarie JC, Dobrzeniecka S, Patry L, Nadon MA, Mucha BE, Major P, Shevell M, et al. 2013. Disruption of TBC1D7, a subunit of the TSC1-TSC2 protein complex, in intellectual disability and megalencephaly. *J Med Genet* **50:** 740–744.

Chen J, Tsai V, Parker WE, Aronica E, Baybis M, Crino PB. 2012a. Detection of human papillomavirus in human focal cortical dysplasia type IIB. *Ann Neurol* **72:** 881–892.

Chen B, Tardell C, Higgins B, Packman K, Boylan JF, Niu H. 2012b. BRAFV600E negatively regulates the AKT pathway in melanoma cell lines. *PLoS ONE* **7:** e42598.

Cho CH. 2011. Frontier of epilepsy research—mTOR signaling pathway. *Exp Mol Med* **43:** 231–274.

Chu-Shore CJ, Major P, Camposano S, Muzykewicz D, Thiele EA. 2010. The natural history of epilepsy in tuberous sclerosis complex. *Epilepsia* **51:** 1236–1241.

Colombo N, Salamon N, Raybaud C, Ozkara C, Barkovich AJ. 2009. Imaging of malformations of cortical development. *Epileptic Disord* **11:** 194–205.

Crino PB. 2005. Molecular pathogenesis of focal cortical dysplasia and hemimegalencephaly. *J Child Neurol* **20:** 330–336.

Crino PB. 2007. Focal brain malformations: A spectrum of disorders along the mTOR cascade. *Novartis Foundation Symposium* **288:** 260–272; discussion 272–281.

Crino PB. 2009. Focal brain malformations: Seizures, signaling, sequencing. *Epilepsia* **50:** 3–8.

Crino PB. 2011. mTOR: A pathogenic signaling pathway in developmental brain malformations. *Trends Mol Med* **17:** 734–742.

Crino PB. 2013. Evolving neurobiology of tuberous sclerosis complex. *Acta Neuropathol* **125:** 317–332.

Crino PB, Nathanson KL, Henske EP. 2006. The tuberous sclerosis complex. *N Engl J Med* **355:** 1345–1356.

Crino PB, Aronica E, Baltuch G, Nathanson KL. 2010. Biallelic TSC gene inactivation in tuberous sclerosis complex. *Neurology* **74:** 1716–1723.

Dibbens LM, de Vries B, Donatello S, Heron SE, Hodgson BL, Chintawar S, Crompton DE, Hughes JN, Bellows ST, Klein KM, et al. 2013. Mutations in DEPDC5 cause familial focal epilepsy with variable foci. *Nat Genet* **45:** 546–551.

Dibble CC, Elis W, Menon S, Qin W, Klekota J, Asara JM, Finan PM, Kwiatkowski DJ, Murphy LO, Manning BD. 2012. TBC1D7 is a third subunit of the TSC1-TSC2 complex upstream of mTORC1. *Mol Cell* **47:** 535–546.

Dobashi Y, Watanabe Y, Miwa C, Suzuki S, Koyama S. 2011. Mammalian target of rapamycin: A central node of complex signaling cascades. *Int J Clin Exp Pathol* **4:** 476–495.

Epi4K Consortium; Epilepsy Phenome/Genome Project, Allen AS, Berkovic SF, Cossette P, Delanty N, Dlugos D, Eichler EE, Epstein MP, Glauser T, et al. 2013. De novo mutations in epileptic encephalopathies. *Nature* **501:** 217–221.

Faustino A, Couto JP, Pópulo H, Rocha AS, Pardal F, Cameselle-Teijeiro JM, Lopes JM, Sobrinho-Simões M, Soares P. 2012. mTOR pathway overactivation in BRAF mutated papillary thyroid carcinoma. *J Clin Endocrinol Metab* **97:** E1139–E1149.

Feliciano DM, Su T, Lopez J, Platel JC, Bordey A. 2011. Single-cell Tsc1 knockout during corticogenesis generates tuber-like lesions and reduces seizure threshold in mice. *J Clin Invest* **121:** 1596–1607.

Feliciano DM, Lin TV, Hartman NW, Bartley CM, Kubera C, Hsieh L, Lafourcade C, O'Keefe RA, Bordey A. 2013. A circuitry and biochemical basis for tuberous sclerosis symptoms: From epilepsy to neurocognitive deficits. *Int J Dev Neurosci* **31:** 667–678.

Flores-Sarnat L, Sarnat HB, Davila-Gutierrez G, Alvarez A. 2003. Hemimegalencephaly: Part 2. Neuropathology suggests a disorder of cellular lineage. *J Child Neurol* **18:** 776–785.

Galanopoulou AS, Gorter JA, Cepeda C. 2012. Finding a better drug for epilepsy: The mTOR pathway as an antiepileptogenic target. *Epilepsia* **53:** 1119–1130.

Guerrini R, Dobyns WB. 2014. Malformations of cortical development: Clinical features and genetic causes. *Lancet Neurol* **13:** 710–726.

Gumbinger C, Rohsbach CB, Schulze-Bonhage A, Korinthenberg R, Zentner J, Haffner M, Fauser S. 2009. Focal cortical dysplasia: A genotype-phenotype analysis of polymorphisms and mutations in the TSC genes. *Epilepsia* **50:** 1396–1408.

Hsu PP, Kang SA, Rameseder J, Zhang Y, Ottina KA, Lim D, Peterson TR, Choi Y, Gray NS, Yaffe MB, et al. 2011. The mTOR-regulated phosphoproteome reveals a mechanism of mTORC1-mediated inhibition of growth factor signaling. *Science* **332:** 1317–1322.

Jacinto E, Loewith R, Schmidt A, Lin S, Ruegg MA, Hall A, Hall MN. 2004. Mammalian TOR complex 2 controls the actin cytoskeleton and is rapamycin insensitive. *Nat Cell Biol* **6:** 1122–1128.

Koelsche C, Wohrer A, Jeibmann A, Schittenhelm J, Schindler G, Preusser M, Lasitschka F, von Deimling A, Capper D. 2013. Mutant BRAF V600E protein in gan-

glioglioma is predominantly expressed by neuronal tumor cells. *Acta Neuropathol* **6:** 891–900.

Krsek P, Maton B, Korman B, Pacheco-Jacome E, Jayakar P, Dunoyer C, Rey G, Morrison G, Ragheb J, Vinters HV, et al. 2008. Different features of histopathological subtypes of pediatric focal cortical dysplasia. *Ann Neurol* **63:** 758–769.

Krueger DA, Care MM, Holland K, Agricola K, Tudor C, Mangeshkar P, Wilson KA, Byars A, Sahmoud T, Franz DN. 2010. Everolimus for subependymal giant-cell astrocytomas in tuberous sclerosis. *N Engl J Med* **363:** 1801–1811.

Krueger DA, Wilfong AA, Holland-Bouley K, Anderson AE, Agricola K, Tudor C, Mays M, Lopez CM, Kim MO, Franz DN. 2013. Everolimus treatment of refractory epilepsy in tuberous sclerosis complex. *Ann Neurol* **74:** 679–687.

Kwiatkowski DJ, Zhang H, Bandura JL, Heiberger KM, Glogauer M, el-Hashemite N, Onda H. 2002. A mouse model of TSC1 reveals sex-dependent lethality from liver hemangiomas, and up-regulation of pp70S6 kinase activity in Tsc1 null cells. *Hum Mol Genet* **11:** 525–534.

Kwon CH, Zhu X, Zhang J, Baker SJ. 2003. mTor is required for hypertrophy of Pten-deficient neuronal soma in vivo. *Proc Natl Acad Sci* **100:** 12923–12928.

Kwon CH, Luikart BW, Powell CM, Zhou J, Matheny SA, Zhang W, Li Y, Baker SJ, Parada LF. 2006. Pten regulates neuronal arborization and social interaction in mice. *Neuron* **50:** 377–388.

Lal D, Reinthaler EM, Schubert J, Muhle H, Riesch E, Kluger G, Jabbari K, Kawalia A, Bäumel C, Holthausen H, et al. 2014. DEPDC5 mutations in genetic focal epilepsies of childhood. *Ann Neurol* **75:** 788–792.

Lamparello P, Baybis M, Pollard J, Hol EM, Eisenstat DD, Aronica E, Crino PB. 2007. Developmental lineage of cell types in cortical dysplasia with balloon cells. *Brain* **130:** 2267–2276.

Lasarge CL, Danzer SC. 2014. Mechanisms regulating neuronal excitability and seizure development following mTOR pathway hyperactivation. *Front Mol Neurosci* **7:** 18.

Lee JH, Huynh M, Silhavy JL, Kim S, Dixon-Salazar T, Heiberg A, Scott E, Bafna V, Hill KJ, Collazo A, et al. 2012. De novo somatic mutations in components of the PI3K-AKT3-mTOR pathway cause hemimegalencephaly. *Nat Genet* **44:** 941–945.

Liu S, Lu L, Cheng X, Xu G, Yang H. 2014. Viral infection and focal cortical dysplasia. *Ann Neurol* **75:** 614–616.

Ljungberg MC, Bhattacharjee MB, Lu Y, Armstrong DL, Yoshor D, Swann JW, Sheldon M, D'Arcangelo G. 2006. Activation of mammalian target of rapamycin in cytomegalic neurons of human cortical dysplasia. *Ann Neurol* **60:** 420–429.

Loewith R, Jacinto E, Wullschleger S, Lorberg A, Crespo JL, Bonenfant D, Oppliger W, Jenoe P, Hall MN. 2002. Two TOR complexes, only one of which is rapamycin sensitive, have distinct roles in cell growth control. *Mol Cell* **10:** 457–468.

Ma J, Meng Y, Kwiatkowski DJ, Chen X, Peng H, Sun Q, Zha X, Wang F, Wang Y, Jing Y, et al. 2010. Mammalian target of rapamycin regulates murine and human cell differentiation through STAT3/p63/Jagged/Notch cascade. *J Clin Invest* **120:** 103–114.

Manoranjan B, Provias JP. 2010. Hemimegalencephaly: A fetal case with neuropathological confirmation and review of the literature. *Acta Neuropathol* **120:** 117–130.

Marucci G, Martinoni M, Giulioni M. 2013. Relationship between focal cortical dysplasia and epilepsy-associated low-grade tumors: An immunohistochemical study. *APMIS* **121:** 22–29.

Meikle L, Talos DM, Onda H, Pollizzi K, Rotenberg A, Sahin M, Jensen FE, Kwiatkowski DJ. 2007. A mouse model of tuberous sclerosis: Neuronal loss of Tsc1 causes dysplastic and ectopic neurons, reduced myelination, seizure activity, and limited survival. *J Neurosci* **27:** 5546–5558.

Menon S, Manning BD. 2008. Common corruption of the mTOR signaling network in human tumors. *Oncogene* **27:** S43–S51.

Menon S, Dibble CC, Talbott G, Hoxhaj G, Valvezan AJ, Takahashi H, Cantley LC, Manning BD. 2014. Spatial control of the TSC complex integrates insulin and nutrient regulation of mTORC1 at the lysosome. *Cell* **156:** 771–785.

Mirzaa GM, Dobyns WB. 2013. The "megalencephaly-capillary malformation" (MCAP) syndrome: The nomenclature of a highly recognizable multiple congenital anomaly syndrome. *Am J Med Genet A* **161A:** 2115–2116.

Mischel PS, Nguyen LP, Vinters HV. 1995. Cerebral cortical dysplasia associated with pediatric epilepsy. Review of neuropathologic features and proposal for a grading system. *J Neuropathol Exp Neurol* **54:** 137–153.

Miyata H, Chiang AC, Vinters HV. 2004. Insulin signaling pathways in cortical dysplasia and TSC-tubers: Tissue microarray analysis. *Ann Neurol* **56:** 510–519.

Muhlebner A, Coras R, Kobow K, Feucht M, Czech T, Stefan H, Weigel D, Buchfelder M, Holthausen H, Pieper T, et al. 2012. Neuropathologic measurements in focal cortical dysplasias: Validation of the ILAE 2011 classification system and diagnostic implications for MRI. *Acta Neuropathol* **123:** 259–272.

Orlova KA, Crino PB. 2010. The tuberous sclerosis complex. *Ann NY Acad Sci* **1184:** 87–105.

Orlova KA, Parker WE, Heuer GG, Tsai V, Yoon J, Baybis M, Fenning RS, Strauss K, Crino PB. 2010a. STRADα deficiency results in aberrant mTORC1 signaling during corticogenesis in humans and mice. *J Clin Invest* **120:** 1591–1602.

Orlova KA, Tsai V, Baybis M, Heuer GG, Sisodiya S, Thom M, Strauss K, Aronica E, Storm PB, Crino PB. 2010b. Early progenitor cell marker expression distinguishes type II from type I focal cortical dysplasias. *J Neuropathol Exp Neurol* **69:** 850–863.

Palmini A, Najm I, Avanzini G, Babb T, Guerrini R, Foldvary-Schaefer N, Jackson G, Luders HO, Prayson R, Spreafico R, et al. 2004. Terminology and classification of the cortical dysplasias. *Neurology* **62:** S2–S8.

Parker WE, Orlova KA, Heuer GG, Baybis M, Aronica E, Frost M, Wong M, Crino PB. 2011. Enhanced epidermal growth factor, hepatocyte growth factor, and vascular endothelial growth factor expression in tuberous sclerosis complex. *Am J Pathol* **178:** 296–305.

Parker WE, Orlova KA, Parker WH, Birnbaum JF, Krymskaya VP, Goncharov DA, Baybis M, Helfferich J, Okochi K, Strauss KA, et al. 2013. Rapamycin prevents seizures

after depletion of STRADA in a rare neurodevelopmental disorder. *Sci Transl Med* **5:** 182ra53.

Poduri A, Evrony GD, Cai X, Elhosary PC, Beroukhim R, Lehtinen MK, Hills LB, Heinzen EL, Hill A, Hill RS, et al. 2012. Somatic activation of AKT3 causes hemispheric developmental brain malformations. *Neuron* **74:** 41–48.

Prabowo AS, Anink JJ, Lammens M, Nellist M, van den Ouweland AM, Adle-Biassette H, Sarnat HB, Flores-Sarnat L, Crino PB, Aronica E. 2013. Fetal brain lesions in tuberous sclerosis complex: TORC1 activation and inflammation. *Brain Pathol* **23:** 45–59.

Puffenberger EG, Strauss KA, Ramsey KE, Craig DW, Stephan DA, Robinson DL, Hendrickson CL, Gottlieb S, Ramsay DA, Siu VM, et al. 2007. Polyhydramnios, megalencephaly and symptomatic epilepsy caused by a homozygous 7-kilobase deletion in LYK5. *Brain* **130:** 1929–1941.

Pun RY, Rolle IJ, Lasarge CL, Hosford BE, Rosen JM, Uhl JD, Schmeltzer SN, Faulkner C, Bronson SL, Murphy BL, et al. 2012. Excessive activation of mTOR in postnatally generated granule cells is sufficient to cause epilepsy. *Neuron* **75:** 1022–1034.

Qin W, Chan JA, Vinters HV, Mathern GW, Franz DN, Taillon BE, Bouffard P, Kwiatkowski DJ. 2010. Analysis of TSC cortical tubers by deep sequencing of TSC1, TSC2 and KRAS demonstrates that small second-hit mutations in these genes are rare events. *Brain Pathol* **20:** 1096–1105.

Raffo E, Coppola A, Ono T, Briggs SW, Galanopoulou AS. 2011. A pulse rapamycin therapy for infantile spasms and associated cognitive decline. *Neurobiol Dis* **43:** 322–329.

Reith RM, Way S, McKenna J III, Haines K, Gambello MJ. 2011. Loss of the tuberous sclerosis complex protein tuberin causes Purkinje cell degeneration. *Neurobiol Dis* **43:** 113–122.

Reith RM, McKenna J, Wu H, Hashmi SS, Cho SH, Dash PK, Gambello MJ. 2013. Loss of Tsc2 in Purkinje cells is associated with autistic-like behavior in a mouse model of tuberous sclerosis complex. *Neurobiol Dis* **51:** 93–103.

Riviere JB, Mirzaa GM, O'Roak BJ, Beddaoui M, Alcantara D, Conway RL, St-Onge J, Schwartzentruber JA, Gripp KW, Nikkel SM, et al. 2012. De novo germline and postzygotic mutations in AKT3, PIK3R2 and PIK3CA cause a spectrum of related megalencephaly syndromes. *Nat Genet* **44:** 934–940.

Russell RC, Fang C, Guan KL. 2011. An emerging role for TOR signaling in mammalian tissue and stem cell physiology. *Development* **138:** 3343–3356.

Sabers CJ, Martin MM, Brunn GJ, Williams JM, Dumont FJ, Wiederrecht G, Abraham RT. 1995. Isolation of a protein target of the FKBP12-rapamycin complex in mammalian cells. *J Biol Chem* **270:** 815–822.

Samadani U, Judkins AR, Akpalu A, Aronica E, Crino PB. 2007. Differential cellular gene expression in ganglioglioma. *Epilepsia* **48:** 646–653.

Sha LZ, Xing XL, Zhang D, Yao Y, Dou WC, Jin LR, Wu LW, Xu Q. 2012. Mapping the spatio-temporal pattern of the mammalian target of rapamycin (mTOR) activation in temporal lobe epilepsy. *PLoS ONE* **7:** e39152.

Scheffer IE, Heron SE, Regan BM, Mandelstam S, Crompton DE, Hodgson BL, Licchetta L, Provini F, Bisulli F, Vadlamudi L, et al. 2014. Mutations in mammalian target of rapamycin regulator DEPDC5 cause focal epilepsy with brain malformations. *Ann Neurol* **75:** 782–787.

Schick V, Majores M, Engels G, Hartmann W, Elger CE, Schramm J, Schoch S, Becker AJ. 2007a. Differential PI3K-pathway activation in cortical tubers and focal cortical dysplasias with balloon cells. *Brain Pathol* **17:** 165–173.

Schick V, Majores M, Koch A, Elger CE, Schramm J, Urbach H, Becker AJ. 2007b. Alterations of phosphatidylinositol 3-kinase pathway components in epilepsy-associated glioneuronal lesions. *Epilepsia* **48:** 65–73.

Schindler G, Capper D, Meyer J, Janzarik W, Omran H, Herold-Mende C, Schmieder K, Wesseling P, Mawrin C, Hasselblatt M, et al. 2011. Analysis of BRAF V600E mutation in 1,320 nervous system tumors reveals high mutation frequencies in pleomorphic xanthoastrocytoma, ganglioglioma and extra-cerebellar pilocytic astrocytoma. *Acta Neuropathol* **121:** 397–405.

Sims J. 1835. On hypertrophy and atrophy of the brain. *Med Chir Trans* **19:** 315–380.

Sisodiya SM. 2004. Malformations of cortical development: Burdens and insights from important causes of human epilepsy. *Lancet Neurol* **3:** 29–38.

Sliwa A, Plucinska G, Bednarczyk J, Lukasiuk K. 2012. Post-treatment with rapamycin does not prevent epileptogenesis in the amygdala stimulation model of temporal lobe epilepsy. *Neurosci Lett* **509:** 105–109.

Sosunov AA, Wu X, McGovern RA, Coughlin DG, Mikell CB, Goodman RR, McKhann GM II. 2012. The mTOR pathway is activated in glial cells in mesial temporal sclerosis. *Epilepsia* **53:** 78–86.

Southwell DG, Garcia PA, Berger MS, Barbaro NM, Chang EF. 2012. Long-term seizure control outcomes after resection of gangliogliomas. *Neurosurgery* **70:** 1406–1413; discussion 1413–1404.

Talos DM, Kwiatkowski DJ, Cordero K, Black PM, Jensen FE. 2008. Cell-specific alterations of glutamate receptor expression in tuberous sclerosis complex cortical tubers. *Ann Neurol* **63:** 454–465.

Talos DM, Sun H, Zhou X, Fitzgerald EC, Jackson MC, Klein PM, Lan VJ, Joseph A, Jensen FE. 2012. The interaction between early life epilepsy and autistic-like behavioral consequences: A role for the mammalian target of rapamycin (mTOR) pathway. *PloS ONE* **7:** e35885.

Tassi L, Colombo N, Garbelli R, Francione S, Lo Russo G, Mai R, Cardinale F, Cossu M, Ferrario A, Galli C, et al. 2002. Focal cortical dysplasia: Neuropathological subtypes, EEG, neuroimaging and surgical outcome. *Brain* **125:** 1719–1732.

Taylor DC, Falconer MA, Bruton CJ, Corsellis JA. 1971. Focal dysplasia of the cerebral cortex in epilepsy. *J Neurol Neurosurg Psychiatry* **34:** 369–387.

Theilhaber J 1, Rakhade SN, Sudhalter J, Kothari N, Klein P, Pollard J, Jensen FE. 2013. Gene expression profiling of a hypoxic seizure model of epilepsy suggests a role for mTOR and Wnt signaling in epileptogenesis. *PLoS ONE* **8:** e74428.

Tinkle BT, EK Schorry, DN Franz, KR Crone, HM Saal. 2005. Epidemiology of hemimegalencephaly: A case series and review. *Am J Med Genet A* **139:** 204–211.

Tsai PT, Hull C, Chu Y, Greene-Colozzi E, Sadowski AR, Leech JM, Steinberg J, Crawley JN, Regehr WG, Sahin M. 2012a. Autistic-like behaviour and cerebellar dysfunction in Purkinje cell Tsc1 mutant mice. *Nature* **488:** 647–651.

Tsai V, Parker WE, Orlova KA, Baybis M, Chi AW, Berg BD, Birnbaum JF, Estevez J, Okochi K, Sarnat HB, et al. 2012b. Fetal brain mTOR signaling activation in tuberous sclerosis complex. *Cereb Cortex* **24:** 315–327.

Tsai PT, Greene-Colozzi E, Goto J, Anderl S, Kwiatkowski DJ, Sahin M. 2013. Prenatal rapamycin results in early and late behavioral abnormalities in wildtype C57Bl/6 mice. *Behav Genet* **43:** 51–59.

Urbanska M, Gozdz A, Swiech LJ, Jaworski J. 2012. Mammalian target of rapamycin complex 1 (mTORC1) and 2 (mTORC2) control the dendritic arbor morphology of hippocampal neurons. *J Biol Chem* **287:** 30240–30256.

Van Vliet EA, Forte G, Holtman L, den Burger JC, Sinjewel A, de Vries HE, Aronica E, Gorter JA. 2012. Inhibition of mammalian target of rapamycin reduces epileptogenesis and blood-brain barrier leakage but not microglia activation. *Epilepsia* **53:** 1254–1263.

Vaughn J, Hagiwara M, Katz J, Roth J, Devinsky O, Weiner H, Milla S. 2013. MRI characterization and longitudinal study of focal cerebellar lesions in a young tuberous sclerosis cohort. *AJNR Am J Neuroradiol* **34:** 655–659.

Way SW, McKenna J III, Mietzsch U, Reith RM, Wu HC, Gambello MJ. 2009. Loss of Tsc2 in radial glia models the brain pathology of tuberous sclerosis complex in the mouse. *Hum Mol Genet* **18:** 1252–1265.

Way SW, Rozas NS, Wu HC, McKenna J III, Reith RM, Hashmi SS, Dash PK, Gambello MJ. 2012. The differential effects of prenatal and/or postnatal rapamycin on neurodevelopmental defects and cognition in a neuroglial mouse model of tuberous sclerosis complex. *Hum Mol Genet* **21:** 3226–3236.

Weber JD, Gutmann DH. 2012. Deconvoluting mTOR biology. *Cell Cycle* **11:** 236–248.

Weston MC, Chen H, Swann JW. 2014. Loss of mTOR repressors Tsc1 or Pten has divergent effects on excitatory and inhibitory synaptic transmission in single hippocampal neuron cultures. *Front Mol Neurosci* **7:** 1.

White R, Hua Y, Scheithauer B, Lynch DR, Henske EP, Crino PB. 2001. Selective alterations in glutamate and GABA receptor subunit mRNA expression in dysplastic neurons and giant cells of cortical tubers. *Ann Neurol* **49:** 67–78.

Wong M. 2008. Mechanisms of epileptogenesis in tuberous sclerosis complex and related malformations of cortical development with abnormal glioneuronal proliferation. *Epilepsia* **49:** 8–21.

Wong M. 2013. A critical review of mTOR inhibitors and epilepsy: From basic science to clinical trials. *Expert Rev Neurother* **13:** 657–669.

Wong M, Crino PB. 2012. mTOR and epileptogenesis in developmental brain malformations. In: *Jasper's basic mechanisms of the epilepsies* (ed. Noebels JL, et al.). National Center for Biotechnology Information, Bethesda, MD.

Yasin SA, Ali AM, Tata M, Picker SR, Anderson GW, Latimer-Bowman E, Nicholson SL, Harkness W, Cross JH, Paine SM, et al. 2013. mTOR-dependent abnormalities in autophagy characterize human malformations of cortical development: Evidence from focal cortical dysplasia and tuberous sclerosis. *Acta Neuropathol* **126:** 207–218.

Zeng LH, Xu L, Gutmann DH, Wong M. 2008. Rapamycin prevents epilepsy in a mouse model of tuberous sclerosis complex. *Ann Neurol* **63:** 444–453.

Zeng LH, Rensing NR, Wong M. 2009. The mammalian target of rapamycin signaling pathway mediates epileptogenesis in a model of temporal lobe epilepsy. *J Neurosci* **29:** 6964–6972.

Zeng LH, Rensing NR, Zhang B, Gutmann DH, Gambello MJ, Wong M. 2011. Tsc2 gene inactivation causes a more severe epilepsy phenotype than Tsc1 inactivation in a mouse model of tuberous sclerosis complex. *Hum Mol Genet* **20:** 445–454.

Zhou H, Huang S. 2011. Role of mTOR signaling in tumor cell motility, invasion and metastasis. *Curr Protein Pept Sci* **12:** 30–42.

Zhou Y, Pan Y, Zhang S, Shi X, Ning T, Ke Y. 2007. Increased phosphorylation of p70 S6 kinase is associated with HPV16 infection in cervical cancer and esophageal cancer. *Br J Cancer* **97:** 218–222.

Zoncu R, Efeyan A, Sabatini DM. 2011. mTOR: From growth signal integration to cancer, diabetes and ageing. *Nat Rev Mol Cell Biol* **12:** 21–35.

Cold Spring Harbor Perspectives in Medicine

mTOR Signaling in Epilepsy: Insights from Malformations of Cortical Development

Peter B. Crino

Cold Spring Harb Perspect Med 2015; doi: 10.1101/cshperspect.a022442

Subject Collection Epilepsy: The Biology of a Spectrum Disorder