

Newcastle University e-prints

Date deposited: 19 July 2010

Version of file: Published, final

Peer Review Status: Peer-reviewed

Citation for published item:

Yu Wai Man P, Griffiths PG, Gorman GS, Lourenco CM, Wright AF, Auer-Grumbach M, Toscano A, Musumeci O, Valentino ML, Caporali L, Lamperti C, Tallaksen CM, Duffey P, Miller J, Whittaker RG, Baker MR, Jackson MJ, Clarke MP, Dhillon B, Czermin B, Stewart JD, Hudson G, Reynier P, Bonneau D, Marques W, Lenaers G, McFarland R, Taylor RW, Turnbull DM, Votruba M, Zeviani M, Carelli V, Bindoff LA, Horvath R, Amati-Bonneau P, Chinnery PF. [Multi-system neurological disease is common in patients with *OPA1* mutations](#). *Brain* 2010,**133** 771-786.

Further information on publisher website:

<http://brain.oxfordjournals.org/>

Publisher's copyright statement:

The definitive version of this article, published by Oxford University Press, 2010, is available at:

<http://dx.doi.org/10.1093/brain/awq007>

Always use the definitive version when citing.

Use Policy:

The full-text may be used and/or reproduced and given to third parties in any format or medium, without prior permission or charge, for personal research or study, educational, or not for profit purposes provided that:

- A full bibliographic reference is made to the original source
- A link is made to the metadata record in Newcastle E-prints
- The full text is not changed in any way.

The full-text must not be sold in any format or medium without the formal permission of the copyright holders.

<p>Robinson Library, University of Newcastle upon Tyne, Newcastle upon Tyne. NE1 7RU. Tel. 0191 222 6000</p>

Multi-system neurological disease is common in patients with *OPA1* mutations

P. Yu-Wai-Man,^{1,2} P.G. Griffiths,^{1,2} G.S. Gorman,¹ C.M. Lourenco,³ A.F. Wright,⁴ M. Auer-Grumbach,⁵ A. Toscano,⁶ O. Musumeci,⁶ M.L. Valentino,⁷ L. Caporali,⁷ C. Lamperti,⁸ C.M. Tallaksen,⁹ P. Duffey,¹⁰ J. Miller,¹¹ R.G. Whittaker,¹ M.R. Baker,^{11,12} M.J. Jackson,¹¹ M.P. Clarke,² B. Dhillon,¹³ B. Czermin,¹⁴ J.D. Stewart,¹ G. Hudson,¹ P. Reynier,^{15,16} D. Bonneau,^{15,16} W. Marques Jr,³ G. Lenaers,¹⁷ R. McFarland,¹ R.W. Taylor,¹ D.M. Turnbull,¹ M. Votruba,^{18,19} M. Zeviani,⁸ V. Carelli,⁷ L.A. Bindoff,^{20,21} R. Horvath,^{1,22} P. Amati-Bonneau^{15,16} and P.F. Chinnery^{1,23}

1 Mitochondrial Research Group, Institute for Ageing and Health, The Medical School, Newcastle University, UK

2 Department of Ophthalmology, Royal Victoria Infirmary, Newcastle upon Tyne, UK

3 Neuroscience Department, School of Medicine of Ribeirao Preto, University of Sao Paulo, Brazil

4 MRC Human Genetics Unit, Institute of Genetics and Molecular Medicine, Western General Hospital, Edinburgh, UK

5 Institute of Human Genetics and University Clinic of Internal Medicine, Division of Endocrinology and Nuclear Medicine, Medical University of Graz, Austria

6 Department of Neuroscience, Psychiatry and Anaesthesiology, University of Messina, Messina, Italy

7 Dipartimento di Scienze Neurologiche, Università di Bologna, Bologna, Italy

8 Unit of Molecular Neurogenetics, Pierfranco and Luisa Mariani Center for the Study of Children's Mitochondrial Disorders, National Neurological Institute, Milan, Italy

9 Ullevål Department of Neurology, Oslo University Hospital, Oslo, Norway, UK

10 Department of Neurology, York Hospital, York, UK

11 Department of Neurology, Royal Victoria Infirmary, Newcastle upon Tyne, UK

12 Institute of Neuroscience, The Medical School, Newcastle University, UK

13 Princess Alexandra Eye Pavilion, Edinburgh, UK

14 Medical Genetic Center MGZ, Munich, Germany

15 Département de Biochimie et Génétique, Centre Hospitalier Universitaire d'Angers, Angers, France

16 INSERM U-694, Angers, France

17 INSERM U-583, Institut des Neurosciences de Montpellier, Université de Montpellier I et II, Montpellier, France

18 School of Optometry and Vision Sciences, Cardiff University, Cardiff, UK

19 Cardiff Eye Unit, University Hospital of Wales, Cardiff, UK

20 Department of Clinical Medicine, University of Bergen, Bergen, Norway

21 Department of Neurology, Haukeland University Hospital, Bergen, Norway

22 Department of Neurology, Friedrich-Baur-Institute, Ludwig Maximilians University, Munich, Germany

23 Institute of Human Genetics, Newcastle University, UK

Correspondence to: Professor Patrick Francis Chinnery,
Mitochondrial Research Group,
The Medical School,
Newcastle University,
Newcastle upon Tyne,
NE2 4HH, UK
E-mail: p.f.chinnery@ncl.ac.uk

Received November 11, 2009. Revised December 15, 2009. Accepted December 16, 2009.

© The Author(s) 2010. Published by Oxford University Press on behalf of Brain.

This is an Open Access article distributed under the terms of the Creative Commons Attribution Non-Commercial License (<http://creativecommons.org/licenses/by-nc/2.5>), which permits unrestricted non-commercial use, distribution, and reproduction in any medium, provided the original work is properly cited.

Additional neurological features have recently been described in seven families transmitting pathogenic mutations in *OPA1*, the most common cause of autosomal dominant optic atrophy. However, the frequency of these syndromal 'dominant optic atrophy plus' variants and the extent of neurological involvement have not been established. In this large multi-centre study of 104 patients from 45 independent families, including 60 new cases, we show that extra-ocular neurological complications are common in *OPA1* disease, and affect up to 20% of all mutational carriers. Bilateral sensorineural deafness beginning in late childhood and early adulthood was a prominent manifestation, followed by a combination of ataxia, myopathy, peripheral neuropathy and progressive external ophthalmoplegia from the third decade of life onwards. We also identified novel clinical presentations with spastic paraparesis mimicking hereditary spastic paraplegia, and a multiple sclerosis-like illness. In contrast to initial reports, multi-system neurological disease was associated with all mutational subtypes, although there was an increased risk with missense mutations [odds ratio=3.06, 95% confidence interval=1.44–6.49; $P=0.0027$], and mutations located within the guanosine triphosphate-ase region (odds ratio=2.29, 95% confidence interval=1.08–4.82; $P=0.0271$). Histochemical and molecular characterization of skeletal muscle biopsies revealed the presence of cytochrome *c* oxidase-deficient fibres and multiple mitochondrial DNA deletions in the majority of patients harbouring *OPA1* mutations, even in those with isolated optic nerve involvement. However, the cytochrome *c* oxidase-deficient load was over four times higher in the dominant optic atrophy + group compared to the pure optic neuropathy group, implicating a causal role for these secondary mitochondrial DNA defects in disease pathophysiology. Individuals with dominant optic atrophy plus phenotypes also had significantly worse visual outcomes, and careful surveillance is therefore mandatory to optimize the detection and management of neurological disability in a group of patients who already have significant visual impairment.

Keywords: deletions; dominant optic atrophy; hereditary spastic paraplegia; mitochondrial DNA; multiple sclerosis; *OPA1*

Abbreviations: COX = cytochrome *c* oxidase; DOA = autosomal dominant optic atrophy; DOA+ = dominant optic atrophy plus syndrome; GTP = Guanosine triphosphate; LogMAR = logarithm of the minimum angle of resolution; mtDNA = mitochondrial DNA; PCR = polymerase chain reaction; SDH = succinate dehydrogenase

Introduction

Mitochondria supply most of the cellular adenosine triphosphate (ATP) requirements through oxidative phosphorylation, a process that involves five protein complexes located along the inner mitochondrial membrane. Mitochondrial DNA (mtDNA) codes for 13 of the key structural polypeptides that constitute these multimeric complexes, in addition to two ribosomal RNAs and 22 transfer RNAs which are required for initiating translation and protein synthesis (DiMauro and Schon, 2003; Schapira, 2006). Over the past decade, a growing number of nuclear genetic defects have been identified that disrupt mitochondrial function either by a reduction in mtDNA copy number, and/or the accumulation of secondary mtDNA deletions: *POLG1*, *POLG2*, *PEO1*, *SLC25A4*, *TYMP*, *DGUOK*, *TK2*, *SUCLA2*, *SUCLG1*, *MPV17* and *RRM2B* (Hudson and Chinnery, 2006; Chinnery and Zeviani, 2008; Copeland, 2008). These disorders of mtDNA maintenance constitute an important group of human genetic diseases and they manifest as an array of clinical syndromes ranging from severe infantile encephalomyopathy, hepatic failure and epilepsy, to late-onset ataxia, peripheral neuropathy and myopathy, or isolated progressive external ophthalmoplegia. However, visual failure is rare in this group of patients.

A recent unexpected addition to this list of genes linked to nuclear mitochondrial disorders was *OPA1*, the major causative gene in ~60% of families with autosomal dominant optic atrophy (DOA, OMIM 605290) (Alexander *et al.*, 2000; Delettre *et al.*, 2000; Yu-Wai-Man *et al.*, 2009a). *OPA1* consists of 30 exons spanning 100kb of genomic DNA on the long arm of chromosome 3 (3q28–q29), and the protein product is a 960 amino acid

polypeptide which co-localizes to the inner mitochondrial membrane (Davies and Votruba, 2006). *OPA1* contains a highly conserved functional GTPase domain shared by members of the dynamin superfamily of mechanoenzymes, and it regulates several important cellular processes including the stability of the mitochondrial network via its pro-fusion properties (Chan, 2007), mitochondrial bioenergetic output through a postulated effect on the assembly and stability of complex I and IV subunits (Chevrollier *et al.*, 2008; Zanna *et al.*, 2008), and the sequestration of pro-apoptotic cytochrome *c* molecules within the mitochondrial cristae spaces (Cipolat *et al.*, 2006; Frezza *et al.*, 2006).

DOA is one of the most common inherited optic neuropathies and it classically presents in early childhood with progressive visual failure, with selective retinal ganglion cell loss as its defining pathological characteristic (Newman and Biousse, 2004; Yu-Wai-Man *et al.*, 2009a). However, even in the pre-molecular era, patients with DOA and other clinical manifestations, most commonly sensorineural deafness, ataxia, myopathy and progressive external ophthalmoplegia, were recognized (Hoyt, 1980; Meire *et al.*, 1985). The significance of these syndromal DOA variants was recently highlighted by the identification of cytochrome *c* oxidase (COX)-deficient muscle fibres and multiple mtDNA deletions in skeletal muscle biopsies from these patients, implicating a previously unsuspected role of *OPA1* in mtDNA maintenance (Amati-Bonneau *et al.*, 2008; Hudson *et al.*, 2008; Zeviani, 2008). Although intriguing from a mechanistic perspective, the broader clinical significance of our observations was unclear, given that only seven families had been identified. We therefore conducted a systematic clinical and molecular

study of *OPA1* positive families to establish the frequency of DOA plus syndrome (DOA+) in *OPA1* disease, describe the phenotypic spectrum and the natural history of these additional neuromuscular features, and define any genotype–phenotype correlations.

Materials and methods

Patient cohorts

OPA1 positive families included in this study were identified from the following groups.

- (i) Our initial cohort was assembled as part of an ongoing epidemiological study of inherited optic neuropathies in the North of England. *OPA1* screening was performed on probands with a clinical diagnosis of DOA where previous investigations had excluded other compressive, inflammatory and infiltrative causes for their bilateral optic atrophy. Additional family members were examined both during the initial diagnostic work up of the proband, and at the time of active contact tracing following the identification of a pathogenic *OPA1* mutation.
- (ii) The relatively high prevalence of DOA+ phenotypes among patients with *OPA1* mutations in the North of England prompted us to extend our original study to other diagnostic and research centres with an interest in neuro-ophthalmological disorders. DNA samples were analysed for patients with a high suspicion of an underlying mitochondrial genetic disease due to the multi-system pattern of their clinical presentations, evidence of a mitochondrial biochemical defect, and/or the presence of multiple mtDNA deletions. Visual failure was a prominent feature of their phenotypes and when initial screens for *POLG1*, *POLG2*, *PEO1* and *SLC25A4* were found to be negative, *OPA1* sequencing was performed.

In addition, we conducted a systematic review of the literature to identify other DOA+ families with confirmed *OPA1* mutations. These published data were included in our final analysis to provide a definitive description of the visual prognosis and genotype–phenotype associations seen in DOA+.

Phenotypic evaluation

All patients harbouring pathogenic *OPA1* mutations were comprehensively assessed by a team of experienced ophthalmologists and neurologists to define both the extent and the severity of their ocular and neuromuscular deficits. A complete orthoptic assessment was performed to document any abnormalities of ocular motility, supplemented by formal eye-movement recordings where appropriate. Ancillary investigations including visual electrophysiology, peripheral nerve conduction studies, electromyography, electroencephalography, audiometry and neuroimaging were also performed as dictated by the patient's symptoms and the familial phenotype to confirm possible cases of non-penetrance.

Best corrected visual acuity was measured using the Snellen chart and for the purpose of statistical analysis, Snellen ratios were converted to LogMAR (logarithm of the minimum angle of resolution) decimal values.

A LogMAR value of 0 is equivalent to 6/6 Snellen vision and a value of 1.0 is equivalent to 6/60 Snellen vision, the largest optotype on standard Snellen charts. Patients with visual acuities reduced to counting fingers were assigned a LogMAR value of 2.0, whilst those with only hand movement perception were given a LogMAR value of 2.3 (Schulze-Bonsel *et al.*, 2006; Lange *et al.*, 2009).

Identification of *OPA1* mutations

The entire *OPA1*-coding region and flanking exon–intron boundaries were amplified by the polymerase chain reaction (PCR) and sequenced with BigDye™ terminator cycle chemistries on an appropriate genetic analyser (Primers and cycling conditions are available on request). Sequence chromatograms were compared with the Genbank *OPA1* reference sequence (Accession number AB011139) and all genetic variants were confirmed by reverse sequencing. Novel *OPA1* mutations not reported on the e*OPA1* database (<http://lbbma.univ-angers.fr/eOPA1/>) were screened in a panel of 150–300 age-matched controls using (i) a multiplex primer extension assay and product analysis with matrix-associated laser desorption/ionization time of flight mass spectrometry (MALDI-TOF) (Sequenom, San Diego, CA); or (ii) BigDye™ sequencing of the relevant PCR-amplified *OPA1* fragments (Stewart *et al.*, 2008).

Reverse-transcriptase PCR

Total RNA was extracted from blood samples with Trizol™ reagent (Invitrogen, Groningen, The Netherlands), and complementary DNA was obtained using SuperScript™ RNA polymerase and poly-T as the primer (Invitrogen, Cergy Pontoise, France). PCR was performed with the following primer pair: (i) forward 5'-ACG CAA GAT CAT CTG CCA CGG-3'; and (ii) reverse 5'-CCT GCT TGG ACT GGC TAC A-3', to amplify a 597bp fragment overlapping *OPA1* exons 9–14 (Amati-Bonneau *et al.*, 2004). The generated products were analysed on a 1% agarose gel and sequenced with BigDye™ terminator cycle chemistries.

Mitochondrial histochemistry

Skeletal muscle biopsies collected from 34 *OPA1* mutation carriers were snap frozen in melting liquid isopentane (−150°C) and then stored at −80°C. The blocks were serially sectioned on a cryostat before being stained for COX, succinate dehydrogenase (SDH) and sequential COX–SDH activities, using standard histochemical protocols (Johnson and Barron, 1996). The proportion of muscle fibres exhibiting a mitochondrial oxidative phosphorylation defect can be accurately quantified, as normal COX-positive fibres stain brown; whereas COX-negative fibres are highlighted blue as a result of impaired complex IV activity. The histochemical findings in our DOA+ cohort were compared with an age-matched control group of 20 skeletal muscle biopsies from healthy subjects (mean age=51.1 years, SD=10.7 years, $P=0.4334$) (Brierley *et al.*, 1996).

Mitochondrial DNA deletion and depletion assays

Multiple mtDNA deletions in homogenate skeletal muscle DNA were identified by Southern blot and/or long-range PCR (Amati-Bonneau *et al.*, 2008; Hudson *et al.*, 2008). mtDNA copy number was determined using a well-established iQ SYBR Green protocol on the MyiQ™ real-time PCR detection system (Biorad, USA), with *MTND1* as the mtDNA reference gene and *GAPDH* as the nuclear DNA

reference gene (Pyle *et al.*, 2007; Cree *et al.*, 2008). Both assays were optimized and confirmed to be linear over an appropriate concentration range by the standard curve method, and all measurements were done in triplicate. The relative mtDNA copy number was derived using the $2^{(-\Delta Ct)}$ equation, where ΔCt was the difference in threshold cycle value (Ct) between *MTND1* and *GAPDH*, and accounting for two copies of *GAPDH* per cell nucleus. mtDNA copy number in skeletal muscle homogenate samples was also determined for a group of age-matched healthy controls (mean age=43.1 years, SD=20.1 years, $n=20$, $P=0.1300$), and paediatric patients with known mtDNA depletion syndromes (mean age=3.3 years, SD=2.7 years, $n=6$, $P<0.0001$).

Statistical analysis

Statistical analysis was performed using GraphPad™ v.4 statistical software (San Diego, CA). Fisher's exact test and an independent sample *t*-test were used for group comparisons, as required. Prevalence figures were derived from the mid-2008 census data for the North of England, and 95% CIs were calculated using Poisson distribution variables for small numbers (Bland, 2000).

Results

OPA1 cohorts

The epidemiological study identified *OPA1* mutations in 14 genetically distinct *OPA1* families, and a total of 64 affected family members were living in the North of England. Their mean age was 39.5 years (SD=17.8 years, range 6.0–78.0 years), with a male to female ratio of 1.06:1, and DOA+ clinical features were present in 11 out of 64 patients (17.2%) from 6 out of 14 (42.9%) families. In collaboration with other clinical centres, 49 additional DOA+ patients from 21 families harbouring *OPA1* mutations were also found: British, $n=8$; French, $n=5$; Italian, $n=3$; German, $n=2$; Norwegian, $n=1$; Austrian, $n=1$; and Brazilian, $n=1$ (mean age=44.9 years, SD=18.4 years). A systematic review of the literature revealed 18 published *OPA1* positive families segregating a DOA+ phenotype and clinical information was available for 44 affected individuals (mean age=43.5 years, SD=17.0 years, Table 1).

OPA1 mutations in DOA+

A total of 33 different *OPA1* mutations were identified in these 45 independent DOA+ families: missense ($n=18$, 54.5%), nonsense ($n=2$, 6.1%), splice site ($n=8$, 24.2%), and deletion ($n=5$, 15.2%) (Table 1, Fig. 1). A majority of these were located in the GTPase regions ($n=19$, 57.6%), with a small cluster in the dynamin domain ($n=4$, 12.1%). We compared our findings to the e*OPA1* database (<http://lbbma.univ-angers.fr/lbbma.php?id=9>), which currently lists 205 different *OPA1* mutations, all of which have been reported in patients with non-syndromal pure DOA. There was a higher risk of developing a DOA+ phenotype with missense mutations (OR=3.06, 95% CI=1.44–6.49, $P=0.0027$), and mutations located in the GTPase region (OR=2.29, 95% CI=1.08–4.82, $P=0.0271$) (Table 2). The risk of this occurring

was significantly lower with mutations within the dynamin gene domain (OR=0.28, 95% CI=0.10–0.84. $P=0.0159$) (Table 2).

We identified 9 novel *OPA1* variants which were not found in 150–300 age- and ethnically-matched control subjects: (i) c.344C>T (p.A115V) in exon 2; (ii) c.768C>G (p.S256R) in exon 5b; (iii) c.728T>A (p.L243X) in exon 7; (iv) c.854A>G (p.Q285R) in exon 8; (v) c.1071A>G (p.A358A) in exon 11; (vi) c.1327G>A (p.A443T) in exon 14; (vii) c.1462G>A (p.G488R) in exon 15; (viii) c.1484C>T (p.A495V) in exon 15; and (ix) c.1642G>A (p.V548I) in exon 17 (Supplementary Fig. 1). With complementary DNA analysis, in-frame skipping of exon 12, with the loss of 24 amino acids (p.T381-N404del), was demonstrated for the c.1071A>G (p.A358A) synonymous substitution. In two German siblings (DE-1), both the c.635_636del (amino acid) deletion (p.K212fsX4) in exon 6 and the c.1642G>A (p.V548I) missense mutation in exon 17 were present. In the absence of additional clinical information and DNA samples from other family members, it was not possible to determine whether these variants were present on the same allele or were compound heterozygous. A 60-year-old Norwegian proband (NO-1) was compound heterozygous for the c.768C>G (p.S256R) missense mutation in exon 5b and the c.854A>G (p.Q285R) missense mutation in exon 8 (Table 1), and these two variants were also identified in his 64-year-old, similarly affected, sister. Both their parents, who are no longer alive, were apparently healthy, and the proband's two daughters, who are not visually symptomatic, only harboured the c.768C>G substitution in exon 5b. Haplotype analysis confirmed that the proband and his affected sister were compound heterozygous for the c.768C>G (p.S256R) and the c.854A>G (p.Q285R) mutations.

Major clinical features

Optic nerve dysfunction was present in 89/104 (85.6%) patients with DOA+ features in our cohort (Table 3). In two, large, three-generational families with autosomal dominant progressive external ophthalmoplegia (IT-1 and IT-3), the penetrance of visual failure was low (2/13, 15.4%), and if these are excluded, only four of the remaining 91 cases (4.4%) were visually asymptomatic with normal optic nerve parameters. Visual acuity data were available for 66 patients and they were compared with 42 patients from the same families, but with only isolated optic nerve involvement. The mean age of onset of visual loss was 8.2 years (SD=0.9 years) for the pure DOA group, and 7.7 years (SD=0.9 years) for the DOA+ group. This difference was not statistically significant ($P=0.7255$) and the majority of individuals in both groups (~95%) were symptomatic by the age of 15 years (Fig. 2A). At the time of their last ophthalmological assessment, the mean visual acuity was 0.87 LogMAR (6/44 Snellen) for patients with pure DOA, and 1.07 LogMAR (6/70 Snellen) for those with DOA+ phenotypes, this difference being statistically significant ($P=0.0170$) (Fig. 2B).

The second most common feature documented in DOA+ patients was deafness (65/104, 62.5%) which invariably followed the onset of visual failure with a peak age of onset in the second and third decades of life (Table 3). Pure-tone threshold audiometry was performed in 58 out of 65 cases and confirmed

Table 1 Clinical and molecular characteristics of patients with DOA+ phenotypes

Pedigree	Age (years)	Sex	FH _x	Clinical features						OPA1 mutations				
				Optic atrophy	Deafness	Ataxia	Myopathy	Neuropathy	PEO	Others	Complementary DNA	Amino acid change	Domain	
UK-1	54	M	+	+	+							c.1212 + 3a>t	–	–
UK-2	36	F	+	+			+				Migraine	c.870 + 5g>a	–	–
UK-2	55	F	+	+			+				Migraine	c.870 + 5g>a	–	–
UK-3	59	M	+	+				+			HSP Migraine	c.876–878del(TGT)	p.V294fsX667	–
UK-3	75 ^a	M	+	+							HSP	c.876–878del(TGT)	p.V294fsX667	–
UK-4	44	M		+	+					+		c.1198C>T	p.P400S	GTPase
UK-5	48	F	+	+				+			HSP	c.889C>T	p.Q297X	–
UK-5	21	M	+	+							HSP	c.889C>T	p.Q297X	–
UK-6	58	F	+	+		+					MS	c.2613 + 1g>a	–	–
UK-7	46	F		+						+		c.2708_2711del(TTAG)	p.V903fsX3	–
UK-8	44	F	+	+		+					Diabetes	c.32 + 1g>a	–	–
UK-8	53	M	+	+							Diabetes	c.32 + 1g>a	–	–
UK-9	15	M	+	+			+		+			c.1212 + 1G>A	–	–
UK-10	42	F	+	+	+							c.1202G>A	p.G401D	GTPase
UK-11	70 ^a	F	+	+	+	+			+	+		c.1635C>G	p.S545R	Dynamin
UK-11	64	F	+	+	+	+	+		+	+	Diabetes	c.1635C>G	p.S545R	Dynamin
UK-11	42	M	+	+		+				+		c.1635C>G	p.S545R	Dynamin
UK-11	38	F	+	+	+	+	+		+	+	Migraine	c.1635C>G	p.S545R	Dynamin
UK-11	30	M	+	+		+	+		+	+		c.1635C>G	p.S545R	Dynamin
UK-12	43	M	+	+		+	+		+	+		c.1294A>G	p.I432V	GTPase
UK-12	44	F	+	+		+	+		+	+		c.1294A>G	p.I432V	GTPase
UK-12	69	F	+							+		c.1294A>G	p.I432V	GTPase
UK-13	43	M		+	+		+			+		c.1334G>A	p.R445H	GTPase
UK-14	44	F	+	+	+				+	+		c.1334G>A	p.R445H	GTPase
UK-14	42	F	+	+	+	+				+		c.1334G>A	p.R445H	GTPase
UK-14	73	M	+	+	+	+			+	+		c.1334G>A	p.R445H	GTPase
AU-1	35	F	+	+	+	+			+	+		c.1635C>G	p.S545R	Dynamin
AU-1	34	F	+	+	+	+			+	+		c.1635C>G	p.S545R	Dynamin
AU-1	61	F	+	+		+				+		c.1635C>G	p.S545R	Dynamin
BE-1	72	F	+	+	+					+		c.1334G>A	p.R445H	GTPase
BE-1	59	F	+	+	+					+		c.1334G>A	p.R445H	GTPase
BE-1	29	F	+	+	+					+		c.1334G>A	p.R445H	GTPase
BE-1	25	F	+	+	+					+		c.1334G>A	p.R445H	GTPase
BR-1	9	M	+	+	+	+					CAPOS	c.1327G>A	p.A443T	GTPase
CN-1	46	F	+	+	+							c.1334G>A	p.R445H	GTPase
CN-1	22	F	+	+	+							c.1334G>A	p.R445H	GTPase
CN-2	34	F	+	+	+							c.1202G>A	p.G401D	GTPase
CN-2	36	M	+	+	+							c.1202G>A	p.G401D	GTPase
CN-2	33	M	+	+	+							c.1202G>A	p.G401D	GTPase
CN-2	29	F	+	+	+							c.1202G>A	p.G401D	GTPase
CN-3	61	F	+	+	+							c.2848_2849del(GA)	p.D950fsX4	–
CN-3	55	M	+	+	+							c.2848_2849del(GA)	p.D950fsX4	–
CN-3	37	M	+	+	+							c.2848_2849del(GA)	p.D950fsX4	–
CN-3	24	M	+	+	+							c.2848_2849del(GA)	p.D950fsX4	–
DE-1	14	F	+	+	+							c.635_636del(AA)	p.K212fsX4	–
DE-1	13	F	+	+	+							c.1642G>A	p.V548I	Dynamin
DE-1	13	F	+	+	+							c.635_636del(AA)	p.K212fsX4	–
DE-1	13	F	+	+	+							c.1642G>A	p.V548I	Dynamin
DE-2	11	M	+	+	+							c.1313A>T	p.D438V	GTPase
ES-1	57	F	+	+	+		+		+	+	Dementia	c.1334G>A	p.R445H	GTPase
ES-1	30	F	+	+	+							c.1334G>A	p.R445H	GTPase
FI-1		F	+	+	+							c.970_978del(9)	p.R324_P326del	–
FR-1	30	M	+	+	+	+	+		+	+		c.1635C>G	p.S545R	Dynamin
FR-2	35	F	+	+	+	+						c.1334G>A	p.R445H	GTPase
FR-3	14	M	^b	+	+							c.1334G>A	p.R445H	GTPase
FR-4	39	M	+	+	+	+			+			c.728T>A	p.L243X	–
FR-5	53	M		+							Epilepsy	c.1071A>G	p.A358A ^c	–
FR-6	12	F		+	+							c.1334G>A	p.R445H	GTPase

(continued)

Table 1. Continued

Pedigree	Age (years)	Sex	FH _x	Clinical features							OPA1 mutations			
				Optic atrophy	Deafness	Ataxia	Myopathy	Neuropathy	PEO	Others	Complementary DNA	Amino acid change	Domain	
FR-7	20	M	+	+								c.1334G>A	p.R445H	GTPase
FR-8	38	F	+	+	+							c.1334G>A	p.R445H	GTPase
FR-9	43	M	+	+	+	+	+	+	+			c.1635C>G	p.S545R	Dynamin
FR-10	67	M	+	+		+	+	+	+			c.1069G>A	p.A357T	GTPase
FR-11	44	M		+						MS		c.1937C>T	p.S646L	Dynamin
IT-1	64	F	+			+	+	+	+			c.1462G>A	p.G488R	GTPase
IT-1	64 ^a	M	+		+	+	+	+	+	Dementia		c.1462 A>G	p.G488R	GTPase
IT-1	36 ^a	M			+		+		+	Migraine, epilepsy		c.1462 A>G	p.G488R	GTPase
IT-1	72	F	+		+	+	+	+	+			c.1462 A>G	p.G488R	GTPase
IT-1	69	M	+		+	+	+	+	+	Migraine		c.1462 A>G	p.G488R	GTPase
IT-1	46	F	+				+		+			c.1462 A>G	p.G488R	GTPase
IT-1	44	M	+				+		+			c.1462 A>G	p.G488R	GTPase
IT-1	53	M	+	+			+					c.1462 A>G	p.G488R	GTPase
IT-2	12	F		+		+		+				c.344C>T	p.A115V	Basic
IT-3	69	M	+		+		+	+	+			c.1484C>T	p.A495V	GTPase
IT-3	60	M	+				+		+			c.1484C>T	p.A495V	GTPase
IT-3	62	M	+				+		+			c.1484C>T	p.A495V	GTPase
IT-3	39	F	+				+		+			c.1484C>T	p.A495V	GTPase
IT-3	68	M	+	+				+				c.1484C>T	p.A495V	GTPase
IT-4	38	M	+	+	+	+	+	+	+			c.1316G>T	p.G439V	GTPase
IT-4	6	F	+	+	+							c.1316G>T	p.G439V	GTPase
IT-5	59	M	+	+			+					c.2729T>A	p.V910D	GE
IT-5	53	M	+	+			+					c.2729T>A	p.V910D	GE
IT-6	47	F	+	+				+				c1410_1443 + 4del(38)	p.D470fsX13	-
IT-6	46	F	+	+				+				c1410_1443 + 4del(38)	p.D470fsX13	-
IT-7	42	M	+	+	+	+	+	+	+			c.1745A>G	p.Y582C	Dynamin
NO-1	60	M	+	+		+	+	+		Spasticity		c.768C>G	p.S256R	CC
												c.854A>G	p.Q285R	GTPase
NO-1	64	F	+	+		+	+	+		Spasticity		c.768C>G	p.S256R	CC
												c.854A>G	p.Q285R	GTPase
NO-1	43	F	+									c.768C>G	p.S256R	CC
NO-1	35	F	+									c.768C>G	p.S256R	CC
US-1	71	M	+	+	+				+			c.1334G>A	p.R445H	GTPase
US-1	68	F	+	+	+				+			c.1334G>A	p.R445H	GTPase
US-1	64	M	+	+	+				+			c.1334G>A	p.R445H	GTPase
US-1	56	M	+	+	+				+			c.1334G>A	p.R445H	GTPase
US-1	77	F	+	+	+				+			c.1334G>A	p.R445H	GTPase
US-1	64	F	+	+	+				+			c.1334G>A	p.R445H	GTPase
US-1	49	F	+	+					+			c.1334G>A	p.R445H	GTPase
US-1	45	F	+	+	+				+			c.1334G>A	p.R445H	GTPase
US-1	38	M	+	+	+				+			c.1334G>A	p.R445H	GTPase
US-1	42	M	+	+	+				+			c.1334G>A	p.R445H	GTPase
US-1	43	F	+	+	+				+			c.1334G>A	p.R445H	GTPase
US-1	51	F	+	+	+				+			c.1334G>A	p.R445H	GTPase
US-1	26	F	+	+	+				+			c.1334G>A	p.R445H	GTPase
US-1	19	F	+	+	+				+			c.1334G>A	p.R445H	GTPase
US-2	48	F		+		+			+			c113_130del(18)	p.R38_S43del	-

AU = Austria; BE = Belgium; BR = Brazil; CN = China; DE = Germany; ES = Spain; FI = Finland; FR = France; IT = Italy; NO = Norway; UK = United Kingdom; US = USA; AA = amino acid; FH_x = family history; HSP = hereditary spastic paraplegia; MS = multiple sclerosis-like illness; CAPOS = cerebellar ataxia, areflexia, pes cavus, optic atrophy and sensorineural hearing loss; CC = coiled-coil domain; GE = GTPase effector domain; PEO = progressive external ophthalmoplegia.

^aAge of death.

^bDe novo OPA1 mutation.

^cIn-frame skipping of exon 12 (p.T381-N404del).

BE-1: (Meire *et al.*, 1985; Payne *et al.*, 2004); CN-1: (Li *et al.*, 2005); CN-2: (Ke *et al.*, 2006); CN-3: (Chen *et al.*, 2007); ES-1: (Amati-Bonneau *et al.*, 2005); FI-1: (Puomila *et al.*, 2005); FR-6, FR-7, FR-8: (Amati-Bonneau *et al.*, 2005); FR-9, FR-10: (Amati-Bonneau *et al.*, 2008); IT-4: (Amati-Bonneau *et al.*, 2008; Liguori *et al.*, 2008); IT-5: (Amati-Bonneau *et al.*, 2008); IT-6: (Spinazzi *et al.*, 2008); IT-7: (Ferraris *et al.*, 2008); UK-11: (Hudson *et al.*, 2008); UK-12, UK-13, UK-14: (Stewart *et al.*, 2008); US-1: (Payne *et al.*, 2004); US-2: (Milone *et al.*, 2009).

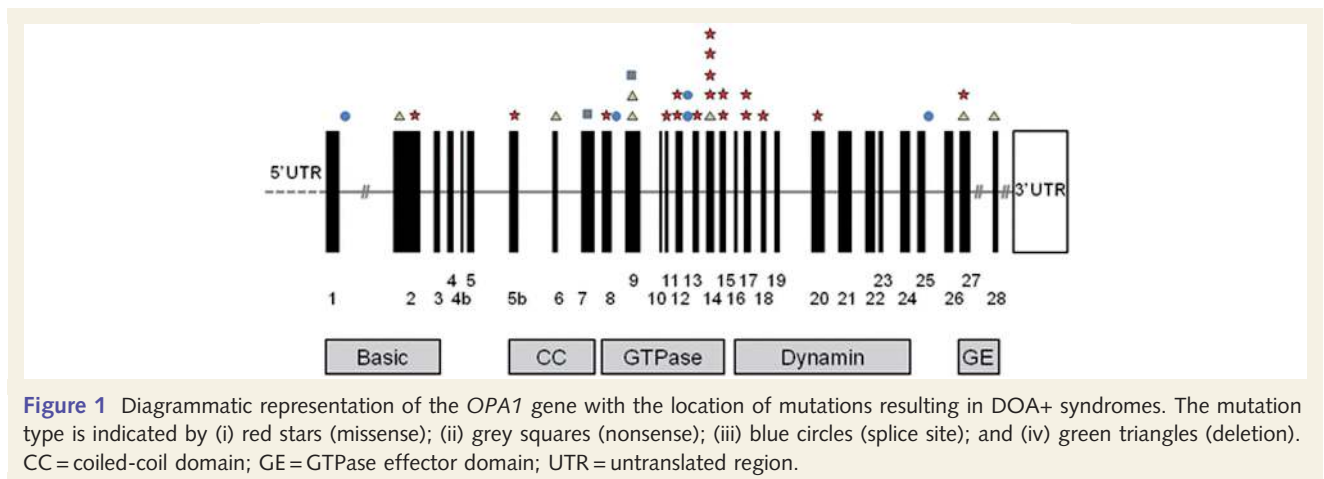


Figure 1 Diagrammatic representation of the *OPA1* gene with the location of mutations resulting in DOA+ syndromes. The mutation type is indicated by (i) red stars (missense); (ii) grey squares (nonsense); (iii) blue circles (splice site); and (iv) green triangles (deletion). CC = coiled-coil domain; GE = GTPase effector domain; UTR = untranslated region.

Table 2 Odd ratios for developing a DOA+ phenotype based upon *OPA1* mutation type and domain

OPA1 mutations		eOPA1 ^a	This study ^b	OR	95% CI	P-value
Type (n)	Missense	55	18	3.06	1.44–6.49	0.0027*
	Nonsense	34	2	0.31	0.07–1.34	0.0975
	Splice	55	8	0.81	0.35–1.92	0.6378
	Deletion	51	5	0.50	0.18–1.38	0.1745
Domain (n)	GTPase	76	19	2.29	1.08–4.82	0.0271*
	Dynamamin	67	4	0.28	0.10–0.84	0.0159*
	Others	61	10	1.02	0.46–2.27	0.9628

CI = confidence interval, OR = odds ratio.

^aeOPA1 online database (<http://lbbma.univ-angers.fr/lbbma.php?id=9>).

^bMeta-analysis of 33 *OPA1* mutations which includes nine previously published *OPA1* mutations. * = Significant P-value.

Table 3 Major clinical features observed in DOA+ patients

Clinical features ^a	n	%	95% CI	
			Lower	Upper
Optic atrophy	89/104	85.6	77.5	91.2
Deafness	65/104	62.5	52.9	71.2
Ataxia	31/104	29.8	21.8	39.2
Neuropathy	31/104	29.8	21.8	39.2
Myopathy	37/104	35.6	27.0	45.2
Progressive external ophthalmoplegia	48/104	46.2	36.9	55.7

CI = confidence interval.

^aMeta-analysis of 104 *OPA1* mutation carriers from 45 DOA+ families, which includes previously published data on 44 individuals from 18 DOA+ families.

sensorineural hearing impairment. Of those individuals who suffered from hearing loss, 39 out of 65 (60.0%) also developed significant neuromuscular deficits in later life, and these were a combination of progressive external ophthalmoplegia (48/104, 46.2%), proximal myopathy (37/104, 35.6%), ataxia (31/104, 29.8%), and axonal sensory and/or motor neuropathy (31/104,

29.8%). These additional features became manifest from the third decade of life onwards, with on average a slightly later age of onset for progressive external ophthalmoplegia. Subclinical nerve conduction abnormalities were detected in two of the 31 individuals who were investigated further because of their strong familial phenotype, and neurophysiological studies were normal in nine patients with symptoms suggestive of a possible neuropathic component.

Novel presentations

Spastic paraplegia

In two families with clinically presumed autosomal dominant hereditary spastic paraplegia (HSP), pathogenic *OPA1* mutations were identified segregating with both optic atrophy and spastic paraparesis: (i) a 3-bp in-frame deletion c.876-878del(TGT) in exon 9 (p.V294fsX667) (UK-3); and (ii) a nonsense GTPase mutation c.889C>T in exon 9 (p.Q297X) (UK-5), which are predicted to result in premature termination codons. Prior to *OPA1* screening, the probands were extensively investigated to establish

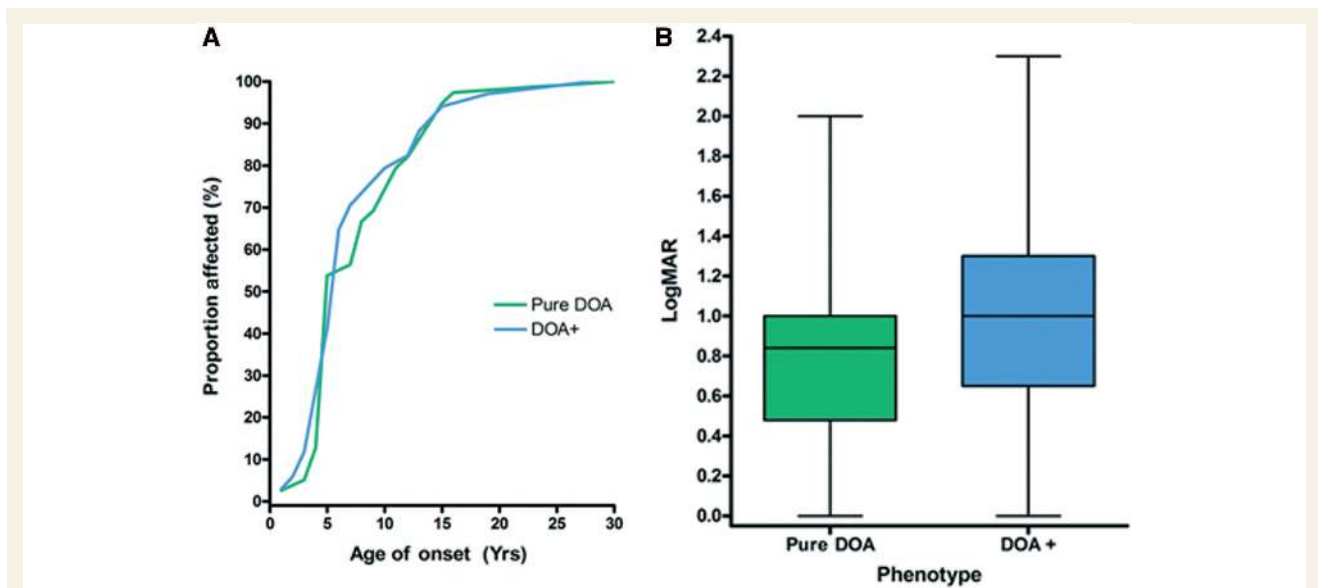


Figure 2 (A) Cumulative distribution curve of age on onset of visual failure in pure DOA and DOA+, and (B) comparison of mean LogMAR visual acuity between patients with pure DOA and DOA+ features ($P=0.0170$). The whiskers represent the minimum and maximum LogMAR values, the ends of the boxes are the upper and lower quartiles, the vertical length of the boxes indicate the interquartile range, and the line within the boxes represent the median LogMAR values for each group.

the underlying cause for their spasticity, and these were all negative: cerebrospinal fluid (CSF) studies, metabolic screen, brain and spinal cord MRI, and *SPG4* genetic testing. In family UK-3, the proband was a 59-year-old man who first presented to a neurologist when he was 46-years-old with marked lower limb spasticity, in addition to complicated migraine and poor vision (counting fingers, both eyes), which was noted at the time of preschool vision screening. His spastic paraplegia has gradually worsened over the years and he had more recently developed an axonal sensorimotor neuropathy. His maternal uncle who died at the age of 75-years-old was similarly affected but both of the proband's two sons have isolated optic atrophy and no subjective problems with their legs. In family UK-5, the proband was a 48-year-old woman with progressive gait and balance difficulties going back to her mid-thirties and severe visual failure from early childhood (counting fingers, both eyes). Her neuro-ophthalmological investigations confirmed bilateral total optic atrophy, lower limb spasticity with spontaneous ankle clonus, and a predominantly axonal sensory neuropathy on nerve conduction studies. Her 21-year-old son was a mutational carrier and although visually asymptomatic (6/6, both eyes), he had subtle temporal disc pallor and lower limb spasticity which had previously been ascribed to cerebral palsy. His 26-year-old sister also had evidence of mild optic nerve involvement (6/9, both eyes) but her neurological examination was otherwise normal.

Multiple sclerosis-like illness

A 58-year-old woman was referred by her optometrist following a routine eye test with suspected bilateral optic atrophy (UK-6). She had no visual complaints (6/9, both eyes) but on examination her colour vision was severely reduced, with bilateral small caeco-central scotomas on Goldmann field perimetry. She had

mild gait ataxia and a comprehensive neurological assessment revealed periventricular white matter lesions on MRI, and unmatched oligoclonal bands in her CSF, both supportive of an underlying demyelinating process clinically indistinguishable from multiple sclerosis (Fig. 3). Two of her brothers, aged 61 and 63 years old, had previously been investigated for poor vision and a label of Leber hereditary optic neuropathy was given, even though a screen for the three primary Leber hereditary optic neuropathy mtDNA point mutations (m.3460G>A, m.11778G>A and m.14484T>C) was negative. The family history was also consistent with an autosomal dominant pattern of inheritance and this prompted *OPA1* genetic screening, which uncovered a c.2613+1g>a splice-site mutation within intron 25 segregating with affected disease status in both the proband and her two brothers.

Additional clinical features

Late-onset non-insulin dependent diabetes developed in 3 of the 83 (3.6%) DOA+ patients and this was associated with deafness in one case. Recurrent migrainous-type headaches were also reported by 4 of the 83 (4.8%) patients in our DOA+ cohort: (i) a 36-year-old woman with the c.870+5g>a mutation (UK-2); (ii) her 54-year-old sister who also carried the c.870+5g>a mutation; (iii) a 59-year-old man with the c.876_878del(TGT) deletion (UK-3); and (iv) a 38-year-old woman with the c.1635C>G mutation (UK-11). The onset was in their mid to late teens, three of the four (75.0%) described a prodromal phase characterized by positive visual phenomena and photophobia, and all four of them experienced a stereotypical pattern characterized by severe fronto-temporal headaches associated with nausea and vomiting. Additional complicated features included

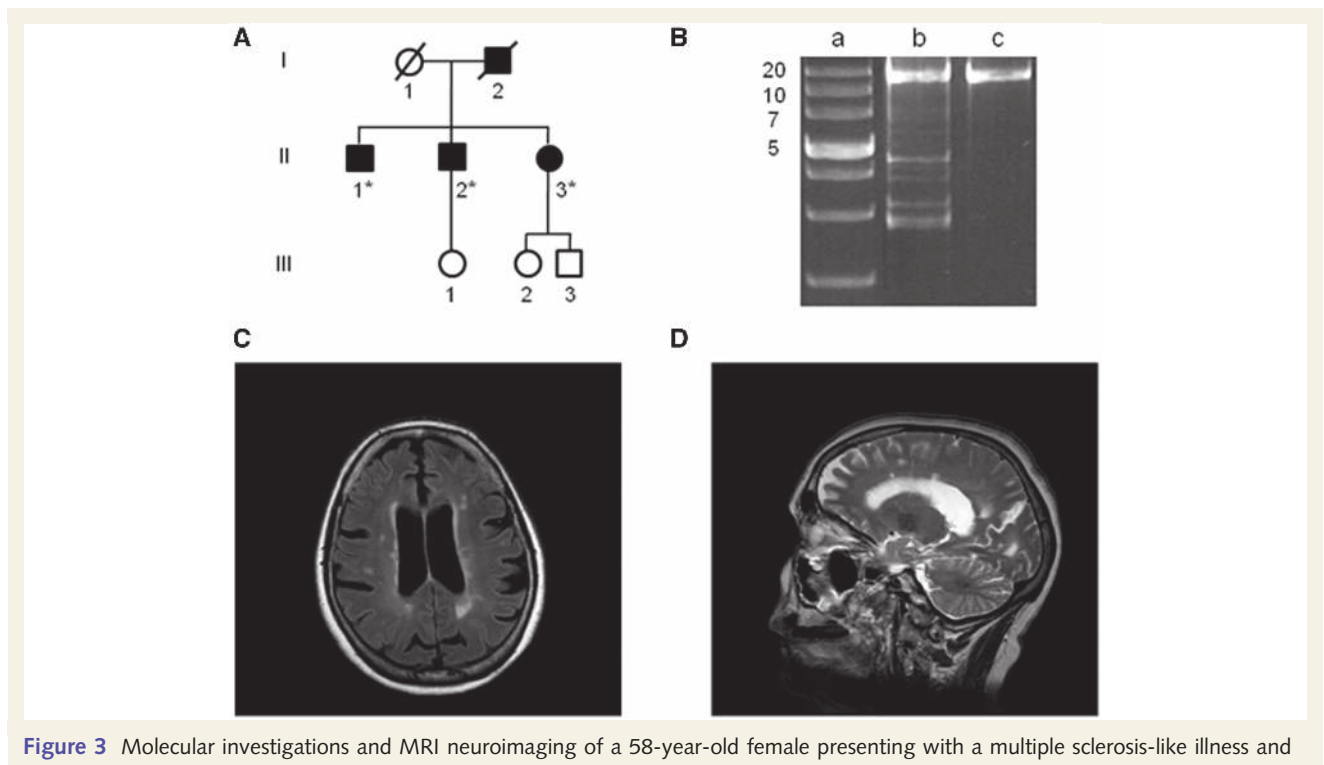


Figure 3 Molecular investigations and MRI neuroimaging of a 58-year-old female presenting with a multiple sclerosis-like illness and harbouring a c.2613 + 1g>a splice-site mutation within intron 25 of the *OPA1* gene (UK-6). (A) Family tree of the affected proband (II-3). DNA samples were obtained from her 62-year-old (II-1) and 59-year-old (II-2) brothers, who both had a pure DOA phenotype, and *OPA1* sequencing confirmed the presence of the same heterozygous c.2613 + 1g>a variant. The asterisk indicates family members where DNA samples were available for molecular analysis. (B) A 16 kb long-range PCR assay was performed on homogenate DNA extracted from the patient's skeletal muscle biopsy, and multiple deletion bands were identified. Lane a: 1 kb DNA ladder with the adjacent numbers indicating the size of the band; lane b: patient; lane c: wild-type control. (C) Axial T₂-weighted fluid attenuated inversion recovery and (D) sagittal T₂-weighted turbo spin echo slices showing cortical atrophy and characteristic white matter lesions in the periventricular areas and more peripherally near to grey matter.

dysphasia, evolving visual scotomas, and a transient confusional state after the headache had subsided.

Neuroimaging and metabolic findings

Neuroimaging abnormalities were identified in 12 of the 40 (30.0%) DOA+ patients: (i) bilateral basal ganglia calcifications ($n=2$, 5.0%); (ii) periventricular multiple sclerosis-like lesions ($n=2$, 5.0%); (iii) non-specific white matter lesions ($n=4$, 10.0%); and (iv) varying degrees of cortical and cerebellar atrophy ($n=5$, 12.5%). Brain magnetic resonance spectroscopy was performed on a 43-year-old man with a complex DOA+ phenotype due to a c.1635C>G mutation in exon 17 (FR-9). His MRI scan showed mild cortical and cerebellar atrophy, but both *n*-acetyl-aspartate and lactate peaks were not altered on his magnetic resonance spectroscopy spectra. CSF analysis performed on 29 DOA+ patients was unremarkable, except for the two patients with periventricular white matter lesions (UK-6 and FR-11), who both had unmatched oligoclonal bands. There was no evidence of marked metabolic derangement in our patient cohort. Plasma lactate levels were elevated in only five patients, and no abnormal organic acids profile was reported in the subgroup of patients with ataxia and spastic paraplegia.

Histochemical studies

Dual COX–SDH staining was performed on skeletal muscle biopsies from 10 patients with pure DOA (mean age=49.3 years, SD=9.6 years, range=39.0–65.0 years) and 24 patients with DOA+ phenotypes (mean age=50.6 years, SD=11.0 years, range=24.0–69.0 years), and there was no significant age difference between these two groups ($P=0.7354$). Published muscle biopsy data from an additional four patients with features of DOA+ were also included in the meta-analysis (Ferraris *et al.*, 2008; Spinazzi *et al.*, 2008; Milone *et al.*, 2009). The frequency of COX-deficient muscle fibres in the pure DOA group (mean=1.30%, SD=1.20%, range=0–3.00%) was significantly lower than in the DOA+ group (mean=5.41%, SD=5.90%, range=0–21.18%, $P=0.0226$, Fig. 4A). However, COX-deficient fibres were significantly more frequent in both pure DOA ($P<0.0001$) and DOA+ patients ($P<0.0001$), compared to controls (mean=0.03%, SD=0.07%, range=0–0.30%, Fig. 4B).

Mitochondrial DNA analysis

There was clear evidence of multiple mtDNA deletions in skeletal muscle in the majority of patients with both pure DOA

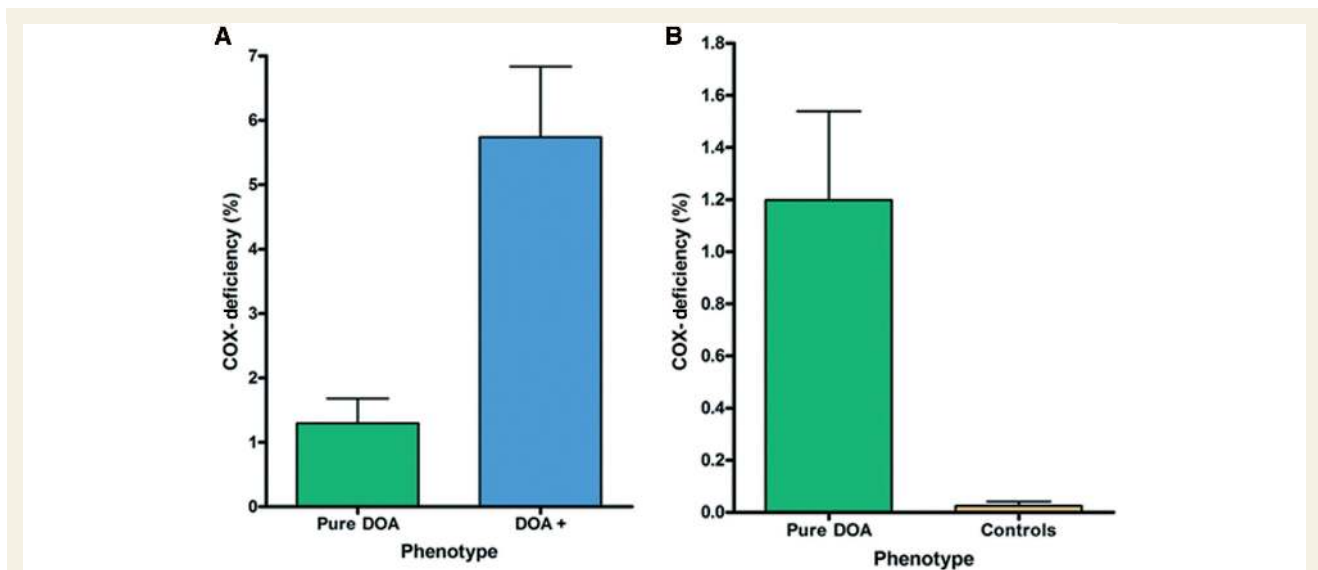


Figure 4 Mean level of COX-deficiency in skeletal muscle biopsies: (A) pure DOA versus DOA+ phenotypes ($P=0.0226$) and (B) pure DOA versus age-matched controls ($P<0.0001$). The error bars represent the standard error of the mean.

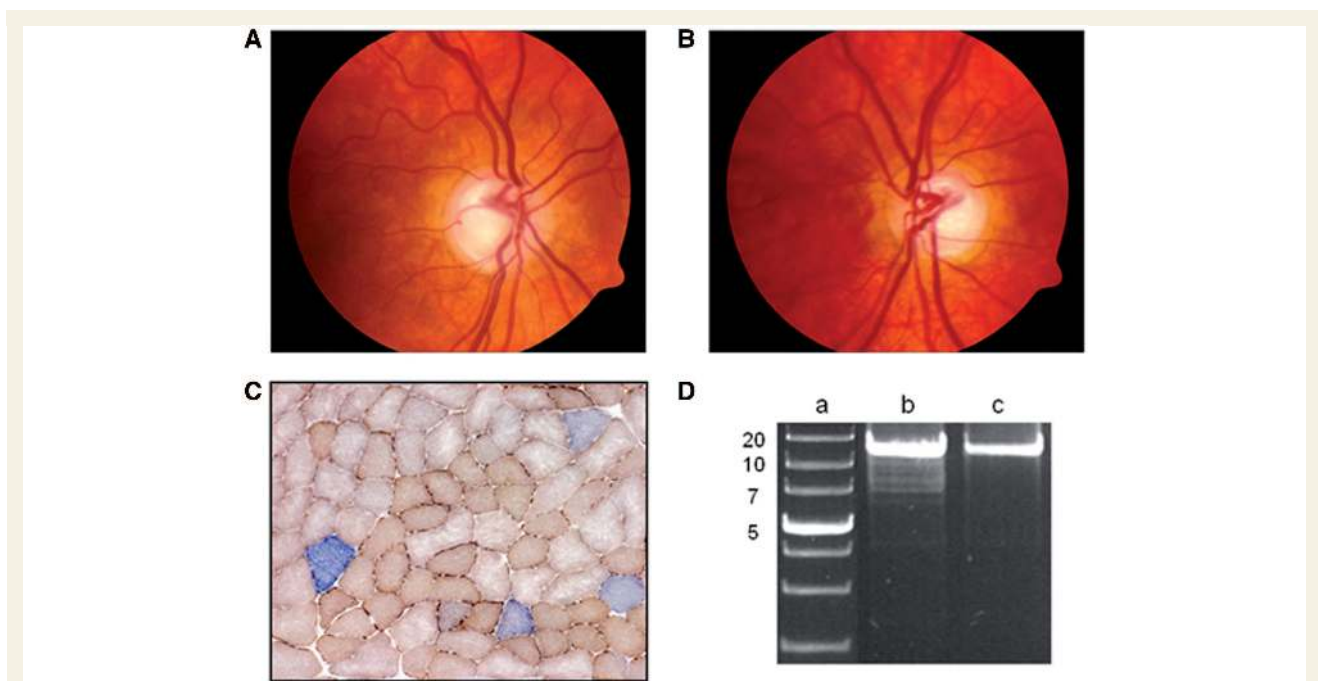


Figure 5 Clinical, histochemical and molecular features observed in a 59-year-old female with isolated optic nerve involvement due to an exon 27 c.2713C>T (p.R905X) *OPA1* missense mutation. (A) Right, and (B) left optic discs displaying generalized pallor of the neuro-retinal rim and pathological excavation. (C) Dual COX-SDH histochemistry performed on 20 μ m thick cryostat sections showing the presence of COX-deficient muscle fibres (33/1100, 3.00%). (D) Long-range PCR of the patient's homogenate skeletal muscle DNA revealing multiple deletion bands in addition to the wild-type 16-kb fragment. Lane a: 1-kb DNA ladder with the adjacent numbers indicating the size of the band; lane b: patient; lane c: wild-type control.

(8/10, 80.0%, Fig. 5) and DOA+ phenotypes (24/28, 85.7%), with no significant difference between these 2 groups ($\chi^2=0.1810$, $P=0.6706$, Table 4). For the four patients with DOA+ features but no multiple mtDNA deletions on long-range

PCR, COX-negative fibres were also not detected in their muscle biopsies (mean age = 45.5 years, SD = 7.9 years, range = 35.0–54.0 years). This specific subgroup harboured two different splice-site mutations: c.1212+3a>t (UK-1) and c.870+5g>a (UK-2), and a

Table 4 Summary of *OPA1* mutations and molecular profile identified in patients with DOA+ phenotypes

		<i>OPA1</i> mutations			
		Missense	Nonsense	Splice site	Deletion
DOA+ patients	<i>n</i> 80	3	8	13	
COX-deficiency ^a	– 1	–	3	2	
	+ 17	1	2	2	
MtDNA deletions ^a	– –	–	2	2	
	+ 18	1	3	2	

^aFor DOA+ patients where muscle biopsies were available for histochemical and molecular analysis (*n* = 28).

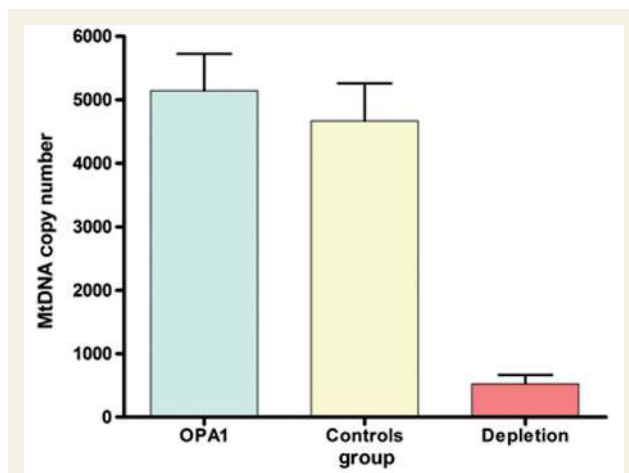


Figure 6 Comparison of mtDNA copy number in homogenate skeletal muscle DNA from patients with *OPA1* mutations (mean = 5144, SD = 2843, *n* = 24) with age-matched healthy controls (mean = 4669, SD = 2640, *n* = 20, *P* = 0.5719), and patients with mtDNA depletion syndromes (mean = 524, SD = 345, *n* = 6, *P* = 0.0005). The error bars represent the standard error of the mean.

previously reported frame-shift deletion c1410_1443+4del(38) (Spinazzi *et al.* 2008). Repeat muscle biopsies were available for two patients. The first was a 36-year-old woman with proximal myopathy, peripheral neuropathy, complicated migraine and the c.870+5g>a splice-site mutation (UK-2). Muscle biopsies were taken when she was 25- and 35-years-old, and both showed no evidence of COX-deficiency or multiple mtDNA deletions on long-range PCR. In contrast, her 55-year-old sister, who had a remarkably similar clinical picture, had definite evidence of multiple mtDNA deletions on long-range PCR with normal COX-SDH staining in a muscle biopsy taken at the age of 54 years. The second was a 59-year-old man with an HSP-like phenotype, complicated migraine and the c.876_878del(TGT) deletion (UK-3). His most recent muscle biopsy taken when he was 58-years-old revealed 2.07% (10/482) COX-deficient fibres and a laddering pattern on long range PCR indicating multiple deleted mtDNA species. Histochemical and molecular studies on a skeletal muscle

specimen taken 13 years earlier, when his lower limb spasticity was much less severe, were entirely normal. There was no evidence of mtDNA depletion in skeletal muscle homogenate DNA from *OPA1* positive patients (mean mtDNA copy number = 5144, SD = 2843, *n* = 24) when compared to age-matched healthy controls (mean mtDNA copy number = 4669, SD = 2640, *n* = 20, *P* = 0.5719; Fig. 6).

Discussion

By studying 45 DOA+ families from different geographical backgrounds, we have shown that additional neuromuscular features frequently develop as the disease progresses, with an adverse impact on the pre-existing visual morbidity. A meta-analysis of 104 patients with DOA+ phenotypes, including 44 previously reported cases in the literature, confirmed that sensorineural deafness is the most frequently observed extra-ocular feature, present in nearly two-thirds of all patients, over half of whom eventually developed more severe neuromuscular symptoms. Progressive external ophthalmoplegia and a predominantly axonal sensory neuropathy were the next most common clinical manifestations, followed by ataxia and myopathy. Although there is a degree of overlap, a chronological pattern is emerging with visual failure occurring within the first decade of life, followed by deafness from late childhood to early adulthood, and then a combination of ataxia, myopathy, peripheral neuropathy and progressive external ophthalmoplegia from the third decade of life onwards (Fig. 7). Excluding singleton cases and subjects younger than 25-years-old, it is also remarkable that in about a third of all pedigrees (11/32, 34.4%), family members were found to manifest both pure DOA and DOA+ phenotypes despite carrying the same *OPA1* mutation, and presumably having shared common environmental influences, especially in the first two decades of life in parent-offspring cases.

Optic nerve sparing

OPA1 mutations were identified in two large Italian pedigrees (IT-1 and IT-3) segregating autosomal dominant progressive external ophthalmoplegia, and remarkably, only a minority of family members were visually symptomatic with evidence of optic atrophy (2/13, 15.4%). In sharp contrast, almost all of the remaining DOA+ cases had evidence of optic nerve dysfunction (87/91, 95.6%), and the published penetrance figures are generally >80% in well characterized, multi-generational families with pure DOA (Yu-Wai-Man *et al.*, 2009a). The observation in these two Italian families has important diagnostic implications, and it will be important to screen a larger cohort of autosomal dominant progressive external ophthalmoplegia pedigrees without prominent visual symptoms, to determine the true prevalence of *OPA1* mutations in this specific disease subgroup. Furthermore, it is intriguing that *OPA1* mutational carriers can be non-penetrant for optic nerve failure, but yet manifest other deficits including deafness, myopathy and peripheral neuropathy, besides progressive external ophthalmoplegia. This is critically important, because it means that clinicians should consider *OPA1* screening in patients with unexplained neurological features, especially if molecular investigations

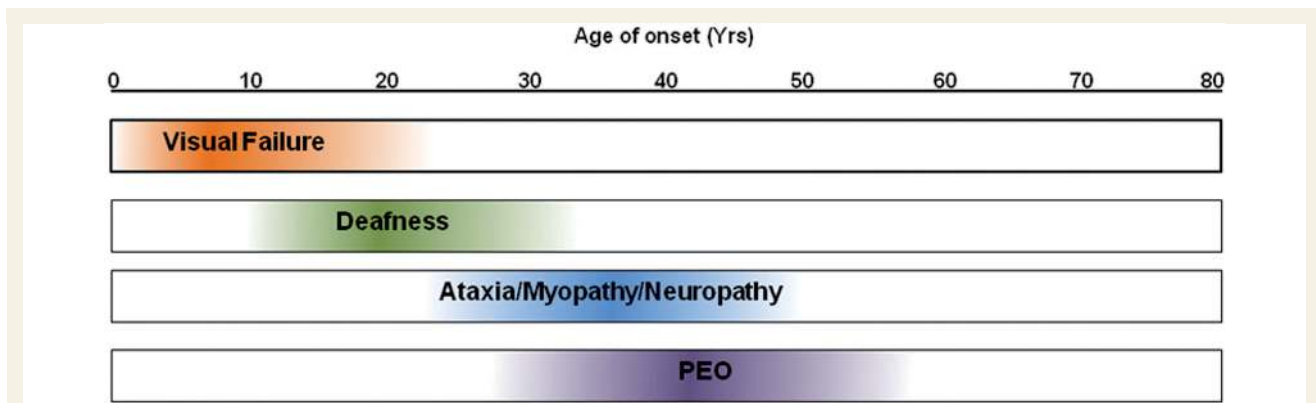


Figure 7 Evolution of the major clinical features observed in DOA+ syndromes.

subsequently reveal the presence of multiple mtDNA deletions (Stewart *et al.*, 2008).

Expanding DOA+ phenotype

We identified several unexpected phenotypes in patients with *OPA1* mutations, including spastic paraparesis and a multiple sclerosis-like illness, and these are unlikely to be chance associations. In the two probands presenting with progressive lower limb spasticity (UK-3 and UK-5), no underlying metabolic, inflammatory or compressive causes were found despite extensive investigations over several years. Isolated spastic paraparesis is unusual in adults with mitochondrial disease (Corona *et al.*, 2002), and the degeneration of corticospinal tract axons seen in these two families is particularly revealing. Further studies into the mechanisms involved could provide important insights into the pathophysiological mechanisms at work in hereditary spastic paraplegia, the obvious corollary being that the *OPA1* mutation is having a negative impact on neuronal survival by creating an imbalance in mitochondrial network dynamic and axonal trafficking (Reid, 2003; Salinas *et al.*, 2008). The presence of COX-deficient fibres and multiple mtDNA deletions in skeletal muscle biopsies is also very significant and further supports a link with mitochondrial dysfunction in a subgroup of patients with hereditary spastic paraplegia (McDermott *et al.*, 2003).

The unmatched CSF oligoclonal bands and abnormal white matter lesions in the 58-year-old woman with a multiple sclerosis-like illness (UK-6) are also unlikely to be co-incidental findings. Based upon recent epidemiological data (Fox *et al.*, 2004), we estimate the chance finding of an *OPA1* mutation in a patient with multiple sclerosis in the UK at 1 in 41 million (95% CI = 25–73 million), and of note, this association has already been reported in a 44-year-old man with gait ataxia and lower-limb spasticity (FR-11), who had MRI and CSF changes consistent with a demyelinating process, and a novel c.1937C>T (p.S646L) missense mutation in the dynamin region the *OPA1* gene (Verny *et al.*, 2008). These observations are reminiscent of the well-established association between primary mtDNA Leber hereditary optic neuropathy mutations and a multiple sclerosis-like illness (Harding's disease) (Harding *et al.*, 1992; Kovacs *et al.*, 2005), and it is therefore tempting to speculate a causal link between *OPA1* mutations, mitochondrial dysfunction,

oligodendrocyte survival and the complex autoimmune process which underlies the pathophysiology of multiple sclerosis (Carelli and Bellan, 2008; Mahad *et al.*, 2009).

Nearly a third of all the DOA+ patients in our study had evidence of an axonal neuropathy, an observation with important parallels to a specific subtype of Charcot-Marie-Tooth (CMT) disease or, hereditary motor and sensory neuropathy type VI (HMSN VI, OMIM 601152). This variant is caused by mutations in the *MFN2* gene and it is characterized by early onset, severe peripheral neuropathy in the first decade of life, followed by subacute, progressive optic atrophy in later childhood (Zuchner *et al.*, 2006). Mitofusin-2 is located within the mitochondrial outer membrane and it shares a high degree of structural and functional complementarity with Opa1, both being dynamin GTPase proteins (Zuchner *et al.*, 2006; Chan, 2007). Mitofusin-2 interacts closely with Opa1 to promote fusion of the mitochondrial network, and it could also play a distinct role in mitochondrial oxidative output by regulating the expression of nuclear-encoded respiratory chain subunits (Pich *et al.*, 2005). It is also noteworthy that abnormal nerve conduction studies were documented in two DOA+ patients with no overt neuropathic features. As neurophysiological investigations were performed mostly to confirm a suspected peripheral neuropathy, the true burden of subclinical disease remains to be determined, not only in DOA+, but also among patients with pure DOA.

The prevalence of non-insulin dependent diabetes in our DOA+ cohort (3.6%) was comparable to the latest UK national figures (3.9%) (NHS Quality and Outcomes Framework, 2008), and although severe, characteristic migrainous episodes were reported by 4 out of 83 (4.8%) patients with DOA+, this could simply reflect the background prevalence of migraine in the general population (11–15%), and not an *OPA1*-related effect *per se* (Goadsby *et al.*, 2002; Bigal *et al.*, 2006).

Prevalence of DOA+

As a result of the different referral patterns in this study, the prevalence of patients with DOA+ phenotypes is difficult to ascertain. However, a reasonable estimate can be derived from our epidemiological data from the North of England, which has a centralized National Health Service with well defined catchment areas (Man *et al.*, 2003). Based upon our latest figures, 64 patients

with *OPA1* mutations currently reside in the North of England, and of those 11 out of 64 (17.2%) had DOA+ features, suggesting that these syndromal manifestations are not uncommon and probably affect up to one in six of all cases. Using the latest census data for the North of England (Office for National Statistics, 2008), we estimate the minimum prevalence of DOA+ at 0.36 per 100 000 (95% CI=0.25–0.50 per 100 000); about 1 in 250 000 of the general population. This is comparable to other well-recognized neurogenetic disorders with prominent ocular features such as oculopharyngeal muscular dystrophy (Brais, 2009), neuromyelitis optica (Devic disease) (Wingerchuk *et al.*, 2007), and diabetes insipidus and mellitus with optic atrophy and deafness (Wolfram syndrome 1) (Khanim *et al.*, 2001).

Novel *OPA1* mutations

We have identified an additional nine novel *OPA1* mutations in this study, adding to the list of >200 pathogenic variants so far catalogued on the e*OPA1* database (Ferre *et al.*, 2005, 2009). Unusually, in two families, DE-1 and NO-1, affected family members harboured two different *OPA1* mutations. Only one other case of compound heterozygosity has previously been described in a female patient from a German family, and she carried two presumed pathogenic substitutions in exon 8: c.808G>A (p.E270K) and c.868C>T (p.R290W) (Pesch *et al.*, 2001). The patient's visual loss was more severe compared with five other affected family members who were all simple heterozygotes, which led the authors to speculate that her greater visual impairment was related to the presence of two pathogenic *OPA1* variants. Unlike this previously published family who only exhibited isolated optic atrophy, both DE-1 and NO-1 had DOA+ features, with the two Norwegian siblings having a particularly aggressive disease course characterized by ataxia, peripheral neuropathy, corticospinal tract involvement and myopathy, in contrast to relatively mild sensorineural hearing loss for the two German siblings. Although the number of cases is small, it is tempting to invoke a combined mutational effect, with the presence of two *OPA1* mutations leading to greater disease severity.

The Norwegian family, NO-1, is also unusual in carrying an exon 5b missense mutation, c.768C>G (p.S256R), in the coiled-coil domain of the Opa1 protein. Using *in silico* modelling, the change of a serine to arginine at position 256 is predicted to result in a marked reduction in the likelihood of coiled-coil formation in this region (Fig. 8), with a detrimental effect on the ability of the Opa1 protein to form oligomers, which is critical for its normal function. We previously reported another exon 5b mutation, c.740G>A (p.R247H), in a 23-year-old male with pure DOA and a unique clinical course characterized by spontaneous, progressive visual recovery (Cornille *et al.*, 2008). This amino acid substitution was also identified in the patient's father who was non-penetrant for optic atrophy. The c.740G>A (p.R247H) mutation was predicted to disrupt the coiled-coil forming potential, and in addition, fibroblasts harvested from both family members showed mitochondrial network abnormalities and oxidative phosphorylation uncoupling, with a greater susceptibility to undergo apoptosis (Cornille *et al.*, 2008).

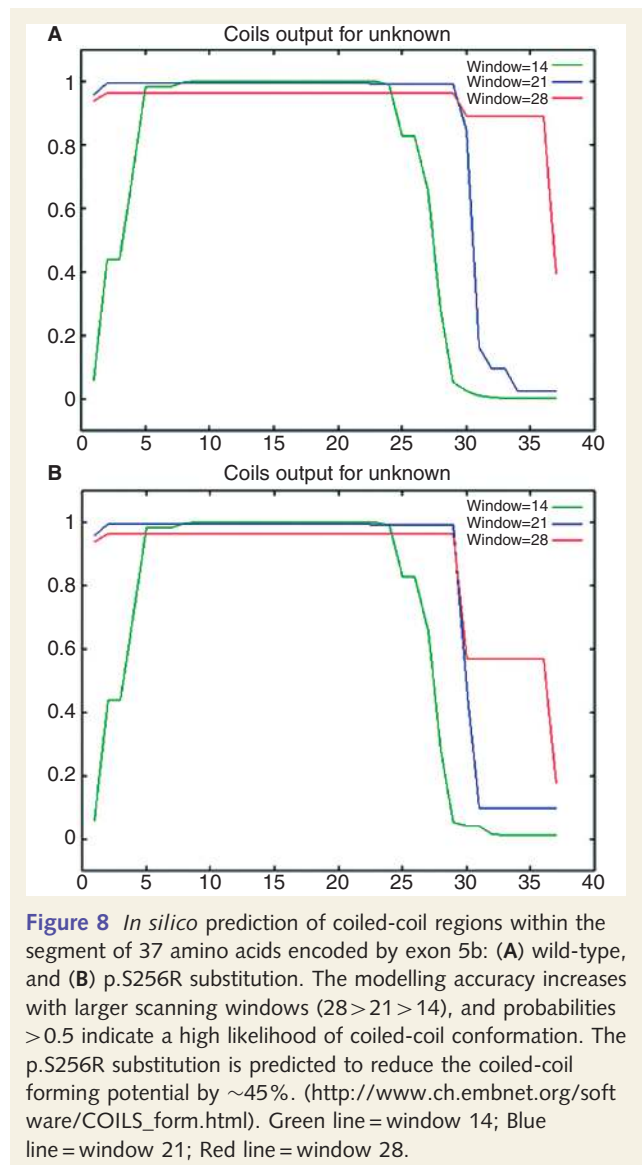


Figure 8 *In silico* prediction of coiled-coil regions within the segment of 37 amino acids encoded by exon 5b: (A) wild-type, and (B) p.S256R substitution. The modelling accuracy increases with larger scanning windows (28 > 21 > 14), and probabilities > 0.5 indicate a high likelihood of coiled-coil conformation. The p.S256R substitution is predicted to reduce the coiled-coil forming potential by ~45%. (http://www.ch.embnet.org/software/COILS_form.html). Green line = window 14; Blue line = window 21; Red line = window 28.

It is therefore interesting that only the c.768C>G (p.S256R) variant was identified in the two, visually asymptomatic, 35- and 43-year-old daughters of the Norwegian proband. *OPA1* mRNA exists as eight isoforms as a result of alternate splicing of exons 4, 4b and 5b, and from an evolutionary perspective, exons 4b and 5b are only found in higher vertebrates with a putative role in regulating cytochrome *c* release during apoptosis (Olichon *et al.*, 2007). The 37 amino acids encoded by exon 5b are identical in all higher vertebrates and only two substitutions have so far been reported, both non-synonymous. Although speculative, as exon 5b is only present in ~40% of total *OPA1* mRNA transcripts, this could explain the relatively mild pathogenic nature of exon 5b variants on their own. Additional functional studies, for example comparing fibroblast cell lines from NO-1 family members, are also warranted to further clarify whether there is a synergistic action between the exon 5b and the exon 8 variants in compound heterozygous individuals, contributing to disease severity.

Mitochondrial mechanisms in DOA+

In our original description of multiple mtDNA deletions in DOA+, all the *OPA1* mutations were missense substitutions and in 5/7 families, these clustered in the GTPase domain (Amati-Bonneau *et al.*, 2008; Hudson *et al.*, 2008). A possible dominant negative effect was therefore suggested with the mutant Opa1 protein disrupting mitochondrial inner membrane function and/or the delicate balance of the intra-mitochondrial nucleotide pool required for efficient mtDNA replication (Zeviani, 2008). Although these remain to be proven experimentally, a gain of function mechanism cannot explain the association of *OPA1* deletions and splice-site mutations with DOA+, both of which lead to haploinsufficiency, and were identified in DOA+ families in this study.

Histochemical and molecular studies performed on skeletal muscle biopsies from patients with both pure DOA and DOA+ features have also provided some interesting insights into the possible disease mechanisms involved in retinal ganglion cell loss and optic nerve degeneration. COX-deficiency is a useful surrogate marker of the extent of mitochondrial dysfunction due to mtDNA defects, and consistent with this, patients with DOA+ phenotypes had over four times higher levels of COX-negative muscle fibres compared to patients with pure DOA. The majority of patients in both subgroups harboured multiple mtDNA deletions, but in a few patients with DOA+ features, both COX-deficiency and secondary mtDNA deletions were not present, even when using long-range PCR, a highly sensitive technique that preferentially amplifies smaller mtDNA species (Lightowlers *et al.*, 1999). It is therefore possible that mtDNA deletions contribute to the pathophysiology of DOA, but they are not the sole mechanism responsible for triggering cellular dysfunction, especially optic nerve neurodegeneration. In keeping with this hypothesis, we recently showed that secondary mtDNA abnormalities were not present in retinal ganglion cells harvested from a pure DOA mouse model, implying that retinal ganglion cell loss must be the result of other deleterious consequences induced by the *OPA1* mutation (Yu-Wai-Man *et al.*, 2009b). One important caveat is that the molecular observations in this study relate to skeletal muscle biopsies, which might not be a true reflection of the changes operating within retinal ganglion cells, tissue-specific mechanisms being well-recognized features of mitochondrial disorders.

The Opa1 protein is involved in several inter-related biological processes and further studies are needed to clarify whether specific mutations operate predominantly via certain pathways (Davies and Votruba, 2006; Yu-Wai-Man *et al.*, 2009a). These are not however mutually exclusive, for example, increased levels of reactive oxygen species secondary to disturbed oxidative phosphorylation could potentiate the formation of mtDNA deletions (Krishnan *et al.*, 2008), and mitochondrial network fragmentation could accelerate their clonal expansion, the compartmentalization of the mtDNA pool effectively decreasing the copy number in these discrete units, and reducing the time required for the deleted mtDNA species to reach supra-threshold levels (Chinnery and Samuels, 1999).

Genotype–phenotype correlations

Genetic counselling has always been a challenging issue in DOA due to the marked intra- and inter-familial variability in visual prognosis, and these difficulties have now been further compounded by the heterogeneous individual manifestations of DOA+ features. Although further studies are warranted, our study has allowed us to define some broad genotype–phenotype correlations for clinicians advising patients on the implications of the *OPA1* mutations segregating in their families: (i) mutations causing optic atrophy in association with sensorineural deafness are not limited to the c.1334G>A (p.R445H) variant but, as in other reports, we found this mutation to be the most common, being present in 11 out of 30 (36.7%) families in our study; (ii) there is a 2–3-fold increased risk of developing DOA+ features with missense mutations and those located within the GTPase region; (iii) this risk is 4-fold lower with *OPA1* mutations located within the dynamin domain; (iv) patients with DOA+ phenotypes have on average a worse visual prognosis compared to patients with pure DOA; and (v) *OPA1* is a highly polymorphic gene but there is no evidence that certain combination of single nucleotide polymorphisms are acting as intragenic modifiers and influencing either disease severity or specific clinical manifestations (data not shown).

Conclusions

Although the majority of patients with *OPA1* disease have symptomatic optic neuropathy, additional neuromuscular features are common in patients with *OPA1* mutations. There is currently no definitive treatment for this disorder, but the fact that these complex phenotypes eventually develop in up to 20% of all mutational carriers has important implications for clinical management. Significant neurological impairment can easily be overlooked in patients and simply attributed to their visual failure, but careful surveillance of at-risk individuals will identify components which might be amenable to supportive therapy, such as physiotherapy or anti-spasmodic drugs for those with upper motor neuron involvement, and cochlear implantation which is of proven benefit in mitochondrial hearing impairment (Sinnathuray *et al.*, 2003; Chinnery and Griffiths, 2006). The heterogeneous multi-system manifestations seen in DOA+ families and the remarkable variable penetrance among carriers with the same pathogenic variant clearly implicate the influence of secondary modulatory factors on the phenotypic expression of the 'primary' *OPA1* mutation. Identifying these together with the underlying molecular pathways will be key in dissecting the complex processes leading to tissue-specific dysfunction in both pure and syndromal forms of DOA.

Funding

MRC Clinical Research Fellowship in Neuro-ophthalmology to P.Y.W.M.; Wellcome Trust Senior Fellowship in Clinical Science to P.F.C.; P.F.C. also receives funding from the Parkinson's Disease Society (UK), the Medical Research Council Translational Muscle Centre, and the UK NIHR Biomedical Research Centre in

Ageing and Age related disease. R.H. is supported by the Deutsche Forschungsgemeinschaft (HO 2505/2-1) and the Academy of Medical Sciences. R.M. and M.V. are MRC Clinician Scientists. D.M.T. and R.W.T. are funded by the Wellcome Trust, and the UK National Commissioning Group for Rare Mitochondrial Disorders of Adults and Children. L.B. receives funding from Helse Vest (RHF) and the Norwegian Research Council. G.S.G. is supported by the NIHR Biomedical research Centre for Ageing and Age-related disease; Telethon-Italy grant (GGP06233) to V.C.

Supplementary material

Supplementary material is available at *Brain* online.

References

- Alexander C, Votruba M, Pesch UEA, Thiselton DL, Mayer S, Moore A, et al. *OPA1*, encoding a dynamin-related GTPase, is mutated in autosomal dominant optic atrophy linked to chromosome 3q28. *Nat Genet* 2000; 26: 211–5.
- Amati-Bonneau P, Guichet A, Olichon A, Chevrollier A, Viala F, Miot S, et al. *OPA1* R445H mutation in optic atrophy associated with sensorineural deafness. *Annals of Neurology* 2005; 58: 958–63.
- Amati-Bonneau P, Pasquier L, Lainey E, Ferre M, Odent S, Malthiery Y, et al. Sporadic optic atrophy due to synonymous codon change altering mRNA splicing of *OPA1*. *Clin Genet* 2004; 67: 102–3.
- Amati-Bonneau P, Valentino ML, Reynier P, Gallardo ME, Bornstein B, Boissiere A, et al. *OPA1* mutations induce mitochondrial DNA instability and optic atrophy plus phenotypes. *Brain* 2008; 131: 338–51.
- Bigal ME, Liberman JN, Lipton RB. Age-dependent prevalence and clinical features of migraine. *Neurology* 2006; 67: 246–51.
- Bland M. *An Introduction to Medical Statistics*. Oxford: Oxford University Press, 2000.
- Brais B. Oculopharyngeal muscular dystrophy: a polyalanine myopathy. *Current Neurology and Neuroscience Reports* 2009; 9: 76–82.
- Brierley EJ, Johnson MA, James OFW, Turnbull DM. Effects of physical activity and age on mitochondrial function. *QJM* 1996; 89: 251–8.
- Carelli V, Bellan M. Myelin, mitochondria, and autoimmunity - What's the connection? *Neurology* 2008; 70: 1075–6.
- Chan DC. Mitochondrial dynamics in disease. *New England J Med* 2007; 356: 1707–9.
- Chen SQ, Zhang YL, Wang YM, Li WL, Huang S, Chu X, et al. A novel *OPA1* mutation responsible for autosomal dominant optic atrophy with high frequency hearing loss in a Chinese family. *Am J Ophthalmol* 2007; 143: 186–8.
- Chevrollier A, Guillet V, Loiseau D, Gueguen N, de Crescenzo MA, Verry C, et al. Hereditary optic neuropathies share a common mitochondrial coupling defect. *Ann Neurol* 2008; 63: 794–8.
- Chinnery PF, Griffiths TD. Mitochondrial Otology. In: DiMauro S, Schon EA, editors. *Mitochondrial medicine*. London: Parthenon; 2006. p. 161–78.
- Chinnery PF, Samuels DC. Relaxed replication of mtDNA: A model with implications for the expression of disease. *Am J Hum Genet* 1999; 64: 1158–65.
- Chinnery PF, Zeviani M. 155th ENMC workshop: polymerase gamma and disorders of mitochondrial DNA synthesis, 21–23 September 2007, Naarden, The Netherlands. *Neuromuscul Disord* 2008; 18: 259–67.
- Cipolat S, Rudka T, Hartmann D, Costa V, Serneels L, Craessaerts K, et al. Mitochondrial rhomboid PARL regulates cytochrome c release during apoptosis via *OPA1*-dependent cristae remodeling. *Cell* 2006; 126: 163–75.
- Copeland WC. Inherited mitochondrial diseases of DNA replication. *Ann Rev Med* 2008; 59: 131–46.
- Cornille K, Milea D, Amati-Bonneau P, Procaccio V, Zazoun L, Guillet V, et al. Reversible optic neuropathy with *OPA1* exon 5b mutation. *Ann Neurol* 2008; 63: 667–71.
- Corona P, Lamantea E, Greco M, Carrara F, Agostino A, Guidetti D, et al. Novel heteroplasmic mtDNA mutation in a family with heterogeneous clinical presentations. *Ann Neurol* 2002; 51: 118–22.
- Cree LM, Patel SK, Pyle A, Lynn S, Turnbull DM, Chinnery PF, et al. Age-related decline in mitochondrial DNA copy number in isolated human pancreatic islets. *Diabetologia* 2008; 51: 144–3.
- Davies V, Votruba M. Focus on molecules: the *OPA1* protein. *Exp Eye Res* 2006; 83: 1003–4.
- Delettre C, Lenaers G, Griffoin JM, Gigarel N, Lorenzo C, Belenguer P, et al. Nuclear gene *OPA1*, encoding a mitochondrial dynamin-related protein, is mutated in dominant optic atrophy. *Nat Genet* 2000; 26: 207–10.
- DiMauro S, Schon EA. Mechanisms of disease: Mitochondrial respiratory-chain diseases. *N Engl J Med* 2003; 348: 2656–68.
- Ferraris S, Clark S, Garelli E, Davidzon G, Moore SA, Kardon RH, et al. Progressive external ophthalmoplegia and vision and hearing loss in a patient with mutations in *POLG2* and *OPA1*. *Arch Neurol* 2008; 65: 125–31.
- Ferre M, Amati-Bonneau P, Tourmen Y, Malthiery Y, Reynier P. eOPA1: an online database for *OPA1* mutations. *Hum Mutat* 2005; 25: 423–8.
- Ferre M, Bonneau D, Milea D, Chevrollier A, Verry C, Dollfus H, et al. Molecular screening of 980 cases of suspected hereditary optic neuropathy with a report on 77 novel *OPA1* mutations. *Hum Mutat* 2009; 30: E692–705.
- Fox CM, Bensa S, Bray I, Zajicek JP. The epidemiology of multiple sclerosis in Devon: a comparison of the new and old classification criteria. *J Neurol Neurosurg Psychiatr* 2004; 75: 56–60.
- Frezza C, Cipolat S, de Brito OM, Micaroni M, Beznoussenko GV, Rudka T, et al. *OPA1* controls apoptotic cristae remodeling independently from mitochondrial fusion. *Cell* 2006; 126: 177–89.
- Goadsby PJ, Lipton RB, Ferrari MD. Migraine—current understanding and treatment. *N Engl J Med* 2002; 346: 257–70.
- Harding AE, Sweeney MG, Miller DH, Mumford CJ, Kellarwood H, Menard D, et al. Occurrence of a Multiple Sclerosis-Like Illness in Women Who Have a Lebers Hereditary Optic Neuropathy Mitochondrial-DNA Mutation. *Brain* 1992; 115: 979–989.
- Hoyt CS. Autosomal dominant optic atrophy – a spectrum of disability. *Ophthalmology* 1980; 87: 245–51.
- Hudson G, Amati-Bonneau P, Blakely EL, Stewart JD, He LP, Schaefer AM, et al. Mutation of *OPA1* causes dominant optic atrophy with external ophthalmoplegia, ataxia, deafness and multiple mitochondrial DNA deletions: a novel disorder of mtDNA maintenance. *Brain* 2008; 131: 329–37.
- Hudson G, Chinnery PF. Mitochondrial DNA polymerase-gamma and human disease. *Hum Mol Genet* 2006; 15: R244–52.
- Johnson MA, Barron MJ. Muscle biopsy analysis. In: Lane RJM, editor. *Handbook of muscle disease* New York, USA: Marcel Dekker, 1996: 61–79.
- Ke T, Nie S-w, Yang Q-b, Liu J-p, Zhou L-n, Ren X, et al. The G401D mutation of *OPA1* causes autosomal dominant optic atrophy and hearing loss in a Chinese family. *Zhonghua Yi Xue Yi Chuan Xue Za Zhi* 2006; 23: 481–5.
- Khanim F, Kirk J, Latif F, Barrett TG. WFS1/Wolframin mutations, Wolfram syndrome, and associated diseases. *Hum Mutat* 2001; 17: 357–67.
- Kovacs GG, Hoftberger R, Horvath R, Barsi P, Komoly S, Lassmann H, et al. Neuropathology of white matter disease in Leber's hereditary optic neuropathy. *Brain* 2005; 128: 35–41.
- Krishnan KJ, Reeve AK, Samuels DC, Chinnery PF, Blackwood JK, Taylor RW, et al. What causes mitochondrial DNA deletions in human cells? *Nat Genet* 2008; 40: 275–9.

- Lange C, Feltgen N, Junker B, Schulze-Bonsel K, Bach M. Resolving the clinical acuity categories "hand motion" and "counting fingers" using the Freiburg Visual Acuity Test (FrACT). *Graefes Arch Clin Exp Ophthalmol* 2009; 247: 137–42.
- Li CM, Kosmorsky G, Zhang K, Katz BJ, Ge J, Traboulsi EI. Optic atrophy and sensorineural hearing loss in a family caused by an R445H OPA1 mutation. *Am J Med Genet Part A* 2005; 138A: 208–11.
- Lightowers RH, Jacobs HT, Kajander OA. Mitochondrial DNA - all things bad? *Trends Genet* 1999; 15: 91–3.
- Liguori M, La Russa A, Manna I, Andreoli V, Caracciolo M, Spadafora P, et al. A phenotypic variation of dominant optic atrophy and deafness (ADOAD) due to a novel OPA1 mutation. *J Neurol* 2008; 255: 127–9.
- Mahad DJ, Ziabreva I, Campbell G, Lax N, White K, Hanson PS, et al. Mitochondrial changes within axons in multiple sclerosis. *Brain* 2009; 132: 1161–74.
- Man PY, Griffiths PG, Brown DT, Howell N, Turnbull DM, Chinnery PF. The epidemiology of Leber hereditary optic neuropathy in the North East of England. *Am J Hum Genet* 2003; 72: 333–9.
- McDermott CJ, Taylor RW, Hayes C, Johnson M, Bushby KMD, Turnbull DM, et al. Investigation of mitochondrial function in hereditary spastic paraparesis. *Neuroreport* 2003; 14: 485–8.
- Meire F, Delaey JJ, Debie S, Vanstaey M, Matton MT. Dominant optic nerve atrophy with progressive hearing-loss and chronic progressive external ophthalmoplegia (Cpeo). *Ophthalm Paed Genet* 1985; 5: 91–7.
- Milone M, Younge BR, Wang J, Zhang SL, Wong LJ. Mitochondrial disorder with OPA1 mutation lacking optic atrophy. *Mitochondrion* 2009; 9: 279–81.
- Newman NJ, Biousse V. Hereditary optic neuropathies. *Eye* 2004; 18: 1144–60.
- NHS Quality and Outcomes Framework. Disease Prevalence: <http://www.diabetes.org.uk/en/Professionals/Publications-reports-and-resources/Reports-statistics-and-case-studies/Reports/Diabetes-prevalence-2008/>, 2008.
- Office for National Statistics. Populations and Households: <http://www.statistics.gov.uk/statbase/Product.asp?vlnk=15106>, 2008.
- Olichon A, Elachouri G, Baricault L, Delettre C, Belenguer P, Lenaers G. OPA1 alternate splicing uncouples an evolutionary conserved function in mitochondrial fusion from a vertebrate restricted function in apoptosis. *Cell Death Differentiation* 2007; 14: 682–92.
- Payne M, Yang ZL, Katz BJ, Warner JEA, Weight CJ, Zhao Y, et al. Dominant optic atrophy, sensorineural hearing loss, ptosis, and ophthalmoplegia: A syndrome caused by a missense mutation in OPA1. *Am J Ophthalmol* 2004; 138: 749–55.
- Pesch UEA, Leo-Kottler B, Mayor S, Jurklics B, Kellner U, Apfelstedt-Sylla E, et al. OPA1 mutations in patients with autosomal dominant optic atrophy and evidence for semi-dominant inheritance. *Hum Mol Genet* 2001; 10: 1359–68.
- Pich S, Bach D, Briones P, Liesa M, Camps M, Testar X, et al. The Charcot-Marie-Tooth type 2A gene product, Mfn2, up-regulates fuel oxidation through expression of OXPHOS system. *Hum Mol Genet* 2005; 14: 1405–15.
- Puomila A, Huoponen K, Mantyjarvi M, Hamalainen P, Paananen R, Sankila EM, et al. Dominant optic atrophy: correlation between clinical and molecular genetic studies. *Acta Ophthalmologica Scandinavica* 2005; 83: 337–46.
- Pyle A, Taylor RW, Durham SE, Deschauer M, Schaefer AM, Samuels DC, et al. Depletion of mitochondrial DNA in leucocytes harbouring the 3243A->G mtDNA mutation. *J Med Genet* 2007; 44: 69–74.
- Reid E. Science in motion: common molecular pathological themes emerge in the hereditary spastic paraplegias. *Journal of Medical Genetics* 2003; 40: 81–6.
- Salinas S, Proukakis C, Crosby A, Warner TT. Hereditary spastic paraplegia: clinical features and pathogenetic mechanisms. *Lancet Neurol* 2008; 7: 1127–38.
- Schapira AHV. Mitochondrial disease. *Lancet* 2006; 368: 70–82.
- Schulze-Bonsel K, Feltgen N, Burau H, Hansen L, Bach M. Visual acuities "hand motion" and "counting fingers" can be quantified with the Freiburg visual acuity test. *Investigat Ophthalmol Visual Sci* 2006; 47: 1236–40.
- Sinnathuray AR, Raut V, Awa A, Magee A, Toner JG. A review of cochlear implantation in mitochondrial sensorineural hearing loss. *Otol Neurotol* 2003; 24: 418–26.
- Spinazzi M, Cazzola S, Bortolozzi M, Baracca A, Loro E, Casarin A, et al. A novel deletion in the GTPase domain of OPA1 causes defects in mitochondrial morphology and distribution, but not in function. *Hum Mol Genet* 2008; 17: 3291–302.
- Stewart JD, Hudson G, Yu-Wai-Man P, Blakeley EL, He L, Horvath R, et al. Opa1 in multiple mitochondrial DNA deletion disorders. *Neurology* 2008; 71: 1829–1831.
- Verny C, Loiseau D, Scherer C, Lejeune P, Chevrollier A, Gueguen N, et al. Multiple sclerosis-like disorder in OPA1-related autosomal dominant optic atrophy. *Neurology* 2008; 70: 1152–3.
- Wingerchuk DM, Lennon VA, Lucchinetti CF, Pittock S, Weinshenker BG. The spectrum of neuromyelitis optica. *Lancet Neurol* 2007; 6: 805–15.
- Yu-Wai-Man P, Davies VJ, Piechota MJ, Cree LM, Votruba M, Chinnery PF. Secondary mtDNA defects do not cause optic nerve dysfunction in a mouse model of dominant optic atrophy. *Invest Ophthalmol Vis Sci* 2009b; 50: 4561–6.
- Yu-Wai-Man P, Griffiths PG, Hudson G, Chinnery PF. Inherited mitochondrial optic neuropathies. *J Med Genet* 2009a; 46: 145–58.
- Zanna C, Ghelli A, Porcelli AM, Karbowski M, Youle RJ, Schimpf S, et al. OPA1 mutations associated with dominant optic atrophy impair oxidative phosphorylation and mitochondrial fusion. *Brain* 2008; 131: 352–67.
- Zeviani M. OPA1 mutations and mitochondrial DNA damage: keeping the magic circle in shape. *Brain* 2008; 131: 314–17.
- Zuchner S, De Jonghe P, Jordanova A, Claeys KG, Guergueltcheva V, Cherninkova S, et al. Axonal neuropathy with optic atrophy is caused by mutations in mitofusin 2. *Annal Neurol* 2006; 59: 276–81.