



Multidetector Computed Tomography in Patients with Femoral Neck Fracture for Assessing Osteoporosis: Comparison with Dual Energy X-Ray Absorptiometry

대퇴골 경부 골절 환자에서 골다공증 평가를 위한 다중검출 CT의 이용: 이중에너지 X-선 흡수계측법과의 비교

Hyo Jeong Lee, MD , Ji Young Hwang, MD*

Department of Radiology, Ewha Womans University, School of Medicine, Seoul, Korea

Received December 12, 2019

Revised March 20, 2020

Accepted April 24, 2020

*Corresponding author

Ji Young Hwang, MD
Department of Radiology,
Ewha Womans University,
College of Medicine
25 Magokdong-ro 2-gil,
Gangseo-gu, Seoul 07804, Korea.

Tel 82-2-6986-3727

Fax 82-2-2650-5302

E-mail mshjy@ewha.ac.kr

This is an Open Access article distributed under the terms of the Creative Commons Attribution Non-Commercial License (<https://creativecommons.org/licenses/by-nc/4.0>) which permits unrestricted non-commercial use, distribution, and reproduction in any medium, provided the original work is properly cited.

ORCID iDs

Hyo Jeong Lee

[https://](https://orcid.org/0000-0002-6566-9667)

orcid.org/0000-0002-6566-9667

Ji Young Hwang

[https://](https://orcid.org/0000-0001-5848-3429)

orcid.org/0000-0001-5848-3429

Purpose To evaluate the ability of the Hounsfield unit (HU) measurement of the femoral neck during multidetector computed tomography (MDCT) for assessing osteoporosis compared with dual-energy X-ray absorptiometry (DXA).

Materials and Methods Forty-two patients with femoral neck fractures who underwent MDCT and DXA from July to December 2016 were included in this study. HU measurements were made of the cancellous portions of the normal contralateral femoral neck on MDCT. Bone mineral density (BMD) and T-scores were obtained at the femur DXA. Correlations of HU values with BMD and T-scores were analyzed using Spearman's correlation test.

Results The mean BMD and T-score of the femoral neck were 0.650 g/cm² and -2.4, respectively. The mean HU values for the normal, osteopenia, and osteoporosis groups were 131.9, 98.9, and 41.3, respectively. HU values at the femoral neck were positively correlated with BMD ($r^2 = 0.670$; $p < 0.001$) and T-scores ($r^2 = 0.676$; $p < 0.001$).

Conclusion The HU values of the femoral neck on MDCT are significantly correlated with BMD and T-scores of femur DXA. The HU values may serve as a diagnostic tool for the screening of regional bone quality when MDCT is performed for other reasons.

Index terms Multidetector Computed Tomography; Femoral Neck; Osteoporosis; Bone Density; Absorptiometry, Dual-Energy X-Ray

INTRODUCTION

The most common metabolic bone disease is osteoporosis, which is characterized by low bone mass and abnormal bone microarchitecture, resulting in fragile bones with susceptibility to fracture (1). Osteoporosis is a growing public health problem, particularly as patients over 65 years of age are rapidly becoming a larger proportion of the population (2). The burden of this disease and its substantial health care costs have led to the routine use of dual energy X-ray absorptiometry (DXA) measurements of bone mineral density as a screening examination. DXA remains the gold standard for bone mineral density quantification and has been shown to correlate with fracture risk and the efficacy of treatment (3). DXA has advantages for the screening of osteoporosis due to its minimal radiation exposure and low cost (4).

The common causes of femoral neck fracture are high energy trauma and preexisting osteoporosis. In the emergency department, clinicians usually perform pelvic bone multidetector computed tomography (MDCT) when a femoral neck fracture is suspected. MDCT could be useful not only to diagnose the femoral neck fracture, but also to evaluate the underlying bone quality. Therefore, we hypothesized that MDCT could be helpful for clinicians that make an impression or presumed diagnosis of osteoporosis in patients before the DXA examination.

A recent study revealed that Hounsfield unit (HU) values at the capitata bone were significantly correlated with DXA results in patients with distal radius fractures (4). However, the correlation between HU values and DXA results has not yet been investigated in pelvic bone MDCT.

The purpose of this study is to evaluate the ability of HU measurements at the femoral neck on MDCT to recognize osteoporosis compared with DXA.

MATERIALS AND METHODS

PATIENT SELECTION

This retrospective study was approved by the Institutional Review Board of our institute (IRB No. 2018-01-072-001). A database of subjects with femoral neck fractures in our institute was reviewed.

One hundred thirty patients who had pelvic bone MDCT taken were identified from July to December 2016. Among these 130 patients, 86 patients were diagnosed with a femoral neck fracture.

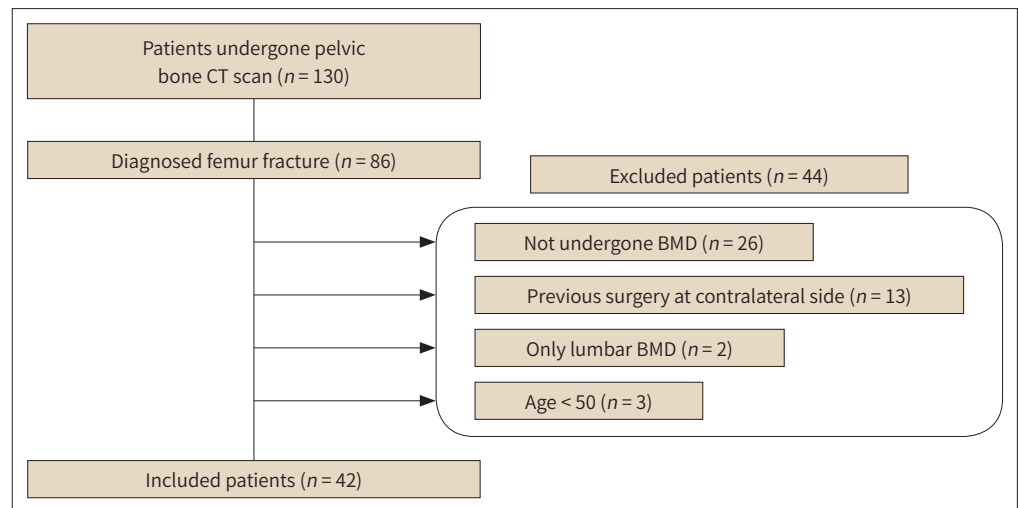
The exclusion criteria were as follows: 1) 26 cases who did not take DXA, 2) 13 cases with invalid DXA findings due to previously inserted surgical material on the normal contralateral femur, 3) 2 patients who had only lumbar DXA, and 4) 3 patients whose age less than 50.

Our final cohort consisted of 42 patients with femoral neck fractures who underwent both MDCT and DXA examinations (Fig. 1). The mean time interval between MDCT and DXA was 7 days (Interval range: 5–65 days).

IMAGE ACQUISITION

DXA (GE Healthcare LUNAR Prodigy Advance, Diegem, Belgium) was performed using standard techniques according to International Society for Clinical Densitometry (ISCD)

Fig. 1. Flow chart for the selection of patients with exclusion criteria.



BMD = bone mineral density

guidelines.

Pelvic bone MDCT without contrast enhancement was performed using MDCT scanners (64 Sensation; Somatom Perspective, all from Siemens Medical Solutions, Erlangen, Germany). The MDCT parameters were as follows: tube voltage, 120–130 kVp; effective tube current, 120–150 mAs; collimation, 0.6 mm; slice thickness, 3 mm; pitch, 0.6; field of view, 370–470 mm; window width, 1400; window level, 300.

IMAGE ANALYSIS

Two radiologists with 19 years and 2 years of experience reviewed MDCT and DXA independently. For the DXA analysis, the femoral neck and total hip bone marrow density (BMD) value (g/cm^2) and T-score were included. The T-score represents the standard deviation (SD) of the difference between a patient's BMD and that of a young-adult reference population, and is used for men above 50 years of age and postmenopausal woman (5). T-scores of the femoral neck were calculated using the U.S. National Health and Nutrition Examination Survey III reference database (6). In this study, each patient was categorized according to their femoral neck T-score based on WHO criteria, into three groups: normal (> -1.0), osteopenia (1.0 and > -2.5) and osteoporosis (≤ -2.5). We analyzed BMD values and T-scores for identification of the relationship with the MDCT HU values.

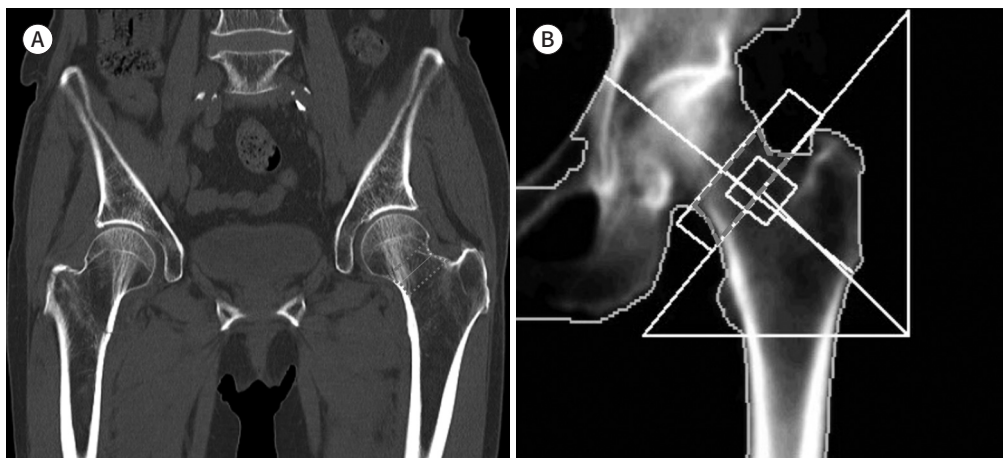
The HU of the femur on the MDCT images was measured on the normal contralateral side of the femoral neck. The HU value is a standardized X-ray attenuation coefficient of tissue, based on a defined scale of 0 for water and -1000 for air, which represents the density of tissue (4). Regions of interest (ROI) were outlined on coronal images of the femur. Among the all coronal images, one plane that includes the widest area of the femoral neck was selected. All measurements were isolated to the cancellous portions of the femoral neck, as shown in Fig. 2. We assessed the mean and SD of HU values, area (cm^2) of ROI, and mean HU/area.

Fig. 2. Schema of ROI of the femoral neck in pelvic bone MDCT (A) and femur DXA (B).

A. The center line of the femoral neck (gray line) is identified as the narrowest line between points on the two opposite sides of the femoral neck on the coronal image. ROI of the femoral neck (dashed line) was outlined in the cancellous portion of the femoral neck with a width of 10 mm for HU measurement.

B. The same ROI of the femoral neck is automatically drawn in femur DXA.

DXA = dual energy X-ray absorptiometry, HU = Hounsfield unit, MDCT = multidetector computed tomography, ROI = region of interest



STATISTICAL ANALYSIS

The interreader and intrareader agreement for the HU measurements on MDCT were assessed by using intraclass correlation coefficients (ICC) with a two-way random model.

The Spearman's correlation coefficients were used to evaluate the correlation between the HU and BMD as well as HU and T-scores in each group of patients.

All statistical analysis was performed using the SPSS Statistics 17.0 software (SPSS Inc., Chicago, IL, USA). The *p*-value < 0.05 was considered as statistically significant.

RESULTS

The 42 patients consisted of 16 men (38.1%) and 26 women (61.9%), with a mean age of 77.8 years (range 57–92 years). Among 42 patients, 2 (4.8%) were classified as normal, 17 (40.5%) as osteopenia, and 23 (54.8%) as osteoporosis by the femoral neck T-scores based on WHO criteria.

The DXA results were as follows: T-scores at the femoral neck ranged from -4.2 to 0.0 (mean \pm SD, -2.4 ± 0.9), and BMD values of the femoral neck ranged from 0.401 to 0.942 g/cm² (mean \pm SD, 0.646 ± 0.111 g/cm²). T-scores of the total hip ranged from -4.1 to -0.2 (mean \pm SD, -2.3 ± 0.8), and the BMD value ranged from 0.410 to 0.950 g/cm² (mean \pm SD, 0.673 ± 0.098 g/cm²) (Table 1).

The MDCT results were shown in Table 2. The HU values at the femoral neck ranged from -25.5 to 163.6 (mean \pm SD, 68.9 ± 46.6) by reader 1 and from -27.1 to 166.4 (mean \pm SD, 63.4 ± 43.0) by reader 2. The mean area (cm²) of ROI was 3.4 cm² by reader 1 and 3.7 by reader 2, respectively.

The interreader agreement between two radiologists for the HU measurements on MDCT was good with an ICC of 0.942 [95% confidence interval (CI), 0.895 to 0.969, *p* < 0.001]. The in-

trareader agreement was also good with an ICC of 0.971 (95% CI, 0.948 to 0.985, $p < 0.001$).

The mean HU values were 131.9 (95% CI, 123.4 to 140.4) in the normal group, 98.9 (95% CI, 34.3 to 163.6) in the osteopenia group, and 41.3 (95% CI, -25.5 to 116.4) in the osteoporosis group by reader 1. The mean HU values were 115.5 (95% CI, 110.7 to 120.3) in the normal group, 92.5 (95% CI, 37.2 to 166.4) in the osteopenia group, and 37.4 (95% CI, -27.1 to 110.8) in the osteoporosis group by reader 2 (Fig. 3).

HU values were positively correlated with BMD, as measured at the femoral neck (reader 1:

Table 1. Mean BMD Value and T-score of Femoral Neck and Total Hip

	BMD (g/cm ²)	T-Score
Femoral neck	0.646 ± 0.111	-2.4 ± 0.9
Total hip	0.673 ± 0.198	-2.3 ± 0.8

Values are the mean ± standard deviation.
BMD = bone mineral density

Table 2. Mean HU Measurement of Femoral Neck from Each Reader

	Reader 1	Reader 2
Mean HU ± SD	68.9 ± 46.6	63.4 ± 43.0
Area (cm ²)	3.4 ± 0.8	3.8 ± 0.9
Mean HU/area	22.3 ± 17.8	18.6 ± 15.8

HU = Hounsfield unit, SD = standard deviation

Fig. 3. Box plot of HU value at femoral neck according to different BMD categories by femur DXA measured by reader 1 (A) and reader 2 (B). Numbers are represents maximum HU at upper end, minimum HU at lower end, and mean HU at 'x' mark.
BMD = bone mineral density, DXA = dual-energy X-ray absorptiometry, HU = Hounsfield unit

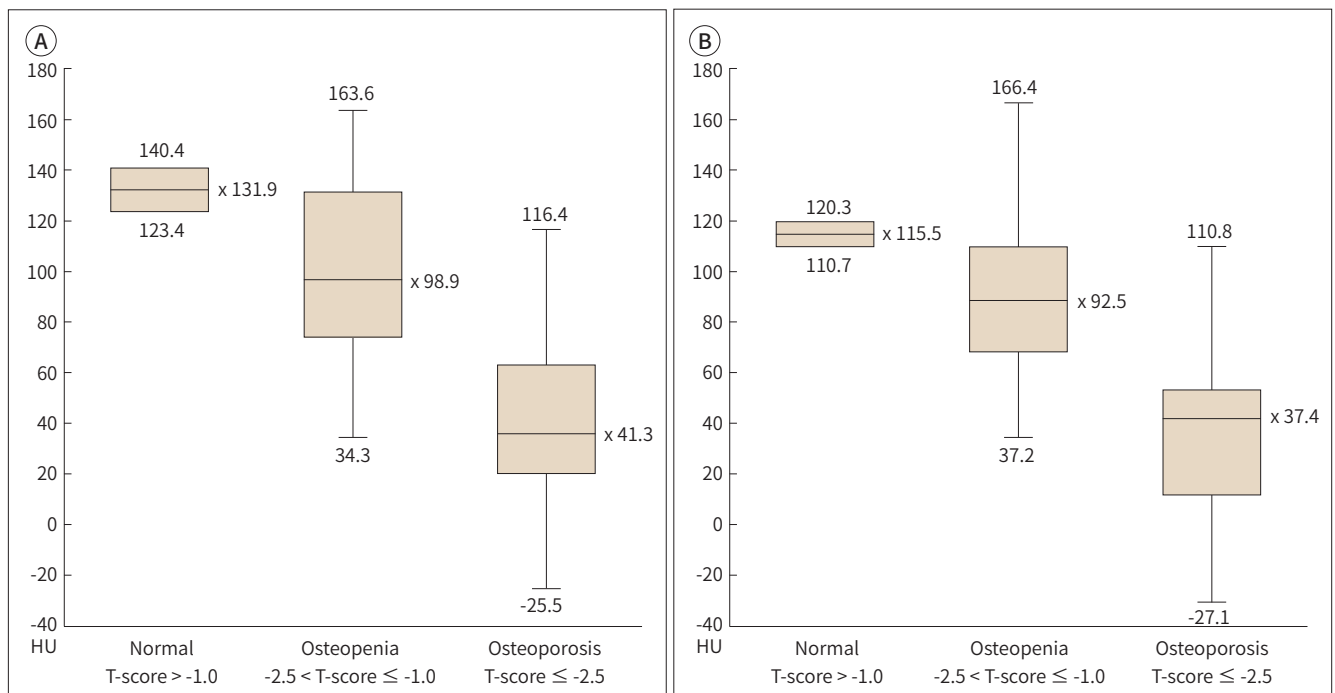


Table 3. Correlation between HU Value with BMD Value and T-Scores by DXA at Femoral Neck from Each Reader

	r^2	p -Value
Reader 1		
BMD	0.670*	< 0.001 [†]
T-score	0.676*	< 0.001 [†]
Reader 2		
BMD	0.713*	< 0.001 [†]
T-score	0.716*	< 0.001 [†]

*Correlation coefficient value between HU on MDCT and BMD or T-score on DXA at femoral neck.

[†] p -value < 0.05.

BMD = bone mineral density, DXA = dual energy X-ray absorptiometry, HU = Hounsfield unit, MDCT = multi-detector computed tomography

$r^2 = 0.670$, $p < 0.001$, reader 2: $r^2 = 0.713$, $p < 0.001$). HU values were also associated with T-scores of the femoral neck (reader 1: $r^2 = 0.676$, $p < 0.001$, reader 2: $r^2 = 0.716$, $p < 0.001$), as summarized in Table 3.

DISCUSSION

In previous studies, Schreiber et al. (3) identified a correlation of similar magnitude between lumbar spine HU measurements with lumbar spine BMD and T-score. Pervaiz et al. (7) also reported a significant correlation between HU measurements of the proximal humerus and femoral neck BMD and T-score. Furthermore, moderate correlations were also reported between HU measurements and BMD in the multiple regions by Lee et al. (8). In our study with a mean age of 77.8 years, HU values of the femoral neck were positively correlated with BMD. Heidari et al. (9) indicated that diabetes, obesity, and higher muscle strength were associated with higher BMD, while anemia and prior fracture were associated with lower BMD, after adjustment for all covariates.

According to ISCD guidelines, indications for bone densitometry are as follows: women aged 65 and older, postmenopausal women below 65 with risk factors, men aged 70 and older, adults with a fragility fracture, adults with a disease or condition associated with low bone mass or bone loss, adults taking medications associated with low bone mass or bone loss, anyone being considered for pharmacologic therapy, anyone being treated, to monitor treatment effect, anyone not receiving therapy in whom evidence of bone loss would lead to treatment (6).

At our institution, about 70% of patients with femoral neck fractures had undergone a DXA examination. This reveals that not all patients with fractures undergo an osteoporosis screening. The results of this study mean that a patient's bone density can be evaluated based on a diagnostic MDCT scan that may already be available. Because HU values measured by MDCT correlate with BMD values that are obtained by DXA, clinicians have an additional tool for determining patients at high risk who require further evaluation and intervention for osteoporosis. In this manner, the HU value may be used as a guide to performing further examinations such as DXA for osteoporosis.

DXA is the gold standard for the diagnosis of osteoporosis. Still, when an MDCT scan has already been taken during the diagnostic process of femoral neck fractures, the information of the patient's bone quality is immediately available to clinicians by measuring HU values. Furthermore, the interreader and intrareader agreement were excellent (ICC, 0.942, and 0.971) for HU measurements in this study. Lee et al. (8) showed lower interobserver and intraobserver reliability (ICC, 0.505, and 0.691) for HU measurement at the femoral neck. The difference in the interreader variance between both studies seemed to be dependent on the ROI setting. Small circular ROI was used in Lee et al. (8), while a large ROI including the all cancellous portion of the femoral neck in one coronal plane with the widest area of the femoral neck was used in our study. Therefore, marrow and trabeculae of the femoral neck could be relative constantly measured and reflected HU.

The retrieval of DXA data available from MDCT requires no additional cost, time, equipment, or radiation (10). This opportunistic screening method will increase the detection of osteoporosis and give the appropriate treatment to reduce fracture risk. Also, this leads to overall cost savings and a reduction in the number of normal DXA studies needed (11).

The plain radiography of hip has also been investigated to evaluate bone mineral density in previous studies (12). The parameters, including hip axis length, femoral neck-shaft angle, femoral neck width, and femoral neck cortical thickness, from the DXA scans and from the plain radiograph, were significantly correlated. Also, a femoral neck cortical thickness less than 0.29 mm in both DXA and the plain radiograph showed a significant correlation with osteoporosis. These radiographic parameters demonstrate that routine radiographs may also have a role in bone quality assessment.

Our study has several limitations. First, the data were obtained from elderly patients who had femoral neck fractures. In general, these patients had decreased bone mineral density compared with the population as a whole. Therefore, these data may not accurately represent the general population. Second, with developed technologies such as quantitative computed tomography, HU analysis seems like an overly simplistic approach to bone mineral density. However, we suggest HU measurement as a supplementary tool, not as a replacement method, due to its wide availability and easy interpretability. Third, DXA scans analyze both cancellous and cortical bone, and our assessment of the HU value involved evaluation of only cancellous bone, which may have led to some differences between the DXA findings and the HU values. Also, positioning of the femur was internal rotation by 15–20° to make femoral neck axis parallel to plane of scan table during DXA scan, while this positioning was not constantly achieved during pelvic bone MDCT in patients with femoral neck fracture of our study. Fourth, our study was retrospective nature, and there was a small number of patients studied, which may have affected the statistical power. Finally, other risk factors of osteoporosis, such as diabetes, obesity, muscle strength, anemia, prior fracture, smoking status, alcohol use, and hormonal status, were not analyzed in this study (13).

The measurement of the HU value from a region of interest designation on an MDCT image can be done accurately and reliably with minimal time or training requirements. We demonstrated that the HU values of the femoral neck on pelvic bone MDCT image are significantly correlated with BMD values and T-scores of the femoral neck. Therefore, the HU value may serve as a diagnostic tool for the screening of regional bone quality when MDCT is

performed for other reasons, thereby alerting the physician to conduct an additional work-up in individuals in whom osteoporosis may be suspected.

Author Contributions

Conceptualization, all authors; data curation, all authors; formal analysis, all authors; funding acquisition, H.J.Y.; investigation, all authors; methodology, all authors; project administration, H.J.Y.; resources, H.J.Y.; supervision, H.J.Y.; visualization, all authors; writing—original draft, L.H.J.; and writing—review & editing, H.J.Y.

Conflicts of Interest

The authors have no potential conflicts of interest to disclose.

Acknowledgments

We thank professor Ji Eun Park (Asan Medical Center) for providing software and useful discussions on the study.

REFERENCES

1. Gerety EL, Hopper MA, Bearcroft PW. The reliability of measuring the density of the L1 vertebral body on CT imaging as a predictor of bone mineral density. *Clin Radiol* 2017;72:177.e9-177.e15
2. Gausden EB, Nwachukwu BU, Schreiber JJ, Lorch DG, Lane JM. Opportunistic use of ct imaging for osteoporosis screening and bone density assessment: a qualitative systematic review. *J Bone Joint Surg Am* 2017;99:1580-1590
3. Schreiber JJ, Anderson PA, Rosas HG, Buchholz AL, Au AG. Hounsfield units for assessing bone mineral density and strength: a tool for osteoporosis management. *J Bone Joint Surg Am* 2011;93:1057-1063
4. Johnson CC, Gausden EB, Weiland AJ, Lane JM, Schreiber JJ. Using Hounsfield units to assess osteoporotic status on wrist computed tomography scans: comparison with dual energy x-ray absorptiometry. *J Hand Surg Am* 2016;41:767-774
5. Lewiecki EM, Binkley N, Morgan SL, Shuhart CR, Camargos BM, Carey JJ, et al. Best practices for dual-energy x-ray absorptiometry measurement and reporting: International society for clinical densitometry guidance. *J Clin Densitom* 2016;19:127-140
6. Leib ES, Lewiecki EM, Binkley N, Hamdy RC; International Society for Clinical Densitometry. Official positions of the International Society for Clinical Densitometry. *J Clin Densitom* 2004;7:1-6
7. Pervaiz K, Cabezas A, Downes K, Santoni BG, Frankle MA. Osteoporosis and shoulder osteoarthritis: incidence, risk factors, and surgical implications. *J Shoulder Elbow Surg* 2013;22:e1-e8
8. Lee SY, Kwon SS, Kim HS, Yoo JH, Kim J, Kim JY, et al. Reliability and validity of lower extremity computed tomography as a screening tool for osteoporosis. *Osteoporos Int* 2015;26:1387-1394
9. Heidari B, Muhammadi A, Javadian Y, Bijani A, Hosseini R, Babaei M. Associated factors of bone mineral density and osteoporosis in elderly males. *Int J Endocrinol Metab* 2017;15:e39662
10. Pickhardt PJ, Pooler BD, Lauder T, Del Rio AM, Bruce RJ, Binkley N. Opportunistic screening for osteoporosis using abdominal computed tomography scans obtained for other indications. *Ann Intern Med* 2013;158:588-595
11. Pickhardt PJ, Lee LJ, Del Rio AM, Lauder T, Bruce RJ, Summers RM, et al. Simultaneous screening for osteoporosis at CT colonography: bone mineral density assessment using MDCT attenuation techniques compared with the DXA reference standard. *J Bone Miner Res* 2011;26:2194-2203
12. Vaseenon T, Chaimuang C, Phanphaisarn A, Namwongprom S, Luevitonvechkij S, Rojanasthien S. Correlation of proximal femoral bone geometry from plain radiographs and dual energy X-ray absorptiometry in elderly patients. *J Med Assoc Thai* 2015;98:39-44
13. Simon LS. Osteoporosis. *Rheum Dis Clin North Am* 2007;33:149-176

대퇴골 경부 골절 환자에서 골다공증 평가를 위한 다중검출 CT의 이용: 이중에너지 X선 흡수계측법과의 비교

이효정 · 황지영*

목적 대퇴골 경부 골절 환자를 대상으로 골다공증 평가를 위해 다중검출 전산화단층촬영 (multidetector computed tomography; 이하 MDCT)에서의 감쇠 계수(Hounsfield unit; 이하 HU)와 이중 에너지 X선 흡수 계측법(dual energy X-ray absorptiometry; 이하 DXA)을 비교하였다.

대상과 방법 2016년 6월부터 12월까지 MDCT와 DXA를 모두 시행한 42명의 대퇴골 경부 골절 환자가 본 연구의 대상으로 포함되었다. MDCT에서는 정상 대퇴골 경부의 해면골에서 HU를 측정하였으며 DXA에서는 동 부위의 골밀도 및 T 값을 얻었다. HU와 골밀도 및 T 값의 상관관계를 Spearman 상관계수를 이용하여 분석하였다.

결과 대퇴골 경부 골절 환자의 골밀도와 T 값의 평균은 각각 0.650 g/cm^2 과 -2.4 이었다. 정상, 골감소증, 골다공증 환자 군의 HU의 평균은 각각 131.9, 98.9, 41.3이었다. HU는 골밀도($r^2 = 0.670; p < 0.001$) 및 T 값($r^2 = 0.676; p < 0.001$) 모두와 양의 상관관계를 보였다.

결론 다중검출 전산화단층촬영에서 감쇠계수의 측정은 골다공증 선별검사를 위한 유용한 진단적 도구가 될 수 있다.

이화여자대학교 의과대학 영상의학교실