

# *Acta Medica Okayama*

---

*Volume 54, Issue 6*

2000

*Article 1*

DECEMBER 2000

---

## Muscle fiber type distribution in multifidus muscle in cases of lumbar disc herniation.

Snjezana Bajek\*

Dragica Bobinac<sup>†</sup>

Goran Bajek<sup>‡</sup>

Tamara Soic Vranic\*\*

Boris Lah<sup>††</sup>

Daniela Malnar Dragojevic<sup>‡‡</sup>

\*University of Rijeka,

<sup>†</sup>University of Rijeka,

<sup>‡</sup>University of Rijeka,

\*\*University of Rijeka,

<sup>††</sup>Clinical Orthopedic Hospital,

<sup>‡‡</sup>University of Rijeka,

# Muscle fiber type distribution in multifidus muscle in cases of lumbar disc herniation.\*

Snjezana Bajek, Dragica Bobinac, Goran Bajek, Tamara Soic Vranic, Boris Lah, and Daniela Malnar Dragojevic

## Abstract

A study was conducted to analyze the distribution and diameter of muscle fiber types in samples of the medial paravertebral lumbar muscle, i.e., multifidus muscle, obtained from 76 patients who underwent surgery for disc herniation. The samples were compared with 41 control samples of corresponding muscle tissue taken from 41 young healthy subjects who had died a sudden death. Histochemical analysis of fibers associated with myofibrillar adenosine triphosphatase (AT-Pase) revealed the presence of Type I fibers (slow-twitch fibers) and of Type IIA and IIB fibers (fast-twitch fibers) in both the experimental and control samples. The respective percentage of muscle fibers was calculated and their diameters were measured. Type I fibers predominated in both groups and were significantly larger in diameter than Type IIA and IIB fibers. Both fast-twitch fiber types were distributed in almost equal proportions in the healthy women. In the healthy men, Type IIA fibers prevailed. In the healthy females, the percentage of Type I fibers was found to be slightly higher than in the males, but the diameter of all fiber types was respectively smaller. In the females who had undergone surgery, Type I fibers were significantly larger in diameter than those of the healthy subjects. On the other hand, the diameters of all muscle fiber types were significantly larger, and the percentage of both fast-twitch fibers were lower in the samples from men who underwent surgery, as compared to the healthy tissue samples. The morphometric changes in the multifidus muscle at the level of the protruded disc observed by the histochemical method for demonstration of myofibrillar ATPase could not be related to the compressed nerve root in the majority of cases in our study.

**KEYWORDS:** multifidus muscle, histochemistry, disc herniation, muscle fiber types

---

\*PMID: 11132916 [PubMed - indexed for MEDLINE]

Copyright (C) OKAYAMA UNIVERSITY MEDICAL SCHOOL

## Muscle Fiber Type Distribution in Multifidus Muscle in Cases of Lumbar Disc Herniation

Snježana BAJEK<sup>a\*</sup>, Dragica BOBINAC<sup>a</sup>, Goran BAJEK<sup>b</sup>, Tamara Šoić VRANIĆ<sup>a</sup>, Boris LAH<sup>c</sup> and Daniela Malnar DRAGOJEVIĆ<sup>a</sup>

<sup>a</sup>Department of Anatomy, School of Medicine, University of Rijeka 51000, Croatia, <sup>b</sup>Department of Neurosurgery, Clinical Hospital, University of Rijeka, Croatia and <sup>c</sup>Clinical Orthopedic Hospital, Lovran 51415, Croatia

A study was conducted to analyze the distribution and diameter of muscle fiber types in samples of the medial paravertebral lumbar muscle, i.e., multifidus muscle, obtained from 76 patients who underwent surgery for disc herniation. The samples were compared with 41 control samples of corresponding muscle tissue taken from 41 young healthy subjects who had died a sudden death. Histochemical analysis of fibers associated with myofibrillar adenosine triphosphatase (ATPase) revealed the presence of Type I fibers (slow-twitch fibers) and of Type IIA and IIB fibers (fast-twitch fibers) in both the experimental and control samples. The respective percentage of muscle fibers was calculated and their diameters were measured. Type I fibers predominated in both groups and were significantly larger in diameter than Type IIA and IIB fibers. Both fast-twitch fiber types were distributed in almost equal proportions in the healthy women. In the healthy men, Type IIA fibers prevailed. In the healthy females, the percentage of Type I fibers was found to be slightly higher than in the males, but the diameter of all fiber types was respectively smaller. In the females who had undergone surgery, Type I fibers were significantly larger in diameter than those of the healthy subjects. On the other hand, the diameters of all muscle fiber types were significantly larger, and the percentage of both fast-twitch fibers were lower in the samples from men who underwent surgery, as compared to the healthy tissue samples. The morphometric changes in the multifidus muscle at the level of the protruded disc observed by the histochemical method for demonstration of myofibrillar ATPase

could not be related to the compressed nerve root in the majority of cases in our study.

**Key words:** multifidus muscle, histochemistry, disc herniation, muscle fiber types

**S**low twitch fibers (Type I) predominate in tonic muscles and tend to assume a postural role. In contrast, fast twitch fibers (Type II) occupy a relatively larger area in those muscles whose primary function is to perform fast movements; some muscles of extremities would fall under the latter category (1). Moreover, due to the differentiated functions and various roles of particular segments of the same muscle, each segment has a different histochemical profile (2).

The function of paravertebral lumbar musculature is to control posture and to stabilize joints. These functions are carried out primarily by slow twitch fibers, which are fatigue-resistant and consequently predominant in this musculature (3-7). These muscles are active in most everyday situations. However, modern lifestyles rarely require that they be fully contracted.

Degenerative changes in the intervertebral disc result in altered mutual relationships between particular elements in the lumbar region. Such degeneration thus frequently provokes disc-radicular conflict, i.e., pressure of the protruded nucleus pulposus against the spinal lumbar nerve root. Such changes can be expected to affect the condition of lumbar paravertebral muscles, most notably, the multifidus muscle, which now have to cope with different and newly imposed demands on an unstable segment. Moreover, possibly deranged innervation can

---

\* To whom correspondence should be addressed.

exacerbate the problem. The aim of this study was to investigate, by means of a histochemical method, the extent of the morphological changes provoked by altered biodynamic relationships in this spinal segment. In addition, the potential for deranged innervation of the multifidus muscle in patients operated on for disc herniation was investigated.

Various authors have reported their analyses of deep lumbar muscle tissue in healthy and physically active young adults (3, 6, 7). These results confirm the primarily static function of this muscle, which is characterized by a predominance of Type I fibers and a trend toward homogeneity of the size of all fiber types in this region. However, in the present study, the size of fast-twitch IIA and IIB fibers in women was found to be relatively smaller than the size of the slow-twitch fibers (3, 7). Data from previous studies were obtained, for the most part, from the samples dissected from the corpses of people who had died a sudden death. Those tissue samples presented a mosaic distribution with a slightly greater percentage of Type I fibers (4-6, 8) as well as a comparatively larger diameter of this fiber type than that of Type II fibers.

There have been several analyses of these muscles as regards disturbances of the lumbar segment of the spine. Some of the disturbances included in previous studies are: instability of the segment, spondylolisthesis, disc prolapse, and degenerative change in the lumbosacral area with accompanying nerve root compression. Fidler *et al.* (4) reported a relatively higher percentage of slow twitch fibers associated with a variety of disturbances; only 7 of the cases discussed in that study involved disc protrusions. Overall, the muscles generally maintained a mosaic aspect; Type II fibers were slightly smaller in diameter than Type I fibers. Ford *et al.* (9) have suggested that paravertebral muscles in patients who underwent surgery for disc disorders can be regarded as representative of healthy, unchanged muscles, in which Type I fibers predominate and are relatively larger in diameter than Type II fibers. Similar relations between fiber types were observed in cadaver muscle samples, as well as in the samples obtained during surgery for disc herniation described by Širca and Kostevc (5). However, the latter study presented fibers with a relatively smaller diameter than that of fibers from healthy subjects. This observation was ascribed to the patients' prolonged limitation of lumbar motion. According to Zhu *et al.*, limited mobility is also accountable for the reduction in diameter of Type

IIA and IIB fibers in patients who had undergone similar surgery (10). Mattila *et al.* (8) reported an almost identical distribution of fibers in patients who had undergone surgery for disc herniation and in control group; however, a slightly reduced diameter of both fiber types was observed in the female patients, and in males, increased diameter was observed in both types of fibers. Bagnall *et al.* (11) investigated 19 patients with lumbar spine disorders and found a relative predominance of Type I fibers as well as a larger diameter of these fibers in comparison with Type II fibers. It should be noted, however, that these findings were contrasted with findings in the unaffected side of the vertebral column rather than with those observed in a control group. Comparatively larger slow-twitch fibers were observed in patients with chronic low back pain (12). In general, these reports point out the great variety in the histological findings. As a result, there is little consensus at the interpretive level. For example, some authors have labeled such paravertebral musculature as "normal" without comparing it to a control group (11).

## Materials and Methods

**Material.** The investigation was approved by the ethics committee of Rijeka University Medical School. Biopsic material from the multifidus muscle was obtained from patients who underwent surgery for disc herniation. Informed consent was obtained from all subjects. The disc herniations were unilateral (45 left-side and 31 right-side) and single-level (3 at L3-L4, 51 at L4-L5, and 22 at L5-S1). The patients had clinically evident symptoms of nerve root compression. The specimens were taken at the L3-L4 or L4-L5 or L5-S1 level, 1 cm lateral from the midline on the side of extrusion deeper than the aponeurosis of the erector spinae muscle. The patients were 76 adults (30 women) ranging in age between 27 and 67 years (mean age 47.2) who had suffered from the disorder between 6 months and 2.5 years with intermittent occurrences prior to the surgery. The control group consisted of 41 people who had died a sudden death and who had not suffered from neuromuscular diseases. They ranged in age between 17 and 50 years (mean age 34.8). Six of the subjects were women. The specimens from the control group were taken at the level between the fourth and fifth lumbar vertebra, deeper than the aponeurosis of the erector spinae muscle, 1 cm lateral from the midline, up to 48 h after death.

**Methods.** Muscle samples were frozen in isopentane cooled in liquid nitrogen and cut into 10  $\mu\text{m}$ -thick serial cross-sections at  $-20^\circ\text{C}$ . Fibers were classified as either Type I or Type II on the basis of myofibrillar ATPase activity shown at pH 9.4. Subgroup typing, *i.e.*, typing for IIA, IIB, and IIC, was performed after preincubation at pH 4.3 and 4.6 (13). The cross-sections of some of the samples were then further stained with Van Gieson stain for 5 min, washed in distilled water for 5 min, dehydrated in 96% and 100% alcohol, and then were inserted into Canadian balm.

Quantitative analysis was performed using Sform (VAMS, Croatia), which is software for quantitative microscope image analysis. An Olympus BX50 microscope, a Pulnix 765 video camera, and a Sony Triton display were used for obtaining images. The data obtained refer to the relative percentage and diameter of Type I, Type IIA, IIB, and IIC fibers. Between 400 and 1,100 fibers were counted per sample for the percentage assessment. The smaller fibers' diameters (14) were measured on 200–300 sample fibers. The findings were evaluated using the software program Statistica for Windows, and the percentage and diameter values of each group were mutually contrasted using Student's *t*-test for independent samples. A probability of 0.05 or less was accepted as statistically significant ( $P < 0.05$ ).

## Results

Histochemical analysis of multifidus muscle samples taken from the control group (Fig. 1) revealed a mosaic distribution of muscle fibers with a higher percentage of

Type I fibers in all but 2 samples in which Type II fibers predominated. Distribution of Type IIA and IIB fibers was fairly even in women. In men, Type IIA was significantly more predominant than it was in women. In both sexes, Type I fibers were found to be significantly larger in diameter than Type IIA and IIB fibers (Table 1). The wide range of findings points to deviations in fiber distribution and size. Furthermore, in a single cross-section with a mosaic distribution (in 19% of subjects), fascicles that contained almost exclusively the slow-twitch fibers, were observed. In women, the relative percentage of Type I fibers was slightly greater than in men, but the diameter of all 3 fiber types was smaller. The smallest fibers in both sexes were the Type IIB fibers. A subtle



**Fig. 1** Multifidus muscle of a male (36 years) from the control group. Mosaic distribution of muscle fiber types; ATPase at pH 9.4; dark fibers are Type II;  $\times 100$ ; bar = 100  $\mu\text{m}$ .

**Table 1** The percentage and diameter of fiber types in multifidus muscle in the control group and the operated persons (mean values  $\pm$  SD)

	Control group		Operated persons	
	Female (N = 6)	Male (N = 35)	Female (N = 30)	Male (N = 46)
Age	33.80 $\pm$ 4.07	35.70 $\pm$ 10.49	47.70 $\pm$ 9.02	46.80 $\pm$ 9.25
Type I fiber percent (%)	65.98 $\pm$ 8.29	60.76 $\pm$ 6.89	66.40 $\pm$ 11.17	67.40 $\pm$ 10.87*
Type IIA fiber percent (%)	16.40 $\pm$ 4.68	21.72 $\pm$ 7.14	18.81 $\pm$ 6.36	18.16 $\pm$ 6.55*
Type IIB fiber percent (%)	17.62 $\pm$ 7.45	17.48 $\pm$ 6.17	14.79 $\pm$ 8.19	14.23 $\pm$ 6.26*
Type I fiber diameter ( $\mu\text{m}$ )	53.92 $\pm$ 7.88 <sup>°</sup>	62.16 $\pm$ 6.06 <sup>°</sup>	69.61 $\pm$ 12.95**	69.94 $\pm$ 10.27**
Type IIA fiber diameter ( $\mu\text{m}$ )	41.51 $\pm$ 3.73	49.67 $\pm$ 8.67	44.90 $\pm$ 11.77	56.02 $\pm$ 10.27*
Type IIB fiber diameter ( $\mu\text{m}$ )	36.97 $\pm$ 4.12	42.85 $\pm$ 8.72	39.23 $\pm$ 10.04	48.27 $\pm$ 10.74*

\*, statistically significant difference as compared to the control group ( $P < 0.05$ ); <sup>°</sup>, statistically significant difference as compared to Type IIA and IIB fibers of the same group ( $P < 0.05$ ).

grouping of muscle fiber types was observed in 3 subjects (7.3%).


Histochemical findings of the multifidus muscle samples obtained from patients who underwent surgery for disc herniation (Figs. 2 and 3) also demonstrated (*cf.* Table 1 for the control group) an overall greater proportion of Type I fibers as well as a larger diameter in this Type of fiber as compared to Type IIA and IIB fibers in both sexes. In particular, comparison of fiber distribution between the experimental and control subjects revealed a significantly higher percentage of Type I fibers and a lower percentage of Type IIA and IIB fibers ( $P < 0.05$ ) in men only; no such differences were observed in

the tissue samples from women. As regards size, the diameter of Type I fibers was significantly larger in the subjects who had undergone surgery, particularly among the women ( $P < 0.01$ ). In contrast, the Type IIA and IIB diameters of tissue from males in the experimental group were found to be significantly larger than in the control tissue ( $P < 0.01$  and  $P < 0.05$ , respectively). In women this difference was not significant. In both sexes and groups, Type IIB fibers were the smallest. (Fig. 4).

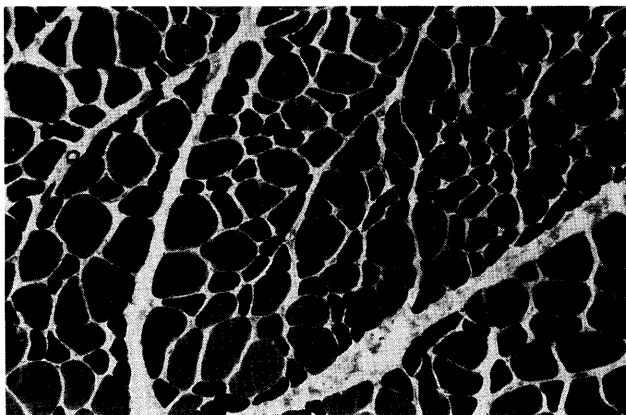
In 5 (6.5%) of the patients, a prevalence of fast-twitch fibers was observed. As in some muscle samples taken from healthy individuals, the cross sections in a general mosaic pattern, revealed segments of Type II fiber prevalence. Occasionally (in 21% of the patients), individual fascicles were found to contain almost exclusively Type I fibers. A subtle grouping of fiber types was observed in 10.5% patients (Fig. 5). In 2 (2.6%) patients, a small fascicle with atrophic fibers that were difficult to classify was observed. Intermediate fibers (IIC) occurred rarely (0.3–1.9) in both the study group and controls.

## Discussion


The present study, consistent with previous findings (5, 8, 12, 15, 16) revealed the prevalence of slow-twitch fibers, *i.e.*, tonic fatigue-resistant fibers, in multifidus muscles in both the study group and in the controls. Fast-twitch Type IIA and Type IIB fibers were generally evenly distributed. Type IIA fibers prevailed only in men. In both of our groups of subjects, Type IIA and IIB



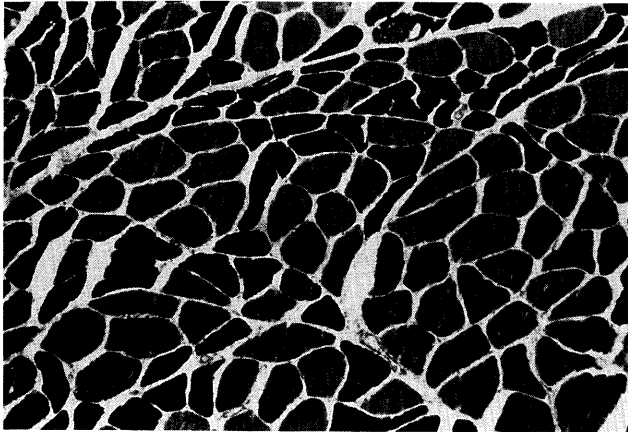
**Fig. 2** Multifidus muscle of a male patient (40 years). Predominant Type I muscle fibers (dark); ATPase at pH 4.3;  $\times 100$ .



**Fig. 3** Multifidus muscle of a female patient (52 years). Type II muscle fibers are smaller than Type I muscle fibers; ATPase at pH 9.4 combined with Van Gieson staining;  $\times 100$ .



**Fig. 4** Multifidus muscle of a male patient (33 years). Type IIB fibers are the smallest; ATPase at pH 4.6;  $\times 100$ .



**Fig. 5** Multifidus muscle of a male patient (31 years). Subtle clustering of fiber types; ATPase at pH 9.4 combined with Van Gieson staining;  $\times 100$ .

fibers tended to be smaller than Type I fibers. This finding suggests the less frequent activation of fast-twitch fibers in these patients. Such fibers are not resistant to fatigue, but are required for powerful and fast contractions. This in turn points to the fact that disc herniation does not provoke any changes in the interrelationship between fast and slow-twitch fibers, as has commonly been demonstrated in previous studies of this muscle, which has a primarily postural function. The smaller relative size and percentage of fast-twitch fibers may be a consequence of modern lifestyles, rarely require frequent, powerful contractions and heavy instant demands that would necessitate fast-twitch fibers. It is possible that the relatively larger size of muscle fibers in men as compared to women reflects the fact that men more frequently perform strenuous physical activities than do women. The higher percentage of Type IIA fibers observed in the healthy men as compared to the healthy women seems to further support this hypothesis. On the other hand, the relative percentages of IIA and IIB fibers in the subjects who underwent surgery were not significantly altered. Some authors have found twice the number of Type IIB fibers than Type IIA fibers in patients with disc herniation. In addition, the patients, particularly the females, display smaller Type IIA and IIB fibers than Type I fibers, (10).

The diameter of all 3 fiber types found in multifidus muscle samples in our study was significantly larger in male patients who underwent surgery for disc herniation than in the control group. It is possible that these muscles

become partially denervated due to nerve root compression, or that they are spared due to pain or for therapeutical purposes. Such assumptions would lead us to expect to find these muscles in varying states of atrophy. In addition, one could expect that the pressure on the nerve root due to dorsolateral disc hernia might also affect axons in the dorsal ramus of the lumbar spinal nerve innervating the autochthonous deep dorsal musculature. This pressure would consequently provoke changes at the cellular level. Although compressed nerve fibers can cause denervation of the corresponding muscle fibers with resulting progressive atrophy, the axons of the non-affected motoneurons that persist ramify and extend towards these denervated muscle fibers, thus forming large aggregates of muscle fibers of uniform histochemical staining (17). Not surprisingly, therefore, the expected atrophy is not necessarily observed. Disc herniation most commonly provokes pressure on the root of one level below the herniation. Occasionally, the same level or the level above herniation will undergo excess pressure (18). In other words, the lateral disc protrusion at level L4-L5 will most often provoke pressure on the root of the fifth spinal nerve. A detailed anatomical study conducted by Macintosh *et al.* in 1986 (19) demonstrated that the multifidus muscle is unisegmentally innervated. If applied to the present example, this would lead us to expect denervation of the multifidus muscle fascicle that originates from the spinal process of the fifth lumbar vertebra; that fascicle lies low along the spinal process of the first sacral segment. Consequently, as a muscle sample is taken from the level between the spinous processes L4 and L5, there is no reason to expect changes in it due to the pressure on the root of the fifth spinal nerve. Some authors have discussed longitudinal changes in distribution due to the continuous processes of denervation and reinnervation associated with normal ageing; the grouping pattern found in older people is probably the result of a process which began in their fifties (20). This could explain our observation of fiber type grouping in a small number of patients, as their mean age was higher than that of the control group. Another possible explanation for the grouping is a disturbance in the function of the lumbar dorsal ramus due to the changes in the neighboring bony and ligamentous structures and the resulting dorsal ramus syndrome (21).

As regards the activity of paravertebral muscles there are some differences between healthy individuals and subjects with lower back pain. In healthy individuals,

kinetic electromyography reveals hardly any activity in the erector spinae muscle (2 cm from the spinous process L4) in a standing position, whereas in patients, activity is registered in this muscle (22). This difference could suggest that in patients, there is a constant activity in these muscles at almost every moment. At full flexion, relaxation is present in healthy individuals, but is absent in most patients (22). Thus, in patients there is greater demand on these muscles that are rarely relaxed. Moreover, muscle activity during flexion is greater in patients than in healthy individuals. In patients with hypermobility of the lumbar segment, the healthy segments show an even more intense activity than the corresponding regions in healthy individuals. This finding could be interpreted as being due to compensation carried out by the neighboring healthy segments (23). Therefore, it is not surprising that no reduction was observed in the size of the fibers in this study. Spasm of paravertebral lumbar muscles is typical of patients with lower back pain (21). Such continuous contraction could prevent atrophy and even lead to an increase in the diameter of muscle fibers, as was the case in most patients with disc herniation in our study. Muscle hypertrophy can result from physical exertion when close to the maximum capacity of the muscle is required; hypertrophy can also be due to isometric contractions (17), to which these muscles are constantly exposed (6). The diameter of Type IIA and IIB fibers was significantly larger in the men of the experimental group in our study than in healthy controls. This was not the case with female patients, however. The difference is probably due to the fact that many of the male patients were physical laborers who had developed large fast-twitch fibers prior to the operation.

Our study also found that the diameter of all 3 types of fibers was larger in the patients than in the controls. Referring to studies carried out by Sola *et al.* in 1973. (24), Mattila *et al.* suggested (8) that one of the contributing factors in diameter increase could be the stretching that leads to Type I hypertrophy even in normally innervated, but also in denervated muscles. This could apply to paravertebral muscles as well, as they are the most frequently used and elongated during everyday activities. The lumbar part of the body is frequently extended during the day. For example, while one is bent forward, the lumbar region is elongated. This is one of the most frequent problematic movements made particularly by women doing most of the household work. Some theories hold that extension of muscular cell membrane

represents an anabolic stimulus for the muscular cell and that this stimulus can result in fiber hypertrophy (25). Persisting maintenance of an irregular posture and exaggerated contractions can also lead to disturbed proprioceptor activity and a resulting increase in motoneuron activity (26). Such unnatural, *i.e.*, antalgic positions, are typical of patients who, in their attempt to reduce pain, tend to bend toward the side opposing that of the root compression.

The morphometric changes in multifidus muscle at the level of protruded disc observed by the myofibrillar ATPase method could not be related to the compressed root in the majority of cases in our study. Rather, a corresponding denervation should be found in the more caudal muscle segments in most patients, since such a disc generally compresses the root of one caudal level below the protrusion. On the other hand, the increase in the diameter of muscle fibers at the level of disc herniation could point to increased activity of this musculature compensating for the ineffective denervated lower segments. Increased diameter could also be due to the presence of a spasm. Moreover, such spasmic activity can result in muscle exhaustion and probably moth-eaten or targetoid fibers, as demonstrated in some studies by means of histochemical analysis for NADH activity (8, 9, 16).

Acknowledgments. This work was supported by a grant from the Ministry of Science and Technology (project Nr. 3-01-429).

## References

1. Johnson MA, Polgar J, Weightman D and Appleton D: Data on the distribution of fibre types in thirty-six human muscles. An autopsy study. *J Neurol Sci* (1973) **18**, 111-129.
2. Lindman R, Eriksson A and Thornell LE: Fiber type composition of the human female trapezius muscle: Enzyme-histochemical characteristics. *Am J Anat* (1991) **190**, 385-392.
3. Thorstensson A and Carlson H: Fibre types in human lumbar back muscles. *Acta Physiol Scand* (1987) **131**, 195-202.
4. Fidler MW, Jowett RL and Troup JD: Myosin ATPase activity in multifidus muscle from cases of lumbar spinal derangement. *J Bone Joint Surg Br* (1975) **57**, 220-227.
5. Širca A and Kostevc V: The fibre type composition of thoracic and lumbar paravertebral muscles in man. *J Anat* (1985) **141**, 131-137.
6. Jørgensen K, Nicholaisen T and Kato M: Muscle fiber distribution, capillary density, and enzymatic activities in the lumbar paravertebral muscles of young men. Significance for isometric endurance. *Spine* (1993) **18**, 1439-1450.
7. Mannion AF, Dumas GA, Cooper RG, Espinosa FJ, Faris MW and Stevenson JM: Muscle fibre size and type distribution in thoracic and lumbar regions of erector spinae in healthy subjects without low back pain: Normal values and sex differences. *J Anat* (1997) **190**, 505-



- 513.
8. Mattila M, Hurme M, Alaranta H, Paljärvi L, Kalimo H, Falck B, Lehto M, Einola S and Järvinen M: The multifidus muscle in patients with lumbar disc herniation. A histochemical and morphometric analysis of intraoperative biopsies. *Spine* (1986) **11**, 732-738.
  9. Ford D, Bagnall KM, McFadden KD, Greenhill B and Raso J: Analysis of vertebral muscle obtained during surgery for correction of a lumbar disc disorder. *Acta Anat* (1983) **116**, 152-157.
  10. Zhu XZ, Parniapour M, Nordin M and Kahanovitz N: Histochemistry and morphology of erector spinae muscle in lumbar disc herniation. *Spine* (1989) **14**, 391-397.
  11. Bagnall KM, Ford DM, MCFadden KD, Greenhill BJ and Raso VJ: The histochemical composition of human vertebral muscle. *Spine* (1984) **9**, 470-473.
  12. Rissanen A, Kalimo H and Alaranta H: Effect of intensive training on the isokinetic strength and structure of lumbar muscles in patients with chronic low back pain. *Spine* (1995) **20**, 333-340.
  13. Dubowitz V: Histological and histochemical stains and reactions; in *Muscle Biopsy: A Practical Approach*, 2nd Ed, Bailliere Tindall, London (1985) pp19-40.
  14. Dubowitz V: Definition of pathological changes seen in muscle biopsies; in *Muscle Biopsy: A Practical Approach*, 2nd Ed, Bailliere Tindall, London (1985) pp82-128.
  15. Jowett RL, Fidler MW and Troup JD: Histochemical changes in the multifidus in mechanical derangements of the spine. *Orthop Clin North Am* (1975) **6**, 145-161.
  16. Weber BR, Grob D, Dvorák J and Müntener M: Posterior surgical approach to the lumbar spine and its effect on the multifidus muscle. *Spine* (1997) **22**, 1765-1772.
  17. Adams RD: Experimental pathology; in *Diseases of Muscle: A Study in Patology*, 3rd Ed, Medical Department, Harper & Row, Hagerstown (1975) pp112-203.
  18. Fisher MA, Kaur D and Houchins J: Electrodiagnostic examination, back pain and entrapment of posterior rami. *Electromyogr Clin Neurophysiol* (1985) **25**, 183-189.
  19. Macintosh JE, Valencia F, Bogduk N and Munro RR: The morphology of the human lumbar multifidus. *Clin Biomech* (1986) **1**, 196-204.
  20. Lexell J, Downham D and Sjöström M: Distribution of different fibre types in human skeletal muscles: Fibre type arrangement in *m. vastus lateralis* from three groups of healthy men between 15 and 83 years. *J Neurol Sci* (1986) **72**, 211-222.
  21. Bogduk N: Lumbar dorsal ramus syndrome. *Med J Aust* (1980) **2**, 537-541.
  22. Sihvonen T, Partanen J, Hänninen O and Soimakallio S: Electric behavior of low back muscles during lumbar pelvic rhythm in low back pain patients and healthy controls. *Arch Phys Med Rehabil* (1991) **72**, 1080-1087.
  23. Sihvonen T and Partanen J: Segmental hypermobility in lumbar spine and entrapment of dorsal rami. *Electromyogr Clin Neurophysiol* (1990) **30**, 175-180.
  24. Sola OM, Christensen DL and Martin AW: Hypertrophy and hyperplasia of adult chicken anterior latissimus dorsi muscles following stretch with and without denervation. *Exp Neurol* (1973) **41**, 76-100.
  25. Hofman WW: Mechanisms of muscular hypertrophy. *J Neurol Sci* (1980) **45**, 205-216.
  26. Bentley S: Exercise-induced muscle cramp. Proposed mechanisms and management. *Sports Med* (1996) **21**, 409-420.

---

Received December 21, 1999; accepted April 12, 2000.