

AperTO - Archivio Istituzionale Open Access dell'Università di Torino

Musculoskeletal ultrasonography for psoriatic arthritis and psoriasis patients: a systematic literature review

This is a pre print version of the following article:

Original Citation:

Availability:

This version is available <http://hdl.handle.net/2318/1642658> since 2017-06-20T17:51:12Z

Published version:

DOI:10.1093/rheumatology/kex179

Terms of use:

Open Access

Anyone can freely access the full text of works made available as "Open Access". Works made available under a Creative Commons license can be used according to the terms and conditions of said license. Use of all other works requires consent of the right holder (author or publisher) if not exempted from copyright protection by the applicable law.

(Article begins on next page)

TITLE

MUSCULOSKELETAL ULTRASONOGRAPHY FOR PSORIATIC ARTHRITIS AND PSORIASIS PATIENTS. A SYSTEMATIC LITERATURE REVIEW.

RUNNING TITLE: ULTRASONOGRAPHY IN PSORIATIC ARTHRITIS

AUTHORS:

Alen Zabotti¹, MD, Francesca Bandinelli², MD, Alberto Batticciotto³, MD, Carlo Alberto Scirè^{4,5}, MD, Annamaria Iagnocco⁶, MD, Garifallia Sakellariou⁷, MD on behalf of the Musculoskeletal Ultrasound Study Group of the Italian Society of Rheumatology.

¹ Rheumatology Clinic, Department of Medical and Biological Sciences, University Hospital Santa Maria della Misericordia, Udine, Italy

² Rheumatology Unit, ASL Centro Firenze, Florence, Italy

³ Rheumatology Unit, L. Sacco University Hospital, Milan, Italy

⁴ Epidemiology Unit of the Italian Society for Rheumatology (SIR), Milan, Italy

⁵ Department of Medical Sciences, Section of Rheumatology, University of Ferrara, Ferrara, Italy

⁶ Dipartimento di Scienze Cliniche e Biologiche, Università degli Studi di Torino, Turin, Italy

⁷ Chair and Division of Rheumatology, IRCCS Policlinico San Matteo Foundation, University of Pavia, Pavia, Italy

This study has been supported by the Musculoskeletal Ultrasound Study Group of the Italian Society for Rheumatology.

Corresponding Author:

Prof. Annamaria Iagnocco

Dipartimento di Scienze Cliniche e Biologiche, Università degli Studi di Torino

Azienda Ospedaliero-Universitaria San Luigi Gonzaga

Regione Gonzole 10,

10043 Orbassano Torino, Italy

Key messages:

- This is the first systematic literature review on the use of ultrasonography in psoriasis and psoriatic arthritis;
- The systematic literature review points up the importance and potential of ultrasonography in the management of psoriatic arthritis and psoriasis but it also underlines the need of a large amount of research to optimise the use of ultrasonography in the diagnosis and monitoring of psoriatic disease in clinical practice;
- Based on the evidence arising from the literature review, a research agenda has been proposed.

Abstract

Objective: To systematically review the role of musculoskeletal ultrasound (MSUS) in patients suffering from psoriatic arthritis (PsA) or psoriasis (Pso) in terms of prevalence, diagnosis, prognosis, monitoring and treatment.

Methods: A systematic literature review was conducted through medical databases (MEDLINE via PubMed, Embase) and the grey literature up to September 2015 to inform a new study of the Musculoskeletal Ultrasound Study Group of the Italian Society for Rheumatology. All articles reporting data on MSUS in PsA or PsO were included and extracted according to the underlying clinical question.

Results: 86 publications were included. The prevalence of US abnormalities showed a wide range for each examined feature (e.g. 37% to 95% for entheses thickness of the lower limbs). The performance of US for diagnosis of disease or elementary lesions was variable across studies but no study evaluated the overall performance of US in addition to clinical findings to diagnose PsA. Considering US in defining PsA and Pso prognosis, several works focused on US of entheses of lower limbs in Pso while for the monitoring of PsA activity, 5 different scoring systems were identified. Lastly, the results of the role of US to guide intra-articular interventions were controversial for the clinical outcomes while in favour of US for accuracy.

Conclusion: despite the recognised importance of US in the management of PsA and Pso , this review clearly demonstrated the need of a pivotal research to optimise the use of US in the diagnosis and monitoring of psoriatic disease.

Introduction

Psoriatic arthritis (PsA) is a systemic inflammatory disease with articular and extra-articular features. In the last years, imaging is playing an increasingly important role in the differential diagnosis and in monitoring treatment response in PsA. Recently, the European League Against Rheumatism (EULAR) recommendations for the use of imaging in the diagnosis and management of spondyloarthritis (SpA) advise the use of magnetic resonance imaging (MRI) and ultrasound (US) for the diagnosis, monitoring activity and evaluating structural changes in peripheral SpA (1). US demonstrated good accuracy, reliability and sensitivity to change in the assessment of various structures which may be involved in PsA, i.e. tendons, entheses, synovium and bone (1–3). In addition, the information given by US assessment can be integrated to those obtained by clinical examination thus improving differential diagnosis (e.g. early seronegative polyarthritis), stratification of patients and therapeutic strategies in a treat-to-target (T2T) context (4,5). Currently, the utility of US in clinical practice is not yet supported by adequate evidence (6), therefore, reflecting the need to determine the role of US in diagnosis and prognostic stratification and to support prioritisation of US studies in PsA, the Musculoskeletal Ultrasound Study Group of the Italian Society of Rheumatology decided to perform a systematic literature review (SLR) on the use of US in the management of PsA.

METHODS

The Preferred Reporting Items for Systematic reviews and Meta-analyses (PRISMA) were followed to design and report this review(7). The most relevant areas of application of US in PsA and psoriasis (Pso) (prevalence and diagnosis of the disease, diagnosis of elementary lesions typical of PsA, prognosis, follow-up and treatment guide) were identified and pre-specified inclusion criteria for each item were developed (Table S1).

Data Sources and Search

PubMed and Embase were searched, without time limits, up to September 27th, 2015. The search strategy was developed based on search terms aiming at identifying studies including patients with PsA or Pso in which musculoskeletal US was performed. The search strategy is presented in Table S2. Abstract of the American College of Rheumatology (ACR) and EULAR congresses (2014 and 2015) were hand searched. Studies had to be published in English, no publication restriction or selection based on quality were applied.

Study Selection

Studies included patients with suspected or confirmed PsA, including mixed population of arthritis, only when a part of patients diagnosed with PsA. Studies on patients with skin psoriasis without known arthropathy were also eligible for inclusion. US was considered as index test/intervention, details on the comparators, outcomes and eligible study designs are shown in Table 1. The reviewers (FB, AB, AZ) worked in pairs for each area of interest, independently screening titles and abstracts. The full-text of potentially eligible articles was obtained; inclusion assessment was performed by one reviewer and checked by a second.

Data extraction and quality assessment

Study characteristics and data were extracted using separate standardised forms for each area of interest. For diagnostic accuracy items, when possible data were extracted as 2x2 tables and sensitivity, specificity, positive and negative likelihood ratios (LR) with 95% confidence intervals (CI) were calculated. **Pre-specified meta-analyses were not planned, due to the expected heterogeneity across studies. The hypothesis of heterogeneity was tested in the subgroup of studies assessing the performance of US in detecting elementary lesions.** The risk of bias and methodological quality of the included studies were assessed with different tools, depending on study design. For diagnostic studies, the QUADAS-2 tool was used (8), for RCTs the risk of bias tool proposed by the Cochrane collaboration (9) while for observational studies the Newcastle-Ottawa scale (NOS) (10).

RESULTS

Selected studies

Of the 365 studies produced by PubMed and Embase search, 71 studies met the criteria for the inclusion. Furthermore 15 additional studies were included, 2 from hand search and 13 from the 2014-2015 abstracts of ACR and EULAR. Figure 1 shows the flowchart of the study selection process. **Table 2 highlights on high quality studies on prevalence, diagnosis and prognosis.**

Prevalence of US abnormalities in PsA and Pso

The search retrieved 56 studies examining the prevalence of US abnormalities in PsA (50/56 studies) and isolated Pso (6/50 studies) (11), (12), (13), (14), (15), (16), (17), (18), (19), (20), (21), (22), (23), (24), (25), (26), (27), (28), (29), (30), (31), (32), (33), (34), (35), (36), (37), (38), (39), (40), (41), (42), (43), (44), (45), (46), (47), (48), (49), (50), (51), (52), (53), (54), (55), (56), (57), (58), (59), (60), (61), (62), (63), (64), (65), (66). The results are summarized in Table 1, while complete results are shown in table S3. Regarding the examined US abnormalities, synovitis, erosions and enthesopathy were often studied, less frequently soft tissue inflammation, described as oedema and/or PD peri-tendinous. The prevalence of the examined lesions had a wide range in the studies: 10 to 100% for synovitis (22), (34), (48), (52), (55); 37% to 94.5% for entheses thickness of the lower limbs (14), (17), (15), (24), (27), (30), (35), (36); and 10.8 to 52% for erosions (16), (34), (53), (55). The sites examined were very variable, except for studies of US entheses in which the lower limbs were the most frequently studied. For entheses evaluation Glasgow Ultrasound Enthesitis Scoring System (GUESS) as the most commonly employed score (15), (17), (27), (41), (50), (59), followed by MASEI score (12), (26). Furthermore two studies evaluated the synovial contrast enhancement with a prevalence in PsA of approximately 30 percent (33), (55). The risk of bias for all selected studies, assessed using the NOS, is reported in table S3.

Making a diagnosis of PsA

Performance of US in the diagnosis of PsA and Pso

The search retrieved 23 studies, including a qualitative systematic review (67), examining the performance of US to diagnose PsA (37), (40), (42), (45), (46), (47), (56), (58), (59), (12), (26), (27), (17), (20), (28), (19), (31), (30), (29), (21), (34), (68). The results of the studies are summarized in Table S4,, figures 2, S1 and S2 . The diagnostic performance of US was variable across studies, in particular no study evaluated the overall performance of US in addition to clinical findings to diagnose PsA, while most studies were focusing on single lesions. However, no study demonstrated an adequate performance for US variables, considered separately. The performance of US to detect PsA was broadly variable among studies, with sensitivities ranging from 0.22 to 1.00 for enthesopathy, from 0.16 to 0.76 for synovial hypertrophy and from 0.14 to 0.58 form joint bone erosions. Also sensitivities were extremely variables, ranging from 0.20 to 1.0 for enthesopathy, from 0 to 1.0 for synovial hypertrophy and from 0.40 to 1.0 for bone erosions. Most of the studies (22 out of 23) followed a cross-sectional case-control design, and the evaluation of

the diagnostic performance of US was in many cases not the primary objective of the study. As expected, the studies were heterogeneous in terms of examined sites and reference standard, although clinical diagnosis or classification criteria were the only standard adopted. The risk of bias, assessed by the modified version of the QUADAS, was in general considered high for the items concerning patients recruitment, unclear for the items dealing with the index test and mostly low for the items covering the reference standard and the timing (Figure S3).

Performance of US in the diagnosis of PsA and Pso elementary lesions

The search retrieved 30 studies examining the performance of US to diagnose PsA elementary lesions (11), (15), (16), (20), (23), (24), (25), (30), (32), (69), (33), (34), (37), (38), (39), (44), (45), (70), (47), (48), (51), (52), (71), (53), (55), (57), (58), (63), (64),(72). The results of the studies are summarized in Table S5. The PsA elementary lesions evaluated were heterogeneous for type of lesions (e.g. synovial or extra-synovial features), anatomic structures and reference standard. The reference standard was clinical examination in 14 studies, MRI in 5, Conventional Radiography (CR) and arthroscopy in 3, Computer Tomography (CT) and Histological Evaluation (HE) in 1. Considering MRI as reference standard, the sensibility and specificity underwent wide variations depending on examined anatomic structures and types of lesions, for example considering synovitis, sensibility ranged from 0.49 to 0.94 while specificity from 0.20 to 0.91 (Figure S4). In the unique study using histopathology as reference, the amount of power Doppler did not significantly associate with a global histopathological inflammatory score (44); while for the single study comparing US with CT, a large proportion of bone lesions detected by US could be verified by CT (32). The risk of bias, assessed by the modified version of the QUADAS, was in general considered high for the items concerning patients' recruitment, unclear for the items dealing with the reference standard and mostly low for the index test and flow and timing (Figure S5). **This subgroup of studies was used to test the presence of heterogeneity across studies (Supplementary Figure S6, available online only), showing a significant degree of heterogeneity (for joint abnormalities: Chi square= 785.46, p<0.0001 for the presence of heterogeneity; for enthesal abnormalities: Chi square=1027.29, p<0.0001 for the presence of heterogeneity).**

Prognosis and follow up

Role of US in defining PsA and Pso prognosis

The search retrieved **15** studies examining the role of US in defining PsA and Pso prognosis (11), (14), (73), (41), (74), (75), (56), (59), (23), (76), (77), (78),(79),(80), (49) with only two having a prospective design (75), (80). The results of the studies are summarized in Table S6. **Several works, selected for this item, focused on target entheses US in Pso patients revealing a high rate of subclinical inflammatory signs. Subclinical enthesitis, confirmed by a significant higher GUESS score, was found more frequently in Pso compared to healthy controls (14), (73), (41), while only one study focused on the prevalence of subclinical synovitis in Pso (49). There was only one prospective study, published by *Tinazzi et al*, in which GUESS scores of patients with Pso who developed PsA compared to those who did not develop PsA did not statistically differ. Furthermore, in the logistic regression analysis, baseline thickness of the quadriceps tendon was**

found to be an independent predictor of the development of PsA (75). Moreover, the presence of PD signal in entheses, evaluated as enthesal-organ in *Aydin et al 2013* and within 2 mm of bone insertion in *Gutierrez et al 2011*, was found to be highly specific for psoriatic disease (14), (41) . The risk of bias for all selected studies, assessed using the NOS, is reported in Table S6.

Role of US in the follow-up of PsA and Pso

The search retrieved 15 studies exploring the role of US in PsA follow up (81), (82), (18), (83), (69), (84), (85), (86), (87), (88), (89), (90), (91), (92), (63). The results are summarized in Table 3. In several studies, US assessment was used to analyze the response to a standardized therapeutic approach with inhomogeneous US endpoints. The comparison between articles is made difficult by the variability in definitions of elementary lesions and scoring systems, machine settings and image acquisition. Among selected articles, five different scoring systems have been tested. The US Group of Spanish Society of Rheumatology demonstrated that the PDUS examination of 14 peripheral entheses was able to monitor the 6 months therapeutic response in 197 SpA patients (87). The German US7 scores, significantly reflected the therapeutic response of PsA patients evaluating synovitis, tenosynovitis and erosions of small joints whereas the SOLAR score, used to evaluate synovitis and tenosynovitis (GS and PD) of the large joints was able to monitor the treatment response in a cohort of PsA (82), (89). The “Five Targets Power Doppler for Psoriatic Disease” (5TPD) score was the first score including all domains characterizing PsA (joint, tendon with synovial sheath, entheses, skin and nail) and those, one for each target area, showing the highest expression of PD were selected for monitoring an anti-TNF therapy for 8 weeks in 16 PsA patients (91). The 5TPD score showed a significant improvement during therapy but it did not correlate with HAQ-modified for SpA. Lastly, Ficjan et al. developed two US score (PsA-Son22 and PsA-Son13) in a prospective study on 83 consecutive PsA patients, these scores explored joints, peri-articular structures and entheses. Both composite scores had sufficient sensitivity to change and the bilateral score (PsA-Son22) was more sensitive than the unilateral score to detect PsA lesions whereas the unilateral (PsA-Son13) was faster (90). The risk of bias, assessed using the “NOS, the “PRISMA Checklist” and the Cochrane diagnostic test Accuracy, was reported in Table 3.

US to guide intra-articular interventions

The search retrieved 4 studies, including two randomised controlled trials, examining the role of US to guide intra-articular interventions (93), (94), (95), (96). Among the two RCT, comparing blinded and US-guided injections, the results were controversial for the clinical outcomes while the accuracy was better for US-guided procedures (95),(96). In *Sibbit et al.*, US directed intra-articular injections were superior to palpation-guided methods in all therapeutic measures: absolute VAS pain scores for injection pain were 81% less, responder rates were increased by 38%, and non-responder rates were reduced by 34% (96). Conversely, in the study published by *Cunnington et al.* there was no statistically significant difference between US-guided and blind injections for any of the major outcome variables (e.g. VAS pain, function and stiffness) measured at 2 weeks or 6 weeks (95). Only one study focused on tenosynovitis while no study focused on

enthesitis or bursitis (94). The risk of bias, assessed by the Cochrane Collaboration's tool for intervention studies, is reported in [figure S7](#).

DISCUSSION

The usefulness of US in diagnosis, prognosis, and follow-up of inflammatory arthritis in clinical practice is still a matter of debate, despite the evidence of a higher sensitivity over clinical examination. Recently, an EULAR task force developed evidence-based recommendations on the use of imaging in the clinical management of RA and SpA (1) (97), acknowledging the need of further extensive research to optimise the use of imaging in routine clinical practice. On this basis, and in order to identify and prioritise its research agenda in the field of PsA, the Musculoskeletal Ultrasound Study Group of the Italian Society of Rheumatology, decided to plan a SLR with the aim to highlight the current state of knowledge. Currently, in early inflammatory arthritis, rheumatologists need supporting tools to strengthen the diagnosis (98). Among imaging modalities, US is the most attractive one, as less time consuming, safe and readily and easily used. For this reason, an increasing number of studies about US to diagnose PsA has been recently published. However, its use in clinical practice is still a matter of debate. In the SLR the diagnostic performance of US was widely variable and no study evaluated the overall performance of US in addition to clinical findings to diagnose PsA. Moreover, most of the selected diagnostic studies followed a cross-sectional case-control design, introducing a bias in patients selection and leading to an overestimation of the diagnostic performance of the index test. The ability of US to detect elementary lesions, which may support the diagnosis of PsA, is widely described in literature. Considering the potential pathogenetic role of entheses in PsA, US of entheses was not surprisingly the most frequently used for diagnosis (42), (45), (46), (59), (81), (26), (27), (17), (31), (30), (11), (15), (23), (38), (39), (25), (24), (52). Furthermore, US was used to image synovitis, tenosynovitis, bursitis and erosions and less frequently soft tissue and hand nails. Clinical examination was often the reference standard for both the diagnosis of PsA and psoriatic elementary lesions. Only one study examined the performance of PD to identify synovitis using histopathology as gold standard, showing that a negative PD in the synovium did not exclude the possibility of synovitis (44). In axial, SpA imaging (conventional radiography and MRI of sacro-iliac joints) is a key component of classification criteria, mostly due to the absence of specific clinical symptoms (1), while in the classification of peripheral inflammatory arthritis, its use is not mandatory. However, in early disease imaging might play an important role supporting diagnosis and directing the treatment. Regarding the differential diagnosis, studies seem to support the idea that PsA could be differentiated from RA for a major extra-synovial involvement. Soft tissue inflammation, described as oedema and/or PD peri-tendinous, could be a very distinctive sign of PsA, being absent in RA controls (45), (34), (40). *Fourniè et al.* highlighted a major synovial involvement in RA than PsA (i.e. 100% vs 76%) and furthermore, the prevalence of erosions was lower in PsA than in RA (34), (58), (60), (63), even though this result was recently questioned by another study (45). Moreover, the prevalence of features differed greatly between selected studies, mainly due to the heterogeneity of inclusion criteria, elementary lesion definitions and equipment. In addition, possible sources of bias mainly related to patient selection might have been present. With clinical remission being the ideal treatment target, the application of US to predict development of arthritis in Pso patients or to identify PsA patients with poorer outcome, is of interest. Considering the importance of enthesitis as the key lesion in PsA, some studies focused on entheses of lower limbs in psoriatic

disease (with or without arthritis) revealing an high rate of enthesopathy signs (73), (14), (41), particularly for PD activity. The results of SLR supported the idea that enthesal PD, rather than GS changes, is a highly specific feature for PsA. However, the prognostic role of these lesions in the development of arthritis in Pso patients is not clear yet. There was only one prospective work by *Tinazzi et al.* demonstrating that in Pso patients, baseline thickness of quadriceps tendons was an independent predictor of PsA development, and suggesting the need of further investigation in larger cohorts in order to understand the real predictive value of the entheses US (75). Currently, in RA synovitis, tenosynovitis and bone marrow oedema appear to be predictors of radiographic progression and synonymous of disease activity (99), (100), (101), (94). To date, in PsA, US predictors of poorer outcome have not been identified, moreover many studies had an unappropriated design to evaluate prognostic measures. Since in RA T2T studies based solely on US did not prove a superiority of imaging over clinical management (102), the potential role of US in monitoring disease activity has to be tested in addition to clinical follow-up. The integration of US with clinical examination to stratify patients and to decide treatments in a T2T strategy also represents an interesting possibility. The SLR identified few US scores to monitor disease activity in PsA patients. German US7 scores, developed in RA, was the first applied and was able to significantly reflect the therapeutic response of PsA patients evaluating synovitis, tenosynovitis and erosions (82). Focusing on large joints, the SOLAR score, was used to evaluate activity in a cohort of PsA and Ankylosing Spondylitis patients and the authors concluded that it was a valuable tool (89). Furthermore, the Group of Spanish Society of Rheumatology demonstrated that the PDUS examination of 14 peripheral entheses was able to monitor the response of SpA patients during anti-TNF therapy, and interestingly the authors highlighted that the score may contribute to the development of a cumulative scoring system of combined elementary lesions (87). Considering the clinical heterogeneity of PsA with different domains and peculiar sites involved, a dedicated ultrasound composite score is arguably necessary. First, Gutierrez et al. developed a PsA dedicated preliminary five target score for the assessment of PsA patients during anti-TNF therapy (91). Later, also *Ficjan et al.* proposed two PsA specific US score (PsASon-13 and PsASon-22) to monitor disease activity in PsA (90). All these last three scores are original and interesting, but they are not applied in other series, thus remaining preliminary scores despite good sensitivity for the detection of inflammation and feasibility. Despite the extensive use in clinical practice, superiority for clinical outcome of US-guided injections over blinded injections remains doubtful in PsA and further studies are needed to better define the efficacy of one over the other. US-guided injections resulted to be overall more accurate. Accordingly *Cunnington et al.* recommended US-guided procedures in joints that were frequently injected inaccurately (e.g. shoulder, ankle, hip) and in order to reduce tissue necrosis or the possible damage to surround tissues (98). Therefore actually, safety data seem to be an added value of US-guided injections. Although the SLR pointed up the importance and potential of US in the management of PsA and Pso, it also underlined the need of a large amount of research to optimise the use of US in the diagnosis and monitoring of psoriatic disease in clinical practice. In particular, several gaps in the literature were underlined, as well as the presence of possible biases, such as patient selection and reference standard for diagnostic studies or to randomisation in interventional studies. In addition, since the presence of publication bias was not investigated, it cannot be excluded. Based on the evidence arising from

the literature review, a research agenda has also been proposed (Table 4). Considering the gaps of the literature underlined by the SLR, the Ultrasound Study Group of the Italian Society for Rheumatology gave priority to a novel study aiming to identify clinical and US predictors of Minimal Disease Activity in PsA patients with active peripheral arthritis starting a new course of therapy (Ultrasound in Psoriatic Arthritis Treatment – UPSTREAM study). Identifying prognostic factors of achieved remission or low disease activity will help a better selection of patients with poorer outcome and possibly the improvement of therapeutic strategies, responding to the need of personalized medicine, optimizing the outcome of patients with PsA as well as the treatments management.

REFERENCES

1. Mandl P, Navarro-Compan V, Terslev L, Aegerter P, van der Heijde D, D'Agostino MA, et al. EULAR recommendations for the use of imaging in the diagnosis and management of spondyloarthritis in clinical practice. *Ann Rheum Dis*. 2015 Jul;74(7):1327–39.
2. Gutierrez M, Filippucci E, De Angelis R, Filosa G, Kane D, Grassi W. A sonographic spectrum of psoriatic arthritis: “the five targets.” *Clin Rheumatol*. 2010 Feb;29(2):133–42.
3. Kane D. The role of ultrasound in the diagnosis and management of psoriatic arthritis. *Curr Rheumatol Rep*. 2005 Aug;7(4):319–24.
4. Zabotti A, Salvin S, Quartuccio L, De Vita S. Differentiation between early rheumatoid and early psoriatic arthritis by the ultrasonographic study of the synovio-entheseal complex of the small joints of the hands. *Clin Exp Rheumatol*. 2016 Jun;34(3):459–65.
5. Coates LC, Helliwell PS. Treat to Target in Psoriatic Arthritis—Evidence, Target, Research Agenda. *Curr Rheumatol Rep*. 2015 Apr 23;17(6):1–6.
6. Gutierrez M, Draghessi A, Bertolazzi C, Erre GL, Saldarriaga-Rivera LM, López-Reyes A, et al. Ultrasound in psoriatic arthritis. Can it facilitate a best routine practice in the diagnosis and management of psoriatic arthritis? *Clin Rheumatol*. 2015 Aug 23;34(11):1847–55.
7. Moher D, Liberati A, Tetzlaff J, Altman DG, PRISMA Group. Preferred reporting items for systematic reviews and meta-analyses: the PRISMA statement. *PLoS Med*. 2009 Jul 21;6(7):e1000097.
8. QUADAS-2 | School of Social and Community Medicine | University of Bristol [Internet]. [cited 2016 Oct 11]. Available from: <http://www.bristol.ac.uk/social-community-medicine/projects/quadas/quadas-2/>
9. Higgins J. 8 Assessing risk of bias in included studies. In [cited 2016 Oct 11]. Available from: http://handbook.cochrane.org/chapter_8/8_assessing_risk_of_bias_in_included_studies.htm
10. Wells G. Ottawa Hospital Research Institute [Internet]. [cited 2016 Oct 11]. Available from: http://www.ohri.ca/programs/clinical_epidemiology/oxford.asp
11. Abbas M, Suhail M, Ejaz A, Shaikh ZI, Minhas AH, Dar NR, et al. Comparison of clinical and sonographical findings of achilles tendon involvement in newly diagnosed and established cases of psoriasis. *J Pak Assoc Dermatol*. 2011;21(1):16–21.
12. Acquacalda E, Albert C, Montaudie H, Fontas E, Danre A, Roux CH, et al. Ultrasound study of entheses in psoriasis patients with or without musculoskeletal symptoms: A prospective study. *Joint Bone Spine*. 2015;82(4):267–71.
13. Aydin SZ, Castillo-Gallego C, Ash ZR, Marzo-Ortega H, Emery P, Wakefield RJ, et al. Ultrasonographic assessment of nail in psoriatic disease shows a link between onychopathy and distal interphalangeal joint extensor tendon enthesopathy. *Dermatology*. 2012;225(3):231–5.
14. Aydin SZ, Ash ZR, Tinazzi I, Castillo-Gallego C, Kwok C, Wilson C, et al. The link between enthesitis and arthritis in psoriatic arthritis: A switch to a vascular phenotype at insertions may play a role in arthritis development. *Ann Rheum Dis*. 2013;72(6):992–5.
15. Balint PV, Kane D, Wilson H, McInnes IB, Sturrock RD. Ultrasonography of enthesal insertions in the lower limb in spondyloarthropathy. *Ann Rheum Dis*. 2002;61(10):905–10.

16. Bandinelli F, Denaro V, Prignano F, Collaku L, Ciancio G, Matucci-Cerinic M. Ultrasonographic wrist and hand abnormalities in early psoriatic arthritis patients: Correlation with clinical, dermatological, serological and genetic indices. *Clin Exp Rheumatol*. 2015;33(3):330–5.
17. Bandinelli F, Prignano F, Bonciani D, Bartoli F, Collaku L, Candelieri A, et al. Ultrasound detects occult enthesal involvement in early psoriatic arthritis independently of clinical features and psoriasis severity. *Clin Exp Rheumatol*. 2013;31(2):0219–24.
18. Bonifati C, Elia F, Francesconi F, Ceralli F, Izzi S, Solivetti FM, et al. The diagnosis of early psoriatic arthritis in an outpatient dermatological centre for psoriasis. *J Eur Acad Dermatol Venereol*. 2012;26(5):627–33.
19. De Simone C, Caldarola G, D'Agostino M, Carbone A, Guerriero C, Bonomo L, et al. Usefulness of ultrasound imaging in detecting psoriatic arthritis of fingers and toes in patients with psoriasis. *Clin Dev Immunol*. 2011;2011:390726.
20. Ciancio G, Volpinari S, Fotinidi M, Furini F, Farina I, Bortoluzzi A, et al. Involvement of the inconstant bursa of the fifth metatarsophalangeal joint in psoriatic arthritis: a clinical and ultrasonographic study. *Biomed Res Int*. 2014;2014:174841.
21. Coari G, Iagnocco A, Mastrantuono M, De Cata A, Persia S, Passariello R, et al. Sonographic and NMR imaging study of sausage digit. *Acta Derm Venereol Suppl Stockh*. 1994;186:33–4.
22. De Agustín JJ, Moragues C, De Miguel E, Möller I, Acebes C, Naredo E, et al. A multicentre study on high-frequency ultrasound evaluation of the skin and joints in patients with psoriatic arthritis treated with infliximab. *Clinical and Experimental Rheumatology*. 2012;30(6):879–85.
23. De Simone C, Guerriero C, Giampietruzzi AR, Costantini M, Di Gregorio F, Amerio P. Achilles tendinitis in psoriasis: Clinical and sonographic findings. *J Am Acad Dermatol*. 2003;49(2):217–22.
24. Delle Sedie A, Riente L, Filippucci E, Scirè CA, Iagnocco A, Gutierrez M, et al. Ultrasound imaging for the rheumatologist XXVI. Sonographic assessment of the knee in patients with psoriatic arthritis. *Clin Exp Rheumatol*. 2010;28(2):147–52.
25. Delle Sedie A, Riente L, Filippucci E, Scire CA, Iagnocco A, Meenagh G, et al. Ultrasound imaging for the rheumatologist. XXXII. Sonographic assessment of the foot in patients with psoriatic arthritis. *Clin Exp Rheumatol*. 2011 Mar;29(2):217–22.
26. Eder L, Jayakar J, Thavaneswaran A, Haddad A, Chandran V, Salonen D, et al. Is the madrid sonographic enthesitis index useful for differentiating psoriatic arthritis from psoriasis alone and healthy controls? *J Rheumatol*. 2014;41(3):466–72.
27. Ezzat Y, Gaber W, Abd ELRSF, Ezzat M, El Sayed M. Ultrasonographic evaluation of lower limb entheses in patients with early spondyloarthropathies. *Egypt Rheumatol*. 2013;35(1):29–35.
28. Falcao S, de Miguel E, Castillo-Gallego C, Peiteado D, Branco J, Martin Mola E. Achilles enthesitis ultrasound: the importance of the bursa in spondyloarthritis. *Clin Exp Rheumatol*. 2013 May;31(3):422–7.
29. Falsetti P, Frediani B, Filippou G, Acciai C, Baldi F, Storri L, et al. Enthesitis of proximal insertion of the deltoid in the course of seronegative spondyloarthritis. An atypical enthesitis that can mime impingement syndrome. *Scand J Rheumatol*. 2002;31(3):158–62.

30. Falsetti P, Frediani B, Fioravanti A, Acciai C, Baldi F, Filippou G, et al. Sonographic study of calcaneal entheses in erosive osteoarthritis, nodal osteoarthritis, rheumatoid arthritis and psoriatic arthritis. *Scand J Rheumatol*. 2003;32(4):229–34.
31. Farouk HM, Mostafa AAA, Youssef SS, Elbeblawy MMS, Assaf NY, Elokda ESE. Value of enthesal ultrasonography and serum cartilage oligomeric matrix protein in the preclinical diagnosis of psoriatic arthritis. *Clin Med Insights Arthritis Musculoskelet Disord*. 2010;3((Farouk H.M., dr_hananfarouk@hotmail.com) Internal Medicine and Rheumatology, Faculty of Medicine Ain Shams University, Cairo, Egypt):7–14.
32. Finzel S, Ohrndorf S, Englbrecht M, Stach C, Messerschmidt J, Schett G, et al. A detailed comparative study of high-resolution ultrasound and micro-computed tomography for detection of arthritic bone erosions. *Arthritis Rheum*. 2011 May;63(5):1231–6.
33. Fiocco U, Ferro F, Cozzi L, Vezzù M, Sfriso P, Checchetto C, et al. Contrast medium in power Doppler ultrasound for assessment of synovial vascularity: Comparison with arthroscopy. *J Rheumatol*. 2003;30(10):2170–6.
34. Fournié B, Margarit-Coll N, Champetier de Ribes TL, Zabraniecki L, Jouan A, Vincent V, et al. Extrasynovial ultrasound abnormalities in the psoriatic finger. Prospective comparative power-doppler study versus rheumatoid arthritis. *Joint Bone Spine*. 2006;73(5):527–31.
35. Frediani B, Falsetti P, Storri L, Allegri A, Bisogno S, Baldi F, et al. Quadriceps tendon enthesitis in psoriatic arthritis and rheumatoid arthritis: ultrasound examinations and clinical correlations. *J Rheumatol*. 2001 Nov;28(11):2566–8.
36. Frediani B, Falsetti P, Storri L, Allegri A, Bisogno S, Baldi F, et al. Ultrasound and clinical evaluation of quadriceps tendon enthesitis in patients with psoriatic arthritis and rheumatoid arthritis. *Clin Rheumatol*. 2002;21(4):294–8.
37. Freeston JE, Coates LC, Helliwell PS, Hensor EM, Wakefield RJ, Emery P, et al. Is there subclinical enthesitis in early psoriatic arthritis? A clinical comparison with power doppler ultrasound. *Arthritis Care Res Hoboken*. 2012 Oct;64(10):1617–21.
38. Freeston JE, Coates LC, Nam JL, Moverley AR, Hensor EM, Wakefield RJ, et al. Is there subclinical synovitis in early psoriatic arthritis? A clinical comparison with gray-scale and power Doppler ultrasound. *Arthritis Care Res Hoboken*. 2014 Mar;66(3):432–9.
39. Galluzzo E, Lischi DM, Taglione E, Lombardini F, Pasero G, Perri G, et al. Sonographic analysis of the ankle in patients with psoriatic arthritis. *Scand J Rheumatol*. 2000;29(1):52–5.
40. Gutierrez M, Filippucci E, Salaffi F, Di Geso L, Grassi W. Differential diagnosis between rheumatoid arthritis and psoriatic arthritis: The value of ultrasound findings at metacarpophalangeal joints level. *Ann Rheum Dis*. 2011;70(6):1111–4.
41. Gutierrez M, Filippucci E, De Angelis R, Salaffi F, Filosa G, Ruta S, et al. Subclinical Enthesal Involvement in Patients with Psoriasis: An Ultrasound Study. *Semin Arthritis Rheum*. 2011;40(5):407–12.
42. Iagnocco A, Spadaro A, Marchesoni A, Cauli A, De Lucia O, Gabba A, et al. Power Doppler ultrasonographic evaluation of enthesitis in psoriatic arthritis. A multi-center study. *Joint Bone Spine*. 2012 May;79(3):324–5.

43. Karreman MC, Weel AEAM, Van Der Ven M, Vis M, Tchetverikov I, Nijsten TEC, et al. Musculoskeletal complaints and psoriatic arthritis in primary care patients with psoriasis. *Arthritis Rheumatol.* 2014;66((Karreman M.C.; Weel A.E.A.M.; Van Der Ven M.; Vis M.; Nijsten T.E.C.; Hazes J.M.W.; Luime J.J.) Erasmus University Medical Center, Rotterdam, Netherlands):S694.
44. Koski JM, Saarakkala S, Helle M, Hakulinen U, Heikkinen JO, Hermunen H. Power Doppler ultrasonography and synovitis: Correlating ultrasound imaging with histopathological findings and evaluating the performance of ultrasound equipments. *Ann Rheum Dis.* 2006;65(12):1590–5.
45. Lin Z, Wang Y, Mei Y, Zhao Y, Zhang Z. High-Frequency Ultrasound in the Evaluation of Psoriatic Arthritis: A Clinical Study. *Am J Med Sci.* 2015 Jul;350(1):42–6.
46. Marchesoni A, De Lucia O, Rotunno L, De Marco G, Manara M. Enthesal power Doppler ultrasonography: A comparison of psoriatic arthritis and fibromyalgia. *J Rheumatol.* 2012;39(SUPPL. 89):29–31.
47. Melchiorre D, Calderazzi A, Maddali Bongi S, Cristofani R, Bazzichi L, Eligi C, et al. A comparison of ultrasonography and magnetic resonance imaging in the evaluation of temporomandibular joint involvement in rheumatoid arthritis and psoriatic arthritis. *Rheumatol Oxf.* 2003 May;42(5):673–6.
48. Milosavljevic J, Lindqvist U, Elvin A. Ultrasound and power Doppler evaluation of the hand and wrist in patients with psoriatic arthritis. *Acta Radiol.* 2005 Jul;46(4):374–85.
49. Naredo E, Moller I, de Miguel E, Batlle-Gualda E, Acebes C, Brito E, et al. High prevalence of ultrasonographic synovitis and enthesopathy in patients with psoriasis without psoriatic arthritis: a prospective case-control study. *Rheumatol Oxf.* 2011 Oct;50(10):1838–48.
50. Pistone G, La Vecchia M, Pistone A, Bongiorno MR. Achilles tendon ultrasonography may detect early features of psoriatic arthropathy in patients with cutaneous psoriasis. *Br J Dermatol.* 2014;171(5):1220–2.
51. Riente L, Delle Sedie A, Filippucci E, Iagnocco A, Sakellariou G, Talarico R, et al. Ultrasound imaging for the rheumatologist XLV. Ultrasound of the shoulder in psoriatic arthritis. *Clin Exp Rheumatol.* 2013 May;31(3):329–33.
52. Riente L, Delle Sedie A, Sakellariou G, Filippucci E, Meenagh G, Iagnocco A, et al. Ultrasound imaging for the rheumatologist XXXVIII. Sonographic assessment of the hip in psoriatic arthritis patients. *Clin Exp Rheumatol.* 2012;30(2):152–5.
53. Sankowski AJ, Łebkowska UM, Ćwikła J, Walecka I, Walecki J. The comparison of efficacy of different imaging techniques (conventional radiography, ultrasonography, magnetic resonance) in assessment of wrist joints and metacarpophalangeal joints in patients with psoriatic arthritis se. *Pol J Radiol.* 2013;78(1):18–29.
54. Scarpa R, Cuocolo A, Peluso R, Attenu M, Gisonni P, Iervolino S, et al. Early psoriatic arthritis: the clinical spectrum. *J Rheumatol.* 2008 Jan;35(1):137–41.
55. Solivetti FM, Elia F, Teoli M, De Mutiis C, Chimenti S, Berardesca E, et al. Role of contrast-enhanced ultrasound in early diagnosis of psoriatic arthritis. *Dermatology.* 2010;220(1):25–31.
56. Turner DE, Hyslop E, Barn R, McInnes IB, Steultjens MP, Woodburn J. Metatarsophalangeal joint pain in psoriatic arthritis: a cross-sectional study. *Rheumatol Oxf.* 2014 Apr;53(4):737–40.

57. Weiner SM, Jurenz S, Uhl M, Lange-Nolde A, Warnatz K, Peter HH, et al. Ultrasonography in the assessment of peripheral joint involvement in psoriatic arthritis. *Clin Rheumatol*. 2008;27(8):983–9.
58. Wiell C, Szkudlarek M, Hasselquist M, Moller JM, Vestergaard A, Norregaard J, et al. Ultrasonography, magnetic resonance imaging, radiography, and clinical assessment of inflammatory and destructive changes in fingers and toes of patients with psoriatic arthritis. *Arthritis Res Ther*. 2007;9(6):R119.
59. Woodburn J, Hyslop E, Barn R, McInnes IB, Turner DE. Achilles tendon biomechanics in psoriatic arthritis patients with ultrasound proven enthesitis. *Scand J Rheumatol*. 2013;42(4):299–302.
60. Zayat AS, Ellegaard K, Conaghan PG, Terslev L, Hensor EM, Freeston JE, et al. The specificity of ultrasound-detected bone erosions for rheumatoid arthritis. *Ann Rheum Dis*. 2015 May;74(5):897–903.
61. Rizzo G, Raffener B, Coran A, Ciprian L, Fiocco U, Botsios C, et al. Pixel-based approach to assess contrast-enhanced ultrasound kinetics parameters for differential diagnosis of rheumatoid arthritis. *J Med Imaging*. 2015 Sep 11;2(3):034503.
62. Yumusakhuyly Y, Kasapoglu E, Murat S, Kurum E, Keskin H, Icagasioglu A, et al. SAT0631 Similar Enthesopathy Scores by Us in Psoriatic Arthritis and Osteoarthritis: Table 1. *Ann Rheum Dis*. 2015 Jun;74(Suppl 2):889.3–890.
63. Coates LC, Freeston JE, Nam J, Conaghan PG, Helliwell PS. THU0426 Ultrasound Identifies Additional Erosive Disease in Patients with Early Psoriatic Arthritis – Results from the Ticopa Study: *Ann Rheum Dis*. 2015 Jun;74(Suppl 2):353.1–353.
64. van der Ven M, Karreman M, Weel A, Tchetverikov I, Vis M, Nijsten T, et al. FRI0562 Ultrasound Enthesitis in Primary Care Psoriasis Patients with Musculoskeletal Complaints. *Ann Rheum Dis*. 2015 Jun;74(Suppl 2):631.1–631.
65. Ceccarelli F, Ricci E, Rutigliano IM, Finucci A, Scirocco C, Gattamelata A, et al. SAT0609 Synovitis in Patients with Inflammatory Arthropathies: Comparison Between Rheumatoid Arthritis and Psoriatic Arthritis Evaluated by Power-Doppler Ultrasound: Table 1. *Ann Rheum Dis*. 2015 Jun;74(Suppl 2):882.2–882.
66. Acosta-Felquer M. Enteseal Abnormalities and Nail Involvement at the Distal Interphalangeal Joints on Ultrasound Examination in Patients with Psoriasis and Psoriatic Arthritis. Could the Nail-Enthesitis Theory be Supported? [Internet]. *ACR Meeting Abstracts*. [cited 2016 Oct 5]. Available from: <http://acrabstracts.org/abstract/enteseal-abnormalities-and-nail-involvement-at-the-distal-interphalangeal-joints-on-ultrasound-examination-in-patients-with-psoriasis-and-psoriatic-arthritis-could-the-nail-enthesitis-theory-be-supp/>
67. Bakewell CJ, Olivieri I, Aydin SZ, Dejaco C, Ikeda K, Gutierrez M, et al. Ultrasound and magnetic resonance imaging in the evaluation of psoriatic dactylitis: status and perspectives. *J Rheumatol*. 2013 Dec;40(12):1951–7.
68. Mendonça JA, Nogueira JP, Laurido IMM, Vierhout C, Peron F, Lyrio AM, et al. SAT0191 Can Spectral Doppler Identify Nail Enthesitis in Psoriatic Arthritis? *Ann Rheum Dis*. 2014 Jun;73(Suppl 2):659.1–659.
69. Fiocco U, Cozzi L, Rubaltelli L, Rigon C, De Candia A, Tregnaghi A, et al. Long-term sonographic follow-up of rheumatoid and psoriatic proliferative knee joint synovitis. *Br J Rheumatol*. 1996;35(2):155–63.

70. Meenagh G, Filippucci E, Delle Sedie A, Iagnocco A, Scire CA, Riente L, et al. Ultrasound imaging for the rheumatologist XXX. Sonographic assessment of the painful knee. *Clin Exp Rheumatol*. 2010 Nov;28(6):803–5.
71. Rubaltelli L, Fiocco U, Cozzi L, Baldovin M, Rigon C, Bortoletto P, et al. Prospective sonographic and arthroscopic evaluation of proliferative knee joint synovitis. *J Ultrasound Med*. 1994 Nov;13(11):855–62.
72. Rekek S, Jrad M, Aouadi A, Boussaid S, Ajleni H, Sahli H, et al. SAT0235 Assessment of Achilles Enthesitis in the Spondyloarthritis by Colour Doppler Ultrasound. *Ann Rheum Dis*. 2015 Jun;74(Suppl 2):743.3–743.
73. Gisondi P, Tinazzi I, El-Dalati G, Gallo M, Biasi D, Barbara LM, et al. Lower limb enthesopathy in patients with psoriasis without clinical signs of arthropathy: a hospital-based case-control study. *Ann Rheum Dis*. 2008 Jan;67(1):26–30.
74. Husic R, Gretler J, Felber A, Graninger WB, Duftner C, Hermann J, et al. Disparity between ultrasound and clinical findings in psoriatic arthritis. *Ann Rheum Dis*. 2014 Aug;73(8):1529–36.
75. Tinazzi I, McGonagle D, Biasi D, Confente S, Caimmi C, Girolomoni G, et al. Preliminary evidence that subclinical enthesopathy may predict psoriatic arthritis in patients with psoriasis. *J Rheumatol*. 2011;38(12):2691–2.
76. Özçakar L, Çetin A, İnanici F, Kaymak B, Gürer CK, Kölemen F. Ultrasonographical evaluation of the Achilles' tendon in psoriasis patients. *Int J Dermatol*. 2005;44(11):930–2.
77. Michelsen B, Diamantopoulos A, Kavanaugh A, Haugeberg G. SAT0385 Lack of Correlation between Clinical and Ultrasonographic Evidence of Disease Activity in Psoriatic Arthritis: *Ann Rheum Dis*. 2014 Jun;73(Suppl 2):733.2–733.
78. Negm AA, AL Araby S, Abdulazim E, Abul Ela M, AboGamal AF. AB0942 Comparison between Enthesopathy in Psoriasis and Psoriatic Arthritis. (Clinical and Ultrasonographic Study). *Ann Rheum Dis*. 2014 Jun;73(Suppl 2):1111.3–1112.
79. Michelsen B. Sensivity and Specificity of Clinical Criteria to Identify Patients in Ultrasound Remission in Psoriatic Arthritis [Internet]. *ACR Meeting Abstracts*. [cited 2016 Oct 5]. Available from: <http://acrabstracts.org/abstract/sensivity-and-specificity-of-clinical-criteria-to-identify-patients-in-ultrasound-remission-in-psoriatic-arthritis/>
80. Marin J. Utility of Power Doppler Ultrasound-Detected Synovitis for the Prediction of Short Term Flare in Psoriatic Arthritis Patients in Clinical Remission [Internet]. *ACR Meeting Abstracts*. [cited 2016 Oct 5]. Available from: <http://acrabstracts.org/abstract/utility-of-power-doppler-ultrasound-detected-synovitis-for-the-prediction-of-short-term-flare-in-psoriatic-arthritis-patients-in-clinical-remission/>
81. Acquacalda E, Albert C, Montaudie H, Fontas E, Danre A, Roux CH, et al. Ultrasound study of entheses in psoriasis patients with or without musculoskeletal symptoms: A prospective study. *Joint Bone Spine*. 2015;82(4):267–71.
82. Backhaus M, Ohrndorf S, Kellner H, Strunk J, Backhaus TM, Hartung W, et al. Evaluation of a novel 7-joint ultrasound score in daily rheumatologic practice: A pilot project. *Arthritis Care Res*. 2009;61(9):1194–201.

83. Cozzi F, Raffeiner B, Beltrame V, Ciprian L, Coran A, Botsios C, et al. Effects of mud-bath therapy in psoriatic arthritis patients treated with TNF inhibitors. Clinical evaluation and assessment of synovial inflammation by contrast-enhanced ultrasound (CEUS). *Joint Bone Spine*. 2015;82(2):104–8.
84. Fiocco U, Ferro F, Vezzù M, Cozzi L, Checchetto C, Sfriso P, et al. Rheumatoid and psoriatic knee synovitis: Clinical, grey scale, and power Doppler ultrasound assessment of the response to etanercept. *Ann Rheum Dis*. 2005;64(6):899–905.
85. Fraser AD, van Kuijk AW, Westhovens R, Karim Z, Wakefield R, Gerards AH, et al. A randomised, double blind, placebo controlled, multicentre trial of combination therapy with methotrexate plus ciclosporin in patients with active psoriatic arthritis. *Ann Rheum Dis*. 2005 Jun;64(6):859–64.
86. Keen HI, Mease PJ, Bingham CO 3rd, Giles JT, Kaeley G, Conaghan PG. Systematic review of MRI, ultrasound, and scintigraphy as outcome measures for structural pathology in interventional therapeutic studies of knee arthritis: focus on responsiveness. *J Rheumatol*. 2011 Jan;38(1):142–54.
87. Naredo E, Batlle-Gualda E, García-Vivar ML, García-Aparicio AM, Fernández-Sueiro JL, Fernández-Prada M, et al. Power doppler ultrasonography assessment of entheses in spondyloarthropathies: Response to therapy of enthesial abnormalities. *J Rheumatol*. 2010;37(10):2110–7.
88. Teoli M, Zangrilli A, Chimenti MS, Talamonti M, Bavetta M, Graceffa D, et al. Evaluation of clinical and ultrasonographic parameters in psoriatic arthritis patients treated with adalimumab: a retrospective study. *Clin Dev Immunol*. 2012;2012:823854.
89. Schafer VS, Fleck M, Kellner H, Strunk J, Sattler H, Schmidt WA, et al. Evaluation of the novel ultrasound score for large joints in psoriatic arthritis and ankylosing spondylitis: six month experience in daily clinical practice. *BMC Musculoskelet Disord*. 2013;14:358.
90. Ficjan A, Husic R, Gretler J, Lackner A, Graninger WB, Gutierrez M, et al. Ultrasound composite scores for the assessment of inflammatory and structural pathologies in Psoriatic Arthritis (PsASon-Score). *Arthritis Res Ther*. 2014 Oct 31;16(5):476.
91. Gutierrez M, Di geso L, Salaffi F, Bertolazzi C, Tardella M, Filosa G, et al. Development of a preliminary US power Doppler composite score for monitoring treatment in PsA. *Rheumatol U K*. 2012;51(7):1261–8.
92. Ramírez García J, Inciarte-Mundo J, Ruíz-Esquide V, Cabrera S, Celis R, Cuervo A, et al. THU0177 Comparative Study on the Presence of Ultrasound Subclinical Synovitis between Patients with RA and PSA in Clinical Remission or Low Disease Activity in Treatment with Anti-TNF Therapy: Table 1. *Ann Rheum Dis*. 2014 Jun;73(Suppl 2):242.1–242.
93. Goncalves B, Ambrosio C, Serra S, Alves F, Gil-Agostinho A, Caseiro-Alves F. US-guided interventional joint procedures in patients with rheumatic diseases - When and how we do it? *Eur J Radiol*. 2011;79(3):407–14.
94. Di Geso L, Filippucci E, Meenagh G, Gutierrez M, Ciapetti A, Salaffi F, et al. CS injection of tenosynovitis in patients with chronic inflammatory arthritis: The role of US. *Rheumatol U K*. 2012;51(7):1299–303.
95. Cunnington J, Marshall N, Hide G, Bracewell C, Isaacs J, Platt P, et al. A randomized, double-blind, controlled study of ultrasound-guided corticosteroid injection into the joint of patients with inflammatory arthritis. *Arthritis Rheum*. 2010 Jul;62(7):1862–9.

96. Sibbitt WL, Band PA, Chavez-Chiang NR, Delea SL, Norton HE, Bankhurst AD. A randomized controlled trial of the cost-effectiveness of ultrasound-guided intraarticular injection of inflammatory arthritis. *J Rheumatol*. 2011 Feb;38(2):252–63.
97. Colebatch AN, Edwards CJ, Østergaard M, van der Heijde D, Balint PV, D’Agostino M-A, et al. EULAR recommendations for the use of imaging of the joints in the clinical management of rheumatoid arthritis. *Ann Rheum Dis*. 2013 Jun;72(6):804–14.
98. Sakellariou G, Scirè CA, Zambon A, Caporali R, Montecucco C. Performance of the 2010 classification criteria for rheumatoid arthritis: a systematic literature review and a meta-analysis. *PLoS One*. 2013;8(2):e56528.
99. Bellis E, Scirè CA, Carrara G, Adinolfi A, Batticciotto A, Bortoluzzi A, et al. Ultrasound-detected tenosynovitis independently associates with patient-reported flare in patients with rheumatoid arthritis in clinical remission: results from the observational study STARTER of the Italian Society for Rheumatology. *Rheumatol Oxf Engl*. 2016 Jun 27;
100. Døhn UM, Ejlertsen B, Boonen A, Hetland ML, Hansen MS, Knudsen LS, et al. No overall progression and occasional repair of erosions despite persistent inflammation in adalimumab-treated rheumatoid arthritis patients: results from a longitudinal comparative MRI, ultrasonography, CT and radiography study. *Ann Rheum Dis*. 2011 Feb;70(2):252–8.
101. Hetland ML, Ejlertsen B, Hørslev-Petersen K, Jacobsen S, Vestergaard A, Jurik AG, et al. MRI bone oedema is the strongest predictor of subsequent radiographic progression in early rheumatoid arthritis. Results from a 2-year randomised controlled trial (CIMESTRA). *Ann Rheum Dis*. 2009 Mar;68(3):384–90.
102. Dale J, Stirling A, Zhang R, Purves D, Foley J, Sambrook M, et al. Targeting ultrasound remission in early rheumatoid arthritis: the results of the TaSER study, a randomised clinical trial. *Ann Rheum Dis*. 2016 Jun;75(6):1043–50.

TABLES

Table 1: prevalence of US abnormalities (range, %) across primary studies

PsA patients	<i>Prevalence on site examined (%)</i>	<i>Prevalence on patient (%)</i>
<i>Gray Scale Synovitis</i>	14.0 – 57.0	10.0-100.0
<i>Power Doppler Synovitis</i>	2.0 – 8.7	28.6 – 73.0
<i>Joint erosions</i>	6.1 – 57.7	10.8 – 52.0
<i>Increased thickness of lower</i>	10.0 – 43.1	37.0 - 94.5
<i>Limbs entheses:</i>		
<i>PD at entheses</i>	0.0 - 7.4	15.6 - 40.2
<i>Enthesal erosions</i>	5.0 – 14.9	0.0 – 10.8
<i>Soft tissue inflammation</i>	38.9 – 65.8	14.3 – 32.0

Table 2. Summary table on prevalence, diagnosis and prognosis reporting high quality studies (i.e. relevant results for the reviewers and including at least 20 PsA patients or 30 Pso patients). that included at least 20 PsA patients or 30 Pso patients . Full results are reported in the supplementary online material.

Study	N	Population	Control	Examined structures	Equipment	Area of interest
Aydin et al. 2012	42 PsA	Cutaneous psoriasis with nail disease	20 HC	Nail	GE Logiq E9, 10-18 Mhz	Disease prevalence; Diagnosis of PsA and elementary lesions
Aydin et al. 2013	58 PsA	Cutaneous psoriasis including PsA	42 Pso; 23 HC	Lower limb entheses	GE Logiq E9 and Logiq5 machine	Disease prevalence; Diagnosis of PsA and elementary lesions; Prognosis
Bandinelli et al. 2015	112 PsA	PsA with symptoms onset < 1 year	-	MCP-PIP-DIP joints; flexor and extensor digitorum tendons; radio and intercarpal joints	Esaote MyLab70 XVG, 6-18 Mhz	Disease prevalence; Diagnosis of elementary lesions
Eder et al. 2014	50 PsA	PsA	66 Pso; 60 HC	Enthesis included in the MASEI score	Esaote MyLab 70XVG, 6-18 MHz	Disease prevalence; Diagnosis of PsA and elementary lesions
Fourniè et al. 2006	20 PsA	PsA and RA	21 RA	Hand joints (MCP, PIP and DIP); Extensor and flexor tendon; Soft tissue	Siemens Sonoline Elegra, 13.5 Mhz	Disease prevalence; Diagnosis of PsA and elementary lesions
Freeston et al. 2012	42 PsA	Early PsA (<24 months)	10 HC	Lateral epicondyles of the elbow, inferior patellar tendon insertion, Achilles tendon, plantar fascia	Philips HDI 5000, 5-12 and 7-15 MHz	Disease prevalence; Diagnosis of PsA and elementary lesions
Freeston et al. 2014	49 PsA	Early PsA (<24 months)	8 HC	Bilateral posterior glenohumeral joints, olecranon fossa,	Philips HDI 5000 machine, 5-12 MHz and 7-15	Disease prevalence; Diagnosis of elementary lesions

				wrists, MCP and PIP joints, knees, tibiotalar and MTP joints	MHz	
Gisondi et al. 2008	30 Pso	Pso without any clinical evidence of arthritis or enthesitis	30 HC	Target entheses (GUESS score)	ATL HDI 3000, 10–15 MHz probe	Prognosis
Gutierrez et al. 2011	20 PsA	PsA and RA	18 RA	MCP joints	Esaote MyLab70 XVG 6-18 Mhz	Disease prevalence; Diagnosis of PsA and elementary lesions
Gutierrez et al. 2011	45 Pso	Pso without any clinical evidence of arthritis or enthesitis	45 HC	Target entheses of GUESS score	Esaote MyLab70 XVG 6-18 Mhz	Disease prevalence; Prognosis
Husic et al. 2014	70 PsA	PsA	-	68 joints and 14 entheses	Esaote MyLabTwice, 6-18 Mhz	Prognosis
Marchesoni et al. 2012	30 PsA	PsA and Fibromyalgia (FM)	30 FM	14 target entheses	GE Logiq5, 8-15 Mhz	Disease prevalence; Diagnosis of PsA
Naredo et al. 2011	162 Pso	Plaque psoriasis	60 controls with other skin disease	wrist, MCP- PIP and DIP joints of the hands, knee, tibiotalar joint; extensor tendon of the wrist; finger flexor tendon; target entheses	GE Logiq 9, 8-14 Mhz	Disease prevalence; Prognosis
Tinazzi et al. 2011	30 Pso	Pso	-	Target entheses (GUESS score)	ATL HDI 3000, 10–15 MHz probe; GE Logiq5, 10-15 Mhz	Prognosis
Zayat et al. 2015	60 PsA	PsA, RA, gout and OA	70 RA, 60 gout, 60 OA, 60 HC	distal articular radius and ulna, II-III and V MCP joints, II-III PIP joints and I and V MTP joints, 2nd, 3rd	GE LogiqE9, 6-15 Mhz	Disease prevalence; Diagnosis of elementary lesions

Table 3: Studies evaluating US in monitoring PsA. US: ultrasonography.

Study	N	Study design	Inclusion criteria	Examined structures	Equipment	Results	Risk of bias
Acquacalda 2015	22 Pso 12 PsA	Prospective cohort	CASPAR before introduction of the first systemic treatment or biologic	5 entheses Hypoechogenicity, thickness, erosion, calcification, PD, morphological/structural lesion	Esaoite MyLab70 XVG	US morphological abnormalities (baseline vs 6 months) PsO 30% vs 17.7% P=0.021 PsA (PD) 33% vs 24% p=0.164	Sel ** Comp ** Exp **
Backhaus 2009	120 patients (PsA 9%)	Prospective cohort	PSA starting new therapy	Wrist, 2 nd - 3 rd MCP and PIP, 2 nd -5 th MTP GS and PD	Different US machines	3 months: synovitis GSUS/DAS28 r=0.44, p<0.05 PDUS/DAS28 r=0.44, p<0.05 tenosynovitis GSUS/DAS28 r=0.11, p>0.05 PDUS/DAS28 r=0.11, p>0.05 Erosions/DAS28 r=0.11, p>0.05 6 months: synovitis GSUS/DAS28 r=0.38, p<0.05 PDUS/DAS28 r=0.31, p<0.05 tenosynovitis GSUS/DAS28 r=0.26, p<0.05 PDUS/DAS28 r=0.24, p<0.05 Erosions/DAS28 r=0.16, p>0.05	Sel *** Comp Exp *
Bonifati 2014	25 PsA	Retrospective cohort	CASPAR criteria, ETA o ADA (>12 months)	Target joints US contrast-enhanced	-	Positive CEUS (baseline vs 12 months) 22/25 vs 3/25 p<0.0001	Sel *** Comp Exp **
Cozzi 2015	36 PsA	RCT	CASPAR, TNFi >6 months	All joints of both hands	Esaoite My Lab	CEUS in PsA receiving mud-bath (baseline-45 days):	High Risk

				US contrast enhanced	70	seconds, mean (sd)		
							Time of appearance 22.21 (8.79) vs 25.71 (12.81) p<0.05	
							Washout rate 9.32 (0.49) vs 9.12 (0.78) p>0.05	
							Peak value 0.14 (0.06) vs 0.13 (0.04) p>0.05	
							Contrast flow 0.07 (0.03) vs 0.06(0.03) P<0.05	
Ficjan 2014	83 PsA	Prospective cohort	CASPAR, peripheral articular manifestations	PsASon 22, bilateral score included 22 joints and 4 entheses.	Esaote My Lab Twice	PsASon 22 and 13 (6 months)		Sel ***
						Global ultrasound inflammation subscore:		Comp
						SRM: -0.53 to -0.04 (entire cohort)		Exp ***
				PsASon13, unilateral score included 13 joints and 2 entheses		-1.04 to -0.09 (pts from active disease to MDA)		
						ICC: 0.84 (PsASon22), 0.54 (PsASon 0.96)		
Fiocco 1996	23 patients (11 PsA)	Prospective cohort	Moll and Wright, Knee joint pain, patients treated with NSAIDs and second-line drugs >6 months	Knee Joint effusion/Synovial Tickness	7.5 MHz electronic linear transducer/10 MHz mechanical sectorial transducer	Significant correlation between clinical and US indexes at all timepoints (baseline, 2 months, 6 months, 12 months)		Sel ** Comp * Exp **
Fiocco 2005	27 patients (8 PsA)	Prospective cohort	Moll and Wright Criteria, eligible for TNFi	Involved knee Synovitis PD	Elegra, Siemens	F/SI-PD mean (sd) Baseline 1.31 (0.30) ; 3 months 0.63 (0.21) p<0.001; 12 months 0.44 (0.20) p<0.05		Sel *** Comp Exp **
						P/CI-PD mean (sd) Baseline 1.59 (0.21), 3 months 1.62 (0.018) p>0.05; 12 months 0.89 (0.18) <0.05		
Fraser 2005	72 PsA	RCT	18-70 years, PsA criteria 1994 >24 weeks,	2 nd -5 th MCP and PIP of the	ATL HDI 3000	US synovitis reduction after 12 months		Unclear

			active PsA and Pso, no response to MTX	dominant hand		-2.5 (95% CI -4.07, -1.01)	
Keen 2011	-	Systematic review	published studies in English, humans, comparing imaging of structural tissue	Involved knee Synovial thickness, effusion size, PD	-	US internal responsiveness was found with regard to synovial thickness, effusion size, and popliteal cyst size.	PRISMA Checklist: 20/28
						External responsiveness was demonstrated against several referenced health status measures.	
						No quantitative synthesis, references were screened.	
Gutierrez 2012	16 PsA	Prospective cohort	CASPAR, starting therapy with ADA, ETA, IFX	MCPs, MTPs, wrists, finger flexor tendons, tibialis posterior tendons, peroneous tendons, entheses (Achilles tendon, distal and proximal insertion of patellar tendon), psoriatic plaques, nails.	Esaote My Lab 70 XVG	Median (IQR) 5 target PD: Baseline 9 (4-12), 8 weeks 3 (1-5), p=0.0001 Inter-reader reliability baseline k: joint 0.74, tendon 0.79 entheses 0.97, nail 0.65, skin 0.88 Intra-reader reliability baseline k: joint 0.98, tendon 0.98, entheses 0.97, nail = 0.82, skin 0.94	Sel *** Comp Exp **
Naredo 2010	327 SpA	Prospective cohort	ESSG or Amor criteria, starting TNF i	14 peripheral entheses. Morphologic abnormalities, Calcific deposits, Cortical abnormalities, adjacent bursitis, PD	Logiq 5 PRO; (General Electric)	Baseline vs 6 months (mean , sd) Morphologic abnormality score 2.19 (2.66) vs 1.34 (2.02) p<0.0005 Calcific deposit score 1.11 (1.63) vs 1.23 (1.79) p=0.142 Cortical abnormality score 3.92 (3.73) vs 4.17 (3.86) p=0.036 Adjacent bursitis score 0.94 (1.21) vs 0.76 (1.19) p=0.036 Intraentheses PD 1.36 (2.11) vs 0.68 (1.64) p<0.0005 Perientheses PD 1.75 (2.92) vs 0.98 (2.23) p<0.0005	Sel *** Comp Exp ***
Teoli 2012	40 PsA	Retrospective cohort	CASPAR; therapy with ADA	Most clinically involved joints. Synovial effusion, synovial	Logiq 5 Pro (General	Baseline vs 24 months score (mean , IQR) Synovial effusion 2.3 (1–3) vs 0.1 (0-1)	Sel *** Comp

				proliferation, PD	Electric)	Synovial proliferation 1,125 (0–2) vs 0,025 (0-1)	Exp **
						PD 2.5 (1–3) vs 1 (0–2)	
						Bone erosions 0,2 (0–2) vs 0,25 (0–2)	
Schafer	126 SpA	Prospective cohort	CASPAR	Shoulder, elbow, hip, knee	-	Baseline vs 6 months score (mean, sd)	Sel ***
2013				Solar score (GS/PD)		Shoulder GS 2.8 (1.9) vs 1.1 (1.2) p<0.05	Comp
						PD 1.7 (1.6) vs 0.4 (0.8) p<0.05	Exp ***
						Elbow GS 4,3 (2.6) vs 0.9 (1.5) p<0.05	
						PD 2.3 (2.0) vs 0.6 (1.1) p<0.05	
						Hip GS 2.0 (0.8) vs 1.0 (1.1) p<0.05	
						PD 0.7 (0.9) vs 0.3 (0.5) p>0.05	
						Knee GS 5.3 (2.9) vs 2.8 (2.8) p<0.001	
						PD 2.9 (3.1) vs 1.4 (2.4) p<0.05	
Coates 2015	89 PsA	Retrospective cohort	Early PsA	Hands US	Unclear	Erosions (%) baseline vs 48 weeks	Unclear
				Erosions		3.5% vs 5.6%	

PsA: psoriatic arthritis; Pso: psoriasis; HC; N: number; GS: grey-scale, PD: power Doppler; MCP: metacarpophalangeal joints; PIP: proximal interphalangeal joints; MTP: metatarsophalangeal joints; CASPAR: Classification criteria for psoriatic arthritis, PASI: psoriasis area severity index; TNFi: tumor necrosis factor inhibitors; ADA: adalimumab; ETA: etanercept; IFX: infliximab; MTX: methotrexate; CSA: cyclosporine A; NSAIDs: non steroidal anti-inflammatory drugs; F/SI-PD: fluid/synovium interface; P/CI-PD pannus/cartilage or pannus/ capsule interface.

Table 4: Research Agenda of US in PsA and Pso patients

-
1. To investigate the integration of US in clinical practice in order to improve the certainty of diagnosis
 2. To investigate which US elementary lesions could be highly specific for PsA
 3. To investigate the prognostic role of US in identifying Pso patient at risk to develop PsA
 4. To further analyse US score in order to monitor disease activity
 5. To identify US predictors of treatment response in order to stratify treatment regimen (i.e. better selection of patients with poorer outcome)
 6. To further analyse the supposed superiority of US guided injection compared to palpation guided injection
-

FIGURES

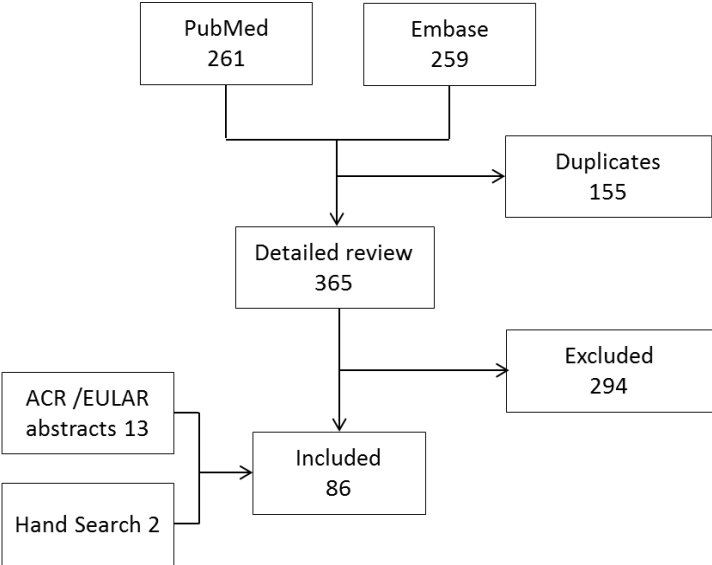


Figure 1: flow-chart showing the selection process.

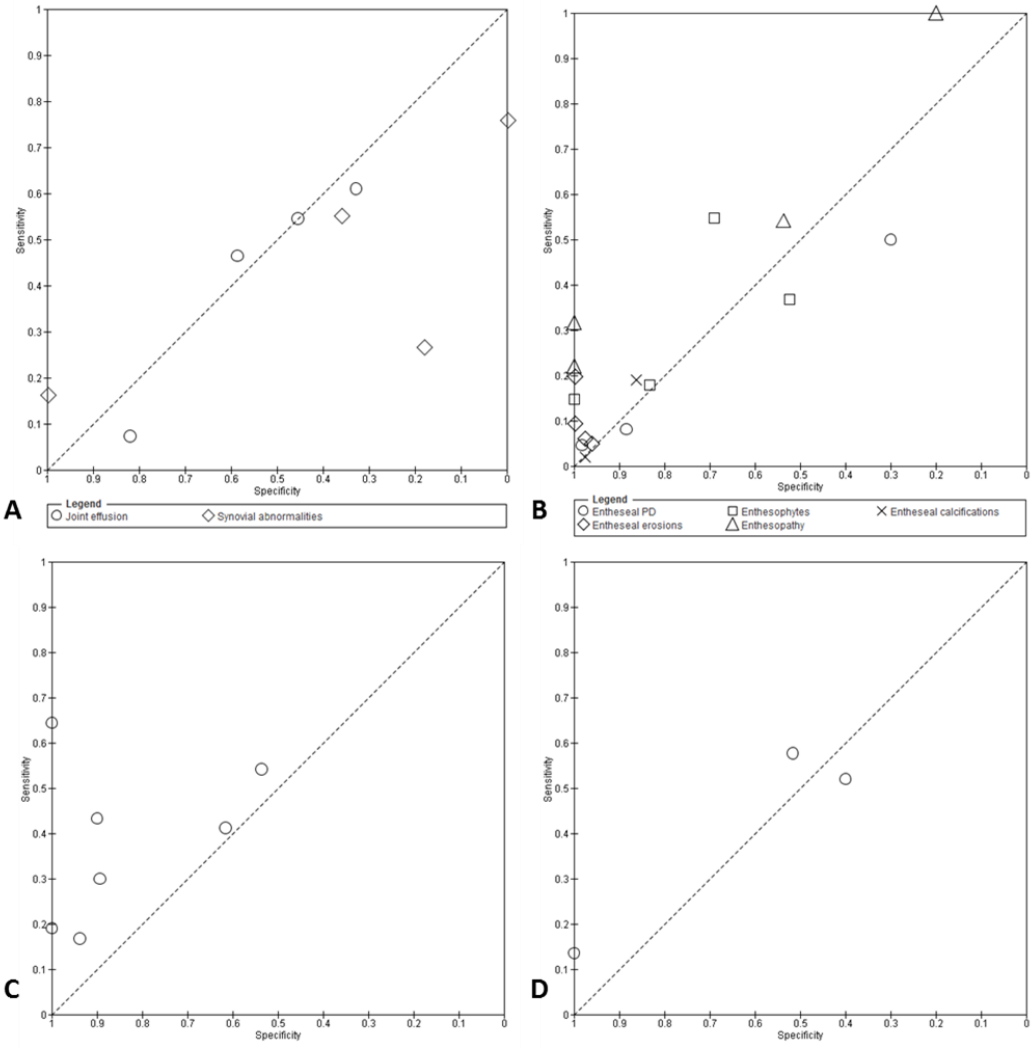


Figure 2: Performance of US variables to diagnose PsA: sensitivities and specificities of primary studies. A: synovial abnormalities/joint effusion; B: enthesal abnormalities; C: tendon abnormalities; D: bone erosions. No US abnormality, considered alone, had an optimal diagnostic performance to diagnose PsA.

ACKNOWLEDGEMENTS

UPSTREAM study group

Andrea Delle Sedie; Antonella Draghessi; Alessandra Gabba; Alessandro Volpe; Andrea Di Matteo; Antonella Adinolfi; Bernd Raffeiner; Francesca Bandinelli; Alberto Batticciotto; Nicola Boffini; Alessandra Bortoluzzi; Carlo Venditti; Claudio Mastaglio; Scioscia Crescenzo; Daniela Rossi; Daniele Lubrano; Emanuela Bellis; Emilio Filippucci; Gentiana Vukatana; Georgios Filippou; Gianluca Santoboni; Giovanni Cagnotto; Giuseppe Scavo; Ilaria Tinazzi; Giuliana Maria Concetta La Paglia; Luca Idolazzi; Filippo Luccioli; Marco Canzoni; Maria Cristina Focherini; Pierluigi Macchioni; Marilena Frigato; Marta Caprioli; Michele Colaci; Giulia Mirabelli; Mirco Magnani; Marco Massarotti; Orazio De Lucia; Oscar Massimiliano Epis; Marco Piras; Roberta Ramonda; Salvatore Bellinvia; Silvia Rossi; Simone Parisi; Matteo Piga; Riccardo Terenzi; Valentina Denaro; Viviana Ravagnani; Alen Zabotti; Garifallia Sakellariou; Carlo Alberto Scirè; Annamaria Iagnocco

CONFLICT OF INTEREST STATEMENT

The authors declare no conflicts of interest

FUNDING STATEMENT

This study has been supported by the Musculoskeletal Study Group of the Italian Society for Rheumatology.