

## Mutations in Multiple PKD Genes May Explain Early and Severe Polycystic Kidney Disease

Carsten Bergmann,<sup>\*†</sup> Jennifer von Bothmer,<sup>†</sup> Nadina Ortiz Brüchle,<sup>†</sup> Andreas Venghaus,<sup>†</sup> Valeska Frank,<sup>\*</sup> Henry Fehrenbach,<sup>‡</sup> Tobias Hampel,<sup>‡</sup> Lars Pape,<sup>§</sup> Annegret Buske,<sup>||</sup> Jon Jonsson,<sup>¶\*\*</sup> Nanette Sarioglu,<sup>††</sup> Antónia Santos,<sup>‡‡</sup> Jose Carlos Ferreira,<sup>‡‡</sup> Jan U. Becker,<sup>§§</sup> Reinhold Cremer,<sup>|||</sup> Julia Hoefele,<sup>¶¶</sup> Marcus R. Benz,<sup>¶¶</sup> Lutz T. Weber,<sup>¶¶</sup> Reinhard Buettner,<sup>\*\*\*</sup> and Klaus Zerres<sup>†</sup>

<sup>\*</sup>Center for Human Genetics, Bioscientia, Ingelheim, Germany; <sup>†</sup>Department of Human Genetics, Rheinisch-Westfaelische Technische Hochschule (RWTH) Aachen University, Germany; <sup>‡</sup>Department of Pediatric Nephrology, Memmingen, Germany; <sup>§</sup>Department of Pediatric Nephrology, Hannover Medical School, Hannover, Germany; <sup>||</sup>Practice for Medical Genetics, Berlin, Germany; <sup>¶</sup>Department of Genetics and Molecular Medicine, Landspítali University Hospital, Reykjavik, Iceland; <sup>\*\*</sup>Department of Biochemistry and Molecular Biology, University of Iceland, Reykjavik, Iceland; <sup>††</sup>Department of Pathology, Charité Campus Virchow, Berlin, Germany; <sup>‡‡</sup>Department of Obstetrics & Gynecology, Prenatal Diagnosis Center, Hospital Garcia de Orta, Almada, Portugal; <sup>§§</sup>Department of Pathology, Hannover Medical School, Hannover, Germany; <sup>|||</sup>Pediatric Nephrology Clinics, Children's Hospital Cologne, Cologne, Germany; <sup>¶¶</sup>Pediatric Nephrology, Dr. von Haunersches Kinderspital, University Children's Hospital, Ludwig-Maximilian's University, Munich, Germany; and <sup>\*\*\*</sup>Department of Pathology, University of Cologne, Cologne, Germany

### ABSTRACT

Autosomal dominant polycystic kidney disease (ADPKD) is typically a late-onset disease caused by mutations in *PKD1* or *PKD2*, but about 2% of patients with ADPKD show an early and severe phenotype that can be clinically indistinguishable from autosomal recessive polycystic kidney disease (ARPKD). The high recurrence risk in pedigrees with early and severe PKD strongly suggests a common familial modifying background, but the mechanisms underlying the extensive phenotypic variability observed among affected family members remain unknown. Here, we describe severely affected patients with PKD who carry, in addition to their expected familial germ-line defect, additional mutations in PKD genes, including *HNF-1 $\beta$* , which likely aggravate the phenotype. Our findings are consistent with a common pathogenesis and dosage theory for PKD and may propose a general concept for the modification of disease expression in other so-called monogenic disorders.

*J Am Soc Nephrol* 22: 2047–2056, 2011. doi: 10.1681/ASN.2010101080

Autosomal dominant polycystic kidney disease (ADPKD) is the most frequently inherited renal disease and one of the most common Mendelian human disorders with a prevalence of 1/400 to 1/1000.<sup>1,2</sup> This approximates to about 12.5 million affected individuals worldwide. About 5 to 10% of all patients requiring renal replacement therapy are affected by ADPKD. As the name implies, ADPKD is transmitted in an autosomal dominant, fully penetrant fashion, *i.e.* virtually all individuals who inherit a mutated *PKD* allele

in their germ-line will develop sonographically detectable renal cysts by age 30 or slightly later.

Received October 21, 2010. Accepted August 1, 2011.

Published online ahead of print. Publication date available at [www.jasn.org](http://www.jasn.org).

**Correspondence:** Dr. Carsten Bergmann, Center for Human Genetics, Bioscientia, Konrad-Adenauer-Str. 17, 55218 Ingelheim, Germany. Phone: 49-6132-781-476; Fax: 49-6132-781-298; E-mail: [carsten.bergmann@bioscientia.de](mailto:carsten.bergmann@bioscientia.de)

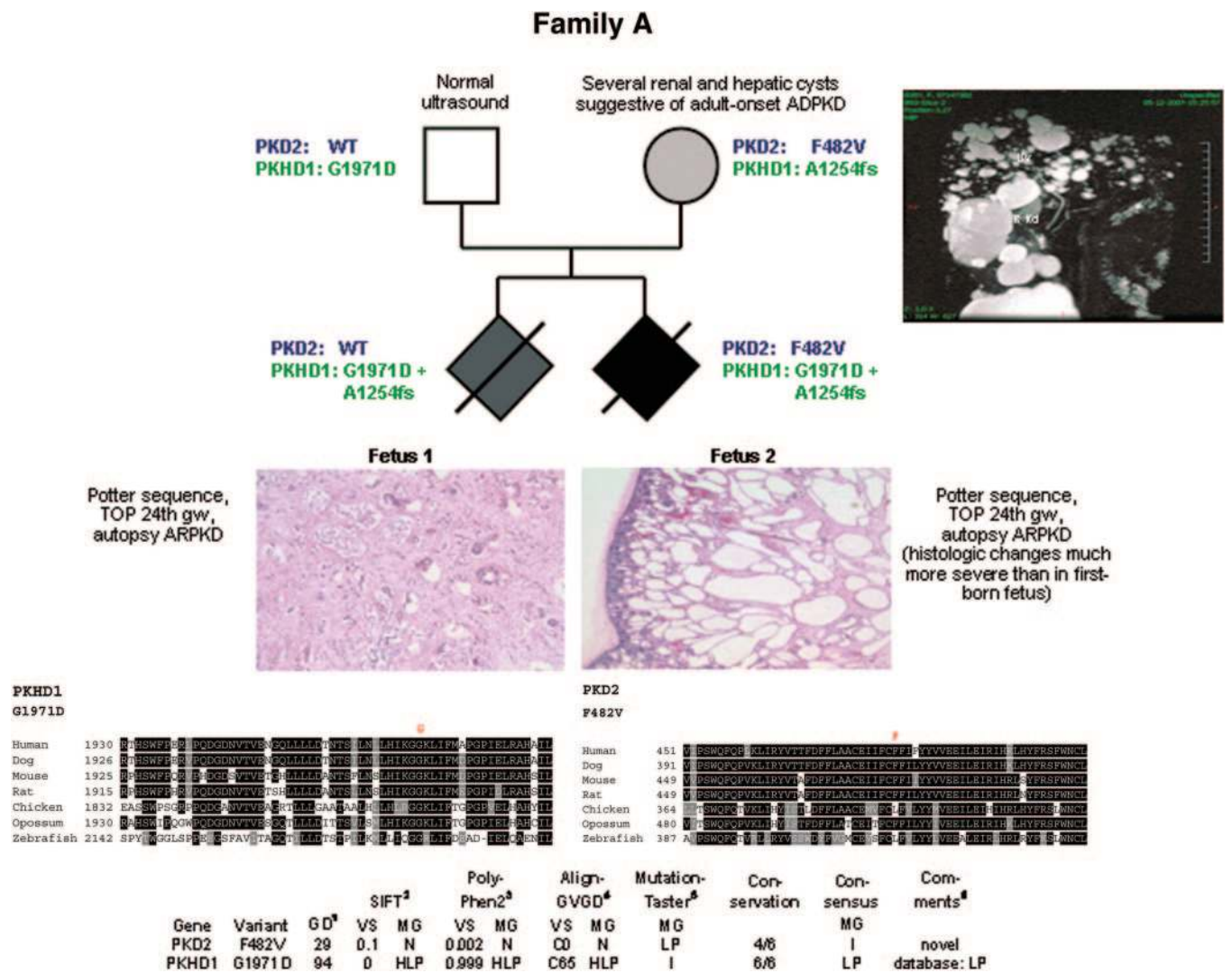
Copyright © 2011 by the American Society of Nephrology

Clinical symptoms usually do not arise until middle age. The majority of ADPKD patients carry a germ-line mutation in the *PKD1* gene on chromosome 16p13, and 15 to 20% of patients harbor a *PKD2* mutation on 4q21. ADPKD1 causes more severe disease with an average age of 54 years (*versus* 74 years for ADPKD2) at ESRD.<sup>3</sup>

In a minor subset of patients, ADPKD manifests very early in life and as a much more severe disorder.<sup>4,5</sup> We recently demonstrated that early and severe ADPKD is not strictly confined to persons with a *PKD1* mutation as previously thought but can also occur in patients with a *PKD2* mutation.<sup>6,7</sup> Homozygosity for *PKD1* and the coinheritance *in trans* of an incompletely penetrant *PKD1* allele with an inactivating *PKD1* mutation may explain some of the cases of early-onset PKD; however, other mechanisms for early-onset ADPKD are still

unknown.<sup>8,9</sup> Among those cases with early-onset PKD are fetuses with Potter sequence and significant perinatal/neonatal morbidity and mortality sometimes clinically indistinguishable from those with a typical presentation of autosomal recessive polycystic kidney disease (ARPKD) and mutations in the *PKHD1* gene on chromosome 6p12.<sup>9</sup> Several lines of evidence corroborate these clinical observations and suggest a common pathogenesis for these diseases.

First, most cystoproteins, among them the ADPKD proteins polycystin-1 and polycystin-2 and the ARPKD protein fibrocystin/polyductin, colocalize in primary cilia and related organelles. Polycystin-1 and polycystin-2 directly interact, and polycystin-2 and polyductin form a common protein complex in which polyductin is crucial for polycystin-2 channel function.<sup>10,11</sup>



**Figure 1.** Pedigree of family A with clinical information, genotypes, multisequence alignments, and bioinformatic data for both missense changes detected. Renal histology shows much more severe changes in the second-born fetus than in the first-born as regards size and number of renal cysts. (Top right panel) MR cholangiogram (T2-weighted gadolinium-enhanced coronal projection) of the mother of both fetuses in family A at 35 years of age showing multiple cysts of various sizes. The multiple hepatic cysts do not communicate with the biliary tree. Liv, Liver; R Kd, right kidney; S, superior; I, inferior; LA, left anterior; RP, right posterior.

On a cellular level, a recessive two-hit disease model has been proposed for ADPKD with a *PKD1* or *PKD2* germ-line mutation on one allele and a transheterozygous somatic *PKD1* or *PKD2* mutation. In keeping with a recessive disease model, *Pkd1* mice harboring a hypomorphic missense change on both alleles develop severe PKD that interestingly is confined to distal nephron segments and thus mimic the pattern typically seen in ARPKD.<sup>12</sup> Likewise, ARPKD patients and mice with cysts not confined to distal tubules and collecting ducts but present in all nephron segments are also known (our unpublished data).<sup>13</sup> Hepatic ductal plate malformation is an invariable feature of ARPKD but can also be found in some patients with ADPKD.

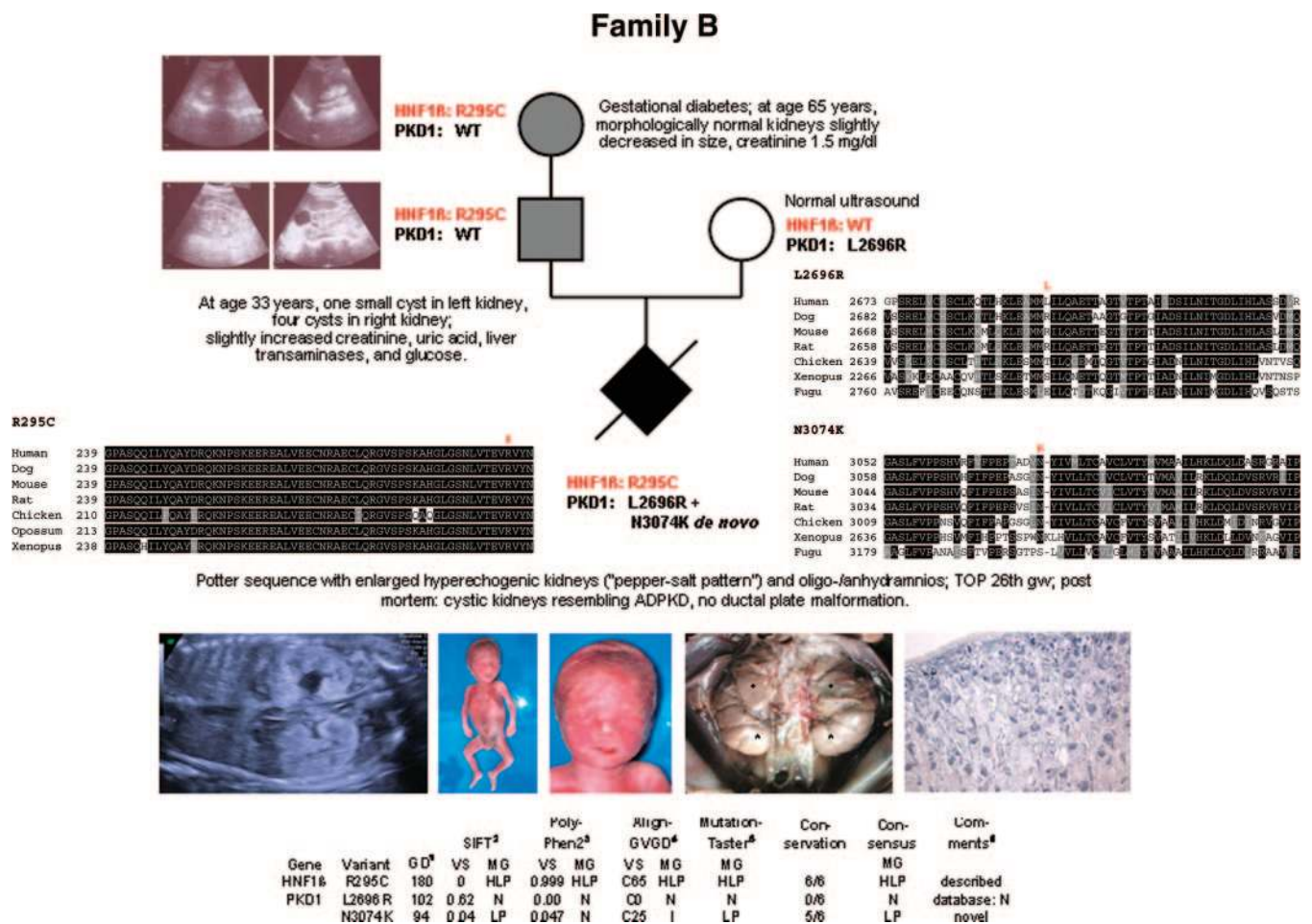
Williams *et al.*<sup>13</sup> described an ARPKD mouse model with a homozygous *Pkhd1* mutation in which *Pkd1* and *Pkd2* expression

was considerably reduced. Direct evidence for genetic interactions between ADPKD and ARPKD loci came from two other mouse studies in which *Pkhd1/Pkd1* and *Pkhd1/Pkd2* transmutants showed a much more severe renal cystic phenotype than mice bearing a mutation in only one of these genes.<sup>11,14</sup>

The high recurrence risk for early and severe polycystic kidney disease in affected pedigrees suggests a common familial modifying background.<sup>15</sup> Here we present the data of eight pedigrees in which the severely affected patients are the only family members that carry other PKD alleles *in trans* and/or *de novo* in addition to the familial germ-line mutation (see Figures 1 through 8).

**Family A**

The mother showed several renal and hepatic cysts of various sizes in accordance with a clinical diagnosis of ADPKD (Figure 1).



**Figure 2.** Pedigree of family B with genotypes, clinical and ultrasonographic data, multisequence alignments, and bioinformatic data for all three missense changes identified in this family. (Top panel) At age 65 years, the grandmother’s kidneys were slightly decreased in size but morphologically normal without any cyst. (Middle panel) The father’s kidneys showed one small cyst on the left and four cysts on the right side at the age of 33 years. (Bottom left panel) Prenatal ultrasound revealed oligo/anhydramnios and enlarged hyperchogenic fetal kidneys with a so-called “pepper-salt pattern.” (Bottom middle panel) Post mortem findings in the severely affected male fetus of this family with facial features typical of Potter sequence (termination of pregnancy in the 26th week of gestation [TOP 26th gw]). Abdominal situs with bilaterally enlarged kidneys (weight, 12.5 g; reference range for respective gestational age, 5.5 to 9.3 g). \*Kidneys; +adrenal glands; arrows, ureters. (Bottom right panel) Renal histology (2.5× hematoxylin and eosin staining) with small tubular and glomerular cysts. The collecting ducts were not considerably dilated.

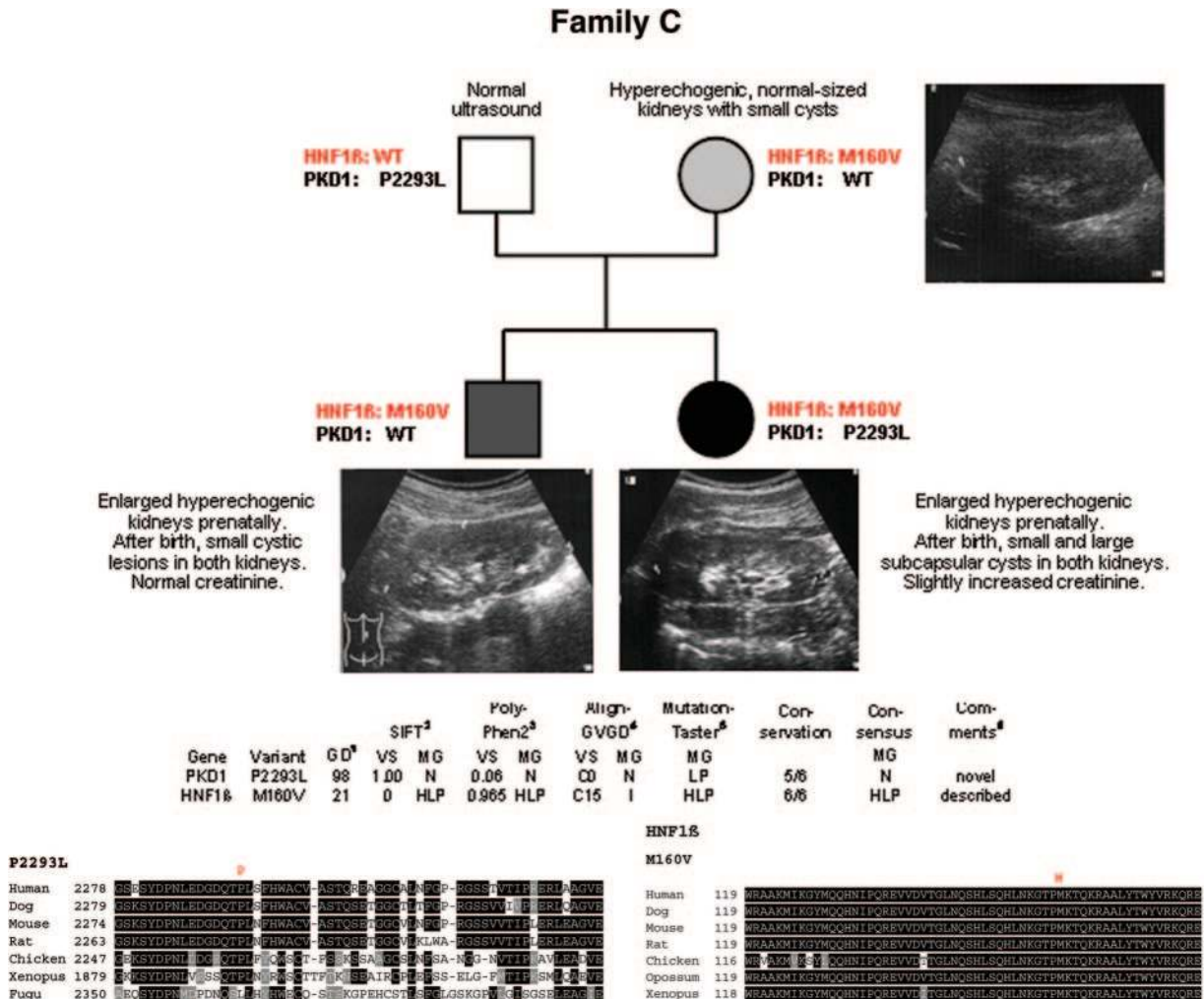
Both of her pregnancies were complicated by Potter sequence with enlarged hyperechogenic kidneys and oligo/anhydramnios and terminated in the 24<sup>th</sup> gestational week, respectively. Post mortem performed in both fetuses was in line with ARPKD. However, notably, pathologic changes were much more severe in the second-born fetus (Figure 1). By *PKHD1* mutation analysis, two convincing mutations were found that both have been described in the literature: paternally, the non-conservative, an evolutionarily highly conserved amino acid affecting missense mutation c.5912G>A (p.G1971D), and maternally, the frameshifting mutation c.3761\_3762delCC insG (p.A1254fs). However, heterozygosity for *PKHD1* could not explain the clinical features suggestive of ADPKD in the mother. Thus, we proceeded with sequencing of *PKD1* and *PKD2* and detected the novel *PKD2* missense mutation c.1444T>G (p.F482V) that was not present among 200 tested controls and alters a conserved polycystin-2 residue. In line with a dosage theory for PKD, only the

more severely affected second fetus inherited this *PKD2* allele.

As regards the next families discussed, it is of importance that *HNF1β/TCF2* mutations can mimic polycystic kidney disease and that phenotypic variability, even within a family, is often extensive (our unpublished data).<sup>16–18</sup> *HNF1β* directly regulates the transcription of *PKD2* and *PKHD1*.<sup>19</sup> In line, mice with renal-specific inactivation of *Hnf1β* develop polycystic kidney disease and renal cyst formation is accompanied by a drastic defect in *Pkd2* and *Pkhd1* expression.<sup>20</sup> Thus, it can be postulated that early and severe PKD phenotypes in patients with *HNF1β* mutation may, at least in part, be due to *in trans* coinheritance of changes in the genes for ADPKD and ARPKD.

**Family B**

The couple's first pregnancy was affected with Potter sequence. The ultrasonographic "pepper-salt pattern" of the fetal kidneys was suggestive of ARPKD (Figure 2). The couple decided to



**Figure 3.** Pedigree of family C with genotypes, *in silico* information on both missense changes detected in this family, and clinical and ultrasonographic data. Mother and son presented with hyperechogenic normal-sized kidneys with small cysts, whereas the daughter additionally displayed some large subcapsular cystic lesions.

terminate the pregnancy in the 26<sup>th</sup> gestational week. Post mortem showed cystic kidneys resembling ADPKD, but no evidence of ductal plate malformation in the liver. The mother displayed normal renal ultrasound, whereas the father had one small cyst in his left kidney and four cysts in the right kidney at the age of 33 years. Clinically, he showed slightly increased levels of creatinine, uric acid, liver transaminases, and glucose. His mother developed gestational diabetes and later on type 2 diabetes. At the age of 65 years, she showed morphologically normal kidneys slightly decreased in size by ultrasound and a creatinine of 1.5 mg/dl.

Given the clinical data and family history, we started with mutation analysis of *HNF1B* and detected the missense mutation c.883C>T (p.R295C) in the fetus, father, and paternal grandmother. This mutation has been described in the literature, affects an evolutionarily conserved amino acid, and is bioinformatically predicted to be “highly likely pathogenic.”<sup>21</sup> To explain the severe fetal phenotype suggestive of ADPKD, we additionally performed sequencing of the known PKD genes and identified the *PKD1* missense change c.8087T>G (p.L2696R) on the maternal allele, classified as neutral in the ADPKD database, in line with the normal renal phenotype of the mother. In addition, only the fetus was shown to carry the novel *PKD1* mutation c.9222C>G (p.N3074K) that arose *de novo* and affects an evolutionarily highly conserved residue. In accordance, *in silico* data predicts this mutation to be “likely pathogenic.”

### Family C

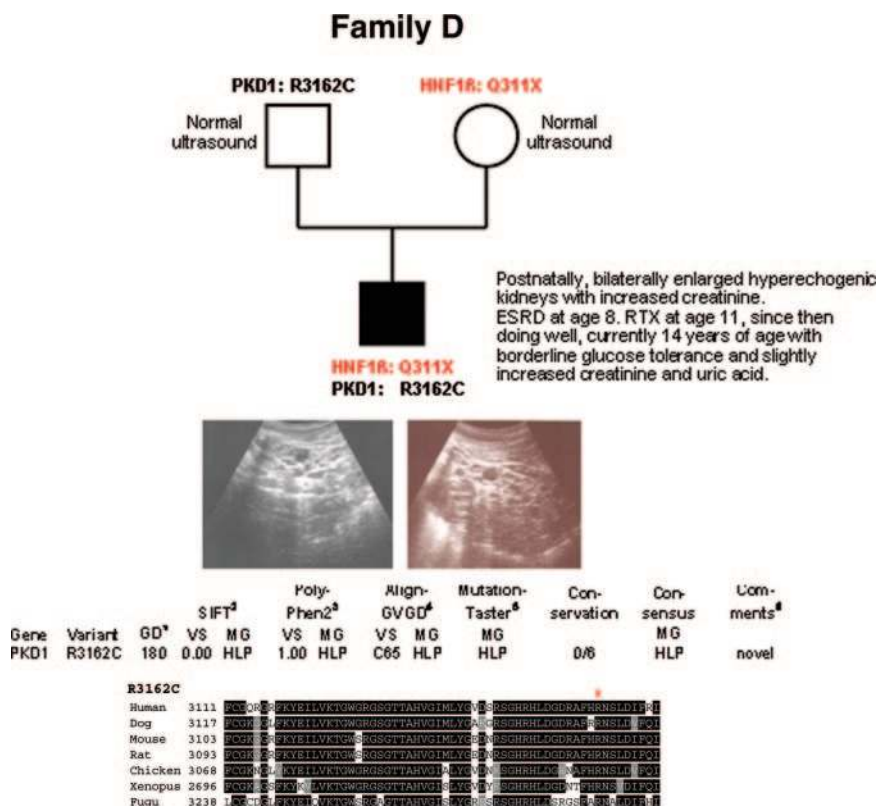
Both pregnancies of this couple were complicated by enlarged hyperechogenic kidneys. Postnatally, small cystic lesions were present in the son, whereas large subcapsular cystic lesions were additionally noted in the daughter (Figure 3). We initiated *HNF1B* mutation analysis because kidney biopsy revealed glomerular cysts. This resulted in detection of the novel missense mutation c.478A>G (p.M160V) that was absent from 200 controls, affects an evolutionarily highly conserved residue, and was categorized *in silico* as “(highly) likely pathogenic.” Segregation analysis revealed this mutation to be of maternal origin. The mother was clinically healthy but showed hyperechogenic, normal-sized kidneys with small cysts. No other *HNF1B*-related feature was present in her. Sequencing of the mother’s parents proved the mutation to be *de novo* in her. To explain the clinical variability in this family, we proceeded with sequencing of *PKD1*, *PKD2*, and *PKHD1*. By this, we identified the novel and putatively hypomorphic *PKD1* missense mutation c.6878C>T (p.P2293L) on the daughter’s paternal allele, for which her brother and mother showed the wild-type sequence. In line with recent data on incomplete *PKD1* penetrance and normal ultrasound data of the father in this family, heterozygous *PKD1* alleles like P2293L are assumed to be not sufficient to cause ADPKD but can exert an aggravating effect in concert with other changes, a hypothesis that is further corroborated by

the findings obtained in the pedigrees described below.<sup>8,9</sup>

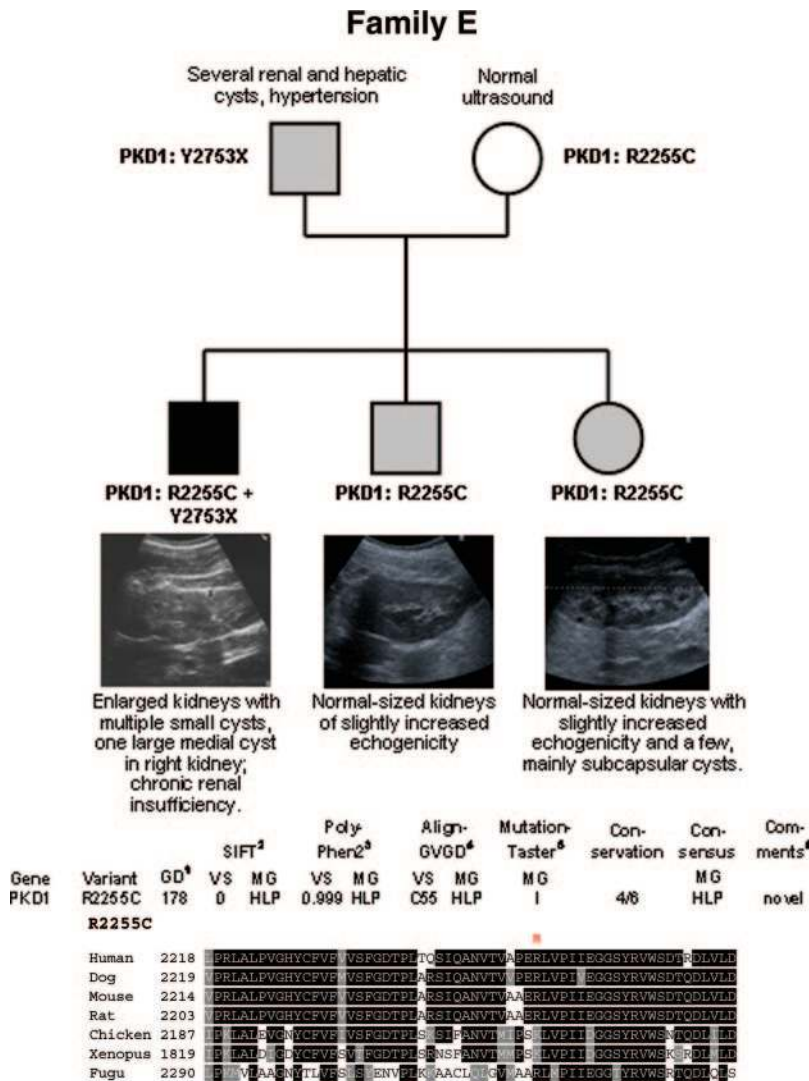
### Family D

The family’s proband already displayed increased serum creatinine values and ultrasonographic features of PKD with bilaterally enlarged hyperechogenic kidneys postnatally (Figure 4). At the age of 8 years, he proceeded to ESRD and received peritoneal dialysis for almost 3 years before he was successfully transplanted. Since then he has been doing well with borderline glucose tolerance and slightly increased values for serum creatinine and uric acid at the age of 14 years. He carries the *HNF1B* nonsense mutation c.931C>T (p.Q311X) on his maternal allele, and the novel nonconservative *PKD1* missense mutation c.9484C>T (p.R3162C) on his paternal allele. This change affects an evolutionarily highly conserved residue and is predicted by all bioinformatic tools used to be “highly likely pathogenic.” Surprisingly, neither the mother nor the father showed any clinical or ultrasonographic features in their mid-thirties.

In addition to the above pedigrees with mutations in more than one PKD gene, we also identified ADPKD families



**Figure 4.** Pedigree and genotypes of family D. Renal ultrasound of the proband at the age of 10 years with polycystic, considerably enlarged hyperechogenic kidneys. (Bottom panel) Bioinformatic data obtained for the *PKD1* mutation R3162C.



**Figure 5.** Pedigree, genotypes, and renal ultrasound data of all children of family E. Enlarged kidneys with multiple small cysts and one large medial cyst in the right kidney were present in the eldest son, whereas his younger siblings demonstrated normal-sized kidneys with slightly increased echogenicity. A few mainly subcapsular cysts were also seen in the girl. (Bottom panel) *In silico* data obtained for the *PKD1* mutation R2255C identified in this pedigree.

in which the early and severely affected index patient harbored an *in trans* or *de novo* *PKD1* change in addition to the familiar *PKD1* germ-line mutation (see Figures 5 through 8).

**Family E**

The most severely affected eldest son of this family (Figure 5) carries *PKD1* mutations on both parental alleles: the nonsense mutation c.8259C>G (p.Y2753X) on his paternal allele and the nonconservative missense mutation c.6763C>T (p.R2255C) on his maternal allele, whereas his two siblings have only inherited the hypomorphic missense allele from her mother which obviously leads to mild disease with incomplete penetrance.

**Family F**

In this family (Figure 6), the novel 2-bp deletion in *PKD1* c.4051\_4052del (p.R1351fs) segregates with ADPKD, whereas the son’s early and severe phenotype with histologically proven ductal plate malformation is thought to have been further aggravated by occurrence of the paternally inherited nonconservative *PKD1* missense change c.8087T>G (p.L2696R) (same mutation as in Family B).

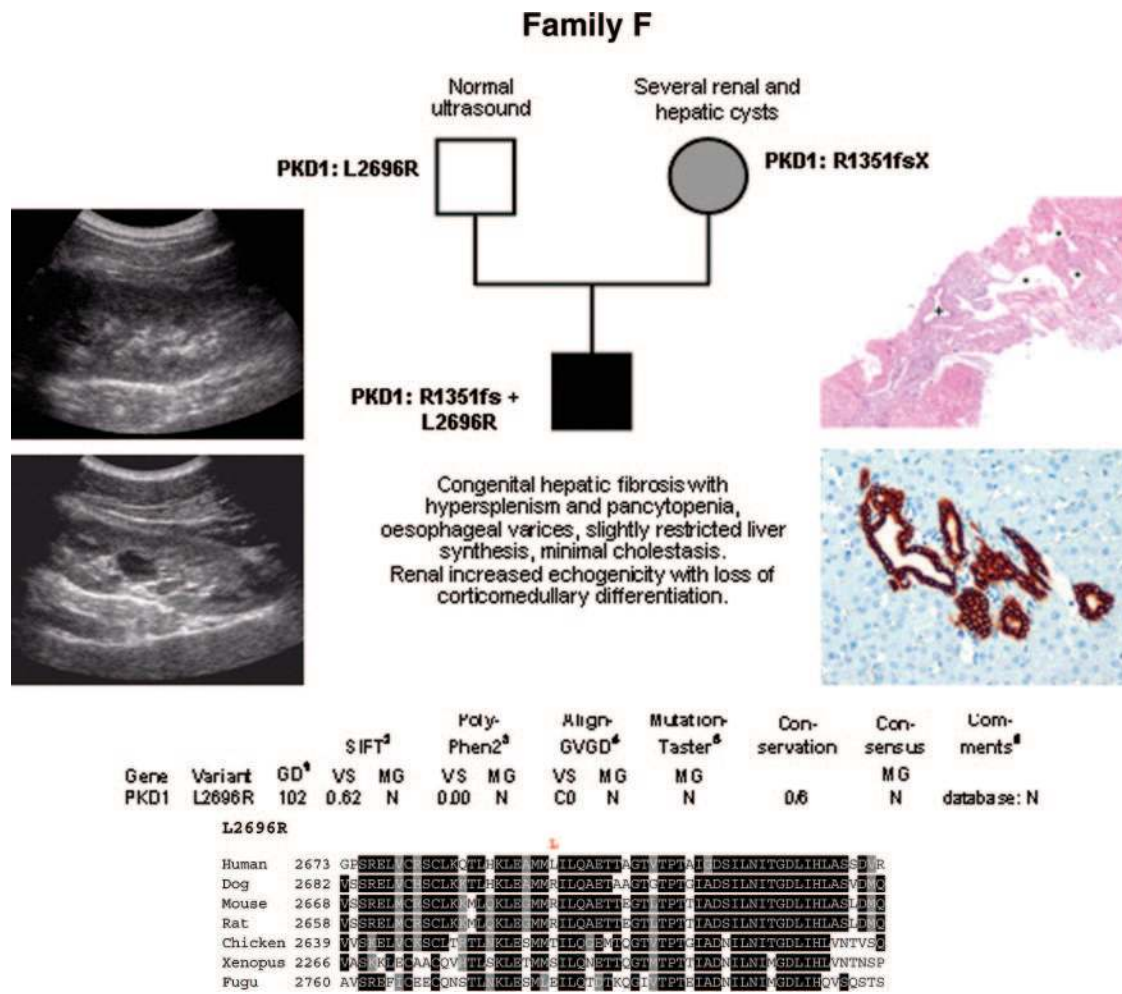
**Family G**

Patient 1 of this family (Figure 7) experienced respiratory distress and became cyanotic 1 h after birth. X-ray showed a pneumothorax on the right side and a white lung on the left side. Drainage of the pneumothorax and intubation with application of surfactant stabilized the patient. The girl’s abdomen was distended and ultrasound revealed two enlarged polycystic kidneys with increased echogenicity and a singular cyst in the liver. Serum creatinine normalized within 4 weeks. Despite multiple antihypertensive drug therapy, the girl developed cardiac insufficiency at the age of 9 months. Addition of carvedilol and occlusion of a persistent ductus arteriosus improved cardiac function. At the age of 5 years, GFR is normal and BP is under control with a quintuple combination of antihypertensive agents. While the girl’s 37-year-old father is healthy and showed normal abdominal ultrasound, the 25-year-old, clinically healthy mother displayed multiple cysts in the liver, but only a few in the kidneys. Abdominal ultrasound of the proposita’s maternal grandmother was in line with ADPKD, at the birth of her granddaughter her serum creatinine was around 2.0 mg/dl, recently she reached ESRD. During the mother’s second pregnancy, prenatal ultrasound revealed enlarged

hyperechogenic kidneys. Postnatally, the patient was respiratory stable, and serum creatinine was in normal range, whereas the BP was elevated and is currently treated by amlodipine, atenolol, and captopril. Genetically, the novel *PKD1* 1-bp deletion c.4199del (p.L1400fs) segregates with ADPKD in this family. In contrast to their mother and maternal grandmother, both girls additionally carry a second *PKD1* change (c.12413G>A, p.R4138H) on their other parental allele, which may have aggravated their clinical course.

**Family H**

Parental consanguinity and the clinical course of all three affected children were suggestive of ARPKD. However, haplotype analysis was incompatible with linkage to *PKHD1*. After



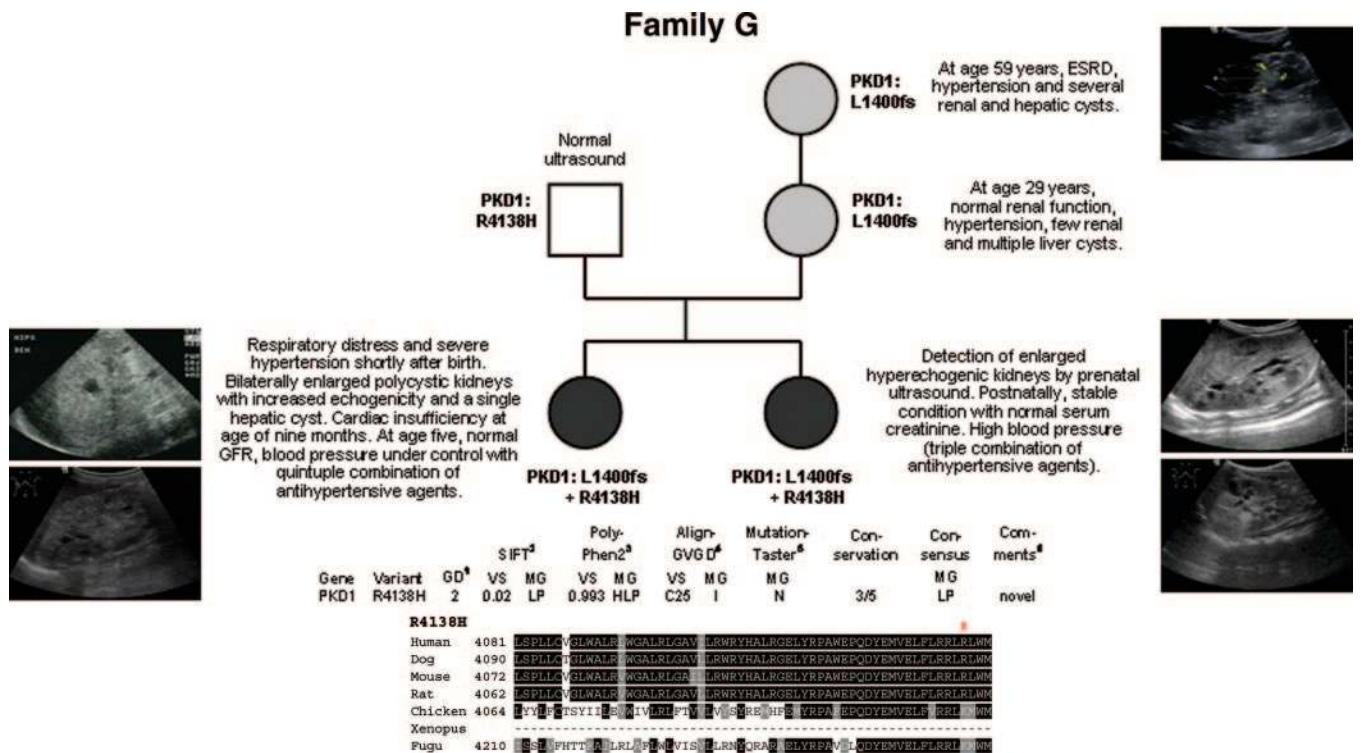
**Figure 6.** Pedigree and genotypes of family F. (Left panel) Renal ultrasound of the proband at the age of 15 years with increased echogenicity, one large cyst in the left kidney (bottom panel) and loss of corticomedullary differentiation. (Right top panel) Liver histology at the age of 9 years showing ductal plate malformation with irregularly distributed, dilated portal vein branches (asterisk), and dilated bile ducts (cross) in a fibrotic, expanded portal field (hematoxylin and eosin; original magnification,  $\times 40$ ). (Right bottom panel) Liver histology at the age of 15 years in line with ductal plate malformation and congenital hepatic fibrosis and demonstrating a portal tract with irregular, circular arrangement of widened bile ducts (brown) that extend into the hepatic lobules. Note absence of inflammation and fibrosis in this portal tract (Cytokeratin 7 immunoperoxidase staining; original magnification,  $\times 200$ ). (Bottom panel) Bioinformatic prediction scores and multiple sequence alignments obtained for the *PKD1* change L2696R.

*HNF1B* mutation analysis had been negative, we started with ADPKD diagnostics and detected the homozygous *PKD1* missense change c.3820G>A (p.V1274M) in all affected children inherited *in cis* with c.8716G>A (p.G2906S) on the maternal disease allele (Figure 8). The parents, although still young (mother, 25 years old; father, 29 years old), showed no clinical or ultrasonographic abnormalities. Also, the family history was unremarkable for kidney diseases and related disorders.

The data obtained from the latter families further strengthens the message on incomplete penetrance and a dosage effect in ADPKD.<sup>8,9</sup> Conclusively, heterozygous *PKD1* alleles like V1274M in pedigree H, R4138H in family G, or L2696R in pedigrees B and F can be expected to be insufficient to cause ADPKD on their own but are most likely able to worsen the clinical course in affected individuals with other mutations. In

family H, it is also tempting to speculate whether G2906S further impairs the functionality of the maternal disease allele.

Reconstruction of our data by animal models and/or functional assays may corroborate the message; however, these experiments are cumbersome and considerably hampered by the size and structure of *PKD1* and *PKHD1*. According to the hypothesized recessive disease model on a cellular level in ADPKD, Piontek *et al.*<sup>22</sup> recently demonstrated that the developmental age in which the second allele in *Pkd1* is inactivated is crucial for disease severity. Inactivation of *Pkd1* in mice before day 13 resulted in severely cystic kidneys, whereas later *Pkd1* inactivation resulted in significantly milder and later onset of disease. These findings are in accordance with germ-line mutations identified in our early and severely affected patients and in contrast to ADPKD patients with a “typical” adult disease



**Figure 7.** Pedigree and genotypes of family G. (Left panel) Renal ultrasound of probanda postnatally (left top panel) and at the age of 4 years (left bottom panel). (Right top panel) Renal ultrasound of maternal grandmother at the age of 59 years. (Middle and bottom right panels) Renal ultrasound of the second-born daughter postnatally (middle right panel) and at the age of 15 months (bottom right panel). (Bottom panel) Bioinformatic predictions and multiple sequence alignments for the *PKD1* variant R4138H identified on the paternal allele of both severely affected girls.

onset in which stochastically acquired somatic changes during later life are to be hypothesized.

Given these results and existing literature data, we find that there is sufficient evidence that our findings describe a general principle instead of being just a sequence of single cases. We postulate that additional PKD alleles *in trans* and/or *de novo* exert an aggravating effect and contribute to early and severe disease expression in polycystic kidney disease. Oligogenic inheritance with changes in different genes and converging pathomechanistic pathways is well known for syndromic ciliopathies like Bardet-Biedl syndrome but has not been described in a series of patients with polycystic kidney disease so far.<sup>23,24</sup> We hypothesize that a reduced dosage of PKD proteins severely disturbs homeostasis and network integrity, and by this correlates with disease severity in PKD. It is likely that stochastic and environmental factors and changes in other (especially ciliary) genes/proteins that converge in common pathways may further influence the phenotype. Improved sequencing facilities (next-generation sequencing) will provide further rapidly growing insight in this issue and the mutational-load theory.

Elucidation of molecular mechanisms that may explain some of the phenotypic variability in these families is of importance for the understanding of polycystic kidney disease. Moreover, it is to be expected that similar findings may also

apply for variable disease expression in other so-called monogenic conditions, most probably describing a general concept. These results and the aspect of early and severe disease manifestation in ADPKD deserve increased attention, *e.g.* in genetic counseling. Only few ADPKD patients and presumably also attending physicians know about early and severe disease expression and the considerably increased recurrence risk in affected families. Our findings may thus have important implications for the clinical and molecular understanding of the disease and the management of affected families.

### CONCISE METHODS

The study was approved by the relevant review board and ethics committee, and the participants gave informed consent. For haplotype analysis of *PKHD1*, we used previously described markers and techniques.<sup>25</sup> Mutation analysis involved direct sequencing of exonic and flanking intronic regions of *PKD1*, *PKD2*, *HNF1β/TCF2*, and *PKHD1*. All of the novel splice and missense mutations detected in one of the aforementioned genes were not present in 400 control chromosomes tested by DHPLC or restriction digestion analysis. The ADPKD and ARPKD mutation databases were used as a source of information about known *PKD1*, *PKD2*, and *PKHD1* variants.<sup>26,27</sup> Scoring of likely mutations was performed as





5. Ogborn MR: Polycystic kidney disease: A truly pediatric problem. *Pediatr Nephrol* 8: 762–767, 1994
6. Bergmann C, Ortiz Bröchle N, Frank V, Rehder H, Zerres K: Perinatal deaths in a family with autosomal dominant polycystic kidney disease and a PKD2 mutation. *N Engl J Med* 359: 318–319, 2008
7. Bergmann C, Ortiz Bröchle N, Frank V, von Bothmer J, Zerres K: Early and severe disease manifestation in autosomal dominant polycystic kidney disease (ADPKD) [Abstract]. *Med Gen* 21: 62, 2009
8. Rossetti S, Kubly VJ, Consugar MB, Hopp K, Roy S, Horsley SW, Chauveau D, Rees L, Barratt TM, van't Hoff WG, Niaudet P, Torres VE, Harris PC: Incompletely penetrant PKD1 alleles suggest a role for gene dosage in cyst initiation in polycystic kidney disease. *Kidney Int* 75: 848–855, 2009
9. Vujic M, Heyer CM, Ars E, Hopp K, Markoff A, Orndal C, Rudenhe B, Nasr SH, Torres VE, Torra R, Bogdanova N, Harris PC: Incompletely penetrant PKD1 alleles mimic the renal manifestations of ARPKD. *J Am Soc Nephrol* 21: 1097–1102, 2010
10. Wang S, Zhang J, Nauli SM, Li X, Starremans PG, Luo Y, Roberts KA, Zhou J: Fibrocystin/polyductin, found in the same protein complex with polycystin-2, regulates calcium responses in kidney epithelia. *Mol Cell Biol* 27: 3241–3252, 2007
11. Kim I, Fu Y, Hui K, Moeckel G, Mai W, Li C, Liang D, Zhao P, Ma J, Chen XZ, George AL Jr., Coffey RJ, Feng ZP, Wu G: Fibrocystin/polyductin modulates renal tubular formation by regulating polycystin-2 expression and function. *J Am Soc Nephrol* 19: 455–468, 2008
12. Yu S, Hackmann K, Gao J, He X, Piontek K, Garcia-González MA, Menezes LF, Xu H, Germino GG, Zuo J, Qian F: Essential role of cleavage of Polycystin-1 at G protein-coupled receptor proteolytic site for kidney tubular structure. *Proc Natl Acad Sci USA* 104: 18688–18693, 2007
13. Williams SS, Cobo-Stark P, James LR, Somlo S, Igarashi P: Kidney cysts, pancreatic cysts, and biliary disease in a mouse model of autosomal recessive polycystic kidney disease. *Pediatr Nephrol* 23: 733–741, 2008
14. Garcia-Gonzalez MA, Menezes LF, Piontek KB, Kaimori J, Huso DL, Watnick T, Onuchic LF, Guay-Woodford LM, Germino GG: Genetic interaction studies link autosomal dominant and recessive polycystic kidney disease in a common pathway. *Hum Mol Genet* 16: 1940–1950, 2007
15. Zerres K, Rudnik-Schoneborn S, Deget F: Childhood onset autosomal dominant polycystic kidney disease in sibs: Clinical picture and recurrence risk. German Working Group on Paediatric Nephrology. *J Med Genet* 30: 583–588, 1993
16. Ulinski T, Lescure S, Beaufils S, Guignon V, Decramer S, Morin D, Clauin S, Deschênes G, Bouissou F, Bensman A, Bellanné-Chantelot C: Renal phenotypes related to hepatocyte nuclear factor-1beta (TCF2) mutations in a pediatric cohort. *J Am Soc Nephrol* 17: 497–503, 2006
17. Faguer S, Bouissou F, Dumazer P, Guitard J, Bellanné-Chantelot C, Chauveau D: Massively enlarged polycystic kidneys in monozygotic twins with TCF2/HNF-1beta (hepatocyte nuclear factor-1beta) heterozygous whole-gene deletion. *Am J Kidney Dis* 50: 1023, 2007
18. Decramer S, Parant O, Beaufils S, Clauin S, Guillou C, Kessler S, Aziza J, Bandin F, Schanstra JP, Bellanné-Chantelot C: Anomalies of the TCF2 gene are the main cause of fetal bilateral hyperechogenic kidneys. *J Am Soc Nephrol* 18: 923–933, 2007
19. Gresh L, Fischer E, Reimann A, Tanguy M, Garbay S, Shao X, Hiesberger T, Fiette L, Igarashi P, Yaniv M, Pontoglio M: A transcriptional network in polycystic kidney disease. *EMBO J* 23: 1657–1668, 2004
20. Hiesberger T, Bai Y, Shao X, McNally BT, Sinclair AM, Tian X, Somlo S, Igarashi P: Mutation of hepatocyte nuclear factor-1 $\beta$  inhibits *Pkhd1* gene expression and produces renal cysts in mice. *J Clin Invest* 113: 814–825, 2004
21. Bellanné-Chantelot C, Clauin S, Chauveau D, Collin P, Daumont M, Douillard C, Dubois-Laforgue D, Dusselier L, Gautier JF, Jadoul M, Laloi-Michelin M, Jacquesson L, Larger E, Louis J, Nicolino M, Subra JF, Wilhelm JM, Young J, Velho G, Timsit J: Large genomic rearrangements in the hepatocyte nuclear factor-1beta (TCF2) gene are the most frequent cause of maturity-onset diabetes of the young type 5. *Diabetes* 54: 3126–3132, 2005
22. Piontek K, Menezes LF, Garcia-Gonzalez MA, Huso DL, Germino GG: A critical developmental switch defines the kinetics of kidney cyst formation after loss of *Pkd1*. *Nat Med* 13: 1490–1495, 2007
23. Fliegauf M, Benzing T, Omran H: When cilia go bad: Cilia defects and ciliopathies. *Nat Rev Mol Cell Biol* 8: 880–893, 2007
24. Zaghoul NA, Katsanis N: Functional modules, mutational load and human genetic disease. *Trends Genet* 26: 168–176, 2010
25. Bergmann C, Senderek J, Sedlacek B, Pegiazoglou I, Puglia P, Eggemann T, Rudnik-Schöneborn S, Furu L, Onuchic LF, De Baca M, Germino GG, Guay-Woodford L, Somlo S, Moser M, Büttner R, Zerres K: Spectrum of mutations in the gene for autosomal recessive polycystic kidney disease (ARPKD/PKHD1). *J Am Soc Nephrol* 14: 76–89, 2003
26. Harris PC, Rossetti S: Molecular diagnostics for autosomal dominant polycystic kidney disease. *Nat Rev Nephrol* 6: 197–206, 2010
27. Bergmann C, Küpper F, Dornia C, Schneider F, Senderek J, Zerres K: Algorithm for efficient PKHD1 mutation screening in autosomal recessive polycystic kidney disease (ARPKD). *Hum Mutat* 25: 225–231, 2005
28. Dowdle WE, Robinson JF, Kneist A, Zerres K, Frints SGM, van Lijnschoten G, Mulders L, Verver DE, Salomé S, Sirerol-Piquer M, García-Verdugo JM, Corbit KC, Katsanis N, Bergmann C, Reiter JF: Disruption of a ciliary B9 protein complex causes Meckel Syndrome. *Am J Hum Genet* 89: 94–110, 2011

Supplemental information for this article is available online at <http://www.jasn.org/>