

# Mutations of the *IN11* Rhabdoid Tumor Suppressor Gene in Medulloblastomas and Primitive Neuroectodermal Tumors of the Central Nervous System<sup>1</sup>

Jaclyn A. Biegel,<sup>2</sup> Benjamin Fogelgren, Jun-Ying Zhou, C. David James, Anna J. Janss, Jeffrey C. Allen, David Zagzag, Corey Raffel, and Lucy B. Rorke

Divisions of Human Genetics and Molecular Biology [J. A. B., B. F., J.-Y. Z.] and Oncology [A. J. J.], and Department of Pathology [L. B. R.], The Children's Hospital of Philadelphia and Department of Pediatrics, University of Pennsylvania School of Medicine [J. A. B., A. J. J.], Philadelphia, Pennsylvania 19104; Departments of Experimental Pathology [C. D. J.] and Neurosurgery [C. R.] Mayo Clinic, Rochester, Minnesota 55905; Department of Neurology, Beth Israel Medical Center, North Division, New York, New York 10128 [J. C. A.]; and Department of Pathology, Kaplan Cancer Center, New York, New York 10016 [D. Z.]

## ABSTRACT

**Germ-line and somatic mutations of the *hSNF5/IN11* gene have been reported in atypical teratoid/rhabdoid tumors (AT/RTs) of the brain, consistent with its role as a tumor suppressor gene. In the present study, we determined the frequency of deletions and mutations of *IN11* in 52 children whose original diagnosis was medulloblastoma (MB) or primitive neuroectodermal tumor (PNET) of the central nervous system. Mutations were detected in DNA isolated from four tumors, all from children less than 3 years of age at diagnosis. Two of the four were reviewed and reclassified as atypical teratoid tumor, whereas there was insufficient material to establish this diagnosis in the two remaining cases. The relatively low frequency of mutations, even in a large series of infants, suggests that loss of sequences from chromosome 22 and/or mutations of *IN11* do not account for the poor prognosis of children with MB or PNET who are less than 3 years of age at diagnosis. Nevertheless, chromosome 22 deletion and *IN11*-mutation analysis of infants with MB/PNET should be considered for all children who are less than 1 year of age. Detection of these mutations suggests that the child has an AT/RT, rather than a MB/PNET, a finding with important prognostic value.**

Received 2/4/00; revised 4/3/00; accepted 4/10/00.

The costs of publication of this article were defrayed in part by the payment of page charges. This article must therefore be hereby marked *advertisement* in accordance with 18 U.S.C. Section 1734 solely to indicate this fact.

<sup>1</sup> This work was supported by NIH Grant CA 46274 and Grant NS34514 (to J. A. B.) and was facilitated in part by the Children's Cancer Group, which is supported by National Cancer Institute Grant 5U10 CA13539.

<sup>2</sup> To whom requests for reprints should be addressed, at The Children's Hospital of Philadelphia, Room 1002, Abramson Research Building, 3516 Civic Center Boulevard, Philadelphia, PA 19104. Phone: (215) 590-3856; Fax: (215) 590-3764; E-mail: biege1@mail.med.upenn.edu.

## INTRODUCTION

MB<sup>3</sup> and supratentorial PNET are the most common malignant brain tumors of childhood, affecting approximately 1 in 200,000 children per year (1). The incidence of MB peaks between 3 and 4 years, and again between 8 and 9 years, although newborns and young adults may present with such tumors (1, 2). Similarly, most patients with supratentorial PNET are diagnosed between birth and 10 years of age. Prognostic factors have been identified from both single-institution and large collaborative-group trials. Total surgical resection of tumor, infratentorial location, lack of metastatic disease, age greater than 3 years, and high TrkC expression are each associated with an improved prognosis, especially in children treated with combined radiation and chemotherapy (2–5). The biological basis for the poor prognosis seen in children with MB/PNET who are less than 36 months of age has not yet been elucidated (2, 3).

AT/RTs of the brain are clinically aggressive malignancies that have overlapping clinical, histological, and radiographic features with MB/PNET (6). AT/RT of the brain is almost exclusively a tumor of infants, with the majority of patients being diagnosed in the first 2 years of life. In the past, the majority of AT/RTs have been misclassified as MB/PNETs because two-thirds of AT/RTs contain fields of primitive neuroepithelial cells characteristic of MB/PNET (6, 7). Cytogenetic and molecular studies are a useful adjunct in the differential diagnosis of children with malignant brain tumors. An isochromosome 17q is present in approximately 30–40% of MBs and has not, to date, been observed in AT/RT (8–10). Conversely, although monosomy or deletion of chromosome 22 is seen in the majority of rhabdoid tumors in all anatomical sites, the nonrandom association of monosomy 22 with MB/PNET is still a subject of debate (8).

Identification of *hSNF5/IN11* as a candidate tumor suppressor gene on chromosome 22 for malignant rhabdoid tumors was recently reported (11). The *hSNF5/IN11* (12, 13) gene is a component of the mammalian SWI/SNF complex, which functions in an ATP-dependent manner to remodel chromatin, thus allowing transcription factor binding to DNA (14). We demonstrated germ-line and somatic mutations of *IN11* in CNS AT/RTs as well as in rhabdoid tumors in the kidney and soft tissue (15). We, therefore, hypothesized that the deletion or mutation of *IN11*, which is associated with an aggressive and usually fatal clinical course in children with AT/RT, could also account for the poor prognosis observed in some infants with classified

<sup>3</sup> The abbreviations used are: MB, medulloblastoma; PNET, primitive neuroectodermal tumor; AT/RT, atypical teratoid/rhabdoid tumor; CNS, central nervous system; FISH, fluorescence *in situ* hybridization.

MB/PNET. At the same time, the specificity of *INI1* mutations for rhabdoid tumors in the CNS could be determined.

In the present study, we evaluated MB/PNET biopsy samples from 52 children by FISH and molecular genetic techniques to detect deletions and to determine loss of heterozygosity in chromosome 22. Tumors were then analyzed for intragenic deletions and mutations in the *INI1* gene by a combination of heteroduplex and direct sequence analysis.

## MATERIALS AND METHODS

Biopsy specimens were obtained after informed consent from children having surgery at The Children's Hospital of Philadelphia (17 cases), the Mayo Clinic (24 cases), or other outside institutions (11 cases) participating in approved Children's Cancer Group biology studies under the direction of one of the authors (J. A. B.). Patients were diagnosed between 1988 and 1998 and were treated according to institutional protocols open during this time period.

Karyotypes were prepared from 10 primary tumors and have previously been published (9). Cytogenetic pellets or touch preparations from frozen tumor tissue were analyzed by interphase FISH (10 cases) using cosmid probes for *INI1* in 22q11.2 and EWS in 22q12 (15). DNA isolated from fresh or frozen tissue was analyzed by PCR-based microsatellite analysis (49 of 52 cases) for loss of heterozygosity using probes that map to 22q according to previously reported methods (15, 16).

The 28 tumors analyzed at The Children's Hospital of Philadelphia were screened by PCR and heteroduplex analysis of each of the 9 coding exons of the *INI1* gene, as described previously (15). Exons with bandshifts suggestive of a mutation were then sequenced to identify the base alteration. For the 24 Mayo Clinic cases, the 9 exons and corresponding exon/intron boundaries were directly sequenced if there was evidence of loss of heterozygosity for markers on chromosome 22 (5 tumors) or if loss of heterozygosity could not be determined (1 tumor; Ref. 11, 16).

## RESULTS

**Clinical Findings.** The 52 patients had an original diagnosis of MB, PNET, or supratentorial PNET. Areas of rhabdoid cells that were suggestive of AT/RT were noted in 1 of the 52 cases.

The patients ranged in age between 4 days and 20 years, with a median age at diagnosis of 4 years. Twenty-three (44%) of the 52 children were  $\leq 3$  years of age at diagnosis. The Children's Hospital of Philadelphia patients were selected from a larger cohort based on age and available DNA samples, and, therefore, the high percentage of young children in this study does not reflect the natural age-specific incidence of MB/PNET.

Two children (4 days and 1 year of age) received no further therapy after surgery and died within a year of diagnosis. Two patients (6 and 7 years of age) were treated with surgery and radiation therapy and are alive 9 and 12 years from diagnosis. The other 48 patients were treated with combined chemotherapy according to one of six different protocols. Forty of the 48 patients also received radiation treatment. Ten (43%) of 23 patients  $\leq 3$  years of age have died, and 10 (34%) of 29 patients  $> 3$  years of age at diagnosis have died. A multivariate statistical

Table 1 Deletion analysis of MB/PNET patients

	Age $\leq 3$ yr	Age $> 3$ yr
No. of patients	23	29
Deletion of 22q11	8	8
Mutation of <i>INI1</i>	4	0

analysis to assess correlations between age at diagnosis and outcome with respect to mutation or deletion status could not be performed because of the variability in treatment protocols.

**Deletion and *INI1* Mutation Analysis.** As shown in Table 1, a total of 16 (30%) of 52 cases demonstrated monosomy 22, deletion of 22q11.2, or loss of heterozygosity for markers that map to 22q11-q12. None of the tumors were homozygously deleted for the *INI1* region in chromosome 22q11.2. Eight (35%) of the 23 patients who were  $\leq 3$  years of age at diagnosis had loss of chromosome 22, whereas 8 (28%) of 29 patients  $> 3$  years of age demonstrated loss of chromosome 22 in their tumors.

As shown in Table 2, mutations of *INI1* were identified in 4 of the 16 tumors with loss of chromosome 22. All 4 of the mutations were found in children less than 3 years of age. Eighteen tumors without loss of chromosome 22 (11 cases  $< 3$  years of age; 7 cases  $> 3$  years of age) were also screened for alterations in the *INI1* gene, but no additional mutations were identified.

The first child was 6 months of age at the time of diagnosis. As previously reported (15), the only cytogenetic abnormality identified in the tumor karyotype was monosomy 22, which was subsequently confirmed by interphase FISH. An alteration of the first exon/intron of *INI1* was identified by PCR amplification using primers that amplify the first exon and the 5' and exon1/intron 1 boundaries. Limited material for histology review was available, and a diagnosis of MB was confirmed in the absence of immunohistochemical studies. The child relapsed and died within one year of diagnosis.

The second case was a pineoblastoma (PNET of the pineal gland) diagnosed in a 7-month-old infant. Karyotypes demonstrated monosomy 22 as the only abnormality. A missense mutation in exon 2 in *INI1* was identified in the remaining allele. A C $\rightarrow$ T bp change that introduces a novel stop codon (codon 40) in place of an arginine is predicted to result in premature truncation of the protein. Normal tissue was not available, and thus a germ-line mutation could not be ruled out. The histology and immunophenotyping was reviewed; however, based on the limited material available, there was no evidence to support a change in diagnosis to AT/RT. This child also died because of disease progression.

An identical single bp deletion of one of four cytosines in codons 382 or 383 (exon 9) was detected in cases 3 and 4. The sequence profile from one of the tumors is shown in Fig. 1. This mutation is predicted to result in the addition of an extra 100 amino acids to the end of the INI1 protein (Fig. 2). Normal tissue was not available in either case to determine whether the mutation was constitutional.

One of the children with an exon 9 mutation was 2 years 7 months at the time of diagnosis. On the basis of a deletion of 22q11.2 detected by FISH, the histology of this case was re-

Table 2 Chromosome 22 deletions and *INI1* mutations in four children with MB/PNET

Case	Age	Deletion	Mutation	Effect	Final diagnosis	Outcome
1	6 mo	Monosomy 22	Alteration in exon/intron 1	No expression	MB	DOD <sup>a</sup>
2	7 mo	Monosomy 22	C118T	ARG→STOP	Pineoblastoma	DOD
3	2 yr 7 mo	22q11.2 deletion	delC	Frameshift	AT/RT	DOT
4	8 mo	LOH for 22	delC	Frameshift	AT/RT	Alive

<sup>a</sup> DOD, died of disease; DOT, died of toxicity; LOH, loss of heterozygosity.

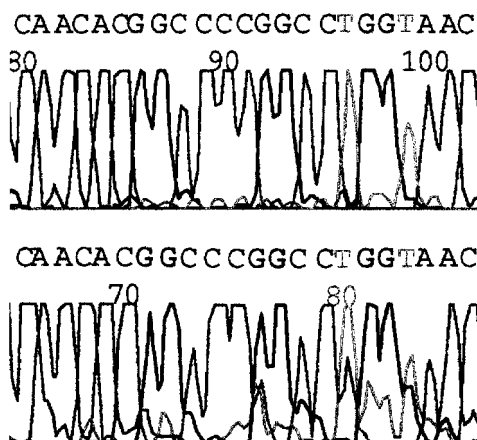


Fig. 1 Sequence profile for the deletion observed in cases 3 and 4. The normal sequence (top) contains four cytosines, whereas the mutant sequence (bottom) contains only three cytosines.

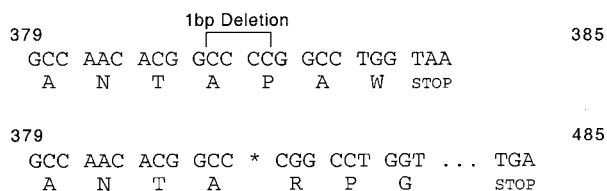


Fig. 2 Schematic representation of the frameshift mutation shown in Fig. 1. Deletion of one cytosine causes a change in the reading frame, eliminating the normal stop codon at position 385. A novel stop codon is created 300 bp downstream and is predicted to add 100 amino acids to the protein.

viewed. After exhaustive analysis of the biopsy material, a small region of rhabdoid cells was observed, and the diagnosis was changed to AT/RT. The child died of fungal sepsis 6 months after the initiation of chemotherapy (Children's Cancer Group Protocol 99703).

The other patient with the exon 9 mutation was diagnosed at 8 months of age with a brain stem tumor. The original diagnosis was PNET, although small areas with rhabdoid cells were noted in the histological sections from the surgical sample. Microsatellite analysis of DNA isolated from the formalin-fixed and paraffin-embedded tumor tissue demonstrated loss of alleles at three markers from 22q11.2, consistent with loss of heterozygosity. The loss of chromosome 22 and subsequent identification of the exon 9 mutation in a tumor with rhabdoid cells is

consistent with a diagnosis of AT/RT. The child had been treated on a Children's Cancer Group therapeutic study (CCG-9921) with combined induction chemotherapy consisting of ifosfamide, vincristine, etoposide, and carboplatin, followed by maintenance chemotherapy and delayed radiation therapy at 36 months of age. At last follow-up, she was 6 years of age and showed no evidence of disease.

## DISCUSSION

The aim of the present study was to determine the frequency of *INI1* deletions and mutations in MBs and supratentorial PNETs. In particular, we sought to determine whether the poor prognosis associated with age less than 3 years in patients with MB/PNET could be attributable to alterations of the *INI1* rhabdoid tumor suppressor gene.

Cytogenetic and/or molecular genetic deletions of chromosome 22 were identified in 16 of 52 tumors. Coding sequence mutations in *INI1* were identified in 4 of these 16 tumors. Eighteen additional tumors were screened by heteroduplex analysis and/or direct sequencing, but there were no apparent mutations. The remaining 17 tumors without loss of heterozygosity for markers on chromosome 22 were not screened for an *INI1* mutation. Bi-allelic *INI1* mutations could have been missed in these cases. This possibility is reduced by the fact that, to date, we have only identified one rhabdoid tumor with mutations in both alleles and no loss of chromosome 22 (Ref. 15 and unpublished data).<sup>4</sup>

In two of the four patients (cases 3 and 4 in Table 2), the finding of an *INI1* mutation provided evidence for a change in diagnosis from MB to AT/RT. Because of insufficient tissue for the first two cases, additional studies that may have been used to confirm a diagnosis of AT/RT could not be performed. Because at least two-thirds of AT/RTs contain areas of tumor that resemble PNET (6), it is not possible to exclude a diagnosis of AT/RT based on the histological identification of such tissue in the biopsy specimen. Expression of epithelial membrane antigen, often used to make a diagnosis of AT/RT in this setting, could not be tested in the first case and was negative in the second case. However, this might also be expected if only a small sample of the tumor were available. Given that both children were less than 1 year of age at the time of diagnosis, the possibility of AT/RT must be considered.

The mutations identified in the present report are consistent with what others and we have previously published for *hSNF5*/<sup>4</sup>

<sup>4</sup> J. A. Biegel, unpublished data.



*INI1* (11, 15, 17, 18). In fact, an identical exon 9 deletion was noted in two other sporadic CNS AT/RTs in our previous series of tumors (15). Recently, Sevenet *et al.* (17, 18) screened a series of brain tumors for deletions or mutations of *hSNF5/INI1*, including 53 MB/PNETs. Two of 17 PNETs and 5 of 36 MBs had mutations in *INI1*. Interestingly, mutations were also detected in four of six choroid plexus carcinomas. These authors suggest that a variety of CNS tumors, including MB, "central" PNET, and choroid plexus carcinoma share a common molecular genetic pathway in tumor development based on the finding of *INI1* deletions and mutations in each of these tumor types. Historically, most AT/RTs have been misclassified as MBs, ependymomas, germ cell tumors, choroid plexus carcinomas, or supratentorial PNETs (6, 7). We recently reported a patient with a constitutional mutation of exon 7 who developed a CNS tumor and, 6 months later, presented with a renal rhabdoid tumor (19). Although the original diagnosis of the brain tumor was choroid plexus carcinoma, it was reclassified as an AT/RT by histology and immunophenotyping before the identification of an *INI1* mutation. Sevenet *et al.* (17) did not indicate whether the histology of their cases with *INI1* mutations was reviewed. This might rule out the possibility that tumors with *INI1* mutations identified as MB, PNET, or choroid plexus carcinoma were actually AT/RT. Regardless of the histology, however, the finding of a homozygous deletion or mutation in *INI1* suggests that these tumors be considered the same disease.

Sevenet *et al.* (17) also noted that the tumors with *INI1* mutations seemed to be clustered among the younger patients. Mutations were identified in 4 of 9 MB/PNET patients who were less than 36 months of age, compared with only 3 of 44 patients who were older than 36 months at diagnosis. In the present study, we selected additional tumors from children less than 3 years of age from our larger cohort of brain tumor patients to increase the likelihood of detecting mutations. Overall, the frequency of *INI1* mutations in this series of MB/PNET patients was quite low. Not surprisingly, all of the mutations we found were in tumors from young children. In fact, three of the four children were less than 1 year of age at diagnosis. Statistical analysis of the survival data were not feasible in this study because the patients were collected over a ten-year time period, and they were treated with one of six different protocols. However, it is notable that one of the children with a mutation in exon 9 mutation was still alive six years from the date of diagnosis. Clinical correlative studies designed to compare *INI1* deletion and mutation status and outcome will clearly be of interest.

Our findings also suggest that the poor prognosis associated with young age at diagnosis for children with MB/PNET is not likely to be associated with a deletion of chromosome 22q11 or mutation of the *INI1* gene. As shown in Table 1, there was a higher frequency of chromosome 22 deletions in the younger age group (35% in children less than 3 years *versus* 28% in children greater than 3 years). However, if we exclude the two patients with *INI1* mutations for whom the diagnosis was changed to AT/RT, then 6 (29%) of 21 children  $\leq 3$  years at diagnosis had loss of chromosome 22, which is similar to what was seen in the older children. The finding that approximately one-fourth (14 of 52, or 27%) of MB/PNETs may have loss of heterozygosity for markers that map to 22q suggests the pres-

ence of another tumor suppressor gene that maps to this chromosome. Future studies will be designed to explore this possibility as novel candidate genes from chromosome 22 are identified. At present, because of the clinically aggressive nature of AT/RT, we suggest that newly diagnosed infants with malignant CNS tumors be screened for loss of chromosome 22 and mutation of the *INI1* gene. This will become critical as tumor-specific treatment protocols for AT/RT and MB/PNET are developed.

## ACKNOWLEDGMENTS

We gratefully acknowledge the technical assistance of Luanne Wainwright, Melissa Audette, and Cindy Stenstrom. We thank the following for submitting specimens or providing clinical information: Drs. Leslie Sutton, Anne-Christine Duhaime, Peter Sun, Naryan Shah, Amy Lowichik, Marc Rosenblum, J. Russell Geyer, James Boyett, Ana Rubio, Craig Childs, Renuka Gera, and Kathy Bonner.

## REFERENCES

- Gurney, J. G., Severson, R. K., Davis, S., and Robison, L. L. Incidence of cancer in children in the United States. Sex-, race-, and 1-year age specific rates by histologic type. *Cancer (Phila.)*, 75: 2186–2195, 1995.
- Packer, R. J., Cogen, P., Vezina, G., and Rorke, L. B. Medulloblastoma. Clinical and biologic aspects. *Neuro-Oncology*, 1: 232–250, 1999.
- Zeltzer, P. M., Boyett, J. M., Finlay, J. L., Albright, A. L., Rorke, L. B., Milstein, J. M., Allen, J. C., Stevens, K. R., Stanley, P., Li, H., Wisoff, J. H., Geyer, J. R., McGuire-Cullen, P., Stehbens, J. A., Shurin, S. B., and Packer, R. J. Metastasis stage, adjuvant treatment, and residual tumor are prognostic factors for medulloblastoma in children: conclusions from the Children's Cancer group 921 randomized Phase III study. *J. Clin. Oncol.*, 17: 832–845, 1999.
- Segal R. A., Goumnerova L. C., Kwon Y. K., Stiles, C. D., and Pomeroy, S. L. Expression of the neurotrophin receptor *trkC* linked to a favorable outcome in medulloblastoma. *Proc. Natl. Acad. Sci. USA*, 91: 12867–12871, 1994.
- Grotzer, M. A., Janss, A. J., Fung, K.-M., Biegel, J. A., Sutton, L. M., Rorke, L. B., Zhao, H., Cnaan, A., Phillips, P. C., Lee, V. M.-L., Trojanowski, J. Q. TrkC expression predicts good clinical outcome in primitive neuroectodermal brain tumors. *J. Clin. Oncol.*, 18: 1027–1035, 2000.
- Rorke, L. B., Packer, R. J., and Biegel, J. A. Central nervous system atypical teratoid/rhabdoid tumors of infancy and childhood: definition of an entity. *J. Neurosurg.*, 85: 56–65, 1996.
- Burger, P. C., Yu, I.-T., Tihan, T., Friedman, H. S., Strother, D. R., Kepner, J. L., Duffner, P. K., Kun, L. E., and Perlman, E. J. Atypical teratoid/rhabdoid tumor of the central nervous system: a highly malignant tumor of infancy and childhood frequently mistaken for medulloblastoma. *Am. J. Surg. Pathol.*, 22: 1083–1092, 1998.
- Biegel, J. A. Cytogenetics and molecular genetics of childhood brain tumors. *Neuro-Oncology*, 1: 139–151, 1999.
- Biegel, J. A., Rorke, L. B., Packer, R. J., Sutton, L. N., Schut, Bonner, K., and Emanuel, B. S. Isochromosome 17q in primitive neuroectodermal tumors of the central nervous system. *Genes Chromosomes Cancer*, 1: 139–147, 1989.
- Biegel, J. A., Rorke, L. B., Packer, R. J., and Emanuel, B. S. Monosomy 22 in rhabdoid or atypical teratoid tumors of the brain. *J. Neurosurg.*, 73: 710–714, 1990.
- Versteeg, I., Sevenet, N., Lange, J., Rousseau-Merck, M.-F., Ambros, P., Handgretinger, R., Aurias, A., Delattre, O. Truncating mutations of *hSNF5/INI1* in aggressive paediatric cancer. *Nature (Lond.)*, 394: 203–207, 1998.

12. Kalpana, G. V., Marmon, S., Wang, W., Crabtree, G. R., Goff, S. P. Binding and stimulation of HIV-1 integrase by a human homolog of yeast transcription factor SNF5. *Science (Washington DC)*, 266: 2002–2006, 1994.
13. Muchardt, C., Sardet, C., Bourachot, B., Onufryk, C., and Yaniv, M. A human protein with homology to *Saccharomyces cerevisiae* SNF5 interacts with the potential helicase hbrm. *Nucleic Acids Res.*, 23: 1127–1132, 1995.
14. Muchardt, C., and Yaniv, M. The mammalian SWI/SNF complex and the control of cell growth. *Semin. Cell Dev. Biol.*, 10: 189–195, 1999.
15. Biegel, J. A., Zhou, J-Y, Rorke, L. B, Stenstrom, C., Wainwright, L. M, and Fogelgren, B. Germ-line and acquired mutations of *INI1* in atypical teratoid and rhabdoid tumors. *Cancer Res.*, 59: 74–79, 1999.
16. Raffel, C., Jenkins, R. B., Frederick, L., Hebrink, D., Alderete, B., Fults, D. W., and James, C. D. Sporadic medulloblastomas contain PTC mutations. *Cancer Res.*, 57: 842–845, 1997.
17. Sevenet, N. Lellouch-Tubiana, A., Schofield, D., Xoang-Xuan, K., Gessler, M., Birnbaum, D., Jeanpierre, C., Jouviet, A., and Delattre, O. Spectrum of hSNF5/*INI1* somatic mutations in human cancer and genotype-phenotype correlations. *Hum. Mol. Genet.*, 8: 2359–2368, 1999.
18. Sevenet, N., Sheridan, E., Amram, D., Schneider, P., Handgretinger, R., and Delattre, O. Constitutional mutations of the *hSNF5/INI1* gene predispose to a variety of cancers. *Am. J. Hum. Genet.*, 65: 1342–1348, 1999.
19. Biegel, J. A., Fogelgren, B., Wainwright, L. M., Zhou, J-Y., Bevan, H., and Rorke, L. B. Germline *INI1* mutation in a patient with a central nervous system atypical teratoid tumor and a renal rhabdoid tumor. *Genes Chromosomes Cancer*, 28: 31–37, 2000.