

**CASE REPORT**

# Myxedema coma accompanied by sick sinus syndrome and hypoventilation: A case report

Ko Harada MD<sup>1</sup> | Shuntaro Murakami Medical student<sup>1</sup> | Kazuki Tokumasu MD<sup>1</sup> | Yu Togawa MD<sup>2</sup> | Fumio Otsuka MD, PhD<sup>1</sup>

<sup>1</sup>Department of General Medicine, Okayama University Graduate School of Medicine, Dentistry and Pharmaceutical Sciences, Kitaku, Japan

<sup>2</sup>Department of Internal Medicine, Kaneda Hospital, Maniwa, Japan

**Correspondence**

Ko Harada, MD, Department of General Medicine, Okayama University Graduate School of Medicine, Dentistry and Pharmaceutical Sciences, 2-5-1 Shikata-cho, Kita-ku, Okayama 700-8558, Japan.  
Email: me422084@s.okayama-u.ac.jp

**Abstract**

Myxedema coma is an emergency presentation of hypothyroidism, and cardiopulmonary manifestations of the disease are related to a high mortality rate. We herein report a case of myxedema coma accompanied by sick sinus syndrome requiring temporary cardiac pacing and hypercapnic respiratory failure in an 87-year-old woman. This case is unique because both of the cardiac and pulmonary manifestations were reversible and successfully treated with thyroid hormone replacement. Our case indicates that early detection of the condition and administration of levothyroxine are essential to improve the life-threatening condition and avoid invasive treatment such as permanent pacemaker implantation or intubation.

**KEYWORDS**

hypercapnic respiratory failure, myxedema coma, sick sinus syndrome

## 1 | INTRODUCTION

Myxedema coma is an emergency presentation of hypothyroidism, leading to altered mental status, hypothermia, and cardiopulmonary dysfunction related to slowing of function in multiple organs. Myxedema coma is rare with an incidence rate of only 0.22 per 1 million people per year, and it occurs almost exclusively in persons 60 years of age or older with a female predominance (80%).<sup>1</sup> The mortality rate of the disease was reported to be as high as 25%-52%.<sup>2</sup> Among symptoms associated with myxedema coma, cardiovascular and pulmonary manifestations tend to be severe and related to a high mortality rate.<sup>3,4</sup> We herein report a rare case of myxedema coma accompanied by sick sinus syndrome (SSS) as a cardiovascular manifestation and hypercapnic respiratory failure as a pulmonary manifestation, both of which were reversible and successfully treated with levothyroxine.

## 2 | CASE PRESENTATION

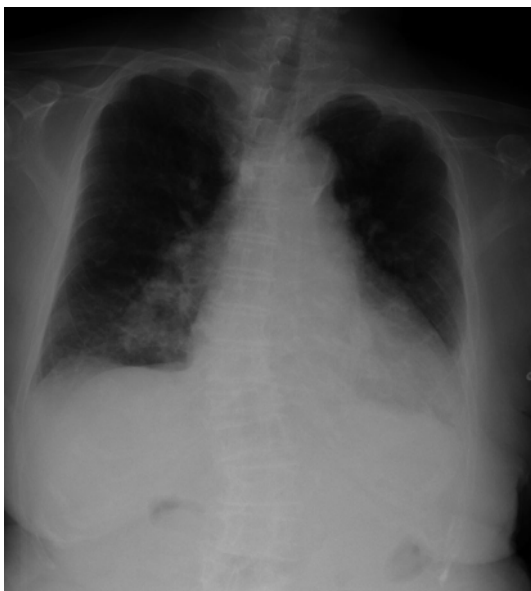An 87-year-old Japanese woman with a history of hypertension and dyslipidemia was referred to our hospital because of bradycardia and respiratory failure. Fourteen days prior to admission to our hospital, the patient developed dyspnea and altered mental status, and she was admitted to the previous hospital. On physical examination, her height, body weight, and BMI were 146.5 cm, 41.7 kg, and 19.4 kg/m<sup>2</sup>, respectively. Oxygen saturation was 72% on room air, respiratory rate was 12 breaths per minute, body temperature was 36.9°C, and Glasgow Coma Scale score was 12 (E3V4M5). Arterial blood gas showed pH 7.308, pCO<sub>2</sub> of 92.2 mm Hg, and bicarbonate of 45.2 mmol/L. Laboratory findings revealed severe hypothyroidism with a thyroid-stimulating hormone (TSH) level of 40.56 μIU/mL (normal range: 0.54-4.26), free T<sub>4</sub> (FT<sub>4</sub>) of 0.11 ng/dL (normal range: 0.71-1.52), and free T<sub>3</sub> of 0.60 pg/mL (normal range: 2.30-4.00).

This is an open access article under the terms of the Creative Commons Attribution-NonCommercial License, which permits use, distribution and reproduction in any medium, provided the original work is properly cited and is not used for commercial purposes.

© 2019 The Authors. *Journal of General and Family Medicine* published by John Wiley & Sons Australia, Ltd on behalf of Japan Primary Care Association.

Antithyroid peroxidase antibody and antithyroglobulin antibody were negative, and thyroglobulin was 134 ng/mL (normal range: 0-33.0). Adrenal insufficiency was ruled out as the serum cortisol level in the morning was 23.0 µg/dL. Electrocardiography (ECG) showed sinus bradycardia with first-degree atrioventricular (AV) block with a heart rate (HR) of 53 beats/min (bpm). A chest X-ray showed enlargement of the cardiac silhouette and bilateral costophrenic angle blunting (Figure 1). Echocardiography showed a left ventricular ejection fraction of 65% without pericardial effusion. After being admitted to the previous hospital, she had bradycardia, with a HR between 36 and 40 bpm, which lasted for several hours. Her clinical features along with laboratory findings strongly suggested myxedema coma accompanied by SSS and hypercapnic respiratory failure.

Her clinical course is shown in Figure 2. Treatment with oral levothyroxine of 150 µg per day was initiated via a nasogastric tube, and a transvenous temporary pacemaker was inserted via the right femoral vein with a ventricular rate of 60 bpm. Noninvasive positive pressure ventilation (NPPV) was administered because of her respiratory failure. On day 9, the patient developed fever and chills, and two sets (from 4 bottles) of blood cultures tested positive for methicillin-resistant *Staphylococcus epidermidis* (MRSE). Transthoracic echocardiography showed no vegetation in heart valves. Based on the diagnosis of MRSE bacteremia without any involvement of other sites, intravenous administration of vancomycin was initiated and discontinued 2 weeks after confirmation of negative blood culture. The patient was referred to our hospital for further evaluation and treatment. On admission to our hospital, both TSH and free T4 were normalized. Since her hypercapnic respiratory failure had been improved, NPPV was discontinued. Because her HR was stable around 50 bpm without cardiac pacing, temporary pacemaker was also discontinued. Her cardiomegaly on chest X-ray improved with hormone



**FIGURE 1** A chest X-ray showed enlargement of the cardiac silhouette and bilateral costophrenic angle blunting

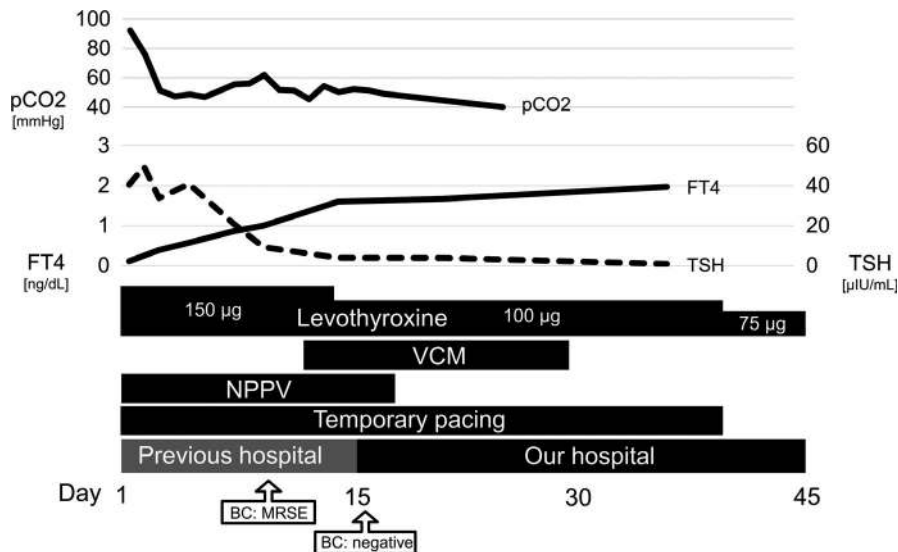
replacement therapy. After removing temporary pacemaker, the patient did not show any symptoms associated with bradycardia such as loss of consciousness or heart failure. On day 45, she was transferred to the previous hospital for rehabilitation.

### 3 | DISCUSSION

We report a case of severe hypothyroidism in an elderly woman that caused SSS requiring temporary cardiac pacing and hypercapnic respiratory failure that was treated with NPPV. Our case fulfills the diagnostic criteria for myxedema coma (3rd draft) provided by the Japan Thyroid Association, with hypothyroidism, altered mental status, hypoventilation, and cardiac dysfunction.<sup>5</sup> This case is also unique with respect to the clinical course, in which those cardiopulmonary dysfunctions were reversible to some extent with thyroid hormone replacement therapy.

Cardiovascular complications with severe hypothyroidism include sick sinus syndrome, AV block, decreased myocardial contractility, low cardiac output, and hypotension. Myxedema coma requiring temporary or permanent pacemaker implantation is rare, and the requirement of the procedure is mainly due to second-degree or complete AV block. Although those conditions usually need permanent pacemaker insertion even after normalization of thyroid status, reversible cases have been reported.<sup>6</sup> To cite an example, Waseem et al reported a case of myxedema coma with severe bradycardia and high-grade AV block that was successfully treated with thyroxine hormone replacement without requiring cardiac pacemaker placement.<sup>7</sup> Schoenmakers et al reported a 90-year-old patient who presented with complete AV block because of severe hypothyroidism, in whom AV conduction was restored after supplementation with levothyroxine.<sup>8</sup> To the best of our knowledge, this is the first reported case of hypothyroidism-induced SSS requiring a temporary pacemaker successfully avoiding permanent pacemaker with hormone replacement therapy. Our case, together with previous cases, suggests that SSS accompanying myxedema coma can be improved by treatment of hypothyroidism with permanent pacemaker implantation, thereby being avoidable, as in our case. Since myxedema coma mainly affects elderly people, early recognition and treatment with levothyroxine are important for avoiding permanent pacemaker implantation, which is a relatively invasive procedure.

Hypercapnic respiratory failure is another emergency complication of myxedema coma. In patients with myxedema crisis, hypoxemia is observed in 80%, while hypercapnia in 54% of the patients.<sup>9,10</sup> Hypoventilation with respiratory acidosis primarily results from central depression of ventilatory drive and decreased responsiveness to hypoxia and hypercapnia.<sup>11</sup> Other contributing factors of respiratory failure because of hypothyroidism include respiratory muscle weakness, mechanical obstruction by a large tongue and pharynx, obesity, diaphragmatic dysfunction, and sleep apnea.<sup>11,12</sup> These respiratory abnormalities respond to thyroid hormone replacement, as observed in our case. Although hypoventilatory respiratory failure does not tend to be associated with endocrine diseases, hypothyroidism should



**FIGURE 2** The patient's clinical course and transition of laboratory data including pCO<sub>2</sub> of arterial blood gas, free T<sub>4</sub> (FT<sub>4</sub>), and thyroid-stimulating hormone (TSH). Since blood culture (BC) examination revealed methicillin-resistant *Staphylococcus epidermidis* (MRSE), intravenous vancomycin (VCM) was administered. Noninvasive positive pressure ventilation (NPPV) was discontinued on day 16, and temporary cardiac pacing was discontinued on day 39

be included as a differential diagnosis in elderly patients if no obvious cardiopulmonary or central nervous system disease explains the clinical presentation because myxedema coma occurs in elderly populations, especially those older than 60 years of age.<sup>13</sup>

In conclusion, we report a case of myxedema coma in an elderly woman that was accompanied by SSS and hypercapnic respiratory failure, which were successfully treated with thyroid hormone replacement. Since the mortality rate of the disease is high possibly because of its cardiopulmonary complications, early detection of the condition and administration of levothyroxine, intravenous levothyroxine if available, are essential to improve the life-threatening condition and avoid invasive treatment such as permanent pacemaker implantation or intubation.

## ACKNOWLEDGEMENT

None.

## CONFLICT OF INTEREST

The authors have stated explicitly that there are no conflicts of interest in connection with this article.

## ORCID

Ko Harada  <https://orcid.org/0000-0002-3801-1472>

## REFERENCES

- Rodriguez I, Fluiters E, Perez-Mendez LF, Luna R, Paramo C, Garcia-Mayor RV. Factors associated with mortality of patients with myxoedema coma: prospective study in 11 cases treated in a single institution. *J Endocrinol.* 2004;180:347–50.
- Ono Y, Ono S, Yasunaga H, Matsui H, Fushimi K, Tanaka Y. Clinical characteristics and outcomes of myxedema coma: analysis of a national inpatient database in Japan. *J Epidemiol.* 2017;27:117–22.
- Chaudhari D, Gangadharan V, Forrest T. Heart failure presenting as myxedema coma: case report and review article. *Tenn Med.* 2014;107:39–41.
- Behnia M, Clay AS, Farber MO. Management of myxedematous respiratory failure: review of ventilation and weaning principles. *Am J Med Sci.* 2000;320:368–73.
- Aoki C, Kasai K. [The diagnosis and treatment of myxedema coma]. *Nihon Rinsho.* 2012;70:1995–9.
- Ozcan KS, Osmonov D, Erdinler I, Altay S, Yildirim E, Turkkan C, et al. Atrioventricular block in patients with thyroid dysfunction: prognosis after treatment with hormone supplementation or antithyroid medication. *J Cardiol.* 2012;60:327–32.
- Waseem H, Hashmi AT, Anser M, Wali N, Rodriguez D, Greenberg Y. A pacemaker that was avoided. *Cureus.* 2018;10:e2555.
- Schoenmakers N, de Graaff WE, Peters RH. Hypothyroidism as the cause of atrioventricular block in an elderly patient. *Neth Heart J.* 2008;16:57–9.
- Reinhardt W, Mann K. Incidence, clinical picture and treatment of hypothyroid coma. Results of a survey. *Med Klin (Munich).* 1997;92:521–4.
- Salomo Lh, Laursen Ah, Reiter N, Feldt-Rasmussen U. Myxoedema coma: an almost forgotten, yet still existing cause of multiorgan failure. *BMJ Case Rep.* 2014;2014. <https://doi.org/10.1136/bcr-2013-203223>.
- Zwillich CW, Pierson DJ, Hofeldt FD, Lufkin EG, Weil JV. Ventilatory control in myxedema and hypothyroidism. *N Engl J Med.* 1975;292:662–5.
- Martinez FJ, Bermudez-Gomez M, Celli BR. Hypothyroidism. A reversible cause of diaphragmatic dysfunction. *Chest.* 1989;96:1059–63.
- Guo F, Xu T, Wang H. Early recognition of myxedematous respiratory failure in the elderly. *Am J Emerg Med.* 2009;27:212–5.

**How to cite this article:** Harada K, Murakami S, Tokumasu K, Togawa Y, Otsuka F. Myxedema coma accompanied by sick sinus syndrome and hypoventilation: A case report. *J Gen Fam Med.* 2019;20:206–208. <https://doi.org/10.1002/jgf2.267>