

Myxoid Leiomyosarcoma of the Uterus : A Case Report and Review of the Literature

A case report of myxoid leiomyosarcoma of the uterus in a 54-year-old woman is presented as a rare variant of uterine sarcoma. Only 14 cases have been described in the literature. These tumors have a striking myxoid appearance and exhibit highly malignant behavior despite their low mitotic index. Although it is difficult to establish the nature of the neoplastic cells in the myxoid areas, both light microscopical and immunohistochemical characteristics showed features of smooth muscle cells in some of the cellular areas. Our patient had a tumor which arose in association with hyalinized benign leiomyomatous lesion. Like other reported cases of myxoid leiomyosarcoma, the tumor behaved aggressively.

Key Words : Uterus; Leiomyosarcoma, myxoid

Eundeok Chang, Sang In Shim

Department of Pathology, Catholic University of Korea, Seoul, Korea

Received : April 29, 1998

Accepted : June 2, 1998

Address for correspondence

Eundeok Chang, M.D.
Department of Pathology, St. Vincent's Hospital,
Catholic University of Korea, Ji-dong 93, Paldal-gu,
Suwon, Kyunggi 440-060, Korea
Tel : +82.331-240-2240, Fax : +82.331-248-5520
E-mail : paikns@unitel.co.kr

*This paper was in part supported by the Catholic University Publication Fund.

INTRODUCTION

Myxoid leiomyosarcoma of the uterus was first described in 1982 by King et al. (1). Their six cases were typified grossly by a gelatinous appearance, microscopically by large amount of myxoid material surrounding neoplastic cells and a low mitotic index [range 0 to 2

per 10 high power fields (hpf)]. All cases followed a malignant course. Eight additional cases have been published since King's report (Table 1) and the majority of them had low mitotic rates. However, four cases with a high mitotic rate were also reported (2-5). The diagnosis was primarily based on gross and microscopic features rather than the mitotic index. We report a case

Table 1. Reported cases of uterine myxoid leiomyosarcoma

Authors (year)	No. of patients	Ages at presentation (yr)	Treatment	No. of mitoses per 10 hpf	Time interval to recurrence	Comments
King et al. (1) (1982)	6	47-68	5 of 6 TAH/BSO; 1 chemoT; 2 RT	0-2	6 ms-10 yrs	4 of 6 died
Kim et al. (5) (1983)	1	50	TAH/BSO	1-4		Tumor free 2 yrs; lost to FU
Yu et al. (8) (1984)	2	59, 76	TAH; TAH/BSO	0-1		Lost to FU; alive; 2 yrs
Salm and Evans (3) (1985)	2	67, 68	TAH/BSO	8-19	9 ms	Lost to FU
Peacock and Archer (6) (1989)	1	30	TAH/BSO	0-2		No evidence of recurrence
Kunzel et al. (4) (1992)	1	49	TAH/BSO ChemoT	30	5 ms	Living; recurrent abdominal disease
Schneider et al. (5) (1995)	1	65	TAH/BSO	20-30	6 ms	Died at 8 ms
Chang and Shim (present case)	1	54	TAH/BSO ChemoT	0-2	10 ms	Died at 1 yr

TAH/BSO, total abdominal hysterectomy with bilateral salpingo-oophorectomy; FU, follow up; ChemoT, chemotherapy; RT, radiation therapy; ms, months; yrs, years; hpf, high power field.

of myxoid leiomyosarcoma of the uterus in association with benign leiomyomatous lesion.

CASE REPORT

A 54-year-old Korean woman, gravida 4, para 4, elective abortion 1, presented with a 1-year history of low abdominal mass, increasing menometrorrhagia and low abdominal pain was studied. On pelvic examination, a large, ill-defined, symmetrical, soft, globular, nontender uterus was palpated. Ultrasonography revealed an enlarged uterus consistent with myoma, and a moderate amount of fluid in the cul-de-sac. Papanicolaou smears from the uterine cervix and the straw-colored fluid in the cul-de-sac were benign. Computerized tomography (CT) demonstrated a huge diffuse hyalinized mass with linear and nodular calcifications (Fig. 1). After enhancement, hypodense areas which indicate some degeneration of the tumor were noted within the tumor. Chest x-ray film was normal. She has a blindness in the right eye, following a trauma. The preoperative serum CA-125 level was 248 IU/ml and other laboratory values were normal except anemia. The presumptive diagnosis was uterine leiomyoma.

A total abdominal hysterectomy and bilateral salpingo-oophorectomy were performed. The patient was treated with six courses of carboplatin-VP 16, followed with serial physical exams and serum CA-125 levels. The postoperative serum CA-125 level had fallen to 40 IU/ml from a preoperative level of 248 IU/ml, reaching 16.0

IU/ml after the completion of the fourth chemotherapy cycle.

On postoperative 18 months, two months after completion of the sixth chemotherapy cycle, she returned with hypertension and pelvic pain, most probably due to local recurrence. On CT scan, the evidence of recurrence with multiple pelvic masses, liver metastasis and peritoneal dissemination was found.

Pathologic findings

Inspection of the opened uterine specimen revealed a 17-cm bulky, poorly circumscribed mass with a soft gelatinous consistency and a variegated cut surface that is amber yellow, partly dark red to black, with foci of hemorrhage (Fig. 2). A white hard leiomyomatous lesion was associated within the tumor. The mass shows gross evidence of extension into the endometrium. Intraoperative frozen section was interpreted as "borderline to malignant neoplasm, definitive diagnosis deferred". The uterus weighed 1,850 g and measured 17×8×13 cm. There was no evidence of extrauterine disease. Both adnexae were unremarkable.

On microscopic examination, the tumor was highly myxomatous and large areas of the tumor were necrotic and hemorrhagic. There was an osteocalcific area in diffuse hyalinized stroma. The stellate and bipolar spindle cells were seen in the background of myxoid stroma (Fig. 3). Focally, bundles of typical anaplastic smooth muscle cells were noted. Mitotic figures were inconspicuous in the well differentiated myxoid areas (0-2 per 10), but

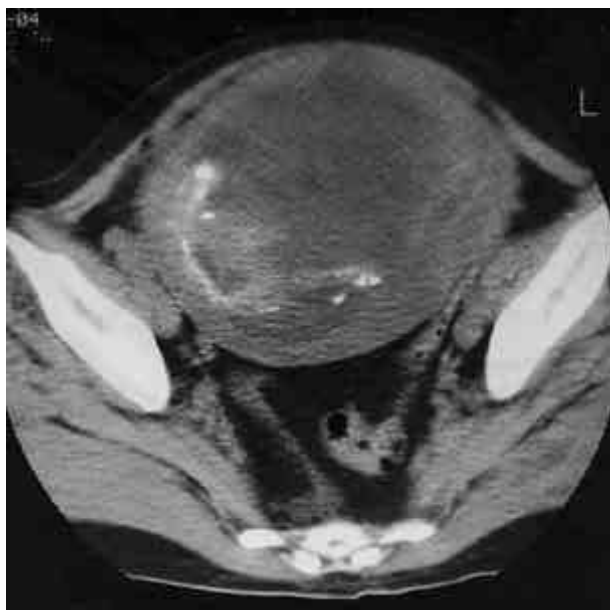

Fig. 1. CT shows a huge diffuse hyalinized mass with linear and nodular calcifications.

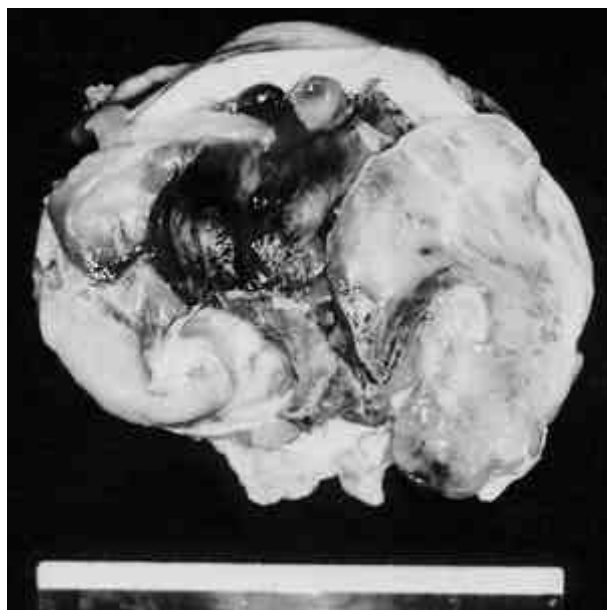


Fig. 2. A bulky, poorly circumscribed mass with a myxoid and gelatinous appearance in myometrium.

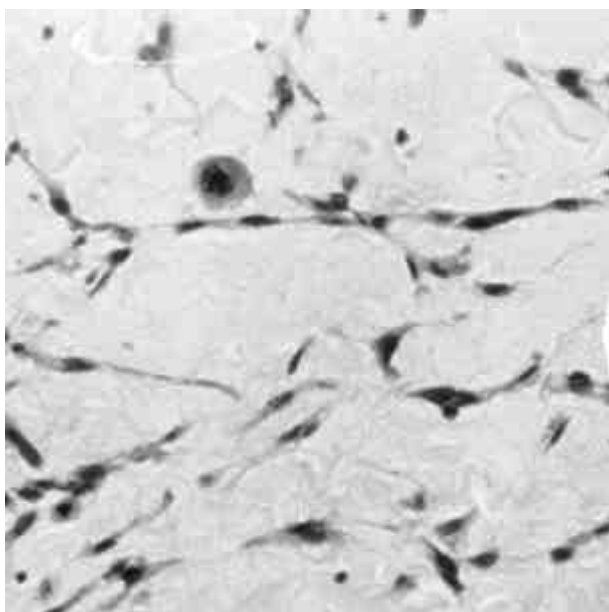


Fig. 3. Stellate and bipolar spindle tumor cells in the background of myxoid stroma with a mitosis (H&E, $\times 400$).

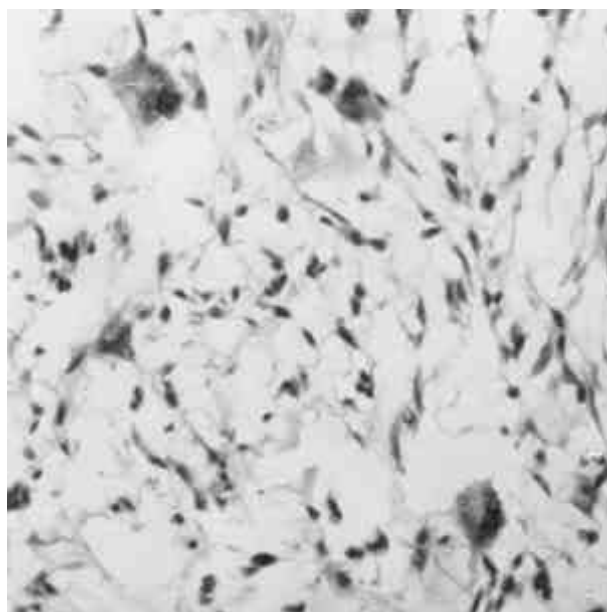


Fig. 4. Tumor contains several osteoclast-like giant cells (H&E, $\times 200$).

higher in more cellular pleomorphic areas (up to 8 per 10 hpf). Tumor contained several osteoclast-like giant cells (Fig. 4). The peculiar feature of this tumor was the presence of myxoid material in the cytoplasm of malignant cells as well as diffuse in the extracellular matrix. This material showed positive staining for Alcian blue.

Immunoperoxidase staining performed on formalin-fixed material showed a strong positive reaction for alpha-smooth muscle actin and vimentin. The tumor invaded the myometrium, but no vascular or lymphatic invasion was seen.

DISCUSSION

Myxoid leiomyosarcomas represent a rare neoplasm with an incidence estimated at 0.3 to 0.67 per 100,000 women (6, 7), but it is an important variant of leiomyosarcoma of uterus and broad ligament. Myxoid degeneration in benign leiomyomas has been reported with an incidence as high as 13%, but myxoid change in a uterine leiomyosarcoma is extremely rare (4). The entity known as "myxoid leiomyosarcoma of the uterus" was first described by King et al. (1) in 1982 with a report of six cases. The patients ranged in age from 47 to 68 years and presented with vaginal bleeding and/or a pelvic mass. All had recurrence of disease within 6 months to 10 years despite total abdominal hysterectomy with bilateral salpingo-oophorectomy or radiation therapy. Only 14 cases have been described in the literature including two

cases in Korea (Table 1) (1-6, 8). The patients ranged in age from 30 to 76 years with a mean age of 57 years. All patients were first seen with abnormal bleeding and/or pelvic mass. The tumors were relatively large, ranging from 5 cm in one of the oldest patient to "massive". Almost all cases except one were treated by total abdominal hysterectomy and bilateral salpingo-oophorectomy with adjuvant therapy. Three of the 14 reported cases were lost to follow-up (2, 3, 8), and only 1 patient showed no evidence of recurrence 18 months after the operation (6). All of the others had recurrence of the disease within 5 months to 10 years.

Myxoid leiomyosarcomas usually arose in postmenopausal women and were not known to be related to the known risk factors for endometrial carcinoma (nulliparity, obesity, diabetes mellitus, hypertension, etc.) or carcinosarcoma (prior radiation therapy) (9). They may occur in uteri that also bear typical benign leiomyomas, but leiomyosarcomas rarely can be proven to have arisen in or from benign leiomyomas (9). This present case had also a focus of hyalinized leiomyoma.

They have a gelatinous appearance and apparently well-circumscribed border. Microscopically, they are invasive and highly myxomatous, focally bundles of typical smooth muscle cells alternate with nondescriptive mesenchymal cells.

Traditionally, the mitotic count has separated leiomyosarcomas from cellular leiomyomas. For this variant of leiomyosarcoma, the metastatic mitotic count rule does not apply; they tend to recur and metastasize whether

mitoses are scanty or numerous. Therefore, this tumor is an exception to the general rule that the mitotic count in determining the malignant potential of a smooth muscle tumor. Ten of the 14 previously reported cases of myxoid leiomyosarcoma had less than 2 mitoses per 10 hpf and yet they manifested a malignant course (1). These tumors behaved similar to high-grade sarcomas despite mitotic counts of 0 to 2 per 10 hpf (6). However, Kunzel et al. (4) described an infiltrative growth pattern, bizarre nuclei and 30 abnormal mitotic figures per 10 hpf. Exceptionally, leiomyosarcomas are seen to contain a large population of osteoclast-like giant cells.

Although it was difficult to establish the nature of the neoplastic cells in many of the myxoid and even some of the cellular areas, the tumor cells were typical of smooth muscle cells on light microscopical examination in areas, and immunohistochemical stainings also revealed features of smooth muscle cells.

Like other uterine smooth muscle neoplasms, this tumor probably arose from the smooth muscle cells of the myometrium, or possibly of its blood vessel walls (1).

The myxoid leiomyosarcoma of the uterus described in this and previous articles is a rare entity but should be included in the differential diagnosis of any uterine tumor with a predominantly myxomatous composition. To differentiate myxoid leiomyosarcoma from a benign leiomyoma with myxoid change, one cannot rely solely on intraoperative frozen section because these tumors are characterized by a low mitotic count without atypia in most instances (4).

A better prognosis is associated with premenopausal status, circumscribed margins, and low mitotic counts (4). The myxoid variant may be an exception; it has a poor prognosis overall but perhaps a more indolent course (9). Like other reported cases of myxoid leiomyosarcoma, the present tumor behaved aggressively.

Acknowledgements

Special thanks to Insun Kim, M.D., Department of Pathology, Korea University, for critical review and comments on histologic slides.

REFERENCES

1. King ME, Dickersin GR, Scully RE. *Myxoid leiomyosarcoma of the uterus. A report of six cases. Am J Surg Pathol* 1982; 6: 589-98.
2. Kim HK, Choi JS, Paik SY, Kim MS. *A case report of myxoid leiomyosarcoma of the uterus. Korean J Pathol* 1983; 17: 160-4.
3. Salm R, Evans DJ. *Myxoid leiomyosarcoma. Histopathology* 1985; 9: 159-69.
4. Kunzel KE, Mills NZ, Muderspach LI, D'Ablaing G. *Myxoid leiomyosarcoma of the uterus, case report. Gynecol Oncol* 1993; 48: 277-80.
5. Schneider D, Halperin R, Segal M, Maymon R, Bukovsky I. *Myxoid leiomyosarcoma of the uterus with unusual malignant histologic pattern - a case report. Gynecol Oncol* 1995; 59: 156-8.
6. Peacock G, Archer S. *Myxoid leiomyosarcoma of the uterus: case report and review of the literature. Am J Obstet Gynecol* 1989; 160: 1515-9.
7. Zaloudek C, Norris HJ. *Mesenchymal tumors of the uterus. In: Kurman RJ, ed. Blaustein's pathology of the female genital tract. 3rd ed. New York: Springer-verlag, 1987: 373-408.*
8. Yu ES, Ahn GH, Lee HS, Nam SY, Lee JY. *Myxoid leiomyosarcoma of the uterus, a report of two cases. Korean J Pathol* 1984; 18: 271-5.
9. Silverberg SG, Kurman RJ. *Tumors of the uterine corpus and gestational trophoblastic disease. In: Atlas of Tumor Pathology, series 3, fascicle 3. Washington, DC: Armed Forces Institute of Pathology, 1992: 130-6.*