

Narrowband (311-nm) UV-B Therapy for Small Plaque Parapsoriasis and Early-Stage Mycosis Fungoides

Angelika Hofer, MD; Lorenzo Cerroni, MD; Helmut Kerl, MD; Peter Wolf, MD

Background: Broadband UV-B phototherapy has been used for many years in the treatment of small plaque parapsoriasis (SPP) and early-stage mycosis fungoides (MF). Our purpose was to investigate the effect on these diseases of narrowband (311-nm) UV-B therapy, which was recently established for the treatment of psoriasis and found to be more effective than broadband UV-B therapy.

Observations: Twenty patients (5 women, 15 men; age range, 39-85 years) with histologically confirmed SPP or early-stage MF were enrolled. Six patients had early-stage MF (patch stage), and 14 had SPP. Treatment with 311-nm UV-B was given 3 to 4 times a week for 5 to 10 weeks. In 19 patients, lesions completely cleared after a mean number of 20 treatments (range, 14-29 treatments) and a mean cumulative UV-B dose of 16.3 J/cm²

(range, 7.4-36.4 J/cm²) within a mean time of 6 weeks (range, 5-10 weeks). Biopsy specimens taken immediately after the end of phototherapy showed only sparse inflammatory infiltrates but no signs of SPP or MF. Relapses at cutaneous sites occurred in all patients within a mean time of 6 months (range, 2-15 months).

Conclusions: Narrowband UV-B therapy is an effective short-term treatment modality for clearing SPP and early-stage MF. However, the treatment response did not sustain long-term remission. Further studies are necessary to examine how the clinical response to and follow-up after narrowband UV-B therapy compares with that of established phototherapy modalities in these diseases.

Arch Dermatol. 1999;135:1377-1380

TREATMENT OF small and large plaque parapsoriasis and mycosis fungoides (MF) for many years has consisted of UV-B¹ as well as psoralen-UV-A (PUVA)²⁻⁶ therapy. Although large plaque parapsoriasis is considered an early form of MF, the relation of small plaque parapsoriasis (SPP) to MF is still a matter of discussion.⁷⁻⁹ However, to prevent early-stage MF from progressing, an early aggressive therapy and careful monitoring of the patients may be necessary.¹⁰

Narrowband UV-B was introduced recently for the treatment of psoriasis and found to be more effective than broadband UV-B at clearing psoriatic lesions.¹¹ Indeed, even when compared with PUVA photochemotherapy, narrowband UV-B was reported to have on average the same efficacy but fewer side effects.¹² Therefore, the purpose of our study was to investigate the effect of narrowband (311-nm) UV-B in patients with SPP and early-stage MF.

RESULTS

All 20 patients completed the study, and 19 (95%) had a complete clinical remis-

sion (patients with SPP, 14 of 14; patients with MF, 5 of 6) (Table 1 and Figure 1). Complete clearance of skin lesions in those 19 patients was observed after a mean number of 20 treatments (range, 14-29 treatments) and a mean cumulative UV-B dose of 16.3 J/cm² (range, 7.4-36.4 J/cm²) within a mean time of 44 days (range, 36-69 days). The clinical remission could be confirmed histologically in 13 patients who agreed to have a punch biopsy specimen taken before and after therapy (Figure 2). The posttreatment biopsy specimens of these patients showed only a sparse inflammatory infiltrate but no features typical of SPP or MF (Figure 2, right). One patient with MF (patient 16) showed only a partial response to 311-nm UV-B but a complete clinical response to PUVA therapy. In 5 (26%) of 19 patients who had a complete clinical response, postinflammatory hyperpigmentation occurred at the site of diseased skin.

In the follow-up period, relapses occurred in all patients within a mean time of 6 months (range, 2-15 months) (Table and Figure 3). There was no statistically significant difference in the primary response rate (Fisher exact test, $P = .30$) or in the response rate on long-term follow-up (log-

From the Department of Dermatology, University of Graz, Graz, Austria.

PATIENTS AND METHODS

PATIENTS

Twenty patients with histologically confirmed SPP or early-stage MF were enrolled in the study, after giving their informed consent. Their demographic and phototherapeutic data are given in **Table**. Diagnoses were made according to clinical and histopathological findings.¹³ Fourteen patients (2 women and 12 men; mean age, 51 years; age range, 39-67 years) had small, oval, red-brown, slightly scaly patches symmetrically distributed on the limbs and trunk; these were all classified clinically and histopathologically as SPP. In these 14 patients, the mean disease duration was 7 years (range, 6 months to 17.5 years). Six patients (3 women and 3 men; mean age, 71.5 years; age range, 57-85 years) showed large red-brown patches (some of which were slightly wrinkled), mostly on the trunk; these were classified clinically and histopathologically as patch-stage MF (stage IA and IB, according to the National Cancer Institute classification¹⁴) (**Figure 1**). In these 6 patients, the mean disease duration was 11 years (range, 1.5-25 years). None of the patients had enlarged axillary or inguinal lymph nodes. There were no abnormalities in red or white blood cell counts in any of the patients. The results of all other routine investigations were within normal limits.

LIGHT SOURCE AND TREATMENT

Therapy was given in a UV irradiation cubicle (Waldmann 7001; Waldmann Medizinische Technik, Gevelsberg, Germany) equipped with 40 100-W fluorescent lamps (TL-01; Philips Company, Eindhoven, the Netherlands). The mean light intensity of the UV cubicle was 7.41 mW/cm² as measured by the integrated light-detecting instrument. Therapy was given 3 to 4 times a week until more than 95% clearing of the patient's skin lesions had occurred. The initial treatment dose was 70% of a patient's individual minimal 311-nm UV-B erythema dose. The UV dose was increased weekly by 20% if previous treatments had caused no or slight erythema. The dose was not increased if previous treatments had produced marked erythema. During the study and the follow-up period, only emollients were permitted for topical skin care.

DETERMINATION OF CLINICAL RESPONSE

Clinical response was rated as follows: complete response, more than 95% clearing of skin lesions; partial response, 50% to 95%; and no response, less than 50%. Before and after therapy, 4-mm punch biopsy specimens were taken from each patient at the site of a representative skin lesion for histologic examination. The specimens were processed routinely and stained with hematoxylin-eosin for light microscopic examination.

Demographics and Phototherapeutic Data*

| Patient No./ Sex/Age, y | Disease | Duration of Disease, y | No. of Exposures | Therapy Duration, d | Total UV-B Dose, J/cm ² | Response | Side Effects | Remission-Free Interval, wk |
|----------------------------|---------|---------------------------|---------------------|------------------------|---------------------------------------|----------|-----------------|--------------------------------|
| 1/M/85 | MF | 3 | 19 | 38 | 24.4 | CR | None | 14 |
| 2/M/75 | MF | 25 | 20 | 44 | 14.7 | CR | None | 9 |
| 3/M/45 | SPP | NA | 19 | 39 | 13.4 | CR | None | 11 |
| 4/M/57 | SPP | 4.5 | 14 | 43† | 7.8 | CR | None | 39 |
| 5/F/78 | MF | 13 | 15 | 38 | 7.4 | CR | PH | 65 |
| 6/M/54 | SPP | 0.5 | 27 | 42 | 19.8 | CR | None | 9 |
| 7/M/67 | SPP | 17.5 | 18 | 38 | 14.7 | CR | None | 44 |
| 8/M/39 | SPP | 7 | 14 | 38 | 10.1 | CR | PH | 13 |
| 9/M/59 | SPP | 10 | 23 | 46 | 16.9 | CR | None | 39 |
| 10/F/41 | SPP | 8 | 19 | 42 | NA | CR | None | 31 |
| 11/M/45 | SPP | NA | 18 | 38 | 20.4 | CR | None | 26 |
| 12/M/52 | SPP | 5 | 18 | 39 | 11.5 | CR | None | 9 |
| 13/M/52 | SPP | 13.5 | 24 | 60† | 15.0 | CR | PH | 14 |
| 14/M/48 | SPP | 3 | 26 | 49 | 36.4 | CR | None | 18 |
| 15/M/59 | MF | NA | 29 | 69† | 26.4 | CR | None | 18 |
| 16/F/75 | MF | NA | 15 | 22 | 6.1 | PR | None | NA |
| 17/F/53 | SPP | 6 | 15 | 45† | 7.6 | CR | None | 26 |
| 18/F/57 | MF | 1.5 | 17 | 36 | 13.0 | CR | None | 11 |
| 19/M/49 | SPP | 5 | 21 | 46 | 18.0 | CR | PH | 18 |
| 20/M/57 | SPP | 3 | 18 | 39 | 15.6 | CR | PH | 32 |

*MF indicates mycosis fungoides stage IA or IB; SPP, small plaque parapsoriasis; NA, data not available; CR, complete response (>95% clearance of diseased area); PR, partial response (50%-95% clearance of diseased area); and PH, postinflammatory hyperpigmentation.

†Therapy was interrupted for 3 to 6 days for personal reasons.

rank test, $P = .73$) between patients with SPP and those with early-stage MF (patch stage) (Figure 3). In 7 (37%) of 19 patients who had complete clearance, the skin changes associated with relapse were less widespread and intense, and

topical steroids were then effective at producing clearance again. Five patients (patients 1, 2, 12, 13, and 18) were again treated with 311-nm UV-B and again responded with complete clearing (data not shown).

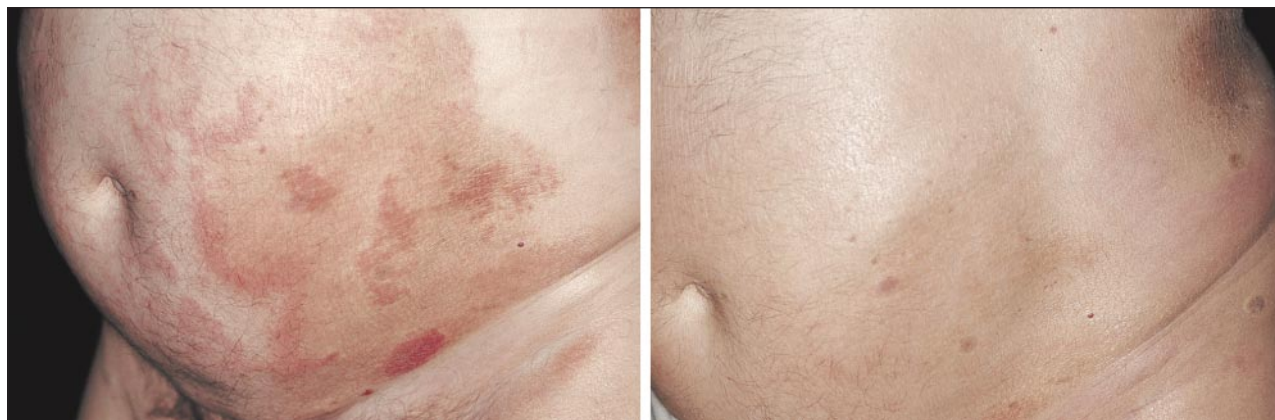

Figure 1. Patient 1. An 85-year-old man with early-stage mycosis fungoides before (left) and after (right) approximately 6 weeks of 311-nm UV-B therapy.

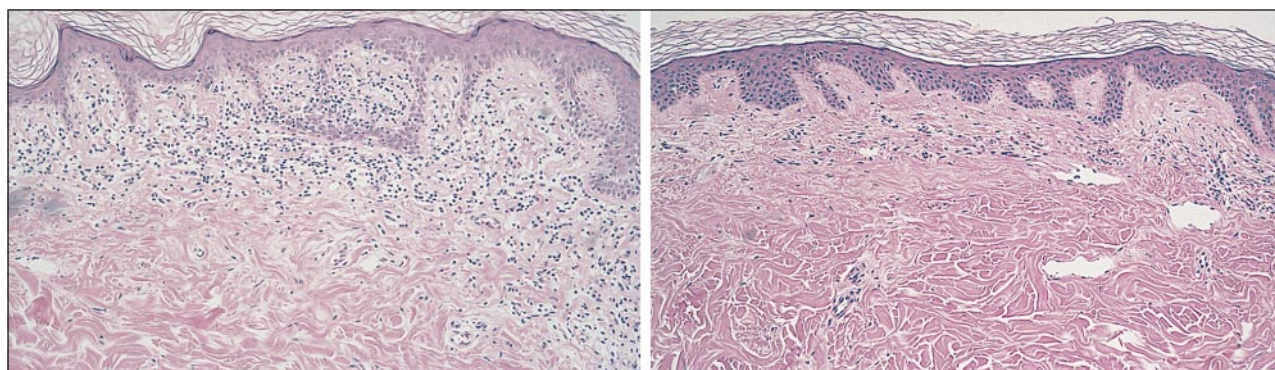


Figure 2. Histologic specimen from patient 18, a 57-year-old woman with early-stage mycosis fungoides before (left) and after (right) 311-nm UV-B therapy. Left, Bandlike infiltrate of lymphocytes within a fibrotic papillary dermis. Epidermotropism is seen. Right, Discrete inflammatory infiltrate within the superficial dermis. Epidermotropism is absent.

COMMENT

To our knowledge, this is the first study showing that narrowband UV-B therapy is effective in clearing skin lesions of SPP and early-stage MF. Treatment with 311-nm UV-B cleared the skin lesions in 100% of patients with SPP and all but 1 patient with early-stage MF (Figure 1) within a mean time of 6 weeks. However, in the follow-up period, relapses occurred in all patients within a mean time of 6 months. One possible reason why relapse occurred so relatively quickly in all cases of SPP and early-stage MF treated with 311-nm UV-B may have been the lack of maintenance therapy and/or slow tapering schedule after remission.

Compared with broadband UV-B therapy, 311-nm UV-B therapy as applied herein seemed to induce an equal or even higher primary response rate in patients with SPP as well as those with early-stage MF.^{1,15} For instance, Ramsay et al¹ showed in a retrospective nonrandomized study of 37 patients with early (stages IA-IIB) cutaneous T-cell lymphoma (CTCL) that broadband UV-B treatment produced complete clearance in 25 (83%) of 30 patients with stage I CTCL after a median time of 5 months, but produced no response in any patients with stage II CTCL. Among the patients who achieved complete remission, 5 (20%) had a relapse after a median time of 5 months (range, 1-33 months); in 2 of these patients, relapse occurred during UV-B maintenance therapy, which was given to all patients for at least 3 months. Resnik and Vonderheid¹⁵ re-

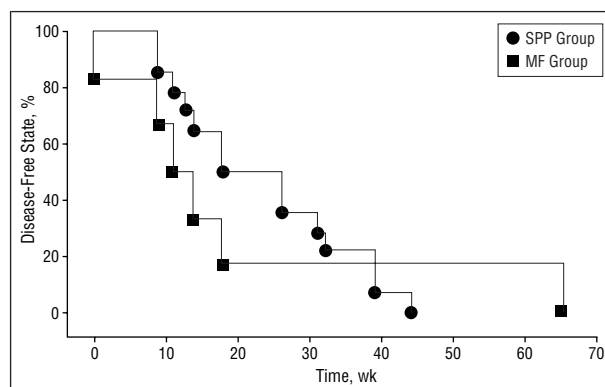


Figure 3. Kaplan-Meier lifetime table analysis for the follow-up of patients with small plaque parapsoriasis (SPP) ($n = 14$) and early-stage mycosis fungoides (MF) ($n = 6$) treated with 311-nm UV-B therapy. There was no statistically significant difference in the disease-free rate between patients with SPP and MF (log-rank test, $P = .73$).

ported on the long-term follow-up of 31 patients with early MF of stage IA (21 patients), stage IB (9 patients), and stage IIA (1 patient) treated with commercially available home UV phototherapy units emitting UV radiation in the UV-A and UV-B wavelength range (280-350 nm). Twenty-three (74%) of 31 patients achieved a complete clinical response after a mean time of 5 months (range, 1-38 months), but 12 (63%) of 19 patients available for follow-up suffered relapses after a median of 16.5 months (range, 5-109 months). Compared with our 311-nm UV-B treatment, the

home phototherapy regimen was much more time-consuming and produced a much lower clearance rate.

However, our results compare well with the primary response rates reported for PUVA treatment of parapsoriasis en plaques and early-stage MF. For instance, Rosenbaum et al⁴ reported an overall initial complete response rate of 58% (25 of 43 patients) with CTCL, including parapsoriasis en plaques (7 patients) and plaque-stage (23 patients), tumor-stage (5 patients), and erythrodermic MF (8 patients). Although maintenance PUVA treatment was given in 17 (68%) of 25 patients, the disease recurred after a mean of approximately 6 months. Herrmann et al⁶ observed complete clinical and histologic clearing in 53 (65%) of 82 patients with MF of all stages (including 68 patients [83%] with stage 1A or 1B) with a mean duration of total complete response of 43 months.

Until now there have been only a few, mostly retrospective studies concerning the treatment of SPP and MF with UV-B therapy or PUVA photochemotherapy. Therefore, prospective, randomized studies seem to be desirable for comparing the clinical efficacy of PUVA, broadband UV-B, and 311-nm UV-B in the treatment of SPP and early-stage MF. Those studies should show whether 311-nm UV-B therapy can gain a place in the routine phototherapeutic armamentarium for early-stage CTCL.

Accepted for publication May 21, 1999.

Corresponding author: Peter Wolf, MD, Department of Dermatology, University of Graz, Auenbruggerplatz 8, A-8036, Graz, Austria (e-mail: peter.wolf@kfunigraz.ac.at).

REFERENCES

1. Ramsay DL, Lish KM, Yalowitz CB, Soter NA. Ultraviolet-B phototherapy for early-stage cutaneous T-cell lymphoma. *Arch Dermatol*. 1992;128:931-933.
2. Westphal HJ, Walther A. Phototherapy of parapsoriasis. *Dermatol Monatsschr*. 1989;175:555-560.
3. Gilchrist BA. Methoxsalen photochemotherapy for mycosis fungoides. *Cancer Treat Rep*. 1979;63:663-667.
4. Rosenbaum MM, Roenigk HH Jr, Caro WA, Esker A. Photochemotherapy in cutaneous T cell lymphoma and parapsoriasis en plaques: long-term follow-up in forty-three patients. *J Am Acad Dermatol*. 1985;13:613-622.
5. Morita A, Takashima A, Nagai M, Dall'Acqua F. Treatment of a case of mycosis fungoides and one parapsoriasis en plaque with topical PUVA using a monofunctional furcoumarin derivative, 4,6,4'-trimethylengelicin. *J Dermatol*. 1990;17:545-549.
6. Herrmann JJ, Roenigk HH, Hurria A, et al. Treatment of mycosis fungoides with photochemotherapy (PUVA): long-term follow-up. *J Am Acad Dermatol*. 1995;33:234-242.
7. Burg G, Dummer R. Small plaque (digitate) parapsoriasis is an "abortive cutaneous T-cell lymphoma" and is not mycosis fungoides [editorial comment]. *Arch Dermatol*. 1995;131:336-338.
8. Ackerman AB. If small plaque (digitate) parapsoriasis is a cutaneous T-cell lymphoma, even an "abortive" one, it must be mycosis fungoides! *Arch Dermatol*. 1996;132:562-566.
9. Cerroni L, Kerl H, Gatter K. *An Illustrated Guide to Skin Lymphoma*. Cambridge, Mass: Blackwell Publishers; 1998.
10. Lawrence CM, Marks JM, Burridge A, et al. The nature of mycosis fungoides. *QJM*. 1986;227:281-293.
11. El Ghorri AA, Norval M. Biological effects of narrow-band (311 nm TL 01) UVB irradiation: a review. *J Photochem Photobiol B*. 1997;38:99-106.
12. Van Weelden H, Baart de la Faille H, Young E, van der Leun JC. Comparison of narrow-band UV-B phototherapy and PUVA photochemotherapy in the treatment of psoriasis. *Acta Derm Venereol*. 1990;70:212-215.
13. LeBoit PE, McCalmont TH. Cutaneous lymphomas and leukemia. In: Elder D, Elenitsas R, Jaworsky C, Johnson B Jr, eds. *Lever's Histopathology of the Skin*. Philadelphia, Pa: Lippincott-Raven Publishers; 1997:805-846.
14. Lamberg SI, Bunn PA Jr. Cutaneous T-cell lymphomas: summary of the Mycosis Fungoides Cooperative Group-National Cancer Institute Workshop. *Arch Dermatol*. 1979;115:1103-1105.
15. Resnik KS, Vonderheid EC. Home UV phototherapy of early mycosis fungoides: long-term follow-up observations in thirty-one patients. *J Am Acad Dermatol*. 1993;29:73-77.