

University of Nebraska - Lincoln

DigitalCommons@University of Nebraska - Lincoln

Papers in Veterinary and Biomedical Science

Veterinary and Biomedical Sciences,
Department of

8-1-1986

Natural and Experimental Infection with an Attaching and Effacing Strain of *Escherichia coli* in Calvest

Rodney A. Moxley

University of Nebraska-Lincoln, rmoxley1@unl.edu

David H. Francis

South Dakota State University, david.francis@sdstate.edu

Follow this and additional works at: <https://digitalcommons.unl.edu/vetscipapers>



Part of the [Veterinary Medicine Commons](#)

Moxley, Rodney A. and Francis, David H., "Natural and Experimental Infection with an Attaching and Effacing Strain of *Escherichia coli* in Calvest" (1986). *Papers in Veterinary and Biomedical Science*. 16. <https://digitalcommons.unl.edu/vetscipapers/16>

This Article is brought to you for free and open access by the Veterinary and Biomedical Sciences, Department of at DigitalCommons@University of Nebraska - Lincoln. It has been accepted for inclusion in Papers in Veterinary and Biomedical Science by an authorized administrator of DigitalCommons@University of Nebraska - Lincoln.

Natural and Experimental Infection with an Attaching and Effacing Strain of *Escherichia coli* in Calves†

RODNEY A. MOXLEY^{1*} AND DAVID H. FRANCIS²

Department of Veterinary Science, Institute of Agriculture and Natural Resources, University of Nebraska, Lincoln, Nebraska 68583-0907,¹ and Department of Veterinary Science, South Dakota State University, Brookings, South Dakota 57007-1396²

Received 13 January 1986/Accepted 25 April 1986

Gnotobiotic calves were inoculated with an O5:K4:H⁻, urease-positive strain of *Escherichia coli* isolated from a 2-day-old calf with diarrhea. The calves developed elevated temperatures and passed loose mucoid feces, with or without blood. The *E. coli* strain was negative for heat-stable and heat-labile enterotoxins but produced high levels of Shiga-like toxin. Bacteria attached diffusely to the epithelium of the large intestine and multifocally to the epithelium of the ileum. The duodenum and jejunum were not affected. At the sites of bacterial attachment, microvilli were effaced, enterocytes were degenerate, and necrosis and exfoliation had occurred. These results confirm a previous report from England that calves may naturally contract infections similar to those caused by enteropathogenic *E. coli* strains pathogenic to humans or rabbits. This suggests that the calf bacterial strains, like some enteropathogenic *E. coli* strains, produce high levels of Shiga-like toxin and cause attachment and effacement lesions in the colonic epithelium of the infected host.

The term enteropathogenic *Escherichia coli* (EPEC) has been used rather indiscriminately in the past for strains of *E. coli* which cause diarrhea by different mechanisms (34). The term was originally used to describe certain *E. coli* serotypes that caused enteric disease in humans (37). It has since included strains that cause diarrhea by means of (i) heat-stable (ST) (23, 57) and heat-labile (LT) (23, 24) enterotoxins (strains now termed enterotoxigenic [15]); (ii) invasiveness (14, 42), as judged by the Sereny test (56) (strains now termed enteroinvasive [15]); (iii) unknown, untested mechanism(s) (37); and (iv) unknown, nonenterotoxigenic, nonenteroinvasive mechanism(s) (29). The term EPEC has been redefined as those *E. coli* strains belonging to certain serogroups whose pathogenetic mechanisms are of the last type, although the group may contain organisms that produce diarrhea by different mechanisms (15). At least some EPEC intimately attach to and efface microvilli and have been called attaching and effacing *E. coli* (AEEC) (36, 48) or enterocyte-adherent (55) *E. coli*. It has been postulated that the lesion of attachment and effacement results in maldigestion (62) and malabsorption (36). *Shigella dysenteriae* 1 (Shiga)-like toxin (SLT) is frequently produced by EPEC and is thought to play a role in the pathogenesis of diarrhea (46).

Natural infections with EPEC that are AEEC (EPEC-AEEC) occur in humans (10, 18, 51, 62) and rabbits (6, 43, 47-50, 52), and characteristic lesions and disease have been experimentally reproduced (6, 7, 11, 18, 36, 43, 46-48, 52, 59). Recently, an atypical strain of *E. coli* was isolated from calves with dysentery in which attachment and effacement lesions were observed (9, 25). A search for nonenterotoxigenic, SLT-producing *E. coli* strains from diarrheic calves and pigs has indicated that possibly there are rare occurrences in both species in the United States (J. G. Mainil, C. J. Duchesnes, and H. W. Moon, Abstr. Annu. Meet. Conf. Res. Work. Anim. Dis. 1985, 148, p. 28). At least some

of these strains can produce attachment and effacement lesions, as demonstrated in rabbit ileal loops (C. J. Duchesnes, H. W. Moon, and J. G. Mainil, Abstr. Annu. Meet. Conf. Res. Work. Anim. Dis. 1985, 149, p. 28). Attachment and effacement lesions have been seen in the intestinal epithelium of a calf, presumably from the United States, but apparently the causative organism was not isolated, nor was the infection experimentally reproduced (34).

This report confirms studies in England (9, 25) that urease-positive strains of *E. coli* serogroup O5 may cause attachment and effacement lesions and diarrhea in calves. This is, to our knowledge, the first description of such an infection in the United States, in which there was (i) characterization of clinical signs and lesions in the natural infection, with experimental reproduction of lesions and disease in gnotobiotic calves, and (ii) demonstration of SLT production by the bacteria. The organism and the disease it produces are similar to those of EPEC-AEEC of humans and rabbits.

MATERIALS AND METHODS

Natural disease. A 2-day-old Hereford calf from southwestern Minnesota was presented to the South Dakota State University Veterinary Diagnostic Laboratory with diarrhea. Although the diarrhea seemed mild, 3 of 50 calves in the herd had died. Rotavirus and coronavirus particles were observed by electron microscopy (16) in the feces of the calf. There was diffuse villous atrophy in the small intestine and diffuse colonization of the colonic epithelium by bacteria. Large numbers of nonhemolytic *E. coli* were isolated from the large intestine on sheep blood agar (heart infusion base) and tergitol-7. The isolate (strain 84-5406) was subcultured onto blood agar for the expression of the K88 (F4) and 987P (F6) pilus antigens (44) and onto E agar (19) for the expression of the K99 (F5) pilus antigen but was negative for these antigens, as determined by seroagglutination tests (19).

In a preliminary study of the pathogenicity of strain 84-5406, a conventional, colostrum-deprived lamb was inoculated orally with an unspecified dose of broth-cultured organisms. The lamb passed a formed stool containing blood

* Corresponding author.

† Published as paper 7982, Journal Series, Nebraska Agricultural Experiment Station.

TABLE 1. Experimental design and clinical observations

Calf no.	Treatment	Inoculum titer (CFU)	Febrile response ^a	Diarrhea (blood in feces) ^a	No. of days observed PI
1	Strain 84-5406	1.58×10^9	+	+ (-)	5
2	Strain 84-5406	1.12×10^9	+	+ (+)	3
3	Strain 84-5406	1.61×10^{10}	+	- (-)	7
4	Strain G58-1	3.82×10^9	-	- (-)	7
5	TSB		-	- (-)	7

^a +, Positive; -, negative.

and fibrinous material on day 3 postinoculation (PI) and died on day 5 PI, having passed blood-streaked loose stools until the time of death. The lamb was necropsied, and the intestines were cultured for *E. coli* (8) and processed for histologic examination by routine methods (30). *E. coli* was cultured in large numbers from the colon, and diffuse bacterial colonization of the colon was observed by histologic examination. The bacterial isolate from the lamb was found to have the same serotype as strain 84-5406 and was negative for ST (12, 35) and LT (13) enterotoxins, as tested by R. A. Wilson by the same methods as those used on the original isolate (see below). In addition, the isolate from the lamb was found to have the same plasmid electrophoretic pattern (D. H. Francis, unpublished data) as that of strain 84-5406. Thus, Koch's postulates were satisfied, and inoculation of calves was then attempted.

***E. coli* characteristics.** The serotype of strain 84-5406 was determined by standard procedures (22) by R. A. Wilson, The Pennsylvania State University, University Park, Pa. Strain 84-5406 was serotype O5:K4:H⁻, urease positive, and negative for ST and LT enterotoxins. The suckling-mouse (12) and piglet-intestinal-loop (35) assays were used to test for the presence of STI and STII, respectively; the presence of LT was tested for by the Y1 adrenal-cell assays (13). Strain 84-5406 showed no evidence of invasiveness, as judged by the Sereny test (56). Toxicity for Vero cells (28; A. D. O'Brien, T. A. Lively, M. E. Chen, S. W. Rothman, and S. B. Formal, Letter, Lancet i:702, 1983) was detected in broth culture supernatant by D. A. Benfield (South Dakota State University). Microcytotoxicity assays were performed by A. D. O'Brien (Uniformed Services University of the Health Sciences, Bethesda, Md.) by using HeLa cells to detect *S. dysenteriae* 1 (21) or SLT (38), and the results were expressed as the CD₅₀ (cytotoxic doses required to kill 50% of the cells) (24, 40). Strain 84-5406 was classified as a category 4 (high level) SLT producer, having a titer of 10⁴ CD₅₀/ml of broth culture supernatant and 10⁶ CD₅₀/mg of bacterial extract. The cytotoxicity of the bacterial extract was neutralized by rabbit anti-Shiga toxin sera and monoclonal antibodies to SLT (39, 58). Spontaneously released and UV-inducible bacteriophages were detected from strain 84-5406 by N. A. Strockbine (Uniformed Services University of the Health Sciences) by using procedures previously reported (41).

Strain G58-1, a nonenteropathogenic, nonenterotoxigenic strain, serotype O101:K28:H⁻, was obtained from W. K. Maas (New York University, New York, N.Y.). This organism was originally isolated from pig feces and was used as a control inoculum in our study. Strain G58-1 was found to be a low-level SLT producer, with a HeLa cell microcytotoxicity titer of 320 CD₅₀/mg of protein in the bacterial extract, the toxicity of which was neutralized by rabbit anti-Shiga toxin sera (21, 39, 40, 58).

Inoculation procedure. Inocula of strains 84-5406 and G58-1 were prepared as follows. Two bacterial colonies isolated on blood agar were incubated in Trypticase soy broth (TSB; BBL Microbiology Systems, Cockeysville, Md.) for 15 h at 37°C. A 10% (vol/vol) suspension of this culture in TSB was then incubated for 5 h at 37°C on a rocker to obtain a log-phase growth of bacteria. Five calves (three principals and two controls) were used in the study and are listed in order of inoculation in Table 1. Three calves (principals) were inoculated with 1 to 10 ml of a broth suspension of strain 84-5406, equivalent to 1.12×10^9 to 1.61×10^{10} CFU. One control calf was inoculated with 1 ml of a broth suspension containing 3.82×10^{10} CFU of strain G58-1, and the other control calf was fed 10 ml of sterile TSB. The inoculum was fed in approximately 50 ml of sterile milk replacer in a nipple bottle, followed by the regular (946 to 1,092 ml) feeding of milk replacer.

Animals. Gnotobiotic calves were obtained by cesarean section and were maintained in isolators, as previously described (33). Preinoculation sterility was checked by swab cultures from the nares and rectum on blood agar and in thioglycolate broth. Samples of whole blood were obtained from the umbilical vein during cesarean section. A lysate of the buffy coat was passaged four times in a continuous line of bovine turbinate cells and in primary bovine fetal lung cells to check for bovine virus diarrhea (BVD) virus (3). Serum neutralization tests for anti-BVD virus antibodies were also attempted.

All calves were inoculated when they were approximately 24 h old. The inoculations were made in the midafternoon to avoid variability in rectal temperatures due to diurnal fluctuations (20). The calves were checked at 12-h intervals PI for anorexia, depression, fever, diarrhea, and the presence of mucus or blood in the feces and were killed at the first appearance of blood in the feces or at 7 days PI if none appeared.

Tissue collection and processing. Intestinal tissues were collected aseptically while the calves were anesthetized with sodium thiamylal and methoxyflurane (60). Samples for scanning electron microscopy (SEM), transmission electron microscopy (TEM), light microscopy (LM), immunofluorescence microscopy, and bacterial culture (8, 18) were obtained from five sites in the small intestine, and one site each in the cecum, midspiral colon, and midrectum. The samples from the small intestine were taken at sites spaced equidistant from one another from the duodenum (5 cm distal to the pylorus) to the ileum (5 cm proximal to the ileocecal valve). The samples were processed for SEM (61), TEM (61), and LM (30) as previously described. Indirect fluorescent antibody tests on frozen sections (6 μm thick) of gut were incubated with rabbit anti-O5 serum (courtesy of R. A. Wilson) and then with fluorescein isothiocyanate-conjugated goat anti-rabbit immunoglobulin G (Cooper Biomedical, Inc., Malvern, Pa.). Bacterial isolates from intestinal cultures grown on E agar (19) were tested for the F5 pilus antigen by a seroagglutination test (17). Frozen ileal sections were also tested for bovine rotaviral, bovine coronaviral, and BVD viral antigens by direct fluorescent antibody tests by using standard procedures (3, 31, 32). Cecal contents were processed and examined for virus particles by TEM, as previously described (16). Hemostasis was maintained until intestinal sampling was finished. Calves were exsanguinated, and rumen, abomasum, liver, spleen, mesenteric lymph node, kidney, heart, and lung samples were obtained, cultured (8), and processed for LM (30) by standard procedures.

RESULTS

Clinical observations. Calves inoculated with strain 84-5406 had mildly increased rectal temperatures ($0.5 \pm 0.3^\circ\text{C}$) at 36 h PI. The temperature peaked ($0.9 \pm 0.3^\circ\text{C}$) at 48 h PI and fluctuated slightly thereafter for 1 to 3 more days before returning to normal (Fig. 1). Calves became depressed when rectal temperatures were 40.0°C , but none became anorectic. Two of the three principals excreted loose, dark green, mucoid feces at 36 h PI. The feces of one diarrheic calf contained frank blood at 60 h PI, and this calf exhibited tenesmus during defecation (Table 1). One of the two diarrheic calves did not excrete grossly visible blood in the feces, and diarrhea lasted only 24 h. The control calves exhibited no anorexia or depression and excreted formed feces without blood or mucus.

Pathologic observations. Hyperemia of the longitudinal folds of the rectum was noted at necropsy in both the principals and the control calves, but histologic lesions, as observed by LM, were limited to the intestines of the principals and were most severe in the colon and rectum. Gram-negative, rod-shaped bacteria colonized the ileal epithelium in a multifocal pattern, resulting in epithelial cell necrosis with detachment and villous atrophy (Fig. 2). Bacteria diffusely colonized the cecal, colonic, and rectal epithelium (Fig. 3). Epithelial cells colonized by bacteria had eosinophilic cytoplasm and pyknotic nuclei. Necrotic cells sloughed into the intestinal lumen, resulting in multifocal or moderate villous atrophy in the ileum. A minimal acute multifocal inflammatory reaction was present in the lamina propria of the colon and rectum. This was evident by the presence of small clusters of neutrophils and proteinaceous fluid in the lamina propria, with necrosis being limited to epithelial cells. When observed by immunofluorescence microscopy, bacteria on the colonic and rectal mucosae were stained with conjugated anti-O5 serum absorbed with strain G58-1 but not with antiserum absorbed with strain 84-5406 (Fig. 4). Bacteria with specific fluorescence were not observed in the ilea of the principals or in the large or small intestines of the control calves.

As observed by SEM, the colonic and rectal mucosae of the control calves had smooth-surfaced longitudinal folds and patent crypt and goblet cell openings. Epithelial cell junctions were demarcated by microvillous ridges, and api-

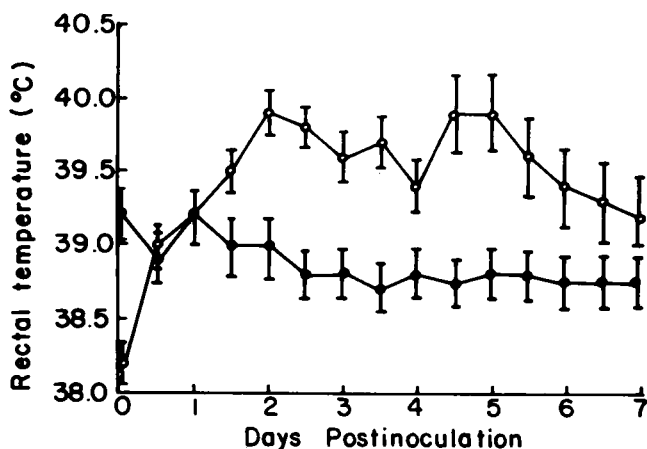


FIG. 1. Mean rectal temperatures \pm standard deviations in calves PI with strain 84-5406 (○) or control inoculum (strain G58-1 or TSB) (●).

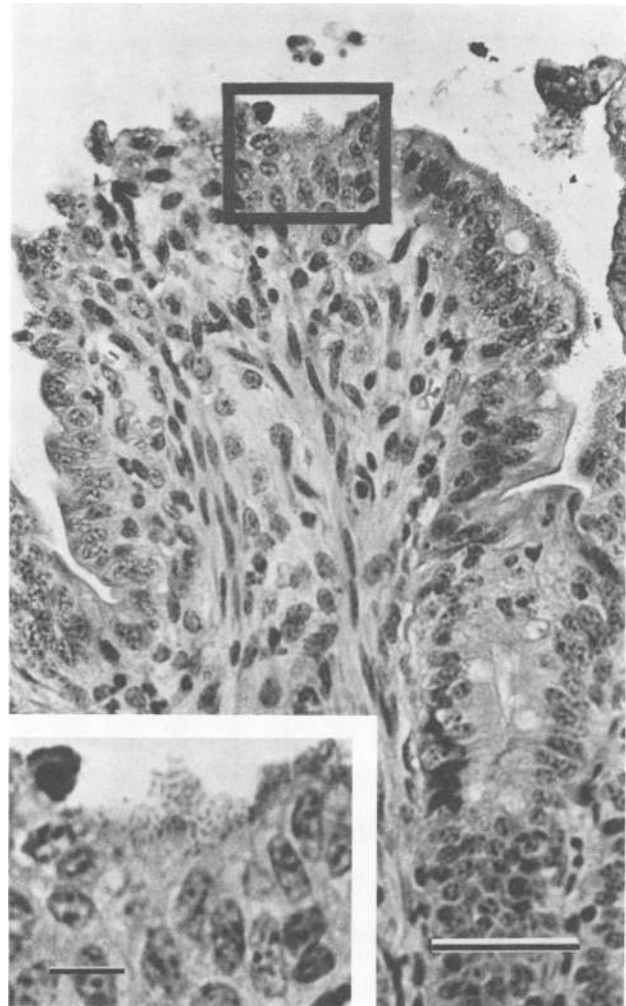


FIG. 2. Light micrograph of ileum from calf inoculated with strain 84-5406. There is multifocal enterocyte necrosis and detachment associated with microcolonies of bacteria (inset) attached to apical cell membranes. Loss of enterocytes has resulted in villous atrophy (as evidenced by a villus: crypt ratio of one in this affected villus). Bar = 100 μm . Inset shows detail of bacterial microcolonies (bar = 5 μm).

cal cell membranes contained short, evenly aligned microvilli that were largely free of adherent debris or microorganisms. The colonic and rectal mucosae of the principals were diffusely colonized with bacteria, and epithelial cells were swollen and detaching from the mucosae. Bacterial colonization and enterocyte swelling distorted the colonic and rectal architecture such that longitudinal folds and crypt openings were obscured. Swelling of enterocytes resulted in the separation of intercellular junctions and detachment of cells from the mucosal surface. Detachment of bacteria from the epithelial surface due to tissue processing revealed cuplike or pedestallike distortions of apical cell membranes, with thickening and elongation of microvilli between the sites of bacterial attachment (Fig. 5). No bacteria were observed by SEM in the ilea of the principals or in the large or small intestines of the control calves.

As observed by TEM, bacteria were intimately attached to apical cell membranes of colonic and rectal enterocytes, resulting in effacement of microvilli. Enterocytes with microvillous effacement had numerous intracytoplasmic

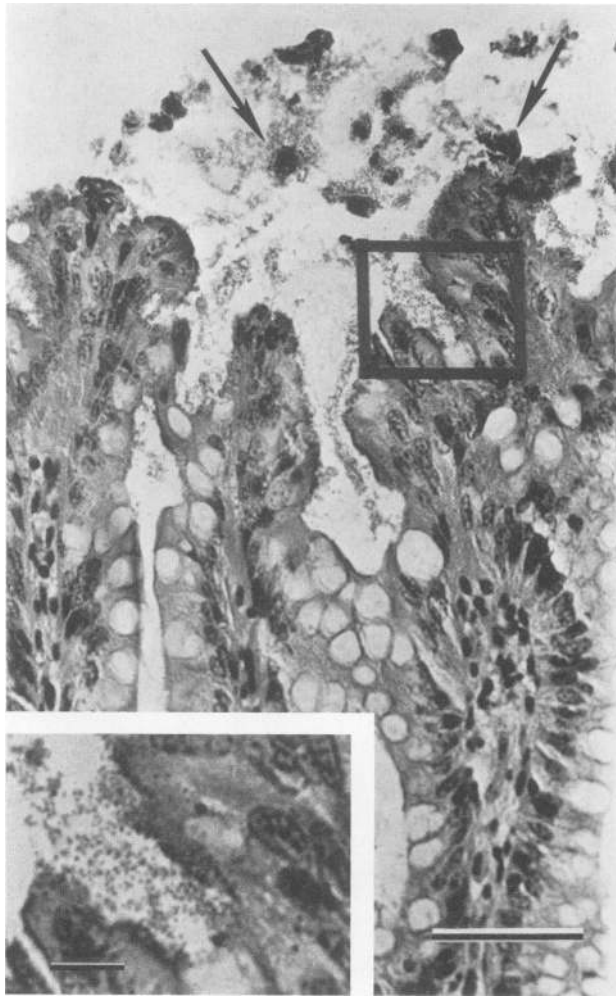


FIG. 3. Light micrograph of rectum from calf inoculated with strain 84-5406. Bacterial colonization is diffuse and extensive, with diffuse enterocyte necrosis and detachment (arrows). Bacterial microcolonies are not observed in crypts. Bar = 100 μm . Inset shows detail of bacterial microcolonies (bar = 5 μm).

vacuoles and often were detached. Cell membranes at the bacterial attachment sites were distorted into pedestal-like evaginations or cuplike invaginations (Fig. 6). The cytoplasm at these sites was homogeneous, except for the presence of vacuoles, and lacked a detectable terminal web. Bacterial surfaces were partially covered with a faint-staining, fibrillar material which interconnected bacteria in the gut lumen but was not discernible at the sites of attachment between bacteria and host cell membranes. Amorphous, electron-dense material was also present near host cell membranes and was associated with the fibrillar strands on bacterial surfaces. No lesions were observed by TEM in the ilea of the principals or in the ilea, colons, or recta of the control calves.

Bacterial cultures. No bacteria were isolated from the preinoculation cultures of the nares or recta of the principals. Pure cultures of O5 serogroup-positive *E. coli* were isolated from intestinal tissues of the principals at necropsy. The organisms were present in moderate numbers in the duodena and jejunum and in large numbers in the ilea, ceca,

colons, and recta. No bacteria were isolated from the preinoculation cultures of the nares or rectum or from the tissues taken at necropsy from the calf that received TSB only. Low numbers of group D fecal streptococci were isolated from the preinoculation cultures of the nares and rectum of the calf inoculated with strain G58-1, apparently from contamination during cesarean section. These organisms, as well as O101 serogroup-positive *E. coli*, were isolated in low numbers from the small and large intestines taken at necropsy. No bacteria or rare colonies of group D fecal streptococci and nontyped *E. coli* were isolated from the parenchymal organs of the calf inoculated with strain G58-1 and from the principals.

Tests for viral contamination. All frozen samples of intestines from the principals and controls were negative for bovine coronaviral, bovine rotaviral, and BVD viral antigens. Buffy-coat lysates and tissues were negative for BVD virus after four passages in cell cultures. All serum samples

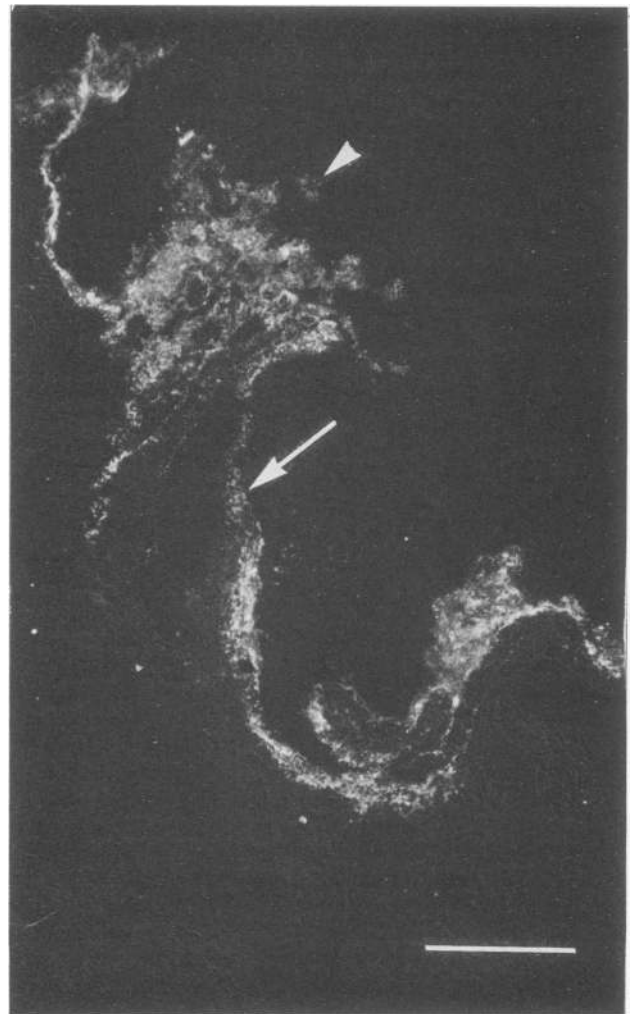


FIG. 4. Dark-field immunofluorescence micrograph of rectum from calf inoculated with strain 84-5406. Bacteria diffusely colonizing the mucosa (arrow) of longitudinal fold show specific fluorescence by indirect fluorescent antibody test with anti-O5 serum (absorbed with strain G58-1) as the primary antibody. Enterocyte detachment (arrowhead) from the tips of folds is outlined by bacteria on cell membranes. Bar = 100 μm .



FIG. 5. Scanning electron micrograph of colon from calf inoculated with strain 84-5406. Bacteria (arrow) cover the apical cell membranes of enterocytes. Cuplike or pedestallike distortions of the apical cell membranes (arrowhead) are present at sites where bacteria were detached during tissue processing. Microvilli between attached bacterial cells are prominent and elongated. Enterocytes are swollen and are in the process of detachment from the mucosal surface. Bar = 1 μ m.

from the principals and controls were negative for anti-BVD virus antibodies by the serum neutralization test.

DISCUSSION

Strain 84-5406 infected gnotobiotic calves and produced diarrhea without ST or LT enterotoxins or invasiveness. Attachment and effacement lesions were observed and were essentially identical to those seen in other cases of EPEC-AEEC (6, 7, 36, 47-50, 52, 59). The lesions in our calves were most severe in the large intestine, similar to another AEEC infection of calves (9, 25) and those of weanling rabbits (6, 7, 11, 48, 52), adult humans (19, 54), and pigs and rabbits infected with human bacterial strains (36). Contrary to what has been observed with infection by AEEC strains pathogenic for humans and neonatal rabbits, strain 84-5406 did not cause duodenal or jejunal lesions (46, 62). Although bacteria were not detected in the ilea of our principals by immunofluorescence microscopy, SEM, or TEM, they were detected by LM. The colonization in the ileum detected by LM was multifocal. Samples for the other tests may have been obtained from noninfected areas. Bacteria within the phagosomes of enterocytes, attachment of bacteria to apical cell membranes of goblet cells, and the presence of electron-dense structures at the bacterial attachment sites are features which have been observed in rabbits and pigs infected with human EPEC-AAEC strains (36), but they were not observed in our calves or in calves infected with the atypical *E. coli* strain S102-9 (25).

SLT is thought to play a role in the pathogenesis of diarrhea in O157:H7 infection (5, 46) analogous to the postulated role of Shiga toxin in shigellosis (27) (i.e., enteric mucosal cell degeneration, inflammatory changes, and diarrhea). The two toxins are considered the same or very similar (5). High levels of SLT are produced by many human EPEC strains (39), whereas avirulent strains of *E. coli* produce only trace amounts of SLT (39, 46). If high-level SLT production is indeed involved in the pathogenesis, strain 84-5406 may be a more suitable model for the study of human EPEC infections involving SLT than strain RDEC-1, inasmuch as RDEC-1 is a low-level producer of SLT (40). However, the development of attachment and effacement lesions does not seem to require high-level SLT production, since strain RDEC-1 is capable of producing the lesions (6, 7). In addition, microvillous effacement is apparently dependent on a phenomenon associated with bacterial attachment, rather than diffusion of a toxin from the gut lumen, since the lesions have been observed only at the attachment sites of EPEC and other bacterial strains (26), and effacement was not reported for rabbits which were given SLT alone (46).

An O157:H7 strain of *E. coli* has recently been associated with food-borne outbreaks and sporadic cases of hemorrhagic colitis in adults in the United States and Canada (45, 53, 54; W. M. Johnson, H. Lior, and G. S. Bezanson, Letter, Lancet i:76, 1983). Experimental infection of neonatal piglets (18) and rabbits (46) has resulted in multifocal ileal and diffuse colonic absorptive enterocyte attachment and efface-

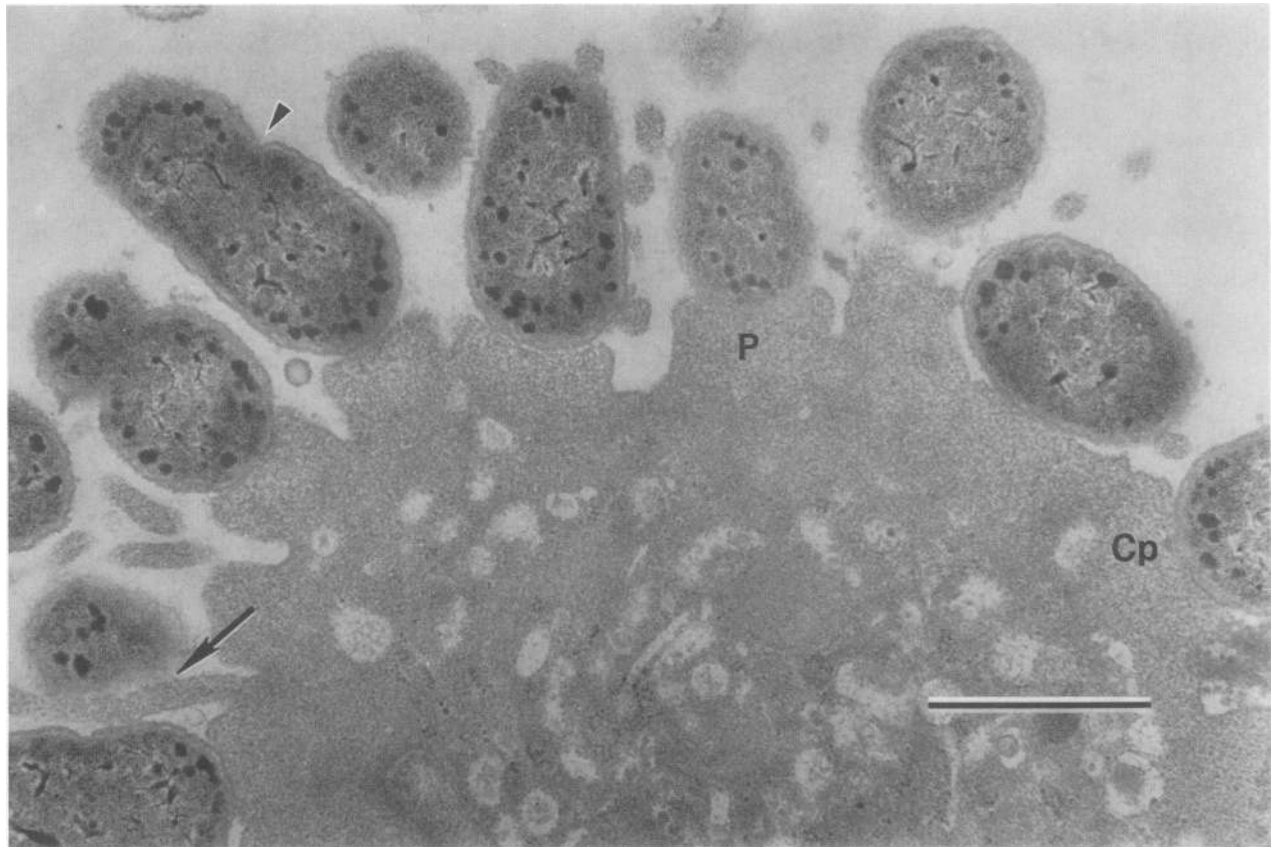


FIG. 6. Transmission electron micrograph of rectum from calf inoculated with strain 84-5406. The attachment of bacteria to this enterocyte results primarily in pedestallike cell membrane evagination (P), with occasional cuplike invagination (Cp). Microvilli between sites of bacterial attachment are elongated (arrow). Some bacteria are in the process of binary fission (arrowhead). The cytoplasm lacks a discernible terminal web and contains numerous vacuoles. Bar = 1 μ m.

ment with diarrhea, features consistent with strain 84-5406 infection. Differences noted were crypt enterocyte attachment and effacement with necrosis and inflammation; pigs also developed submucosal edema, a lesion consistent with radiographic findings in humans (18). Both the O157:H7 and 84-5406 strains produce high levels of SLT. Strain O157:H7 contains an SLT-converting phage (41). A spontaneously released and UV-inducible phage was also found in strain 84-5406; however, further work is needed to determine whether this phage in strain 84-5406 is an SLT converter.

Strain 84-5406 has a number of characteristics in common with strain S102-9, which was isolated from calves in Great Britain (9, 25). These characteristics include (i) possession of the O5 serogroup antigen, (ii) lack of the F5 pilus antigen, (iii) the ability to produce urease, (iv) the inability to produce ST or LT enterotoxins, (v) the inability to be enteroinvasive, and (vi) a preference for colonizing the large bowel epithelium. In addition, infections by the two *E. coli* strains are similar in that they result in attachment and effacement lesions and the presence of blood and mucus in the feces. Concurrent viral infections were observed in naturally occurring diseases caused by either strain. The two isolates may be the same organism. However, strain 84-5406 produces the K4 antigen, whereas strain S102-9 apparently does not. Strain 84-5406 produces high levels of SLT. Whether S102-9 produces SLT has not been reported. Although the intestinal lesions caused by the two strains are essentially identical, the clinical features of disease appear to be some-

what different. Our experimentally infected calves developed elevated temperatures, whereas the British calves did not. The natural disease resulting from infection with strain 84-5406 was found in younger calves than was the case with strain S102-9. In both natural and experimental diseases, calves infected with S102-9 had profound dysentery and had intracryptal organisms. Such was not the case for calves infected with strain 84-5406. However, we killed the calves at the first appearance of blood in the feces; profound dysentery may have occurred later if the disease had been allowed to run its full course. Deaths in naturally occurring cases were probably due to malabsorption-induced dehydration associated with concurrent bacterial and viral infections (1, 63).

Another feature important in the study of EPEC infections is the mechanism of adhesion or attachment. Strain RDEC-1 from rabbits has been used for most studies of EPEC adhesion and is thought to adhere by means of pili (2, 4) and negatively charged surface polysaccharides (4). Electron microscopy procedures in these studies used ruthenium red stains for the detection of negatively charged substances such as polysaccharides and anti-surface polysaccharide serum for the morphologic stabilization of capsular material in thin tissue sections. Fine fibrillar strands on bacterial surfaces which stained with ruthenium red were identified in strain RDEC-1 (4). Although these reagents were not used in our study, fibrillar strands on bacterial surfaces interconnecting bacteria in the microcolonies were observed. These

structures, as well as dense amorphous aggregates near bacterial surfaces, were morphologically very similar to negatively charged polysaccharides of strain RDEC-1. Future studies with strain 84-5406 are necessary to identify the adhesive mechanism.

In conclusion, this study confirms a previous report from England that calves may naturally contract infections similar to those caused by EPEC strains pathogenic to humans or rabbits. Our results suggest that the calf bacterial strains, like some EPEC strains, produce high levels of SLT and cause attachment and effacement lesions in the colonic epithelium of the infected host.

ACKNOWLEDGMENTS

This work was supported by the University of Nebraska-Lincoln Institute of Agriculture and Natural Resources (UNL-IANR) and the UNL-IANR Calf Scours Royalty Fund. The research was conducted under Project 14-025.

We thank M. C. Libal for referring the case, E. D. Erickson and F. A. Osorio for microbiologic assistance, and O. Urban, G. Steppat, B. Clement, T. Bargar, G. Mills, D. Greer, and K. Walbridge for technical assistance.

LITERATURE CITED

- Argenzio, R. A. 1978. Physiology of diarrhea—large intestine. *J. Am. Vet. Med. Assoc.* **173**:667–672.
- Boedecker, E. C., and P. Cheney. 1984. Pili as adherence factors in *Escherichia coli* strain RDEC-1, p. 101–112. In E. C. Boedecker (ed.), *Attachment of organisms to the gut mucosa*, vol. 1. CRC Press, Inc., Boca Raton, Fla.
- Cabrey, E. A., L. N. Brown, T. L. Chow, R. F. Kahrs, D. G. McKercher, L. K. Smithies, and T. W. Tamoglia. 1971. Recommended standard laboratory techniques for diagnosing infectious bovine rhinotracheitis, bovine virus diarrhea and shipping fever (parainfluenza-3). *Proc. U.S. Anim. Health Assoc.* **75**:629–648.
- Cantey, J. R. 1984. The role of negatively charged surface polysaccharide in adherence of *Escherichia coli* strain RDEC-1 to gut epithelial cells in the rabbit, p. 209–219. In E. C. Boedecker (ed.), *Attachment of organisms to the gut mucosa*, vol. 1. CRC Press, Inc., Boca Raton, Fla.
- Cantey, J. R. 1985. Shiga toxin—an expanding role in the pathogenesis of infectious diseases. *J. Infect. Dis.* **151**:766–771.
- Cantey, J. R., and R. K. Blake. 1977. Diarrhea due to *Escherichia coli* in the rabbit: a novel mechanism. *J. Infect. Dis.* **135**:454–462.
- Cantey, J. R., and L. R. Inman. 1981. Diarrhea due to *Escherichia coli* strain RDEC-1 in the rabbit: the Peyer's patch as the initial site of attachment and colonization. *J. Infect. Dis.* **143**:440–446.
- Carter, M. E. 1984. Enterobacteria, p. 92–110. In R. G. Carter (ed.), *Diagnostic procedures in veterinary bacteriology and mycology*, 4th ed. Charles C Thomas, Publisher, Springfield, Ill.
- Chanter, N., J. H. Morgan, J. C. Bridger, G. A. Hall, and D. J. Reynolds. 1984. Dysentery in gnotobiotic calves caused by an atypical *Escherichia coli*. *Vet. Rec.* **114**:71.
- Clausen, C. R., and D. L. Christie. 1982. Chronic diarrhea in infants caused by adherent enteropathogenic *Escherichia coli*. *J. Pediatr.* **100**:358–361.
- Coussemant, W., R. Ducatelle, G. Charlier, L. Okerman, and J. Hoorens. 1984. Pathology of experimental colibacillosis in rabbits. *Zentralbl. Veterinaermed. Reihe B* **31**:64–72.
- Dean, A. G., Y. C. Ching, R. A. Williams, and L. B. Harden. 1972. Test for *E. coli* enterotoxin using infant mice: application in a study of diarrhea in children in Honolulu. *J. Infect. Dis.* **125**:407–411.
- Donta, S. T., and D. M. Smith. 1974. Stimulation of steroidogenesis in tissue culture by enterotoxigenic *Escherichia coli* and its neutralization by specific antiserum. *Infect. Immun.* **9**:500–505.
- Dupont, H. L., S. B. Formal, R. B. Hornick, M. J. Snyder, J. P. Libonati, D. G. Sheahan, E. H. LaBrec, and J. P. Kalas. 1971. Pathogenesis of *Escherichia coli* diarrhea. *N. Engl. J. Med.* **285**:1–9.
- Edelman, R., and M. M. Levine. 1983. Summary of NIAID workshop on enteropathogenic *Escherichia coli*. *J. Infect. Dis.* **147**:1108–1118.
- England, J. J., and D. E. Reed. 1980. Negative contrast electron microscopic techniques for diagnosis of viruses of veterinary importance. *Cornell Vet.* **70**:125–136.
- Francis, D. H. 1983. Use of immunofluorescence, Gram's staining, histology examination, and seroagglutination in the diagnosis of porcine colibacillosis. *Am. J. Vet. Res.* **44**:1884–1888.
- Francis, D. H., J. E. Collins, and J. R. Duimstra. 1986. Infection of gnotobiotic pigs with an *Escherichia coli* O157:H7 strain associated with an outbreak of hemorrhagic colitis. *Infect. Immun.* **51**:953–956.
- Francis, D. H., G. A. Remmers, and P. S. DeZeeuw. 1982. Production of K88, K99, and 987P antigens by *Escherichia coli* cultured on synthetic and complex media. *J. Clin. Microbiol.* **15**:181–183.
- Gaalas, J. 1945. Effect of atmospheric temperature on body temperature and respiration rate of Jersey cattle. *J. Dairy Sci.* **28**:555–563.
- Gentry, M. K., and J. M. Dalrymple. 1980. Quantitative microtiter cytotoxicity assay for *Shigella* toxin. *J. Clin. Microbiol.* **12**:361–366.
- Glantz, P. J. 1971. Serotypes of *Escherichia coli* associated with colibacillosis in neonatal animals. *Ann. N.Y. Acad. Sci.* **176**:67–79.
- Gyles, C. L. 1971. Heat-labile and heat-stable forms of the enterotoxin from *E. coli* strains enteropathogenic for pigs. *Ann. N.Y. Acad. Sci.* **176**:314–322.
- Gyles, C. L., and D. A. Barnum. 1969. A heat-labile enterotoxin from strains of *Escherichia coli* enteropathogenic for pigs. *J. Infect. Dis.* **120**:419–426.
- Hall, G. A., D. J. Reynolds, N. Chanter, J. H. Morgan, K. R. Parsons, T. G. Debney, A. B. Bland, and J. C. Bridger. 1985. Dysentery caused by *Escherichia coli* (S102-9) in calves: natural and experimental disease. *Vet. Pathol.* **22**:156–163.
- Johnson, E., and S. W. Barthold. 1979. The ultrastructure of transmissible murine colonic hyperplasia. *Am. J. Pathol.* **97**:291–313.
- Keusch, G. T., G. F. Grady, A. Takeuchi, and H. Sprinz. 1972. The pathogenesis of shigella diarrhea. II. Enterotoxin-induced acute enteritis in the rabbit ileum. *J. Infect. Dis.* **126**:92–95.
- Konowalchuk, J., J. I. Speirs, and S. Stavric. 1977. Vero response to a cytotoxin of *Escherichia coli*. *Infect. Immun.* **18**:775–779.
- Levine, M. M., D. R. Nalin, R. B. Hornick, E. J. Bergquist, D. H. Waterman, C. R. Young, S. Sotman, and B. Rowe. 1978. *Escherichia coli* strains that cause diarrhea but do not produce heat-labile or heat-stable enterotoxins and are non-invasive. *Lancet* **i**:1119–1122.
- Luna, L. G. (ed.). 1968. *Manual of histologic staining methods of the Armed Forces Institute of Pathology*, 3rd ed., p. 1–46. McGraw-Hill Book Co., New York.
- Mebus, C. A., E. L. Stair, M. B. Rhodes, and M. J. Twiehaus. 1973. Pathology of neonatal calf diarrhea induced by a coronavirus-like agent. *Vet. Pathol.* **10**:45–64.
- Mebus, C. A., E. L. Stair, N. R. Underdahl, and M. J. Twiehaus. 1971. Pathology of neonatal calf diarrhea induced by a reo-like virus. *Vet. Pathol.* **8**:490–505.
- Mebus, C. A., N. R. Underdahl, and M. J. Twiehaus. 1972. Isolation unit used in studies on neonatal calf diarrhea. *Am. J. Vet. Res.* **33**:2335–2340.
- Moon, H. W., R. E. Isaacson, and J. Pohlenz. 1979. Mechanisms of association of enteropathogenic *Escherichia coli* with intestinal epithelium. *Am. J. Clin. Nutr.* **32**:119–127.
- Moon, H. W., D. K. Sorensen, and J. H. Sautter. 1966. *Escherichia coli* infection of the ligated intestinal loop of the newborn pig. *Am. J. Vet. Res.* **27**:1317–1325.
- Moon, H. W., S. C. Whipp, R. A. Argenzio, M. M. Levine, and

- R. A. Giannella. 1983. Attaching and effacing activities of rabbit and human enteropathogenic *Escherichia coli* in pig and rabbit intestines. *Infect. Immun.* **41**:1340-1351.
37. Neter, E. 1965. Enteritis due to enteropathogenic *Escherichia coli*. *Am. J. Dig. Dis.* **10**:883-886.
 38. O'Brien, A. D., and G. D. Laveck. 1982. Immunochemical and cytotoxic activities of *Shigella dysenteriae* 1 (Shiga) and Shiga-like toxins. *Infect. Immun.* **35**:1151-1154.
 39. O'Brien, A. D., G. D. LaVeck, D. E. Griffin, and M. R. Thompson. 1980. Characterization of *Shigella dysenteriae* 1 (Shiga) toxin purified by anti-Shiga toxin affinity chromatography. *Infect. Immun.* **30**:170-179.
 40. O'Brien, A. D., G. D. LaVeck, M. R. Thompson, and S. B. Formal. 1982. Production of *Shigella dysenteriae* type 1-like cytotoxin by *Escherichia coli*. *J. Infect. Dis.* **146**:763-769.
 41. O'Brien, A. D., J. W. Newland, S. F. Miller, and R. K. Holmes. 1984. Shiga-like toxin-converting phages from *Escherichia coli* strains that cause hemorrhagic colitis or infantile diarrhea. *Science* **226**:694-696.
 42. Ogawa, H., A. Nakamura, and R. Sakazaki. 1968. Pathogenic properties of "enteropathogenic" *Escherichia coli* from diarrheal children and adults. *Jpn. J. Med. Sci. Biol.* **21**:333-349.
 43. Okerman, L., P. Lintermans, W. Coussement, and L. A. Devriese. 1982. *Escherichia coli* ne produisant pas d'enterotoxine comme agent d'enterite chez le lapin avant le serrage. *Recl. Med. Vet. Ec. Alfort* **158**:467-472.
 44. Orskov, F., and I. Orskov. 1984. Serotyping of *Escherichia coli*, p. 43-112. In T. Bergan (ed.), *Methods in microbiology*, vol. 14. Academic Press, Inc. (London), Ltd., London.
 45. Pai, C. H., R. Gordon, H. V. Sims, and L. E. Bryan. 1984. Sporadic cases of hemorrhagic colitis associated with *Escherichia coli* O157:H7. *Ann. Intern. Med.* **101**:738-742.
 46. Pai, C. H., J. K. Kelley, and G. L. Meyers. 1986. Experimental infection of infant rabbits with verotoxin-producing *Escherichia coli*. *Infect. Immun.* **51**:16-23.
 47. Peeters, J. E., G. J. Charlier, and P. H. Halen. 1984. Pathogenicity of attaching effacing enteropathogenic *Escherichia coli* isolated from diarrheic suckling and weanling rabbits for newborn rabbits. *Infect. Immun.* **46**:690-696.
 48. Peeters, J. E., G. J. Charlier, and R. Raeymakers. 1985. Scanning and transmission electron microscopy of attaching effacing *Escherichia coli* in weanling rabbits. *Vet. Pathol.* **22**:54-59.
 49. Peeters, J. E., P. Pohl, and G. Charlier. 1984. Infectious agents associated with diarrhea in commercial rabbits: a field study. *Ann. Rech. Vet.* **15**:24-29.
 50. Peeters, J. E., P. Pohl, L. Okerman, and L. A. Devriese. 1984. Pathogenic properties of *Escherichia coli* strains isolated from diarrheic commercial rabbits. *J. Clin. Microbiol.* **20**:34-39.
 51. Polotsky, Y. E., E. M. Dragunskaya, V. G. Seliverstova, T. A. Avdeeva, M. G. Chakhutinskaya, I. Ketyi, A. Vertinyi, B. Ralovich, L. Emody, I. Malovics, N. V. Safonova, E. S. Snigirevskaya, and E. I. Karyagina. 1977. Pathogenic effect of enterotoxigenic *Escherichia coli* and *Escherichia coli* causing infantile diarrhea. *Acta Microbiol. Acad. Sci. Hung.* **24**:221-236.
 52. Prescott, J. F. 1978. *Escherichia coli* and diarrhea in the rabbit. *Vet. Pathol.* **15**:237-248.
 53. Remis, R. S., K. L. MacDonald, L. W. Riley, N. D. Puhr, J. G. Wells, B. R. Davis, P. A. Blake, and M. L. Cohen. 1984. Sporadic cases of hemorrhagic colitis associated with *Escherichia coli* O157:H7. *Ann. Intern. Med.* **101**:624-626.
 54. Riley, L. W., R. S. Remis, S. D. Helgerson, H. B. McGee, J. G. Wells, B. R. Davis, R. J. Hebert, E. S. Olcott, L. M. Johnson, N. T. Hargrett, P. A. Blake, and M. L. Cohen. 1983. Hemorrhagic colitis associated with a rare *Escherichia coli* serotype. *N. Engl. J. Med.* **308**:681-685.
 55. Rothbaum, R., A. J. McAdams, R. Gianella, and J. C. Partin. 1982. A clinicopathologic study of enterocyte-adherent *Escherichia coli*: a cause of protracted diarrhea in infants. *Gastroenterology* **83**:441-454.
 56. Sereny, B. 1955. Experimental shigella keratoconjunctivitis: a preliminary report. *Acta Microbiol. Acad. Sci. Hung.* **2**:293-296.
 57. Smith, H. W., and C. L. Gyles. 1970. The relationship between two apparently different enterotoxins produced by enteropathogenic strains of *Escherichia coli* of porcine origin. *J. Med. Microbiol.* **3**:387-401.
 58. Strockbine, N. A., L. R. M. Marques, R. K. Holmes, and A. D. O'Brien. 1985. Characterization of monoclonal antibodies against Shiga-like toxin from *Escherichia coli*. *Infect. Immun.* **50**:695-700.
 59. Takeuchi, A., L. R. Inman, P. D. O'Hanley, J. R. Cantey, and W. B. Lushbaugh. 1978. Scanning and transmission electron microscopic study of *Escherichia coli* O15 (RDEC-1) enteric infection in rabbits. *Infect. Immun.* **19**:686-694.
 60. Thurman, J. C., and G. J. Benson. 1981. Anesthesia in ruminants and swine, p. 58-81. In J. L. Howard (ed.), *Current veterinary therapy: food animal practice*. The W. B. Saunders Co., Philadelphia.
 61. Torres-Medina, A. 1981. Morphologic characteristics of the epithelial surface of aggregated lymphoid follicles (Peyer's patches) in the small intestine of newborn gnotobiotic calves and pigs. *Am. J. Vet. Res.* **42**:232-236.
 62. Ulshen, M. H., and J. L. Rollo. 1980. Pathogenesis of *Escherichia coli* gastroenteritis in man—another mechanism. *N. Engl. J. Med.* **302**:99-101.
 63. Whipp, S. C. 1978. Physiology of diarrhea—small intestines. *J. Am. Vet. Med. Assoc.* **173**:662-666.