

 Open access • Journal Article • DOI:10.1177/1071100714552480

## Natural history of nonoperatively treated osteochondral lesions of the talus.

— [Source link](#) 

Georg Klammer, Gerardo Juan Maquieira, Silke Spahn, Vanessa Vigfusson ...+2 more authors

**Institutions:** University of Zurich

**Published on:** 01 Jan 2015 - Foot & Ankle International (SAGE Publications)

**Topics:** Ankle and Magnetic resonance imaging

Related papers:

- [Treatment of osteochondral lesions of the talus: a systematic review](#)
- [Osteochondral defects in the ankle: why painful?](#)
- [Osteochondral lesion of the talus: is there a critical defect size for poor outcome?](#)
- [Arthroscopic Treatment of Chronic Osteochondral Lesions of the Talus Long-term Results](#)
- [Transchondral fractures \(osteochondritis dissecans\) of the talus.](#)

Share this paper:    

View more about this paper here: <https://typeset.io/papers/natural-history-of-nonoperatively-treated-osteochondral-2vl9hfxria>



**University of  
Zurich**<sup>UZH</sup>

**Zurich Open Repository and  
Archive**

University of Zurich  
University Library  
Strickhofstrasse 39  
CH-8057 Zurich  
[www.zora.uzh.ch](http://www.zora.uzh.ch)

---

Year: 2015

---

## **Natural history of nonoperatively treated osteochondral lesions of the talus.**

Klammer, Georg ; Maquieira, Gerardo J ; Spahn, Silke ; Vigfusson, Vanessa ; Zanetti, Marco ;  
Espinosa, Norman

**Abstract:** **BACKGROUND** We hypothesized that patients undergoing nonoperative treatment for asymptomatic or minimally symptomatic osteochondral lesions of the talus (OLTs) would not deteriorate clinically or radiologically over time. **METHODS** Forty-eight patients (mean age = 48 years; range, 13-78 years) with an OLT confirmed by magnetic resonance imaging (MRI) who had not undergone ankle joint surgery were retrospectively reviewed. All patients were evaluated after a minimum follow-up of 2 years (mean = 52 months; range, 27-124 months). All patients filled out an individual questionnaire and underwent a physical and radiographic assessment (radiograph and hindfoot MRI). **RESULTS** At final follow-up, 43 ankles (86%) in 41 patients were pain-free (visual analogue scale [VAS] 0, n = 12) or less painful (VAS 1-3, n = 31). Radiographically, osteoarthritis was absent in 47%, and grade 1 and 2 osteoarthritis each were found in 27% (van Dijk classification). Magnetic resonance imaging revealed no substantial progression in staging or lesion size. Pain at time of follow-up correlated with the depth of the lesion at initial MRI ( $P < .05$ ) and with subchondral cyst formation and presence or change of bone marrow edema at follow-up MRI ( $P < .05$ ). **CONCLUSION** Minimally symptomatic OLTs did not appear to progress or worsen over time when treated nonoperatively.

DOI: <https://doi.org/10.1177/1071100714552480>

Posted at the Zurich Open Repository and Archive, University of Zurich

ZORA URL: <https://doi.org/10.5167/uzh-104578>

Journal Article

Accepted Version

Originally published at:

Klammer, Georg; Maquieira, Gerardo J; Spahn, Silke; Vigfusson, Vanessa; Zanetti, Marco; Espinosa, Norman (2015). Natural history of nonoperatively treated osteochondral lesions of the talus. *Foot and Ankle International*, 36(1):24-31.

DOI: <https://doi.org/10.1177/1071100714552480>

# Foot & Ankle International

<http://fai.sagepub.com/>

---

## Natural History of Nonoperatively Treated Osteochondral Lesions of the Talus

Georg Klammer, Gerardo J. Maquieira, Silke Spahn, Vanessa Vigfusson, Marco Zanetti and Norman Espinosa

*Foot Ankle Int* published online 6 October 2014

DOI: 10.1177/1071100714552480

The online version of this article can be found at:

<http://fai.sagepub.com/content/early/2014/10/06/1071100714552480>

---

Published by:



<http://www.sagepublications.com>

On behalf of:



[American Orthopaedic Foot & Ankle Society](#)

**Additional services and information for *Foot & Ankle International* can be found at:**

**Email Alerts:** <http://fai.sagepub.com/cgi/alerts>

**Subscriptions:** <http://fai.sagepub.com/subscriptions>

**Reprints:** <http://www.sagepub.com/journalsReprints.nav>

**Permissions:** <http://www.sagepub.com/journalsPermissions.nav>

>> [OnlineFirst Version of Record](#) - Oct 6, 2014

[What is This?](#)

# Natural History of Nonoperatively Treated Osteochondral Lesions of the Talus

Foot & Ankle International

1-8

© The Author(s) 2014

Reprints and permissions:

sagepub.com/journalsPermissions.nav

DOI: 10.1177/1071100714552480

fai.sagepub.com

Georg Klammer, MD<sup>1</sup>, Gerardo J. Maquieira, MD<sup>1</sup>, Silke Spahn, MD<sup>1</sup>,  
Vanessa Vigfusson, MD<sup>1</sup>, Marco Zanetti, MD<sup>1</sup>, and Norman Espinosa, MD<sup>1</sup>

## Abstract

**Background:** We hypothesized that patients undergoing nonoperative treatment for asymptomatic or minimally symptomatic osteochondral lesions of the talus (OLTs) would not deteriorate clinically or radiologically over time.

**Methods:** Forty-eight patients (mean age = 48 years; range, 13-78 years) with an OLT confirmed by magnetic resonance imaging (MRI) who had not undergone ankle joint surgery were retrospectively reviewed. All patients were evaluated after a minimum follow-up of 2 years (mean = 52 months; range, 27-124 months). All patients filled out an individual questionnaire and underwent a physical and radiographic assessment (radiograph and hindfoot MRI).

**Results:** At final follow-up, 43 ankles (86%) in 41 patients were pain-free (visual analogue scale [VAS] 0, n = 12) or less painful (VAS 1-3, n = 31). Radiographically, osteoarthritis was absent in 47%, and grade 1 and 2 osteoarthritis each were found in 27% (van Dijk classification). Magnetic resonance imaging revealed no substantial progression in staging or lesion size. Pain at time of follow-up correlated with the depth of the lesion at initial MRI ( $P < .05$ ) and with subchondral cyst formation and presence or change of bone marrow edema at follow-up MRI ( $P < .05$ ).

**Conclusion:** Minimally symptomatic OLTs did not appear to progress or worsen over time when treated nonoperatively.

**Level of Evidence:** Level IV, case series.

**Keywords:** natural history, nonoperative, osteochondral lesion, talus

## Introduction

Many published articles deal with operative treatment strategies, but there is a paucity of available studies evaluating the outcome of nonoperative treatment in the presence of symptomatic osteochondral lesions of the talus (OLTs).<sup>2,7,12,15,18</sup> The natural history of OLTs is not well described. It is unclear whether these lesions tend to progress in terms of size and symptoms or lead to joint deterioration.<sup>2-4,9,12,17-19</sup> The purpose of this study was to describe the natural history of OLTs in a cohort of patients treated nonoperatively.

## Methods

Between 1995 and 2006, all patients who were diagnosed with an OLT were identified. For study eligibility, patients needed a magnetic resonance image (MRI) that confirmed OLT at first visit and a minimum follow-up of 2 years. In addition, patients were included only if their OLT had a minimum size of 4 mm in the coronal and/or sagittal plane of the MRI. All patients with a medical history of previous or scheduled ankle joint surgery were excluded.

Our institutional review board granted study protocol approval before commencement of study procedures. All patients who met the study criteria were invited to participate in a follow-up visit, including clinical and imaging assessments (radiograph and MRI).

Between 1995 and 2006, a total of 150 patients with OLTs were identified. Of these, 18 patients underwent ankle joint surgery before the first visit at our institution and, thus, were excluded. Thirty-four of the remaining 132 patients (26%) were treated operatively for OLT before starting the study. Of these patients, 30 patients underwent surgery within the first 6 months after the first visit because they were referred only after conservative treatment had failed; only 4 patients had attempted prolonged conservative treatment and had been operated on later. Thus, at the time of patient selection, 98 patients undergoing nonoperative

<sup>1</sup>Balgrist Hospital, University of Zurich, Zurich, Switzerland

### Corresponding Author:

Norman Espinosa, MD, Balgrist Hospital, University of Zurich,  
Forchstrasse 340, 8008, Zurich, Switzerland.

Email: norman.espinosa@balgrist.ch

**Table 1.** Demographic Factors, History of Trauma, and Family History.<sup>a</sup>

Demographic Factor	No. (%) of Patients/ Ankles and → Statistical Correlation to VAS Groups
<b>Age/sex</b>	
Age distribution at follow-up [range], y	48 [13-78] → <i>P</i> = .70
Sex, male:female	56%:44% → <i>P</i> = .48
<b>Location</b>	
Affected side, left:right:bilateral	37.9%:57.9%:4.2%
<b>Body mass index (N = 48 patients), kg/m<sup>2</sup></b>	
Mean [range]	26.6 [18.7-40.6]
Normal	21 (43.8%)
Overweight	14 (29.2%)
Obese	13 (27.2%)
<b>History of trauma (N = 48 patients)</b>	
None	5 (10.4%)
At least 1	43 (89.6%)
Single (N = 43 patients)	15 (34.9%)
Repetitive (N = 43 patients)	28 (65.1%)
<b>Positive family history of OLT (N = 48 patients)</b>	
	0

Abbreviations: OLT, osteochondral lesion of the talus; VAS, visual analogue scale.

<sup>a</sup>Where reasonable, *P* values of statistical correlation to grouped VAS pain levels (at time of follow-up) are given.

treatment for OLT were identified. Of these, 20 (20%) had no MRI at first visit, and 30 (31%) were not willing or able to participate in the study. Finally, 50 feet in 48 patients met the inclusion criteria and were enrolled in the study.

The main indication for MRI was pain at the ankle joint (43 patients, 7 with additional instability). In 5 patients, an extra-articular pathology was supposed (in 4 patients, Achilles tendinopathy was confirmed; in 1 patient, a stress fracture of the cuneiform bone was found). There were 21 female patients (44%) and 27 male patients (56%), with a mean age at follow-up of 48 years (range, 13-78 years). The right and left ankles were involved in 28 and 18 patients, respectively. Two patients (4.2%) had bilateral occurrence. The average follow-up was 52 months (range, 27-124 months) (Table 1).

### Clinical Evaluation

At the time of follow-up, a standardized protocol was used for clinical evaluation. By means of a questionnaire, we obtained data regarding history of pain (as assessed by the visual analogue scale [VAS]), limitations of daily living, recreational and sports activities, as well as profession. In addition, any use of orthopedic aids was noted. Information

on risk factors was gathered, including family history, trauma, or subjective ankle instability, and body mass index (BMI). Patients were grouped based on their BMI, according to the World Health Organization classification adopted in 1995 (normal, BMI 18.5 to 24.9 kg/m<sup>2</sup>; overweight, BMI 25 to 29.9 kg/m<sup>2</sup>; obese, BMI > 30 kg/m<sup>2</sup>).<sup>24</sup>

During clinical examination, special attention was paid to local swelling or atrophy, hindfoot alignment, locus of tenderness, objective ankle stability and range of motion of the ankle, and subtalar joint.

Pain at time of follow-up was evaluated using the VAS. To assess the amount of pain at follow-up, results of the VAS were subgrouped as follows: no pain (VAS 0), mild (VAS 1-3), moderate (VAS 4-6), severe (VAS 7-9), or excruciating pain (VAS 10).

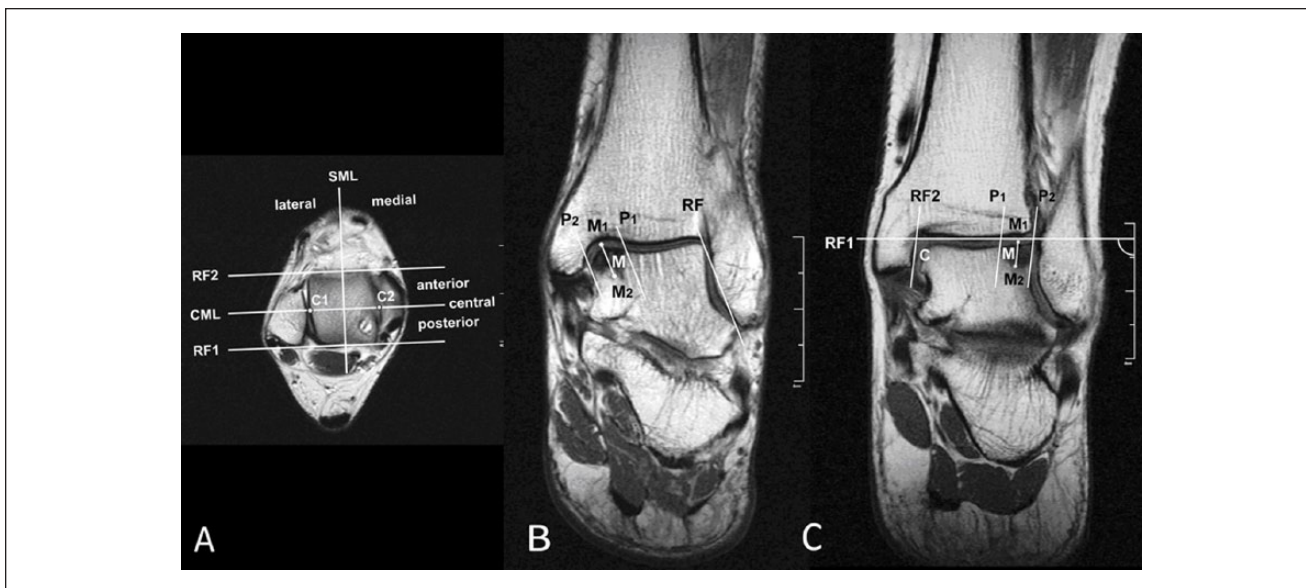
### Imaging Studies

During follow-up, all patients underwent a standardized radiographic workup including conventional imaging (weight-bearing anteroposterior, Mortise and lateral views of the hindfoot) and hindfoot MRI. The localization of OLT was assessed and ankle joint degeneration staged according to van Dijk's classification.<sup>22</sup>

Magnetic resonance imaging was chosen because of its high sensitivity and specificity<sup>10,23</sup> and as it was typically obtained prior to computed tomography (CT) in cases of unexplained ankle pain.<sup>13</sup> Therefore, further CT scans were not performed in the majority of patients who opted for conservative treatment. Magnetic resonance images were obtained with the patient in supine position, with the affected ankle in neutral position (MRI: Symphony 1.5-T; Siemens Medical Systems, Erlangen, Germany). The size and locus of any OLT; cartilaginous defects; subchondral cyst formation; bone marrow edema; and any additional hindfoot pathologies were assessed by a musculoskeletal radiologist who specialized in foot and ankle disorders, with 16 years of experience.

The lesion size was determined in 3 planes on T1-weighted images, assessing the diameter of the hypointense region as indicated in Figure 1 (Software: PACS Cerner Pro Vision Web, Idstein, Germany). In a pilot study, this method was tested for reliability by 3 independent raters (interobserver correlation, 0.90-0.94). The coronal plane on initial MRI with the largest diameter of the lesion was set as the reference. This allowed the use of the same plane for the determination of lesion sizes on the follow-up MRIs.

The lesions were staged according to the classification described by Anderson et al<sup>1</sup>: stage 1, subchondral trabecular compression; stage 2, incomplete separation of the fragment; stage 2A, formation of subchondral cysts; stage 3, unattached, undisplaced fragments; stage 4, displaced fragments.



**Figure 1.** Determination of location and lesion size on coronal and axial T1-weighted magnetic resonance images (MRIs). (A) Localization of osteochondral lesions of the talus (OLTs) on axial planes: For the classification of the localization, the axial slice with the largest diameter of the lesion was chosen. Tangential lines to the anterior and posterior articular borders of the talus were drawn as reference lines (RF1 and RF2), allowing the definition of the midline (CML). The rectangular (AP) through the mediolateral midpoint on CML divided the field in 4 quadrants. Lesions coming to lie on the rectangular midline (AP) were defined as central lesions (posteromedially located lesion). (B) Lesion size of medial OLT on coronal planes: A tangent line to the intact lateral talar articular surface was chosen as the reference line (RF). The mediolateral dimension of the lesion was determined by the distance between 2 lines (P1/P2) parallel to the RF at the lateral and medial borders of the hypointense zone. To measure lesion depth, a midline parallel line was drawn between P1 and P2 and the distance between the cartilage border (M1) and the end of the hypointense zone (M2) was noted. For the sagittal diameter of the lesion, the most anterior and posterior coronal MRI plane was selected, in which the lesion was visible, and the diameter calculated by the number of planes and the interplane distance (3 mm). (C) Lesion size of lateral OLT on coronal planes: As the reference line, a perpendicular line to the cm mark was drawn through the most inferior point of the tibial pylon (RF1). First, a 90 degree angled reference line to the cm mark line at the right margin of the images was drawn tangentially to the most distal point of the tibia (RF1). A second reference line (RF2) was defined by the point (C) where reference line 1 (RF1) meets the most distal bony point of the medial malleolar joint surface. The distance between the parallel lines to RF2 through the most medial (M1) and lateral (M2) points of the hypointense area defined the mediolateral diameter of the lesion. The sagittal diameter was measured by the same method for medial OLT as outlined above.

The lesions and their evolution over time were classified according to cartilage defect size and rated as unchanged, extended, or regressive.

### Statistical Analysis

Pain levels (VAS groups) at follow-up were tested for correlations with the clinical findings at the follow-up visit (ie, BMI, hindfoot edema, calf atrophy, hindfoot axis, range of motion, and ankle stability) and with the lesion characteristics on MRI at the initial and the follow-up visits (ie, OLT stage, bone cyst formation, bone marrow edema, and size). All calculations were performed by 1 of the coauthors in collaboration with a biostatistician. Standard statistical software (SPSS for Windows; SPSS Inc, Chicago, IL) was used for all analysis. Recorded values were indicated as means with their ranges. A 1-way analysis of variance (ANOVA) was used first to identify

differences among the continuous variables, followed by a post hoc analysis of group means using an unpaired Student *t* test. For the calculation of the correlation value, both Pearson and Spearman tests were performed. The level of significance was set at .05.

## Results

### Patient Questionnaire and Clinical Examination

These results are presented in detail in Tables 1 and 2.

A traumatic event prior to the onset of ankle pain was recalled by 43 of the 48 patients (89.6%). Of these, 15 (34.9%) patients reported a single event, whereas 28 patients (65.1%) reported multiple traumas to their ankle joints. Among the 43 patients with a traumatic history, the most frequent mechanism reported was ankle sprain (21 patients, 48.8%), followed by hyperflexion (5 patients,

**Table 2.** Subjective and Objective Clinical Findings at Time of Follow-up.<sup>a</sup>

Clinical Factor	No. (%) of Patients/Ankles and → Statistical Correlation to VAS Groups
Pain: VAS scales, evolution, and localization	
Grouped pain levels (N = 50 ankles)	
None (VAS 0)	12 (24.0)
Mild (VAS 1-3)	31 (62.0)
Moderate (VAS 4-6)	6 (12)
Severe (VAS 7-9)	1 (2)
Excruciating (VAS 10)	0
Subjective pain evolution since initial visit (N = 50 ankles)	
Decreased	33 (66)
Unchanged	11 (22)
Increased	6 (12)
Joint locking	5 (10) → P = .34
Subjective ankle instability	24 (48) → P = .70
Use of orthopaedic aids (N = 48 patients)	
Insoles	9 (18.8)
Shoe modifications	5 (10.4)
Crutches	3 (6.3)
Limitations (N = 48 patients)	
Activities of daily living	11 (22.9)
Recreational or sports activities	28 (58.3)
Restrictions in activities during work (N = 48 patients)	
None	43 (89.6)
Limitations requiring a change of workplace	2 (4.2)
Workers' compensation due to foot problem	2 (4.2)
Workers' compensation due to other reason	1 (2.1)
Any hindfoot swelling	6 (12) → P = .35
Calf atrophy	0
Hindfoot axis	→ P = .77
Valgus (> 7 degrees valgus)	7 (14)
Physiologic (0-7 degrees valgus)	39 (78)
Varus (< 0 degrees)	3 (6)
Ankle ROM (compared to contralateral side)	→ P = .82
Symmetric	36 (72)
Increased	3 (6)
Decreased	11 (22)
Subtalar ROM (compared to contralateral side)	→ P = .54
Symmetric	32 (64)
Increased	9 (18)
Decreased	9 (18)
Objective ankle stability	→ P = .89
Positive anterior drawer test only	4 (8)
Positive lateral talar tilt test only	9 (18)
Positive anterior drawer and lateral talar tilt test	6 (12)
Tenderness at ankle joint (N = 50 ankles)	28 (56)
Other hindfoot tenderness (N = 50 ankles)	
Subtalar joint	9 (18)
Sinus tarsi	4 (8)
Achilles tendon insertion	2 (4)
Plantar fascia origin	1 (2)

Abbreviations: ROM, range of motion; VAS, visual analogue scale.

<sup>a</sup>Grouped VAS pain levels are highlighted in gray. Where reasonable, P values of statistical correlation to the grouped VAS pain levels are given.

12%), hyperextension (2 patients, 4.7%), and a combination of pronation-supination trauma (1 patient, 2.3%). Fourteen patients could not exactly recall the mechanism of trauma (falls from a height or on stairs; accidents while bicycling, playing volleyball, hiking, driving a car, or horseback riding). Five patients did not report any trauma (Table 1).

**Pain.** Pain evolution from the initial presentation was rated as unchanged by 10 patients (11 ankles, 22%; including 2 patients who remained pain-free [2 ankles, 4%]), as decreased or vanished by 33 patients (33 ankles, 66%), and as increased by 5 patients (6 ankles, 12%). Twelve patients (12 feet, 24%) were pain-free at the follow-up visit. The location of ankle tenderness corresponded to the location of the OLT in only 15 feet (30%).

Whereas 4 patients (5 feet, 10%) reported occasional joint locking, another 2 (4%) reported that the locking phenomena had disappeared by the time of the follow-up visit. Twenty-four ankles (48%) in 23 patients were subjectively considered unstable (Table 2).

**Activities of daily living and work.** Eleven of the 48 patients (22.9%) reported limitations in activities of daily living and another 28 patients (58.3%) during recreational or sports activities. Forty-three patients could pursue their work without limitations; 5 patients (10.4%) had some restrictions, leading to a change of profession in 1 and frequent changes of the place of employment in another. Two patients received workers' compensation related to their foot problem, and a third, related to a nonskeletal disease (Table 2).

### Conventional Radiography

Radiographs with sufficient quality to assess the grade of ankle osteoarthritis were available in 21 ankles at the initial visit and in 49 ankles at the time of follow-up. The mean follow-up time was 50 months (range, 26-120 months). Of the 21 ankles at initial visit, 13 showed no signs of osteoarthritis (van Dijk grade 0), 6 patients presented with osteophyte formation without joint space narrowing (grade 1), and 1 presented with subtotal joint space narrowing or deformation of the joint space (grade 2). At the time of follow-up, only 1 patient showed a progression into a grade 1 osteoarthritis, whereas all the others remained unchanged. Considering the radiographic assessment of all 49 ankles at the time of follow-up, osteoarthritis was absent in 47%, and grade 1 and 2 osteoarthritis each were found in 27%. Whereas in 3 cases, OLT was evident on radiographs between the initial and the follow-up visits, in 2 cases (a 15-year-old girl and a 48-year-old man), the OLT had radiologically vanished.

**Table 3.** Localization of the Osteochondral Lesions on the Talar Dome on Magnetic Resonance Image.

Location of the Osteochondral Lesions on the Talar Dome (N = 50)			
	Medial	Central	Lateral
Anterior	4 (8%)	0	4 (8%)
Central	12 (24%)	1 (2%)	8 (16%)
Posterior	16 (32%)	0	5 (10%)

## MRI

The localizations of the osteochondral lesions on the talar dome are presented in Table 3. Lesion characteristics at initial and follow-up MRI as well as the change over time are summarized in Table 4. Eighty-four percent of the lesions remained unchanged at the follow-up visit. Six lesions (12%) showed a progression of 1 stage (in 5 cases, from stage 1 to stage 2A lesion; in 1 case, from stage 2 to stage 2A). In contrast, 2 lesions (4%) improved (1 complete remission from a stage 1 lesion, and in the other case, from a stage 2A to a stage 1 lesion).

The width of the lesion (mediolateral diameter) decreased in 68% of the cases by an average of 2 mm (range, 0.03-9.18 mm): The depth (craniocaudal diameter) decreased in 80% by 1.7 mm (range, 0.02-6.41 mm) and the length (anteroposterior diameter) in 50% by 4 mm (range, 0.30-19.2 mm). An average width increase of 1 mm (range, 0.20-3.40 mm) was observed in 32%, a depth increase by 1.1 mm (range, 0.03-2.5 mm) in 20%, and a length increase by 2.8 mm (range, 0.6-5.9 mm) in 45%.

Associated pathologies observed on the follow-up MRIs are summarized in Table 4. Most commonly, ruptures or scars of the lateral ankle ligaments could be found, indicating prior ankle sprains.

## Correlations With Pain Scales at Follow-up

No clinical variable at the follow-up visit showed a statistically significant correlation with the level of pain at the follow-up visit (Tables 1 and 2). Among all radiographic criteria, as observed on the initial MRI, only the depth of the lesion reached statistical significance ( $P < .05$ ), possibly allowing the prediction of pain evolution in a patient with OLT (Table 4).

At the time of follow-up, the correlation between depth of the lesion and pain persisted ( $P < .05$ ). In addition, there were new parameters (subchondral cyst formation, presence and change of bone marrow edema) that correlated significantly with the level of pain ( $P < .05$ ). Three ankles presented with extensive bone marrow edema at time of follow-up with pain levels at VAS 0, 3, and 5. Ten out of 11 patients with complete resolution of bone marrow edema

pertained to the group with decreased pain in their history. One patient claimed to have the same pain when compared with the initial workup (Table 4).

Five patients (6 ankles, respectively) reported an increase of pain, but neither suspicious nor indicative signs on imaging studies could be found. Three patients did not present with any perifocal bone marrow edema on the follow-up MRI. In all of these patients, an alternate cause for the pain increase was identified: 1 patient sustained a conservatively treated ankle fracture with consecutive ankle osteoarthritis, 1 presented an equinus deformity and complex regional pain syndrome, and subjective and objective ankle instability was found in 2 patients. One patient reported a sprain of both his ankles with OLT just 1 month prior to the follow-up visit.

## Discussion

The current study identified patients who had OLT and who wished to pursue conservative treatment instead of undergoing operative treatment. Because the latter results in a bias toward less symptomatic lesions, the clinical and radiological outcome in these patients cannot be applied to all patients having OLT. Although it would be interesting to compare the current data with patients who have undergone surgery, this was not the goal of the study and is beyond the focus of the present investigation.

When compared with data in the literature, the average age of the patients in the current series is higher (mean = 48 years [range, 13-78 years]).<sup>1,3,5,7,8,16,20</sup> Male preponderance (56%), bilateral occurrence (4.2%), localization on the talar dome (64% medial, 34% lateral, and 2% central), and history of trauma as a triggering event before onset of symptoms (90%) are in accordance with previously published ranges.<sup>1,3-5,7,8,20</sup>

It is interesting that the present study showed that at final follow-up, most patients (86%) did not have pain (VAS 0: 24%) or had mild symptoms (VAS 1-3: 62%). Pain persisted in only a small number of patients (14%) (VAS 4-6: 12%; VAS 7-9: 2%; VAS 10: 0%). Nevertheless, a high share of patients reported on limitations in activities of daily living (23%) or during recreational or sports activities (58%).

Retrospective assessment of pain several years later is not possible. Therefore, we were not able to assess the VAS at the initial visit. As such, the most accurate parameter was pain assessed at time of follow-up. Considering this limitation, however, it may be of interest that only 5 patients (6 ankles, 12%) rated their pain as increased and 10 patients (11 feet, 22%) as unchanged, but two-thirds (33 patients, 33 feet, 66%) as improved. Furthermore, all 5 patients reported increased pain from other comorbidities that could explain their complaints. None of the clinical or demographic factors showed a significant correlation to VAS pain scores at the time of follow-up (Tables 1 and 2).



**Table 4.** Initial and Follow-up MRI Parameters.<sup>a</sup>

MRI Variable	At Initial MRI	At Follow-up MRI	Change
	→ Statistical Correlation to VAS Groups		
Anderson classification	→ $P = .73$	→ $P = .16$	
Stage 1	25 (50%)	21 (42%)	
Stage 2	8 (16%)	7 (14%)	
Stage 2A	11 (22%)	16 (32%)	
Stage 3	6 (12%)	6 (12%)	
Stage 4	0	0	
Anderson stage change			→ $P = .19$
Unchanged			42 (84%)
Cases with stage progression			6 (12%)
Cases with stage regression			2 (4%)
Subchondral cyst formation	→ $P = .33$	→ $P = .047^b$	
Occurring in	12 (24%)	19 (38%)	
Cyst number change			→ $P = .26$
New formation at follow-up			6 (12%)
Increased			3 (6%)
Decreased			4 (8%)
Unchanged			35 (70%)
Perifocal bone marrow edema	→ $P = .09$	→ $P = .02^b$	
Occurring in	25 (50%)	16 (32%)	
Marrow edema change			→ $P = .02^b$
Complete regression			11 (22%)
Partial regression			1 (2%)
Newly developed			2 (4%)
Area increased			3 (6%)
Size, mean [range], mm			
Width	→ $P = .08$ 9.6 [3.6-21.7]	→ $P = .51$ 8.6 [0.5-22.5]	
Depth	→ $P = .01^b$ 8.3 [3.1-19.6]	→ $P = .01^b$ 7.1 [1.2-17.8]	
Length	→ $P = .25$ 15.8 [4.1-26.4]	→ $P = .09$ 15.5 [0-26.0]	
Size change			
Width (increased/decreased in)			→ $P = .46^c$ 16 (32%)/34 (68%)
Depth (increased/decreased in)			→ $P = .57^c$ 10 (20%)/40 (80%)
Length (increased/decreased in)			→ $P = .26^c$ 19 (45%)/21 (50%)
Associated hindfoot pathologies			
Lateral ankle ligament lesions		23 (46%)	
Tibialis posterior tendinopathy		9 (18%)	
Achilles tendon lesions		7 (14%)	
Ankle or subtalar osteoarthritis		6 (12%)	
Spring ligament lesions		3 (6%)	
Deltoid ligament lesions		3 (6%)	
Plantar fasciitis		1 (2%)	
Distal tibial bone cyst		1 (2%)	

Abbreviations: MRI, magnetic resonance imaging; VAS, visual analogue scale.

<sup>a</sup>The table provides a synopsis of all initial and follow-up MRI parameters assessed. The variables from the initial and the follow-up MRI, as well as the changes over time, were correlated to the grouped VAS levels at follow-up.  $P$  values indicate statistical significance. Associated hindfoot pathologies found at follow-up are listed.

<sup>b</sup>Statistically significant correlation ( $P < .05$ ).

<sup>c</sup>Statistical correlation to the size change from initial to follow-up diameter in mm.

Conventional radiographs and MRI studies were used to analyze and characterize the OLT and to possibly identify factors predicting pain levels or pain evolution.<sup>11</sup> According to the classification described by van Dijk et al,<sup>22</sup> almost half of the patients did not have ankle osteoarthritis at the time of follow-up, and 27% each had grade 1 osteoarthritis (osteophyte formation without joint space narrowing) or grade 2 osteoarthritis (subtotal joint space narrowing or deformation of the joint space). This rate of ankle osteoarthritis in patients with OLT is comparable with data from earlier studies.<sup>4,7,12,18,21</sup> Bauer et al<sup>2</sup> described the development of severe ankle osteoarthritis after an average follow-up of 21 years in only 1 of 30 patients having OLT. In our study population, only 1 patient demonstrated a stage progression from 0 to 1 on the van Dijk classification,<sup>22</sup> whereas all others remained unchanged. However, due to selection bias, the limited availability of complete radiographic documentation, and the mid-term follow-up, the long-term evolution of ankle osteoarthritis cannot definitively be assessed. Comparative long-term and randomized studies of patients treated either operatively or conservatively would be required.

The majority of OLT patients who participated in this study and in whom a conservative treatment was applied were classified on MRI as Anderson stage 1 (50%), 2 (16%), or 2A (22%). Only 12% showed a stage 3 lesion and none a stage 4 lesion. Nevertheless, OLT stage did not significantly correlate to the patient VAS pain scores. Lesion characteristics reached a significant correlation for the presence of subchondral cysts, perifocal bone marrow edema, and depth in the follow-up MRI. The strongest positive correlation was found between lesion depth on MRI and pain, that is, the deeper the talar lesion, the greater the pain. Christensen et al<sup>6</sup> were able to show in an experimental cadaver study that larger lesions negatively influenced joint contact characteristics. They suggested that lesion size may assist in predicting long-term outcomes of cartilage defects. This, however, may be questioned because, in our series, lesion length and width were not significantly correlated to VAS pain scores, and the majority of the lesions in our patients decreased in size over time (68% in width, 50% in length, and 80% in depth).

Complete remission of osteochondral lesions by means of conservative treatment has been described in the literature and seems to happen most commonly in children.<sup>2,12</sup> To support the finding of healing capacity of immature cartilage,<sup>2</sup> we found 1 case with complete remission of a stage 1 OLT in an 11-year-old patient. In another 10-year-old patient, regression from a stage 2A was observed with disappearance of a small cyst on MRI. This may be an error due to MRI slice thickness; however, possible involution of bone cysts indicating regression into a lower stage lesion or even spontaneous healing was previously reported in the literature.<sup>10</sup> In spite of stable lesion size (25 × 7.4 × 4.2 mm), the patient became pain-free at follow-up.

Bone marrow edema may indicate a reparative process or a progressively unstable lesion.<sup>10</sup> Hence, the hypothesis of a correlation between presence and change of marrow edema may be derived. This could actually be found with statistically significant correlations between VAS pain levels and the presence of edema at follow-up ( $P < .05$ ) and changes in edema observed in the initial and follow-up MRIs ( $P < .05$ ), respectively. This is supported by the finding that 10 of the 11 patients with a complete remission of bone marrow edema rated their pain levels as improved.

Only 12% of the osteochondral lesions in this series showed a stage progression. In all of the cases, a new formation of bone cysts was detected but none of them progressed into advanced stages 3 or 4. Although Elias et al<sup>10</sup> conducted their MRI series on conservatively treated OLT with a shorter follow-up time (average 14 months), they found much higher rates of stage progression (45%). Furthermore, 5 of 12 lesions in their series presented with displacement of a fragment. Although their findings seem to support the hypothesis that osteochondral lesions of the talus are progressive, our current results put this into question.

There are several limitations to our study. First, only patients who pursued nonoperative treatment were included. Thus, a bias toward less symptomatic and possibly smaller lesions may have occurred. By excluding patients who underwent secondary operative treatment, a direct comparison of lesion characteristics was not possible and therefore only a limited conclusion could be drawn on what findings are more consistent with a good nonoperative result. However, our primary intention was to evaluate the evolution of OLT in patients who did not abandon conservative treatment over time. Second, we did not conduct a comparison with operative outcomes. Third, a small sample size resulted from the high share of patients treated nonoperatively (untraceable or unwilling to participate in the study). Finally, pain and activity levels were available only for the time of the study visit and evolution was rated subjectively by the patient in a retrospective manner.

## Conclusion

The results of the present study demonstrate favorable clinical and radiological midterm results after nonoperative treatment of OLTs. Considering clinical criteria and MRI characteristics on initial examination, only lesion depth correlated to pain levels at follow-up. In the majority of patients, the lesion size decreased, MRI stages remained unchanged, and ankle osteoarthritis, as seen on conventional radiograph, did not progress. Although a substantial number of patients recalled minor limitations while conducting activities of daily living or sports and recreation, they were satisfied subjectively with their midterm outcome. This study supports the premise that conservative treatment should be pursued,

at least in patients with mild pain due to OLT. Furthermore, prospectively randomized studies will be needed to judge whether operative treatment could improve the clinical outcome or ameliorate the prognosis.

### Declaration of Conflicting Interests

The author(s) declared no potential conflicts of interest with respect to the research, authorship, and/or publication of this article.

### Funding

The author(s) received no financial support for the research, authorship, and/or publication of this article.

### References

- Anderson IF, Crichton KJ, Grattan-Smith T, Cooper RA, Brazier D. Osteochondral fractures of the dome of the talus. *J Bone Joint Surg Am*. 1989;71(8):1143-1152.
- Bauer M, Jonsson K, Linden B. Osteochondritis dissecans of the ankle. A 20-year follow-up study. *J Bone Joint Surg Br*. 1987;69(1):93-96.
- Berndt AL, Harty M. Transchondral fractures (osteochondritis dissecans) of the talus. *J Bone Joint Surg Am*. 1959;41-A:988-1020.
- Canale ST, Belding RH. Osteochondral lesions of the talus. *J Bone Joint Surg Am*. 1980;62(1):97-102.
- Choi WJ, Park KK, Kim BS, Lee JW. Osteochondral lesion of the talus: is there a critical defect size for poor outcome? *Am J Sports Med*. 2009;37(10):1974-1980. <http://dx.doi.org/10.1177/0363546509335765>.
- Christensen JC, Driscoll HL, Tencer AF. 1994 William J. Stickel Gold Award. Contact characteristics of the ankle joint. Part 2. The effects of talar dome cartilage defects. *J Am Podiatr Med Assoc*. 1994;84(11):537-547.
- Elias I, Jung JW, Raikin SM, et al. Osteochondral lesions of the talus: change in MRI findings over time in talar lesions without operative intervention and implications for staging systems. *Foot Ankle Int*. 2006;27(3):157-166.
- Flick AB, Gould N. Osteochondritis dissecans of the talus (transchondral fractures of the talus): review of the literature and new surgical approach for medial dome lesions. *Foot Ankle*. 1985;5(4):165-185.
- Laffenetre O. Osteochondral lesions of the talus: current concept. *Orthop Traumatol Surg Res*. 2010;96(5):554-566. <http://dx.doi.org/10.1016/j.otsr.2010.06.001>.
- Lee KB, Bai LB, Park JG, Yoon TR. A comparison of arthroscopic and MRI findings in staging of osteochondral lesions of the talus. *Knee Surg Sports Traumatol Arthrosc*. 2008;16(11):1047-1051. <http://dx.doi.org/200810.1007/s00167-008-0607-x>.
- Mach DB, Rogers SD, Sabino MC, et al. Origins of skeletal pain: sensory and sympathetic innervation of the mouse femur. *Neuroscience*. 2002;113(1):155-166. <http://dx.doi.org/S0306452202001653>.
- McCullough CJ, Venugopal V. Osteochondritis dissecans of the talus: the natural history. *Clin Orthop Relat Res*. 1979;(144):264-268.
- McGahan PJ, Pinney SJ. Current concept review: osteochondral lesions of the talus. *Foot Ankle Int*. 2010;31(1):90-101.
- Mukherjee SK, Young AB. Dome fracture of the talus. A report of ten cases. *J Bone Joint Surg Br*. 1973;55(2):319-326.
- Pettine KA, Morrey BF. Osteochondral fractures of the talus. A long-term follow-up. *J Bone Joint Surg Br*. 1987;69(1):89-92.
- Pritsch M, Horoshovski H, Farine I. Arthroscopic treatment of osteochondral lesions of the talus. *J Bone Joint Surg Am*. 1986;68(6):862-865.
- Rynn M, Fazekas EA, Hecker RL. Osteochondral lesions of the talus. *J Foot Surg*. 1983;22(2):155-158.
- Shearer C, Loomer R, Clement D. Nonoperatively managed stage 5 osteochondral talar lesions. *Foot Ankle Int*. 2002;23(7):651-654.
- Stroud CC, Marks RM. Imaging of osteochondral lesions of the talus. *Foot Ankle Clin*. 2000;5(1):119-133.
- van Bergen CJ, de Leeuw PA, van Dijk CN. Treatment of osteochondral defects of the talus. *Rev Chir Orthop Reparatrice Appar Mot*. 2008;94(8)(suppl):398-408. <http://dx.doi.org/10.1016/j.rco.2008.09.003>.
- van Dijk CN, Reilingh ML, Zengerink M, van Bergen CJ. Osteochondral defects in the ankle: why painful? *Knee Surg Sports Traumatol Arthrosc*. 2010;18(5):570-580. <http://dx.doi.org/10.1007/s00167-010-1064-x>.
- van Dijk CN, Verhagen RA, Tol JL. Arthroscopy for problems after ankle fracture. *J Bone Joint Surg Br*. 1997;79(2):280-284.
- Verhagen RA, Maas M, Dijkgraaf MG, Tol JL, Krips R, van Dijk CN. Prospective study on diagnostic strategies in osteochondral lesions of the talus. Is MRI superior to helical CT? *J Bone Joint Surg Br*. 2005;87(1):41-46.
- World Health Organization. *Physical Status: The Use and Interpretation of Anthropometry*. Geneva, Switzerland: World Health Organization; 1995. Technical Report Series No. 854.