

volume, and total lung capacity.<sup>5</sup> Any reduction in pulmonary mechanical efficiency must be avoided in respiratory failure, and controlled use of carbimazole may permit a fall in basal metabolic oxygen requirement but with thyroid function remaining within the normal range.

Carbimazole would seem suitable for a double-blind controlled trial of treatment in chronic irreversible respiratory failure, and the drug may have a role in otherwise intractable cases while the results of such a study are awaited.

We are grateful to Dr D Davies for help with this paper.

<sup>1</sup> Bernard, E, *et al*, *Journal Français de Médecine et Chirurgie Thoraciques*, 1965, **19**, 703.

<sup>2</sup> Hurst, A, Levine, M N, and Rich, D R, *Annals of Allergy*, 1955, **13**, 393.

<sup>3</sup> Ormston, B J, *et al*, *Lancet*, 1971, **2**, 10.

<sup>4</sup> Crooks, J, Murray, I P C, and Wayne, E J, *Quarterly Journal of Medicine*, 1958, **28**, 211.

<sup>5</sup> Wilson, W R, and Bedell, G N, *Clinical Research*, 1958, **6**, 247.

(Accepted 29 January 1979)

City Hospital, Nottingham NG5 1PB

P F JENKINS, MA, MRCP, registrar

M S KNAPP, MD, FRCP, consultant physician

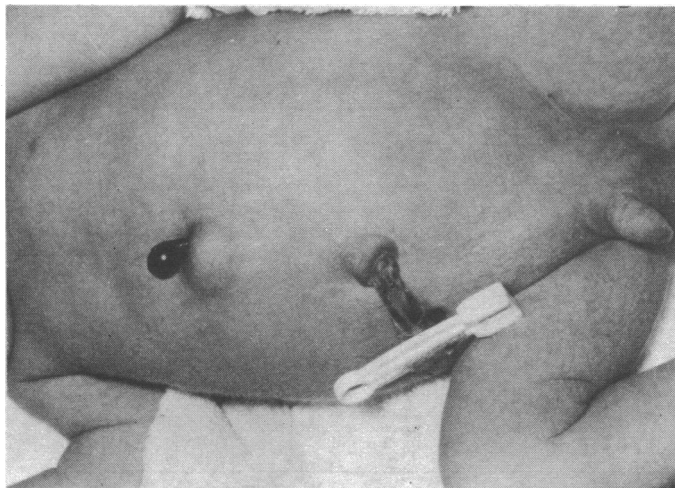
## Neonatal small-bowel obstruction associated with amniocentesis

Mid-trimester amniocentesis is a well established and relatively safe diagnostic procedure.<sup>1</sup> Nevertheless, there are inevitable hazards associated with the technique and if it is to be used in comprehensive antenatal screening programmes<sup>2</sup> potential complications should be recognised. Injuries to the fetus occur infrequently but they may be serious.

### Case report

A boy was born at term (weighing 3270 g) by normal vertex delivery after surgical induction of labour. This was the mother's third pregnancy and because of her age (39 years) she had requested amniocentesis, which had been performed after ultrasound placental localisation at 16 weeks' gestation. Amniocentesis had been straightforward with removal of 20 ml of clear fluid through a 20 G spinal needle with trochar.

At birth a pink fleshy mass 2 cm long with a necrotic tip was noted to protrude through a small epigastric abdominal wall defect just left of the midline (see figure). Meconium had not been passed 20 hours after birth, at which time the baby had a single copious vomit. Abdominal radiograph confirmed intestinal obstruction.



Abdominal wall of the infant showing the protruding, necrotic knuckle of small bowel.

At laparotomy the small bowel was obstructed at about its midpoint by an atretic segment, the bowel being represented by a fibrous cord spanning a defect in the mesentery (Bland Sutton type II atresia). The distal bowel was totally collapsed. Proximally it was distended to about 3 cm diameter, and a portion of its wall passed through the abdominal wall defect to form the fleshy mass seen externally. Peritoneal adhesions around this portion, anchoring it to the edges of the defect, suggested that it had prolapsed some considerable time before birth. The intestinal tract was otherwise normal. Forty centimetres of small bowel were resected and an anastomosis fashioned.

The postoperative period was complicated by a wound infection and a slow return to normal bowel function. After 10 days of intravenous parenteral nutrition the baby improved and was discharged on the 34th day. At the time of writing the infant was thriving.

### Comment

The abdominal wall defect described in this case does not have a satisfactory embryological explanation. Similar atretic lesions of the bowel have been experimentally produced in animals by intrauterine perforation of the fetal ileum or by ligation of mesenteric vessels.<sup>3</sup> The combination at the same site of a defect in the abdominal wall without embryological explanation and an ileal defect which can be produced experimentally by perforation or devascularisation makes trauma a likely cause. Both might have been induced by needle puncture at the time of amniocentesis. An alternative but unlikely explanation is that the needle puncture allowed an already dilated proximal portion of obstructed ileum to push through the abdominal wall.

When attempts are made to puncture the fetal abdominal wall during intrauterine transfusions for rhesus incompatibility important fetal trauma occurs in at least 10% of cases. Many types of visceral injury have been reported, including traumatic and functional intestinal obstruction. Similarly, amniocentesis for assessment of rhesus disease causes fetal puncture in many hydropic infants.<sup>4</sup> These procedures, however, are usually performed in the third trimester of pregnancy, when a larger fetus is surrounded by relatively less liquor.

Second-trimester amniocentesis appears to be safer, but fetal injuries have been reported with important consequences such as limb deformity, fetal haemorrhage, and puncture wounds of the eye and other vital organs. Rickwood has also recorded a similar case of ileal atresia with an abdominal wall fistula after amniocentesis at 18 weeks' gestation.<sup>5</sup>

The amniocentesis needle may therefore be responsible for serious fetal trauma. With the inevitable increase in the use of this important procedure such consequences should be borne in mind.

We acknowledge the help of Dr R W Whittlesey and thank Dr R L'E Orme and Mr D W Sykes for allowing us to report this case.

<sup>1</sup> NICHD Study Group, *Journal of the American Medical Association*, 1976, **236**, 1471.

<sup>2</sup> UK Collaborative Study on Alpha-fetoprotein in Relation to Neural-tube Defects, *Lancet*, 1977, **1**, 1323.

<sup>3</sup> Louw, J H, *Annals of the Royal College of Surgeons of England*, 1959, **25**, 209.

<sup>4</sup> Cook, L N, Shott, R J, and Andrews, B F, *Pediatrics*, 1971, **53**, 421.

<sup>5</sup> Rickwood, A M K, *Journal of Pediatrics*, 1977, **91**, 312.

(Accepted 5 January 1979)

Royal Devon and Exeter Hospital (Heavitree), Exeter

P G F SWIFT, MRCP, senior registrar in paediatrics, (now consultant paediatrician, Leicester General Hospital, Leicester, LE5 4PW)

I B DRISCOLL, MRCOG, registrar in obstetrics

K D J VOWLES, FRCS, consultant surgeon

## Spinal muscular atrophy associated with HLA-B7

The spinal muscular atrophies are familial disorders characterised by degeneration of the anterior horn cells of the spinal cord or bulbar motor nuclei but with no disease of the pyramidal tract or peripheral nerves. Although the characteristic neuronal changes can be determined only at necropsy, diagnosis of the secondary muscular changes on clinical, electrodiagnostic, and histological grounds is