

Network localization of cervical dystonia based on causal brain lesions

Daniel T. Corp,^{1,2,*} Juho Joutsa,^{1,3,4,5,*} R. Ryan Darby,^{1,6} Cathérine C. S. Delnooz,⁷ Bart P. C. van de Warrenburg,⁸ Danielle Cooke,¹ Cecília N. Prudente,⁹ Jianxun Ren,³ Martin M. Reich,^{1,10} Amit Batla,¹¹ Kailash P. Bhatia,¹² Hyder A. Jinnah,¹³ Hesheng Liu³ and Michael D. Fox^{1,3,14}

*These authors contributed equally to this work.

Cervical dystonia is a neurological disorder characterized by sustained, involuntary movements of the head and neck. Most cases of cervical dystonia are idiopathic, with no obvious cause, yet some cases are acquired, secondary to focal brain lesions. These latter cases are valuable as they establish a causal link between neuroanatomy and resultant symptoms, lending insight into the brain regions causing cervical dystonia and possible treatment targets. However, lesions causing cervical dystonia can occur in multiple different brain locations, leaving localization unclear. Here, we use a technique termed ‘lesion network mapping’, which uses connectome data from a large cohort of healthy subjects (resting state functional MRI, $n = 1000$) to test whether lesion locations causing cervical dystonia map to a common brain network. We then test whether this network, derived from brain lesions, is abnormal in patients with idiopathic cervical dystonia ($n = 39$) versus matched controls ($n = 37$). A systematic literature search identified 25 cases of lesion-induced cervical dystonia. Lesion locations were heterogeneous, with lesions scattered throughout the cerebellum, brainstem, and basal ganglia. However, these heterogeneous lesion locations were all part of a single functionally connected brain network. Positive connectivity to the cerebellum and negative connectivity to the somatosensory cortex were specific markers for cervical dystonia compared to lesions causing other neurological symptoms. Connectivity with these two regions defined a single brain network that encompassed the heterogeneous lesion locations causing cervical dystonia. These cerebellar and somatosensory regions also showed abnormal connectivity in patients with idiopathic cervical dystonia. Finally, the most effective deep brain stimulation sites for treating dystonia were connected to these same cerebellar and somatosensory regions identified using lesion network mapping. These results lend insight into the causal neuroanatomical substrate of cervical dystonia, demonstrate convergence across idiopathic and acquired dystonia, and identify a network target for dystonia treatment.

- 1 Berenson-Allen Center for Non-Invasive Brain Stimulation and Division of Cognitive Neurology, Department of Neurology, Beth Israel Deaconess Medical Center, Harvard Medical School, Boston, MA 02215, USA
- 2 Cognitive Neuroscience Unit, School of Psychology, Deakin University, 221 Burwood Highway, Burwood, VIC 3125, Australia
- 3 Athinoula A. Martinos Center for Biomedical Imaging, Massachusetts General Hospital and Harvard Medical School, Charlestown, MA 02129, USA
- 4 Department of Neurology, University of Turku, Turku, Finland
- 5 Division of Clinical Neurosciences, Turku University Hospital, Turku, Finland
- 6 Department of Neurology, Division of Cognitive and Behavioral Neurology, Vanderbilt University Medical Center, Nashville, TN, 37232, USA
- 7 Department of Neurology, Máxima Medical Centre, Veldhoven, The Netherlands
- 8 Department of Neurology, Donders Institute for Brain, Cognition, and Behaviour, Radboud University Medical Centre, Nijmegen, The Netherlands
- 9 MicroTransponder, Austin, TX 78738, USA
- 10 Department of Neurology, University Hospital and Julius-Maximilians-University, Wuerzburg, Germany

Received October 3, 2018. Revised January 27, 2019. Accepted February 24, 2019

© The Author(s) (2019). Published by Oxford University Press on behalf of the Guarantors of Brain. All rights reserved.

For Permissions, please email: journals.permissions@oup.com

- 11 UCL Institute of Neurology, Queen Square, London, WC1N 3BG, UK
- 12 Sobell Department of Movement Neuroscience, Institute of Neurology, UCL, National Hospital for Neurology, Queen Square, London, WC1N 3BG, UK
- 13 Department of Neurology, Emory University, Atlanta, Georgia, USA
- 14 Department of Neurology, Massachusetts General Hospital, Harvard Medical School, Boston, MA 02114, USA

Correspondence to: Daniel T. Corp
Department of Neurology, Beth Israel Deaconess Medical Center, Harvard Medical School
Boston, MA 02215, USA
E-mail: danielcorp@gmail.com

Correspondence may also be addressed to: Michael D. Fox
E-mail: foxmdphd@gmail.com

Keywords: cervical dystonia; lesions; functional connectivity; cerebellum; somatosensory cortex

Abbreviations: DBS = deep brain stimulation; rs-fcMRI = resting state functional connectivity MRI

Introduction

Cervical dystonia is a chronic neurological disorder characterized by sustained and involuntary contractions of the neck muscles, and is the most common form of focal dystonia (Xiao *et al.*, 2012). Cervical dystonia has traditionally been ascribed to dysfunction of the basal ganglia (Galardi *et al.*, 1996; Naumann *et al.*, 1998), but abnormalities have been observed in many other brain regions including the cerebellum (Batla *et al.*, 2015), prefrontal cortex (Li *et al.*, 2017), midbrain (Holmes *et al.*, 2012), motor cortex (Richardson, 2015), and somatosensory cortex (Prudente *et al.*, 2016). This has led to the suggestion that cervical dystonia is a ‘network disorder’ resulting from dysfunction in multiple different brain regions (Jinnah *et al.*, 2006). However, the key nodes of this network have yet to be identified. Further, it remains unclear which brain regions are causative and which are compensatory or incidental correlates.

Occasionally, a focal brain lesion can cause symptoms that are nearly identical to those observed in idiopathic cervical dystonia (LeDoux *et al.*, 2003; Albanese *et al.*, 2013). Although these cases of acquired cervical dystonia are rare compared to cases of idiopathic cervical dystonia (LeDoux *et al.*, 2003), they are uniquely valuable because lesions allow for causal links between the damaged brain region and resultant symptoms (Adolphs, 2016; Fox, 2018). However, lesions causing cervical dystonia can occur in numerous brain locations, spanning the cerebellum, medulla, pons, midbrain, and basal ganglia (LeDoux *et al.*, 2003). Further, symptoms can emerge not only from the lesion itself, but also from the effect of the lesion on remote but connected brain regions, a phenomenon referred to as diaschisis (von Monakow, 1914; Carrera *et al.*, 2014). These factors complicate the localization of cervical dystonia symptoms based on focal brain lesions alone.

Recently, we validated a technique termed ‘lesion network mapping’, which can link lesions in different locations to a common brain network (Boes *et al.*, 2015).

Rather than focusing solely on lesion location, this technique uses a database of normative resting state functional connectivity MRI (rs-fcMRI) scans to identify the network of brain regions connected to each lesion location. This technique has lent insight into the localization of multiple neuropsychiatric symptoms (Fox, 2018), including other movement disorders (Fasano *et al.*, 2016; Laganieri *et al.*, 2016; Joutsa *et al.*, 2018a), and may help identify therapeutic targets for brain stimulation therapies (Joutsa *et al.*, 2018a, b). Here, we apply this approach to lesions causing cervical dystonia. We then go beyond prior lesion network mapping studies by investigating whether the neuroanatomical substrate of cervical dystonia derived from focal brain lesions is also abnormal in patients with similar symptoms, but without brain lesions.

Materials and methods

Case selection

Cases of lesions causing cervical dystonia were identified from a systematic search of Pubmed in January 2017 using the combination of synonyms of the following terms: cervical dystonia; torticollis; lesion; infarct; tumor; magnetic resonance imaging; and computerized tomography. The exact search syntax is provided in the Supplementary material. Reference lists of selected articles were searched for possible cases missed in the initial search. Inclusion criteria were: (i) neurological examination documenting cervical dystonia that was thought to be caused by an intraparenchymal brain lesion(s); and (ii) a figure or image showing the lesion location in sufficient clarity for it to be traced onto a standard brain atlas. Exclusion criteria were: (i) lesions in children aged <10 years, given that in these cases the brain is not sufficiently developed to resemble the standard adult brain; and (ii) lesions of the CNS but outside the brain (e.g. meningioma). As the emergence of dystonia may be delayed by months or even years following a brain insult (Scott *et al.*, 1996; LeDoux *et al.*, 2003), we did not apply a strict time limit for the onset of symptoms post-lesion. Based on these criteria, it is important to note that not all

lesions causing cervical dystonia found in our search, which would be eligible based on clinical description (LeDoux and Brady, 2003), were eligible for inclusion in the current analysis.

Lesion network mapping

The network of regions functionally connected to each lesion location was identified using previously described methods (Boes *et al.*, 2015; Darby *et al.*, 2018a). First, lesions from published images were traced by hand onto a standardized brain atlas ($2 \times 2 \times 2$ mm MNI152 brain) using FSLview software (version 5.0.9) (Jenkinson *et al.*, 2012). This approach generates only 2D slices of 3D lesions, but prior work has shown that the resulting connectivity maps are nearly identical (Boes *et al.*, 2015; Darby *et al.*, 2018a). Second, rs-fcMRI maps were created for each lesion using a standard seed-based approach, leveraging rs-fcMRI data from a normative dataset of 1000 healthy young adults (Yeo *et al.*, 2011; Holmes *et al.*, 2015). The time course of the average blood oxygen level-dependent signal within the lesion volume was extracted for each participant in the normative cohort and correlated with all brain voxels. Resulting individual r-maps were Fisher z-transformed, which were then used to generate a single connectivity *t*-map for each lesion. For step three, connectivity maps for each lesion were thresholded at a *t*-value of ± 7 [corresponding to whole brain family-wise error (FWE)-corrected $P < 10^{-6}$], binarized (functionally connected or not, positive and negative connectivity separately as they may have different biological interpretation), and then overlapped to identify voxels connected to all 25 of our lesion locations causing cervical dystonia (Fig. 1). This three-step technique is summarized in Fig. 2.

We also ran a number of lesion network mapping subanalyses, excluding cases with ataxia or dysmetria ($n = 11$), head tremor ($n = 6$), hemiparesis ($n = 9$), dystonia symptoms outside of cervical regions ($n = 6$), and excluding cases not caused by ischaemic stroke ($n = 15$), to check that our findings were not being driven by these cases.

Specificity

To test for specificity to cervical dystonia, we compared our results to two ‘control’ datasets of lesions not causing cervical dystonia, as described previously (Joutsa *et al.*, 2018a). First, we used a ‘non-specific’ dataset of lesions that were distributed throughout the brain without a common neuropsychiatric phenotype ($n = 135$) (Corbetta *et al.*, 2015). Second, we used a ‘movement disorders’ dataset, consisting of 73 lesions causing movement disorders other than dystonia: asterixis ($n = 30$) (Kim, 2001; Laganiere *et al.*, 2016); hemichorea-hemiballismus ($n = 29$) (Laganiere *et al.*, 2016), and freezing of gait ($n = 14$) (Fasano *et al.*, 2016).

We compared our network maps from lesions causing cervical dystonia to these two control lesion datasets using two statistical methods: (i) a Liebermeister test, using voxel-based lesion-symptom mapping (VLSM) (Rorden *et al.*, 2007); and (ii) a two-sample *t*-test, using Statistical Parametric Mapping (SPM12; <http://www.fil.ion.ucl.ac.uk/spm/software/spm12/>) (Ashburner, 2012). Both statistical approaches identify voxels that are significantly more or less connected to cervical dystonia lesion locations than control lesion locations. The

difference between these approaches is that the Liebermeister test analyses voxels in a binary fashion (functionally connected or not), and is more commonly used in lesion analyses, while the *t*-test takes into account the strength of the connection, and is more commonly used in functional neuroimaging (Fasano *et al.*, 2016). Because the Liebermeister test is used for binary image analyses, the group comparisons were conducted separately for positive and negative connectivity maps. Correction for multiple comparisons was conducted using whole brain voxel-level FWE for *t*-tests and false discovery rate (FDR) for Liebermeister tests across the whole brain voxels showing at least 10% overlap in the whole sample. Corrected *P*-values < 0.05 were considered significant. Specificity analyses were restricted to voxels within the cervical dystonia lesion network map [i.e. regions that were functionally connected to $> 90\%$ (at least 23/25) of the lesions as shown in Fig. 3].

Regions of interest

To identify regions whose connectivity was both sensitive and specific to lesion locations causing cervical dystonia, we performed a conjunction analysis of the above maps. These regions of interest comprised of voxels that were connected to $> 90\%$ of lesion locations causing cervical dystonia, and also specific to cervical dystonia across all four specificity analyses above (two control groups \times two statistical tests). Because the somatosensory cortex cluster that survived all four specificity tests was very small (14 voxels with the centre of gravity at $-8 -43 -75$ mm; Supplementary Fig. 1D), voxels surviving three of the four specificity analyses were used to define the somatosensory region of interest.

The resultant cerebellar and somatosensory regions of interest were then used in three analyses. First, we used a linear model to test whether connectivity between lesion locations and these regions of interest were independent or redundant predictors of lesion-induced cervical dystonia. Note that our method of selecting these regions of interest requires that connectivity to each region of interest alone be a predictor of cervical dystonia, but does not tell us whether these are independent predictors when combined in a linear model. Second, we used these regions of interest to generate a network map that, by definition, encompasses lesion locations causing cervical dystonia. To generate this map, we identified all voxels positively correlated with our cerebellar region of interest, all voxels negatively correlated with our somatosensory region of interest, thresholded each map ($t \geq \pm 7$, voxelwise FWE corrected $P < 10^{-6}$), and identified voxels meeting both criteria. Lesion locations were overlaid on this map for illustrative purposes. Finally, we used these regions of interest to test whether these same regions, identified based on brain lesions, were abnormal in idiopathic cervical dystonia.

These regions of interest were localized in greater anatomical detail using the Anatomy toolbox within SPM 12, using cerebellar (Schmahmann *et al.*, 1999; Diedrichsen, 2006; Diedrichsen *et al.*, 2009), motor cortex (Geyer *et al.*, 1996), and somatosensory cortex (Geyer *et al.*, 2000; Grefkes *et al.*, 2001) atlases. The cerebellar atlas uses nomenclature of Schmahmann *et al.* (1999), and also includes updates provided by Diedrichsen (2006) and Diedrichsen *et al.* (2009) to determine fissure and lobule locations.

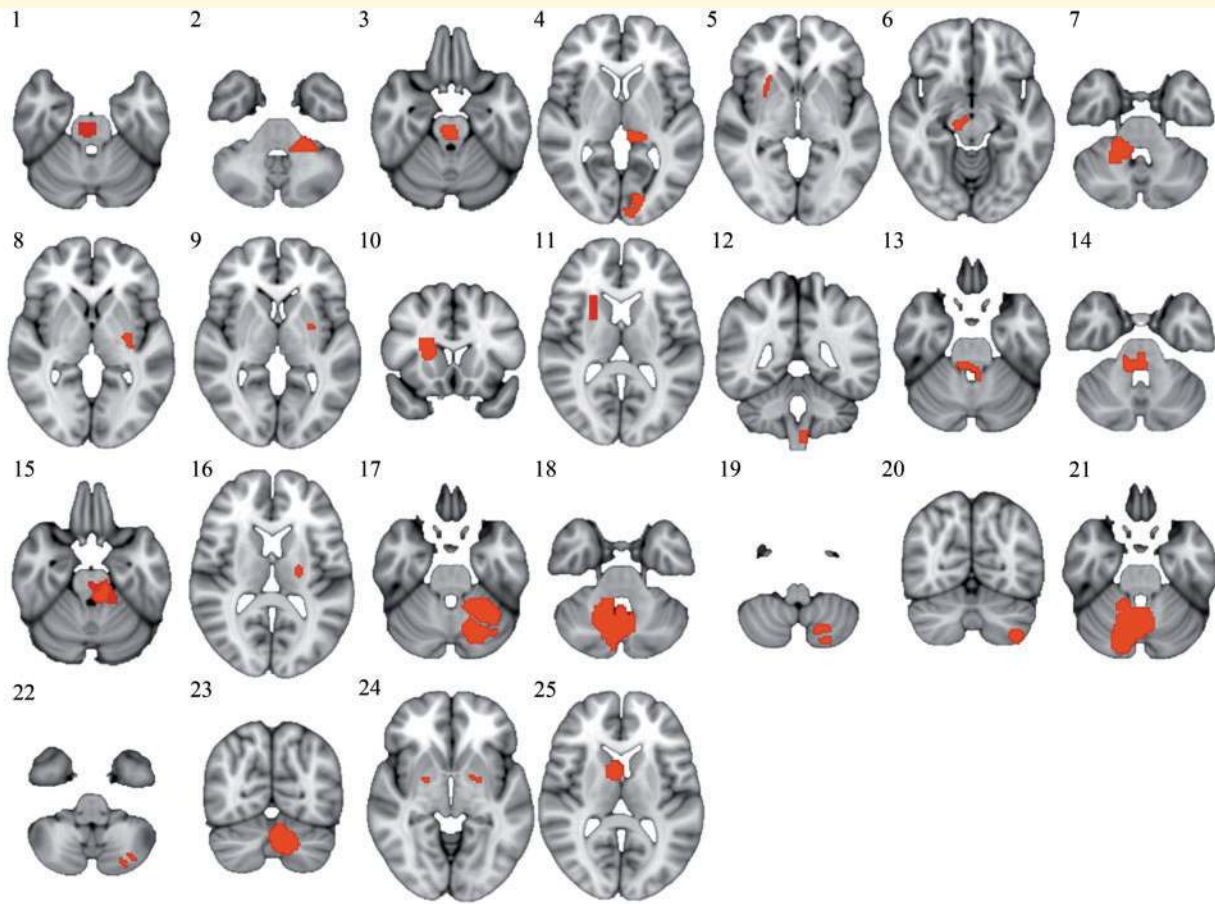


Figure 1 Lesion locations causing cervical dystonia. A systematic literature search identified 25 cases of cervical dystonia with an identifiable lesion location that could be traced onto a standard brain atlas. Case numbers correspond to those in Table 1 and Supplementary Table 1, which provides additional clinical details of cases listed in Table 1.

Relevance to idiopathic cervical dystonia

Our cerebellar and somatosensory regions of interest were used as seed regions to compare functional connectivity patterns between 39 idiopathic cervical dystonia patients and 37 control subjects, in a dataset collated from two previously published rs-fcMRI studies of idiopathic cervical dystonia (Delnooz *et al.*, 2013; Prudente *et al.*, 2016). The preprocessing of the rs-fcMRI data followed conventional methods and guidelines, including global signal regression (Fox *et al.*, 2010; Murphy *et al.*, 2016), but added an extra artefact-reduction step modified from prior principal component analysis-based approaches (Behzadi *et al.*, 2007) (Supplementary material).

Functional connectivity of patients and controls was compared using non-parametric permutation interference with threshold-free cluster enhancement implemented in FSL software (Jenkinson *et al.*, 2012). Permutation/randomization-based correction for multiple comparisons was selected to avoid inflated type I error rate often associated with parametric cluster-level correction (Winkler *et al.*, 2014; Eklund *et al.*, 2016). Because patients often move more than controls, two metrics of in-scanner movement were included as subject-level covariates (relative frame-to-frame motion and cumulative

frame-wise transposition) in addition to dataset (Fox *et al.*, 2010). FWE corrected P -values <0.05 were considered significant. The z -transformed values were extracted from all of the significant clusters to illustrate the direction of connectivity (positive or negative). Cumulative and relative in-scanner movement was compared between the groups using two-sample t -tests. P -values <0.05 were considered significant.

To assess specificity, we repeated this analysis using control regions of interest derived from prior lesion network mapping studies of other neurological symptoms (Boes *et al.*, 2015; Fasano *et al.*, 2016; Fischer *et al.*, 2016; Laganieri *et al.*, 2016; Darby *et al.*, 2017; 2018a, b; Joutsa *et al.*, 2018a). Control regions of interest were derived in the same way as our dystonia regions of interest, based on stronger connectivity to lesions causing a neurological symptom versus control lesions not causing the symptom. We identified 19 control regions of interest from eight previous papers, covering 11 different neurological symptoms (MNI coordinates of each control region are provided in the Supplementary material). Coordinates of one region of interest were not reported in the original study (Laganieri *et al.*, 2016), and were identified through visual comparison with an atlas brain. For this analysis, a 5-mm radius sphere was generated at each coordinate, including centre of gravity coordinates for our cerebellar and

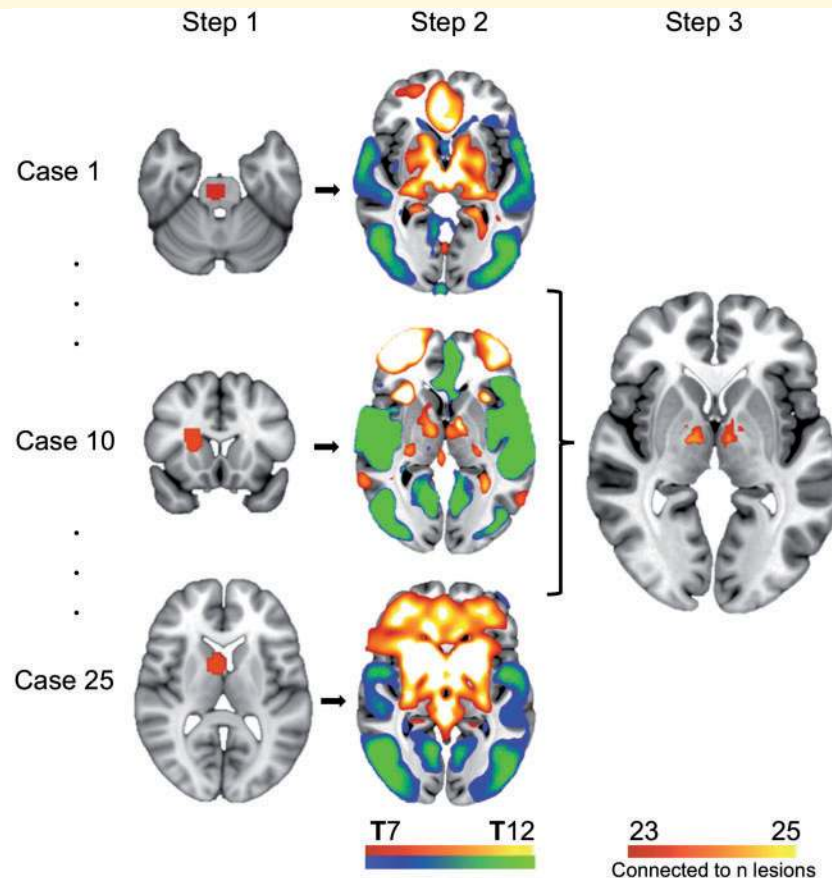


Figure 2 Lesion network mapping technique. In step one, lesions causing cervical dystonia were traced onto a standard atlas. In step two, connectivity between each lesion location and the rest of the brain was computed using a normative dataset of resting state functional connectivity scans from 1000 healthy individuals, and a standard seed-based approach. In step three, functional connectivity maps were thresholded, binarized (functionally connected or not), and overlapped to identify voxels connected to the greatest number of lesion locations.

somatosensory regions of interest. For each region of interest, we repeated the above permutation-based analysis to identify differences in connectivity between patients with idiopathic cervical dystonia and healthy controls. This resulted in a statistical map of T-values for each region of interest. To quantify the overall magnitude of these connectivity abnormalities, we computed the average absolute T-value of all brain voxels. We compared the average absolute T-values of the 19 control regions of interest to those from our two dystonia regions of interest (cerebellar and somatosensory) using two-sided one-sample *t*-tests with the null hypotheses that the control regions of interest do not differ from either of the cervical dystonia regions of interest.

Relevance to deep brain stimulation treatment

Clusters of voxels near the globus pallidus significantly associated with clinical response to deep brain stimulation (DBS) for dystonia were extracted from a recent study (Reich *et al.*, 2019). Briefly, this study examined DBS electrode locations and stimulation sites from 105 patients with dystonia (53 cervical dystonia, and 52 generalized or segmental dystonia patients). Patients were categorized as having a ‘good’ or ‘poor’ DBS response based on improvement in Toronto Western

Spasmodic Torticollis Rating Scale (TWSTRS) score (cervical dystonia), or Burke-Fahn-Marsden Dystonia Rating Scale (generalized or segmental dystonia). Voxels significantly associated with good clinical response were identified for the full cohort of dystonia patients ($P < 0.01$), and also separately for subjects with cervical dystonia ($P < 0.05$). Although not emphasized in the paper by Reich *et al.*, there was also a cluster of voxels significantly associated with poor DBS response in the full dystonia cohort ($P < 0.01$). We tested whether ‘good’ clusters were functionally connected to our dystonia regions of interest, and whether this connectivity in the full dystonia cohort was significantly greater than for the ‘poor’ cluster, using our resting state functional connectivity dataset from 1000 healthy young adults (Yeo *et al.*, 2011; Holmes *et al.*, 2015). Finally, we performed a voxelwise analysis to identify voxels significantly connected to the ‘good’ cluster, controlling for connectivity to the ‘poor’ cluster using partial correlation. After *z*-transformation, the significance of the correlations was calculated using two-sided one-sample *t*-tests, and differences in connectivity from ‘good’ versus ‘poor’ clusters to our regions of interest were analysed using two-sided paired *t*-tests. Correlation to our cerebellar and somatosensory regions of interest, and to all brain voxels, was calculated as with lesion analyses, described in the previous paragraphs.

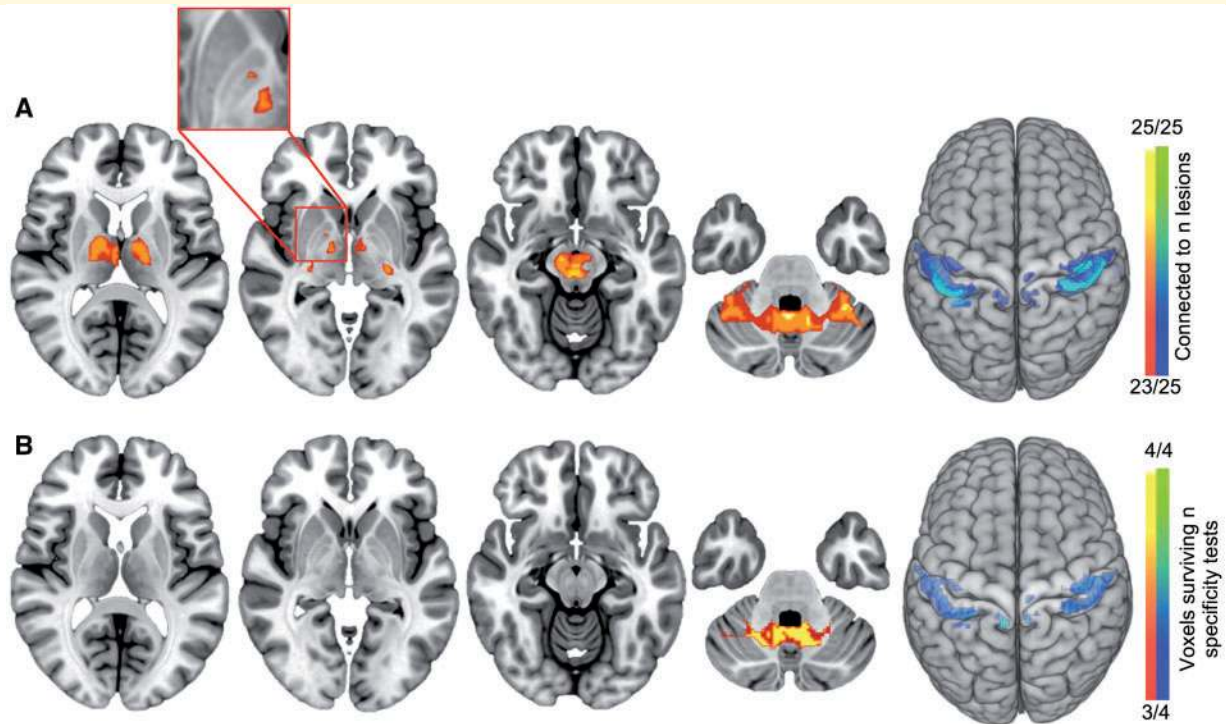


Figure 3 Lesion network mapping of cervical dystonia. (A) Regions positively correlated (orange/yellow) or negatively correlated (blue/green) to lesion locations causing cervical dystonia (thresholded at 90% or 23/25 cases). From left to right: thalamus ($z = 10$); globus pallidus ($z = -2$); midbrain ($z = -13$); cerebellum ($z = -32$), and somatosensory cortex (projected onto the brain surface). (B) Regions that are both sensitive and specific to lesions causing cervical dystonia, with significantly greater (positive or negative) functional connectivity to lesion locations causing cervical dystonia compared to control lesion locations (conjunction across four separate specificity analyses).

Data availability

Data are available from the corresponding authors upon request.

Results

Lesions causing cervical dystonia

We identified 25 cases of lesion-induced cervical dystonia that met our inclusion/exclusion criteria (Supplementary Table 1, Table 1 and Fig. 1). Lesions occurred in a number of different brain locations including the cerebellum (11 lesions), brainstem ($n = 9$), basal ganglia ($n = 8$), thalamus ($n = 1$), and occipital lobe ($n = 1$). Some patients had lesions in multiple locations.

Lesion network mapping

Each lesion location was converted into a lesion network map, and regions functionally connected to all or most lesion locations causing cervical dystonia were identified (Fig. 2). Despite heterogeneity in lesion locations, all lesions causing cervical dystonia were part of a single functionally connected brain network. All 25 lesion locations were

functionally connected (positively correlated) to the cerebellar vermis, dentate nucleus, cerebellar cortex, and midbrain (Table 2), and over 90% of lesion locations were functionally connected to the thalamus and globus pallidus (Fig. 3A). All 25 lesion locations were also functionally connected, but negatively correlated, to the right somatosensory cortex (Table 2), and over 90% of lesion locations were connected to the somatosensory cortex bilaterally, extending slightly into the motor cortex (Fig. 3A). Medial and lateral clusters were found within the somatosensory cortex, consistent with previous reports of both a medial and lateral representation for the neck within the homunculus (Prudente *et al.*, 2015, 2016). Some smaller clusters of (positive and negative) functionally connected voxels were also present (Supplementary Fig. 2). Results were unchanged when excluding cases with ataxia or dysmetria, head tremor, hemiparesis, dystonia symptoms outside of cervical regions, or cases not caused by ischaemic stroke (Supplementary Fig. 3).

Connectivity to the cerebellum and somatosensory cortex was specific to lesion locations causing cervical dystonia, compared to control lesion locations, independent of the statistical approach and control dataset (Fig. 3B). We performed a conjunction analysis to identify regions whose connectivity was both sensitive and specific to lesion locations causing cervical dystonia. This identified a region of

Table 1 Case characteristics of lesions causing cervical dystonia

Case	Authors	Age/gender	Lesion type	Lesion location	Head/neck position	CD symptom latency
1	LeDoux and Brady (2003)	55/M	Haemorrhage	R pons	L rotation	12 h
2	LeDoux and Brady (2003)	42/F	Cyst	L CB/pons	L rotation, R laterocollis	3 to 4 months
3	LeDoux and Brady (2003)	67/F	Infarct	Pons/midbrain	R latero- and anterocollis	Several days
4	LeDoux and Brady (2003)	72/M	Infarct	Pons, L thalamus, L occipital	L rotation, retrocollis	1 day
5	Isaac and Cohen (1989)	28/M	Haemorrhage	R putamen	L rotation, R shoulder elevation	4–5 years
6	Plant <i>et al.</i> (1989)	30/F	MS plaques	R midbrain, R CB	L rotation	1 year
7	Tranchant <i>et al.</i> (1991)	53/F	Angioma	R CB	L rotation, antero- and laterocollis	3 years
8	Molho and Factor (1993)	68/F	Infarct	L putamen	R rotation, L laterocollis	Acute onset, 1 year before scan
9	Molho and Factor (1993)	41/F	Infarct	L putamen	R rotation, R latero- and anterocollis	Acute onset, 3 years before scan
10	Schulze-Bonhage and Ferbert (1995)	40/M	Glioma	R BG and frontoparietal WM	R laterocollis	2 years before lesion was detected
11	Schwartz <i>et al.</i> (1995)	63/M	Infarct	R BG and IC	R rotation, L laterocollis	Started gradually weeks before scan
12	Kajimoto <i>et al.</i> (2004)	84/F	Infarct	L medulla	R laterocollis	10 days
13	Loher and Krauss (2009)	31/M	Haemorrhage	R midbrain, pons, CB	R laterocollis, L rotation	3 months
14	Loher and Krauss (2009)	42/M	Haemorrhage	Midbrain and pons	R laterocollis, L rotation	4 months
15	Loher and Krauss (2009)	56/M	Haemorrhage	L pons, L CB	R laterocollis, L rotation	1 month
16	Chang <i>et al.</i> (2002)	23/M	Haemorrhage	L GPi	L rotation	3 years
17	Zadro <i>et al.</i> (2008)	48/F	Infarct	L CB	R rotation, anterocollis	1 to 2 days
18	Usmani <i>et al.</i> (2011)	37/M	Haemorrhage	Vermis, R CB	L rotation	15 months
19	O'Rourke <i>et al.</i> (2006)	35/F	Infarct	L and R CB	R rotation	3 days
20	Batla <i>et al.</i> (2015)	56/F	Tumour	L CB	R rotation	Information unavailable
21	Batla <i>et al.</i> (2015)	33/M	Cyst	R CB	R rotation	Information unavailable
22	Batla <i>et al.</i> (2015)	58/M	Infarct	L CB	R rotation	Information unavailable
23	Batla <i>et al.</i> (2015)	29/M	Cyst	L CB	L rotation	Information unavailable
24	Kirton and Riopelle (2001)	60/F	Infarct	L and R GP	Rotation, antero-, retro- and laterocollis	Several years
25	Lambrecq <i>et al.</i> (2010)	23/M	Tumour	R BG, WM and ventricle	Anterocollis	Acute onset, scan taken within days

BG = basal ganglia; CB = cerebellum; CD = cervical dystonia; GPi = globus pallidus interna; IC = internal capsule; L = left; MS = multiple sclerosis; R = right; WM = white matter.

interest in the cerebellum, centred on the vermis of lobule IX (MNI coordinates 1 –54 –34 mm) and a region of interest in the somatosensory cortex/Brodmann's area 1 (MNI coordinates right hemisphere centre of gravity: 45 –24 60 mm; and left hemisphere centre of gravity: and –45 –28 59 mm) (Fig. 3B). See Supplementary Table 2 for greater anatomical detail of these region of interest locations, and Supplementary Figs 4 and 5 for overlay of our cervical dystonia regions of interest on cerebellar (Schmahmann *et al.*, 1999; Diedrichsen, 2006; Diedrichsen *et al.*, 2009), and sensorimotor cortex atlases (Geyer *et al.*, 1996, 2000; Grefkes *et al.*, 2001). Our cerebellar region of interest, connected to lesions causing cervical dystonia, was in a different region of the cerebellum than a previously published region of interest connected to lesions causing freezing of gait (Fasano *et al.*, 2016) (Supplementary Fig. 6).

To test whether connectivity from the lesions to cerebellum and somatosensory cortex regions of interest were independent or redundant predictors of lesion-induced cervical dystonia, we included both as factors in a logistic regression model with a binary outcome variable (cervical

dystonia lesion versus control lesion). Cerebellum region of interest connectivity was a strong independent predictor of cervical dystonia ($P = 0.002$), while somatosensory cortex region of interest connectivity fell just short of our statistical threshold for independence ($P = 0.051$).

By definition, connectivity with our cerebellar and somatosensory regions of interest defines a network that encompasses lesion locations causing cervical dystonia while avoiding control lesions. To illustrate this, we constructed a map of voxels both positively correlated with our cerebellar region of interest and negatively correlated with our somatosensory region of interest. As expected, our lesion locations causing cervical dystonia fell within this topographic distribution (Fig. 4), although one lesion fell just at the boundary of this network (Case 8).

Relevance to idiopathic cervical dystonia

The aforementioned cerebellar and somatosensory regions of interest, identified based on brain lesions, were used as

Table 2 Brain regions functionally connected to 25/25 lesions causing cervical dystonia

Voxels	x	y	z	Brain region
Regions positively connected with lesions				
111	−6	−52	−36	Medial cerebellum
38	−33	−55	−29	Left cerebellar cortex
22	14	−54	−36	Medial cerebellum
9	8	−17	−14	Midbrain
9	1	−25	−12	Midbrain
7	35	−52	−30	Right cerebellar cortex
3	0	−20	−13	Midbrain
2	31	−58	−28	Right cerebellar cortex
1	26	−24	−4	Right lateral geniculate nucleus
Regions negatively connected with lesions				
32	45	−30	58	Somatosensory cortex

seed regions to test whether these same regions were abnormal in patients with idiopathic cervical dystonia. Our seed region of interest in the cerebellum showed abnormal connectivity to regions in the lateral sensorimotor cortex and operculum (Fig. 5A and Supplementary Table 3). Our seed region of interest in the somatosensory cortex showed abnormal connectivity to regions in the basal ganglia, thalamus, anterior cingulate, occipital cortex, and sensorimotor cortex (Fig. 5B and Supplementary Table 3). Each of these connectivity abnormalities involved a loss of normal negative or positive connectivity (Fig. 5).

Our two regions of interest derived from brain lesions causing cervical dystonia showed greater abnormalities in idiopathic cervical dystonia patients than 19 control regions of interest derived from lesions causing other neurological symptoms (cerebellar region of interest versus control regions $P < 0.001$; somatosensory region of interest versus control regions $P < 0.001$). Average absolute t -values for all regions of interest are presented in Supplementary Table 4.

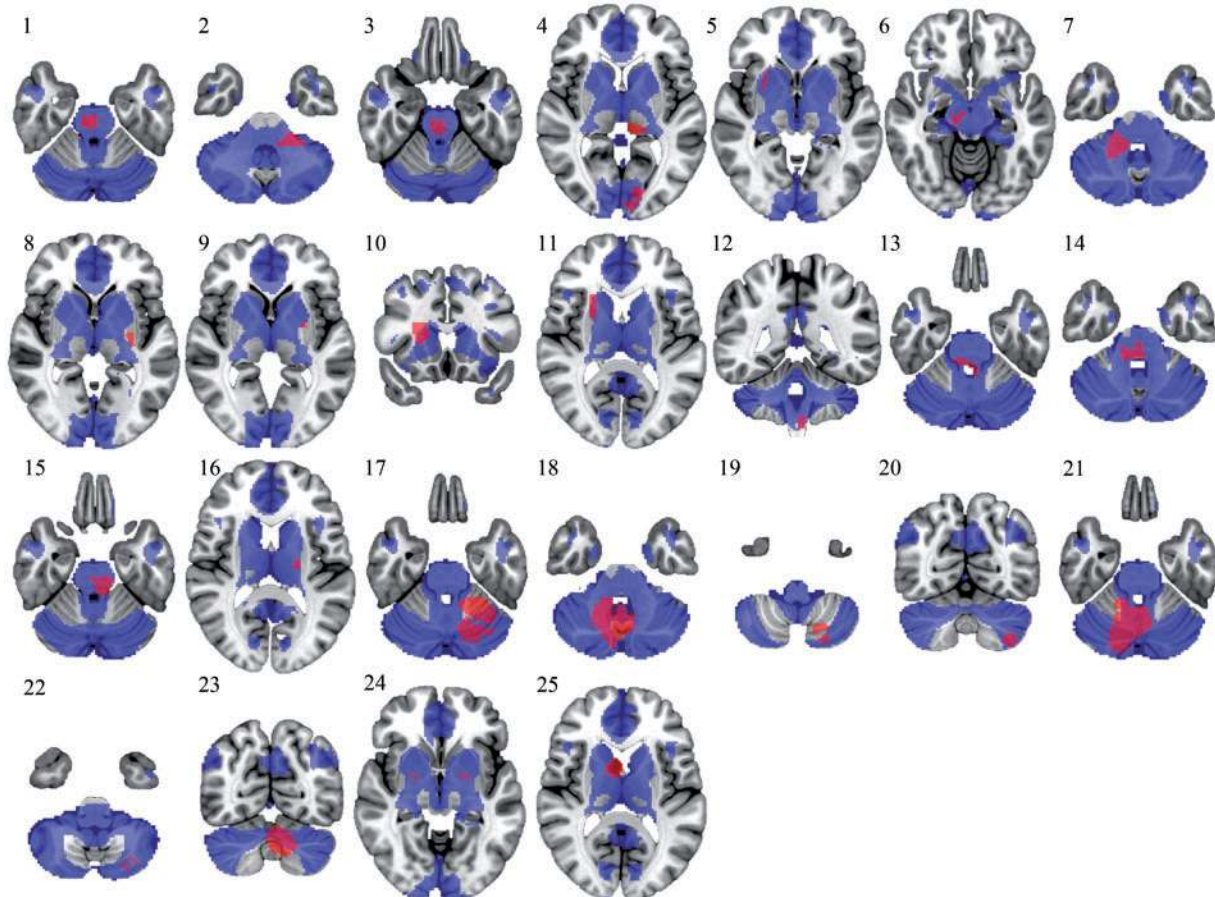


Figure 4 Lesions causing cervical dystonia are part of a commonly connected brain network. The combination of positive connectivity to our cerebellum region of interest and negative connectivity to our somatosensory region of interest defines a network of regions (blue) that encompasses 24 of 25 lesion locations causing cervical dystonia (red). Case 8 lesion location falls immediately adjacent to this network.

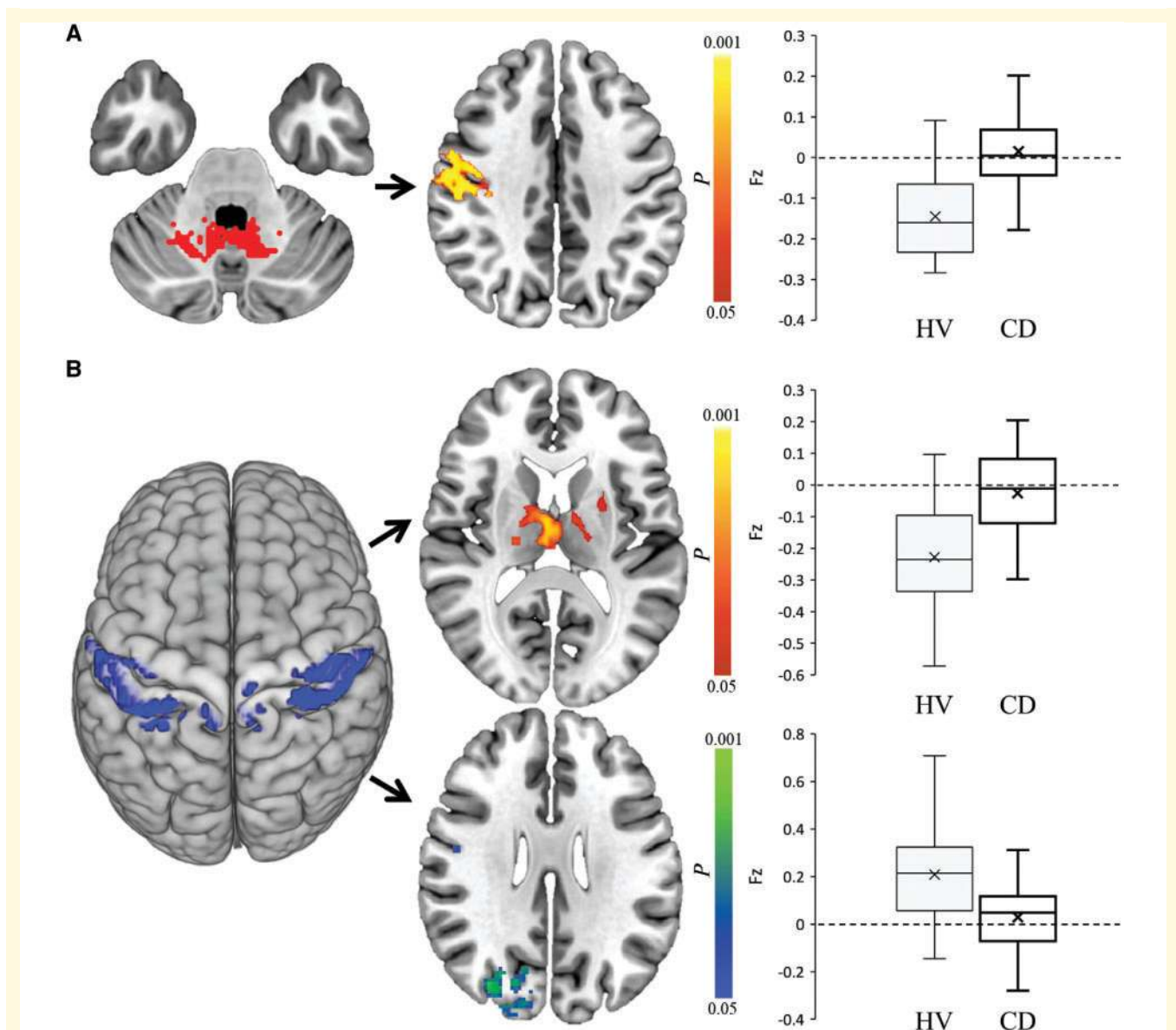


Figure 5 Relevance to idiopathic cervical dystonia. Connectivity with our lesion-derived cerebellar region of interest (**A**, red) and somatosensory region of interest (**B**, blue) is abnormal in patients with idiopathic cervical dystonia. Patients with idiopathic cervical dystonia had a loss of negative functional connectivity from our cerebellar region of interest to the right sensorimotor cortex ($z = 38$) (orange/yellow) (**A**). Patients with idiopathic cervical dystonia also had loss of negative connectivity from our somatosensory region of interest to regions in the thalamus/basal ganglia and anterior cingulate ($z = 12$) (orange/yellow), and loss of positive connectivity to the sensorimotor and occipital cortex ($z = 27$) (blue/green) (**B**). All images were corrected with threshold-free cluster enhancement $P_{FWE} < 0.05$. Corresponding average (SEM) Fischer z transformed correlation coefficients (Fz) are shown in box and whisker plots. Middle line within plot represents median, and cross shows mean. CD = idiopathic cervical dystonia patients; HV = healthy volunteers.

There was no difference in cumulative ($P = 0.69$) or relative ($P = 0.22$) in-scanner movement between cervical dystonia patients and healthy volunteers.

Relevance to deep brain stimulation treatment

Finally, we examined whether our cerebellar and somatosensory regions of interest, derived from focal brain lesions

and abnormal in patients with idiopathic cervical dystonia, were relevant to DBS treatment (Fig. 6). Our cerebellar region of interest was positively connected to DBS sites associated with good clinical response in cervical dystonia patients ($P < 0.001$) and in dystonia patients in general ($P < 0.001$), and significantly more connected to DBS sites associated with good, compared to poor, clinical response ($P = 0.002$). Our somatosensory region of interest was negatively connected with the optimal DBS site for

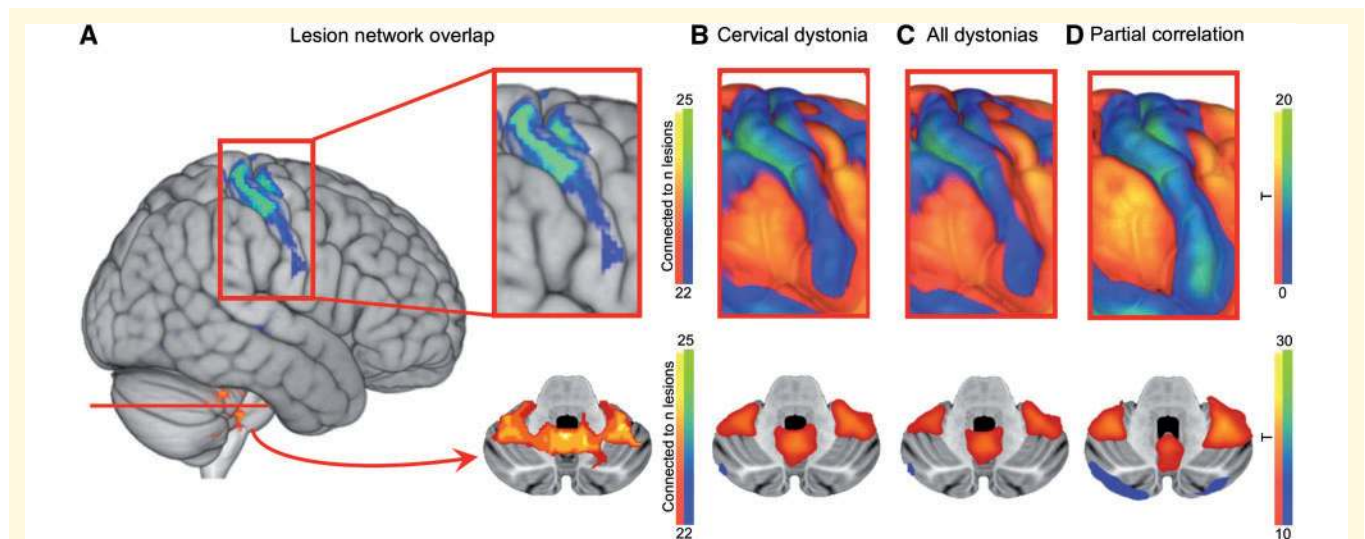


Figure 6 Relevance to deep brain stimulation. Lesions causing cervical dystonia are negatively connected to the somatosensory cortex and positively to the cerebellum (A). Globus pallidus interna DBS locations associated with good clinical response in cervical dystonia (B) and all dystonia patients (C) also show negative functional connectivity to the somatosensory cortex and positive functional connectivity to the cerebellum. Voxels associated with good response also show similar connectivity profile when controlling for voxels associated with poor response (D).

treating cervical dystonia ($P < 0.001$) and dystonia in general ($P < 0.001$) and significantly more negatively connected to DBS sites associated with good, compared to poor, responses ($P < 0.001$). Functional connectivity with these DBS sites matched the spatial topography of our cervical dystonia network derived from focal brain lesions (Fig. 6).

Discussion

There are several noteworthy findings. First, lesions causing cervical dystonia are found in heterogeneous brain locations, but are part of a single functionally connected brain network. Second, this network is defined by positive connectivity to the cerebellum and negative connectivity to the somatosensory cortex, a pattern that is specific to lesions causing cervical dystonia compared to control lesions. Finally, this network is abnormal in patients with idiopathic cervical dystonia, and also matches the connectivity pattern of DBS sites associated with dystonia symptom improvement. These findings suggest a shared neuroanatomical network for cervical dystonia independent of symptom aetiology, and illustrate how lesion network mapping can guide the search for brain abnormalities and treatment targets in non-lesion patients with similar neurological symptoms.

Lesion network mapping in cervical dystonia

It is well known that lesions causing cervical dystonia can occur in different brain locations (LeDoux *et al.*, 2003),

and connectivity with the lesion locations has been hypothesized to play a role in explaining this phenomenon (LeDoux *et al.*, 2003; Prudente *et al.*, 2014). Lesion network mapping allows for direct testing of this hypothesis by integrating brain connectivity into lesion analysis (Boes *et al.*, 2015; Fox, 2018). This technique allows one to localize lesion-induced symptoms to networks, rather than individual brain regions, and has proven useful in localization of other movement disorders (Fasano *et al.*, 2016; Laganieri *et al.*, 2016; Joutsa *et al.*, 2018a). In the present study, we localize cervical dystonia to a single brain network defined by connectivity to the cerebellum and somatosensory cortex.

The cerebellum in cervical dystonia

It has been suggested that cervical dystonia may arise from dysfunction of the cerebellum given its role in integrating motor and proprioceptive inputs to coordinate movement (LeDoux *et al.*, 2003; Jinnah *et al.*, 2006). This hypothesis is supported by functional MRI abnormalities in the cerebellum in cervical dystonia patients (Prudente *et al.*, 2016; Li *et al.*, 2017), Purkinje cell loss on human autopsy (Prudente *et al.*, 2013), and rodent studies causing dystonia via the manipulation of the cerebellum (Pizoli *et al.*, 2002; Calderon *et al.*, 2011). The present study adds to this previous work by showing that all lesion locations causing cervical dystonia are connected to the cerebellum, including the cerebellar cortex, vermis, and dentate nucleus (Fig. 3, Supplementary Table 2 and Supplementary Fig. 4).

Several studies have found normal cerebellar function or connectivity in idiopathic cervical dystonia patients, or

abnormal cerebellar function only in cervical dystonia patients with tremor (Delnooz *et al.*, 2013; Sadnicka *et al.*, 2014; Antelmi *et al.*, 2016; Bologna *et al.*, 2016; Avanzino *et al.*, 2018). Here, we found that all lesions causing cervical dystonia were connected to the cerebellum, including cases with no head tremor (Supplementary Fig. 3D). We also found abnormal cerebellar connectivity in our idiopathic cervical dystonia resting-state functional MRI dataset, composed of patients with minimal or no head tremor (Fig. 5) (Delnooz *et al.*, 2013; Prudente *et al.*, 2016). One possible explanation for these discordant findings is that cervical dystonia involves a specific region within the cerebellum, and other cerebellar regions can appear normal, or abnormal only in patients with tremor. Another possibility is that our lesion-based approach and larger cohort size allowed for increased sensitivity for cerebellar abnormalities in cervical dystonia.

The somatosensory cortex in cervical dystonia

Prior work also implicates the somatosensory cortex in the pathophysiology of cervical dystonia by demonstrating hyperactivity during head rotation (Prudente *et al.*, 2016), increased plasticity to sensorimotor stimuli (Kojovic *et al.*, 2013; Koch *et al.*, 2014), and disinhibition (Inoue *et al.*, 2004). It has been hypothesized that dystonia may result from increased proprioceptive input to the somatosensory cortex, leading to ‘motor overflow’ and co-contraction of muscles (Hallett, 2011; Kaňovský *et al.*, 2011). Our finding that lesion locations are negatively correlated to the somatosensory cortex may be consistent with this hypothesis. The interpretation of negative correlations seen with fcMRI remains a matter of debate (Murphy *et al.*, 2016); however, negative correlations may represent brain regions that are suppressed during activation of competing regions (Fox *et al.*, 2005). Based on this model, a lesion causing cervical dystonia could result in a loss of the normal suppressive input from the lesion location to the somatosensory cortex, and therefore hyperactivity in this region.

Similar results are seen in lesion-induced hallucinations. Specifically, lesions causing visual or auditory hallucinations are negatively correlated with visual and auditory cortices, respectively (Boes *et al.*, 2015). Other similarities exist between cervical dystonia and hallucinations, including hyperactivity in the relevant sensory cortical area (Prudente *et al.*, 2016; Zmigrod *et al.*, 2016), and symptom improvement with sensory input. For example, visual and auditory hallucinations can improve with visual and auditory input (Teunisse *et al.*, 1996; Corlett *et al.*, 2009), while cervical dystonia can improve with sensory or proprioceptive input, the so-called ‘geste antagoniste’ or sensory trick (Naumann *et al.*, 2000; Schramm *et al.*, 2004). The notion that cervical dystonia may be a form of sensory or proprioceptive hallucination is highly speculative, but a testable hypothesis motivated by the present findings.

The basal ganglia in cervical dystonia

Our findings emphasize the importance of the cerebellum and somatosensory cortex in defining the cervical dystonia network, but do not discount a role for the basal ganglia or other brain regions (Neychev *et al.*, 2011). For example, 24 of 25 cervical dystonia lesion locations were connected to the globus pallidus (Fig. 3A), an effective DBS target for cervical dystonia (Volkman *et al.*, 2014). However, unlike the cerebellum and somatosensory cortex, connectivity to the basal ganglia was not specific to lesions causing cervical dystonia. This is not surprising given the role of the basal ganglia in other lesion-induced symptoms, including other movement disorders included in our ‘control lesions’ sample (Fasano *et al.*, 2015; Laganier *et al.*, 2016). Similarly, treatments targeting the basal ganglia such as DBS are not specific to cervical dystonia, but are also effective for other movement disorders (Follett *et al.*, 2010). As such, connectivity to the cerebellum and somatosensory cortex are the most sensitive and specific markers of lesion-induced cervical dystonia, but this does not discount the involvement of the basal ganglia in cervical dystonia.

A two-hit model of cervical dystonia

The involvement of two distinct brain regions differs from previous ‘lesion network mapping’ studies of movement disorders where lesion locations were characterized by connectivity to just a single location (Fasano *et al.*, 2016; Laganier *et al.*, 2016; Joutsa *et al.*, 2018a). Results in cervical dystonia are similar to lesion network mapping of more complex symptoms such as hallucinations (Boes *et al.*, 2015), delusions (Darby *et al.*, 2017), and criminality (Darby *et al.*, 2018a), in which lesion locations were positively connected to one brain region and negatively connected to another. Connectivity of lesion locations to two different regions is consistent with two-hit models of symptom generation. For example, delusions are thought to require both a disruption in sensory processing and belief evaluation (Coltheart, 2010). A two-hit model has previously been proposed for dystonia (Schicatano *et al.*, 1997; Jinnah *et al.*, 2006; Neychev *et al.*, 2008), but these models usually implicate the cerebellum and basal ganglia. Our results suggest that cervical dystonia symptoms may be caused by combined dysfunction of the cerebellum and somatosensory cortex.

Relevance to idiopathic cervical dystonia

One of our most important findings is the demonstration that lesion network mapping can guide analyses of patients with similar symptoms but without brain lesions, to identify a common neuroanatomical substrate. Idiopathic and acquired cervical dystonia can be indistinguishable clinically (LeDoux *et al.*, 2003); however, unlike acquired cervical dystonia where symptoms are causally linked to a

lesion location, the brain regions causing idiopathic cervical dystonia are difficult to isolate. Neuroimaging studies have implicated many different regions and connections between regions (Delnooz *et al.*, 2013; Prudente *et al.*, 2016; Li *et al.*, 2017), and determining which abnormalities are causing symptoms, compensating for symptoms, or incidentally correlated with symptoms can prove difficult or impossible. By starting with brain lesions, we identified a network causally linked to cervical dystonia, defined by connectivity to the cerebellum and somatosensory cortex. Connectivity with these two regions thus defines a distributed brain network that encompasses lesion locations causing cervical dystonia. The fact that connectivity with these same two regions is abnormal in idiopathic cervical dystonia suggests a shared neuroanatomical substrate for idiopathic and acquired cervical dystonia. Note that connectivity need not be abnormal between these two regions to establish this convergence, as it is connectivity between each region and all other brain voxels that defines the cervical dystonia network. Finally, the fact that these two regions were significantly more abnormal than 19 other control regions suggests that lesion network mapping can help identify the location of key abnormalities in patients with similar symptoms but who do not have brain lesions.

This shared neuroanatomical substrate generates testable hypotheses for identifying and refining therapeutic targets in cervical dystonia. For example, DBS to the globus pallidus is effective for many but not all patients with cervical dystonia (Kiss *et al.*, 2007; Volkmann *et al.*, 2014). Here we show that globus pallidus DBS electrode locations associated with good clinical response have positive connectivity to the cerebellum and negative connectivity to the somatosensory cortex. This importance of brain connectivity in mediating DBS response is reminiscent of recent work in Parkinson's disease (Horn *et al.*, 2017; Joutsa *et al.*, 2018a). Similarly, transcranial magnetic stimulation to the lateral cerebellum has shown some promise in patients with cervical dystonia (Koch *et al.*, 2014), and this target could possibly be refined based on the current results. Finally, the present results highlight the somatosensory cortex as a potential therapeutic target easily amenable to non-invasive brain stimulation. Though this target has yet to be tried in cervical dystonia to our knowledge, there is some evidence that this target may provide benefit to patients with hand dystonia (Havrankova *et al.*, 2010).

Limitations

A number of limitations should be acknowledged. First, although we conducted a systematic search to collect a representative sample of brain lesions causing cervical dystonia, we cannot exclude a publication bias, as lesions in locations previously linked to cervical dystonia may be more likely to be reported. Second, there are potential limitations regarding lesion network mapping, such as drawing lesions by hand, using 2D instead of real 3D lesions, and

the use of a normative connectome dataset. However, these limitations have been addressed in detail previously and found to have little impact on lesion network mapping results (Boes *et al.*, 2015; Darby *et al.*, 2018a). Next, interpretations based on functional connectivity data are based on indirect evidence, which constrains the causal interpretation of lesion network mapping findings (Fox, 2018), and of functional connectivity abnormalities observed in patient populations (Fox *et al.*, 2010; Delnooz *et al.*, 2013; Prudente *et al.*, 2016). Finally, there have been numerous brain regions implicated in idiopathic cervical dystonia based on neuroimaging (Prudente *et al.*, 2016; Li *et al.*, 2017), and it is yet to be determined whether the subset of regions connected to causal brain lesions identified in this study will prove more central to symptom pathophysiology, or more useful as treatment targets.

Conclusions

Lesion locations causing cervical dystonia are part of a common brain network defined by connectivity to the cerebellum and the somatosensory cortex. This network, identified based on brain lesions, is abnormal in patients with idiopathic cervical dystonia, and aligns with effective DBS sites. We suggest a shared substrate for idiopathic and acquired cervical dystonia, propose a two-hit model of cervical dystonia symptoms, and provide testable hypotheses for improving treatment.

Acknowledgement

The authors wish to thank Prof. Jens Volkmann for sharing DBS localization data, and for valuable feedback on manuscript drafts.

Funding

The present work was supported by the Dorothy Feiss Dystonia Research Fund and the Dystonia Medical Research Foundation. D.C. was supported by a Victoria Fellowship awarded by the Veski Foundation. J.J. was supported by the Academy of Finland (Grant #295580), the Finnish Medical Foundation, and the Orion Research Foundation. M.D.F. was supported by K23 NS083741, R01 MH113929, the Nancy Lurie Marks Foundation, the National Parkinson's Foundation, and the Mathers Foundation. C.D. receives support from Prinses Beatrix fund and Hersenstichting. B.P.C.vdW. receives research support from Hersenstichting, ZonMW, Bioblast Pharma, and Radboud University Medical Centre. H.L. is supported by the NIH grants 1R01NS091604, P50MH106435, Beijing Municipal Science & Technology Commission grant No. Z161100002616009; and National Natural Science Foundation of China grant No. 81790652. J.J. reports travel grants from Abbvie and Orion. H.J. has active

or recent grant support from the US government (National Institutes of Health), private philanthropic organizations (the Benign Essential Blepharospasm Research Foundation, Cure Dystonia Now), academically-oriented institutions (the Dystonia Study Group), and industry (Cavion Therapeutics, Ipsen Pharmaceuticals, Retrophin Inc.). H.J. has served on advisory boards or as a consultant for Abide Therapeutics, Allergan Inc., Psyadon Pharmaceuticals, Retrophin Inc., Saol Therapeutics, and Medtronic Inc. H.J. has received honoraria or stipends for lectures or administrative work from the American Academy of Neurology, the Dystonia Medical Research Foundation, the International Neurotoxin Society, the International Parkinson's Disease and Movement Disorders Society, The Parkinson's Disease Foundation, and Tyler's Hope for a Cure. H.J. serves on the Scientific Advisory Boards for Cure Dystonia Now, the Dystonia Medical Research Foundation, Lesch-Nyhan Action France, and Tyler's Hope for a Cure. He also is principle investigator for the Dystonia Coalition, which receives the majority of its support through NIH grant TR001456 from the Office of Rare Diseases Research at the National Center for Advancing Translational Sciences, and previously NS065701 from the National Institutes of Neurological Disorders and Stroke. The Dystonia Coalition has received additional material or administrative support from industry sponsors (Allergan Inc. and Merz Pharmaceuticals) as well as private foundations (The American Dystonia Society, Beat Dystonia, The Benign Essential Blepharospasm Foundation, Cure Dystonia Now, Dystonia Inc., Dystonia Ireland, The Dystonia Medical Research Foundation, The European Dystonia Federation, The Foundation for Dystonia Research, The National Spasmodic Dysphonia Association, and The National Spasmodic Torticollis Association). M.M.R. was supported by the Interdisciplinary Center for Clinical Research (Z-3/64) of the University Hospital Würzburg and the German section of the International Federation of Clinical Neurophysiology.

Competing interests

The authors report no competing interests.

Supplementary material

Supplementary material is available at *Brain* online.

References

- Adolphs R. Human lesion studies in the 21st century. *Neuron* 2016; 90: 1151–53.
- Albanese A, Bhatia K, Bressman SB, DeLong MR, Fahn S, Fung VS, et al. Phenomenology and classification of dystonia: a consensus update. *Mov Disord* 2013; 28: 863–73.
- Antelmi E, Di Stasio F, Rocchi L, Erro R, Liguori R, Ganos C, et al. Impaired eye blink classical conditioning distinguishes dystonic patients with and without tremor. *Parkinsonism Relat Disord* 2016; 31: 23–7.
- Ashburner J. SPM: a history. *Neuroimage* 2012; 62: 791–800.
- Avanzino L, Ravaschio A, Lagravinese G, Bonassi G, Abbruzzese G, Pelosin E. Adaptation of feedforward movement control is abnormal in patients with cervical dystonia and tremor. *Clin Neurophysiol* 2018; 129: 319–26.
- Batla A, Sanchez MC, Erro R, Ganos C, Stamelou M, Balint B, et al. The role of cerebellum in patients with late onset cervical/segmental dystonia?—Evidence from the clinic. *Parkinsonism Relat Disord* 2015; 21: 1317–22.
- Behzadi Y, Restom K, Liao J, Liu TT. A component based noise correction method (CompCor) for BOLD and perfusion based fMRI. *Neuroimage* 2007; 37: 90–101.
- Boes AD, Prasad S, Liu H, Liu Q, Pascual-Leone A, Caviness VS, Jr., et al. Network localization of neurological symptoms from focal brain lesions. *Brain* 2015; 138: 3061–75.
- Bologna M, Paparella G, Fabbrini A, Leodori G, Rocchi L, Hallett M, et al. Effects of cerebellar theta-burst stimulation on arm and neck movement kinematics in patients with focal dystonia. *Clin Neurophysiol* 2016; 127: 3472–79.
- Calderon DP, Fremont R, Kraenzlin F, Khodakhah K. The neural substrates of rapid-onset Dystonia-Parkinsonism. *Nat Neurosci* 2011; 14: 357–65.
- Carrera E, Tononi G. Diaschisis: past, present, future. *Brain* 2014; 137: 2408–22.
- Chang JW, Choi JY, Lee BW, Kang UJ, Chung SS. Unilateral globus pallidus internus stimulation improves delayed onset post-traumatic cervical dystonia with an ipsilateral focal basal ganglia lesion. *J Neurol Neurosurg Psychiatry* 2002; 73: 588–90.
- Coltheart M. The neuropsychology of delusions. *Ann NY Acad Sci* 2010; 1191: 16–26.
- Corbetta M, Ramsey L, Callejas A, Baldassarre A, Hacker CD, Siegel JS, et al. Common behavioral clusters and subcortical anatomy in stroke. *Neuron* 2015; 85: 927–41.
- Corlett P, Frith CD, Fletcher P. From drugs to deprivation: a Bayesian framework for understanding models of psychosis. *Psychopharmacology* 2009; 206: 515–30.
- Darby RR, Horn A, Cushman F, Fox MD. Lesion network localization of criminal behavior. *Proc Natl Acad Sci* 2018a; 115: 601–6.
- Darby RR, Joutsa J, Burke MJ, Fox MD. Lesion network localization of free will. *Proc Natl Acad Sci* 2018b; 115: 10792–97.
- Darby RR, Laganieri S, Pascual-Leone A, Prasad S, Fox MD. Finding the imposter: brain connectivity of lesions causing delusional misidentifications. *Brain* 2017; 140: 497–507.
- Delnooz CC, Pasman JW, Beckmann CF, van de Warrenburg BP. Task-free functional MRI in cervical dystonia reveals multi-network changes that partially normalize with botulinum toxin. *PLoS one* 2013; 8: e62877.
- Diedrichsen J. A spatially unbiased atlas template of the human cerebellum. *Neuroimage* 2006; 33: 127–38.
- Diedrichsen J, Balsters JH, Flavell J, Cussans E, Ramnani N. A probabilistic MR atlas of the human cerebellum. *Neuroimage* 2009; 46: 39–46.
- Eklund A, Nichols TE, Knutsson H. Cluster failure: why fMRI inferences for spatial extent have inflated false-positive rates. *Proc Natl Acad Sci* 2016; 113: 7900–5.
- Fasano A, Herman T, Tessitore A, Strafella AP, Bohnen NI. Neuroimaging of freezing of gait. *J Parkinson's Dis* 2015; 5: 241–54.
- Fasano A, Laganieri SE, Lam S, Fox MD. Lesions causing freezing of gait localize to a cerebellar functional network. *Ann Neurol* 2016; 81: 129–41.
- Fischer DB, Boes AD, Demertzi A, Evrard HC, Laureys S, Edlow BL, et al. A human brain network derived from coma-causing brainstem lesions. *Neurology* 2016; 87: 2427–34.

- Follett KA, Weaver FM, Stern M, Hur K, Harris CL, Luo P, et al. Pallidal versus subthalamic deep-brain stimulation for Parkinson's disease. *New Engl J Med* 2010; 362: 2077–91.
- Fox MD. Mapping Symptoms to Brain Networks with the Human Connectome. *New Engl J Med* 2018; 379: 2237–45.
- Fox MD, Greicius M. Clinical applications of resting state functional connectivity. *Front Syst Neurosci* 2010; 4: 19.
- Fox MD, Snyder AZ, Vincent JL, Corbetta M, Van Essen DC, Raichle ME. The human brain is intrinsically organized into dynamic, anticorrelated functional networks. *Proc Natl Acad Sci USA* 2005; 102: 9673–78.
- Galardi G, Perani D, Grassi F, Bressi S, Amadio S, Antoni M, et al. Basal ganglia and thalamo-cortical hypermetabolism in patients with spasmodic torticollis. *Acta Neurologica Scandinavica* 1996; 94: 172–76.
- Geyer S, Ledberg A, Schleicher A, Kinomura S, Schormann T, Bürgel U, et al. Two different areas within the primary motor cortex of man. *Nature* 1996; 382: 805.
- Geyer S, Schormann T, Mohlberg H, Zilles K. Areas 3a, 3b, and 1 of human primary somatosensory cortex: 2. Spatial normalization to standard anatomical space. *Neuroimage* 2000; 11: 684–96.
- Grefkes C, Geyer S, Schormann T, Roland P, Zilles K. Human somatosensory area 2: observer-independent cytoarchitectonic mapping, interindividual variability, and population map. *Neuroimage* 2001; 14: 617–31.
- Hallett M. Neurophysiology of dystonia: the role of inhibition. *Neurobiol Dis* 2011; 42: 177–84.
- Havrankova P, Jech R, Walker ND, Operto G, Tauchmanova J, Vymazal J, et al. Repetitive TMS of the somatosensory cortex improves writer's cramp and enhances cortical activity. *Neuroendocrinol Lett* 2010; 31: 73–86.
- Holmes AJ, Hollinshead MO, O'Keefe TM, Petrov VI, Fariello GR, Wald LL, et al. Brain genomics superstruct project initial data release with structural, functional, and behavioral measures. *Sci Data* 2015; 2: 150031.
- Holmes AL, Forcelli PA, Desjardin JT, Decker AL, Teferra M, West EA, et al. Superior colliculus mediates cervical dystonia evoked by inhibition of the substantia nigra pars reticulata. *J Neurosci* 2012; 32: 13326–32.
- Horn A, Reich M, Vorwerk J, Li N, Wenzel G, Fang Q, et al. Connectivity predicts deep brain stimulation outcome in Parkinson's disease. *Ann Neurol* 2017; 82: 67–78.
- Inoue K, Hashimoto I, Shirai T, Kawakami H, Miyachi T, Mimori Y, et al. Disinhibition of the somatosensory cortex in cervical dystonia—decreased amplitudes of high-frequency oscillations. *Clin Neurophysiol* 2004; 115: 1624–30.
- Isaac K, Cohen JA. Post-traumatic torticollis. *Neurology* 1989; 39: 1642.
- Jenkinson M, Beckmann CF, Behrens TE, Woolrich MW, Smith SM. *Fsl. Neuroimage* 2012; 62: 782–90.
- Jinnah H, Hess EJ. A new twist on the anatomy of dystonia The basal ganglia and the cerebellum? *Neurology* 2006; 67: 1740–41.
- Joutsa J, Horn A, Fox MD. Localizing Parkinsonism based on focal brain lesions. *Brain* 2018a; 141: 2445–56.
- Joutsa J, Shih LC, Horn A, Reich MM, Wu O, Rost NS, et al. Identifying therapeutic targets from spontaneous beneficial brain lesions. *Ann Neurol* 2018b; 84: 153–7.
- Kajimoto Y, Miwa H, Ueno M, Kondo T. Sensorimotor hemiparesis with secondary cervical dystonia following lateral caudal medullary infarction without signs and symptoms of Wallenberg syndrome. *J Neurol Sci* 2004; 219: 167–8.
- Kaňovský P, Rosales RL. Debunking the pathophysiological puzzle of dystonia—with special reference to botulinum toxin therapy. *Parkinsonism Related Disord* 2011; 17: S11–S14.
- Kim JS. Asterixis after unilateral stroke: lesion location of 30 patients. *Neurology* 2001; 56: 533–36.
- Kirton CA, Riopelle RJ. Meige syndrome secondary to basal ganglia injury: a potential cause of acute respiratory distress. *The Canadian journal of neurological sciences. Le Journal Canadien des Sciences Neurologiques* 2001; 28: 167–73.
- Kiss ZH, Doig-Beyaert K, Eliasziw M, Tsui J, Haffenden A, Suchowersky O. The Canadian multicentre study of deep brain stimulation for cervical dystonia. *Brain* 2007; 130: 2879–86.
- Koch G, Porcacchia P, Ponzio V, Carrillo F, Cáceres-Redondo MT, Brusa L, et al. Effects of two weeks of cerebellar theta burst stimulation in cervical dystonia patients. *Brain Stimul* 2014; 7: 564–72.
- Kojovic M, Pareés I, Kassavetis P, Palomar FJ, Mir P, Teo JT, et al. Secondary and primary dystonia: pathophysiological differences. *Brain* 2013; 136: 2038–49.
- Laganieri S, Boes AD, Fox MD. Network localization of hemichorea-hemiballismus. *Neurology* 2016; 86: 2187–95.
- Lambrecq V, Sibon I, Loiseau H, Jeannin S, Dousset V, Rotgé JY, et al. Acute blepharospasm and torticollis associated with an ependymoma of the lateral ventricle. *Mov Disord* 2010; 25: 653–55.
- LeDoux M, Brady K. Secondary cervical dystonia associated with structural lesions of the central nervous system. *Mov Disord* 2003; 18: 60–9.
- Li Z, Prudente CN, Stilla R, Sathian K, Jinnah H, Hu X. Alterations of resting-state fMRI measurements in individuals with cervical dystonia. *Hum Brain Mapp* 2017; 38: 4098–4108.
- Loher TJ, Krauss JK. Dystonia associated with pontomesencephalic lesions. *Mov Disord* 2009; 24: 157–67.
- Molho ES, Factor SA. Basal ganglia infarction as a possible cause of cervical dystonia. *Mov Disord* 1993; 8: 213–16.
- Murphy K, Fox MD. Towards a consensus regarding global signal regression for resting state functional connectivity MRI. *Neuroimage* 2016; 154: 169–73.
- Naumann M, Magyar-Lehmann S, Reiners K, Erbguth F, Leenders KL. Sensory tricks in cervical dystonia: perceptual dysbalance of parietal cortex modulates frontal motor programming. *Ann Neurol* 2000; 47: 322–28.
- Naumann M, Pirker W, Reiners K, Lange KW, Becker G, Brücke T. Imaging the pre- and postsynaptic side of striatal dopaminergic synapses in idiopathic cervical dystonia: A SPECT STUDY Using [123I] epidepride and [123I] β-CIT. *Mov Disord* 1998; 13: 319–23.
- Neychev VK, Fan X, Mitev V, Hess EJ, Jinnah H. The basal ganglia and cerebellum interact in the expression of dystonic movement. *Brain* 2008; 131: 2499–509.
- Neychev VK, Gross RE, Lehericy S, Hess EJ, Jinnah H. The functional neuroanatomy of dystonia. *Neurobiol Dis* 2011; 42: 185–201.
- O'Rourke K, O'Riordan S, Gallagher J, Hutchinson M. Paroxysmal torticollis and blepharospasm following bilateral cerebellar infarction. *J Neurol* 2006; 253: 1644–45.
- Pizoli CE, Jinnah H, Billingsley ML, Hess EJ. Abnormal cerebellar signaling induces dystonia in mice. *J Neurosci* 2002; 22: 7825–33.
- Plant G, Kermod A, Du Boulay E, McDonald W. Spasmodic torticollis due to a midbrain lesion in a case of multiple sclerosis. *Mov Disord* 1989; 4: 359–62.
- Prudente C, Hess E, Jinnah H. Dystonia as a network disorder: what is the role of the cerebellum? *Neuroscience* 2014; 260: 23–35.
- Prudente C, Pardo C, Xiao J, Hanfelt J, Hess E, LeDoux M, et al. Neuropathology of cervical dystonia. *Exp Neurol* 2013; 241: 95–104.
- Prudente C, Stilla R, Buetefisch CM, Singh S, Hess EJ, Hu X, et al. Neural substrates for head movements in humans: a functional magnetic resonance imaging study. *J Neurosci* 2015; 35: 9163–72.
- Prudente C, Stilla R, Singh S, Buetefisch C, Evatt M, Factor SA, et al. A functional magnetic resonance imaging study of head movements in cervical dystonia. *Front Neurol* 2016; 7: 201.
- Reich M, Horn A, Lange F, Roothans J, Pashen S, Runge J, et al. Probabilistic mapping of the antidystonic effect of pallidal neurostimulation: a multicentre imaging study. *Brain* 2019.
- Richardson SP. Enhanced dorsal premotor–motor inhibition in cervical dystonia. *Clin Neurophysiol* 2015; 126: 1387–91.

- Rorden C, Karnath H-O, Bonilha L. Improving lesion-symptom mapping. *J Cogn Neurosci* 2007; 19: 1081–88.
- Sadnicka A, Patani B, Saifee TA, Kassavetis P, Parees I, Korlipara P, et al. Normal motor adaptation in cervical dystonia: a fundamental cerebellar computation is intact. *Cerebellum* 2014; 13: 558–67.
- Schicatanò EJ, Basso MA, Evinger C. Animal model explains the origins of the cranial dystonia benign essential blepharospasm. *J Neurophysiol* 1997; 77: 2842–46.
- Schmahmann JD, Doyon J, McDonald D, Holmes C, Lavoie K, Hurwitz AS, et al. Three-dimensional MRI atlas of the human cerebellum in proportional stereotaxic space. *Neuroimage* 1999; 10: 233–60.
- Schramm A, Reiners K, Naumann M. Complex mechanisms of sensory tricks in cervical dystonia. *Mov Disord* 2004; 19: 452–58.
- Schulze-Bonhage A, Ferbert A. Cervical dystonia as an isolated sign of a basal ganglia tumour. *J Neurol Neurosurg Psychiatry* 1995; 58: 108–109.
- Schwartz M, De Deyn P, Pickut B. Cervical dystonia as a probable consequence of focal cerebral lesion. *Mov Disord* 1995; 10: 797–98.
- Scott BL, Jankovic J. Delayed-onset progressive movement disorders after static brain lesions. *Neurology* 1996; 46: 68–74.
- Teunisse RJ, Zitman F, Cruysberg J, Hoefnagels W, Verbeek A. Visual hallucinations in psychologically normal people: Charles Bonnet's syndrome. *Lancet* 1996; 347: 794–7.
- Tranchant C, Maquet J, Eber AM, Franck P, Warte JM. Cerebellar cavernous cervical dystonia and cross cortical diaschisis. *Rev Neurol (Paris)* 1991; 147: 599–602.
- Usmani N, Bedi GS, Sengun C, Pandey A, Singer C. Late onset of cervical dystonia in a 39-year-old patient following cerebellar hemorrhage. *J Neurol* 2011; 258: 149–51.
- Volkman J, Mueller J, Deuschl G, Kühn AA, Krauss JK, Poewe W, et al. Pallidal neurostimulation in patients with medication-refractory cervical dystonia: a randomised, sham-controlled trial. *Lancet Neurol* 2014; 13: 875–84.
- von Monakow C. Die Lokalisation im Grosshirn und der Abbau der Funktion durch kortikale Herde. *JF Bergmann*, 1914.
- Winkler AM, Ridgway GR, Webster MA, Smith SM, Nichols TE. Permutation inference for the general linear model. *Neuroimage* 2014; 92: 381–97.
- Xiao J, Uitti RJ, Zhao Y, Vemula SR, Perlmutter JS, Wszolek ZK, et al. Mutations in CIZ1 cause adult onset primary cervical dystonia. *Ann Neurol* 2012; 71: 458–69.
- Yeo B, Krienen FM, Sepulcre J, Sabuncu MR, Lashkari D, Hollinshead M, et al. The organization of the human cerebral cortex estimated by intrinsic functional connectivity. *J Neurophysiol* 2011; 106: 1125–65.
- Zadro I, Brinar VV, Barun B, Ozretic D, Habek M. Cervical dystonia due to cerebellar stroke. *Mov Disord* 2008; 23: 919–20.
- Zmigrod L, Garrison JR, Carr J, Simons JS. The neural mechanisms of hallucinations: A quantitative meta-analysis of neuroimaging studies. *Neurosci Biobehav Rev* 2016; 69: 113–23.