



# Neurofibromatosis type 1: a multidisciplinary approach to care

Angela C Hirbe, David H Gutmann

*Lancet Neurol* 2014; 13: 834–43

Departments of Medicine  
(A C Hirbe MD) and Neurology  
(D H Gutmann MD),  
Washington University  
School of Medicine, St Louis,  
MO 63110, USA

Correspondence to:  
Dr David H Gutmann,  
Department of Neurology,  
St Louis, MO 63110, USA  
gutmann@neuro.wustl.edu

Neurofibromatosis type 1 is a relatively common inherited disorder. Patients have a high predisposition to develop both benign and malignant tumours. Although many manifestations of neurofibromatosis type 1 affect the nervous system, other organs and tissues can also be affected. Because of the varying features and clinical heterogeneity inherent to this disorder, patients can present to different medical and surgical specialists and, therefore, the association of clinical symptoms with neurofibromatosis type 1 might not be appreciated. Thus, for prompt diagnosis and to provide optimum care for patients with neurofibromatosis type 1, clinicians must be aware of the diverse clinical features of this disorder. We advocate a multidisciplinary approach to care, entailing a dedicated team of specialists throughout the lifetime of the patient. As our understanding of this disorder deepens through basic laboratory and clinical investigations, swift implementation of new effective treatments becomes feasible.

## Introduction

Neurofibromatosis type 1 is a relatively common inherited disorder that affects about one in 2500 to one in 3000 people worldwide, irrespective of sex or ethnic origin.<sup>1,2</sup> Individuals with neurofibromatosis type 1 are prone to develop benign and malignant tumours of the CNS and peripheral nervous system, in addition to malignant diseases affecting other parts of the body.<sup>3</sup> Tumours that

are commonly associated with the disorder include glioma of the optic pathway, glioblastoma, malignant peripheral nerve sheath tumour, gastrointestinal stromal tumour, breast cancer, leukaemia, pheochromocytoma, duodenal carcinoid tumour, and rhabdomyosarcoma (table).<sup>4–13</sup>

Neurofibromatosis type 1 was first described by Frederich von Recklinghausen in 1882. In 1987, formal diagnostic criteria were published by the National Institutes of Health (panel).<sup>14</sup> In this Review, we describe benign and malignant features of neurofibromatosis type 1, focusing on diagnostic strategies, monitoring, and treatment of tumours located in the nervous system and elsewhere. Additionally, we highlight possible future therapeutic directions based on findings of preclinical drug discovery and evaluation studies in genetically engineered mouse models of neurofibromatosis type 1-associated malignant diseases. Finally, we discuss current and future clinical trials in patients with neurofibromatosis type 1.

## Genetics and genetic testing

Neurofibromatosis type 1 is a dominantly inherited genetic disorder that results from a germline mutation in the *NF1* tumour-suppressor gene. *NF1* is located on chromosome 17q11.2 and encodes a 220 kDa cytoplasmic protein called neurofibromin. This protein functions, in part, as a negative regulator of the Ras proto-oncogene, which is a key signalling molecule in the control of cell growth.<sup>15</sup> Affected individuals start life with one mutated (non-functional) copy and one functional copy of *NF1* in every cell in their body. Although many of the clinical features of this syndrome are apparent from birth, complete loss of gene function is needed for formation of tumours, by acquisition of a somatic *NF1* mutation in selected cells.<sup>16,17</sup>

About 50% of individuals with neurofibromatosis type 1 have no family history of the disease and the disease is due to de novo (spontaneous) mutations. With the advent of accurate genetic testing, early genotype-phenotype correlations are beginning to emerge, including the observation that people with genomic microdeletions affecting the entire *NF1* gene have a more severe phenotype.<sup>18,19</sup> For instance, this particular subgroup of

	Lifetime risk
Glioma of the optic pathway	15–20%
Other brain tumour	More than fivefold increase
Malignant peripheral nerve-sheath tumour	8–13%
Gastrointestinal stromal tumour	4–25%
Breast cancer	About fivefold increase
Leukaemia	About sevenfold increase
Pheochromocytoma	0.1–5.7%
Duodenal carcinoid tumour	1%
Rhabdomyosarcoma	1.4–6%

**Table:** Lifetime risk of different tumours in children and adults with neurofibromatosis type 1

### Panel: NIH consensus criteria<sup>14</sup> for diagnosis of neurofibromatosis type 1

Two or more of the following clinical features are sufficient to establish a diagnosis of neurofibromatosis type 1:

- Six or more café-au-lait macules (>0.5 cm at largest diameter in a prepubertal child or >1.5 cm in post-pubertal individuals)
- Axillary freckling or freckling in inguinal regions
- Two or more neurofibromas of any type or one or more plexiform neurofibromas
- Two or more Lisch nodules (iris hamartomas)
- A distinctive osseous lesion (sphenoid wing dysplasia, long-bone dysplasia)
- An optic pathway glioma
- A first-degree relative with neurofibromatosis type 1 diagnosed by the above criteria

NIH=National Institutes of Health.

individuals with *NF1* microdeletions tend to develop neurofibromas at an earlier age, have a lower mean IQ, manifest abnormal facial features, and are at increased risk of developing malignant peripheral nerve-sheath tumours.<sup>19–21</sup> At present, the diagnosis of neurofibromatosis type 1 is most commonly made using established clinical criteria,<sup>14</sup> reserving *NF1* genetic testing for unusual presentations or reproductive decision-making.

## Non-malignant clinical features

### Pigmentary abnormalities

Frequently, the earliest clinical manifestation of neurofibromatosis type 1 is café-au-lait macules, which usually develop within the first 2 years of life (figure 1). The presence of more than five café-au-lait macules (>0.5 cm in diameter before puberty or >1.5 cm after puberty) is one of the diagnostic criteria for neurofibromatosis type 1. These lesions have no malignant potential and tend to darken with sun exposure and fade with advancing age. For macules that reduce quality of life, individuals can be offered dermatological camouflage treatments.<sup>22</sup>

Axillary and inguinal freckling is another common clinical feature of neurofibromatosis type 1 and is usually detected in affected individuals by age 5–8 years. These pigmentary abnormalities are typically the second diagnostic characteristic seen in children with the disorder, generally arising after development of café-au-lait macules. Freckles can also be found in areas where skinfolds are in apposition, including the neck and under the breasts in women.<sup>23</sup>

Lisch nodules are benign melanocytic hamartomas of the iris, typically first noticed in children aged 5–10 years. Nearly all adults with neurofibromatosis type 1 have Lisch nodules. These pigmented lesions are best detected on slit-lamp examination by an experienced ophthalmologist.<sup>23</sup> Lisch nodules do not impair vision or cause any medical problems.

### Neurofibromas

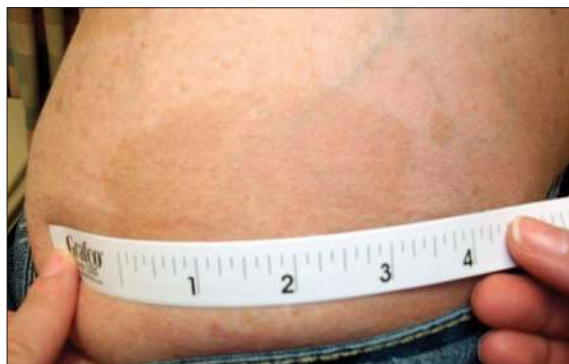Neurofibromas are benign Schwann-cell tumours composed not only of neoplastic Schwann cells<sup>24,25</sup> but also of non-neoplastic fibroblasts, mast cells, macrophages, endothelial cells, pericytes, and perineural cells.<sup>26–29</sup> There are four subtypes: cutaneous, subcutaneous, nodular or diffuse plexiform, and spinal.

Intracutaneous neurofibromas develop during late childhood or early adolescence and do not undergo malignant transformation. Owing to an abundance of mast cells associated with the tumours, these tumours might cause local pruritus. Intracutaneous neurofibromas can result in substantial discomfort or disfigurement when hundreds or thousands of these neurofibromas are present in a patient. In such instances, the tumours can be removed by a plastic surgeon.<sup>22</sup> Spinal neurofibromas can occur at single or multiple nerve roots and are associated with both sensory and motor deficits.

Although neurofibromas are commonly found on the skin—presenting as subcutaneous, dermal, or exophytic masses—they can also be located deep within the body. Individuals with neurofibromatosis type 1 generally develop more neurofibromas as they get older, and some patients can have many deep neurofibromas without clinical symptoms. In these patients, tumour removal should be led by symptoms—such as pain and functional deficits—and findings of a risk-benefit assessment.

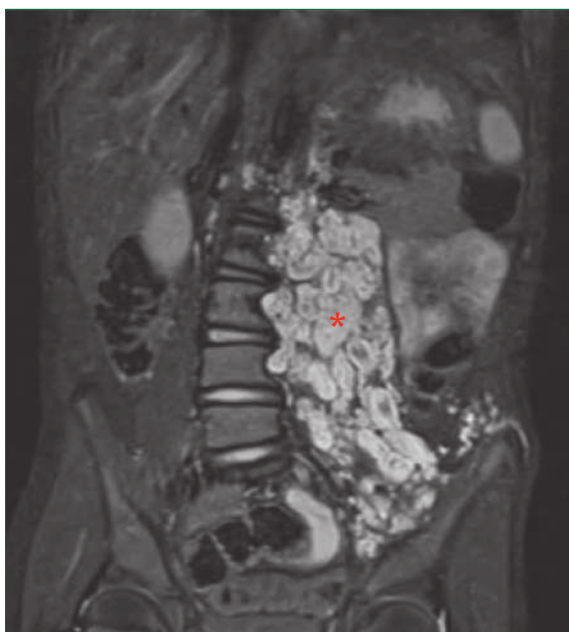### Plexiform neurofibromas

Plexiform neurofibromas typically manifest at birth but can continue to grow during adolescence and early adulthood (figure 2). In most individuals, these tumours enlarge most prominently during the first decade of life. Plexiform neurofibromas develop in about 30–50% of individuals



**Figure 1: Café-au-lait macule**

Macule on a 24-year-old woman with neurofibromatosis type 1 who was diagnosed as a young child (measuring tape shown for reference).



**Figure 2: Internal plexiform neurofibroma**

Coronal MRI shows an extensive neurofibroma (asterisk) in an 8-year-old boy with neurofibromatosis type 1.

with neurofibromatosis type 1. They differ from cutaneous neurofibromas in that they arise from multiple nerve fascicles and can grow along the length of a nerve.<sup>30</sup> These tumours can also extend into surrounding structures, causing substantial pain and bone destruction. Importantly, plexiform neurofibromas have a lifetime risk of malignant transformation. Although the best therapeutic option for symptomatic lesions is surgical removal, this approach is sometimes technically impossible.<sup>3</sup>

Chemotherapy is a potential therapeutic option for plexiform neurofibromas. In a recent phase 1 trial, pegylated interferon- $\alpha$ -2b (antiviral cytokine therapy) was assessed in 30 patients with plexiform neurofibromas who had radiographic progression before enrolment.<sup>31</sup>

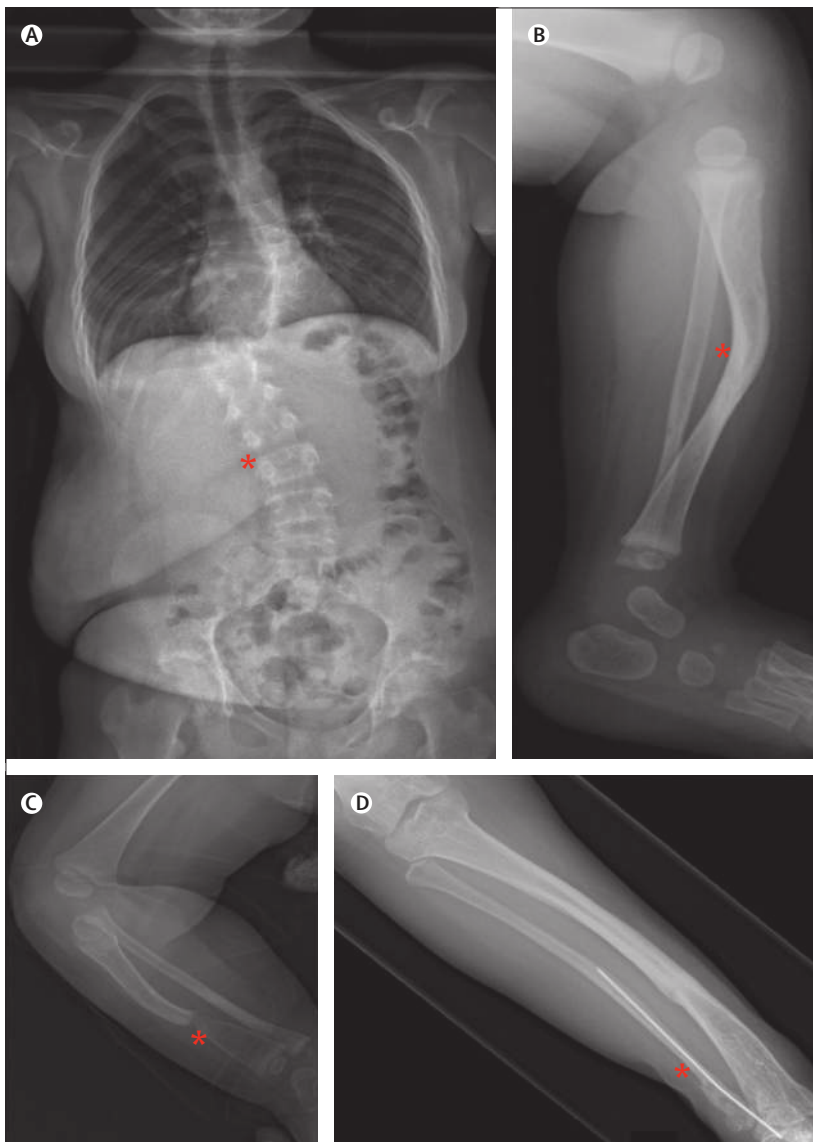
Reported effects were pain reduction (in 11 of 16 patients), decreased tumour mass (13 of 14), and tumour shrinkage or stabilisation (three of four). Similarly, in a phase 2 trial of imatinib (tyrosine kinase inhibitor), 17% of patients with plexiform neurofibromas had a 20% or more reduction in tumour volume.<sup>32</sup> In view of these initial encouraging results, several studies are now in progress to test the use of other biologically targeted therapies, including mammalian target of rapamycin (mTOR) inhibitors and mitogen-activated protein kinase kinase (MEK) inhibitors in these patients.

### Skeletal deformities

People with neurofibromatosis type 1 can develop skeletal abnormalities, including osteopenia, scoliosis, sphenoid wing dysplasia, congenital tibial dysplasia, and pseudarthrosis (figure 3). Moreover, affected individuals tend to be shorter than expected for their age and frequently have low bone-mineral densities.<sup>33</sup> In a large registry-based study of neurofibromatosis type 1, a roughly fivefold increase in fracture risk was reported for adults older than 40 years, and this risk was about threefold higher in children younger than 16 years.<sup>34</sup> Lifestyle modifications such as increased exercise and calcium or vitamin D supplementation might be warranted in these patients. Low concentrations of vitamin D have been recorded in people with neurofibromatosis type 1.<sup>33,35–38</sup> In a retrospective study of vitamin D supplementation, loss of bone-mineral density was reduced significantly in adult patients with neurofibromatosis type 1 whose vitamin D levels were maintained above 30  $\mu\text{g}/\text{L}$ , compared with people who had not been supplemented.<sup>39</sup> Although this finding suggests that all adults should be screened for vitamin D deficiency and appropriate replacements initiated, prospective studies are needed before practice recommendations are changed.

Scoliosis can affect 10–26% of individuals with neurofibromatosis type 1, making annual spinal examinations necessary during childhood and early adolescence.<sup>40</sup> Mild curvature can be treated with bracing; however, more severe cases might need surgery to stabilise progressive spinal and chest-wall deformity and preserve lung function by minimising constrictive forces.<sup>3</sup> The vertical expandable prosthetic titanium rib (VEPTR), which is used to diminish constrictive forces on the lung, has shown promise in clinical trials.<sup>41</sup> It is noteworthy that some individuals with neurofibromatosis type 1 have dystrophic scoliosis with striking curvatures and generally less satisfactory surgical outcomes than those without striking curvatures.

Sphenoid wing dysplasia typically presents as a unilateral bony defect affecting the orbital plate and the frontal bone. Sometimes, thinning or absence of the sphenoid wing is attributable to the presence of an associated orbital plexiform neurofibroma, but it can occur as an isolated bony abnormality.<sup>42</sup> These defects are usually seen in



**Figure 3: Skeletal abnormalities in individuals with neurofibromatosis type 1**  
Plain film radiographs showing: (A) dystrophic scoliosis (asterisk) in an 11-year-old girl; (B) tibial bowing (asterisk) in a 10-month-old baby girl; (C) tibial pseudarthrosis (asterisk) in a 9-month-old baby girl; and (D) tibial pseudarthrosis after insertion of an internal rod (asterisk) in a 9-year-old boy.



asymptomatic individuals after a careful physical examination in which one eye appears asymmetric or is proptotic or sunken. Congenital tibial dysplasia generally presents as anterolateral bowing of the lower leg, with cortical thinning evident on plain radiographs. The presence of bowing in an infant should warrant prompt radiographic assessment. Repeated fractures with failure to heal can lead to development of pseudarthrosis and, in some cases, limb amputation.<sup>43</sup> Referral to a skilled paediatric orthopaedic surgeon is needed to initiate appropriate treatment and avoid this poor outcome.

### Cardiovascular abnormalities

Individuals with neurofibromatosis type 1 can develop various cardiovascular abnormalities, ranging from congenital heart disease to vasculopathy and hypertension. Echocardiographic data suggest that up to 27% of patients with neurofibromatosis type 1 have a cardiovascular anomaly,<sup>44</sup> and pulmonary artery stenosis accounts for as many as 50% of these abnormalities.<sup>45</sup> The prevalence of abnormalities is likely to be an underestimate because a diagnosis is usually made only if symptoms develop. Therefore, all children born with neurofibromatosis type 1 should have a thorough cardiac examination and any murmurs should be investigated further by a skilled paediatric cardiologist.<sup>46</sup>

Neurofibromatosis type 1-related vasculopathy includes renal and cerebral artery stenosis, aortic coarctation, and arteriovenous malformations.<sup>47</sup> The pathogenesis, clinical spectrum, and natural history of these anomalies remains poorly understood; however, impaired *NF1* gene function in vascular endothelial cells results in increased proliferation and growth.<sup>27,48,49</sup> Vasculopathy usually affects the arterial system, leading to cerebrovascular disease (eg, narrowed or ectatic vessels, vascular stenosis, aneurysm, or moyamoya disease) or renal artery stenosis.<sup>47,50,51</sup> Individuals with neurofibromatosis type 1 who present with a new neurological deficit should be assessed for both cerebrovascular disease and brain tumour. Moreover, any patient with unexplained hypertension should undergo investigation for renal artery stenosis. Laboratory assessments (serum creatinine and electrolytes, plasma renin, and urinalysis), appropriate imaging studies, and arteriography are important. Although essential hypertension remains the most common reason for raised blood pressure in this population, other causes include coarctation of the aorta and pheochromocytoma. Some of these abnormalities are likely to be congenital; however, whether vascular stenoses are actually present at birth is unclear. Further study is needed to resolve these uncertainties.

### Neurocognitive deficits

Neurocognitive deficits are among the most common manifestations of neurofibromatosis type 1. Children should undergo neuropsychological screening assessments early in life, followed by more detailed testing

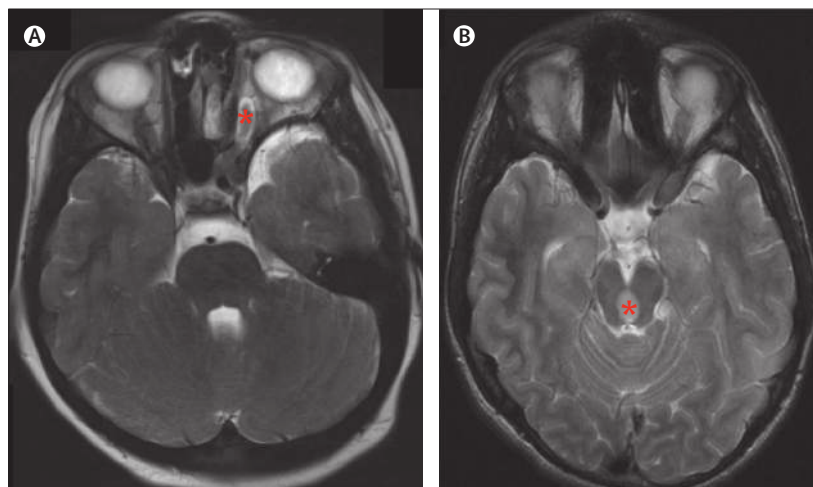
when appropriate.<sup>52</sup> Learning difficulties can include visuospatial and visuomotor deficits, language disorders, and fine and gross motor deficiencies. Furthermore, attention-deficit hyperactivity disorder, autism spectrum disorders, behavioural abnormalities, and psychosocial issues are prevalent in this population.<sup>53</sup> Children with neurofibromatosis type 1 might benefit from a multidisciplinary approach, in which educational specialists, paediatric neuropsychologists, physical therapists, speech therapists, and occupational therapists work together to maximise abilities and optimise the chance for academic and social success. Pharmacological interventions with treatments such as lovastatin<sup>54</sup> or drugs used to treat attention-deficit hyperactivity disorder (eg, methylphenidate) might be of benefit for some children.

### Nervous-system tumours

#### Optic pathway and brainstem gliomas

About 15–20% of individuals with neurofibromatosis type 1 will develop low-grade glial neoplasms; roughly 80% are in the optic pathway, but some (15%) can be present in the brainstem,<sup>22</sup> with rare involvement of the cerebellum, cortex, and subcortical regions.<sup>5</sup> Optic pathway gliomas (figure 4A) typically present in children with neurofibromatosis type 1 who are younger than 7 years.<sup>55</sup> These tumours are mainly WHO grade I glial neoplasms—termed pilocytic astrocytomas—and are indistinguishable histologically from gliomas that arise sporadically in individuals without neurofibromatosis type 1.<sup>56</sup> Although many optic pathway gliomas are asymptomatic, up to half can cause clinical symptoms, most commonly resulting in reduced vision; some children present with precocious puberty.<sup>57</sup>

Owing to the frequency of optic pathway gliomas in young children with neurofibromatosis type 1, all patients who are younger than 13 years should undergo an



**Figure 4: Low-grade glial neoplasms**

(A) MRI showing an optic glioma in the left optic nerve (asterisk) of a 4-year-old boy with neurofibromatosis type 1. (B) MRI showing a brainstem glioma (asterisk) in a 9-year-old boy with neurofibromatosis type 1.

ophthalmological examination every year by a paediatric neuro-ophthalmologist. Screening MRI is not recommended unless children are unable to undertake the ophthalmological assessment and reliable measurements of visual acuity cannot be obtained.<sup>55</sup> On identification of an optic glioma, current recommendations include ophthalmological and MRI studies four times a year for the first year, followed by gradual lengthening of test intervals over the next 2–3 years. A two-line decrease in visual acuity, as measured by a standardised visual assessment procedure such as the Snellen chart, warrants referral to a paediatric neuro-oncologist for treatment.<sup>58</sup>

Surgery plays little part in the treatment of optic pathway gliomas because it can result in permanent neurological damage.<sup>58</sup> First-line treatment for most patients with symptomatic tumours is chemotherapy with carboplatin and vincristine.<sup>59</sup> Other chemotherapy combinations have been used; however, no randomised trial data are available to support the use of one regimen over another.<sup>60</sup> Cranial radiation therapy is not recommended for patients with neurofibromatosis type 1 because of the increased propensity of this population to develop second malignancies, vascular abnormalities, and neuropsychological difficulties.<sup>10,61</sup>

Brainstem gliomas are the most frequently discovered brain tumor outside of the optic pathway in people with neurofibromatosis type 1.<sup>22</sup> Similar to optic pathway tumours, brainstem gliomas (figure 4B) are usually pilocytic astrocytomas; however, they typically present later in the first decade of life. Affected children might come to medical attention with cranial neuropathies, lethargy, gait instability, or headaches. Chemotherapy is used to treat clinically progressive tumours, with drugs such as carboplatin or vincristine, as would be administered for other low-grade gliomas in the paediatric population.

### Glioblastomas

Individuals with neurofibromatosis type 1 have at least a fivefold increased risk for developing other brain tumours, including WHO grade IV astrocytomas (glioblastomas), according to findings of several case reports and small retrospective studies.<sup>9,62–64</sup> Glioblastomas usually present in young adults,<sup>65</sup> in whom the overall prognosis is poor. Treatment is similar to that for people with sporadic glioblastomas and usually entails gross surgical resection followed by adjuvant radiation and chemotherapy (typically oral temozolomide).

### Malignant peripheral nerve sheath tumours

Malignant peripheral nerve sheath tumours—sometimes referred to as neurofibrosarcomas or neurogenic sarcomas—are a subtype of sarcoma with a presumed Schwann cell origin. These tumours represent about 3–10% of all soft-tissue sarcomas, and a large proportion arise in individuals with neurofibromatosis type 1.<sup>66</sup> Malignant peripheral nerve sheath tumours

have a prevalence of 0.001% in the general population versus 0.1% in individuals with neurofibromatosis type 1.<sup>66,67</sup> The cumulative lifetime risk of developing malignant peripheral nerve sheath tumours in a patient with neurofibromatosis type 1 is about 8–13%.<sup>68</sup> Malignant peripheral nerve sheath tumours can arise anywhere within the body. Risk for developing a malignant peripheral nerve sheath tumour is increased 20-fold in the area of an existing internal plexiform neurofibroma.<sup>69</sup> Other risk factors for development of malignant peripheral nerve sheath tumours include previous radiation therapy and large germline mutations encompassing the entire *NF1* gene (microdeletions).<sup>21</sup>

Individuals with neurofibromatosis type 1 who report substantial or difficult-to-control pain, a rapid increase in the size of an existing plexiform neurofibroma, a change in tumour consistency (soft to hard), or a new neurological deficit warrant prompt assessment for malignant peripheral nerve sheath tumours.<sup>67</sup> MRI is helpful to define the location and extent of the tumour, but it is not reliable for distinguishing between malignant disease and benign tumours. Over the past decade, <sup>18</sup>F-fluorodeoxyglucose (<sup>18</sup>F-FDG)-PET has emerged as a highly sensitive and specific method for detection of malignant peripheral nerve sheath tumours (figure 5).<sup>70–72</sup> Needle biopsy can be affected by sampling bias and might not allow the treating clinician to exclude a diagnosis of malignant peripheral nerve sheath tumour with confidence.<sup>67</sup> Furthermore, patients with suspected malignant disease should be examined for evidence of metastatic disease (eg, in the lung or bone). In view of the aggressive nature of malignant peripheral nerve sheath tumours, patients should be assessed and managed by a multidisciplinary team including neurologists, radiologists, surgeons, oncologists, and radiation oncologists to efficiently implement plans for biopsy (non-invasive or open) and treatment.

Surgery is the only curative treatment option for patients with malignant peripheral nerve sheath tumours.<sup>73</sup> Even with surgical excision, 5-year overall survival rates are poor,<sup>6,74</sup> and this cancer represents a substantial cause of mortality in individuals with neurofibromatosis type 1.<sup>9</sup> Some findings suggest that survival is beginning to increase, particularly in women; however, this rise might be attributable to heightened recognition and identification of malignant peripheral nerve sheath tumours at an earlier stage.<sup>75</sup> Although radiation therapy could delay time to recurrence, this treatment does not change time to death.<sup>67,76</sup> Use of adjuvant chemotherapy is controversial.<sup>77,78</sup> In some instances, chemotherapy can be used in the neoadjuvant setting to downstage tumours before resection; however, this practice has not been adopted widely.<sup>67</sup> Clinical studies of promising chemotherapy drugs are underway in individuals with neurofibromatosis type 1-associated malignant peripheral nerve sheath tumours. In patients with metastatic disease, single-agent anthracycline is the most accepted form of palliative care.<sup>67,79</sup>

## Non-nervous-system tumours

### Gastrointestinal stromal tumours

Gastrointestinal stromal tumours are of mesenchymal origin and can develop anywhere along the gastrointestinal tract. Compared with the general population, individuals with neurofibromatosis type 1 are slightly younger at presentation (median age 50 years vs 60 years)<sup>80,81</sup> and about 95% are asymptomatic. Moreover, patients with neurofibromatosis type 1 and gastrointestinal stromal tumours more frequently present with multiple tumours compared with the general population.<sup>82</sup> The most common symptoms reported are abdominal pain, bleeding, intestinal perforation, and intestinal obstruction.<sup>66,83</sup> Gastrointestinal stromal tumours can be an incidental finding during imaging studies, might be spotted during surgery to remove another tumour, or could be diagnosed from presenting symptoms.

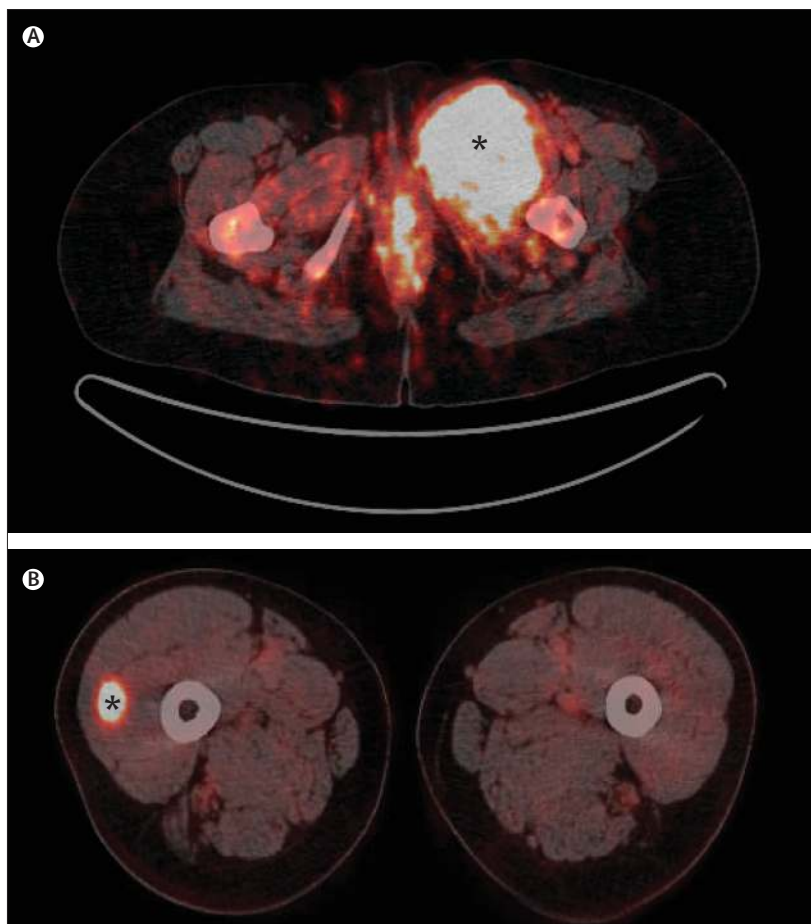
In the general population, gastrointestinal stromal tumours are associated with increased expression of the KIT and PDGFRA transmembrane receptors. Activation of these receptor tyrosine kinases drives proliferation, providing the scientific basis for treatment with imatinib.<sup>80,84</sup> By contrast, in patients with neurofibromatosis type 1, gastrointestinal stromal tumours typically do not overexpress KIT or PDGFRA,<sup>85</sup> which limits the use of imatinib in this population.<sup>86,87</sup> Currently, the only treatment option for neurofibromatosis type 1-associated gastrointestinal stromal tumours is surgery, if feasible. Clinical trials of other tyrosine kinase receptor inhibitors (eg, sunitinib) are ongoing in patients with metastatic disease.<sup>88</sup>

### Breast cancers

A fivefold increased risk for breast cancer has been reported in individuals with neurofibromatosis type 1, mainly affecting women younger than 50 years.<sup>8,13,89,90</sup> Furthermore, mortality rates in women with neurofibromatosis type 1 and breast cancer are higher than those for women with breast cancer in the general population.<sup>91</sup> Although reported studies include only a few patients, relative risks are similar to those for people with a family history of breast cancer. Women age 30–49 years with neurofibromatosis type 1 could undergo early mammography or MRI;<sup>92</sup> however, large prospective studies are needed before formal recommendations can be made about screening in this population. Currently, treatment for neurofibromatosis type 1-associated breast cancer does not differ from that for women with breast cancer in the general population.

### Leukaemia and lymphoma

Children with neurofibromatosis type 1 have at least a sevenfold higher risk for developing myeloid leukaemia compared with children in the general population,<sup>93</sup> and the prevalence of chronic myelomonocytic leukaemia, juvenile chronic myelogenous leukaemia, acute lymphocytic leukaemia, and non-Hodgkin lymphoma is also



**Figure 5: Malignant peripheral nerve-sheath tumours**

<sup>18</sup>F-FDG-PET images showing malignant peripheral nerve-sheath tumours (asterisks) in (A) a 24-year-old woman and (B) a 29-year-old man, both with neurofibromatosis type 1. FDG=fluorodeoxyglucose.

raised.<sup>94,95</sup> However, these tumours are rare in people with neurofibromatosis type 1. Moreover, no evidence is available to support a difference in prognosis between neurofibromatosis type 1-associated leukaemia and lymphoma relative to the general population. Treatments for neurofibromatosis type 1-associated leukaemia parallel those used for individuals without neurofibromatosis type 1.<sup>95</sup>

### Phaeochromocytoma

Phaeochromocytomas—catecholamine-secreting tumours of the adrenal medulla or other sites in the sympathetic nervous system—are seen at increased frequency in individuals with neurofibromatosis type 1. These tumours arise in 0.1–5.7% of people with neurofibromatosis type 1 compared with 0.002–0.008% of the general population. The age of onset (typically the fourth decade of life) is similar in neurofibromatosis type 1-associated and sporadic cases.<sup>12,96</sup> Phaeochromocytomas should be suspected in an individual with neurofibromatosis type 1 who presents with unexplained hypertension, flushing,

headaches, sweating, or heart palpitations. Diagnosis is established typically with a combination of imaging studies (CT or MRI of the chest and abdomen or a meta-iodobenzyl-guanidine scan or somatostatin scintigraphy if CT is negative) and biochemical assessments (eg, the amount of catecholamines in urine).<sup>97</sup> Surgery is curative for resectable disease,<sup>98</sup> whereas chemotherapy or radiopharmaceutical treatment with <sup>131</sup>I-meta-iodobenzyl-guanidine is used for metastatic or unresectable cancers.<sup>99,100</sup>

### Duodenal carcinoids

Carcinoid tumours are neuroendocrine tumours that arise from endocrine cells within the gastrointestinal tract; they are reported in about 1% of individuals with neurofibromatosis type 1.<sup>7,101</sup> The most common site for carcinoid tumours is the periampullary region;<sup>4,66</sup> therefore, individuals usually present with jaundice and non-specific abdominal pain. In patients with neurofibromatosis type 1, these tumours generally present at a young age.<sup>101,102</sup> The diagnosis of carcinoid tumours is typically made with a combination of imaging studies—eg, CT of the chest, abdomen, and pelvis, somatostatin scintigraphy, and endoscopic ultrasound or endoscopy—and measurement of urinary and serum 5-hydroxyindoleacetic acid and chromogranin A, when clinically appropriate.<sup>101</sup> Surgical resection should be done if possible; unresectable and metastatic disease is treated generally with somatostatin analogues or chemotherapy.<sup>101,103</sup>

### Rhabdomyosarcomas

Rhabdomyosarcomas are non-neurogenic sarcomas composed of small round blue cells that probably originate from the neural crest.<sup>66</sup> Children with neurofibromatosis type 1 have about a 20-fold increased risk of developing these tumours.<sup>11</sup> Rhabdomyosarcomas most commonly present as palpable masses. Management relies on surgical resection when feasible, whereas adjuvant chemotherapy and radiation therapy might be appropriate for some individuals.<sup>104,105</sup>

### Conclusions and future directions

Over the past 15 years, substantial advances have been made in our ability to discover, validate, and translate laboratory-based research findings to the clinical workplace. Many accurate preclinical models of neurofibromatosis type 1-associated malignant disease in genetically engineered mice have been developed and used as platforms to evaluate rational targeted treatments.<sup>106–114</sup>

Although these models have some limitations, they have already proven useful in the design and implementation of human clinical trials.

After identification of *NF1* as a negative Ras regulator,<sup>115–117</sup> findings of several preclinical studies in *Nf1*-deficient mice have shown that inhibition of downstream targets of Ras attenuates *Nf1*-deficient tumour cell growth in vitro and in vivo. For example, in studies of genetically engineered *Nf1* mice, rapamycin analogues (eg, everolimus) and MEK inhibitors were effective biologically targeted treatments for neurofibromatosis type 1-associated plexiform neurofibroma,<sup>118,119</sup> and rapamycin analogues and chemokine receptor inhibitors were assessed for neurofibromatosis type 1-associated glioma and malignant peripheral nerve sheath tumours.<sup>120–123</sup>

Models of optic pathway glioma<sup>109,124</sup> and plexiform neurofibroma<sup>108</sup> in genetically engineered *Nf1* mice showed that non-cancerous stromal cells (tumour microenvironment) have important roles in tumour development and growth. Loss of *Nf1* in Schwann cell and astroglial cell precursors alone was not sufficient for tumorigenesis; loss of *Nf1* expression in Schwann cell or astroglial cell precursors must occur in *Nf1*+/- mice (genetically comparable with individuals with neurofibromatosis type 1) for neurofibromas and optic gliomas, respectively, to form.<sup>108,109,124</sup> Further investigation of participatory stromal cell types in models of optic pathway gliomas and plexiform neurofibromas in genetically engineered *Nf1* mice indicates an obligatory role for microglia and mast cells, respectively, in the genesis and maintenance of these tumours.<sup>125–127</sup> The finding that mast cells are important micro-environmental drivers of plexiform neurofibroma growth culminated in use of imatinib to inhibit c-kit function in preclinical studies in *Nf1* mice and the translation of these results to human clinical trials.<sup>32</sup>

Although studies of these genetically engineered *Nf1* mice hold substantial promise, future studies need to report clearly positive findings to facilitate effective translation to human clinical trials. Thus, preclinical response criteria should incorporate the proportion of mice with significant radiographic responses, the durability of these outcomes, and the extent of tumour shrinkage. Pharmacokinetic and pharmacodynamic considerations will also need to be integrated into these criteria to ensure a high likelihood of success in patients.

With the establishment of the Neurofibromatosis Clinical Trials Consortium (NFCTC),<sup>128</sup> therapeutic trials in large numbers of individuals with neurofibromatosis type 1-associated malignant disease can now be undertaken efficiently. Up to now, the NFCTC has initiated several clinical trials, including studies of sorafenib for neurofibromatosis type 1-associated plexiform neurofibromas (NCT00727233), bevacizumab and everolimus for malignant peripheral nerve sheath tumours (NCT01661283), everolimus for progressive neurofibromatosis type 1-associated glioma (NCT01158651),

#### Search strategy and selection criteria

We searched PubMed between January, 1970, and March, 2014, with the terms: "NF1", "skin", "bone", "cardiovascular", "neurocognitive", "plexiform", "malignancy", "optic pathway glioma", "GBM", "MPNST", "breast cancer", "leukemia", "GIST", "pheochromocytoma", "duodenal carcinoids", and "rhabdomyosarcoma". We also chose references from selected articles. We did not restrict our search by language.



MEK inhibitors for children with inoperable neurofibromatosis type 1-associated plexiform neurofibromas (NCT01362803), and MEK inhibitors for patients with tumours activated by RAS, RAF, or MEK, including those with mutations in the *NF1* gene (NCT01885195).

Tumours that develop in patients with neurofibromatosis type 1 are heterogeneous from a molecular and cellular perspective and, therefore, represent complex cancers in which distinct cell types and growth-control pathways regulate tumour behaviour. With availability of accurate preclinical mouse models for most tumour types in neurofibromatosis type 1, a detailed understanding of neurofibromin-controlled signalling pathways, and availability of a clinical trials infrastructure for rapid drug evaluation, we can now envision a future in which effective treatments for people with neurofibromatosis type 1-associated tumours are imminent.

#### Contributors

ACH wrote the manuscript and prepared the figures. DHG edited the manuscript.

#### Declaration of interests

We declare no competing interests.

#### References

- Lammert M, Friedman JM, Kluwe L, Mautner VF. Prevalence of neurofibromatosis 1 in German children at elementary school enrollment. *Arch Dermatol* 2005; **141**: 71–74.
- Huson SM, Harper PS, Compston DA. Von Recklinghausen neurofibromatosis: a clinical and population study in south-east Wales. *Brain* 1988; **111**: 1355–81.
- Williams VC, Lucas J, Babcock MA, Gutmann DH, Korf B, Maria BL. Neurofibromatosis type 1 revisited. *Pediatrics* 2009; **123**: 124–33.
- Brems H, Beert E, de Ravel T, Legius E. Mechanisms in the pathogenesis of malignant tumours in neurofibromatosis type 1. *Lancet Oncol* 2009; **10**: 508–15.
- Crouse NR, Dahiya S, Gutmann DH. Rethinking pediatric gliomas as developmental brain abnormalities. *Curr Top Dev Biol* 2011; **94**: 283–308.
- Ducatman BS, Scheithauer BW, Piepgras DG, Reiman HM, Ilstrup DM. Malignant peripheral nerve sheath tumors: a clinicopathologic study of 120 cases. *Cancer* 1986; **57**: 2006–21.
- Dayal Y, Tallberg KA, Nunnemacher G, DeLellis RA, Wolfe HJ. Duodenal carcinoids in patients with and without neurofibromatosis: a comparative study. *Am J Surg Pathol* 1986; **10**: 348–57.
- Madanikia SA, Bergner A, Ye X, Blakeley JO. Increased risk of breast cancer in women with NF1. *Am J Med Genet A* 2012; **158A**: 3056–60.
- Rasmussen SA, Yang Q, Friedman JM. Mortality in neurofibromatosis 1: an analysis using US death certificates. *Am J Hum Genet* 2001; **68**: 1110–18.
- Sharif S, Ferner R, Birch JM, et al. Second primary tumors in neurofibromatosis 1 patients treated for optic glioma: substantial risks after radiotherapy. *J Clin Oncol* 2006; **24**: 2570–75.
- Sung L, Anderson JR, Arndt C, Raney RB, Meyer WH, Pappo AS. Neurofibromatosis in children with rhabdomyosarcoma: a report from the Intergroup Rhabdomyosarcoma study IV. *J Pediatr* 2004; **144**: 666–68.
- Walther MM, Herring J, Enquist E, Keiser HR, Linehan WM. von Recklinghausen's disease and pheochromocytomas. *J Urol* 1999; **162**: 1582–86.
- Wang X, Levin AM, Smolinski SE, Vigneau FD, Levin NK, Tainsky MA. Breast cancer and other neoplasms in women with neurofibromatosis type 1: a retrospective review of cases in the Detroit metropolitan area. *Am J Med Genet A* 2012; **158A**: 3061–64.
- Anon. National Institutes of Health Consensus Development Conference Statement: neurofibromatosis—Bethesda, MD, USA, July 13–15, 1987. *Neurofibromatosis* 1988; **1**: 172–78.
- Gutmann DH, Parada LF, Silva AJ, Ratner N. Neurofibromatosis type 1: modeling CNS dysfunction. *J Neurosci* 2012; **32**: 14087–93.
- Ruggieri M, Packer RJ. Why do benign astrocytomas become malignant in NF1? *Neurology* 2001; **56**: 827–29.
- Gutmann DH, McLellan MD, Hussain I, et al. Somatic neurofibromatosis type 1 (NF1) inactivation characterizes NF1-associated pilocytic astrocytoma. *Genome Res* 2013; **23**: 431–39.
- Kayes LM, Burke W, Riccardi VM, et al. Deletions spanning the neurofibromatosis 1 gene: identification and phenotype of five patients. *Am J Hum Genet* 1994; **54**: 424–36.
- Cnossen MH, van der Est MN, Breuning MH, et al. Deletions spanning the neurofibromatosis type 1 gene: implications for genotype-phenotype correlations in neurofibromatosis type 1? *Hum Mutat* 1997; **9**: 458–64.
- Leppig KA, Kaplan P, Viskochil D, Weaver M, Ortenberg J, Stephens K. Familial neurofibromatosis 1 microdeletions: cosegregation with distinct facial phenotype and early onset of cutaneous neurofibromata. *Am J Med Genet* 1997; **73**: 197–204.
- De Raedt T, Brems H, Wolkenstein P, et al. Elevated risk for MPNST in NF1 microdeletion patients. *Am J Hum Genet* 2003; **72**: 1288–92.
- Ferner RE, Huson SM, Thomas N, et al. Guidelines for the diagnosis and management of individuals with neurofibromatosis 1. *J Med Genet* 2007; **44**: 81–88.
- Friedman JM. Neurofibromatosis 1: clinical manifestations and diagnostic criteria. *J Child Neurol* 2002; **17**: 548–54.
- Wu M, Wallace MR, Muir D. Tumorigenic properties of neurofibromin-deficient Schwann cells in culture and as syngrafts in Nf1 knockout mice. *J Neurosci Res* 2005; **82**: 357–67.
- Rutkowski JL, Wu K, Gutmann DH, Boyer PJ, Legius E. Genetic and cellular defects contributing to benign tumor formation in neurofibromatosis type 1. *Hum Mol Genet* 2000; **9**: 1059–66.
- Le IQ, Parada LF. Tumor microenvironment and neurofibromatosis type 1: connecting the GAPS. *Oncogene* 2007; **26**: 4609–16.
- Munchhof AM, Li F, White HA, et al. Neurofibroma-associated growth factors activate a distinct signaling network to alter the function of neurofibromin-deficient endothelial cells. *Hum Mol Genet* 2006; **15**: 1858–69.
- Yang FC, Ingram DA, Chen S, et al. Neurofibromin-deficient Schwann cells secrete a potent migratory stimulus for Nf1+/- mast cells. *J Clin Invest* 2003; **112**: 1851–61.
- Yang FC, Ingram DA, Chen S, et al. Nf1-dependent tumors require a microenvironment containing Nf1+/- and c-kit-dependent bone marrow. *Cell* 2008; **135**: 437–48.
- Nguyen R, Kluwe L, Fuensterer C, Kentsch M, Friedrich RE, Mautner VF. Plexiform neurofibromas in children with neurofibromatosis type 1: frequency and associated clinical deficits. *J Pediatr* 2011; **159**: 652–55.e2.
- Jakacki RI, Dombi E, Potter DM, et al. Phase I trial of pegylated interferon-alpha-2b in young patients with plexiform neurofibromas. *Neurology* 2011; **76**: 265–72.
- Robertson KA, Nalepa G, Yang F-C, et al. Imatinib mesylate for plexiform neurofibromas in patients with neurofibromatosis type 1: a phase 2 trial. *Lancet Oncol* 2012; **13**: 1218–24.
- Tucker T, Schnabel C, Hartmann M, et al. Bone health and fracture rate in individuals with neurofibromatosis 1 (NF1). *J Med Genet* 2009; **46**: 259–65.
- Heervä E, Koffert A, Jokinen E, et al. A controlled register-based study of 460 neurofibromatosis 1 patients: increased fracture risk in children and adults over 41 years of age. *J Bone Miner Res* 2012; **27**: 2333–37.
- Brunetti-Pierri N, Doty SB, Hicks J, et al. Generalized metabolic bone disease in neurofibromatosis type I. *Mol Genet Metab* 2008; **94**: 105–11.
- Heervä E, Huilaja L, Leinonen P, Peltonen S, Peltonen J. Follow-up of six patients with neurofibromatosis 1-related osteoporosis treated with alendronate for 23 months. *Calcif Tissue Int* 2014; published online Jan 4. DOI:10.1007/s00223-013-9835-2.
- Petramala L, Giustini S, Zinnamosca L, et al. Bone mineral metabolism in patients with neurofibromatosis type 1 (von Recklinghausen disease). *Arch Dermatol Res* 2012; **304**: 325–31.
- Stevenson DA, Moyer-Mileur LJ, Murray M, et al. Bone mineral density in children and adolescents with neurofibromatosis type 1. *J Pediatr* 2007; **150**: 83–88.



- 39 Schnabel C, Jett K, Friedman JM, Frieling I, Kruse HP, Mautner V. Effect of vitamin D3 treatment on bone density in neurofibromatosis 1 patients: a retrospective clinical study. *Joint Bone Spine* 2013; **80**: 315–19.
- 40 Akbarnia BA, Gabriel KR, Beckman E, Chalk D. Prevalence of scoliosis in neurofibromatosis. *Spine* 1992; **17** (suppl): S244–48.
- 41 White KK, Song KM, Frost N, Daines BK. VEPTR™ growing rods for early-onset neuromuscular scoliosis: feasible and effective. *Clin Orthop Relat Res* 2011; **469**: 1335–41.
- 42 Arrington DK, Danehy AR, Peleggi A, Proctor MR, Irons MB, Ullrich NJ. Calvarial defects and skeletal dysplasia in patients with neurofibromatosis type 1. *J Neurosurg Pediatr* 2013; **11**: 410–16.
- 43 Alwan S, Armstrong L, Joe H, Birch PH, Szudek J, Friedman JM. Associations of osseous abnormalities in neurofibromatosis 1. *Am J Med Genet A* 2007; **143A**: 1326–33.
- 44 Tedesco MA, Di Salvo G, Natale F, et al. The heart in neurofibromatosis type 1: an echocardiographic study. *Am Heart J* 2002; **143**: 883–88.
- 45 Lin AE, Birch PH, Korf BR, et al. Cardiovascular malformations and other cardiovascular abnormalities in neurofibromatosis 1. *Am J Med Genet* 2000; **95**: 108–17.
- 46 Friedman JM, Arbiser J, Epstein JA, et al. Cardiovascular disease in neurofibromatosis 1: report of the NF1 Cardiovascular Task Force. *Genet Med* 2002; **4**: 105–11.
- 47 Oderich GS, Sullivan TM, Bower TC, et al. Vascular abnormalities in patients with neurofibromatosis syndrome type I: clinical spectrum, management, and results. *J Vasc Surg* 2007; **46**: 475–84.
- 48 Li F, Downing BD, Smiley LC, et al. Neurofibromin deficient myeloid cells are critical mediators of aneurysm formation in vivo. *Circulation* 2014; **129**: 1213–24.
- 49 Bajaj A, Li QF, Zheng Q, Pumiglia K. Loss of NF1 expression in human endothelial cells promotes autonomous proliferation and altered vascular morphogenesis. *PLoS One* 2012; **7**: e49222.
- 50 Rosser TL, Vezina G, Packer RJ. Cerebrovascular abnormalities in a population of children with neurofibromatosis type 1. *Neurology* 2005; **64**: 553–55.
- 51 Rea D, Brandsema JF, Armstrong D, et al. Cerebral arteriopathy in children with neurofibromatosis type 1. *Pediatrics* 2009; **124**: e476–83.
- 52 Hyman SL, Shores A, North KN. The nature and frequency of cognitive deficits in children with neurofibromatosis type 1. *Neurology* 2005; **65**: 1037–44.
- 53 Acosta MT, Gioia GA, Silva AJ. Neurofibromatosis type 1: new insights into neurocognitive issues. *Curr Neurol Neurosci Rep* 2006; **6**: 136–43.
- 54 Acosta MT, Kardel PG, Walsh KS, Rosenbaum KN, Gioia GA, Packer RJ. Lovastatin as treatment for neurocognitive deficits in neurofibromatosis type 1: phase I study. *Pediatr Neurol* 2011; **45**: 241–45.
- 55 Albers AC, Gutmann DH. Gliomas in patients with neurofibromatosis type 1. *Expert Rev Neurother* 2009; **9**: 535–39.
- 56 Leonard JR, Perry A, Rubin JB, King AA, Chicoine MR, Gutmann DH. The role of surgical biopsy in the diagnosis of glioma in individuals with neurofibromatosis-1. *Neurology* 2006; **67**: 1509–12.
- 57 King A, Listerick R, Charrow J, Piersall L, Gutmann DH. Optic pathway gliomas in neurofibromatosis type 1: the effect of presenting symptoms on outcome. *Am J Med Genet A* 2003; **122A**: 95–99.
- 58 Listerick R, Ferner RE, Liu GT, Gutmann DH. Optic pathway gliomas in neurofibromatosis-1: controversies and recommendations. *Ann Neurol* 2007; **61**: 189–98.
- 59 Packer RJ, Ater J, Allen J, et al. Carboplatin and vincristine chemotherapy for children with newly diagnosed progressive low-grade gliomas. *J Neurosurg* 1997; **86**: 747–54.
- 60 Ater JL, Zhou T, Holmes E, et al. Randomized study of two chemotherapy regimens for treatment of low-grade glioma in young children: a report from the Children's Oncology Group. *J Clin Oncol* 2012; **30**: 2641–47.
- 61 Oh KS, Hung J, Robertson PL, et al. Outcomes of multidisciplinary management in pediatric low-grade gliomas. *Int J Radiat Oncol Biol Phys* 2011; **81**: e481–88.
- 62 Hakan T, Aker FV. Case report on a patient with neurofibromatosis type 1 and a frontal cystic glioblastoma. *Neurol Neurochir Pol* 2008; **42**: 362–65.
- 63 Gutmann DH, Rasmussen SA, Wolkenstein P, et al. Gliomas presenting after age 10 in individuals with neurofibromatosis type 1 (NF1). *Neurology* 2002; **59**: 759–61.
- 64 Broekman ML, Risselada R, Engelen-Lee J, Spliet WG, Verweij BH. Glioblastoma multiforme in the posterior cranial fossa in a patient with neurofibromatosis type I. *Case Rep Med* 2009; **2009**: 757898.
- 65 Huttner AJ, Kieran MW, Yao X, et al. Clinicopathologic study of glioblastoma in children with neurofibromatosis type 1. *Pediatr Blood Cancer* 2010; **54**: 890–96.
- 66 Patil S, Chamberlain RS. Neoplasms associated with germline and somatic NF1 gene mutations. *Oncologist* 2012; **17**: 101–16.
- 67 Ferner RE, Gutmann DH. International consensus statement on malignant peripheral nerve sheath tumors in neurofibromatosis. *Cancer Res* 2002; **62**: 1573–77.
- 68 Evans DG, Baser ME, McGaughran J, Sharif S, Howard E, Moran A. Malignant peripheral nerve sheath tumours in neurofibromatosis 1. *J Med Genet* 2002; **39**: 311–14.
- 69 Tucker T, Wolkenstein P, Revuz J, Zeller J, Friedman JM. Association between benign and malignant peripheral nerve sheath tumors in NF1. *Neurology* 2005; **65**: 205–11.
- 70 Ferner RE, Golding JF, Smith M, et al. [18F]2-fluoro-2-deoxy-D-glucose positron emission tomography (FDG PET) as a diagnostic tool for neurofibromatosis 1 (NF1) associated malignant peripheral nerve sheath tumours (MPNSTs): a long-term clinical study. *Ann Oncol* 2008; **19**: 390–94.
- 71 Derlin T, Tornquist K, Münster S, et al. Comparative effectiveness of 18F-FDG PET/CT versus whole-body MRI for detection of malignant peripheral nerve sheath tumors in neurofibromatosis type 1. *Clin Nucl Med* 2013; **38**: e19–25.
- 72 Benz MR, Herrmann K, Walter F, et al. (18F)-FDG PET/CT for monitoring treatment responses to the epidermal growth factor receptor inhibitor erlotinib. *J Nucl Med* 2011; **52**: 1684–89.
- 73 Dunn GP, Spiliopoulos K, Plotkin SR, et al. Role of resection of malignant peripheral nerve sheath tumors in patients with neurofibromatosis type 1. *J Neurosurg* 2013; **118**: 142–48.
- 74 Sordillo PP, Helson L, Hajdu SI, et al. Malignant schwannoma: clinical characteristics, survival, and response to therapy. *Cancer* 1981; **47**: 2503–09.
- 75 Ingham S, Huson SM, Moran A, Wylie J, Leahy M, Evans DG. Malignant peripheral nerve sheath tumours in NF1: improved survival in women and in recent years. *Eur J Cancer* 2011; **47**: 2723–28.
- 76 Carli M, Ferrari A, Mattke A, et al. Pediatric malignant peripheral nerve sheath tumor: the Italian and German soft tissue sarcoma cooperative group. *J Clin Oncol* 2005; **23**: 8422–30.
- 77 Frustaci S, Gherlinzoni F, De Paoli A, et al. Adjuvant chemotherapy for adult soft tissue sarcomas of the extremities and girdles: results of the Italian randomized cooperative trial. *J Clin Oncol* 2001; **19**: 1238–47.
- 78 Sarcoma Meta-analysis Collaboration (SMAC). Adjuvant chemotherapy for localised resectable soft tissue sarcoma in adults. *Cochrane Database Syst Rev* 2000; **4**: CD001419.
- 79 Kroep JR, Ouali M, Gelderblom H, et al. First-line chemotherapy for malignant peripheral nerve sheath tumor (MPNST) versus other histological soft tissue sarcoma subtypes and as a prognostic factor for MPNST: an EORTC soft tissue and bone sarcoma group study. *Ann Oncol* 2011; **22**: 207–14.
- 80 Miettinen M, Kopczynski J, Makhlof HR, et al. Gastrointestinal stromal tumors, intramural leiomyomas, and leiomyosarcomas in the duodenum: a clinicopathologic, immunohistochemical, and molecular genetic study of 167 cases. *Am J Surg Pathol* 2003; **27**: 625–41.
- 81 Miettinen M, Fetsch JF, Sobin LH, Lasota J. Gastrointestinal stromal tumors in patients with neurofibromatosis 1: a clinicopathologic and molecular genetic study of 45 cases. *Am J Surg Pathol* 2006; **30**: 90–96.
- 82 Maertens O, Prenen H, Debiec-Rychter M, et al. Molecular pathogenesis of multiple gastrointestinal stromal tumors in NF1 patients. *Hum Mol Genet* 2006; **15**: 1015–23.
- 83 Basile U, Cavallaro G, Polistena A, et al. Gastrointestinal and retroperitoneal manifestations of type 1 neurofibromatosis. *J Gastrointest Surg* 2010; **14**: 186–94.

- 84 Blay JY, Bonvalot S, Casali P, et al, and the GIST consensus meeting panelists. Consensus meeting for the management of gastrointestinal stromal tumors: report of the GIST Consensus Conference of 20–21 March 2004, under the auspices of ESMO. *Ann Oncol* 2005; **16**: 566–78.
- 85 Kinoshita K, Hirota S, Isozaki K, et al. Absence of c-kit gene mutations in gastrointestinal stromal tumours from neurofibromatosis type 1 patients. *J Pathol* 2004; **202**: 80–85.
- 86 Lee JL, Kim JY, Ryu MH, et al. Response to imatinib in KIT- and PDGFRA-wild type gastrointestinal stromal associated with neurofibromatosis type 1. *Dig Dis Sci* 2006; **51**: 1043–46.
- 87 Mussi C, Schildhaus HU, Gronchi A, Wardelmann E, Hohenberger P. Therapeutic consequences from molecular biology for gastrointestinal stromal tumor patients affected by neurofibromatosis type 1. *Clin Cancer Res* 2008; **14**: 4550–55.
- 88 Kalender M, Sevinc A, Tutar E, Siricki A, Camci C. Effect of sunitinib on metastatic gastrointestinal stromal tumor in patients with neurofibromatosis type 1: a case report. *World J Gastroenterol* 2007; **13**: 2629–32.
- 89 Sharif S, Moran A, Huson SM, et al. Women with neurofibromatosis 1 are at a moderately increased risk of developing breast cancer and should be considered for early screening. *J Med Genet* 2007; **44**: 481–84.
- 90 Nakamura M, Tangoku A, Kusanagi H, Oka M, Suzuki T. Breast cancer associated with Recklinghausen's disease: report of a case. *Nihon Geka Hokan* 1998; **67**: 3–9.
- 91 Evans DG, O'Hara C, Wilding A, et al. Mortality in neurofibromatosis 1: in North West England: an assessment of actuarial survival in a region of the UK since 1989. *Eur J Hum Genet* 2011; **19**: 1187–91.
- 92 Evans DG. Are we ready for targeted early breast cancer detection strategies in women with NF1 aged 30-49 years? *Am J Med Genet A* 2012; **158A**: 3054–55.
- 93 Shannon KM, O'Connell P, Martin GA, et al. Loss of the normal NF1 allele from the bone marrow of children with type 1 neurofibromatosis and malignant myeloid disorders. *N Engl J Med* 1994; **330**: 597–601.
- 94 Seminog OO, Goldacre MJ. Risk of benign tumours of nervous system, and of malignant neoplasms, in people with neurofibromatosis: population-based record-linkage study. *Br J Cancer* 2013; **108**: 193–98.
- 95 Stiller CA, Chessells JM, Fitchett M. Neurofibromatosis and childhood leukaemia/lymphoma: a population-based UKCCSG study. *Br J Cancer* 1994; **70**: 969–72.
- 96 Walther MM, Keiser HR, Linehan WM. Pheochromocytoma: evaluation, diagnosis, and treatment. *World J Urol* 1999; **17**: 35–39.
- 97 Nguyen-Martin MA, Hammer GD. Pheochromocytoma: an update on risk groups, diagnosis, and management. *Hosp Physician* 2006; **42**: 17–24.
- 98 Manger WM, Eisenhofer G. Pheochromocytoma: diagnosis and management update. *Curr Hypertens Rep* 2004; **6**: 477–84.
- 99 Huang H, Abraham J, Hung E, et al. Treatment of malignant pheochromocytoma/paraganglioma with cyclophosphamide, vincristine, and dacarbazine: recommendation from a 22-year follow-up of 18 patients. *Cancer* 2008; **113**: 2020–28.
- 100 Grünwald F, Ezziddin S. <sup>131</sup>I-metaiodobenzylguanidine therapy of neuroblastoma and other neuroendocrine tumors. *Semin Nucl Med* 2010; **40**: 153–63.
- 101 Robertson RG, Geiger WJ, Davis NB. Carcinoid tumors. *Am Fam Physician* 2006; **74**: 429–34.
- 102 Relles D, Baek J, Witkiewicz A, Yeo CJ. Periampullary and duodenal neoplasms in neurofibromatosis type 1: two cases and an updated 20-year review of the literature yielding 76 cases. *J Gastrointest Surg* 2010; **14**: 1052–61.
- 103 Bettini R, Falconi M, Crippa S, Capelli P, Boninsegna L, Pederzoli P. Ampullary somatostatinomas and jejunal gastrointestinal stromal tumor in a patient with von Recklinghausen's disease. *World J Gastroenterol* 2007; **13**: 2761–63.
- 104 Stevens MC, Rey A, Bouvet N, et al. Treatment of nonmetastatic rhabdomyosarcoma in childhood and adolescence: third study of the International Society of Paediatric Oncology—SIOP Malignant Mesenchymal Tumor 89. *J Clin Oncol* 2005; **23**: 2618–28.
- 105 Crist WM, Anderson JR, Meza JL, et al. Intergroup rhabdomyosarcoma study IV: results for patients with nonmetastatic disease. *J Clin Oncol* 2001; **19**: 3091–102.
- 106 Mayes DA, Rizvi TA, Cancelas JA, et al. Perinatal or adult Nf1 inactivation using tamoxifen-inducible PlpCre each cause neurofibroma formation. *Cancer Res* 2011; **71**: 4675–85.
- 107 Wu J, Williams JP, Rizvi TA, et al. Plexiform and dermal neurofibromas and pigmentation are caused by Nf1 loss in desert hedgehog-expressing cells. *Cancer Cell* 2008; **13**: 105–16.
- 108 Zhu Y, Ghosh P, Charnay P, Burns DK, Parada LF. Neurofibromas in NF1: Schwann cell origin and role of tumor environment. *Science* 2002; **296**: 920–22.
- 109 Bajenaru ML, Hernandez MR, Perry A, et al. Optic nerve glioma in mice requires astrocyte Nf1 gene inactivation and Nf1 brain heterozygosity. *Cancer Res* 2003; **63**: 8573–77.
- 110 Zhu Y, Harada T, Liu L, et al. Inactivation of NF1 in CNS causes increased glial progenitor proliferation and optic glioma formation. *Development* 2005; **132**: 5577–88.
- 111 Dasgupta B, Li W, Perry A, Gutmann DH. Glioma formation in neurofibromatosis 1 reflects preferential activation of K-RAS in astrocytes. *Cancer Res* 2005; **65**: 236–45.
- 112 Cichowski K, Shih TS, Schmitt E, et al. Mouse models of tumor development in neurofibromatosis type 1. *Science* 1999; **286**: 2172–76.
- 113 Vogel KS, Klesse LJ, Velasco-Miguel S, Meyers K, Rushing EJ, Parada LF. Mouse tumor model for neurofibromatosis type 1. *Science* 1999; **286**: 2176–79.
- 114 Le DT, Kong N, Zhu Y, et al. Somatic inactivation of Nf1 in hematopoietic cells results in a progressive myeloproliferative disorder. *Blood* 2004; **103**: 4243–50.
- 115 Ballester R, Michaeli T, Ferguson K, Xu HP, McCormick F, Wigler M. Genetic analysis of mammalian GAP expressed in yeast. *Cell* 1989; **59**: 681–86.
- 116 Martin GA, Viskochil D, Bollag G, et al. The GAP-related domain of the neurofibromatosis type 1 gene product interacts with ras p21. *Cell* 1990; **63**: 843–49.
- 117 Xu GF, Lin B, Tanaka K, et al. The catalytic domain of the neurofibromatosis type 1 gene product stimulates ras GTPase and complements ira mutants of *S. cerevisiae*. *Cell* 1990; **63**: 835–41.
- 118 Jessen WJ, Miller SJ, Jousma E, et al. MEK inhibition exhibits efficacy in human and mouse neurofibromatosis tumors. *J Clin Invest* 2013; **123**: 340–47.
- 119 Wu J, Dombi E, Jousma E, et al. Preclinical testing of sorafenib and RAD001 in the Nf1(flox/flox);DhhCre mouse model of plexiform neurofibroma using magnetic resonance imaging. *Pediatr Blood Cancer* 2012; **58**: 173–80.
- 120 Hegedus B, Banerjee D, Yeh TH, et al. Preclinical cancer therapy in a mouse model of neurofibromatosis-1 optic glioma. *Cancer Res* 2008; **68**: 1520–28.
- 121 Mo W, Chen J, Patel A, et al. CXCR4/CXCL12 mediate autocrine cell-cycle progression in NF1-associated malignant peripheral nerve sheath tumors. *Cell* 2013; **152**: 1077–90.
- 122 Johannessen CM, Johnson BW, Williams SM, et al. TORC1 is essential for NF1-associated malignancies. *Curr Biol* 2008; **18**: 56–62.
- 123 Warrington NM, Gianino SM, Jackson E, et al. Cyclic AMP suppression is sufficient to induce gliomagenesis in a mouse model of neurofibromatosis-1. *Cancer Res* 2010; **70**: 5717–27.
- 124 Bajenaru ML, Zhu Y, Hedrick NM, Donahoe J, Parada LF, Gutmann DH. Astrocyte-specific inactivation of the neurofibromatosis 1 gene (NF1) is insufficient for astrocytoma formation. *Mol Cell Biol* 2002; **22**: 5100–13.
- 125 Dagniakatte GC, Gutmann DH. Neurofibromatosis-1 (Nf1) heterozygous brain microglia elaborate paracrine factors that promote NF1-deficient astrocyte and glioma growth. *Hum Mol Genet* 2007; **16**: 1098–112.
- 126 Dagniakatte GC, Gianino SM, Zhao NW, Parsanian AS, Gutmann DH. Increased c-Jun-NH2-kinase signaling in neurofibromatosis-1 heterozygous microglia drives microglia activation and promotes optic glioma proliferation. *Cancer Res* 2008; **68**: 10358–66.
- 127 Riccardi VM. Cutaneous manifestation of neurofibromatosis: cellular interaction, pigmentation, and mast cells. *Birth Defects Orig Artic Ser* 1981; **17**: 129–45.
- 128 Gutmann DH, Blakeley JO, Korf BR, Packer RJ. Optimizing biologically targeted clinical trials for neurofibromatosis. *Expert Opin Investig Drugs* 2013; **22**: 443–62.