

 Open access • Journal Article • DOI:10.1007/S00702-012-0813-Z

## Neuroimaging of cognitive brain function in paediatric obsessive compulsive disorder: a review of literature and preliminary meta-analysis — [Source link](#)

[Silvia Brem](#), [Tobias U. Hauser](#), [Reto Iannaccone](#), [Daniel Brandeis](#) ...+3 more authors

**Institutions:** [University of Zurich](#), [Heidelberg University](#)

**Published on:** 08 Jun 2012 - [Journal of Neural Transmission](#) (Springer Vienna)

Related papers:

- [Integrating evidence from neuroimaging and neuropsychological studies of obsessive-compulsive disorder: The orbitofronto-striatal model revisited](#)
- [The epidemiology of obsessive-compulsive disorder in the National Comorbidity Survey Replication.](#)
- [Children's Yale-Brown Obsessive Compulsive Scale: Reliability and Validity](#)
- [Diagnostic and Statistical Manual of Mental Disorders](#)
- [Genetics of early-onset obsessive-compulsive disorder](#)

Share this paper:    

View more about this paper here: <https://typeset.io/papers/neuroimaging-of-cognitive-brain-function-in-paediatric-4ixnsf30w0>



**University of  
Zurich**<sup>UZH</sup>

**Zurich Open Repository and  
Archive**

University of Zurich  
University Library  
Strickhofstrasse 39  
CH-8057 Zurich  
[www.zora.uzh.ch](http://www.zora.uzh.ch)

---

Year: 2012

---

## **Neuroimaging of cognitive brain function in paediatric obsessive compulsive disorder: a review of literature and preliminary meta-analysis**

Brem, Silvia ; Hauser, Tobias U ; Iannaccone, Reto ; Brandeis, Daniel ; Drechsler, Renate ; Walitza, Susanne

**Abstract:** Obsessive compulsive disorder (OCD) is a frequent psychiatric disorder with a prevalence of 1-3 %, and it places an enormous burden on patients and their relatives. Up to 50 % of all cases suffer from onset in childhood or adolescence, and the disorder often takes a chronic course with a poor long-term prognosis. Paediatric OCD, with its high familiarity, is often referred to as a distinct OCD subtype that coincides with a developmental period in which the prefrontal cortex exhibits extensive structural and functional maturation. In the present review, we included all studies examining cognitive brain activation in children and/or adolescents with OCD. We conducted extensive literature searches for relevant articles (Pubmed, ScienceDirect) and summarize, tabulate, and discuss their results. For the eight activation studies using functional magnetic resonance imaging, we also performed preliminary meta-analyses to assess the most consistent hypo- and hyperactivation in paediatric OCD patients during cognitive task performance. The review of literature as well as our preliminary meta-analyses of paediatric studies indicated altered functional activation in the same brain regions of affective and cognitive cortico-striatal-thalamic (CST) circuits as for adult OCD patients despite some variations in the direction of activation difference. The still small number of studies that examined brain activation in paediatric OCD patients thereby largely converged with previous findings in adult patients and with the established neurobiological models of CST circuit dysfunction in OCD.

DOI: <https://doi.org/10.1007/s00702-012-0813-z>

Posted at the Zurich Open Repository and Archive, University of Zurich

ZORA URL: <https://doi.org/10.5167/uzh-74416>

Journal Article

Published Version

Originally published at:

Brem, Silvia; Hauser, Tobias U; Iannaccone, Reto; Brandeis, Daniel; Drechsler, Renate; Walitza, Susanne (2012). Neuroimaging of cognitive brain function in paediatric obsessive compulsive disorder: a review of literature and preliminary meta-analysis. *Journal of Neural Transmission*, 119(11):1425-1448.

DOI: <https://doi.org/10.1007/s00702-012-0813-z>

# Neuroimaging of cognitive brain function in paediatric obsessive compulsive disorder: a review of literature and preliminary meta-analysis

Silvia Brem · Tobias U. Hauser · Reto Iannaccone · Daniel Brandeis · Renate Drechsler · Susanne Walitza

Received: 19 July 2011 / Accepted: 20 April 2012 / Published online: 8 June 2012  
© Springer-Verlag 2012

**Abstract** Obsessive compulsive disorder (OCD) is a frequent psychiatric disorder with a prevalence of 1–3 %, and it places an enormous burden on patients and their relatives. Up to 50 % of all cases suffer from onset in childhood or adolescence, and the disorder often takes a chronic course with a poor long-term prognosis. Paediatric OCD, with its high familiarity, is often referred to as a distinct OCD subtype that coincides with a developmental period in which the prefrontal cortex exhibits extensive structural and functional maturation. In the present review, we included all studies examining cognitive brain activation in children and/or adolescents with OCD. We conducted extensive literature searches for relevant articles (Pubmed, ScienceDirect) and summarize, tabulate, and discuss their results. For the eight activation studies using functional magnetic resonance imaging, we also performed preliminary meta-analyses to assess the most consistent hypo- and hyperactivation in paediatric OCD patients

during cognitive task performance. The review of literature as well as our preliminary meta-analyses of paediatric studies indicated altered functional activation in the same brain regions of affective and cognitive cortico-striatal-thalamic (CST) circuits as for adult OCD patients despite some variations in the direction of activation difference. The still small number of studies that examined brain activation in paediatric OCD patients thereby largely converged with previous findings in adult patients and with the established neurobiological models of CST circuit dysfunction in OCD.

**Keywords** Review · Paediatric · Obsessive compulsive disorder · OCD · Functional brain activation · Functional magnetic resonance imaging (fMRI) · Event-related potentials (ERP) · Meta-analysis

## Introduction

Early-onset obsessive compulsive disorder (OCD): epidemiology

Obsessive compulsive disorder (OCD) is a psychiatric disorder characterised by distressing intrusive, repetitive, and often uncontrollable thoughts (obsessions) and the urge to engage in repetitive time-consuming behaviours (compulsions) that are enacted to reduce, neutralize, or prevent distress, dreaded experiences, or events (American Psychiatric Association 2000). Obsessive symptomatology places an enormous burden on the patients as well as their relatives (Walitza et al. 2010; Mossner et al. 2007). According to a nationally representative survey of adult US citizens, 2.3 % of all respondents fully met the DSM-IV criteria for lifetime OCD (Ruscio et al. 2010). Similar

---

S. Brem (✉) · T. U. Hauser · R. Iannaccone · D. Brandeis · R. Drechsler · S. Walitza  
Department of Child and Adolescent Psychiatry, University of Zurich, Neumünsterallee 9, 8032 Zurich, Switzerland  
e-mail: silvia.brem@kjp.d.uzh.ch

R. Iannaccone  
PhD Program in Integrative Molecular Medicine (imMed),  
University of Zurich, Zurich, Switzerland

D. Brandeis · S. Walitza  
Zurich Center for Integrative Human Physiology,  
University of Zurich, Zurich, Switzerland

D. Brandeis  
Department of Child and Adolescent Psychiatry and  
Psychotherapy, Central Institute of Mental Health, Medical  
Faculty Mannheim, Heidelberg University, J5, 68159  
Mannheim, Germany

prevalence rates between 0.1 and 2.3 % have also been reported for European countries (Wittchen and Jacobi 2005). Up to 50 % of all OCD cases emerge during childhood or adolescence (Flament et al. 1988; Nestadt et al. 2000), and more than 40 % of early-onset OCD cases persist into adulthood (Stewart et al. 2004). OCD with an onset in childhood, thus, often follows a chronic course; and the earlier the age of onset the poorer is the long-term prognosis (Stewart et al. 2004). The disorder seriously affects the everyday lives of children and adolescents and has negative consequences for professional and academic careers and social and emotional development (Kolada et al. 1994). According to the National Comorbidity Survey Replication (Kessler et al. 2005), the median age of OCD onset is 19 years, and in 21 % of the cases, the onset is at age 10 years already. Several studies showed a bimodal onset distribution with a first peak in 11-year-olds and another peak of onset in young adults (21 years) (Delorme et al. 2005; Geller et al. 1998; Rasmussen and Eisen 1992). Because of the heterogeneity of the disorder, it is of great interest to identify distinct subtypes such as, for example, early-onset or paediatric OCD as well as poor-insight OCD or tic-related OCD, respectively (Geller et al. 1998; Rosario-Campos et al. 2001). While adults are usually well aware of their obsessive behaviours and may develop compensatory cognitive and behavioural strategies during the course of the disorder, children may not demonstrate such insight (Geller et al. 1998; American Psychiatric Association 2000; Geller 2006). Despite largely overlapping symptoms seen in early- (paediatric) and late-onset (adult) OCD, early-onset OCD is often referred to as a distinct OCD subtype showing greater familiarity and age-specific molecular genetic differences (Chabane et al. 2005; Pauls et al. 1995; do Rosario-Campos et al. 2005; Walitza et al. 2010), high comorbidity with tic disorders and attention deficit hyperactivity disorder (ADHD), and a male preponderance (Geller et al. 1998). Several differences between the characteristic symptoms in adults versus adolescents and children have been reported. Children and adolescents, for example, suffer more often from aggressive obsessions or hoarding compulsions than adults; religious obsessions are especially dominant in adolescents, and sexual obsessions are underrepresented in children (Geller et al. 2001). Other authors, however, discussed hoarding not only as a symptom of OCD but also as a discrete diagnostic entity if other primary causes are ruled out (Pertusa et al. 2010).

#### Treatment of OCD in paediatric patients

Cognitive behavioural therapy (CBT) and a combination therapy involving CBT with a selective serotonin reuptake inhibitor (SSRI) is the treatment of first choice in paediatric

patients suffering from OCD (Foa et al. 2005). Various investigations have shown that the percentage of OCD patients not responding to first-line treatment is high (30–40 %) and that residual symptoms often persist even in successfully treated patients (Foa et al. 2005). The meta-analysis of Stewart et al. (2004) and a prospective follow-up study of our own group (Zellmann et al. 2009) indicated that early treatment is important as the outcome is better with earlier therapy. The authors of the Cochrane analysis (O’Kearney et al. 2010) summarized that CBT and SSRIs are comparably effective in children, whereas more drop-outs were seen under SSRI therapy. According to some studies, patients with early-onset OCD respond less well to pharmacotherapy (Rosario-Campos et al. 2001), suggesting a different pathophysiology, while those with a family history of OCD respond less well to CBT (Garcia et al. 2010).

#### Functional neuroimaging methods

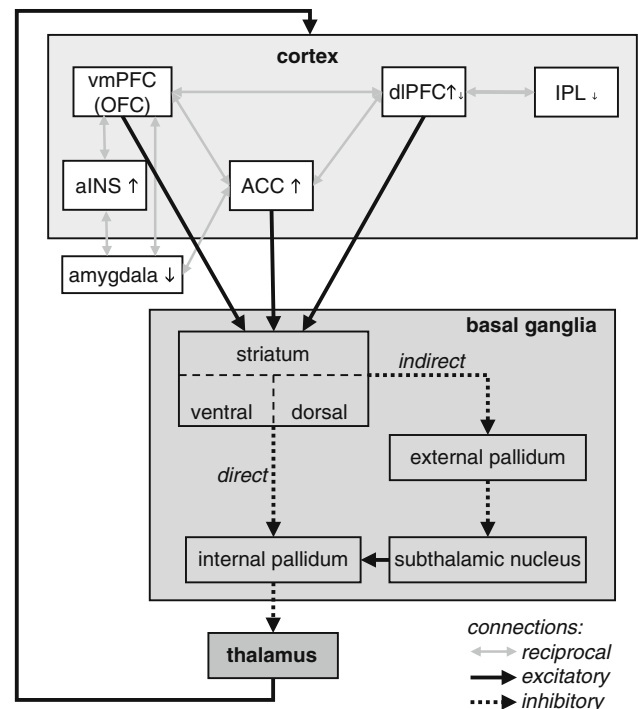
Despite the high prevalence of OCD in childhood and adolescence, most insights into the neurobiology of the affected brain networks and brain functions of the disorder are derived from studies with adults. This may be partly explained by the fact that studying adult patients is often easier, as they may be more cooperative and willing to participate in research studies given their often long period of suffering. Furthermore, modern neuroimaging techniques usually require the patients to lie or sit still for a prolonged period to achieve good data quality. Research on brain (dys)function in paediatric populations rarely justifies the application of neuroimaging techniques that use radioactive tracers as in single photon emission computed tomography (SPECT) or positron emission tomography (PET). Non-invasive techniques such as functional magnetic resonance imaging (fMRI), near-infrared spectroscopy (NIRS), and electro- and/or magnetoencephalography (EEG/MEG) are better suited for investigations in children and adolescents. These techniques reveal neuronal activity either directly (EEG, MEG) or indirectly (fMRI, NIRS) and provide particularly precise information about the timing of information processing (EEG, MEG) or the localization of the neural activation and its connectivity (fMRI). MEG and NIRS are less available than fMRI and EEG, and no study with these techniques has so far been done in paediatric OCD. Please note that, throughout the present review, we use the term “paediatric OCD” for children and adolescents below the age of 18 years who are suffering from OCD.

Interpreting neuroimaging data in paediatric OCD may be even more difficult than in adult OCD patients because the onset of paediatric OCD coincides with a developmental period in which cortical and subcortical brain areas

exhibit extensive structural (Giedd et al. 1999; Thompson et al. 2000; Kanemura et al. 2003; Sowell et al. 2003, 2004a) and functional (Brown et al. 2005; Casey et al. 2005; Galvan et al. 2007; Casey et al. 2008; Somerville and Casey 2010) maturation. Even though the most dramatic brain volume changes have been reported in early childhood until the age of 6 years (Giedd 2004), maturation continues beyond adolescence and early adulthood and includes regional alterations in the volume of grey and white matter (Giedd et al. 1999; Paus et al. 1999; Sowell et al. 1999, 2001, 2004a, b; Giedd 2004): In general, lower-order sensorimotor areas and phylogenetically older structures mature before the more recent and higher-level association areas (Gogtay et al. 2004), and the dorsal, medial, and ventral prefrontal cortices are among the last regions to achieve full maturation (Sowell et al. 1999, 2004b; Giedd 2004). The inverted U-shaped grey matter volume increases in the frontal and parietal cortex and reach their maxima at the age of around 10–12 years (Giedd et al. 1999), while white matter changes follow more linear increases until adulthood (Giedd et al. 1999; Paus et al. 1999). Not only cortical regions but also the basal ganglia and thalamus undergo important developmental changes during childhood and adolescence. A pronounced post-adolescent reduction in gray-matter density has been found in the putamen and pallidum (Sowell et al. 1999), and a marked developmental loss of tissue volume in the head of the caudate nucleus occurs in an age range in which the onset of paediatric OCD peaks (Thompson et al. 2000). It is important to note that those brain areas that show pronounced late maturation such as the prefrontal cortex are among the most relevant to steer the flexible, adaptive behaviour (Elliott et al. 2000) that seems dysfunctional in patients with OCD.

### Neuropsychology and neurobiological models of OCD

The most commonly accepted neurobiological working model addressing neuropsychological deficits proposes a dysfunction of cortico-striato-thalamic (CST) loops (see Fig. 1). This dysfunction may be caused by an imbalance in the signalling of the direct (excitatory) and indirect (inhibitory) paths (Albin et al. 1989; for a review of different models, see Huey et al. 2008). A recent model suggests that two parallel loops (van den Heuvel et al. 2010; Menzies et al. 2008), namely the ventral/affective and the dorsal/cognitive CST loops, are involved in the generation of characteristic OCD symptoms. According to this model, the responsiveness of the dorsal CST loop with projections from the dorsolateral prefrontal (dlPFC), temporal, and parietal association cortices to the dorsal striatum is diminished. The overactive ventral CST loop involves projections from the ventromedial PFC,



**Fig. 1** Simplified illustration of cortico-striato-thalamic (CST) loops based on the models of Albin et al. (1989) and the extensions of van den Heuvel et al. (2010) and Menzies et al. (2008). Projections run from the ventral prefrontal cortex (including OFC and ventromedial PFC) and (rostral) ACC to the ventral striatum or the dorsolateral prefrontal cortex (dlPFC) and (dorsal) ACC to the dorsal striatum. Cortical areas are functionally interconnected by reciprocal connections. Brain structures (see also cluster maxima, Table 2) that exhibited hyper- or hypoactivation in our meta-analysis across paediatric OCD patients are labelled by *arrows pointing upwards* (↑ hyperactivation) or *downwards* (↓ hypoactivation). Direct and indirect paths connect the striatum and the thalamus: The direct path has a net excitatory effect and connects the striatum over the internal part of the globus pallidus with the thalamus. The indirect path has a net inhibitory effect, emerges from the striatum, projects to the external part of the globus pallidus and over the subthalamic nucleus to the internal part of the globus pallidus and finally to the thalamus. The thalamus closes the loops through projections to the cortex. An imbalance of direct and indirect paths within these CST loops may cause the hyper- or hypoactivation of specific brain areas reported in functional brain imaging studies. An imbalance in the parallel cognitive and affective loops further may explain the symptomatic behaviours seen in OCD patients (for more detailed models see also: van den Heuvel et al. 2010; Menzies et al. 2008; Aouizerate et al. 2004; Huey et al. 2008). ACC anterior cingulate cortex, aINS anterior insula, dlPFC dorsolateral prefrontal cortex, IPL inferior parietal lobule, OFC orbitofrontal cortex, vmPFC ventromedial prefrontal cortex

orbitofrontal cortex (OFC), and (rostral) anterior cingulate cortex (ACC) to the ventral striatum and mediodorsal thalamus (Chamberlain et al. 2005, van den Heuvel et al. 2010). A deficient modulation of the affective CST loop through the inhibited dorsal CST loop is in line with the finding that the dlPFC exerts a critical role in the deployment of self-control in decision-making (Hare et al. 2009).

The excessive activation of cortical brain areas implicated in affective processing and the diminished activation of cortical networks exerting executive control result in reduced cognitive control and the inability to inhibit inappropriate, repetitive cognitions and behaviours (van den Heuvel et al. 2010).

Neuropsychological deficits reported for adult patients largely correspond to impairments in these CST loops, especially in the domain of executive functions. The few neuropsychological studies in paediatric OCD patients largely overlapped with those in adults, as children showed relatively consistent impairments of cognitive flexibility (Shin et al. 2008; Ornstein et al. 2010), planning (Behar et al. 1984; Shin et al. 2004; Ornstein et al. 2010, but see Beers et al. 1999), visual memory (Cox et al. 1989; Andres et al. 2007, 2008), and inhibition (Rosenberg et al. 1997a; Woolley et al. 2008; Rubia et al. 2011, but see Beers et al. 1999; Shin et al. 2008).

The importance of CST loops in the pathophysiology of OCD has also been corroborated by an increasing number of structural (meta-analysis; see Radua and Mataix-Cols 2009) and functional neuroimaging studies (reviews: Friedlander and Desrocher 2006; MacMaster et al. 2008; Menzies et al. 2008). These studies showed specific structural abnormalities and/or altered brain activation and connectivity in CST networks during resting state, symptom provocation, or the performance of cognitive tasks. Even though it is still unclear whether altered activity in the CST loops reflects a cause or a consequence of the observed obsessive-compulsive symptoms, there is a broad consensus that the structures of these loops all play crucial roles in various cognitive processes. The OFC, for example, is involved in the evaluation of punishers (Kringelbach 2005), in inhibition (Rosenberg et al. 1997b; Rosenberg and Keshavan 1998; Roth et al. 2007), and in processes requiring cognitive flexibility such as choice behaviour in situations with uncertain outcomes (Elliott et al. 2000), reversal learning (O'Doherty et al. 2001; Chamberlain et al. 2007, 2008), or changing behaviour (Nobre et al. 1999). The ACC may contribute to successful response inhibition through its role in conflict detection during information processing by alerting the systems involved in top-down control for conflict-solving (van Veen and Carter 2002) and by playing a critical role in selecting behavioural responses based on experiences and perceived outcomes together with the OFC (for reviews, see Graybiel and Rauch 2000; Chamberlain et al. 2005).

## Methods

An extensive literature search was performed using the Pubmed library and ScienceDirect database for articles

addressing functional activation in child and adolescent patients with obsessive-compulsive disorder. The last search was conducted on November 1, 2011, and included all studies published by that date.

The search terms “obsessive-compulsive disorder” and “OCD” were used to describe the disorder. For the methodology, the following terms were included: “functional magnetic resonance imaging”, “fMRI”, “magnetic resonance imaging”, “MRI”, “positron emission tomography”, “PET”, “evoked potentials”, “ERP”, “electroencephalography”, “EEG”, “single-photon emission computed tomography”, “SPECT”, “transcranial magnetic stimulation”, “TMS”, “transcranial direct-current stimulation”, “tDCS”, “magnetoencephalography”, “MEG”, “near-infrared spectroscopy”, and “NIRS”. The study group was described with: “adolescent”, “child”, “infant”, and “paediatric”, and the search was restricted to articles published in English. In our literature search, we combined in each case the disease search term either written as an acronym or written out in full with one methodology search term, again written as acronym or written out, and all of the aforementioned study group search terms, each time in all possible combinations. In addition, the reference lists of the suitable articles were screened for other relevant studies.

As already summarized in the recent comprehensive review by Huyser et al. (2009), the majority of the imaging studies that included paediatric patients with OCD concentrated on changes in brain structure measured using MRI and computed tomography (CT) or on brain chemistry assessed using MR proton spectroscopy (H-MRS). In contrast to brain structure and chemistry, cognitive brain function was only rarely examined in paediatric patients. Despite the sophisticated literature search formulas used, many false positive hits were obtained. Several studies, for example, examined groups pooled over paediatric and adult OCD patients but did not specifically report differences between the age groups or between the paediatric patient subgroup and the controls. These studies are, thus, not included in the present review. After careful consideration of all articles, only 15 studies were deemed eligible for the present systematic review since only these directly addressed cognitive activation using brain imaging in paediatric OCD patients. From a total of 15 articles on functional activation, 11 articles used fMRI and 4 used ERPs. Note that several articles examined brain activation in the same or partly the same OCD patient group but focussed on different aspects, e.g.: (1) different cognitive activation tasks (Britton et al. 2010a and Britton et al. 2010b or Huyser et al. 2010 and Huyser et al. 2011, respectively), (2) a comparison to different control groups and the use of different tasks (Rubia et al. 2010; Woolley et al. 2008; Rubia et al. 2011), (3) the use of different

analysis methods and tasks (Fitzgerald et al. 2010, 2011), or (4) testing different aspects of auditory information processing (Oades et al. 1996, 1997). Therefore, the 15 studies in fact included and reported findings for 9 independent groups of paediatric OCD patients. No cognitive activation studies using PET, NIRS, or MEG were found that included paediatric OCD patients.

To assess the consistency of alterations in the brain activation of paediatric OCD patients, we performed a quantitative, voxel-based meta-analysis using activation likelihood estimation (GingerALE V2.1.1) software (Turkeltaub et al. 2002; Laird et al. 2005; Eickhoff et al. 2009). We included all eight paediatric fMRI studies that reported coordinates (foci) from whole-brain analyses (Lazaro et al. 2008; Woolley et al. 2008; Britton et al. 2010a; b; Huyser et al. 2010; Rubia et al. 2010; Huyser et al. 2011; Rubia et al. 2011) showing significant activation differences in cognitive tasks between OCD patients and healthy controls (see Table 1A). Two separate ALE analyses were computed to delineate clusters showing either consistent hypoactivation (OCD < controls, 29 foci, 12 contrasts from 3 independent groups) or hyperactivation (OCD > controls, 18 foci, 7 contrasts from 3 independent groups) in OCD (Fig. 2). Finally, we also report the results of a combined analysis (OCD  $\neq$  controls, 47 foci, 18 contrasts from 4 independent groups) summarizing the brain areas that most consistently exhibited altered functional activation independent of the direction (hypo- or hyperactivation) (Table 2C). First, all coordinates were transformed into the same standard space (MNI) before activation likelihood estimation maps were generated by applying a 3D Gaussian with a subject-number-dependent FWHM between 9 and 11 mm. The random effects analysis method described in the article by Eickhoff et al. (2009) was used to compute *p* values. A false discovery rate (FDR) corrected *p* value (*p*<sub>N</sub>) of 0.05 and a minimal cluster size  $\geq 50$  mm<sup>3</sup> was used to report the ALE results (Table 2) and illustrate the ALE maps (Fig. 2), but foci exceeding the recommended minimal cluster size are specifically marked (\*) in Table 2.

### Summary of findings

Although the number of cognitive brain activation studies in paediatric OCD patients is still limited, the number has increased considerably in recent years (Oades et al. 1996, 1997; Santesso et al. 2006; Hajcak et al. 2008; Lazaro et al. 2008; Woolley et al. 2008; Gilbert et al. 2009; Britton et al. 2010a, b; Fitzgerald et al. 2010, 2011; Huyser et al. 2010, 2011; Rubia et al. 2010, 2011), demonstrating the increasing interest of the scientific community in studying children and adolescents with OCD. The cognitive processes that have been studied in paediatric patients with

functional neuroimaging (fMRI and EEG) involved mainly executive functions such as performance monitoring, inhibition, planning, cognitive flexibility, and working memory. Even though cognitive activation studies that used the fMRI technique were summarised in a recent review by Huyser et al. (2009), the substantial increase in the number of articles within the last 2 years, and the addition of ERP work well justifies another review focusing on cognitive functional brain activation in paediatric OCD. The studies are summarized below. An overview of the groups, methods, and results is also given in Tables 1A (fMRI) and 1B (ERP).

### Symptom provocation in child versus adult OCD

In OCD symptom provocation studies, patients are confronted with pictures of disorder-relevant objects or scenes such as, e.g., a dirty public toilet for patients with contamination fears or a messy pile of toys for patients with symmetry/ordering symptoms. Symptom provocation studies provide insights into functional abnormalities in neural systems related to disorder-specific symptoms. Abnormal activity in certain brain areas of the CST loops has been demonstrated by a considerable number of PET and fMRI studies (for meta-analyses and review tables, see Whiteside et al. 2004; Menzies et al. 2008) in adult (Adler et al. 2000; Mataix-Cols et al. 2004; Nakao et al. 2005) and in paediatric patients (Gilbert et al. 2009). According to studies with adult and paediatric OCD patients, structures of the ventral CST loop such as the OFC, ACC, and caudate nucleus are usually hyperactive at rest (Baxter et al. 1987, 1988; Alptekin et al. 2001; Diler et al. 2004), even though hypoactivation in the form of reduced cerebral blood flow has also been reported (Lucey et al. 1995). More pronounced activation has also been detected when provoking OCD symptoms with pictures or scenes in adults (Adler et al. 2000; Mataix-Cols et al. 2004). Interestingly, different symptom dimensions could be related to distinct patterns of activation with, e.g., greater activation in the ventromedial prefrontal regions, ACC, and caudate nucleus when provoking washing-related anxiety, in the dorsolateral frontal region, ACC, lentiform nucleus, and thalamus for checking anxiety, and in the precentral and orbito-frontal cortex for hoarding in adult patients (Mataix-Cols et al. 2004). However, deactivated structures have also been found in OCD patients, depending on the symptom type, in the ventrolateral PFC, insula, posterior cingulate gyrus, precentral gyrus, precuneus, occipito-temporal cortex, and cerebellum (Mataix-Cols et al. 2004). Studies that examined adult patients before and after treatment, furthermore, reported the normalisation of hyperactivation in the affected brain areas (Schwartz et al. 1996; Nakao et al. 2005) following successful treatments (for reviews, see

**Table 1** Summary of cognitive brain activation studies in paediatric OCD patients

(A) fMRI, fMRI	Article/method meta-analysis (✓)	No. subjects, gender, age, comorbidities, medication	Task(s)	Main findings	Comments
Rubia et al. (2010)	✓	<ul style="list-style-type: none"> <li>Total: <math>N = 60</math></li> <li>10 OCD, all boys, aged <math>14 \pm 1.7</math> years</li> <li>Treated OCD with some residual symptoms</li> <li>Medication/Treatment: SSRI (8), CBT (5)</li> <li>30 ADHD, non-medicated</li> <li>Stop task: <math>N = 18</math> (<math>13.9 \pm 1.1</math> years)</li> <li>Switch task: <math>N = 12</math> (<math>13.7 \pm 1.6</math> years)</li> <li>20 HC, aged (<math>14.5 \pm 1.1</math> years), all boys</li> </ul>	Two different tasks: <ul style="list-style-type: none"> <li>Stop task: choice reaction time task, 50% successful and unsuccessful inhibition trials</li> <li>Switch task: cognitive switching between two spatial dimensions</li> </ul>	<p>No behavioural group differences neither in Stop nor Switch task</p> <p><b>Imaging data</b></p> <ul style="list-style-type: none"> <li>Stop task:               <ul style="list-style-type: none"> <li>Successful stop vs. go trials: ADHD and OCD patients show reduced activation in vmOFC compared to HC. The OFC activation correlated with improvements in CY-BOCS in OCD patients</li> <li>Failed stop vs. go trials: ADHD and OCD patients show reduced activation in left medial frontal/ACC compared to HC; OCD patients and HC show increased activation in right middle/inferior PFC compared to ADHD</li> </ul> </li> <li>Switch task:               <ul style="list-style-type: none"> <li>More pronounced activation in ADHD than HC in right inferior frontal/insula/putamen/superior temporal regions</li> <li>Reduced activation for OCD and ADHD in left inferior frontal/premotor/insula compared to HC; HC and OCD revealed more pronounced activity than ADHD patients in left putamen/caudate/ACC/PCC/parietal regions</li> </ul> </li> </ul>	<p>Same group of OCD children and partly the same tasks as in Woolley et al. (2008) and Rubia et al. (2011)</p> <p>Small OCD-group, medicated and non-medicated patients in partial remission</p>
Woolley et al. (2008)	✓	<ul style="list-style-type: none"> <li>Total: <math>N = 19</math></li> <li>10 OCD, all boys, aged <math>14 \pm 1.7</math> years</li> <li>Treated OCD with some residual symptoms</li> <li>Medication/Treatment: SSRI (8), CBT (5)</li> <li>9 HC, aged <math>14.5 \pm 1.1</math> years, all boys</li> </ul>	Three different tasks: <ul style="list-style-type: none"> <li>Stop task: choice reaction time task, 50% successful and unsuccessful inhibition trials</li> <li>Motor stroop task: stimulus-response spatial incompatibility</li> <li>Switch task: cognitive switching between two spatial dimensions</li> </ul>	<p>No behavioural group differences in any task</p> <p><b>Imaging data</b></p> <ul style="list-style-type: none"> <li>Stop task:               <ul style="list-style-type: none"> <li>OCD show reduced activation in right OFC, thalamus, basal ganglia. Failure in inhibition trials was associated with reduced activation in mesial and dlPFC (incl. ACC)</li> </ul> </li> <li>Motor stroop:               <ul style="list-style-type: none"> <li>OCD show decreased activation than HC in right and left cerebellar vermis and right MTG</li> </ul> </li> <li>Switch task (interference inhibition):               <ul style="list-style-type: none"> <li>OCD exhibit reduced activation in frontal (precentral &amp; inferior PFC), temporoparietal and cerebellar regions</li> </ul> </li> </ul>	<p>Same group of OCD children and partly the same tasks as in Rubia et al. (2010) and Rubia et al. (2011)</p> <p>Small OCD-group, medicated and non-medicated patients in partial remission</p>



**Table 1** continued

(A) fMRI, fMRI	No. subjects, gender, age, comorbidities, medication	Task(s)	Main findings	Comments
Rubia et al. (2011) fMRI ✓	<ul style="list-style-type: none"> <li>• Total: <math>N = 48</math></li> <li>• 10 OCD, all boys, aged <math>13.8 \pm 1</math> years                             <ul style="list-style-type: none"> <li>– Treated OCD with some residual symptoms</li> <li>– Medication/Treatment: SSRI (8), CBT (5)</li> </ul> </li> <li>• 18 ADHD aged <math>14.3 \pm 2</math> years, all boys and all medication naïve</li> <li>• 20 HC aged <math>14.4 \pm 1</math> years, all boys</li> </ul>	<p><i>Simon Task</i>: measuring interference inhibition and selective attention</p> <p>In the Simon task, subjects had to respond to the pointing direction of arrows which was congruent or incongruent (Simon condition) with the side on which the arrow appeared on the screen. Slightly slanted but congruent oddball trials were introduced as control condition</p>	<p><b>Behavioural data</b></p> <p>Simon interference effect on reaction time was higher in OCD patients than ADHD patients. No group differences emerged for accuracy</p> <p><b>Imaging data</b></p> <ul style="list-style-type: none"> <li>• <i>Oddball condition (oddball-congruent trials)</i>:                             <ul style="list-style-type: none"> <li>– OCD show reduced activation in dlPFC as compared to controls and ADHD patients while ADHD patients revealed under activation in the PCC relative to OCD and controls. Furthermore, the activation on the PCC was positively correlated with CY-BOCS obsession scores but negatively correlated with ADHD inattention/hyperactivity SDQ scores.</li> </ul> </li> <li>• <i>Simon condition (incongruent-oddball trials)</i>:                             <ul style="list-style-type: none"> <li>– Reduced activation right IPL in ADHD patients and reduced activity in right ACC/SMA in both patients groups compared to healthy controls</li> </ul> </li> </ul> <p>Shared dysfunction of the mesial frontal cortex (ACC/SMA) in ADHD and OCD and disorder specific underactivations of the dlPFC in OCD patients and of the PCC and IPL in ADHD</p>	<p>Same group of OCD children as in Rubia et al. (2010) and Woolley et al. (2008)</p> <p>Small OCD-group, medicated and non-medicated patients in partial remission</p>
Fitzgerald et al. (2010) fMRI, fMRI	<ul style="list-style-type: none"> <li>• Total: <math>N = 36</math></li> <li>• 18 OCD, aged <math>13.9 \pm 2.6</math> years, 6 boys:                             <ul style="list-style-type: none"> <li>– Comorbidities: separation anxiety disorder (5), generalized anxiety disorder (1), anxiety NOS (3), depression NOS (2) and tics (2)</li> <li>– Medication: 12 patients medicated with SSRI</li> </ul> </li> <li>• 18 HC, aged <math>14.1 \pm 2.66</math> years, 6 boys</li> </ul>	<p><i>Multi-source interference task</i>: Identification of the ordinal value of the unique of 3 digits. Interference: Incongruence of position and ordinality</p>	<p><b>Behavioural data</b></p> <p>No behavioural group differences</p> <p><b>Imaging data</b></p> <p>Search volumes for a priori hypotheses (OCD plus healthy controls) in vMFC and pMFC:</p> <ul style="list-style-type: none"> <li>• <i>Functional activation</i>:                             <ul style="list-style-type: none"> <li>– Interference condition: OCD show increased activation in dACC &amp; vMFC</li> <li>– Error processing: OCD show increased activation in vMFC; rostral ACC (sub-significant)</li> </ul> </li> <li>• <i>Connectivity analyses (f-MRI)</i>:                             <ul style="list-style-type: none"> <li>– Seed region pMFC (dACC): Psychophysiological interaction analyses revealed stronger connectivity of the dACC to the vMFC during incongruent vs. congruent trials in OCD patients.</li> <li>– During resting state, patients showed reduced connectivity of dACC to right anterior operculum.</li> <li>– Seed region vMFC: Reduced connectivity to posterior cingulate cortex in OCD patients during resting state</li> </ul> </li> </ul>	<p>Medicated and non-medicated patients, most of them with comorbid diagnoses</p>

Table 1 continued

(A) fMRI, fMRI	No. subjects, gender, age, comorbidities, medication	Task(s)	Main findings	Comments
Fitzgerald et al. (2011) fMRI	<ul style="list-style-type: none"> <li>Total: <math>N = 121</math></li> <li>61 HC, divided into four age groups:               <ul style="list-style-type: none"> <li>Children: <math>13, 10.7 \pm 1.7</math> years, 6 boys</li> <li>Adolescents: <math>16, 15.3 \pm 1.3</math> years, 8 boys</li> <li>Young adults: <math>15, 21 \pm 2.3</math> years, 7 men</li> <li>Adults: <math>17, 32.3 \pm 5.9</math> years, 7 men</li> </ul> </li> <li>60 OCD, divided into four age groups:               <ul style="list-style-type: none"> <li>Children: <math>11, 11.0 \pm 1.3</math> years, 6 boys</li> <li>Adolescents: <math>18, 16.0 \pm 1.4</math> years, 5 boys</li> <li>Young adults: <math>18, 20 \pm 1.4</math> years, 10 men</li> <li>Adults: <math>13, 32 \pm 6</math> years, 6 men</li> </ul> </li> <li>Medications (OCD): SSRI (24), SSRI/atyp. (2), <math>\alpha</math>-agonist (1), SNRI(1), Bupropion (1), None (32).</li> <li>Comorbidities (OCD): Anxiety (17), Depressive (29), Tic (5), Eating (4), Trichotillomania (1), None (12)</li> </ul>	Resting state	<p><b>Functional connectivity data</b></p> <p>Three seed regions: ventral striatum (nucleus accumbens), dorsal striatum (head of caudate), medial dorsal thalamus</p> <ul style="list-style-type: none"> <li>Reduced connectivity in OCD patients compared with healthy controls between the left dorsal striatum and the rostral ACC. This connection also showed a group x age interaction indicating that this effect was driven by the difference between the youngest groups</li> <li>Interaction of group and age for the connectivity between the right medial dorsal thalamus and bilateral ACC was driven by the reduced connectivity in the OCD children. Group x age effect between left medial dorsal thalamus and left dorsal ACC was explained by reduced connectivity in child patients and increased connectivity in adolescent patients</li> <li>The connectivity between the right dorsal striatum and the ventral medial frontal cortex was increased for OCD patients than healthy controls</li> <li>Greater CY-BOCS severity was correlated with reduced dorsal striatum – rostral ACC connectivity in child patients</li> </ul>	Large sample of medicated and non-medicated patients most of them with comorbid diagnoses. Different age groups are compared Some OCD patients showed subclinical symptoms but posthoc analyses without those patients confirmed the main findings
Britton et al. (2010a) fMRI, sMRI, fMRI	<ul style="list-style-type: none"> <li>Total: <math>N = 35</math></li> <li>15 OCD, aged <math>13.5 \pm 2.4</math> years, 9 boys</li> <li>Comorbidities: Generalized anxiety disorder (2), Simple phobia (2), Agoraphobia (1), Major depression (2), Depression-NOS (1), Tourette disorder (1), ADHD (2).</li> <li>Medications: SSRI (12), Tricycl. Antidepressiva: (3), Mood stabilizers (3), Stimulants (4), Desyrel (1), Clonidine (1), Mefenamine (1), Atomoxetine (1), Lorazepam (1)</li> <li>20 HC, aged <math>13.6 \pm 2.4</math> years, 13 boys</li> </ul>	<p>Sets-shifting task</p> <p>Attributes colour and shape; Repeated (same identifying attribute) and mixed (alternating identifying attribute) blocks</p>	<p><b>Behavioural data</b></p> <p>No group differences in accuracy and only minor differences in RT (OCD tended to respond slower in mixed blocks)</p> <p><b>Imaging data</b></p> <ul style="list-style-type: none"> <li><b>Functional activation:</b> <ul style="list-style-type: none"> <li>OCD less left inferior frontal gyrus (lateral OFC) activation in set shifting contrast, but no between-group differences in dlPFC, ACC, striatal or hippocampal activation</li> <li>Group difference in shift costs: With increasing shift costs, right caudate activation increased in HC and decreased in OCD</li> </ul> </li> <li><b>Functional connectivity:</b> <ul style="list-style-type: none"> <li>Functional connectivity of IFG and caudate only in HC</li> </ul> </li> <li><b>Structural analyses:</b> <ul style="list-style-type: none"> <li>No significant group differences in overall gray matter, white matter or CSF but OCD exhibited greater gray matter density in medial frontal gyrus, OFC and rACC and in inferior frontal gyrus (trend) than HC</li> </ul> </li> </ul>	Partly the same children as in Britton et al. (2010b) Medicated patients, most of them with comorbid diagnoses

**Table 1** continued

(A) fMRI, fMRI	No. subjects, gender, age, comorbidities, medication	Task(s)	Main findings	Comments
Britton et al. (2010b) fMRI ✓	<ul style="list-style-type: none"> <li>Total: <math>N = 29</math></li> <li>12 OCD, aged <math>13.8 \pm 2.4</math> years, 7 boys:                             <ul style="list-style-type: none"> <li>Comorbidities: Generalized anxiety disorder (2), Simple phobia (2), Agoraphobia (1), Major depression (2), Depression-NOS (1), Tourette disorder (1), ADHD (2).</li> <li>Medications: SSRI (9), Tricycl, antidepressiva: (3), Mood stabilizers (3), Stimulants (4), Desyrel (1), Mementine (1), Atomoxetine (1), Lorazepam (1), Zolpidem (1)</li> </ul> </li> <li>17 HC, aged <math>13.2 \pm 2.3</math> years, 11 boys</li> </ul>	<p><i>Gender discrimination task</i> with emotional (happy, disgusted, fearful) and neutral facial expression</p>	<p><b>Behavioural data</b></p> <p>No significant performance in gender discrimination, but postscan valence ratings indicated an overall more negative rating of facial expressions in OCD patients</p> <p><b>Imaging data</b></p> <ul style="list-style-type: none"> <li>More pronounced amygdala/hippocampal border activation in HC than OCD for emotional and neutral faces</li> <li>No correlation of amygdala activation with CY-BOCS, state anxiety scores or disgust sensitivity scores</li> <li><i>Emotional vs. neutral faces:</i> <ul style="list-style-type: none"> <li>More pronounced OFC activation in HC than OCD – for fearful faces</li> <li>More pronounced vIPFC and dACC activation in OCD vs. controls for fearful or happy faces, respectively</li> </ul> </li> </ul>	<p>Partly the same children as in Britton et al. (2010a)</p> <p>Medicated patients, most of them with comorbid diagnoses</p>
Lazaro et al. (2008) fMRI ✓	<ul style="list-style-type: none"> <li>Total: <math>N = 24</math></li> <li>12 OCD, aged <math>13.1 \pm 2.7</math> years, 7 boys                             <ul style="list-style-type: none"> <li>Medication/Comorbidities: drug-naïve and non-medicated, no comorbidity at initial assessment</li> </ul> </li> <li>12 HC, <math>13.7 \pm 2.8</math> years, 7 boys</li> </ul>	<p><i>Serial Reaction Time Task</i> (SRTT): simple and complex sequences</p> <p>Scanning before and after 6 months of pharmacological (SSRI) treatment and behavioural counselling</p>	<p><b>Behavioural data</b></p> <p>8 patients achieved remission, 2 major improvements with treatment</p> <p><b>Imaging data</b></p> <p><i>Before treatment:</i></p> <ul style="list-style-type: none"> <li>OCD patients show more pronounced activation in bilateral MFG to complex as compared to simple trials than HC</li> <li>Correlation of OCD symptoms and activity in nucleus accumbens and superior right parietal lobe</li> </ul> <p><i>After treatment:</i></p> <ul style="list-style-type: none"> <li>OCD patients show more pronounced activation in right IPL to complex as compared to simple trials than HC</li> </ul> <p>Changes in brain activation with treatment: Decreased activation in left insula and left putamen after treatment compared to baseline in OCD but no changes in HC</p>	<p>Pharmacological treatment study with pre-post analyses</p>

Table 1 continued

(A) fMRI, fMRI	No. subjects, gender, age, comorbidities, medication	Task(s)	Main findings	Comments
Huyser et al. (2010) fMRI ✓	<ul style="list-style-type: none"> <li>Total: <math>N = 50</math></li> <li>25 OCD, aged <math>13.95 \pm 2.52</math> years, 9 boys               <ul style="list-style-type: none"> <li>Medication history</li> </ul> </li> </ul>	<p><i>Tower of London task</i></p> <p>Control condition, and five planning conditions with different task loads.</p> <p><i>Flanker interference task</i></p> <p>Congruent and incongruent conditions to examine error and conflict monitoring</p> <p>Cognitive-behavioural therapy (16 sessions)</p> <p>Two test times: baseline – before CBT (T0), after CBT (T1)</p>	<p><b>Behavioural data</b></p> <p>Significant CY-BOCS decrease after treatment</p> <ul style="list-style-type: none"> <li><i>Tower of London task:</i></li> <li><i>Before CBT:</i> <ul style="list-style-type: none"> <li>Longer RT in OCD but same accuracy for planning in OCD and HC</li> </ul> </li> <li><i>After CBT:</i> <ul style="list-style-type: none"> <li>No between group RT difference anymore</li> </ul> </li> <li>Flanker interference task:           <ul style="list-style-type: none"> <li><i>Before &amp; after CBT:</i> <ul style="list-style-type: none"> <li>No group differences for RT and accuracy but RT and errors decreased with test time</li> <li>–CY-BOCS scores correlated with accuracy in incongruent trials, i.e. patients with high CY-BOCS scores were more accurate on the more difficult trials</li> </ul> </li> </ul> </li> </ul>	<p>The articles Huyser et al. (2010) and Huyser et al. (2011) present data of the same groups of paediatric patients</p> <p>CBT treatment study with pre-post analyses</p> <p>Non-medicated OCD patients (no psychotropic medication), but most patients with comorbidities</p>
Huyser et al. (2011) fMRI ✓	<ul style="list-style-type: none"> <li>25 HC, aged <math>13.7 \pm 2.85</math> years, 9 boys</li> </ul>		<p><b>Imaging data</b></p> <ul style="list-style-type: none"> <li><i>Tower of London task:</i></li> <li><i>Before CBT:</i> <ul style="list-style-type: none"> <li>Planning: Diminished activity in OCD compared to HC in left posterior dlPFC/premotor cortex and right parietal cortex</li> <li>Task load: increased load induced stronger activation in patients with OCD in the left dlPFC, left dACC, right dmPFC and left insular cortex</li> </ul> </li> <li><i>After CBT:</i> <ul style="list-style-type: none"> <li>Planning: no group differences in brain activation</li> <li>Task load: no group by task load interactions</li> <li>–CY-BOCS score correlated with activation in dlPFC and left parietal cortex for planning before and after CBT and with task load in the parietal cortex</li> </ul> </li> </ul> <p><i>Before vs. after CBT:</i></p> <p>Interaction of time, group and task load pointed to a significant decrease of activation in patients with OCD compared with HC over time in the right IFG/frontal operculum</p> <ul style="list-style-type: none"> <li><i>Flanker interference task:</i></li> <li><i>Before and after CBT:</i> <ul style="list-style-type: none"> <li>Error processing: Triple interaction of group x age x test time in ACC and insula, mainly driven by increased activation in older OCD patients. Positive correlation of CY-BOCS score and activation in right insula at T0</li> <li>Conflict processing: Triple interaction of group x age x test time in bilateral insula, mainly driven by increased activation in older OCD patients before treatment. Interaction of group x test time in dmPFC, ACC and premotor regions driven by an increase in activation by the OCD group with test time. Positive correlation of CY-BOCS score and activation in left dm PFC at T0. Further, the change in symptom severity correlated with the change in BOLD activation (T1 vs. T0) in bilateral dlPFC, right dmPFC and left premotor cortex</li> </ul> </li> </ul>	

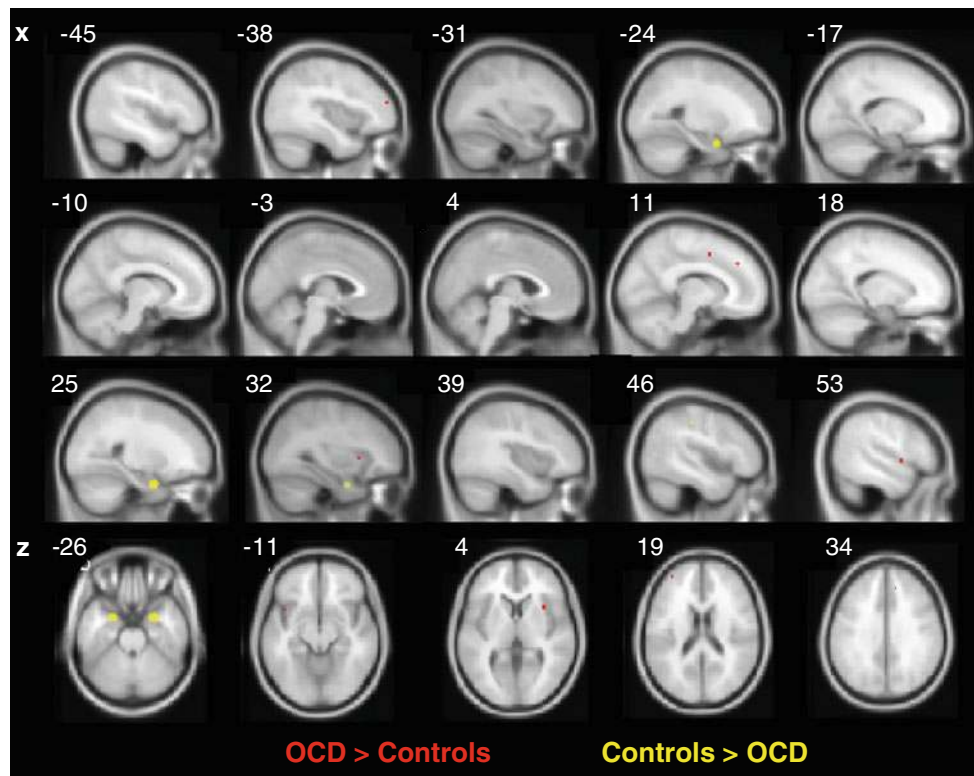
Table 1 continued

(A) fMRI, fMRI	No. subjects, gender, age, comorbidities, medication	Task(s)	Main findings	Comments
Gilbert et al. (2009) fMRI	<ul style="list-style-type: none"> <li>Total: N = 36</li> <li>18 OCD, aged 13.1 ± 2.5 years, 11 boys</li> <li>Comorbidities: transient Tic (1)</li> <li>Medication: Psychotropic medication (9)</li> <li>18 HC, aged 13.6 ± 2.4 years, 11 boys</li> </ul>	<p><i>Symptom provocation</i> Alternating blocks of symptom provocation (contamination-related or symmetry-related)</p> <p>– Anxiety ratings (1–10)</p>	<p><b>Imaging data</b></p> <ul style="list-style-type: none"> <li>OCD patients exhibit in general reduced activity upon the presentation of symptom provoking and neutral pictures. Reduced activity in dlPFC, left OFC, right insula, putamen, thalamus (contamination experiment) and right thalamus and right insula (symmetry experiment). Reduced activation to neutral stimuli in dlPFC, insula, right thalamus and putamen</li> <li>Greater total symptom severity associated with decreased activity in the right dlPFC (OCD vs. HC) and decreased activity in the right putamen</li> <li>Greater contamination/washing severity associated with decreased activity in the right dlPFC in OCD</li> <li>Greater anxiety severity associated with greater activity in the left insula in OCD</li> <li>No sign. differences in neural activity between OCD patients taking medication (n = 9) vs. no medication (n = 9)</li> </ul>	Direct comparison of medicated and non-medicated subgroups of patients yielded no difference in brain activation
(B) ERP	No. subjects, gender, age, comorbidities, medication	Task(s)	Main findings	Comments
Santesso et al. (2006) ERP	<ul style="list-style-type: none"> <li>Total: N = 37, aged 10.2 ± 2.5 years, 16 boys</li> <li>non-clinical sample: CBCL for obsessive compulsive behaviour (parental report)</li> </ul>	<p><i>Visual discrimination task (Flanker)</i></p> <p>5-letter array of H or S, with congruent and incongruent trials</p>	<p><b>Behavioural data</b></p> <p>Higher OC symptom reports correlated with fewer errors and a trend to slower RTs in the flanker task</p> <p><b>ERP data</b></p> <ul style="list-style-type: none"> <li>Larger Ne and Pe found in children with reported OC symptoms compared to children with no OC symptoms. Ne and Pe together explained 23% percent of the variance in predicting OC behaviour</li> <li>Increasing parent-reported OC behaviours were associated with larger Ne amplitude at frontocentral and with Pe at central site</li> </ul>	Non-clinical sample with parent reported OC symptoms
Hajcak et al. (2008) ERP	<ul style="list-style-type: none"> <li>Total N = 36</li> <li>Before CBT:                             <ul style="list-style-type: none"> <li>18 OCD, aged 13.3 ± 2.8 years, 13 boys</li> <li>18 HC, aged 11.9 ± 2.6 years, 8 boys</li> </ul> </li> <li>Group Before and After CBT                             <ul style="list-style-type: none"> <li>10 OCD, 12.5 ± 3.2 years, 3 boys</li> <li>13 HC, aged 12.3 ± 2.7 years, 9 boys</li> </ul> </li> </ul> <p>Medications in OCD: Clomipramine (2), Sertraline (3), Escitalopram (4), Fluoxetine (1), Bupropion (2), Fluvoxamine (1)</p>	<p><i>Modified Simon task</i></p> <p>Before and after cognitive behavioural therapy (CBT: 15 × 1h)</p> <p>In the Simon task, subjects had to respond to the colour of presented arrows; and to disregard their orientation</p>	<p><b>Behavioural data</b></p> <p>No behavioural group differences between OCD and HC in terms of performance accuracy, reaction time and post-error reaction time slowing in the Simon task</p> <p><b>ERP data</b></p> <ul style="list-style-type: none"> <li>More pronounced error-related negativities (Ne) in OCD patients pre- and post behavioural therapy, but no group difference in the correct response negativities (CRN)</li> <li>Medication did non influence Ne and CRN amplitudes</li> </ul>	CBT treatment study with pre-post analyses

Table 1 continued

Article/method	No. subjects, gender, age, comorbidities, medication	Task(s)	Main findings	Comments
(B) ERP				
Oades et al. (1996) and Oades et al. (1997) ERP	<p>Total <math>N = 61</math></p> <ul style="list-style-type: none"> <li>• 13 OCD, mean age 16.3 years (11–19 years) 9 boys, drug-naïve and no comorbidities</li> <li>• 12 PH (paranoid-hallucinatory schizophrenic patients) mean age 18.5 years (14–24 years), 8 boys, medication-free (1), others medicated with Chlorpromazine equivalents and Biperdene (7)</li> <li>• 12 NP (nonparanoid schizophrenic patients) mean age 18.9 years (14–24 years), 6 boys, medication-free (2), others medicated with Chlorpromazine equivalents and Biperdene (5)</li> <li>• 24 HC, mean age 18.5 years (11–24 years), 14 boys</li> </ul>	<p>Three tone oddball task presented in successive passive and active discrimination sessions</p>	<p><b>ERP data</b></p> <p>Certain differences in early and late ERPs between OCD and HC or schizophrenics were reported regarding latency, topographies and amplitudes. Basically ERP responses of OCD patients depended more on stimulus than task (active vs. passive) related features. The latencies of the OCD group were overall less topographically differentiated. The P1 deflection was largest in OCD patients with centroparietal maxima. While HC did not show N1 asymmetries, the N1 tended to be larger over the right hemisphere in the OCD group</p> <p>The P3 (–350ms) like positive deflection in schizophrenic patients did not increase significantly between diffuse and focused attention conditions as compared to the HC and OCD groups</p>	<p>Same groups in Oades et al. (1997) and Oades et al. (1996)</p> <p>The analyses focussed on differences between schizophrenic subgroups</p> <p>Only relevant differences for the OCD group are listed</p>
(A) fMRI, (B) ERP				

ACC anterior cingulate cortex, *dACC* dorsal ACC, *rACC* rostral ACC, *ADHD* attention deficit hyperactivity disorder, *CBCL* child behaviour checklist, *CBT* cognitive behavioural therapy, *CRV* correct response negativity, *CSF* cerebrospinal fluid, *CY-BOCS* Children's Yale-Brown Obsessive Compulsive Scale, *fMRI* functional magnetic resonance imaging, *fMRI* functional connectivity MRI, *HC* healthy controls, *IFG* inferior frontal gyrus, *IPL* inferior parietal lobe, *MFG* middle frontal gyrus, *vMFC* ventral medial frontal cortex, *MTG* middle temporal gyrus, *Ne* error-related negativity, *fMRI* functional connectivity MRI, *HC* healthy controls, *IFG* inferior frontal gyrus, *IPL* inferior parietal orbitofrontal cortex, *vmOFC* ventromedial OFC, *PCC* posterior cingulate cortex, *Pe* error-related positivity, *PFC* prefrontal cortex, *dIPFC* dorsolateral PFC, *dmPFC* dorsomedial PFC, *vIPFC* ventrolateral PFC, *RT* reaction time, *SDQ* parent strength and difficulty questionnaire, *SNRI* serotonin–norepinephrine reuptake inhibitors, *SSRI* selective serotonin reuptake inhibitors, ✓ study included in preliminary meta-analyses



**Fig. 2** Results of the preliminary ALE meta-analysis. The *red foci* represent areas where paediatric OCD patients exhibit overactivation in comparison to healthy controls while the *yellow foci* index hypoactivation in paediatric OCD patients. The clusters are overlaid

on an average MNI template and illustrate sagittal (rows 1–3) as well as axial views (row 4). All FDR ( $p < 0.05$ ) corrected clusters that exceeded a cluster volume  $>50 \text{ mm}^3$  are illustrated

Whiteside et al. 2004; Maia et al. 2008; Menzies et al. 2008). Hypoactivation following the presentation of symptom-provoking and neutral pictures in CST regions were detected in the only fMRI study that examined symptom provocation in paediatric OCD patients (Gilbert et al. 2009). The deactivated structures in the  $13.1 \pm 2.5$ -year-old patients included the right insula, thalamus, right dlPFC, putamen, and left OFC. In addition, symptom-related scores on the contamination dimension were associated with reduced dlPFC activation, and overall symptom severity was negatively correlated with activation in the right putamen.

Differences in cognitive activation between paediatric OCD patients and healthy peers

#### *Conflict monitoring and inhibition*

There is considerable evidence from brain imaging studies of a dysfunctional monitoring system in patients with OCD. One of the critical brain structures of the monitoring system is the anterior cingulate cortex (ACC). ACC activity has been studied in a variety of tasks, most often involving response and/or error monitoring (Ursu et al.

2003; van den Heuvel et al. 2005; Santesso et al. 2006; Hajcak et al. 2008; Fitzgerald et al. 2010; Huyser et al. 2011), working memory (van der Wee et al. 2003), or inhibition (Maltby et al. 2005; Woolley et al. 2008; Rubia et al. 2010). Enhanced activity is, for example, found when conflict arises due to unexpected error feedback (van Veen and Carter 2002). In adult OCD patients, the monitoring system has shown similar excessive activation when erroneous responses or correct responses in high-conflict trials (Ursu et al. 2003; Maltby et al. 2005) were processed. This may indicate that excessive ACC activity reflects a neural correlate of the patients' continuing sense that "something is wrong" (reviews, see Schwartz 1998; Aouizerate et al. 2004) or "just not right" (Maltby et al. 2005) and requires correction. Support comes from ERP studies that have related response monitoring processes to a specific response-locked potential referred to as error negativity ("Ne") or error-related negativity ("ERN"). This Ne is recorded on the scalp at around 50–150 ms after error commission. It emerges in the ACC, as shown by source computations (Dehaene et al. 1994; van Veen and Carter 2002). The Ne has been linked to a phasic error signal from the mesolimbic dopamine system that triggers further processing and compensation (Holroyd and Coles 2002).

**Table 2** Summary of ALE meta-analyses for (A) controls > OCD, (B) OCD > controls and (C) OCD ≠ controls

Cluster No.	Volume (mm <sup>3</sup> )	Weighted centre			ALE Extreme value	ALE (sub)maxima			Hem	Region
		x	y	z		x	y	z		
<b>(A) Controls &gt; OCD</b>										
1*	1,240	27	1	-27	0.0231	26	2	-28	R	Uncus/amygdala
2*	880	-23	2	-25	0.0199	-22	2	-24	L	Parahippocampal gyrus/amygdala
3	64	45	-27	45	0.0080	44	-28	44	R	Inferior parietal lobule
4	56	-54	6	42	0.0089	-54	6	42	L	Middle frontal gyrus/posterior dIPFC
<b>(B) OCD &gt; controls</b>										
1*	80	54	3	0	0.0086	54	3	0	R	Superior temporal gyrus
2*	80	-36	51	18	0.0086	-36	51	18	L	Middle/superior frontal gyrus/dIPFC
3*	80	12	3	48	0.0086	12	2	48	R	Cingulate gyrus/SMA
4*	64	33	15	3	0.0080	33	15	3	R	Putamen/claustrum/anterior insula
5*	56	-42	12	-12	0.0089	-42	12	-12	L	Anterior insula
6*	56	-12	18	36	0.0089	-12	18	36	L	Anterior cingulate gyrus
7*	56	12	36	36	0.0089	12	36	36	R	Medial frontal gyrus, dmPFC
<b>(C) OCD ≠ controls</b>										
1*	1,192	27	1	-27	0.0231	26	2	-28	R	Uncus/amygdala
2*	856	-23	2	-25	0.0199	-22	2	-24	L	Parahippocampal gyrus/amygdala
3*	336	-43	11	-10	0.0116	-42	12	-10	L	Anterior insula
4*	208	-35	31	-5	0.0104	-36	32	-4	L	Inferior frontal gyrus (OFC)

Clusters 1–3 of contrast (C) coincide with clusters in contrasts (A) and (B). Note, for contrasts (A) and (B) all clusters that exceeded a cluster volume >50 mm<sup>3</sup> are listed for information but only clusters denoted with \* exceed the ALE recommended minimum cluster-size threshold *Hem* hemisphere, *R* right, *L* left

An alternative explanation for the occurrence of repetitive behaviours in the form of compulsions in OCD patients is a failure in the inhibition of prepotent responses (Maltby et al. 2005). The stronger activation of the lateral OFC, lateral PFC, and rostral and caudal ACC in adults for correct inhibition in high-conflict trials (Maltby et al. 2005) during Go/Nogo tasks supported this theory: While the caudal ACC activation was explained by an exaggerated response to the identification of a response conflict, the excessive rostral ACC activation may indicate an amplified affective response in conflict situations. The failure to reduce the response conflict through appropriate filtering (Maltby et al. 2005) is reflected by the hyperactive lateral PFC. When considering the role of the lateral OFC in encoding the affective value of an anticipated aversive event and for adapting behaviour, particularly when a negative outcome is anticipated (O'Doherty et al. 2001), its overactivity in OCD patients could reflect excessive concern about the expected outcome (Ursu and Carter 2009).

The findings of ERP studies examining conflict monitoring processes in adult and paediatric OCD patients are consistent, as more pronounced Ne amplitudes have been found in children (Santesso et al. 2006; Hajcak et al. 2008) as well as in adults (Johannes et al. 2001; Endrass et al. 2008; Grundler et al. 2009). The flanker tasks in the studies of Santesso et al. (2006) and Hajcak et al. (2008) targeted

error processing and focussed on the modulation of the characteristic frontocentral Ne in children. Both the findings of (1) an enhanced Ne and subsequent error positivity (Pe) in children ( $10.2 \pm 0.25$  years) (Santesso et al. 2006) and (2) enhanced Ne in a group of partly medicated paediatric patients ( $13.3 \pm 2.8$  years) (Hajcak et al. 2008) corroborate the suggestion that OCD patients show an exaggerated automated response-checking behaviour. The study of Hajcak et al. (2008) also examined treatment effects with pre/post assessments. The Ne remained increased for children with OCD ( $12.5 \pm 3.2$  years) before and after cognitive behavioural therapy (CBT) and, thus, showed no normalization in amplitude. The enlarged Ne has, therefore, been proposed to reflect a trait-like marker that may characterize a useful endophenotype (Hajcak et al. 2008). It is interesting to note that fMRI studies that examined error processing in paediatric patients were not as consistent as ERP studies regarding the corresponding ACC activity: Fitzgerald et al. (2010) used a multisource interference task that was adapted for event-related fMRI to compare the brain activation of a group of medicated and treatment-naïve patients (8–18 years) with moderate OCD symptoms with that of a group of healthy controls. In line with the increased Ne reported in ERP studies (Santesso et al. 2006; Hajcak et al. 2008), excess activation was found in the dorsal ACC (dACC) and ventral medial frontal



cortex (vMFC) during interference task performance and in the vMFC and rostral ACC during error processing in OCD patients. In addition, the functional connectivity of the dorsal ACC and vMFC was enhanced in paediatric patients during task performance. These results corroborate the pronounced drive towards prepotent responding in OCD patients because the atypically exaggerated engagement of the vMFC may indicate the increased emotional salience of cognitive stimuli in conflict situations. Therefore, more performance monitoring through the dACC is required to achieve a similar performance (Fitzgerald et al. 2010). The same authors analysed functional connectivity not only during task performance but also during rest (Fitzgerald et al. 2010, 2011). The analyses focussed on differences in the connections from the dorsal and ventral striatum or the medial dorsal thalamus to cortical regions in four age groups of patients with OCD (children 8–12 years, adolescents 13–17 years, young adults 18–25 years, adults 26–40 years) compared to matched controls. Reduced connectivity was found between the dorsal striatum (head of caudate) and the rostral ACC and between the medio-dorsal thalamus and bilateral ACC. These effects within cortical cognitive control networks depended on age and were driven by the pronounced difference between the youngest groups. Independent of age, excessive connectivity was detected between the ventral striatum (nucleus accumbens) and the ventral medial frontal cortex for OCD patients, suggesting a failure in the regulation of affectively salient information (Fitzgerald et al. 2011). The authors concluded that altered brain function and connectivity may critically affect the interactions between networks and thereby cause the potentiation of distressing, affective thoughts while disrupting performance monitoring in young OCD patients (Fitzgerald et al. 2010). In contrast to the study of Fitzgerald et al. (2010) summarized above, the study of Rubia et al. (2011) did not find increased activation of the ACC during interference processing in their group of OCD patients (mean age 13.8 years). Instead, reduced activation of the right ACC/supplementary motor area (SMA) and the superior parietal lobe was found in both paediatric patients with OCD and patients with ADHD as compared to controls (Rubia et al. 2011). For the easier oddball condition, no disorder-specific hyper- or hypoactivation in the dlPFC was reported for paediatric OCD (Rubia et al. 2011). Cognitive control exerted through the dlPFC may, thus, also be reduced for simpler perceptual attention allocation tasks in paediatric patients (Rubia et al. 2011). The study on cognitive behavioural therapy (CBT) effects conducted by Huyser et al. (2011) pointed to the important influence of age when studying paediatric OCD samples and when looking at ACC function: The rostral ACC (and insula) hyperactivation was especially pronounced in the older patients of the group aged between 9

and 19 years during error processing. This suggests normal ACC function in young patients. However, the disorder may disturb the normal maturation and development of this structure and thereby cause the abnormal function seen later (Huyser et al. 2011). The same study also revealed an increase in the activation of the dorsomedial PFC, ACC, and premotor areas when patients were confronted with conflict trials after successful CBT, suggesting that voluntary regulation could be facilitated through CBT (Huyser et al. 2011).

ERP studies have investigated inhibitory control processes with Go/Nogo tasks. Inhibition-related ERPs (Kopp et al. 1996; Falkenstein et al. 1999) with larger amplitude on Nogo than Go trials include fronto-central N2 (or N200) negativity after 200–300 ms and later (350–600 ms) fronto-central P3 (or P300) positivity. However, there is also some evidence that the N2 with sources in the caudal region of the anterior cingulum (van Veen and Carter 2002) may be driven preliminarily by conflict monitoring processes rather than inhibition alone (Donkers and van Boxtel 2004). Previous studies have reported inconsistent findings regarding the N2 in adult OCD patients for Go/Nogo tasks examining inhibitory control with enhanced (Ruchow et al. 2007), reduced (Kim et al. 2007), or comparable (Di Russo et al. 2000) amplitudes. No ERP study has assessed inhibitory control in paediatric OCD patients up to now, and it remains to be examined whether paediatric OCD patients exhibit abnormal N2 and/or P3 amplitudes. The fMRI studies of Rubia et al. (2010) and Woolley et al. (2008) addressed motor and interference inhibition processes as well as cognitive flexibility in boys with OCD who were treated and in partial remission. The activation in patients with a mean age of  $14.3 \pm 1.7$  years differed from matched healthy controls by showing reduced right orbitofrontal and ACC activation upon successful stop trials and reduced left mesial and dorsolateral frontal activation upon failed stop trials (Woolley et al. 2008; Rubia et al. 2010). While reduced activation of the dlPFC has been reported for planning and reversal learning tasks in adults (van den Heuvel et al. 2005; Remijnse et al. 2006; see below), the reductions in ACC and OFC activation found in paediatric populations contrasts with the hyperactivation observed in adults (Ursu et al. 2003; Maltby et al. 2005).

#### *Cognitive flexibility and learning processes*

In contrast to constant and predefined stimulus–response/reinforcement contingencies in flanker and Go/Nogo tasks, the stimulus–response contingencies change in reversal learning tasks, forcing subjects to adjust their behaviour accordingly. Reversal learning tasks assess cognitive flexibility and reinforcement-based learning, as a previously

learned response has to be adjusted (Chamberlain et al. 2007; Finger et al. 2008; Gu et al. 2008). fMRI studies comparing adult OCD patients and controls revealed less pronounced activation during reversal learning in the lateral OFC and PFC (Remijnse et al. 2006; Chamberlain et al. 2008; Gu et al. 2008) as well as in the parietal cortex (Chamberlain et al. 2008; Gu et al. 2008) in patients. This hypoactivation was related to the weaker performance and especially the slowed responding of patients in tasks requiring cognitive flexibility (Remijnse et al. 2009). Because unaffected relatives of OCD patients also yielded reduced lateral OFC and PFC activation in a reversal learning task, this pattern has been proposed as a candidate endophenotype of OCD (Chamberlain et al. 2008).

Few studies have examined reversal learning in OCD patients using ERPs. These ERP studies focussed particularly on the Ne and on feedback-related potentials. Neither the Ne nor the feedback potentials differed between adult OCD patients and controls in the study of Nieuwenhuis et al. (2005). The absence of excessive Ne amplitude in adult OCD patients may be explained by diminished action monitoring processes given that the task included a trial-to-trial feedback as well as undetermined stimulus response associations (Nieuwenhuis et al. 2005). In a study conducted by Grundler et al. (2009), the relations between Ne amplitude and OC symptoms in adults were opposite even when comparing a probabilistic learning task with a simple flanker task: the diminished differential Ne amplitude in the probabilistic reinforcement learning task was interpreted as hypoactivity in neural systems promoting active avoidance and perhaps corresponding to the inability of OCD patients to learn to inhibit repetitive behaviours. Hyperactivity in the same neural system, in contrast, as seen during the flanker task, could indicate the perpetuation of a previously maladaptive response that is reflected in stereotypical behaviours (Grundler et al. 2009).

Two studies so far have tested cognitive flexibility in children and adolescents. Rubia et al. (2010) used a simple visuo-spatial switch task that required switching between two spatial dimensions to examine their  $14.3 \pm 1.7$ -year-old patients. Only minor activation differences on a trend level in the left precentral and inferior prefrontal cortex between OCD patients and controls (Woolley et al. 2008; Rubia et al. 2010) were found for dimensional switch versus non-switch (repeat) trials. The absence of clear disorder-specific effects in brain activation could, however, be explained by studying a relatively small group ( $n = 10$ ) of mostly medicated OCD patients with only some residual symptoms.

The study of Britton et al. (2010a) of medicated but still symptomatic OCD patients (aged 10–17 years, mean  $13.5 \pm 2.4$  years) examined cognitive flexibility using a blocked set-shifting paradigm with the two dimensions of

colour and shape. Within the blocks, the target dimension (colour or shape) either alternated or remained unchanged. The set-shifting contrast yielded reduced activation in OCD patients in the left inferior frontal gyrus and a negative correlation between behavioural shift costs (defined as reaction time differences between alternating and repeated trials) and right caudate activation. Together with previous findings in adult patients (Remijnse et al. 2006; Chamberlain et al. 2008; Gu et al. 2008), the results suggest dysfunction in the dorsal cognitive CST loop.

Learning processes in paediatric patients with OCD were examined in a study by Lazaro et al. (2008). The dysfunction of premotor-cortico-striatal activity was studied using a serial reaction time task testing the implicit serial learning of complex and simple sequences in a group of OCD patients (7–18 years) before and after 6 months of pharmacological treatment. Hyperactivation of the bilateral middle frontal gyri in OCD patients before and in the right inferior parietal lobe after treatment was reported. A comparison of pre- and post-treatment yielded a reduction in hyperactivation in the left insula and putamen, which has been associated with decreased anxiety due to clinical improvements. Treatment did not normalize the hyperactivity in the frontal cortex. Huyser et al. (2010) compared planning processes in 25 unmedicated paediatric OCD patients (9–19 years) and healthy controls in an age- and gender-matched pairs design. A modified Tower of London task including one control and five planning conditions of different task loads was performed during fMRI scanning before and after 16 sessions of cognitive behavioural treatment (CBT). The effects of group and/or time with planning or task load were analysed. Like adult patients (van den Heuvel et al. 2005), paediatric patients also exhibited hypoactivation in the left posterior dlPFC/premotor cortex and the right parietal cortex prior to CBT. Diminished activation during planning was no longer found after CBT, and the authors suggested that this hypoactivation represents a state rather than a trait marker of paediatric OCD. Task load was associated with increased activation of the ventrolateral and medial PFC, ACC, and insula in paediatric OCD patients compared to controls before treatment, which may reflect increased error monitoring for demanding processes. After treatment, a decrease and normalisation of the right inferior frontal activation in OCD patients was found for increased task loads.

### *Emotion processing*

Only one functional activation study examined emotion processing in paediatric patients with OCD. Britton et al. (2010b) looked at the processing of emotional stimuli in their patients ( $13.8 \pm 2.4$  years) to determine whether paediatric OCD differs from other anxiety disorders by

showing reduced rather than increased amygdala activity. Emotional (fearful, happy, disgusted) and neutral facial stimuli were presented to the children in an event-related design. As expected, the OCD children revealed reduced amygdala/hippocampus activation in response to emotional and neutral facial stimuli and thereby underlined the distinction from other anxiety disorders. Happy faces were, furthermore, associated with excessive activation in the dorsal ACC of OCD patients, while fearful faces evoked hyperactivation in the ventrolateral PFC and hypoactivation in the OFC.

#### *Working memory and memory traces*

There is some evidence for the existence of a deficit in working memory function in patients with OCD (Purcell et al. 1998; van der Wee et al. 2003, 2007; Nakao et al. 2009; review: Chamberlain et al. 2005), especially for difficult tasks with high working memory loads or when failures in strategy impair performance in a given task (Chamberlain et al. 2005). Working memory function may even be related to symptom type, as shown by the poor performance in a study of adult patients with checking symptoms compared to those with washing symptoms (Nakao et al. 2009). Only a few studies have examined working memory function in OCD patients with neuroimaging techniques, and the results have been rather inconsistent. More pronounced activation in the dlPFC, superior temporal gyrus, insula, and cuneus was reported for adult OCD patients compared to controls in a two-back task (Nakao et al. 2009). Van der Wee et al. (2003) revealed enhanced ACC activity in adult OCD patients during a spatial working memory task but attributed this overactivation to monitoring rather than specific working memory processes. A single EEG study (and no fMRI or PET studies) has so far examined working memory traces in paediatric OCD patients. Auditory oddball tasks (Oades et al. 1996, 1997) were applied to study working memory traces during focussed (active) versus diffuse (passive) attention allocation. Healthy controls and the group of adolescents with OCD aged 11–19 years (mean 16.3 years) in the studies by Oades et al. (1996, 1997) served as control patients to two groups of patients with schizophrenia (with or without paranoid-hallucinatory symptoms). The focus of this article was, thus, on group differences in the auditory ERPs in the time range from 20 to 550 ms after stimulus presentation and especially the mismatch negativity (MMN) known to be attenuated in schizophrenia. The MMN represents a pre-attentive potential and has been related to the formation of perceptual traces or working memory. Despite the focus on patients with schizophrenia, the data also has shown some differences between OCD patients and healthy controls. These differences included

strongly expressed P3, enhanced MMN in the active attention allocation condition, topographic asymmetries in the form of a right lateralized auditory N1, a delayed N2 peak, and a reduced P2 amplitude. ERP analyses, thus, have pointed to differences in the formation of perceptual traces in OCD patients, but more research is needed to clarify specific failures in working memory processes.

#### *Preliminary ALE meta-analysis of paediatric OCD studies*

With our preliminary ALE meta-analysis, we attempted to elucidate the most consistent foci of abnormal brain activation across different cognitive tasks in paediatric OCD. Significant clusters that exceeded the ALE minimal cluster threshold were located in the bilateral amygdalae, parahippocampal gyrus, left anterior insula, and left orbitofrontal cortex (see Table 2C). More specifically, the results (Fig. 2) revealed four clusters that showed hypoactivation in paediatric OCD compared to healthy controls in the left and right parahippocampal gyri/amygdala extending to the left orbitofrontal cortex and the ventral part of the putamen. The two clusters in the right inferior parietal lobule and the left posterior dlPFC (middle frontal gyrus) should be regarded as trends for differential activation because of their rather small cluster sizes (Table 2A). Excessive activation in OCD patients was found in the right superior temporal gyrus, anterior insula, putamen, dorsal ACC, right dorsomedial, and left dorsolateral PFC (Table 2B). Please note that these preliminary results have to be interpreted with caution. Major limitations regarding the validity of this analysis apply because the results are based on a very limited set of functional neuroimaging studies. Therefore, these analyses include activation foci of very few independent samples of paediatric OCD patients evoked by different cognitive tasks. The analyses, thus, cannot provide information about task-specific activation abnormalities but may only give a first impression on where the most consistent abnormalities (Table 2C) in functional activation are located. Given the very limited number of studies in paediatric patients, including either unmedicated and/or medicated patients with or without comorbidities, so far, it is difficult to disentangle consistent traits or markers from functional neuroimaging data that specifically characterize childhood OCD.

## **Discussion**

The rapidly growing literature on cognitive functional networks in children and adolescents with OCD shows the increasing interest in understanding the alterations in cognitive networks underlying OCD in childhood and/or adolescence. Studying paediatric patients has the advantage

that the data is usually less prone to confounding factors such as alterations in brain structure and function due to the chronicity of the disorder, past treatments, medications, and/or behavioural compensation strategies that may have emerged in patients to cope with the distressing symptoms. According to formal genetic studies, the early-onset OCD phenotype (age of onset under 18 years of age) showed higher heritability (Chabane et al. 2005) than the late-onset phenotype. Therefore, biological mechanisms seem to more strongly influence the early-onset phenotype (Walitza et al. 2010). Studies with paediatric patients should, thus, provide more direct insights into the underlying brain dysfunctions of early-onset OCD. Similar to adults, however, the interpretation of data collected in paediatric studies also suffers from the heterogeneous nature of the disorder in terms of age of onset, severity, symptom types, and varying time elapsing between onset and diagnosis as well as from comorbidities, therapy, and medication. Moreover, the variability in the data of paediatric OCD patients is further increased by the major developmental and maturational changes that occur in brain networks during childhood and adolescence. This problem is especially pronounced when studies include patients of a wide age range because functional as well as structural changes in grey and white matter and especially within the cortical and subcortical structures of the affected networks are major (Giedd et al. 1999; Paus et al. 1999; Sowell et al. 1999, 2001, 2004a, b; Giedd et al. 2004; Gogtay et al. 2004; Casey et al. 2008; Thompson et al. 2000).

The heterogeneity seen in the symptoms of the disorder is largely mirrored by the variability in the results of neuroimaging studies. Still, the overall pattern of altered functional brain activation in paediatric OCD patients largely corresponds to the neurobiological working model of a dysregulation in cortico-striato-thalamic circuits and, more specifically, to failures of the cognitive and affective loops (reviews, see Saxena et al. 1998; Chamberlain et al. 2005; Friedlander and Desrocher 2006; Maia et al. 2008; Menzies et al. 2008; van den Heuvel et al. 2010). A meta-analysis of cognitive activation studies in adult OCD patients identified the brain areas that showed the most consistent alterations in activation patterns across studies and different tasks (Menzies et al. 2008). Thereafter, excessive activation in OCD patients was localized mainly in the inferior and medial frontal cortex, ACC, claustrum, thalamus, caudate, and parts of the posterior cingulate, occipital, and parietal cortices. According to our preliminary meta-analyses, the excessive activation of the ACC thus coincided in paediatric and adult OCD. Overactive performance monitoring processes in OCD patients, as revealed by ERP and fMRI studies, could be required to control for the increased emotional salience of cognitive stimuli in conflict situations (Fitzgerald et al. 2010) and

may also cause the feeling of patients that something is wrong and needs correction (Aouizerate et al. 2004). Even though abnormal ACC activity quite consistently characterizes adult and paediatric OCD patients, there is some evidence for an age-specific dysfunction of this structure: a volumetric study revealed that the typical maturational increase in the ACC volume in healthy controls was absent in OCD patients (Rosenberg and Keshavan 1998). The absence of these age-related maturation effects and the increased ACC volume (Rosenberg and Keshavan 1998) and grey matter density (Szeszko et al. 2008) in OCD patients have been interpreted as a failure in neuronal pruning during development (Rosenberg and Keshavan 1998). More evidence specifically pointing to a failure in the maturation of CST loops was provided by two very recently published cross-sectional studies, one on cognitive activation during interference processing (Huyser et al. 2011) and one on functional connectivity during resting state (Fitzgerald et al. 2011). These studies directly compared different age groups of paediatric OCD patients (Huyser et al. 2011) or paediatric and adult OCD patients (Fitzgerald et al. 2011). The connectivity between the rostral ACC and the dorsal striatum was especially reduced in young paediatric OCD patients, while the connectivity between the dorsal striatum and the ventral medial frontal cortex was enhanced across development in patients (Fitzgerald et al. 2011). The authors concluded that the hypoconnectivity in the cognitive control circuits may characterize OCD in young patients, in contrast to the hyperconnectivity of affective circuits that is common to OCD across development. Not all studies reported increased ACC activity in paediatric patients with OCD during interference or error processing. The rostral ACC, for example, showed normal activation in very young but increased activity in older paediatric patients during error processing (Huyser et al. 2011), and the dorsal ACC/SMA exhibited diminished activation even during conflict processing in the study of Rubia et al. (2011).

Such findings indicate that differential development may characterize the maturation of CST networks in OCD. Unfortunately, no longitudinal studies exist that track and compare the development of CST networks between affected and healthy children. The neuroimaging studies with the longest follow-up interval to date focussed on the effect of treatments within a restricted period of time (usually up to 6 months) rather than on the long-term development and maturation of brain networks (Lazaro et al. 2009; Huyser et al. 2010, 2011). Longitudinal follow-up studies of patients from childhood onward would be critical to understand how the disorder affects brain maturation and important to disentangle the impact of chronicity, treatment, and development on brain networks. Pronounced abnormalities in the structural development of

CST networks in OCD patients have already been reported (Rosenberg and Keshavan 1998; for a review, see Huyser et al. 2009).

In contrast to the usual hyperactivity in affective CST loops during simple error performance monitoring tasks in OCD patients, the activation of the dorsal, cognitive CST loop, and especially the dorsolateral prefrontal cortex and the lateral OFC was often diminished in challenging cognitive tasks. This held for both paediatric (Woolley et al. 2008; Britton et al. 2010a; Huyser et al. 2010; Rubia et al. 2010) and adult patients (Remijnse et al. 2005, 2006; Chamberlain et al. 2008; Gu et al. 2008; Freyer et al. 2010) in tasks requiring cognitive control for, e.g., planning and/or the flexible adjustment of behaviour through learning. The meta-analyses of Menzies et al. (2008) revealed reduced activation in adult OCD patients in comparison to controls mainly in the basal ganglia, i.e., in the putamen and caudate nucleus but also in the lateral OFC, inferior frontal gyrus, insula, parahippocampal gyrus/amygdala, cerebellum, and ACC (Menzies et al. 2008). The foci of hypoactivation in adult patients, thus, converged with those identified in our preliminary meta-analysis of paediatric patients regarding the parahippocampal gyrus/amygdala. In addition, our meta-analysis pointed to two foci in the middle frontal gyrus (posterior dlPFC) and the inferior parietal lobule, where paediatric patients showed reduced activation. Even though the meta-analyses identified the OFC as a focus of altered activation, no focus of consistent hypoactivation was found in the ventral PFC for paediatric patients. Also, regarding the functional activation of the dlPFC, mixed results were found: one cluster at the posterior end of the dlPFC tended to indicate hypoactivation whereas two clusters in the left dorsolateral and right dorsomedial PFC exhibited hyperactivation in paediatric OCD patients. Still, several studies with paediatric OCD patients have reported hypoactivation of the ventral PFC (including OFC) (Britton et al. 2010a, b; Rubia et al. 2010; Woolley et al. 2008; Gilbert et al. 2009; Fitzgerald et al. 2010) or the dlPFC in switch and planning tasks (Rubia et al. 2010; Woolley et al. 2008; Huyser et al. 2010), in accordance with adult studies. The reduced activation in tasks requiring cognitive flexibility (Remijnse et al. 2009) may represent a neural correlate of deficient self-control over behaviours and explain the difficulty of stopping the inappropriate compulsive behaviours (Aouizerate et al. 2004) that are common to paediatric and adult OCD. To summarize, altered activation was found primarily in the same cortico-striatal brain regions for adult (Menzies et al. 2008) and paediatric OCD patients, as indicated by the meta-analyses. The direction of activation differences, though, yielded partly opposing results between youth and adults such as the hyperactivation in the anterior insula and the putamen in paediatric patients. Even though the results

provide some preliminary insight into alterations in cognitive activation patterns, the interpretation and relation to altered cognitive function is difficult because a variety of cognitive tasks had to be included in the present meta-analyses.

The quite consistent overactivation of the OFC reported for adult patients during symptom provocation (for meta-analyses and review tables, see Whiteside et al. 2004; Menzies et al. 2008; Baxter et al. 1987, 1988; Alptekin et al. 2001; Diler et al. 2004, but see Lucey et al. 1995) has so far not been replicated in paediatric patients (Gilbert et al. 2009): instead, diminished activation was found in the OFC and in other brain areas of the CST loops. An evaluation of this difference between children and adults is difficult since only one study so far has examined paediatric patients, and no direct comparison between adult and paediatric patients is available. It needs to be clarified whether the deactivation found in the prefrontal cortex of paediatric patients is related to a delayed maturation of these structures compared to healthy peers or whether it reflects a neural correlate of dysfunctional cognitive processing.

It has to be noted that the majority of the studies used for the meta-analysis and reviewed here included mixed groups of non-medicated and medicated paediatric patients with or without treatment history and comorbidities (see Table 1). Treatments and comorbidities (e.g., generalized anxiety disorder, depression, etc.) may confound the activation results and make comparisons between studies more difficult. Two of the reviewed paediatric studies, on fMRI symptom provocation and ERP conflict monitoring, included an additional analysis comparing the effects in medicated and non-medicated OCD patients (Gilbert et al. 2009; Hajcak et al. 2008). These comparisons yielded neither fMRI activation differences nor differences in the core ERP measures, thereby confirming the validity of the results. From other studies, however, it is well known that psychotropic medication (e.g., SSRIs) may affect the brain chemistry (Rosenberg et al. 2000), structure (e.g., thalamus (Atmaca et al. 2006; Gilbert et al. 2000) or amygdala (Szeszko et al. 2004)), and functional activation (e.g., Lazaro et al. 2008). Moreover, medication effects depend on the task and, thus, are process specific (Del-Ben et al. 2005). While most of the summarized ERP studies concentrated on medication-free OCD samples, only the fMRI treatment studies examining CBT (Huyser et al. 2010, 2011) or SSRI medication (Lazaro et al. 2008) reported results from non-medicated patients at baseline (Lazaro et al. 2008) or both assessments (Huyser et al. 2010, 2011). In the SSRI treatment study, medication along with clinical improvements had the most impact on activation in the insula and putamen. Given the evidence that treatments and/or comorbidity may affect functional activation, it is

important that future studies control for such confounding variables. However, one should keep in mind that comorbidities are highly frequent among patients with OCD. The strict exclusion of patients with comorbidities would, thus, massively complicate recruitment and result in smaller sample sizes.

To summarize, paediatric and adult studies converge in showing abnormal activity in cognitive as well as affective CST circuits. However, it remains to be examined whether the impact of different CST networks and their role in the establishment of obsessions and/or compulsions change with development and differ between subtypes of OCD.

## Conclusions

Studies on OCD in adult and paediatric patients both point to dysfunction in cognitive and affective CST loops, by either showing hyper- or hypoactivation in—and altered functional connectivity between—specific brain structures. The modest number of paediatric OCD neuroimaging studies and especially the lack of studies with a cross-sectional and/or longitudinal approach to date does not allow for delineating and characterizing specific differences between paediatric and adult OCD or between OCD with early and late onset. Only two very recent studies compared patients across different age groups and were able to show commonalities as well as specific differences between neuronal networks in younger and older OCD patients. More cross-sectional studies elucidating differences in cognitive processing across age groups of paediatric OCD patients and especially longitudinal studies that track the maturation of affected brain networks over time are needed. Such studies may help us to understand how the functional development of CST networks in healthy children deviates from that of patients, how the disorder affects brain development, and whether markers from neuroimaging could be used to characterize different subtypes of OCD in the future.

**Acknowledgments** We thank the Swiss National Science Foundation, project No. 320030\_130237 and the Hartmann-Müller foundation for medical research (project No. 1460), University of Zürich, for funding.

**Conflict of interest** S. Walitza received speakers honoraria from Eli Lilly, Janssen-Cilag and AstraZeneca in the last five years. The other authors declare no competing financial interests.

## References

- Adler CM, McDonough-Ryan P, Sax KW, Holland SK, Arndt S, Strakowski SM (2000) Fmri of neuronal activation with symptom provocation in unmedicated patients with obsessive compulsive disorder. *J Psychiatr Res* 34(4–5):317–324
- Albin RL, Young AB, Penney JB (1989) The functional anatomy of basal ganglia disorders. *Trends Neurosci* 12(10):366–375
- Alptekin K, Degirmenci B, Kivircik B, Durak H, Yemez B, Derebek E, Tunca Z (2001) Tc-99m Hmpao brain perfusion Spect in drug-free obsessive-compulsive patients without depression. *Psychiatry Res* 107(1):51–56
- American Psychiatric Association (2000) DSM-IV: diagnostic and statistical manual of mental disorders. American Psychiatric Association, Washington, D.C.
- Andres S, Boget T, Lazaro L, Penades R, Morer A, Salamero M, Castro-Fornieles J (2007) Neuropsychological performance in children and adolescents with obsessive-compulsive disorder and influence of clinical variables. *Biol Psychiatry* 61(8):946–951
- Andres S, Lazaro L, Salamero M, Boget T, Penades R, Castro-Fornieles J (2008) Changes in cognitive dysfunction in children and adolescents with obsessive-compulsive disorder after treatment. *J Psychiatr Res* 42(6):507–514
- Aouizerate B, Guehl D, Cuny E, Rougier A, Bioulac B, Tignol J, Burbaud P (2004) Pathophysiology of obsessive-compulsive disorder: a necessary link between phenomenology, neuropsychology, imagery and physiology. *Prog Neurobiol* 72(3):195–221
- Atmaca M, Yildirim BH, Ozdemir BH, Aydin BA, Tezcan AE, Ozler AS (2006) Volumetric MRI assessment of brain regions in patients with refractory obsessive-compulsive disorder. *Prog Neuropsychopharmacol Biol Psychiatry* 30(6):1051–1057
- Baxter LR Jr, Phelps ME, Mazziotta JC, Guze BH, Schwartz JM, Selin CE (1987) Local cerebral glucose metabolic rates in obsessive-compulsive disorder. A Comparison with rates in unipolar depression and in normal controls. *Arch Gen Psychiatry* 44(3):211–218
- Baxter LR Jr, Schwartz JM, Mazziotta JC, Phelps ME, Pahl JJ, Guze BH, Fairbanks L (1988) Cerebral glucose metabolic rates in nondepressed patients with obsessive-compulsive disorder. *Am J Psychiatry* 145(12):1560–1563
- Beers SR, Rosenberg DR, Dick EL, Williams T, O’Hearn KM, Birmaher B, Ryan CM (1999) Neuropsychological study of frontal lobe function in psychotropic-naïve children with obsessive-compulsive disorder. *Am J Psychiatry* 156(5):777–779
- Behar D, Rapoport JL, Berg CF, Denckla MB, Mann L, Cox C et al (1984) Computerized tomography and neuropsychological test measures in adolescents with obsessive-compulsive disorder. *Am J Psychiatry* 141:363–369
- Britton JC, Rauch SL, Rosso IM, Killgore WD, Price LM, Ragan J, Chosak A, Hezel DM, Pine DS, Leibenluft E, Pauls DL, Jenike MA, Stewart SE (2010a) Cognitive inflexibility and frontal-cortical activation in pediatric obsessive-compulsive disorder. *J Am Acad Child Adolesc Psychiatry* 49(9):944–953
- Britton JC, Stewart SE, Killgore WD, Rosso IM, Price LM, Gold AL, Pine DS, Wilhelm S, Jenike MA, Rauch SL (2010b) Amygdala activation in response to facial expressions in pediatric obsessive-compulsive disorder. *Depress Anxiety* 27(7):643–651
- Brown TT, Lugar HM, Coalson RS, Miezin FM, Petersen SE, Schlaggar BL (2005) Developmental changes in human cerebral functional organization for word generation. *Cereb Cortex* 15(3):275–290
- Casey B, Galvan A, Hare TA (2005) Changes in cerebral functional organization during cognitive development. *Curr Opin Neurobiol* 15(2):239–244
- Casey BJ, Getz S, Galvan A (2008) The adolescent brain. *Dev Rev* 28(1):62–77
- Chabane N, Delorme R, Millet B, Mouren MC, Leboyer M, Pauls D (2005) Early-onset obsessive-compulsive disorder: a subgroup with a specific clinical and familial pattern? *J Child Psychol Psychiatry* 46:881–887

- Chamberlain SR, Blackwell AD, Fineberg NA, Robbins TW, Sahakian BJ (2005) The neuropsychology of obsessive compulsive disorder: the importance of failures in cognitive and behavioural inhibition as candidate endophenotypic markers. *Neurosci Biobehav Rev* 29(3):399–419
- Chamberlain SR, Fineberg NA, Menzies LA, Blackwell AD, Bullmore ET, Robbins TW, Sahakian BJ (2007) Impaired cognitive flexibility and motor inhibition in unaffected first-degree relatives of patients with obsessive-compulsive disorder. *Am J Psychiatry* 164(2):335–338
- Chamberlain SR, Menzies L, Hampshire A, Suckling J, Fineberg NA, del Campo N, Aitken M, Craig K, Owen AM, Bullmore ET, Robbins TW, Sahakian BJ (2008) Orbitofrontal dysfunction in patients with obsessive-compulsive disorder and their unaffected relatives. *Science* 321(5887):421–422
- Cox CS, Fedio P, Rapoport JL (1989) Neuropsychological testing of obsessive-compulsive adolescents. In: Rapoport JL (ed) *Obsessive-compulsive disorder in children and adolescents*. American Psychiatric Press, Washington, D.C., pp 73–85
- Dehaene S, Posner MI, Tucker DM (1994) Localization of a neural system for error detection and compensation. *Psychol Sci* 5(5):303–305
- Del-Ben CM, Deakin JF, McKie S, Delvai NA, Williams SR, Elliott R (2005) The effect of citalopram pretreatment on neuronal responses to neuropsychological tasks in normal volunteers: an fMRI study. *Neuropsychopharmacology* 30(9):1724–1734
- Delorme R, Golmard JL, Chabane N, Millet B, Krebs MO, Mouren-Simeoni MC, Leboyer M (2005) Admixture analysis of age at onset in obsessive-compulsive disorder. *Psychol Med* 35(2):237–243
- Di Russo F, Zaccara G, Ragazzoni A, Pallanti S (2000) Abnormal visual event-related potentials in obsessive-compulsive disorder without panic disorder or depression comorbidity. *J Psychiatr Res* 34(1):75–82
- Diler R, Kibar M, Avci A (2004) Pharmacotherapy and regional cerebral blood flow in children with obsessive compulsive disorder. *Yonsei Med J* 45(1):90–99
- do Rosario-Campos MC, Leckman JF, Curi M, Quatrano S, Katsovitch L, Miguel EC, Pauls DL (2005) A family study of early-onset obsessive-compulsive disorder. *Am J Med Genet B Neuropsychiatr Genet* 136B:92–97
- Donkers FC, van Boxtel GJ (2004) The N2 in Go/No-Go tasks reflects conflict monitoring not response inhibition. *Brain Cogn* 56(2):165–176
- Eickhoff SB, Laird AR, Grefkes C, Wang LE, Zilles K, Fox PT (2009) Coordinate-based activation likelihood estimation meta-analysis of neuroimaging data: a random-effects approach based on empirical estimates of spatial uncertainty. *Hum Brain Mapp* 30(9):2907–2926
- Elliott R, Dolan RJ, Frith CD (2000) Dissociable functions in the medial and lateral orbitofrontal cortex: evidence from human neuroimaging studies. *Cereb Cortex* 10(3):308–317
- Endrass T, Klawohn J, Schuster F, Kathmann N (2008) Overactive performance monitoring in obsessive-compulsive disorder: Erp evidence from correct and erroneous reactions. *Neuropsychologia* 46(7):1877–1887
- Falkenstein M, Hoormann J, Hohnsbein J (1999) Erp components in Go/Nogo tasks and their relation to inhibition. *Acta Psychol (Amst)* 101(2–3):267–291
- Finger EC, Marsh AA, Mitchell DG, Reid ME, Sims C, Budhani S, Kosson DS, Chen G, Towbin KE, Leibenluft E, Pine DS, Blair JR (2008) Abnormal ventromedial prefrontal cortex function in children with psychopathic traits during reversal learning. *Arch Gen Psychiatry* 65(5):586–594
- Fitzgerald KD, Stern ER, Angstadt M, Nicholson-Muth KC, Maynor MR, Welsh RC, Hanna GL, Taylor SF (2010) Altered function and connectivity of the medial frontal cortex in pediatric obsessive-compulsive disorder. *Biol Psychiatry* 68(11):1039–1047
- Fitzgerald KD, Welsh RC, Stern ER, Angstadt M, Hanna GL, Abelson JL, Taylor SF (2011) Developmental alterations of frontal-striatal-thalamic connectivity in obsessive-compulsive disorder. *J Am Acad Child Adolesc Psychiatry* 50(9):938–948
- Flament MF, Whitaker A, Rapoport JL, Davies M, Berg CZ, Kalikow K, Sceery W, Shaffer D (1988) Obsessive compulsive disorder in adolescence: an epidemiological study. *J Am Acad Child Adolesc Psychiatry* 27(6):764–771
- Foa EB, Liebowitz MR, Kozak MJ, Davies S, Campeas R, Franklin ME, Huppert JD, Kjernisted K, Rowan V, Schmidt AB, Simpson HB, Tu X (2005) Randomized, placebo-controlled trial of exposure and ritual prevention, clomipramine, and their combination in the treatment of obsessive-compulsive disorder. *Am J Psychiatry* 162(1):151–161
- Freyer T, Kloppel S, Tuscher O, Kordon A, Zurowski B, Kuelz AK, Speck O, Glauche V, Voderholzer U (2010) Frontostriatal activation in patients with obsessive-compulsive disorder before and after cognitive behavioral therapy. *Psychol Med* 41(1):207–216
- Friedlander L, Desrocher M (2006) Neuroimaging studies of obsessive-compulsive disorder in adults and children. *Clin Psychol Rev* 26(1):32–49
- Galvan A, Hare T, Voss H, Glover G, Casey BJ (2007) Risk-taking and the adolescent brain: who is at risk? *Dev Sci* 10(2):F8–F14
- Garcia AM, Sapyta JJ, Moore PS, Freeman JB, Franklin ME, March JS, Foa EB (2010) Predictors and moderators of treatment outcome in the pediatric obsessive compulsive treatment study (Pots I). *J Am Acad Child Adolesc Psychiatry* 49(10):1024–1033 (quiz 1086)
- Geller DA (2006) Obsessive-compulsive and spectrum disorders in children and adolescents. *Psychiatr Clin North Am* 29(2):353–370
- Geller D, Biederman J, Jones J, Park K, Schwartz S, Shapiro S, Coffey B (1998) Is juvenile obsessive-compulsive disorder a developmental subtype of the disorder? A review of the pediatric literature. *J Am Acad Child Adolesc Psychiatry* 37(4):420–427
- Geller DA, Biederman J, Faraone S, Agranat A, Craddock K, Hagermoser L, Kim G, Frazier J, Coffey BJ (2001) Developmental aspects of obsessive compulsive disorder: findings in children, adolescents, and adults. *J Nerv Ment Dis* 189(7):471–477
- Giedd JN (2004) Structural magnetic resonance imaging of the adolescent brain. *Ann N Y Acad Sci* 1021:77–85
- Giedd JN, Blumenthal J, Jeffries NO, Castellanos FX, Liu H, Zijdenbos A, Paus T, Evans AC, Rapoport JL (1999) Brain development during childhood and adolescence: a longitudinal MRI study. *Nat Neurosci* 2(10):861–863
- Gilbert AR, Moore GJ, Keshavan MS, Paulson LA, Narula V, Mac Master FP (2000) Decrease in thalamic volumes of pediatric patients with obsessive-compulsive disorder who are taking paroxetine. *Arch Gen Psychiatry* 57(5):449–456
- Gilbert AR, Akkal D, Almeida JR, Mataix-Cols D, Kalas C, Devlin B, Birmaher B, Phillips ML (2009) Neural correlates of symptom dimensions in pediatric obsessive-compulsive disorder: a functional magnetic resonance imaging study. *J Am Acad Child Adolesc Psychiatry* 48(9):936–944
- Gogtay N, Giedd JN, Lusk L, Hayashi KM, Greenstein D, Vaituzis AC, Nugent TF 3rd, Herman DH, Clasen LS, Toga AW, Rapoport JL, Thompson PM (2004) Dynamic mapping of human cortical development during childhood through early adulthood. *Proc Natl Acad Sci USA* 101(21):8174–8179
- Graybiel AM, Rauch SL (2000) Toward a neurobiology of obsessive-compulsive disorder. *Neuron* 28(2):343–347

- Grundler TO, Cavanagh JF, Figueroa CM, Frank MJ, Allen JJ (2009) Task-related dissociation in error amplitude as a function of obsessive-compulsive symptoms. *Neuropsychologia* 47(8–9):1978–1987
- Gu BM, Park JY, Kang DH, Lee SJ, Yoo SY, Jo HJ, Choi CH, Lee JM, Kwon JS (2008) Neural correlates of cognitive inflexibility during task-switching in obsessive-compulsive disorder. *Brain* 131(Pt 1):155–164
- Hajcak G, Franklin ME, Foa EB, Simons RF (2008) Increased error-related brain activity in pediatric obsessive-compulsive disorder before and after treatment. *Am J Psychiatry* 165(1):116–123
- Hare TA, Camerer CF, Rangel A (2009) Self-control in decision-making involves modulation of the Vmpfc valuation system. *Science* 324(5927):646–648
- Holroyd CB, Coles MG (2002) The neural basis of human error processing: reinforcement learning, dopamine, and the error-related negativity. *Psychol Rev* 109(4):679–709
- Huey ED, Zahn R, Krueger F, Moll J, Kapogiannis D, Wassermann EM (2008) A psychological and neuroanatomical model of obsessive-compulsive disorder. *J Neuropsychiatr Clin Neurosci* 20(4):390–408
- Huysen C, Veltman DJ, de Haan E, Boer F (2009) Paediatric obsessive-compulsive disorder, a neurodevelopmental disorder? evidence from neuroimaging. *Neurosci Biobehav Rev* 33:818–830
- Huysen C, Veltman DJ, Wolters LH, de Haan E, Boer F (2010) Functional magnetic resonance imaging during planning before and after cognitive-behavioral therapy in pediatric obsessive-compulsive disorder. *J Am Acad Child Adolesc Psychiatry* 49(12):1238–1248
- Huysen C, Veltman DJ, Wolters LH, de Haan E, Boer F (2011) Developmental aspects of error and high-conflict-related brain activity in pediatric obsessive-compulsive disorder: a fMRI study with a flanker task before and after Cbt. *J Child Psychol Psychiatry* 52(12):1251–1260
- Johannes S, Wieringa BM, Nager W, Rada D, Dengler R, Emrich HM, Münte TF, Dietrich DE (2001) Discrepant target detection and action monitoring in obsessive-compulsive disorder. *Psychiatry Res* 108(2):101–110
- Kanemura H, Aihara M, Aoki S, Araki T, Nakazawa S (2003) Development of the prefrontal lobe in infants and children: a three-dimensional magnetic resonance volumetric study. *Brain Dev* 25(3):195–199
- Kessler RC, Berglund P, Demler O, Jin R, Merikangas KR, Walters EE (2005) Lifetime prevalence and age-of-onset distributions of DSM-IV disorders in the national comorbidity survey replication. *Arch Gen Psychiatry* 62(6):593–602
- Kim MS, Kim YY, Yoo SY, Kwon JS (2007) Electrophysiological correlates of behavioral response inhibition in patients with obsessive-compulsive disorder. *Depress Anxiety* 24(1):22–31
- Kolada JL, Bland RC, Newman SC (1994) Epidemiology of psychiatric disorders in Edmonton. *Obsessive-compulsive disorder. Acta Psychiatr Scand Suppl* 376:24–35
- Kopp B, Mattler U, Goertz R, Rist F (1996) N2, P3 and the lateralized readiness potential in a Nogo task involving selective response priming. *Electroencephalogr Clin Neurophysiol* 99(1):19–27
- Kringelbach ML (2005) The human orbitofrontal cortex: linking reward to hedonic experience. *Nat Rev Neurosci* 6(9):691–702
- Laird AR, Fox PM, Price CJ, Glahn DC, Uecker AM, Lancaster JL, Turkeltaub PE, Kochunov P, Fox PT (2005) ALE meta-analysis: controlling the false discovery rate and performing statistical contrasts. *Hum Brain Mapp* 25(1):155–164
- Lazaro L, Caldu X, Junque C, Bargallo N, Andres S, Morer A, Castro-Fornieles J (2008) Cerebral activation in children and adolescents with obsessive-compulsive disorder before and after treatment: a functional MRI study. *J Psychiatr Res* 42(13):1051–1059
- Lazaro L, Bargallo N, Castro-Fornieles J, Falcon C, Andres S, Calvo R, Junque C (2009) Brain changes in children and adolescents with obsessive-compulsive disorder before and after treatment: a voxel-based morphometric MRI study. *Psychiatry Res* 172(2):140–146
- Lucey JV, Costa DC, Blanes T, Busatto GF, Pilowsky LS, Takei N, Marks IM, Ell PJ, Kerwin RW (1995) Regional cerebral blood flow in obsessive-compulsive disorder patients at rest. Differential correlates with obsessive-compulsive and anxious-avoidant dimensions. *Br J Psychiatry* 167(5):629–634
- MacMaster FP, O'Neill J, Rosenberg DR (2008) Brain imaging in pediatric obsessive-compulsive disorder. *J Am Acad Child Adolesc Psychiatry* 47(11):1262–1272
- Maia TV, Cooney RE, Peterson BS (2008) The neural bases of obsessive-compulsive disorder in children and adults. *Dev Psychopathol* 20(4):1251–1283
- Maltby N, Tolin DF, Worhunsky P, O'Keefe TM, Kiehl KA (2005) Dysfunctional action monitoring hyperactivates frontal-striatal circuits in obsessive-compulsive disorder: an event-related fMRI study. *Neuroimage* 24(2):495–503
- Mataix-Cols D, Wooderson S, Lawrence N, Brammer MJ, Speckens A, Phillips ML (2004) Distinct neural correlates of washing, checking, and hoarding symptom dimensions in obsessive-compulsive disorder. *Arch Gen Psychiatry* 61(6):564–576
- Menzies L, Chamberlain SR, Laird AR, Thelen SM, Sahakian BJ, Bullmore ET (2008) Integrating evidence from neuroimaging and neuropsychological studies of obsessive-compulsive disorder: the orbitofronto-striatal model revisited. *Neurosci Biobehav Rev* 32(3):525–549
- Mossner R, Doring N, Scherag A, Schafer H, Herpertz-Dahlmann B, Remschmidt H, Schulz E, Renner T, Wewetzer C, Warnke A, Lesch KP, Walitza S (2007) Transmission disequilibrium analysis of the functional 5-HT3a receptor variant C178t in early-onset obsessive compulsive-disorder. *J Psychopharmacol* 21(8):833–836
- Nakao T, Nakagawa A, Nakatani E, Nabeyama M, Sanematsu H, Yoshiura T (2009) Working memory dysfunction in obsessive-compulsive disorder: a neuropsychological and functional MRI study. *J Psychiatr Res* 43(8):784–791
- Nakao T, Nakagawa A, Yoshiura T, Nakatani E, Nabeyama M, Yoshizato C, Kudoh A, Tada K, Yoshioka K, Kawamoto M, Togao O, Kanba S (2005) Brain activation of patients with obsessive-compulsive disorder during neuropsychological and symptom provocation tasks before and after symptom improvement: a functional magnetic resonance imaging study. *Biol Psychiatry* 57(8):901–910
- Nestadt G, Samuels J, Riddle M, Bienvenu OJ 3rd, Liang KY, LaBuda M, Walkup J, Grados M, Hoehn-Saric R (2000) A family study of obsessive-compulsive disorder. *Arch Gen Psychiatry* 57(4):358–363
- Nieuwenhuis S, Nielen MM, Mol N, Hajcak G, Veltman DJ (2005) Performance monitoring in obsessive-compulsive disorder. *Psychiatry Res* 134(2):111–122
- Nobre AC, Coull JT, Frith CD, Mesulam MM (1999) Orbitofrontal cortex is activated during breaches of expectation in tasks of visual attention. *Nat Neurosci* 2(1):11–12
- Oades RD, Zerbin D, Dittmann-Balcar A, Eggers C (1996) Auditory event-related potential (Erp) and difference-wave topography in schizophrenic patients with/without active hallucinations and delusions: a comparison with young obsessive-compulsive disorder (Ocd) and healthy subjects. *Int J Psychophysiol* 22(3):185–214
- Oades RD, Dittmann-Balcar A, Zerbin D, Grzella I (1997) Impaired attention-dependent augmentation of MMN in nonparanoid vs paranoid schizophrenic patients: a comparison with obsessive-compulsive disorder and healthy subjects. *Biol Psychiatry* 41(12):1196–1210



- O'Doherty J, Kringelbach ML, Rolls ET, Hornak J, Andrews C (2001) Abstract reward and punishment representations in the human orbitofrontal cortex. *Nat Neurosci* 4(1):95–102
- O'Kearney RT, Anstey KJ, von Sanden C, Hunt A (2010) Behavioural and cognitive behavioural therapy for obsessive compulsive disorder in children and adolescents. *Cochrane Database of Systematic Reviews* 2006, Issue 4: Art. No.: CD004856, The Cochrane Library 2010, Issue 1
- Ornstein TJ, Arnold P, Manassis K, Mendlowitz S, Schachar R (2010) Neuropsychological performance in childhood Ocd: a preliminary study. *Depress Anxiety* 27(4):372–380
- Pauls DL, Alsobrook JP 2nd, Goodman W, Rasmussen S, Leckman JF (1995) A family study of obsessive-compulsive disorder. *Am J Psychiatry* 152:76–84
- Paus T, Zijdenbos A, Worsley K, Collins DL, Blumenthal J, Giedd JN, Rapoport JL, Evans AC (1999) Structural maturation of neural pathways in children and adolescents: in vivo study. *Science* 283(5409):1908–1911
- Pertusa A, Jaurieta N, Real E, Alonso P, Bueno B, Segalas C, Jimenez-Murcia S, Mataix-Cols D, Menchon JM (2010) Spanish adaptation of the dimensional Yale-Brown Obsessive-Compulsive Scale. *Compr Psychiatry* 51(6):641–648
- Purcell R, Maruff P, Kyrios M, Pantelis C (1998) Cognitive deficits in obsessive-compulsive disorder on tests of frontal-striatal function. *Biol Psychiatry* 43(5):348–357
- Radua J, Mataix-Cols D (2009) Voxel-wise meta-analysis of grey matter changes in obsessive-compulsive disorder. *Br J Psychiatry* 195(5):393–402
- Rasmussen SA, Eisen JL (1992) The epidemiology and clinical features of obsessive compulsive disorder. *Psychiatr Clin North Am* 15(4):743–758
- Remijne PL, Nielen MM, van Balkom AJ, Hendriks GJ, Hoogendijk WJ, Uylings HB, Veltman DJ (2009). Differential frontal-striatal and paralimbic activity during reversal learning in major depressive disorder and obsessive-compulsive disorder. *Psychol Med* 39(9):1503–1518
- Remijne PL, Nielen MM, Uylings HB, Veltman DJ (2005) Neural correlates of a reversal learning task with an affectively neutral baseline: an event-related fMRI study. *Neuroimage* 26(2):609–618
- Remijne PL, Nielen MM, van Balkom AJ, Cath DC, van Oppen P, Uylings HB, Veltman DJ (2006) Reduced orbitofrontal-striatal activity on a reversal learning task in obsessive-compulsive disorder. *Arch Gen Psychiatry* 63(11):1225–1236
- Rosario-Campos MC, Leckman JF, Mercadante MT, Shavitt RG, Prado HS, Sada P, Zamignani D, Miguel EC (2001) Adults with early-onset obsessive-compulsive disorder. *Am J Psychiatry* 158(11):1899–1903
- Rosenberg DR, Keshavan MS (1998) A.E. Bennett Research Award. Toward a neurodevelopmental model of obsessive-compulsive disorder. *Biol Psychiatry* 43(9):623–640
- Rosenberg DR, Averbach DH, O'Hearn KM, Seymour AB, Birmaher B, Sweeney JA (1997a) Oculomotor response inhibition abnormalities in pediatric obsessive-compulsive disorder. *Arch Gen Psychiatry* 54(9):831–838
- Rosenberg DR, Dick EL, O'Hearn KM, Sweeney JA (1997b) Response-inhibition deficits in obsessive-compulsive disorder: an indicator of dysfunction in frontostriatal circuits. *J Psychiatry Neurosci* 22(1):29–38
- Rosenberg DR, Benazon NR, Gilbert A, Sullivan A, Moore GJ (2000) Thalamic volume in pediatric obsessive-compulsive disorder patients before and after cognitive behavioral therapy. *Biol Psychiatry* 48(4):294–300
- Roth RM, Saykin AJ, Flashman LA, Pixley HS, West JD, Mamourian AC (2007) Event-related functional magnetic resonance imaging of response inhibition in obsessive-compulsive disorder. *Biol Psychiatry* 62(8):901–909
- Rubia K, Cubillo A, Smith AB, Woolley J, Heyman I, Brammer MJ (2010) Disorder-specific dysfunction in right inferior prefrontal cortex during two inhibition tasks in boys with attention-deficit hyperactivity disorder compared to boys with obsessive-compulsive disorder. *Hum Brain Mapp* 31(2):287–299
- Rubia K, Cubillo A, Woolley J, Brammer MJ, Smith A (2011) Disorder-specific dysfunctions in patients with attention-deficit/hyperactivity disorder compared to patients with obsessive-compulsive disorder during interference inhibition and attention allocation. *Hum Brain Mapp* 32(4):601–611
- Ruchow M, Reuter K, Hermle L, Ebert D, Kiefer M, Falkenstein M (2007) Executive control in obsessive-compulsive disorder: event-related potentials in a Go/Nogo task. *J Neural Transm* 114(12):1595–1601
- Ruscio AM, Stein DJ, Chiu WT, Kessler RC (2010) The epidemiology of obsessive-compulsive disorder in the national comorbidity survey replication. *Mol Psychiatry* 15(1):53–63
- Santesso DL, Segalowitz SJ, Schmidt LA (2006) Error-related electrocortical responses are enhanced in children with obsessive-compulsive behaviors. *Dev Neuropsychol* 29(3):431–445
- Saxena S, Brody AL, Schwartz JM, Baxter LR (1998) Neuroimaging and frontal-subcortical circuitry in obsessive-compulsive disorder. *Br J Psychiatry Suppl*(35):26–37
- Schwartz JM (1998). Neuroanatomical aspects of cognitive-behavioural therapy response in obsessive-compulsive disorder. An evolving perspective on brain and behaviour. *Br J Psychiatry Suppl*(35):38–44
- Schwartz JM, Stoessel PW, Baxter LR Jr, Martin KM, Phelps ME (1996) Systematic changes in cerebral glucose metabolic rate after successful behavior modification treatment of obsessive-compulsive disorder. *Arch Gen Psychiatry* 53(2):109–113
- Shin MS, Park SJ, Kim MS, Lee YH, Ha TH, Kwon JS (2004) Deficits of organizational strategy and visual memory in obsessive-compulsive disorder. *Neuropsychology* 18(4):665–672
- Shin MS, Choi H, Kim H, Hwang JW, Kim BN, Cho SC (2008) A study of neuropsychological deficit in children with obsessive-compulsive disorder. *Eur Psychiatry* 23(7):512–520
- Somerville LH, Casey BJ (2010) Developmental neurobiology of cognitive control and motivational systems. *Curr Opin Neurobiol* 20(2):236–241
- Sowell ER, Thompson PM, Holmes CJ, Jernigan TL, Toga AW (1999) In vivo evidence for post-adolescent brain maturation in frontal and striatal regions. *Nat Neurosci* 2(10):859–861
- Sowell ER, Thompson PM, Tessner KD, Toga AW (2001) Mapping continued brain growth and gray matter density reduction in dorsal frontal cortex: inverse relationships during postadolescent brain maturation. *J Neurosci* 21(22):8819–8829
- Sowell ER, Peterson BS, Thompson PM, Welcome SE, Henkenius AL, Toga AW (2003) Mapping cortical change across the human life span. *Nat Neurosci* 6(3):309–315
- Sowell ER, Thompson PM, Leonard CM, Welcome SE, Kan E, Toga AW (2004a) Longitudinal mapping of cortical thickness and brain growth in normal children. *J Neurosci* 24(38):8223–8231
- Sowell ER, Thompson PM, Toga AW (2004b) Mapping changes in the human cortex throughout the span of life. *Neuroscientist* 10(4):372–392
- Stewart SE, Geller DA, Jenike M, Pauls D, Shaw D, Mullin B, Faraone SV (2004) Long-term outcome of pediatric obsessive-compulsive disorder: a meta-analysis and qualitative review of the literature. *Acta Psychiatr Scand* 110(1):4–13
- Szeszko PR, MacMillan S, McMeniman M, Lorch E, Madden R, Ivey J (2004) Amygdala volume reductions in pediatric patients with obsessive-compulsive disorder treated with paroxetine: preliminary findings. *Neuropsychopharmacology* 29(4):826–832
- Szeszko PR, Christian C, Macmaster F, Lencz T, Mirza Y, Taormina SP, Easter P, Rose M, Michalopolou GA, Rosenberg DR (2008)

- Gray matter structural alterations in psychotropic drug-naïve pediatric obsessive-compulsive disorder: an optimized voxel-based morphometry study. *Am J Psychiatry* 165(10):1299–1307
- Thompson PM, Giedd JN, Woods RP, MacDonald D, Evans AC, Toga AW (2000) Growth patterns in the developing brain detected by using continuum mechanical tensor maps. *Nature* 404(6774):190–193
- Turkeltaub PE, Eden GF, Jones KM, Zeffiro TA (2002) Meta-analysis of the functional neuroanatomy of single-word reading: method and validation. *NeuroImage* 16(1):765–780
- Ursu S, Carter CS (2009) An initial investigation of the orbitofrontal cortex hyperactivity in obsessive-compulsive disorder: exaggerated representations of anticipated aversive events? *Neuropsychologia* 47(10):2145–2148
- Ursu S, Stenger VA, Shear MK, Jones MR, Carter CS (2003) Overactive action monitoring in obsessive-compulsive disorder: evidence from functional magnetic resonance imaging. *Psychol Sci* 14(4):347–353
- van den Heuvel OA, Veltman DJ, Groenewegen HJ, Cath DC, van Balkom AJ, van Hartkamp J, Barkhof F, van Dyck R (2005) Frontal-striatal dysfunction during planning in obsessive-compulsive disorder. *Arch Gen Psychiatry* 62(3):301–309
- van den Heuvel OA, der Werf YD, Verhoef KM, de Wit S, Berendse HW, Wolters E, Veltman DJ, Groenewegen HJ (2010) Frontal-striatal abnormalities underlying behaviours in the compulsive-impulsive spectrum. *J Neurol Sci* 289(1–2):55–59
- van der Wee NJ, Ramsey NF, Jansma JM, Denys DA, van Megen HJ, Westenberg HM, Kahn RS (2003) Spatial working memory deficits in obsessive compulsive disorder are associated with excessive engagement of the medial frontal cortex. *Neuroimage* 20(4):2271–2280
- van der Wee NJ, Ramsey NF, van Megen HJ, Denys D, Westenberg HG, Kahn RS (2007) Spatial working memory in obsessive-compulsive disorder improves with clinical response: a functional MRI study. *Eur Neuropsychopharmacol* 17(1):16–23
- van Veen V, Carter CS (2002) The anterior cingulate as a conflict monitor: Fmri and Erp studies. *Physiol Behav* 77(4–5):477–482
- Walitza S, Wendland JR, Gruenblatt E, Warnke A, Sontag TA, Tucha O, Lange KW (2010) Genetics of early-onset obsessive-compulsive disorder. *Eur Child Adolesc Psychiatry* 19(3):227–235
- Whiteside SP, Port JD, Abramowitz JS (2004) A meta-analysis of functional neuroimaging in obsessive-compulsive disorder. *Psychiatry Res* 132(1):69–79
- Wittchen HU, Jacobi F (2005) Size and burden of mental disorders in Europe—a critical review and appraisal of 27 studies. *Eur Neuropsychopharmacol* 15(4):357–376
- Woolley J, Heyman I, Brammer M, Frampton I, McGuire PK, Rubia K (2008) Brain activation in paediatric obsessive compulsive disorder during tasks of inhibitory control. *Br J Psychiatry* 192(1):25–31
- Zellmann H, Jans T, Irblich B, Hemminger U, Reinecker H, Sauer C, Lange KW, Tucha O, Wewetzer C, Warnke A, Walitza S (2009) Kinder Und Jugendliche Mit Zwangsstörungen - Eine Prospektive Verlaufsstudie/Prospective Follow-up Study in Early Onset Obsessive-Compulsive Disorder. *Zeitschrift für Kinder- und Jugendpsychiatrie und Psychotherapie* 37(3):173–182