

# Neuropathy Associated with Systemic Amyloidosis

Michelle Kaku, MD<sup>1,2</sup> John L. Berk, MD<sup>2,3</sup>

<sup>1</sup>Department of Neurology, Boston Medical Center, Boston, Massachusetts

<sup>2</sup>Amyloidosis Center, Boston Medical Center, Boston University, Boston, Massachusetts

<sup>3</sup>Department of Pulmonology, Boston Medical Center, Boston, Massachusetts

Address for correspondence Michelle Kaku, MD, Division of Neuromuscular Medicine, Department of Neurology, Boston Medical Center, 72 East Concord Street, Neurology C-3, Boston, MA 02118 (e-mail: mikaku@bu.edu).

Semin Neurol 2019;39:578–588.

## Abstract

Peripheral neuropathy occurs in the setting of both hereditary and acquired amyloidosis. The most common form of hereditary amyloidosis is caused by 1 of 140 mutations in the transthyretin (TTR) gene, which can lead to neuropathic hereditary transthyretin amyloidosis (hATTR; previously referred to as transthyretin familial amyloid polyneuropathy), whereas acquired immunoglobulin light chain (AL) amyloidosis is the most common acquired form. Patients typically present with a sensorimotor polyneuropathy, focal neuropathy such as carpal tunnel syndrome, or autonomic neuropathy. When neuropathy is the sole or dominant presenting symptom, the diagnosis is commonly delayed. With the advent of new drug therapies for AL amyloidosis and hATTR amyloidosis, including proteasome inhibitors, TTR silencers, and TTR protein stabilizers, the neurologist is uniquely positioned to diagnose neurologic manifestations of systemic amyloidosis, leading to earlier disease identification and treatment. This article reviews the epidemiology, clinical presentations, pathophysiology, diagnostic workup, and treatment of neuropathy in the setting of amyloidosis.

## Keywords

- ▶ hereditary neuropathy
- ▶ transthyretin
- ▶ AL amyloidosis
- ▶ primary amyloidosis

Neuropathy is a major feature of the amyloidoses, a group of disorders resulting from extracellular deposition of insoluble aggregates of amyloid fibrils in various tissues. The different types of amyloid are classified by the precursor plasma protein that composes the amyloid fibrils. Acquired forms arise from misfolded monoclonal  $\kappa$  or  $\lambda$  light chains in primary systemic amyloid (AL), serum amyloid A protein in secondary amyloidosis (AA), and  $\beta$ 2-microglobulin ( $\beta$ 2M) in dialysis-associated amyloidosis. Hereditary forms include transthyretin (TTR), apolipoprotein A1, gelsolin, lysozyme, fibrinogen, amyloid- $\beta$ , and cystatin C. Among the hereditary subtypes, TTR is the most common variant worldwide. In cases without family histories, genetic testing documenting TTR point mutations has permitted reclassification of apparent sporadic or monoclonal gammopathy of unknown significance (MGUS)-related cases of amyloid neuropathy as hereditary amyloidosis.<sup>1</sup> Although classic presentations of length-dependent sensory loss are most common, atypical presentations of neuropathy including predominant upper limb neuropathy, pure small fiber neuropathy, and carpal tunnel syndrome (CTS) often lead to delayed diagnosis.

## Hereditary Forms of Amyloid Neuropathy

### Transthyretin Amyloidosis

Transthyretin is a plasma transport protein for retinol-binding protein and thyroid hormone.<sup>2</sup> It circulates in the tetrameric confirmation of four TTR proteins, each consisting of 127 amino acid residues. The TTR gene is located on chromosome 18q11.2–12.1.<sup>3</sup> The protein is predominantly produced in the liver, with small amounts synthesized in the retinal pigment epithelium of the eye and the choroid plexus.<sup>4,5</sup> Point mutations destabilize the tetrameric TTR, inducing protein misfolding and aggregation into insoluble amyloid fibrils that deposit in major organs leading to transthyretin amyloid disease (ATTR).

### Genetics and Epidemiology

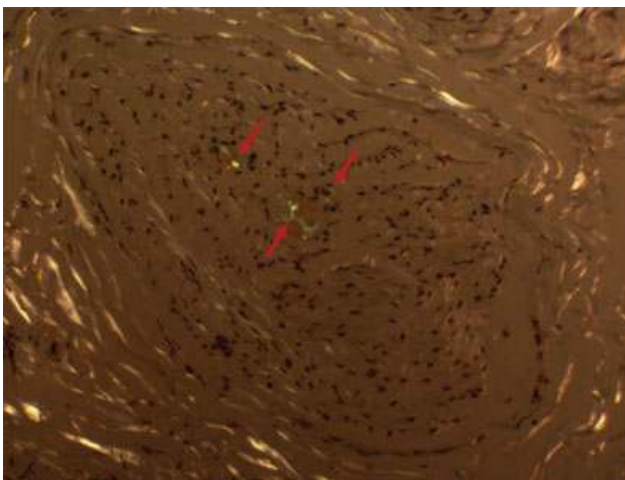
Neuropathic hereditary transthyretin amyloidosis (hATTR) was first described in Portugal in 1952,<sup>6</sup> with large groups of patients later identified in Japan, Sweden, and South America.<sup>7,8</sup> To date, 140 different TTR mutations have been identified (<http://amyloidosismutations.com>). The estimated global

prevalence of neuropathic hATTR is 10,186 persons (range, 5,526–38,468),<sup>9,10</sup> most of which are missense point mutations inherited in an autosomal dominant manner. Worldwide, the most common mutation is a substitution of Methionine for Valine at position 30, the ATTRVal30Met mutation, which causes the classic phenotype of neuropathic hATTR. However, the most common mutation in the United States is the ATTRVal122Ile mutation,<sup>11</sup> and more than 3% of African Americans with amyloidosis carry this mutation,<sup>12</sup> which is principally associated with late-onset cardiomyopathy. Although cardiac manifestations prevail, rates of neuropathy have been reported in up to 10 to 38% of these patients.<sup>11,13</sup> Penetrance, or the proportion of gene carriers who manifest clinical disease, is variable by mutation type. The penetrance of ATTRVal30Met carriers by the age of 80 is 91% in Portuguese, 86% in French, and by the age of 90, it is 69% in Swedes.<sup>14,15</sup> Genetic anticipation has been demonstrated in Portuguese hATTR families, particularly when the trait is maternally inherited.<sup>16</sup>

### Pathophysiology

Amyloid is identified as eosinophilic extracellular deposits with apple green birefringence on Congo red staining or by electron microscopy (► Fig. 1). In autopsy studies, amyloid deposits are found in peripheral nerves, autonomic nervous system, choroid plexus, cardiovascular system, kidneys, as well as spinal cord roots, and spinal ganglia.<sup>17</sup> Loss of myelinated nerve fibers within the vagus nerve and celiac ganglia is seen on pathologic studies.<sup>18</sup> Amyloid fibril deposition occurs in a patchy fashion and leads to direct blood vessel damage, mechanical compression, and potentially toxic effects. On nerve biopsy, histologic findings include axonal degeneration in small myelinated and unmyelinated fibers with Wallerian degeneration. Amyloid nodules can indent and compress myelinated fibers and can be found in the epineurium, perineurium, and endoneurium on light microscopy.<sup>19–21</sup>

An electron microscopic study of 49 sural nerve biopsies from patients with ATTRVal30Met demonstrated that amy-



**Fig. 1** Congo red stain showing a nerve fascicle containing apple green birefringence of Congo red materials (arrows) deposited on the endoneurial blood vessel walls. (Courtesy of Lan Zhou, MD, PhD.)

loid fibrils cause direct Schwann cell damage, with loss of small fiber axons in early-onset cases. Disruption of blood–nerve barriers including loss of tight junctions and fenestration of endothelial cells was also found, regardless of amyloid deposition.<sup>22</sup> Breakdown of the blood–nerve barrier at the dorsal root ganglia and sympathetic ganglia make these areas vulnerable and enable exposure to amyloid proteins.<sup>23</sup>

### Clinical Features

The clinical features of the ATTRVal30Met mutation differ depending on whether the mutation is endemic (localized to a certain area with a traceable family history) or nonendemic. Even in this mutation, there is clinical heterogeneity within and between ethnic groups and there is a spectrum of clinical presentations.

Individuals with the ATTRVal30Met mutation living in endemic regions in Japan, northern Portugal, Sweden, Cyprus, and Majorca exhibit the classic presentation,<sup>24</sup> with earlier onset of neuropathy in the third or fourth decade of life, and prominent small myelinated and unmyelinated fiber involvement. Patients can present with distal sensory loss that is described as dissociated, with selective involvement of pain and thermal abnormalities early in the course. Later, larger myelinated sensory and motor fibers are affected which can impair light touch, vibration, joint position sensation, and eventually distal motor weakness that progresses proximally.<sup>20,25</sup>

Given the extent of small fiber involvement, patients can have severe autonomic dysfunction involving the cardiovascular, gastrointestinal, and genitourinary systems. Pure small fiber neuropathy and pure autonomic dysfunction are less common manifestations. Patients may complain of dry eyes and mouth. Orthostatic hypotension may lead to lightheadedness while standing, and even syncope. Gastrointestinal symptoms may present with alternating postprandial diarrhea and severe constipation. This is primarily the result of loss in inhibitory and increase in excitatory enteric neurons which affect peristalsis, and rarely due to overwhelming amyloid deposition in the muscularis mucosae.<sup>26</sup> Erectile dysfunction often occurs early in men, and impaired bladder innervation leads to increased urinary retention, incomplete bladder emptying, and neurogenic bladder dysfunction. Light-near dissociation of pupillary reaction can also occur, as well as irregular pupillary margins with fringed edges known as scalloped pupils, a unique sign in patients with hATTR.<sup>6,27</sup>

Besides the peripheral nerves, amyloid deposits in the kidneys, heart, gastrointestinal tract, eyes, leptomeninges, and vessels can also present with a host of organ manifestations. Endoneurial amyloid deposition in the transverse ligament can cause median nerve entrapment and can manifest as clinical CTS.<sup>21</sup> Cardiac conduction defects and cardiomyopathy can cause life-threatening arrhythmias and death. Renal insufficiency, proteinuria, and vitreous amyloid deposition may also occur. With advanced neuropathy and organ involvement, weight loss and cachexia develop; mean survival is less than 10 years from diagnosis due to cardiac failure, malnutrition, or infection.<sup>1,28,29</sup>

Individuals with ATTRVal30Met from nonendemic areas typically have a later onset of disease (older than 50 years), male predominance, and obscure family history.<sup>30–32</sup> Unlike the classic phenotype, the clinical picture progresses less rapidly, and patients have relatively mild autonomic dysfunction early in the disease. Patients can present with CTS and generalized sensorimotor polyneuropathy involving both large and small fibers at onset, rather than with dissociated sensory loss.<sup>33</sup>

### Other Neurologic Presentations

Atypical presentations of neuropathy in hATTR can also occur, delaying diagnosis. Patients may present with upper limb onset of neuropathy with predominant sensory symptoms, with lower limb symptoms developing up to 2 years later.<sup>34</sup> Pure motor weakness without sensory or autonomic involvement has been observed in the Ala25Thr mutation. The Glu54Lys TTR variant can cause a rapid progression of polyneuropathy, autonomic dysfunction, and cardiomyopathy.<sup>35</sup> Ataxic phenotype of Tyr77Ser in France and Germany has been reported, presenting with a rapid course of an ataxic, broad-based gait, sensory loss affecting mostly vibration, and joint position sense, with little muscular weakness and diffuse areflexia.<sup>36,37</sup>

Patients may present with only autonomic dysfunction<sup>38</sup> or CTS.<sup>21</sup> Certain mutations such as Leu58Arg,<sup>39</sup> Try114His,<sup>40</sup> and Ile84Ser<sup>41</sup> can present with CTS as the only neurologic manifestation in addition to other systemic manifestations. In a retrospective study of 76 patients with neuropathic hATTR, CTS was an initial presenting symptom in 33%, with no other symptoms for a mean period of 4.6 to 5.6 years.<sup>42</sup> In another prospective study of males age  $\geq$  50 years and females age  $\geq$  60 years undergoing surgery for “idiopathic” CTS, 10 of 96 (10.4%) demonstrated positive Congo red staining on tenosynovial biopsy, including 2 with AL and 7 with TTR subtype, previously undiagnosed. Upon subsequent cardiac workup, two patients were found to have early cardiac involvement.<sup>43</sup> As CTS may be an early manifestation of amyloidosis, sampling and Congo red staining of the flexor retinaculum should be considered in patients presenting with idiopathic CTS, particularly if bilateral. In addition to neuropathy, hATTR has been shown to be associated with other neurological and musculoskeletal complications, including tendon rupture and spinal stenosis from deposition in the ligamentum flavum.<sup>44</sup> Amyloid myopathy is relatively rare but has been reported in several TTR mutations.<sup>45–47</sup>

### Central Nervous System Involvement

TTR mutations with primarily central involvement due to production of TTR by the choroid plexus and/or retinal epithelium can lead to oculoleptomeningeal amyloidosis.<sup>5,48</sup> Multiple mutations have been reported, including Val30Gly, Asp18Gly, Leu12Pro, AL25Thr, Phe64Ser, Val127Met, Ala36Pro, Tyr69His, Gly53Glu, Tyr114Cys variants, as well as Val30Met,<sup>49–55</sup> with a varied clinical spectrum that includes vitreous opacities, dementia, seizures, visual disturbances, ataxia, subarachnoid hemorrhage, hydrocephalus, and spasticity. Neuropathy may or may not be a concurrent feature.

Magnetic resonance imaging of the brain with and without contrast is the imaging modality of choice in these patients, demonstrating leptomeningeal enhancement or focal hemorrhage. Elevated CSF protein can also be seen. A ventriculoperitoneal shunt is often placed if hydrocephalus is noted, although given the continued production of amyloid protein, shunt failure may occur.<sup>53</sup>

Interestingly, patients older than 50 years with ATTRVal30Met amyloidosis demonstrated cognitive dysfunction in a recent study in which neuropsychological testing was performed on untreated patients with ATTRVal30Met.<sup>56</sup>

### Diagnosis/Workup

In patients with a family history of neuropathy, hATTR should be considered in presentations of sensorimotor polyneuropathy with or without autonomic dysfunction. Genetic testing has replaced the need for nerve biopsy in these patients. However, being a mutation carrier does not necessarily confer clinical disease, due to variable penetrance. In sporadic presentations, the diagnosis is often delayed or a misdiagnosis is made, and is initially suspected in only 38% of patients with neuropathy without a family history.<sup>36</sup> ATTR should be considered in patients without a family history with an idiopathic progressive axonal polyneuropathy, particularly when there is associated CTS, autonomic dysfunction, or other systemic involvement such as cardiac dysfunction. In a study of 90 patients who presented as nonhereditary cases in a nonendemic area, mean interval to diagnosis was 4 years with a range of 1 to 10 years, and 18 cases were mistaken for chronic inflammatory demyelinating polyneuropathy (CIDP).<sup>57</sup> Although genetic testing is often not done in the initial battery of testing, given the availability of new treatments for hATTR amyloidosis, we suggest considering genetic testing early in the diagnostic workup.

Various diagnostic scales have been used to measure disease progression in hATTR. The Neuropathy Impairment Score-Lower Limbs (NIS-LL) and Norfolk Quality of Life-Diabetic Neuropathy (Norfolk QOL-DN) have been shown to be reliable measures of hATTR severity.<sup>58</sup> Nerve conduction studies (NCS) and electromyography (EMG), which can evaluate large nerve fibers, demonstrate a predominantly axonal neuropathy with demyelinating features. Sensory nerve action potentials are often affected first, and more severely than compound muscle action potentials (CMAPs) with reduced amplitude or absent potentials. Later, CMAPs become decreased or absent. Needle EMG often demonstrates large neurogenic appearing motor units and fibrillation potentials in a distal symmetric pattern.<sup>19,20,59–62</sup> Compared with other types of neuropathy such as diabetic polyneuropathy, a recent study showed that low ulnar sensory nerve conduction velocity, impaired cold sensation, and mechanical hyperalgesia at the hands may be more common in hATTR,<sup>63</sup> and skin temperature may be lower in hATTR patients compared with those with diabetic neuropathy.<sup>64</sup>

While axonal features are prominent, evidence of demyelination may lead to delayed or misdiagnosis with CIDP. In a study of 194 patients with hATTR, 13 of 84 patients of French ancestry had late-onset demyelinating hATTR. Predictors of

demyelinating hATTR were pain, dysautonomia, small fiber sensory loss above the wrists, upper limb weakness, and absence of ataxia. The most frequent demyelinating features were prolonged distal motor latency of the median nerve and reduced sensory conduction velocity of the median and ulnar nerves. Nerve biopsy showed severe axonal loss and occasional segmental demyelination–remyelination.<sup>65</sup>

In patients with normal NCS/EMG, autonomic function testing (AFT) and quantitative sudomotor axon reflex testing can identify small fiber involvement. Skin biopsy may reveal reduced intraepidermal nerve fiber densities (IENFD) and amyloid deposition.<sup>66</sup> IENFD has been found to be reduced in asymptomatic non-Val30Met mutation carriers.<sup>67</sup> A battery of small fiber testing including laser evoked potentials, sympathetic skin responses, measurement of cold and warm detection thresholds, and heart-rate variability may identify early neuropathy in asymptomatic hATTR carriers or those with subjective sensory complaints or inconsistent sensory deficits on clinical exam.<sup>68</sup> In a recent study, cutaneous amyloid was found in 70% of hATTR and 20% of hATTR without clinical neuropathy. Amyloid burden was associated with reductions in IENFD, sweat gland, pilomotor nerve fiber densities and NIS-LL.<sup>69</sup>

In cases in which the diagnosis remains unclear after noninvasive testing, nerve biopsy may be considered, which can demonstrate amyloid deposits in the endoneurial and epineurial connective tissue, and deposits in endoneurial and epineurial blood vessel walls. Given the patchy, nonuniform deposition, with distal fiber degeneration due to proximal amyloid deposits, a negative sural nerve biopsy for amyloid does not exclude the diagnosis.<sup>70,71</sup> Nerve biopsy sensitivities range from 60 to 86% and vary among centers.<sup>57,72,73</sup> Amyloid can also be found in the flexor retinaculum during carpal tunnel release. In a study of 16 patients with ATTRVal30Met and neurophysiologic CTS who had a carpal tunnel release, amyloid was found in the transverse carpal ligament in 14 patients (87.5%). In all but one case, the CTS preceded the polyneuropathy.<sup>74</sup> If nerve or skin biopsy is negative, tissue may also be obtained by abdominal fat pad, salivary glands, gums, rectal submucosa, heart, or kidney—provided organ dysfunction is demonstrated signaling amyloid involvement.<sup>21</sup>

Magnetic resonance neurography can detect lesions of the sural nerve in asymptomatic carriers. In one study, T2 and proton spin density reliably differentiated between hATTR, mutated TTR carriers, and healthy controls. T2 relaxation time was higher in patients with hATTR only. This marks potentially a noninvasive method to detect early neuropathy involvement in asymptomatic carriers.<sup>75</sup>

## Treatment

Treatment options for hATTR have blossomed in the last decade. The goal of treatment includes disease-modifying therapy to prevent misfolding of mutant TTR (TTR stabilizers); TTR silencers; symptomatic treatment for autonomic dysfunction, CTS, and neuropathic pain; genetic counseling; and psychological support for the patient and their families. A multidisciplinary approach including assessments from cardiology, ophthalmology, nephrology, gastroenterology, and

possibly rehabilitation is suggested. Regular monitoring of these patients enables tracking of their disease progression and targeted therapy to prevent further amyloid deposition.

## Symptomatic Therapy

Symptomatic therapy should be initiated early in the diagnosis to help alleviate discomfort from neuropathic pain, treat CTS, and help the manifestations of autonomic dysfunction. Data for neuropathic agents are based on studies of diabetic and other forms of neuropathy. Anticonvulsants such as gabapentin and pregabalin, and serotonin norepinephrine reuptake inhibitors such as duloxetine and venlafaxine, are commonly used. Tricyclic antidepressants including nortriptyline and amitriptyline are often avoided in these patients as they can worsen concurrent autonomic symptoms such as orthostatic hypotension and urinary retention. Topical agents such as lidocaine patches and high-dose capsaicin can also be considered. CTS can be treated with decompression surgery. Among autonomic symptoms, orthostatic hypotension can be addressed symptomatically by wearing compression stockings. Fist-line medication management typically starts with midodrine. Fludrocortisone can also be used but caution should be taken as it can cause supine hypertension. Pyridostigmine and droxidopa are newer agents that can be considered.<sup>76</sup> Alternating constipation and diarrhea can be helped by adding fiber to the diet to increase stool bulk, or treating with loperamide to reduce bowel peristalsis.<sup>77</sup>

## Liver Transplantation

Liver transplantation has historically been the standard of care in the treatment of hATTR. As the liver is the main producer of amyloid, the goal of liver transplantation has been to remove the source of ATTR. The first liver transplant was in 1990 in Sweden.<sup>78</sup> Early liver transplantation in ATTRVal30Met patients has been shown to have better rates of survival at 10 years than patients who did not receive transplants.<sup>79</sup> According to the world registry of liver transplants for non-Val30Met cases, some variants have had excellent survival rates including Leu111Met, Val71Ala, and Leu58His, while others including Ser50Arg, Ser77Phe, or Ser77Tyr mutation did not.<sup>80</sup>

Wild-type TTR amyloid often deposits in the liver after transplantation.<sup>81</sup> Cerebral amyloid angiopathy was found to occur in 11% of ATTR patients after liver transplantation, on average of 16.8 years after onset of disease.<sup>82</sup> Limitations of liver transplantation include the limited availability of organs, life-long immunosuppression, and high cost of transplantation. Domino liver transplants consist of liver transplant from the hATTR patient to a non-hATTR patient with liver disease and short life expectancy. Amyloid neuropathy may develop in these patients.

## Transthyretin Stabilizers

### Diflunisal

Diflunisal is a nonsteroidal anti-inflammatory agent (NSAID). It binds to T4 binding sites of tetrameric TTR, which stabilizes TTR and decreases fibril formation.<sup>83</sup> In an international,



double-blind 24-month study on 130 hATTR patients with clinical peripheral or autonomic neuropathy, patients were randomized to receive either 250 mg diflunisal twice daily or placebo. The primary end point was the difference in polyneuropathy progression between treatments, measured by the NIS plus 7 nerve test (NIS + 7) which ranges from 0 (no neurological deficits) to 270 (no detectable peripheral nerve function). In the study, the progression of polyneuropathy was significantly less in patients receiving diflunisal–NIS + 7 of 8.7 points (95% confidence interval [CI], 3.3–14.1) in the diflunisal group compared with NIS + 7 of 25.0 points (95% CI, 18.4–31.6) in the placebo group, a difference of 16.3 points (95% CI, 8.1–24.5 points;  $p < 0.001$ ). Additionally, quality-of-life scores demonstrated significant improvement in the treatment group; 29.7% of the diflunisal group and 9.4% of the placebo group exhibited neurological stability at 2 years (<2-point increase in NIS + 7 score;  $p = 0.007$ ).<sup>84</sup>

A study in Japan of 40 patients with hATTR reported a sustained effect of diflunisal 500 mg/day on cardiac and neurological function in 14 patients treated up to 48 months. Diflunisal was found to significantly increase serum TTR concentration at 12 months of treatment and stabilized TTR tetramer structure in each patient. Interestingly, ulnar CMAP amplitude, cardiac wall thickness, and ejection fraction did not show deterioration after 24 months of treatment. However, diflunisal-related adverse events including acute renal injury and thrombocytopenia resulted in discontinuation of the drug in three patients.<sup>85</sup>

A retrospective analysis of off-label use of diflunisal in hATTR patients reported discontinuation of treatment in 57% of patients, largely due to gastrointestinal side effects.<sup>86</sup> Contraindications to using NSAIDs in patients with severe congestive heart failure (New York Heart Association class IV) or renal insufficiency (estimated creatinine clearance <30 mL/min) may limit use of diflunisal in certain hATTR patients.

### Tafamidis

Tafamidis is a thyroxine-like small ligand inhibitor that stabilizes mutant TTR tetramers inhibiting dissociation into monomers, mimicking the biology of diflunisal. A randomized, double-blind study of 120 hATTR patients with ATTRVal30Met sensory peripheral neuropathy examined the effects of tafamidis 20 mg once daily or placebo on disease progression for 18 months. Despite secondary outcome measures demonstrating less neurologic deterioration, less decline in quality-of-life metrics, and improved nutritional measures among treated subjects, the study failed to meet its coprimary end points (total quality of life [TQOL] score [ $p = 0.116$ ] and prevention of neurologic progression in the lower leg [ $p = 0.068$ ]) by intention to treat analysis. On the basis of this failed analysis, the FDA did not approve the drug for marketing. Nonetheless, the European Medicines Agency granted conditional approval of tafamidis for sale as treatment for FAP stage I in 2011; the drug is currently marketed in Europe, Japan, and South America for stage I sensorimotor peripheral neuropathy in patients with hATTR amyloidosis.<sup>87</sup>

Subsequently, two open-label tafamidis extension studies, one of 12 months<sup>88</sup> and another of up to 5.5 years<sup>89</sup>

demonstrated reduced rates of neurological deterioration over 30 months and delayed neurologic progression when instituted early in the disease. Among early-onset patients, a retrospective population-based survival analysis of more than 3,200 Portuguese patients with ATTRVal30Met amyloidosis revealed a 75% reduction in mortality risk for orthotopic liver transplant recipients and a 91% reduction in the tafamidis-treated cohort.<sup>90</sup> Overall, TTR tetramer stabilizers primarily slow down neurologic disease progression while less often arresting nerve injury in patients with hATTR amyloid polyneuropathy.

### Transthyretin Gene Silencers

Anti-sense oligonucleotides (ASOs) and small interfering RNAs (siRNAs) are gene silencing therapies being developed to inhibit hepatic production of mutant and nonmutant TTR.

#### Inotersen

ASOs are strings of nucleotides that prevent targeted protein expression by binding to the messenger RNA that encodes the protein and prevents translation. The ASO inotersen was tested in the NEURO-TTR study, a phase 3 study of 172 adults with hATTR with polyneuropathy. Patients were randomized to receive weekly subcutaneous injections of inotersen (300 mg) or placebo (112 patients in the inotersen group and 60 patients in the placebo group). In the trial, both primary endpoints were met, with significant benefit inhibiting, slowing, or even improving sensorimotor polyneuropathy as measured by comprehensive and quantitative metric, NIS + 7 ( $p < 0.0001$ ), and quality of life by the Norfolk QOL-DN ( $p = 0.0006$ ). Results were independent of hATTR mutation type, disease stage, and cardiomyopathy status at baseline. The main safety concerns included thrombocytopenia and glomerulonephritis.<sup>91</sup> Patients were found to have significant impairment in quality of life compared with the general population.<sup>92</sup> An open-label study of these patients is currently ongoing (NCT02175004).

#### Patisiran

siRNAs are double-stranded RNAs that target a sequence of mRNA conserved across wild-type and all TTR variants, inhibiting TTR synthesis in the liver. Patisiran, a siRNA, was evaluated in a double-blind phase 3 study. Two hundred and twenty-five patients with hATTR amyloidosis with polyneuropathy were randomized to receive intravenous patisiran (0.3 mg/kg) or placebo once every 3 weeks (148 to the patisiran group and 77 to the placebo group). The primary end point was the change from baseline in mNIS + 7 at 18 months. Norfolk QOL-DN, 10-minute walk test, and modified BMI (mBMI) were also assessed. Patisiran significantly slowed, stopped, or in 56% of treated subjects improved neurologic function by mNIS + 7 measures over 18 months of treatment. Additionally, patisiran better preserved gait speed and mBMI compared with the placebo group. The safety profile was similar to placebo.<sup>93</sup> Patisiran recently became the first FDA-approved siRNA therapy, with a formal indication of neurologic manifestations of hATTR disease.

### Apolipoprotein A1

Hereditary amyloidosis associated with mutation of apolipoprotein A1 is relatively rare. Originally described in a family from Iowa in 1969,<sup>94</sup> it is associated with renal, hepatic, and gastrointestinal involvement that presents in the fourth decade.<sup>95</sup> Of the 16 mutations of the *APOA1* gene identified, the Gly26Arg mutation can cause a length-dependent polyneuropathy, although it also has nonneuropathic forms.<sup>95,96</sup> The Leu178His variant is characterized by neuropathy, cardiac amyloidosis, skin lesions, and deposition of amyloid in the vocal cords causing dysphonia.<sup>97</sup> Biochemical analysis of the amyloid fibrils in these families demonstrates a variant fragment of apolipoprotein A1, the major protein of high-density lipoprotein. No specific therapies exist for hereditary amyloidosis associated with apoprotein A1. Experience with liver transplantation has been variable<sup>98</sup> and has not had as much success as in patients with hATTR.<sup>96</sup>

### Gelsolin-Related Neuropathy

Hereditary neuropathy associated with mutation of gelsolin, also referred to as the Finnish type, is also rare, although it demonstrates a worldwide distribution. It typically presents in the third decade of life and is characterized by corneal lattice dystrophy, progressive cranial neuropathies, cutis laxa, and other systemic involvement.<sup>99</sup> The cranial neuropathies that develop typically present with facial nerve palsy involving upper and later lower nerve branches as well as trigeminal neuropathies. Lower cranial nerves are involved later, which can result in bulbar palsies. On EMG, facial myokymia can also be observed. A sensorimotor neuropathy develops later in the disease course.<sup>100–103</sup> Renal and cardiac involvement along with posterior column involvement in the spine and cerebral amyloid angiopathy have also been reported.<sup>104</sup> Autonomic dysfunction is not typically part of the clinical presentation, but when it does occur, it is mild.<sup>105</sup>

Unlike other types of hereditary amyloidosis, nerve root involvement is more prominent compared with more distal nerves. Amyloid deposition can be found in most tissues, although there is a predilection toward blood vessel walls, perineurium, and basement membranes on autopsy studies, whereas TTR is found in the endoneurium, epineurium, and perineurium.<sup>100,105,106</sup> Survival in patients with the gelsolin mutation is similar to survival in unaffected family members.<sup>100</sup> Treatment options are few and include symptomatic therapies, including plastic surgery for cutis laxa and blepharochalasis, and corneal transplantation.

## Acquired Forms of Amyloid Neuropathy

### AL Amyloidosis

AL amyloidosis is the most common form of systemic amyloidosis in the United States, with an estimated prevalence of 2.5 per 100,000 and 1,274 to 3,200 new cases diagnosed annually.<sup>107</sup> It is a multisystem disease in which amyloid fibrils composed of monoclonal immunoglobulin light chains produced by an underlying clonal plasma cell dyscrasia deposit in vital organs including the heart, kidney, peripheral and autonomic nerves, gastrointestinal tract, joints, skin, and

blood vessels of organs. Patients are middle aged to elderly, with a male predominance. Presenting symptoms include congestive heart failure, nephrotic syndrome, peripheral edema, dyspnea, hepatomegaly, renal failure, orthostatic hypotension, marked weight loss, fatigue, cardiac arrhythmia, macroglossia, intermittent claudication, diarrhea, abdominal pain, back pain, purpura, CTS, and neuropathy.<sup>19,108</sup>

Peripheral neuropathy occurs in up to 17 to 35% of patients with AL amyloidosis,<sup>108–110</sup> and is often an incidental physical exam finding at diagnosis.<sup>19,109</sup> Small fiber modalities are typically affected first, presenting with a distal, length-dependent symmetric sensory loss of pain and temperature sensation, although sensory loss is not dissociated in roughly half of cases as it is in hATTR.<sup>19</sup> As large fibers become affected, patients may have numbness and motor weakness. Weakness typically develops later compared with numbness and starts in the big toe extensors, and can progress more proximally to extensors and flexors of the feet causing foot drops. Over time, weakness can progress requiring orthopaedic appliance of wheelchair.<sup>19</sup>

When neuropathy is the presenting symptom, mean symptom duration to diagnosis is 29 to 48 months.<sup>62,109</sup> Sixty-five percent of patients with neuropathy also have symptoms of autonomic neuropathy, including orthostatic hypotension, urinary retention, fecal incontinence, or impotence.<sup>62</sup> CTS can occur in up to 21% of patients with AL amyloidosis.<sup>108</sup> Similar to hATTR, patients with AL amyloidosis can present with atypical presentations of neuropathy including cranial neuropathy and facial diplegia, multiple cranial neuropathies, CIDP, mononeuropathy, multiple mononeuropathies, mononeuritis multiplex, multiple cranial neuropathies, and lumbosacral radiculoplexopathy.<sup>60,61,111–117</sup> Amyloid myopathy is more common in AL amyloidosis than in hATTR amyloidosis, and can cause an isolated amyloid myopathy.<sup>118</sup>

### Labs/Diagnostic Workup

Demonstration of a plasma cell dyscrasia and amyloid in the tissue is required for the diagnosis of AL amyloidosis. Unlike multiple myeloma in which  $\kappa$  light chain is more common, the  $\lambda$  is more common than  $\kappa$  light chain by 50% in AL amyloidosis. Serum and urine protein immunofixation electrophoresis (IFE) is more sensitive than serum and urine protein electrophoresis, particularly in the diagnosis of small or nonmalignant monoclonal gammopathies.<sup>119</sup> The serum free-light chain assay has more than a 10-fold greater sensitivity compared with IFE and should be obtained in patients with possible amyloid neuropathy.<sup>120,121</sup>

Other laboratory abnormalities include anemia, renal failure, proteinuria, transaminitis with liver involvement, or elevated CK in patients with coexistent amyloid myopathy. Elevated CSF protein may also be seen in the setting of a normal cell count, which misleads some to the diagnosis of CIDP.<sup>19,60</sup>

### Treatment

Median survival of AL amyloidosis patients presenting with neuropathy is 25 to 35 months.<sup>122</sup> While survival may be longer than in patients without peripheral neuropathy,<sup>62,109</sup> interestingly, autonomic neuropathy may be an independent,

adverse determinant of survival in these patients.<sup>123</sup> The cause of death is typically from congestive heart failure or renal failure. While initially thought that neuropathy does not improve with treatment,<sup>62,124</sup> there is mounting evidence of improvement in peripheral neuropathy<sup>110,125</sup> and autonomic neuropathy<sup>126</sup> with regression of disease and normalization of serum-free light chains.

The mainstay of treatment options is chemotherapy and autologous peripheral blood stem cell transplantation in selected patients. Historically, chemotherapeutic agents have included melphalan and dexamethasone.<sup>126,127</sup> The most effective therapy is currently high-dose intravenous melphalan and autologous peripheral blood stem cell transplantation, which has been shown to induce hematologic remission, improve 5-year survival, and reverse amyloid-related disease.<sup>126</sup>

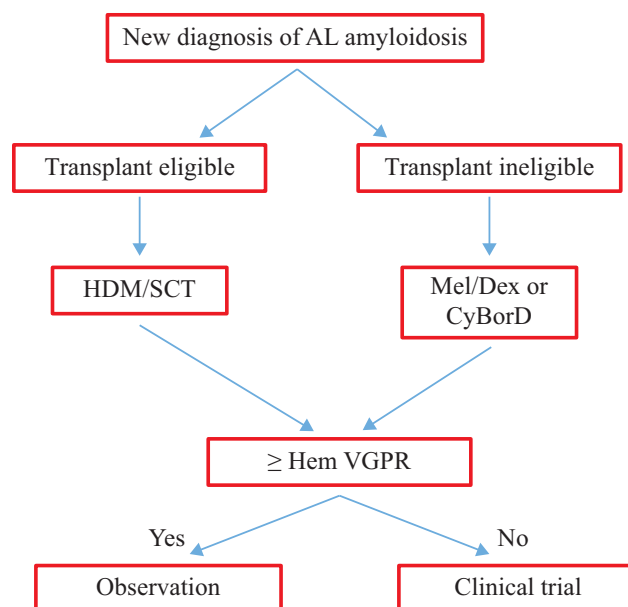
The class of immunomodulating agents include thalidomide, lenalidomide, and pomalidomide. Thalidomide has been limited by side effects including severe fatigue, bradycardia, edema, constipation, neuropathy, and exacerbation of cardiac and renal dysfunction.<sup>128,129</sup> In one study, lenalidomide, alone or in combination with dexamethasone, induced hematologic responses in 67% of patients with AL amyloidosis who had failed prior treatment. Compared with thalidomide, the side effect profile was less toxic and did not cause neuropathy or constipation but did cause rash, renal impairment, and cytopenias.<sup>130</sup>

Proteasome inhibitors such as bortezomib, particularly in combination therapy, have demonstrated promising results. Combination therapy with cyclophosphamide, bortezomib, and dexamethasone (CyBorD) was shown to have a response in 16 of 17 patients (94%), with 71% achieving complete hematologic response and 24% achieving a partial response.<sup>131</sup> In a larger study of 230 AL patients treated with CyBorD, hematologic response was 60% and improved survival was 67% at 2 years.<sup>132</sup> Pomalidomide with dexamethasone has been demonstrated to produce hematologic response in 50% of 24 evaluable patients. The median time to best hematologic response was three cycles, and median duration of hematologic response was 15 months.<sup>133</sup> Another study of 28 patients demonstrated a hematologic response in 68% of patients and improved survival. Median time to response was 1 month.<sup>134</sup> Phase I and II trials of daratumumab, a monoclonal antibody targeting CD38, have shown that the drug is tolerated well, with rapid hematologic response after one dose.<sup>135</sup>

Given the array of new treatment options, 50 international amyloid experts were recently surveyed about their treatment algorithm. Seventy-three percent considered autologous stem cell transplant as the first-line therapy, if medically feasible. CyBorD was the preferred strategy (72%), excluding stem cell transplant.<sup>136</sup> Please see **Fig. 2** for an algorithmic treatment guideline of AL amyloidosis (**Fig. 2**).

### AA Amyloidosis

AA amyloidosis, or secondary amyloidosis, is a rare systemic disorder that can occur in any chronic inflammatory disorder. Recent research suggests that obesity and age may be susceptibility factors for AA amyloidosis.<sup>137</sup> The amyloid



**Fig. 2** Guidelines for treatment of AL amyloidosis. (Courtesy of Vaishali, Sanchorawalla, MD.) CyBorD, cyclophosphamide, bortezomib, dexamethasone; Dex, dexamethasone; HDM, high-dose melphalan; Mel, Melphalan; SCT, stem cell transplant; VGPR, very good partial response.

fibrils are composed of serum amyloid A protein, which is an acute phase reactant synthesized in the liver. The kidney is the organ most commonly targeted. Mean survival after diagnosis is 133 months.<sup>138</sup> AA amyloidosis rarely has neurological manifestations, although reports of peripheral neuropathy and autonomic neuropathy exist.<sup>139–141</sup>

### β2-Microglobulin

β2-Microglobulin-associated amyloidosis is seen in patients on long-term hemodialysis. The β2 protein which is normally broken down in the renal tubules can accumulate with chronic renal failure. β2-Microglobulin can deposit in the flexor retinaculum and cause CTS.<sup>142</sup> A kindred has been described with Asp76Asn variant β2-microglobulin. Clinical symptoms including gastrointestinal symptoms, autonomic neuropathy, and weight loss develop in the sixth decade. Unlike dialysis-associated amyloidosis, in which wild-type β2-microglobulin deposits around bones and joints secondary to high elevations of circulating β2-microglobulin, this variant's β2-microglobulin amyloid deposits in vivo despite normal plasma β2-microglobulin concentrations, suggesting fibrillogenicity of the variant under physiological conditions.<sup>143</sup>

### Wild-Type TTR

Previously known as senile systemic amyloidosis, TTR wild type or ATTRw is a sporadic form of amyloidosis characterized by deposition of wild-type TTR. Most deposition occurs in the heart leading to heart failure and atrial fibrillation, although deposition in the liver, urinary and gastrointestinal tracts, and connective tissues also occurs. CTS may often be an early complication that allows for earlier diagnosis before cardiac involvement develops.<sup>144</sup>

In a series of 102 TTR cases and 32 isolated cardiac AL cases seen at the UK National Amyloidosis Center, 48% of ATTRw patients reported a history of CTS that preceded the onset of clinical symptoms of heart failure in 77%, a median of 8 years before the diagnosis of amyloidosis was made. In this study, mean survival of patients with ATTRw was 2.71 years, and for cardiac AL amyloidosis survival was 0.87 years. Median survival from onset of symptoms was much longer in the ATTRw group—6.07 years compared with 1.7 years in the cardiac AL group.<sup>145</sup>

Neuropathy was not previously thought to occur in ATTRw; however, the Transthyretin Amyloidosis Outcomes Survey (THAOS) has reported sensory neuropathies in up to 30% in a group of 67 patients with ATTRw, specifically affecting motor function in 15% and autonomic function in 25% of the cohort.<sup>146</sup> Other isolated cases have been reported.<sup>122,147</sup> A single-institution retrospective study of 107 ATTRw patients followed by cardiology and 10 ATTRw patients followed by neurology demonstrated 30.8% ( $n = 33$ ) of the cardiology group had neuropathy symptoms, and 100% ( $n = 10$ ) of the neurology group had neuropathy diagnosed by either EMG/NCS or skin biopsy. The authors concluded that symptoms of peripheral neuropathy are common in patients with ATTRw.<sup>148</sup>

## Conclusions

In conclusion, neuropathy is a common manifestation of both hereditary and acquired forms of amyloidosis, and may present with progressive sensorimotor polyneuropathy, focal neuropathy, autonomic neuropathy, as well as other unusual clinical presentations. Diagnosis is often delayed when neuropathy is the presenting feature of amyloidosis. It is prudent that neurologists consider the diagnosis in patients with neuropathy, with or without a family history, given our currently knowledge about sporadic, nonendemic types of hATTR. Given new treatments for both AL and hATTR amyloidosis, it is essential that our approach to diagnosis and treatment as neurologists be revised, so that these patients may be identified and treated earlier.

### Conflict of Interest

J.B. reports personal fees and study collaborations with Alnylam Pharmaceutical, personal fees and study collaborations with Akcea Pharmaceutical, study collaborations with Pfizer Pharmaceutical, personal fees with Intellia Therapeutics, and personal fees and study collaborations with Corino Therapeutics.

## References

- Planté-Bordeneuve V, Lalu T, Misrahi M, et al. Genotypic-phenotypic variations in a series of 65 patients with familial amyloid polyneuropathy. *Neurology* 1998;51(03):708–714
- Robbins J. Thyroxine-binding proteins. *Prog Clin Biol Res* 1976; 5:331–355
- Wallace MR, Naylor SL, Kluge-Beckerman B, et al. Localization of the human prealbumin gene to chromosome 18. *Biochem Biophys Res Commun* 1985;129(03):753–758
- Dickson PW, Aldred AR, Marley PD, Tu GF, Howlett GJ, Schreiber G. High prealbumin and transferrin mRNA levels in the choroid plexus of rat brain. *Biochem Biophys Res Commun* 1985;127(03):890–895
- Soprano DR, Herbert J, Soprano KJ, Schon EA, Goodman DS. Demonstration of transthyretin mRNA in the brain and other extrahepatic tissues in the rat. *J Biol Chem* 1985;260(21): 11793–11798
- Andrade C. A peculiar form of peripheral neuropathy; familiar atypical generalized amyloidosis with special involvement of the peripheral nerves. *Brain* 1952;75(03):408–427
- Andersson R. Familial amyloidosis with polyneuropathy: a clinical study based on patients living in northern Sweden. *Acta Med Scand Suppl* 1976;590:1–64
- Araki S, Mawatari S, Ohta M, Nakajima A, Kuroiwa Y. Polyneuritic amyloidosis in a Japanese family. *Arch Neurol* 1968;18(06): 593–602
- Schmidt HH, Waddington-Cruz M, Botteman MF, et al. Estimating the global prevalence of transthyretin familial amyloid polyneuropathy. *Muscle Nerve* 2018;57(05):829–837
- Plante-Bordeneuve V. Update in the diagnosis and management of transthyretin familial amyloid polyneuropathy. *J Neurol* 2014; 261(06):1227–1233
- Maurer MS, Hanna M, Grogan M, et al; THAOS Investigators. Genotype and phenotype of transthyretin cardiac amyloidosis: THAOS (Transthyretin Amyloid Outcome Survey). *J Am Coll Cardiol* 2016;68(02):161–172
- Yamashita T, Hamidi Asl K, Yazaki M, Benson MD. A prospective evaluation of the transthyretin Ile122 allele frequency in an African-American population. *Amyloid* 2005;12(02):127–130
- Connors LH, Prokaeva T, Lim A, et al. Cardiac amyloidosis in African Americans: comparison of clinical and laboratory features of transthyretin V122I amyloidosis and immunoglobulin light chain amyloidosis. *Am Heart J* 2009;158(04):607–614
- Hellman U, Alarcon F, Lundgren HE, Suhr OB, Bonaiti-Pellié C, Planté-Bordeneuve V. Heterogeneity of penetrance in familial amyloid polyneuropathy, ATTR Val30Met, in the Swedish population. *Amyloid* 2008;15(03):181–186
- Plante-Bordeneuve V, Carayol J, Ferreira A, et al. Genetic study of transthyretin amyloid neuropathies: carrier risks among French and Portuguese families. *J Med Genet* 2003;40:e120–e120
- Lemos C, Coelho T, Alves-Ferreira M, et al. Overcoming artefact: anticipation in 284 Portuguese kindreds with familial amyloid polyneuropathy (FAP) ATTRV30M. *J Neurol Neurosurg Psychiatry* 2014;85(03):326–330
- Takahashi K, Yi S, Kimura Y, Araki S. Familial amyloidotic polyneuropathy type 1 in Kumamoto, Japan: a clinicopathologic, histochemical, immunohistochemical, and ultrastructural study. *Hum Pathol* 1991;22(06):519–527
- Ikeda S, Yanagisawa N, Hongo M, Ito N. Vagus nerve and celiac ganglion lesions in generalized amyloidosis. A correlative study of familial amyloid polyneuropathy and AL-amyloidosis. *J Neurol Sci* 1987;79(1-2):129–139
- Kelly JJ Jr, Kyle RA, O'Brien PC, Dyck PJ. The natural history of peripheral neuropathy in primary systemic amyloidosis. *Ann Neurol* 1979;6(01):1–7
- Dyck PJ, Lambert EH. Dissociated sensation in amyloidosis. Compound action potential, quantitative histologic and teased-fiber, and electron microscopic studies of sural nerve biopsies. *Arch Neurol* 1969;20(05):490–507
- Planté-Bordeneuve V, Said G. Familial amyloid polyneuropathy. *Lancet Neurol* 2011;10(12):1086–1097
- Koike H, Ikeda S, Takahashi M, et al. Schwann cell and endothelial cell damage in transthyretin familial amyloid polyneuropathy. *Neurology* 2016;87(21):2220–2229
- Verghese JP, Bradley WG, Nemni R, McAdam KP. Amyloid neuropathy in multiple myeloma and other plasma cell dyscrasias. A



- hypothesis of the pathogenesis of amyloid neuropathies. *J Neurol Sci* 1983;59(02):237–246
- 24 Adams D, Suhr OB, Hund E, et al. First European consensus for diagnosis, management, and treatment of transthyretin familial amyloid polyneuropathy. *Curr Opin Neurol* 2016;29:S14
  - 25 Thomas PK, King RH. Peripheral nerve changes in amyloid neuropathy. *Brain* 1974;97(02):395–406
  - 26 Rowe K, Pankow J, Nehme F, Salyers W. Gastrointestinal amyloidosis: review of the literature. *Cureus* 2017;9(05):e1228
  - 27 Rubinow A, Cohen AS. Scalloped pupils in familial amyloid polyneuropathy. *Arthritis Rheum* 1986;29(03):445–447
  - 28 Adams D, Samuel D, Goulon-Goeau C, et al. The course and prognostic factors of familial amyloid polyneuropathy after liver transplantation. *Brain* 2000;123(Pt 7):1495–1504
  - 29 Benson MD, Kincaid JC. The molecular biology and clinical features of amyloid neuropathy. *Muscle Nerve* 2007;36(04):411–423
  - 30 Sousa A, Andersson R, Drugge U, Holmgren G, Sandgren O. Familial amyloidotic polyneuropathy in Sweden: geographical distribution, age of onset, and prevalence. *Hum Hered* 1993;43(05):288–294
  - 31 Ikeda S, Nakazato M, Ando Y, Sobue G. Familial transthyretin-type amyloid polyneuropathy in Japan: clinical and genetic heterogeneity. *Neurology* 2002;58(07):1001–1007
  - 32 Yamashita T, Ueda M, Misumi Y, et al. Genetic and clinical characteristics of hereditary transthyretin amyloidosis in endemic and non-endemic areas: experience from a single-referral center in Japan. *J Neurol* 2018;265(01):134–140
  - 33 Sekijima Y, Ueda M, Koike H, Misawa S, Ishii T, Ando Y. Diagnosis and management of transthyretin familial amyloid polyneuropathy in Japan: red-flag symptom clusters and treatment algorithm. *Orphanet J Rare Dis* 2018;13:6
  - 34 Théaudin M, Lozeron P, Algalarrondo V, et al. Upper limb onset of hereditary transthyretin amyloidosis is common in non-endemic areas. *Eur J Neurol* 2019;26(03):497–e36
  - 35 Togashi S, Watanabe H, Nagasaka T, et al. An aggressive familial amyloidotic polyneuropathy caused by a new variant transthyretin Lys 54. *Neurology* 1999;53(03):637–639
  - 36 Adams D, Lozeron P, Theaudin M, et al; French Network for FAP. Regional difference and similarity of familial amyloidosis with polyneuropathy in France. *Amyloid* 2012;19(Suppl 1):61–64
  - 37 Dohrn MF, Röcken C, De Bleecker JL, et al. Diagnostic hallmarks and pitfalls in late-onset progressive transthyretin-related amyloid-neuropathy. *J Neurol* 2013;260(12):3093–3108
  - 38 Ando Y, Suhr OB. Autonomic dysfunction in familial amyloidotic polyneuropathy (FAP). *Amyloid* 1998;5(04):288–300
  - 39 Saeki Y, Ueno S, Yorifuji S, Sugiyama Y, Ide Y, Matsuzawa Y. New mutant gene (transthyretin Arg 58) in cases with hereditary polyneuropathy detected by non-isotope method of single-strand conformation polymorphism analysis. *Biochem Biophys Res Commun* 1991;180(01):380–385
  - 40 Murakami T, Tachibana S, Endo Y, et al. Familial carpal tunnel syndrome due to amyloidogenic transthyretin His 114 variant. *Neurology* 1994;44(02):315–318
  - 41 Zólyomi Z, Benson MD, Halász K, Uemichi T, Fekete G. Transthyretin mutation (serine 84) associated with familial amyloid polyneuropathy in a Hungarian family. *Amyloid* 1998;5(01):30–34
  - 42 Mazzeo A, Russo M, Di Bella G, et al. TTR-FAP: a single-center experience in Sicily, an Italian endemic area. *J Neuromuscul Dis* 2015;42(09):S31–S32
  - 43 Ikram A, Sperry B, Reyes B, Seitz W, Hanna M. Carpal tunnel syndrome and amyloid cardiomyopathy. *J Cardiac Failure* 2017;23:S11–S12
  - 44 Yanagisawa A, Ueda M, Sueyoshi T, et al. Amyloid deposits derived from transthyretin in the ligamentum flavum as related to lumbar spinal canal stenosis. *Mod Pathol* 2015;28(02):201–207
  - 45 Liewluck T, Milone M. Characterization of isolated amyloid myopathy. *Eur J Neurol* 2017;24(12):1437–1445
  - 46 Yamashita T, Ando Y, Katsuragi S, et al. Muscular amyloid angiopathy with amyloidogenic transthyretin Ser50Ile and Tyr114Cys. *Muscle Nerve* 2005;31(01):41–45
  - 47 Carr AS, Pelayo-Negro AL, Jaunmuktane Z, et al. Transthyretin V122I amyloidosis with clinical and histological evidence of amyloid neuropathy and myopathy. *Neuromuscul Disord* 2015;25(06):511–515
  - 48 Ellie E, Camou F, Vital A, et al. Recurrent subarachnoid hemorrhage associated with a new transthyretin variant (Gly53Glu). *Neurology* 2001;57(01):135–137
  - 49 Uemichi T, Uitti RJ, Koeppen AH, Donat JR, Benson MD. Oculoleptomeningeal amyloidosis associated with a new transthyretin variant Ser64. *Arch Neurol* 1999;56(09):1152–1155
  - 50 Mathieu F, Morgan E, So J, Munoz DG, Mason W, Kongkham P. Oculoleptomeningeal amyloidosis secondary to the rare transthyretin c.381T>G (p.Ile127Met) mutation. *World Neurosurg* 2018;111:190–193
  - 51 Benson MD. Leptomeningeal amyloid and variant transthyretins. *Am J Pathol* 1996;148(02):351–354
  - 52 Petersen RB, Goren H, Cohen M, et al. Transthyretin amyloidosis: a new mutation associated with dementia. *Ann Neurol* 1997;41(03):307–313
  - 53 Brett M, Persey MR, Reilly MM, et al. Transthyretin Leu12Pro is associated with systemic, neuropathic and leptomeningeal amyloidosis. *Brain* 1999;122(Pt 2):183–190
  - 54 Blevins G, Macaulay R, Harder S, et al. Oculoleptomeningeal amyloidosis in a large kindred with a new transthyretin variant Tyr69His. *Neurology* 2003;60(10):1625–1630
  - 55 Herrick MK, DeBruyne K, Horoupian DS, Skare J, Vanefsky MA, Ong T. Massive leptomeningeal amyloidosis associated with a Val30Met transthyretin gene. *Neurology* 1996;47(04):988–992
  - 56 Martins da Silva A, Cavaco S, Fernandes J, et al. Age-dependent cognitive dysfunction in untreated hereditary transthyretin amyloidosis. *J Neurol* 2018;265(02):299–307
  - 57 Planté-Bordeneuve V, Ferreira A, Lalu T, et al. Diagnostic pitfalls in sporadic transthyretin familial amyloid polyneuropathy (TTR-FAP). *Neurology* 2007;69(07):693–698
  - 58 Coelho T, Vinik A, Vinik EJ, et al. Clinical measures in transthyretin familial amyloid polyneuropathy. *Muscle Nerve* 2017;55:323–332
  - 59 Kyle RA, Greipp PR. Amyloidosis (AL). Clinical and laboratory features in 229 cases. *Mayo Clin Proc* 1983;58(10):665–683
  - 60 Vucic S, Chong PST, Cros D. Atypical presentations of primary amyloid neuropathy. *Muscle Nerve* 2003;28(06):696–702
  - 61 Tracy JA, Dyck PJ, Dyck PJ. Primary amyloidosis presenting as upper limb multiple mononeuropathies. *Muscle Nerve* 2010;41(05):710–715
  - 62 Rajkumar SV, Gertz MA, Kyle RA. Prognosis of patients with primary systemic amyloidosis who present with dominant neuropathy. *Am J Med* 1998;104(03):232–237
  - 63 Escolano-Lozano F, Barreiros AP, Birklein F, Geber C. Transthyretin familial amyloid polyneuropathy (TTR-FAP): Parameters for early diagnosis. *Brain Behav* 2017;8(01):e00889
  - 64 Seixas A, Vilas-Boas MdC, Carvalho R, et al. Skin temperature of the foot: comparing transthyretin familial amyloid polyneuropathy and diabetic foot patients. *Comput Methods Biomech Biomed Eng Imaging Vis* 2018:1–8
  - 65 Lozeron P, Mariani L-L, Dodet P, et al. Transthyretin amyloid polyneuropathies mimicking a demyelinating polyneuropathy. *Neurology* 2018;91(02):e143–e152
  - 66 Yang N-C, Lee M-J, Chao C-C, et al. Clinical presentations and skin denervation in amyloid neuropathy due to transthyretin Ala97-Ser. *Neurology* 2010;75(06):532–538
  - 67 Masuda T, Ueda M, Suenaga G, et al. Early skin denervation in hereditary and iatrogenic transthyretin amyloid neuropathy. *Neurology* 2017;88(23):2192–2197
  - 68 Lefaucheur J-P, Ng Wing Tin S, Kerschen P, Damy T, Planté-Bordeneuve V. Neurophysiological markers of small fibre

- neuropathy in TTR-FAP mutation carriers. *J Neurol* 2013;260(06):1497–1503
- 69 Ebenezer GJ, Liu Y, Judge DP, et al. Cutaneous nerve biomarkers in transthyretin familial amyloid polyneuropathy. *Ann Neurol* 2017;82(01):44–56
  - 70 Simmons Z, Blaivas M, Aguilera AJ, Feldman EL, Bromberg MB, Towfighi J. Low diagnostic yield of sural nerve biopsy in patients with peripheral neuropathy and primary amyloidosis. *J Neurol Sci* 1993;120(01):60–63
  - 71 Buxbaum JN, Tagoe CE. The genetics of the amyloidoses. *Annu Rev Med* 2000;51:543–569
  - 72 Cappellari M, Cavallaro T, Ferrarini M, et al. Variable presentations of TTR-related familial amyloid polyneuropathy in seventeen patients. *J Peripher Nerv Syst* 2011;16(02):119–129
  - 73 Luigetti M, Conte A, Del Grande A, et al. TTR-related amyloid neuropathy: Clinical, electrophysiological and pathological findings in fifteen unrelated patients. *Neurol Sci* 2013;34:1057–1063
  - 74 Samões R, Taipa R, Valdez K, et al. Amyloid detection in the transverse carpal ligament of patients with hereditary ATTR V30M amyloidosis and carpal tunnel syndrome. *Amyloid* 2017;24(02):73–77
  - 75 Kollmer J, Sahn F, Hegenbart U, et al. Sural nerve injury in familial amyloid polyneuropathy: MR neurography vs clinicopathologic tools. *Neurology* 2017;89(05):475–484
  - 76 Freeman R, Abuzinadah AR, Gibbons C, Jones P, Miglis MG, Sinn DI. Orthostatic hypotension: JACC state-of-the-art review. *J Am Coll Cardiol* 2018;72:1294–1309
  - 77 Wixner J, Suhr OB, Anan I. Management of gastrointestinal complications in hereditary transthyretin amyloidosis: a single-center experience over 40 years. *Expert Rev Gastroenterol Hepatol* 2018;12:73–81
  - 78 Holmgren G, Steen L, Ekstedt J, et al. Biochemical effect of liver transplantation in two Swedish patients with familial amyloidotic polyneuropathy (FAP-met30). *Clin Genet* 1991;40(03):242–246
  - 79 Yamashita T, Ando Y, Okamoto S, et al. Long-term survival after liver transplantation in patients with familial amyloid polyneuropathy. *Neurology* 2012;78(09):637–643
  - 80 Suhr OB, Larsson M, Ericzon BG, Wilczek HE; FAPWTR's Investigators. Survival after transplantation in patients with mutations other than Val30Met: extracts from the FAP World Transplant Registry. *Transplantation* 2016;100(02):373–381
  - 81 Liepnieks JJ, Zhang LQ, Benson MD. Progression of transthyretin amyloid neuropathy after liver transplantation. *Neurology* 2010;75(04):324–327
  - 82 Sekijima Y, Yazaki M, Oguchi K, et al. Cerebral amyloid angiopathy in posttransplant patients with hereditary ATTR amyloidosis. *Neurology* 2016;87(08):773–781
  - 83 Miller SR, Sekijima Y, Kelly JW. Native state stabilization by NSAIDs inhibits transthyretin amyloidogenesis from the most common familial disease variants. *Lab Invest* 2004;84(05):545–552
  - 84 Berk JL, Suhr OB, Obici L, et al; Diflunisal Trial Consortium. Repurposing diflunisal for familial amyloid polyneuropathy: a randomized clinical trial. *JAMA* 2013;310(24):2658–2667
  - 85 Sekijima Y, Tojo K, Morita H, Koyama J, Ikeda S. Safety and efficacy of long-term diflunisal administration in hereditary transthyretin (ATTR) amyloidosis. *Amyloid* 2015;22(02):79–83
  - 86 Whelan C, Sattianayagam P, Dzungu J, et al. Tolerability of diflunisal therapy in patients with transthyretin amyloidosis. XIIIth International Symposium on Amyloidosis May Groningen, Netherlands. Abstract OP 56; 2012
  - 87 Coelho T, Maia LF, Martins da Silva A, et al. Tafamidis for transthyretin familial amyloid polyneuropathy: a randomized, controlled trial. *Neurology* 2012;79(08):785–792
  - 88 Coelho T, Maia LF, da Silva AM, et al. Long-term effects of tafamidis for the treatment of transthyretin familial amyloid polyneuropathy. *J Neurol* 2013;260(11):2802–2814
  - 89 Waddington Cruz M, Amass L, Keohane D, Schwartz J, Li H, Gundapaneni B. Early intervention with tafamidis provides long-term (5.5-year) delay of neurologic progression in transthyretin hereditary amyloid polyneuropathy. *Amyloid* 2016;23(03):178–183
  - 90 Coelho T, Inês M, Conceição I, Soares M, de Carvalho M, Costa J. Natural history and survival in stage 1 Val30Met transthyretin familial amyloid polyneuropathy. *Neurology* 2018;91:e1999–e2009
  - 91 Benson MD, Waddington-Cruz M, Berk JL, et al. Inotersen treatment for patients with hereditary transthyretin amyloidosis. *N Engl J Med* 2018;379(01):22–31
  - 92 Berk J, Wang AK, Coelho T, et al. Burden of hereditary transthyretin amyloidosis with polyneuropathy in patients enrolled in the Phase 3 study NEURO-TTR (P1. 331). AAN Enterprises, 2018. Available at: [https://n.neurology.org/content/90/15\\_Supplement/P1.331](https://n.neurology.org/content/90/15_Supplement/P1.331). Accessed April 24, 2019
  - 93 Adams D, Gonzalez-Duarte A, O'Riordan WD, et al. Patisiran, an RNAi therapeutic, for hereditary transthyretin amyloidosis. *N Engl J Med* 2018;379(01):11–21
  - 94 Van Allen MW, Frohlich JA, Davis JR. Inherited predisposition to generalized amyloidosis. Clinical and pathological study of a family with neuropathy, nephropathy, and peptic ulcer. *Neurology* 1969;19(01):10–25
  - 95 Nichols WC, Gregg RE, Brewer HB Jr, Benson MD. A mutation in apolipoprotein A-I in the Iowa type of familial amyloidotic polyneuropathy. *Genomics* 1990;8(02):318–323
  - 96 Joy T, Wang J, Hahn A, Hegele RA. APOA1 related amyloidosis: a case report and literature review. *Clin Biochem* 2003;36(08):641–645
  - 97 de Sousa MM, Vital C, Ostler D, et al. Apolipoprotein AI and transthyretin as components of amyloid fibrils in a kindred with apoAI Leu178His amyloidosis. *Am J Pathol* 2000;156(06):1911–1917
  - 98 Testro AG, Brennan SO, Macdonell RA, Hawkins PN, Angus PW. Hereditary amyloidosis with progressive peripheral neuropathy associated with apolipoprotein AI Gly26Arg: outcome of hepatorenal transplantation. *Liver Transpl* 2007;13(07):1028–1031
  - 99 Kiuru S, Seppäläinen AM. Neuropathy in familial amyloidosis, Finnish type (FAF): electrophysiological studies. *Muscle Nerve* 1994;17(03):299–304
  - 100 Meretoja J. Familial systemic paramyloidosis with lattice dystrophy of the cornea, progressive cranial neuropathy, skin changes and various internal symptoms. A previously unrecognized heritable syndrome. *Ann Clin Res* 1969;1(04):314–324
  - 101 Kiuru S. Familial amyloidosis of the Finnish type (FAF). A clinical study of 30 patients. *Acta Neurol Scand* 1992;86(04):346–353
  - 102 Boysen G, Galassi G, Kamieniecka Z, Schlaeger J, Trojaborg W. Familial amyloidosis with cranial neuropathy and corneal lattice dystrophy. *J Neurol Neurosurg Psychiatry* 1979;42(11):1020–1030
  - 103 Sunada Y, Shimizu T, Nakase H, et al. Inherited amyloid polyneuropathy type IV (gelsolin variant) in a Japanese family. *Ann Neurol* 1993;33(01):57–62
  - 104 Kiuru S, Salonen O, Haltia M. Gelsolin-related spinal and cerebral amyloid angiopathy. *Ann Neurol* 1999;45(03):305–311
  - 105 Kiuru S, Matikainen E, Kupari M, Haltia M, Palo J. Autonomic nervous system and cardiac involvement in familial amyloidosis, Finnish type (FAF). *J Neurol Sci* 1994;126(01):40–48
  - 106 Kiuru-Enari S, Somer H, Seppäläinen A-M, Notkola I-L, Haltia M. Neuromuscular pathology in hereditary gelsolin amyloidosis. *J Neuropathol Exp Neurol* 2002;61(06):565–571
  - 107 Gertz MA, Lacy MQ, Dispenzieri A. Amyloidosis: recognition, confirmation, prognosis, and therapy. *Mayo Clin Proc* 1999;74(05):490–494
  - 108 Kyle RA, Gertz MA. Primary systemic amyloidosis: clinical and laboratory features in 474 cases. *Semin Hematol* 1995;32(01):45–59
  - 109 Duston MA, Skinner M, Anderson J, Cohen AS. Peripheral neuropathy as an early marker of AL amyloidosis. *Arch Intern Med* 1989;149(02):358–360
  - 110 Matsuda M, Gono T, Morita H, Katoh N, Kodaira M, Ikeda S. Peripheral nerve involvement in primary systemic AL amyloidosis:

- a clinical and electrophysiological study. *Eur J Neurol* 2011;18(04):604–610
- 111 Adams D, Lozeron P, Theaudin M, et al. Varied patterns of inaugural light-chain (AL) amyloid polyneuropathy: a monocentric study of 24 patients. *Amyloid* 2011;18(Suppl 1):98–100
  - 112 Luigetti M, Papacci M, Bartoletti S, Marcaccio A, Romano A, Sabatelli M. AL amyloid neuropathy mimicking a chronic inflammatory demyelinating polyneuropathy. *Amyloid* 2012;19(01):53–55
  - 113 Mathis S, Magy L, Diallo L, Boukhris S, Vallat JM. Amyloid neuropathy mimicking chronic inflammatory demyelinating polyneuropathy. *Muscle Nerve* 2012;45(01):26–31
  - 114 Cheng RR, Eskandari R, Welsh CT, Varma AK. A case of isolated amyloid light-chain amyloidosis of the radial nerve. *J Neurosurg* 2016;125(03):598–602
  - 115 Little KH, Lee EL, Frenkel EP. Cranial nerve deficits due to amyloidosis associated with plasma cell dyscrasia. *South Med J* 1986;79(06):677–681
  - 116 Traynor AE, Gertz MA, Kyle RA. Cranial neuropathy associated with primary amyloidosis. *Ann Neurol* 1991;29(04):451–454
  - 117 Massey EW, Massey JM. Facial diplegia due to amyloidosis. *South Med J* 1986;79(11):1458–1459
  - 118 Liewluck T, Milone M. Amyloid myopathy with and without systemic amyloidosis (S54.006). *Neurology* 2017;88:S54
  - 119 Kahn SN, Bina M. Sensitivity of immunofixation electrophoresis for detecting IgM paraproteins in serum. *Clin Chem* 1988;34(08):1633–1635
  - 120 Abraham RS, Katzmam JA, Clark RJ, Bradwell AR, Kyle RA, Gertz MA. Quantitative analysis of serum free light chains. A new marker for the diagnostic evaluation of primary systemic amyloidosis. *Am J Clin Pathol* 2003;119(02):274–278
  - 121 Katzmam JA, Clark RJ, Abraham RS, et al. Serum reference intervals and diagnostic ranges for free  $\kappa$  and free  $\lambda$  immunoglobulin light chains: relative sensitivity for detection of monoclonal light chains. *Clin Chem* 2002;48(09):1437–1444
  - 122 Wang A, Gorevic P. Neurologic Improvement after Cervical Decompression in Wild-Type Transthyretin Amyloidosis. Companion to Peripheral Neuropathy: Illustrated Cases and New Developments. Philadelphia, PA: Elsevier Saunders; 2010:145–149
  - 123 Dingli D, Tan TS, Kumar SK, et al. Stem cell transplantation in patients with autonomic neuropathy due to primary (AL) amyloidosis. *Neurology* 2010;74(11):913–918
  - 124 Gertz MA, Kyle RA, Greipp PR. Response rates and survival in primary systemic amyloidosis. *Blood* 1991;77(02):257–262
  - 125 Katoh N, Matsuda M, Yoshida T, et al. Primary AL amyloid polyneuropathy successfully treated with high-dose melphalan followed by autologous stem cell transplantation. *Muscle Nerve* 2010;41(01):138–143
  - 126 Skinner M, Sanchorawala V, Seldin DC, et al. High-dose melphalan and autologous stem-cell transplantation in patients with AL amyloidosis: an 8-year study. *Ann Intern Med* 2004;140(02):85–93
  - 127 Kyle RA, Gertz MA, Greipp PR, et al. A trial of three regimens for primary amyloidosis: colchicine alone, melphalan and prednisone, and melphalan, prednisone, and colchicine. *N Engl J Med* 1997;336(17):1202–1207
  - 128 Seldin DC, Choufani EB, Dember LM, et al. Tolerability and efficacy of thalidomide for the treatment of patients with light chain-associated (AL) amyloidosis. *Clin Lymphoma* 2003;3(04):241–246
  - 129 Palladini G, Perfetti V, Perlini S, et al. The combination of thalidomide and intermediate-dose dexamethasone is an effective but toxic treatment for patients with primary amyloidosis (AL). *Blood* 2005;105(07):2949–2951
  - 130 Sanchorawala V, Wright DG, Rosenzweig M, et al. Lenalidomide and dexamethasone in the treatment of AL amyloidosis: results of a phase 2 trial. *Blood* 2007;109(02):492–496
  - 131 Mikhael JR, Schuster SR, Jimenez-Zepeda VH, et al. Cyclophosphamide-bortezomib-dexamethasone (CyBorD) produces rapid and complete hematologic response in patients with AL amyloidosis. *Blood* 2012;119(19):4391–4394
  - 132 Palladini G, Sachchithanatham S, Milani P, et al. A European collaborative study of cyclophosphamide, bortezomib, and dexamethasone in upfront treatment of systemic AL amyloidosis. *Blood* 2015;126(05):612–615
  - 133 Sanchorawala V, Shelton AC, Lo S, Varga C, Sloan JM, Seldin DC. Pomalidomide and dexamethasone in the treatment of AL amyloidosis: results of a phase 1 and 2 trial. *Blood* 2016;128(08):1059–1062
  - 134 Palladini G, Milani P, Foli A, et al. A phase 2 trial of pomalidomide and dexamethasone rescue treatment in patients with AL amyloidosis. *Blood* 2017;129(15):2120–2123
  - 135 Sanchorawala V, Sarosiek S, Sloan JM, et al. Safety and tolerability of daratumumab in patients with relapsed light chain (AL) amyloidosis: preliminary results of a phase II study. *Blood* 2017;130:507
  - 136 Milani P, Gertz MA, Merlini G, Dispenzieri A. Attitudes about when and how to treat patients with AL amyloidosis: an international survey. *Amyloid* 2017;24(04):213–216
  - 137 Blank N, Hegenbart U, Dietrich S, et al. Obesity is a significant susceptibility factor for idiopathic AA amyloidosis. *Amyloid* 2018;25:37–45
  - 138 Lachmann HJ, Goodman HJ, Gilbertson JA, et al. Natural history and outcome in systemic AA amyloidosis. *N Engl J Med* 2007;356(23):2361–2371
  - 139 Tsunoda I, Awano H, Kayama H, et al. Idiopathic AA amyloidosis manifested by autonomic neuropathy, vestibulocochleopathy, and lattice corneal dystrophy. *J Neurol Neurosurg Psychiatry* 1994;57(05):635–637
  - 140 Nakamura T, Tomoda K, Tsukano M, Yamamura Y, Baba S. Gustatory sweating due to autonomic neuropathy in a patient with amyloidosis secondary to rheumatoid arthritis. *Mod Rheumatol* 2004;14(06):498–501
  - 141 Gaspar BL, Garg C, Vasishta RK, Nada R, Goyal MK. Localised SAA amyloidosis with intra-axonal intra-myelin amyloid deposits. *Pathology* 2017;49(01):103–105
  - 142 Perfetto F, Moggi-Pignone A, Livi R, Tempestini A, Bergesio F, Matucci-Cerinic M. Systemic amyloidosis: a challenge for the rheumatologist. *Nat Rev Rheumatol* 2010;6(07):417–429
  - 143 Valleix S, Gillmore JD, Bridoux F, et al. Hereditary systemic amyloidosis due to Asp76Asn variant  $\beta$ 2-microglobulin. *N Engl J Med* 2012;366(24):2276–2283
  - 144 Nakagawa M, Sekijima Y, Yazaki M, et al. Carpal tunnel syndrome: a common initial symptom of systemic wild-type ATTR (ATTRwt) amyloidosis. *Amyloid* 2016;23(01):58–63
  - 145 Pinney JH, Whelan CJ, Petrie A, et al. Senile systemic amyloidosis: clinical features at presentation and outcome. *J Am Heart Assoc* 2013;2(02):e000098
  - 146 Coelho T, Maurer MS, Suhr OB. THAOS - The Transthyretin Amyloidosis Outcomes Survey: initial report on clinical manifestations in patients with hereditary and wild-type transthyretin amyloidosis. *Curr Med Res Opin* 2013;29(01):63–76
  - 147 Lam L, Margeta M, Layzer R. Amyloid polyneuropathy caused by wild-type transthyretin. *Muscle Nerve* 2015;52(01):146–149
  - 148 Wajnsztajn F, Kim A, Boehme A, Maurer M, Brannagan T. Peripheral neuropathy in wild type transthyretin amyloidosis. (P1.438). *Neurology* 2018;90(15, Suppl)