

Neuroprotective effects of *Potentilla fulgens* on spinal cord injury in rats: an immunohistochemical analysis

M. Baloğlu¹, A. Çetin², M.C. Tuncer³

¹Department of Physiotherapy University of Health Sciences, Gazi Yaşargil Education and Research Hospital, Diyarbakir, Turkey

²Department of Neurosurgery, University of Health Sciences, Gazi Yaşargil Education and Research Hospital, Diyarbakir, Turkey

³Department of Anatomy, Faculty of Medicine, University of Dicle, Diyarbakir, Turkey

[Received: 8 February 2018; Accepted: 17 April 2018]

Background: This examination was performed to research the advantage of the antioxidant impact of *Potentilla fulgens* on spinal cord injury (SCI) in rats.

Materials and methods: In the SCI model of this examination, the tolerably serious lesion was performed at the L1–L2 spinal segmental level. SCI animals were given *P. fulgens* 400 mg/kg/day, intraperitoneally. At 7 days post-lesion, exploratory rats were executed after intraperitoneal administration 7 ketamine HCL (0.15 mL/100 g body weight). Spinal cord specimens were taken for histological examination or assurance of malondialdehyde (MDA) and glutathione (GSH) levels and myeloperoxidase (MPO) action. SCI caused a remarkable decline in spinal cord GSH content, trailed by noteworthy increments in MDA levels and MPO action.

Results: Degenerative changes in some multipolar and bipolar nerve cells and pyknotic changes in the nuclei of glial cells were likewise noticed. Remarkable development was seen in cells and vascular structures of *P. fulgens* treated groups when contrasted with untreated groups.

Conclusions: *Potentilla fulgens* application may influence angiogenetic improvement in vein endothelial cells, reduce inflammatory cell aggregation by influencing cytokine system and may make apoptotic nerve cells and neuroprotective component in glial cells. (Folia Morphol 2019; 78, 1: 17–23)

Key words: spinal cord injury, *Potentilla fulgens*, vascular endothelial growth factor (VEGF), B-cell lymphoma 2 (Bcl-2)

INTRODUCTION

Most spinal cord lesions are seen on the cervical spine, while devastating motor, sensory and autonomic dysfunctions are causing issues for spinal cord injury (SCI) cervical, thoracic, lumbar, and sacral levels under injury [3]. Disturbing lesion in spinal cord starts an enormous resistant reaction which may bring about the apoptosis of neurons and the initia-

tion of glial cells, and the neurological dysfunction. Lesion to the spinal cord prompts irreversible loss of neurons [13, 36].

It has been demonstrated that this useful revamping within the dorsal horns comes about because of excessive and non-specific growing of essential afferent sensory fibres and loss of supraspinal innervations/neurons after lesion [18, 22]. It has additionally

been demonstrated that bruise SCI prompts expanded abundance and broad spreading of essential afferents and that a decrease in the abundance of sensory nerve cells is related to reduced pain after SCI [6]. The pathological procedure of SCI can be partitioned into two phases: essential lesion and subordinate lesion. Essential lesion happens instantly after the underlying lesion, and its pathological procedures incorporate demyelination of the spinal cord and necrosis of the neurons and nerve cells [45].

Subordinate lesion happens all through the disease, and its pathological procedures incorporate demyelination, axonal and neuronal necrosis, sensory tissue ischaemia and oedema, oxidative compression, inflammatory response, and glial scar development [12, 26, 32, 37, 43]. The essential injury is privately limited to the territory of the vertebral fracture and is distinguished by intense haemorrhage and ischaemia. Subordinate trauma within the first week after the lesion is distinguished by further destruction of neuronal and glial cells, and leads healing to a remarkable extension of the injury, with the goal that the paralysis can reach out to higher sections.

Oxygen-derived free radicals have been embroiled in the pathogenesis of spinal cord neuronal lesion after injury. Reducing the level of oxidative compression limits the subordinate destructive impact after disturbing lesion. After spinal cord lesion, loss of motor, sensory and autonomic sensory system capacities, muscle spasms, chronic pain, and urinary tract diseases may happen [1]. Both practical (locomotor capacity and bladder function) and histological parameters (tissue sparing, axonal sparing, astrogliosis, inflammation and BSCB permeability) was enhanced by healing with imatinib following spinal cord weight-drop lesion [2].

Potentilla fulgens is an alpine plant of Western Himalayas which is devoured in all parts of the world for its promising therapeutic properties. Pharmacologically, the aerial and root parts of the plant are accounted for to have antioxidant, antitumor, hypoglycaemic and antihyperglycaemic components [3, 19, 40].

Vascular endothelial growth factor (VEGF) is among the essentially upregulated genes found in SCI rats with allodynia [29]. Apoptosis has a noteworthy part in the component of the disturbing lesion in the juvenile brain and is extremely serious in the brain of 7-day-old rats [28]. A few examinations have exhibited that over-expression of B-cell lymphoma 2

(Bcl-2) keeps neurons from cell death incited by free radicals [38], hypoxia [39] or development factor deprivation [23]. The neuroprotective impact of *P. fulgens* on neuronal and angiogenetic function after spinal cord injury was examined.

MATERIALS AND METHODS

Animals and experimental design

Every single surgical methodology and the consequent care and healing of the animals utilised as a part of this investigation were in strict understanding with the National Institutes of Health (NIH Publications No. 8023, revised 1978) rules for animal care. All techniques performed in this examination were approved by the Ethics Committee for Animal Experimentation of the Faculty of Medicine at Dicle University in Turkey. Thirty male Sprague-Dawley rats (200–230 g) were kept up under $22 \pm 1^\circ\text{C}$ and 12 h light/grey cycles with *ad libitum* access to standard pelleted nourishment and water. The 30 rats were separated into three groups as a control group, SCI group and SCI + *P. fulgens* treated group (400 mg/kg/day, i.p.) [24].

The rats of the control ($n = 10$) and the SCI groups ($n = 10$) were administered 1.5 mL physiologic saline solution subcutaneously for 7 days as it were. The rats of all groups were kept up in a similar situation and ate a similar sort of food. All rats toward the finish of the analysis were healthy and no distinction in nourishment/water consumption and body weight pick up amongst experimental and control rats were noticed.

Spinal cord injury model

Experimental rats were anesthetised intraperitoneally with ketamine and chlorpromazine 75 mg/kg and 1 mg/kg, separately [42]. Every rat was then positioned on a heating pad in a prone position and a rectal test was embedded. Under aseptic conditions, following T5-12 midline skin incision and paravertebral muscle dissection, spinous procedures and laminar arcs of T5-12 were evacuated. The particular relative angulation of the spinous procedures of the T9, T10, and T11 vertebrae was utilized as an imperative intraoperative landmark: T9 points caudally, T10 points directly dorsal, and T11 points rostrally. This delivers a solid "triangle" introduction that can be promptly checked whether the animal is positioned flat on the operating table. After the T11 and T12 vertebrae had been distinguished, a laminectomy was performed at T11 and T12 with

Friedman-Pearson rongeurs. The clasp was then held open with a clasp utensil, with the lower cutting edge of the clasp passed extradurally completely around the spinal cord and nerve roots at the intersection between the T11 and T12 vertebrae, comparing to the L1-L2 spinal cord segmental level. The clasp was then quickly discharged from the tool to deliver a bilateral impact force and sustained dorsal-ventral compression. The compression of the spinal cord was kept up for 60 s before expulsion of the clasp. The muscles were then sutured utilising 3-0 polyglactin sutures, and the skin was shut with Michel clips [27]. Following surgical system, the rats were put in warming chamber and their body temperatures were kept up at roughly 37°C until the point when they were totally conscious. An hour after the spinal cord injury in the exploratory groups, saline only was injected intraperitoneally in rats of the SCI group.

After spinal cord injury, *P. fulgens* (400 mg/kg/day, i.p.) was administered intraperitoneally in rats of the SCI + *P. fulgens* treated group during 7 days. Toward the finish of the examination, the animals were sacrificed utilising a decapitator (Harvard Apparatus, Holliston, MA, USA). The 30 rats were partitioned into three groups as control, SCI and SCI + *P. fulgens* treated groups (400 mg/kg/day, i.p.). Each group had 10 animals. All of them were utilised for biochemical parameters and the assessment of histological examination in each group.

Histologic examinations

The specimens taken from the spinal cord were fixed with neutral buffered 10% formalin solution. Spinal cord specimens were directly dehydrated in an evaluated solution of ethanol and implanted into paraffin wax; 5 mm sections were cut with a microtome (Rotatory Microtome, Leica, RM 2265, Germany) and mounted on the smeared slides. The segments were stained with haematoxylin and eosin in order to describe the white and the grey matter, separately.

Immunohistochemical staining

An antigen-retrieval process was performed in citrate buffer solution (pH 6.0) two times: first for 7 min, and afterward for 5 min in a microwave oven at 700 W. They were permitted to cool to room temperature for 30 min and washed in distilled water twice for 5 min. Endogenous peroxidase action was hindered in 0.1% hydrogen peroxide for 15 min. An ultra V block (Histostain-Plus Kit, Invitrogen, Carlsbad, CA) was connected for 10 min before the use of the pri-

mary antibodies (VEGF antibody, mouse monoclonal, 1/200, SantaCruz Biotechnology) and Bcl-2 antibody (mouse monoclonal, 1/100, Abcam) overnight.

The secondary antibody (Histostain-Plus Kit, Invitrogen, Carlsbad, CA) was connected for 15 min. At that point, the slides were exposed to streptavidin-peroxidase for 15 min. Diaminobenzidine (DAB, Invitrogen, Carlsbad) was utilised as a chromogen. Control slides were set up as specified above yet overlooking the primary antibodies. In the wake of counterstaining with haematoxylin, washing in tap water for 5 min, and in refined water for 2 × 5 min, the slides were mounted.

Measurement of MPO activity

The myeloperoxidase (MPO) activity levels were measured using the method described by Hillegass et al. [17]. Spinal cord tissue specimens were homogenised in 50 mM potassium phosphate buffer with a pH of 6.0 and centrifuged at 41,400 g for 10 min. The pellets were then suspended in 50 mM PB containing 0.5% hexadecyl trimethyl-ammonium bromide (HETAB). After three freezes and defrost cycles, with sonication between cycles, the samples were centrifuged at 41,400 g for 10 min. Aliquots (0.3 mL) were added to 2.3 mL of the response mixture containing 50 mM PB, o-dianisidine, and 20 mM H₂O₂ solution. One unit of enzyme action was characterised as the measure of MPO presence that caused an adjustment in absorbance, estimated at 460 nm for 3 min. MPO action was expressed as U/g tissue.

MDA and GSH assays

Spinal cord tissue samples were homogenised with super cold 150 mM KCl for the assurance of malondialdehyde (MDA) and glutathione (GSH) levels. The MDA levels were tested for the products of lipid peroxidation and the outcomes are expressed as nmol MDA/g tissue [20].

Glutathione was resolved by a spectrophotometric technique in light of the utilisation of Ellman's reagent and the outcomes are expressed as μmol GSH/g tissue [10].

Statistical analysis

All information is expressed as means ± standard deviation. Groups of information were contrasted and an analysis of variance (ANOVA) trailed by Tukey's various correlation samples. Estimations of p < 0.05 were considered as significant.

Table 1. Biochemical results according to the study groups

	Control	SCI	SCI + <i>P. fulgens</i>
MDA [nmol/g]	30.45 ± 0.72	47.64 ± 0.66**	33.24 ± 0.82 ⁺⁺
GSH [μmol/g]	2.65 ± 0.08	1.84 ± 0.04*	2.62 ± 0.07 ⁺⁺
MPO [U/g]	4.52 ± 0.02	7.82 ± 0.62**	7.92 ± 0.28 ⁺

Values are presented as mean ± standard deviation. Each group consists of 10 rats. GSH — glutathione; MDA — malondialdehyde; MPO — myeloperoxidase; SCI — spinal cord injury

*p < 0.05, versus control; **p < 0.001 vs. control; +p < 0.01, SCI + *P. fulgens* treated group; ++p < 0.001, SCI + *P. fulgens* treated group

RESULTS

In this study, control, SCI and SCI + *P. fulgens* treated groups were analysed as far as biochemical data. MPO action, which is acknowledged as an indicator of neutrophil infiltration, was fundamentally higher in the spinal cord tissues of disturbed rats than those of the control group (p < 0.001). *P. fulgens* healing fundamentally reduced spinal cord tissue MPO levels (p < 0.01). The injury caused a noteworthy increment in the MDA levels (p < 0.001) with an attending reduction in GSH levels (p < 0.001). *P. fulgens* healing fundamentally decreased the increase in MDA levels and reestablished the GSH content at day 7 (Table 1).

In spinal cord samples of the control group, the nuclei of multipolar neurons with polygonal appearances in the foremost part of the grey matter layer demonstrated rough chromatin and the nerve expansions were scattered in parallel. Glial cells with oval nuclei were seen in the white matter and the axonal and dendritic expansions were orderly. In the SCI group, mononuclear cell infiltration was seen around the vessels, and in addition dilatation and discharge of the veins were seen along the pia mater and in the veins, in the foremost median fissure of the spinal cord. Degenerative changes in a portion of the multipolar and bipolar nerve cells and pyknotic changes in the nuclei of glial cells were noticed.

The histopathological examination of SCI + *P. fulgens* treated groups uncovered minor haemorrhagic sections with decreased inflammatory cells in the grey and the white matter, slight degeneration in multipolar and bipolar cells, and hypertrophic glial cells were likewise noticed. Immunohistochemical examinations of the control group indicated VEGF positive expression in the assortments of multipolar neurons in the foremost part of the spinal cord while it was somewhat expressed in minor fine and vascular endothelial cells. In the spinal cord lesion injury, expanded VEGF expression was seen in the endothelial cells of vessels in the grey and the white matter layers.

Positive VEGF expression was likewise found in some nerve cells and glial cells. In the SCI + *P. fulgens* treated group, VEGF expression in the vascular endothelium was positive. Conversely, it was feeble in the glial cells and a portion of the radicular and funicular cells in the grey and the white matter. In the control group of Bcl-2 expression, negative Bcl-2 immunoreaction was seen in the radicular-funicular nerves and the glial cells. In the SCI group, positive Bcl-2 immunoreaction was seen in apoptotic cells, in minor unipolar neurons, and in glial cells. In SCI + *P. fulgens* treated group, apoptotic changes were seen in bipolar and unipolar neurons, yet Bcl-2 expression surfaces were not as much as the SCI group (Fig. 1).

DISCUSSION

Spinal cord lesion is typically a disturbing lesion to the central nervous system which can bring about tissue and motor dysfunction accompanied by molecular and cellular injury after trauma. Spinal cord lesion brings about a fast and broad oxidative compression. It has for quite some time been built up that oxidative compression assumes a significant part in the pathophysiology of SCI [9, 11, 34]. The utilisation of animal models is significant in formulating experimental healings planned to restore lost functions due to SCI [36].

Receptive astrocytes likewise assume a vital part in lesion healing and practical recuperation after SCI. At the subacute stage, astrocytes relocate to compact the injury, apparently detaching the inflammatory cells to keep them from spreading into the parenchyma of the spinal cord. Initially, it was believed that the essential function of astrocytes was to buffer and supply neurons; however, these days there is a lot of evidence demonstrating that astrocytes are firmly connected with microglia, oligodendrocytes, and different astrocytes in the nervous system. Astrocytes direct neurotransmitters, take an interest in synaptogenesis, mediate the antibody, express extracellular matrix molecules, advanced cell migration, and advanced separation and development of the central nervous system [4].

Apoptosis causes the death of neuronal cells, particularly neurons and oligodendrocytes in the spinal cord after lesion, and further upsets and annihilates the axon-myelin anatomical unit and disables impulse conduction, bringing about neuronal loss [33, 34]. A period course investigation in rats uncovered that apoptosis happened as ahead of schedule as 4 h post lesion and could be seen in decline amount as late as 3 weeks after SCI. After SCI, caspase initiation hap-

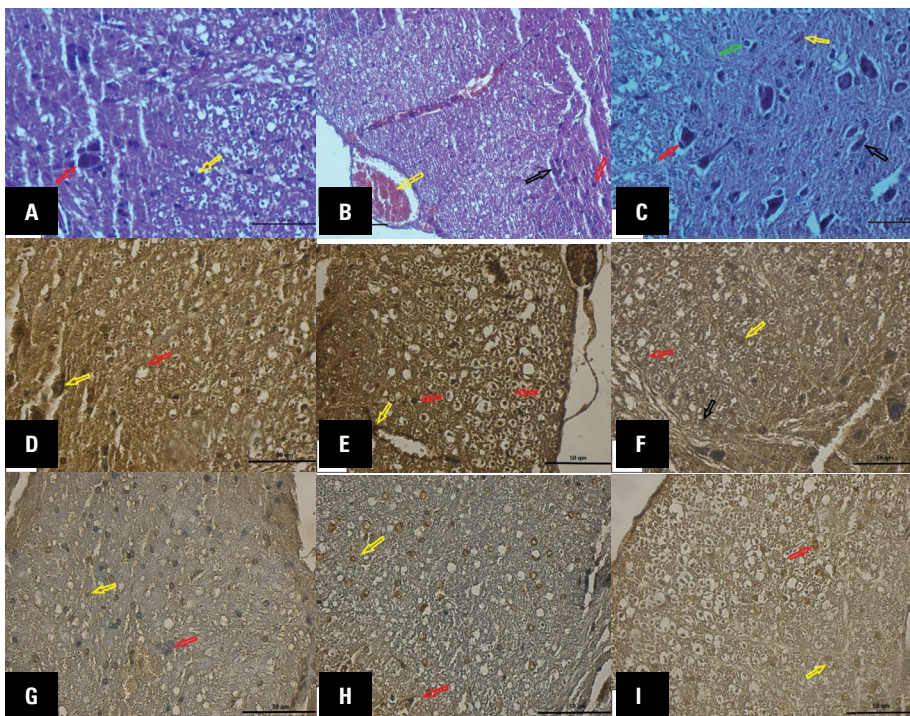


Figure 1. **A.** Control group. The nuclei of multipolar neurons with polygonal appearances at the front of the grey matter layer shows coarse chromatin (red arrow) and the nerve extensions are distributed in parallel, the round nucleus of the glial cells (yellow arrow) in the white matter, the axonal and the dendritic extensions are regular (haematoxylin-eosin staining, bar 50 μm); **B.** Spinal cord injury (SCI) group. Dilatation and haemorrhage in a blood vessel (yellow arrow), degeneration and nuclear pyknosis in radicular (black arrow), funicular neuron cells (red arrow) (haematoxylin-eosin staining, bar 50 μm); **C.** SCI + *P. fulgens* treated group. Small haemorrhagic segments (yellow arrow) with reduced inflammatory cells in the grey and the white matter, slight degeneration in multipolar (red arrow) and bipolar cells (black arrow), and hypertrophic glial cells (green arrow) (haematoxylin-eosin staining, bar 50 μm); **D.** Control group. Vascular endothelial growth factor (VEGF) positive expression in multipolar neurons (yellow arrow) and vascular endothelial cells (red arrow) (VEGF immunostaining, bar 50 μm); **E.** SCI group. An increase in VEGF expression in endothelial cells (yellow arrow), positive VEGF expressions in some nerve cells and glial cells (red arrow) (VEGF immunostaining, bar 50 μm); **F.** SCI + *P. fulgens* treated group. Positive VEGF expression in the vascular endothelium (red arrow), weak VEGF expression in glial cells (yellow arrow) and some of the radicular and funicular cells (black arrow) (VEGF immunostaining, bar 50 μm); **G.** Control group. Negative B-cell lymphoma 2 (Bcl-2) immuno-reaction in radicular-funicular nerves (red arrow) and glial cells (yellow arrow) (Bcl-2 immunostaining, bar 50 μm); **H.** SCI group. Positive Bcl-2 expression in apoptotic cells, small unipolar neurons (red arrow) and glial cells (yellow arrow) (Bcl-2 immunostaining, bar 50 μm); **I.** SCI + *P. fulgens* treated group. Decrease in the quantity of Bcl-2 expression in unipolar neurons (red arrow), and glial cells (yellow arrow) (Bcl-2 immunostaining, bar 50 μm).

pens in neurons at the lesion site within hours, and in oligodendrocytes neighbouring, and far off from, the lesion site over a time of days. The long duration neurological shortages after spinal cord lesion might be expected to a limited extent to induce extensive apoptosis of neurons and oligodendroglia is caused by lesions in distant and often unaffected areas [8].

Özevren et al. [30] found that *P. fulgens* may ameliorate nerve cell injury after traumatic brain lesion, contingent upon the measure of application. VEGF is a contributing component in the advancement of vascularisation amid angiogenesis and spinal cord lesion. In any case, the neuroprotective mechanism of VEGF is as yet uncertain. A few examinations have demonstrated that the administration of VEGF to the wounded spinal cord has neuroprotective effect,

induces angiogenesis and enhances neurobehavioural outcomes [25, 31].

Herrera et al. [16] demonstrated that VEGF is regularly expressed in neurons and astrocytes. They observed that neurons at the site of lesion 1 day after spinal cord lesion were significantly lost and could add to a general reduction in VEGF. After spinal cord lesion, VEGF expression was seen in some nerve cells and glial cells, an expansion in VEGF immuno-response in vascular endothelial cells was noticed. For this situation, angiogenesis was believed to be actuated in endothelial cells after lesion. One investigation demonstrated that the over-expression of Bcl-2 by gene transfer or in transgenic mice decreased infarction after permanent and transient central ischaemia. Expression of the apoptosis-inhibitory Bcl-2 gene

under the control of tissue particular promoters has turned out to be equipped for shielding different sorts of cells from apoptosis, especially motor neurons of the spinal cord [7].

The glutathione/glutathione disulphide (GSH/GSSG) redox framework is a noteworthy contributor to the upkeep of the cellular thiol redox status. Confirmation demonstrated that the decrease in cell GSH was related to upgraded cellular apoptosis while increments in GSH were related to the expression of the anti-apoptotic enzyme, Bcl-2 [15]. As indicated by the outcomes of this investigation, reduction in apoptotic cell quantity of nerves and glial cells, and furthermore reduction in the Bcl-2 immunoreactivity was considered as an indication of cell upturn in apoptosis mechanism.

Tas et al. [41] found that neuronal injury impacted astrocytes in the blood-brain obstruction and initiated cellular apoptosis. Kanno et al. [21] found that autophagic cell death was incited in the wounded tissue after SCI and plainly added to neural tissue injury after SCI.

After spinal cord lesion, inflammation of the spinal cord and impeded vascular structure, apoptotic changes of neurons, and dynamopathic healing are a vital procedure. At the point when apoptosis of neurons and glial cells is counteracted after lesion, the loss of nerve tissue can be fundamentally lessened and spinal cord lesion may improve. Inflammatory reactions are a noteworthy component of the secondary lesion and they are supposed to play a key role in controlling the pathogenesis of intense and chronic SCI and appear to play a significant role in nerve injury and in addition add to the control of the regenerative reaction [14]. In the interim, inflammatory reactions may bring about apoptosis of neurons and oligodendrocytes and also scar formation and lastly the decrease in neuronal capacity [35]. Hence, it is believed that decreasing inflammation could reduce subordinate degeneration and functional impairment after SCI.

CONCLUSIONS

All in all, *P. fulgens* administration after SCI reduced apoptotic cell quantity of nerves and glial cells. Since it impacted the cytokine mechanism, it supposedly decreased the quantity of inflammatory cells and incited angiogenetic advancement. With the distinguishing proof of mechanisms that counteract spinal cord inflammation and apoptosis, come new

methodologies for avoiding and treating SCI. Be that as it may, there is no present strategy for healing of SCI. There is a need for more experimental examinations on the dose quantity and span of healing of *P. fulgens* in SCI. Thusly, therapeutic impact on SCI will be better comprehended later on.

REFERENCES

1. Abrams GM, Ganguly K. Management of chronic spinal cord dysfunction. Continuum (Minneapolis, Minn). 2015; 21(1 Spinal Cord Disorders): 188–200, doi: [10.1212/01.CON.0000461092.86865.a4](https://doi.org/10.1212/01.CON.0000461092.86865.a4), indexed in Pubmed: 25651225.
2. Abrams MB, Nilsson I, Lewandowski SA, et al. Imatinib enhances functional outcome after spinal cord injury. PLoS One. 2012; 7(6): e38760, doi: [10.1371/journal.pone.0038760](https://doi.org/10.1371/journal.pone.0038760), indexed in Pubmed: 22723886.
3. Ahuja CS, Wilson JR, Nori S, et al. Traumatic spinal cord injury. Nat Rev Dis Primers. 2017; 3: 17018, doi: [10.1038/nrdp.2017.18](https://doi.org/10.1038/nrdp.2017.18), indexed in Pubmed: 28447605.
4. Barua CC, Yasmin N. *Potentilla fulgens*: a systematic review on traditional uses, pharmacology and phytochemical study with reference to anticancer activity. J Nat Prod Resour. 2018; 4(1): 162–170, doi: [10.30799/jnpr.058.18040103](https://doi.org/10.30799/jnpr.058.18040103).
5. Bi F, Huang C, Tong J, et al. Reactive astrocytes secrete Icn2 to promote neuron death. Proc Natl Acad Sci U S A. 2013; 110(10): 4069–4074, doi: [10.1073/pnas.1218497110](https://doi.org/10.1073/pnas.1218497110), indexed in Pubmed: 23431168.
6. Cabrera-Aldana EE, Ruelas F, Aranda C, et al. Methylprednisolone administration following spinal cord injury reduces aquaporin 4 expression and exacerbates edema. Mediators Inflamm. 2017; 2017: 4792932, doi: [10.1155/2017/4792932](https://doi.org/10.1155/2017/4792932), indexed in Pubmed: 28572712.
7. Chen MH, Ren QX, Yang WF, et al. Influences of HIF-1 α on Bax/Bcl-2 and VEGF expressions in rats with spinal cord injury. Int J Clin Exp Pathol. 2013; 6(11): 2312–2322, indexed in Pubmed: 24228092.
8. Cho M. Focus on neurodegeneration. Nat Neurosci. 2010; 13(7): 787, doi: [10.1038/nn0710-787](https://doi.org/10.1038/nn0710-787), indexed in Pubmed: 20581813.
9. Christie SD, Comeau B, Myers T, et al. Duration of lipid peroxidation after acute spinal cord injury in rats and the effect of methylprednisolone. Neurosurg Focus. 2008; 25(5): E5, doi: [10.3171/FOC.2008.25.11.E5](https://doi.org/10.3171/FOC.2008.25.11.E5), indexed in Pubmed: 18980479.
10. del Rayo Garrido M, Silva-García R, García E, et al. Therapeutic window for combination therapy of A91 peptide and glutathione allows delayed treatment after spinal cord injury. Basic Clin Pharmacol Toxicol. 2013; 112(5): 314–318, doi: [10.1111/bcpt.12023](https://doi.org/10.1111/bcpt.12023), indexed in Pubmed: 23057752.
11. DeRuisseau LR, Recca DM, Mogle JA, et al. Metallothionein deficiency leads to soleus muscle contractile dysfunction following acute spinal cord injury in mice. Am J Physiol Regul Integr Comp Physiol. 2009; 297(6): R1795–R1802, doi: [10.1152/ajpregu.00263.2009](https://doi.org/10.1152/ajpregu.00263.2009), indexed in Pubmed: 19828842.
12. Fernández R, González P, Lage S, et al. Influence of the cation adducts in the analysis of matrix-assisted laser desorption ionization imaging mass spectrometry data from injury models of rat spinal cord. Anal Chem. 2017; 89(16): 8565–8573, doi: [10.1021/acs.analchem.7b02650](https://doi.org/10.1021/acs.analchem.7b02650), indexed in Pubmed: 28703574.
13. Fouad K, Tetzlaff W. Rehabilitative training and plasticity following spinal cord injury. Exp Neurol. 2012; 235(1): 91–99, doi: [10.1016/j.expneurol.2011.02.009](https://doi.org/10.1016/j.expneurol.2011.02.009).

14. Genovese T, Esposito E, Mazzon E, et al. Absence of endogenous interleukin-10 enhances secondary inflammatory process after spinal cord compression injury in mice. *J Neurochem*. 2009; 108(6): 1360–1372, doi: [10.1111/j.1471-4159.2009.05899.x](https://doi.org/10.1111/j.1471-4159.2009.05899.x), indexed in Pubmed: [19183262](https://pubmed.ncbi.nlm.nih.gov/19183262/).
15. Genovese T, Esposito E, Mazzon E, et al. Evidence for the role of mitogen-activated protein kinase signaling pathways in the development of spinal cord injury. *J Pharmacol Exp Ther*. 2008; 325(1): 100–114, doi: [10.1124/jpet.107.131060](https://doi.org/10.1124/jpet.107.131060), indexed in Pubmed: [18180375](https://pubmed.ncbi.nlm.nih.gov/18180375/).
16. Herrera JJ, Nestic O, Narayana PA. Reduced vascular endothelial growth factor expression in contusive spinal cord injury. *J Neurotrauma*. 2009; 26(7): 995–1003, doi: [10.1089/neu.2008.0779](https://doi.org/10.1089/neu.2008.0779), indexed in Pubmed: [19257807](https://pubmed.ncbi.nlm.nih.gov/19257807/).
17. Hillegass LM, Griswold DE, Brickson B, et al. Assessment of myeloperoxidase activity in whole rat kidney. *J Pharmacol Methods*. 1990; 24(4): 285–295, indexed in Pubmed: [1963456](https://pubmed.ncbi.nlm.nih.gov/1963456/).
18. Hoschouer EL, Yin FQ, Jakeman LB. L1 cell adhesion molecule is essential for the maintenance of hyperalgesia after spinal cord injury. *Exp Neurol*. 2009; 216(1): 22–34, doi: [10.1016/j.expneurol.2008.10.025](https://doi.org/10.1016/j.expneurol.2008.10.025), indexed in Pubmed: [19059398](https://pubmed.ncbi.nlm.nih.gov/19059398/).
19. Jaitak V, Kaul VK, Kumar N, et al. New hopane triterpenes and antioxidant constituents from *Potentilla fulgens*. *Nat Prod Commun*. 2010; 5(10): 1561–1566, indexed in Pubmed: [21121248](https://pubmed.ncbi.nlm.nih.gov/21121248/).
20. Jia YF, Gao HL, Ma LJ, et al. Effect of nimodipine on rat spinal cord injury. *Genet Mol Res*. 2015; 14(1): 1269–1276, doi: [10.4238/2015.February.13.5](https://doi.org/10.4238/2015.February.13.5), indexed in Pubmed: [25730065](https://pubmed.ncbi.nlm.nih.gov/25730065/).
21. Kanno H, Ozawa H, Sekiguchi A, et al. Spinal cord injury induces upregulation of Beclin 1 and promotes autophagic cell death. *Neurobiol Dis*. 2009; 33(2): 143–148, doi: [10.1016/j.nbd.2008.09.009](https://doi.org/10.1016/j.nbd.2008.09.009), indexed in Pubmed: [18948195](https://pubmed.ncbi.nlm.nih.gov/18948195/).
22. Kopach O, Medvediev V, Krotov V, et al. Opposite, bidirectional shifts in excitation and inhibition in specific types of dorsal horn interneurons are associated with spasticity and pain post-SCI. *Sci Rep*. 2017; 7(1): 5884, doi: [10.1038/s41598-017-06049-7](https://doi.org/10.1038/s41598-017-06049-7), indexed in Pubmed: [28724992](https://pubmed.ncbi.nlm.nih.gov/28724992/).
23. Koziel K, Smigelskaite J, Drasche A, et al. RAF and antioxidants prevent cell death induction after growth factor abrogation through regulation of Bcl-2 proteins. *Exp Cell Res*. 2013; 319(17): 2728–2738, doi: [10.1016/j.yexcr.2013.07.029](https://doi.org/10.1016/j.yexcr.2013.07.029), indexed in Pubmed: [23933517](https://pubmed.ncbi.nlm.nih.gov/23933517/).
24. Kundu A, Ghosh A, Singh NK, et al. Wound healing activity of the ethanol root extract and polyphenolic rich fraction from *Potentilla fulgens*. *Pharm Biol*. 2016; 54(11): 2383–2393, doi: [10.3109/13880209.2016.1157192](https://doi.org/10.3109/13880209.2016.1157192), indexed in Pubmed: [27043472](https://pubmed.ncbi.nlm.nih.gov/27043472/).
25. Liu Y, Figley S, Spratt SK, et al. An engineered transcription factor which activates VEGF-A enhances recovery after spinal cord injury. *Neurobiol Dis*. 2010; 37(2): 384–393, doi: [10.1016/j.nbd.2009.10.018](https://doi.org/10.1016/j.nbd.2009.10.018), indexed in Pubmed: [19879362](https://pubmed.ncbi.nlm.nih.gov/19879362/).
26. Ludwig PE, Patil AA, Chamczuk AJ, et al. Hormonal therapy in traumatic spinal cord injury. *Am J Transl Res*. 2017; 9(9): 3881–3895, indexed in Pubmed: [28979667](https://pubmed.ncbi.nlm.nih.gov/28979667/).
27. Moonen G, Satkunendrarajah K, Wilcox JT, et al. A new acute impact-compression lumbar spinal cord injury model in the rodent. *J Neurotrauma*. 2016; 33(3): 278–289, doi: [10.1089/neu.2015.3937](https://doi.org/10.1089/neu.2015.3937), indexed in Pubmed: [26414192](https://pubmed.ncbi.nlm.nih.gov/26414192/).
28. Müller MM, Middelantis J, Meier C, et al. 17 β -estradiol protects 7-day old rats from acute brain injury and reduces the number of apoptotic cells. *Reprod Sci*. 2013; 20(3): 253–261, doi: [10.1177/1933719112452471](https://doi.org/10.1177/1933719112452471), indexed in Pubmed: [22875845](https://pubmed.ncbi.nlm.nih.gov/22875845/).
29. Nestic O, Sundberg LM, Herrera JJ, et al. Vascular endothelial growth factor and spinal cord injury pain. *J Neurotrauma*. 2010; 27(10): 1793–1803, doi: [10.1089/neu.2010.1351](https://doi.org/10.1089/neu.2010.1351), indexed in Pubmed: [20698758](https://pubmed.ncbi.nlm.nih.gov/20698758/).
30. Özveren H, Irtegin S, Devci E, et al. Neuroprotective Effects of *Potentilla fulgens* on traumatic brain injury in rats. *Anal Quant Cytol Histol*. 2017; 39: 35–44.
31. Patel CB, Cohen DM, Ahobila-Vajjula P, et al. Effect of VEGF treatment on the blood-spinal cord barrier permeability in experimental spinal cord injury: dynamic contrast-enhanced magnetic resonance imaging. *J Neurotrauma*. 2009; 26(7): 1005–1016, doi: [10.1089/neu.2008.0860](https://doi.org/10.1089/neu.2008.0860), indexed in Pubmed: [19226205](https://pubmed.ncbi.nlm.nih.gov/19226205/).
32. Ray SK, Samntaray S, Banik NL. Future directions for using estrogen receptor agonists in the treatment of acute and chronic spinal cord injury. *Neural Regen Res*. 2016; 11(9): 1418–1419, doi: [10.4103/1673-5374.191212](https://doi.org/10.4103/1673-5374.191212), indexed in Pubmed: [27857741](https://pubmed.ncbi.nlm.nih.gov/27857741/).
33. Ren Yi, Young W. Managing inflammation after spinal cord injury through manipulation of macrophage function. *Neural Plast*. 2013; 2013: 945034, doi: [10.1155/2013/945034](https://doi.org/10.1155/2013/945034), indexed in Pubmed: [24288627](https://pubmed.ncbi.nlm.nih.gov/24288627/).
34. Savas M, Verit A, Ciftci H, et al. Oxidative Stress in BPH. *JNMA J Nepal Med Assoc*. 2009; 48(173): 41–45, indexed in Pubmed: [19529057](https://pubmed.ncbi.nlm.nih.gov/19529057/).
35. Shen LF, Cheng H, Tsai MC, et al. PAL31 may play an important role as inflammatory modulator in the repair process of the spinal cord injury rat. *J Neurochem*. 2009; 108(5): 1187–1197, doi: [10.1111/j.1471-4159.2008.05865.x](https://doi.org/10.1111/j.1471-4159.2008.05865.x), indexed in Pubmed: [19141070](https://pubmed.ncbi.nlm.nih.gov/19141070/).
36. Silva NA, Sousa N, Reis RL, et al. From basics to clinical: a comprehensive review on spinal cord injury. *Prog Neurobiol*. 2014; 114: 25–57, doi: [10.1016/j.pneurobio.2013.11.002](https://doi.org/10.1016/j.pneurobio.2013.11.002), indexed in Pubmed: [24269804](https://pubmed.ncbi.nlm.nih.gov/24269804/).
37. Sinescu C, Popa F, Grigorean VT, et al. Molecular basis of vascular events following spinal cord injury. *J Med Life*. 2010; 3(3): 254–261, indexed in Pubmed: [20945816](https://pubmed.ncbi.nlm.nih.gov/20945816/).
38. Song Z, Xu S, Song B, et al. Bcl-2-associated athanogene 2 prevents the neurotoxicity of MPP+ via interaction with DJ-1. *J Mol Neurosci*. 2015; 55(3): 798–802, doi: [10.1007/s12031-014-0481-6](https://doi.org/10.1007/s12031-014-0481-6), indexed in Pubmed: [25600833](https://pubmed.ncbi.nlm.nih.gov/25600833/).
39. Sun T, Liu B, Li P. Nerve protective effect of asiaticoside against ischemia-hypoxia in cultured rat cortex neurons. *Med Sci Monit*. 2015; 21: 3036–3041, doi: [10.12659/MSM.894024](https://doi.org/10.12659/MSM.894024), indexed in Pubmed: [26447863](https://pubmed.ncbi.nlm.nih.gov/26447863/).
40. Syiem D, Khup PZ, Syiem AB. Effects of *Potentilla fulgens* Linn. on carbohydrate and lipid profiles in diabetic mice. *Pharmacologyonline*. 2009; 2: 787–795.
41. Tas M, Gok E, Ekinci C, et al. Investigation of Various Events Occurring in the Brain Tissue After Calvarial Defects in Rats. *Int J Morphol*. 2016; 34(1): 29–33, doi: [10.4067/s0717-95022016000100005](https://doi.org/10.4067/s0717-95022016000100005).
42. Toklu HZ, Hakan T, Celik H, et al. Neuroprotective effects of alpha-lipoic acid in experimental spinal cord injury in rats. *J Spinal Cord Med*. 2010; 33(4): 401–409, indexed in Pubmed: [21061900](https://pubmed.ncbi.nlm.nih.gov/21061900/).
43. Tu WZ, Chen WC, Xia W, et al. The regulatory effect of electro-acupuncture on the expression of NMDA receptors in a SCI rat model. *Life Sci*. 2017; 177: 8–14, doi: [10.1016/j.lfs.2017.04.004](https://doi.org/10.1016/j.lfs.2017.04.004), indexed in Pubmed: [28392262](https://pubmed.ncbi.nlm.nih.gov/28392262/).
44. Wu Y, Yang L, Mei X, et al. Selective inhibition of STAT1 reduces spinal cord injury in mice. *Neurosci Lett*. 2014; 580: 7–11, doi: [10.1016/j.neulet.2013.11.055](https://doi.org/10.1016/j.neulet.2013.11.055), indexed in Pubmed: [24321405](https://pubmed.ncbi.nlm.nih.gov/24321405/).
45. Yu YQ, Hu NC, Duan JA, et al. Neuroprotective effects of sufentanil preconditioning on spinal cord injury in mouse models. *J Tissue Eng*. 2016; 20: 5966–5972.