

REVIEW

New dimensions in endodontic imaging: Part 1. Conventional and alternative radiographic systems

S. Patel^{1,2}, A. Dawood², E. Whaites³ & T. Pitt Ford^{1†}

¹Endodontic Postgraduate Unit, King's College London Dental Institute, London, UK; ²Specialist Practice, London, UK; and ³Department of Dental Radiology, King's College London Dental Institute, London, UK

Abstract

Patel S, Dawood A, Whaites E, Pitt Ford T. New dimensions in endodontic imaging: Part 1. Conventional and alternative radiographic systems. *International Endodontic Journal*, **42**, 447–462, 2009.

Conventional radiographs used for the management of endodontic problems yield limited information because of the two-dimensional nature of images produced, geometric distortion and anatomical noise. These factors often act in combination. This review paper assesses the limitations of periapical radiographs and

seeks to clarify three-dimensional imaging techniques that have been suggested as adjuncts to conventional radiographs. These include tuned aperture computed tomography, magnetic resonance imaging, ultrasound, computed tomography and cone beam computed tomography (CBCT). Of these techniques, CBCT appears to be an effective and safe way to overcome some of the problems associated with conventional radiographs.

Keywords: dental imaging, dental radiography, management of endodontic problems.

Received 6 July 2008; accepted 1 December 2008

Introduction

Radiographic examination is an essential component of endodontic management (Forsberg 1987a,b), underpinning aspects of diagnosis, treatment planning, intra-operative control and outcome assessment. Intra-oral periapical radiographs are still most commonly exposed during endodontic procedures (Walker & Brown 2005, Glickman & Pettiette 2006), providing useful information for the presence and location of periradicular lesions, root canal anatomy (Fig. 1) and the proximity of adjacent anatomical structures.

Despite their widespread use, periapical images yield limited information. The aim of this paper was to review these limitations before assessing alternative imaging techniques, which have potential to overcome some of these problems.

Limitations of conventional radiography for endodontic diagnosis

Conventional images, whether captured on X-ray film or digital sensors yield limited information for several reasons.

Compression of three-dimensional anatomy

Conventional images compress three-dimensional anatomy into a two-dimensional image or shadowgraph, greatly limiting diagnostic performance (Webber & Messura 1999, Nance *et al.* 2000, Cohenca *et al.* 2007). Important features of the tooth and its surrounding tissues are visualized in the mesio-distal (proximal) plane only. Similar features presenting in the bucco-lingual plane (i.e. the third dimension) may not be fully appreciated.

The spatial relationship of the root(s) to their surrounding anatomical structures and associated periradicular lesions cannot always be truly assessed with conventional radiographs (Cotti *et al.* 1999, Cotti & Campisi 2004). In addition, the location, nature and

Correspondence: Shanon Patel, Specialist Endodontist, 45 Wimpole Street, London W1G 8SB, UK (e-mail: shanonpatel@hotmail.com).

†Professor Tom Pitt Ford passed away in August 2008.

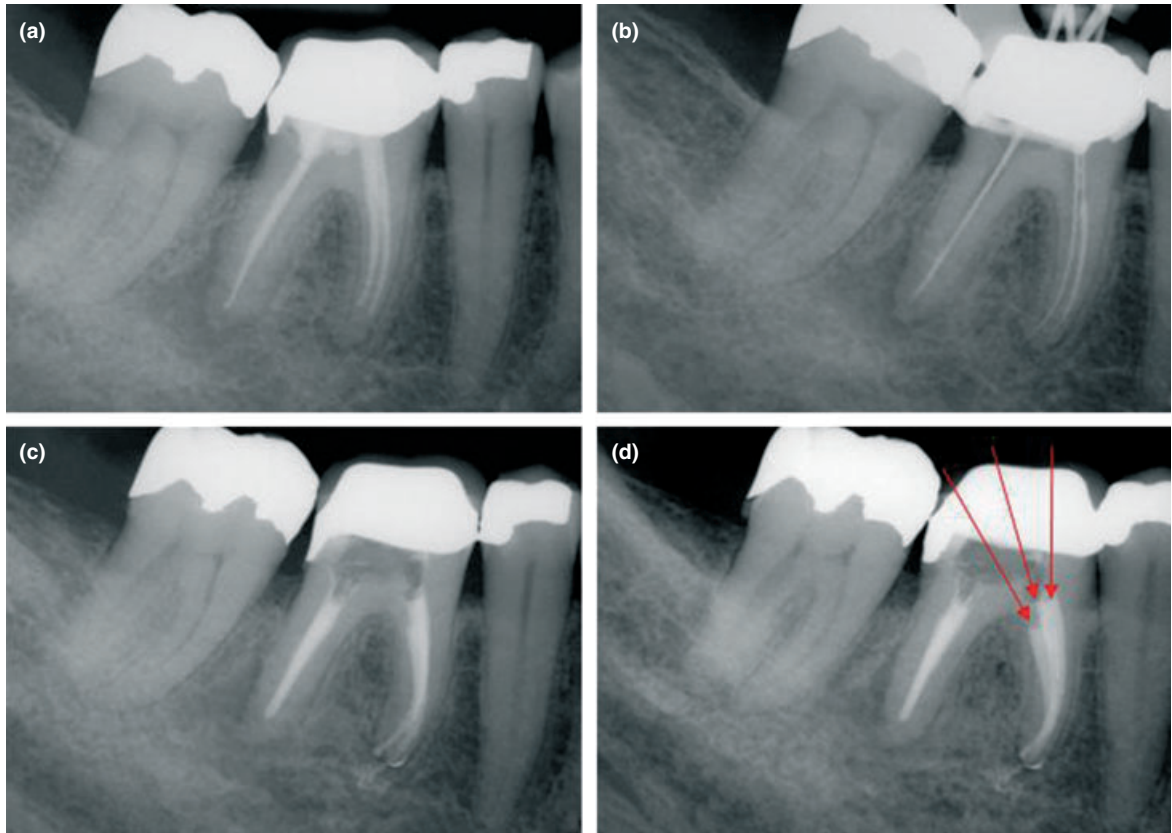


Figure 1 Periapical radiographs of a root-treated mandibular right first molar with persistent symptoms. (a) Pre-treatment radiograph reveal three well-obturated (two mesial and one distal) canals, (b) working length radiograph, (c, d) post-treatment radiograph, note that two additional (mid-mesial and disto-lingual) canals have been identified and treated, arrows indicate the canal entrance of each of the three mesial canals. These additional canals were not identified on the pre-treatment radiograph or in (c).

shape of structures within the root under investigation (for example, root resorption) may be difficult to assess (Fig. 2) (Cohenca *et al.* 2007, Patel *et al.* 2007, Whaites 2007a,b). Diagnostic information in this missing 'third dimension' is of particular relevance in surgical planning (Velvart *et al.* 2001, Low *et al.* 2008), where the angulation of the root to the cortical plate, the thickness of the cortical plate and the relationship of the root to key adjacent anatomical structures such as the inferior alveolar nerve, mental foramen (Fig. 3) or maxillary sinus should be understood.

In an attempt to overcome the limitations of plain radiography, additional exposures with 10–15 degree (Fig. 4) changes in horizontal tubehead angulation (parallax principle) may be considered (Glickman & Pettiette 2006, Patel & Pitt Ford 2007, Whaites 2007a). Several intra-oral views taken at different angles may be necessary for diagnosing traumatic dental injuries (for example, root fractures, luxations and avulsion injuries)

(Flores *et al.* 2007a,b). Brynolf's classic study found 3–4 parallax radiographs of the area of interest resulted in a better perception of depth and spatial relationship of periapical lesions associated with root apices (Brynolf 1967). The parallax principle may also separate roots which are in the same plane as the X-ray beam (Fig. 5), for example, identifying the presence of a second mesio-buccal canal in maxillary molars (Glickman & Pettiette 2006, Manogue *et al.* 2005). However, it should be noted that multiple intra-oral radiographs do not guarantee the identification of all relevant anatomy or disease (Barton *et al.* 2003, Matherne *et al.* 2008), and may not reveal much more than a single exposure.

The observer's knowledge of the anatomy being assessed and their experience of interpreting radiographs taken from different views help them visualize the area being assessed three-dimensionally. However, this mental three-dimensional picture may not be a true reflection of the anatomy being assessed.

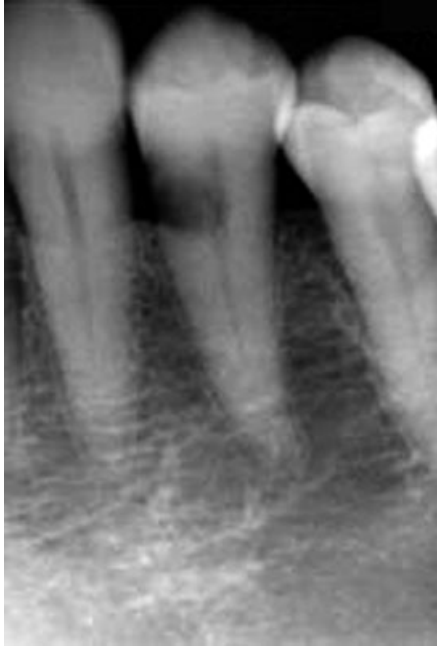

Figure 2 Conventional periapical radiograph of an external cervical resorption defect associated with the mandibular left first premolar tooth. Has this resorptive lesion perforated the root canal? The depth of this lesion cannot be determined from conventional periapical radiographs.

Geometric distortion

Because of the complexity of the maxillo-facial skeleton, radiographic images do not always accurately replicate the anatomy being assessed (Gröndahl & Huumonen

2004). Ideally, radiographs should be taken with a paralleling technique rather than the bisecting technique as it produces more geometrically accurate images (Vande Voorde & Bjorndahl 1969, Forsberg & Halse 1994). A series of investigations by Forsberg (1987a,b,c) concluded that the paralleling technique was more accurate than the bisecting angle technique for accurately and consistently reproducing apical anatomy (Fig. 6).

For accurate reproduction of anatomy, the image receptor (X-ray film or digital sensor) must be parallel to the long axis of the tooth, and the X-ray beam should be perpendicular to the image receptor and the tooth being assessed. This is usually possible in the mandibular molar region where the floor of the mouth comfortably accommodates the image receptor (Walker & Brown 2005), although there may be compromises in patients with small mouths, gagging or poor tolerance to the receptor. In the maxilla, a shallow palatal vault (Fig. 7) may also prevent ideal positioning of the intra-oral image receptor even when using a beam-aiming device. This lack of long-axis orientation results in geometric distortion (poor projection geometry) of the radiographic image. The ideal positioning of solid-state digital sensors may be even more challenging as a result of their rigidity and bulk compared with conventional X-ray films and phosphor plate digital sensors (Wenzel 2006, Whaites 2007a). Over-angulated or under-angulated radiographs (bisecting or paralleling technique) may reduce or increase respectively the radiographic root length of the tooth under investigation (White & Pharaoh 2004, Whaites

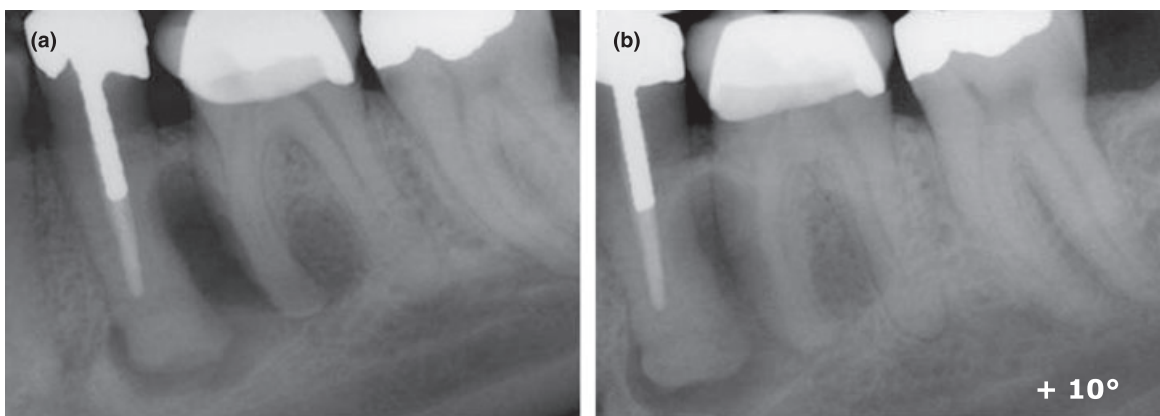


Figure 3 Conventional periapical radiographs taken with the parallax technique of a mandibular left premolar and molar teeth with a large radiolucent lesion. From the radiographs, it is not possible to determine the depth of the endodontic lesion, i.e. has it perforated the lingual cortex and is there a second untreated canal?

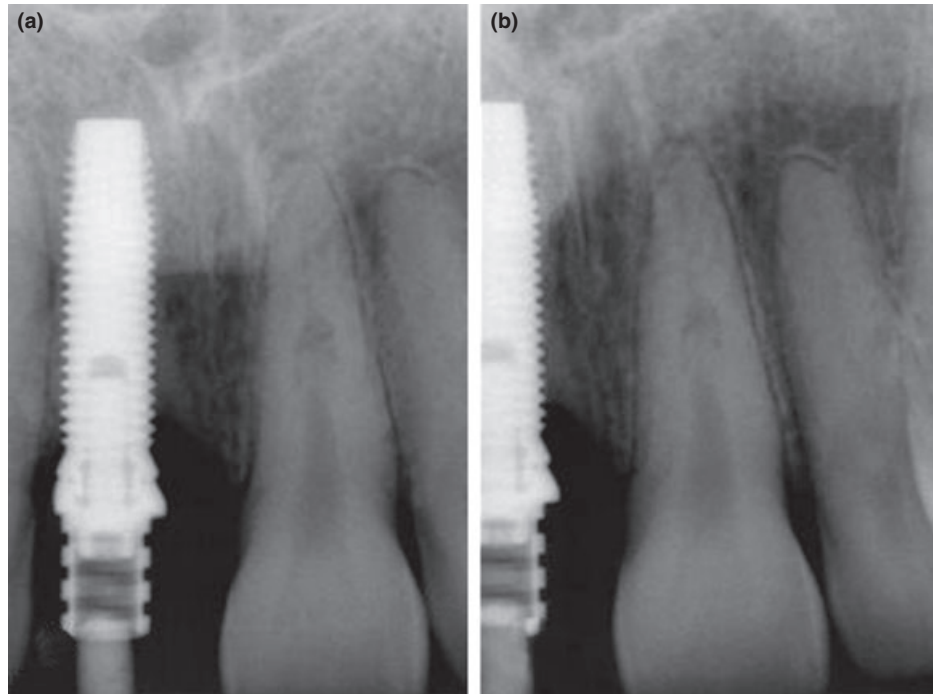


Figure 4 Conventional periapical radiographs taken using the parallax technique of the maxillary left central incisor tooth reveal that the lesion in the mid-third of root canal remains centred confirming that it is internal rather than external cervical resorption. The maxillary right crown incisor has been replaced with an implant-retained crown.

2007a), and increase or decrease the size (Fig. 5) or even result in the disappearance of periradicular lesions (Bender & Seltzer 1961, Huuononen & Ørstavik 2002). In ideal conditions when a 'textbook' parallelising technique radiograph can be exposed, the operator must anticipate a small degree (approximately 5%) of magnification in the final image (Vande Voorde & Bjorndahl 1969, Forsberg & Halse 1994). This magnification is caused by the object (i.e. tooth) and the image receptor being slightly separated (more so in the maxilla) and the X-ray beam being slightly divergent. The use of a long focus-to-skin distance may limit, but will not eliminate this magnification (Whaites 2007a).

Positioning the image receptor parallel to the long axis of the tooth may be possible with teeth that have relatively straight roots (e.g. incisors and premolar teeth). However, it is not uncommon for multi-rooted teeth to have divergent or convergent root anatomy. In these situations, it is impossible to eliminate completely some degree of geometric distortion and magnification. The net result is that diverging roots will not be displayed accurately in a single exposure because of varying degrees of distortion. This is particularly

relevant in the posterior maxilla (Lofthag-Hansen *et al.* 2007).

Anatomical noise

Anatomical features may obscure the area of interest, resulting in difficulty in interpreting radiographic images (Revesz *et al.* 1974, Kundel & Revesz 1976, Gröndahl & Huuononen 2004). These anatomical features are referred to as anatomical, structured or background noise and may be radiopaque (for example zygomatic buttress) or radiolucent (for example incisive foramen, maxillary sinus). The more complex the anatomical noise, the greater the reduction in contrast within the area of interest (Morgan 1965, Revesz *et al.* 1974, Kundel & Revesz 1976) with the result that the radiographic image may be more difficult to interpret.

The problem of anatomical noise in endodontics was first observed by Brynolf (1967, 1970), who noted that the projection of the incisive canal over the apices of maxillary incisors may complicate radiographic interpretation. Several studies (Bender & Seltzer 1961, Schwartz & Foster 1971) have concluded that periapical

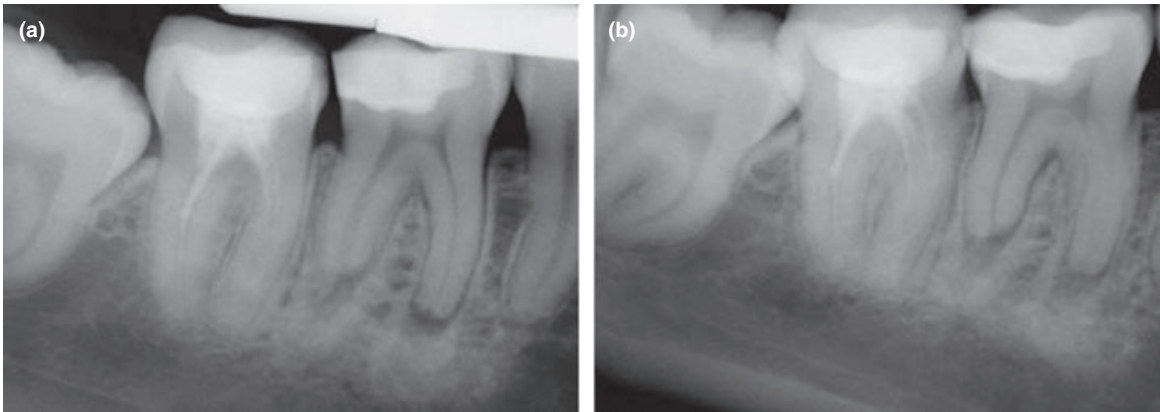


Figure 5 Two mesial canals are distinguishable in the mandibular right first molar using two radiographs taken with the parallax technique, also note how the periapical radiolucent lesions change in size and radio-opacity with a change of angulation of the X-ray tube head.

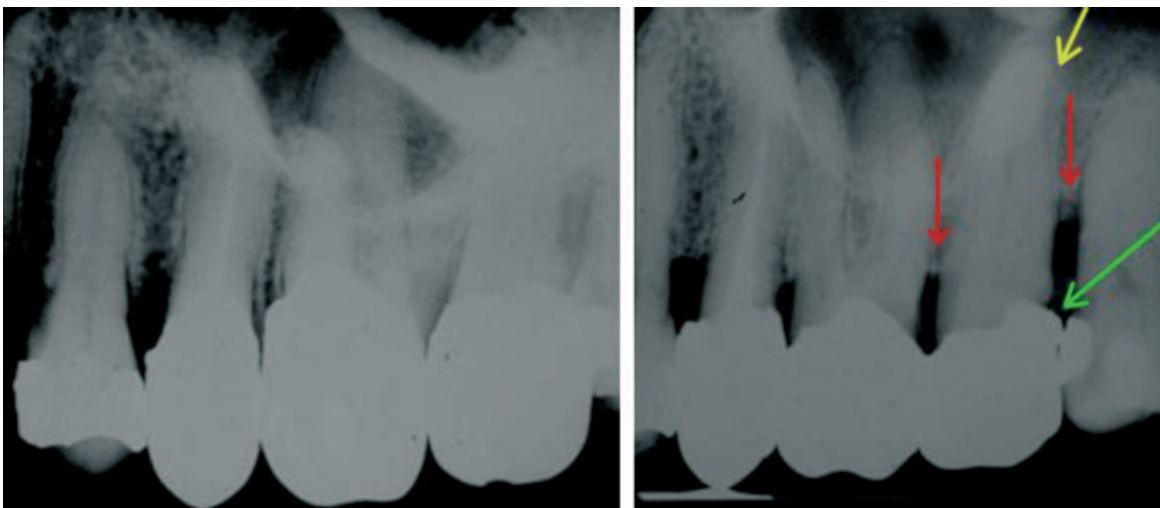


Figure 6 (a) Radiograph taken using the bisecting angle technique and (b) paralleling technique of the same patient. Note the difference in the appearance of the periapical region (yellow arrow), the difference in alveolar bone height (red arrow) and appearance of the restoration (green arrow). Based on Fig. 10.32 in *Essentials in Dental Radiology and Radiography*, 4th edn: Churchill Livingstone Elsevier.

lesions, which are confined to the cancellous bone are not easily visualized on radiographs. This is another example of anatomical noise, the area of interest being masked by the denser overlying cortical plate. Lee & Messer (1986) suggested that periapical lesions may be successfully detected when confined to cancellous bone, provided the cortical bone was thin and the anatomical noise minimal. Such lesions may go undetected beneath a thicker cortex. Anatomical noise also accounts for some under-estimation of periapical lesion size on radiographic images (Bender & Seltzer 1961, Schwartz & Foster 1971, Shoha *et al.* 1974, Marmary *et al.* 1999,

Scarfe *et al.* 1999). Receiver operating characteristic curve analysis has been suggested as an appropriate statistical approach to assess the diagnostic accuracy of imaging systems in detecting periapical lesions (Kullendorf & Nilsson 1996, Kullendorf *et al.* 1996, Paurazas *et al.* 2000). Paurazas *et al.* (2000) concluded that separately prepared artificial periapical lesions within cortical bone were more accurately detected than equivalent-sized lesions confined to the cancellous bone. There was also an increased likelihood of detecting periapical lesions in both groups (cortical and cancellous bone) as the size of the lesion increased.

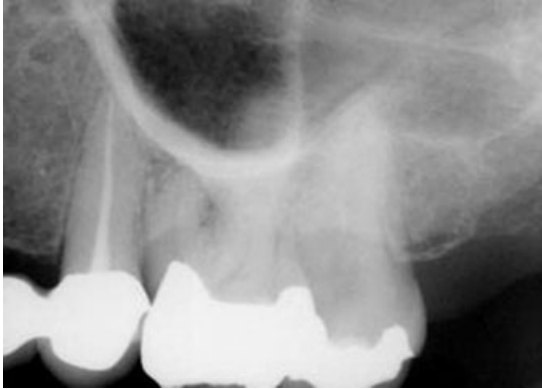

Figure 7 Even with the best techniques it may not be possible to obtain an accurate radiograph of the maxillary teeth using a paralleling technique. In this case, the palatal vault is not high enough to allow the digital sensor to lie parallel to the long axis of the tooth resulting in distortion of the image even though a beam-aiming device has been used.

The complexity of the anatomy of the maxillary molar region (Fig. 8) may partially explain why Goldman *et al.* (1972) found that the greatest amount of disagreement between examiners for detecting periapical lesions occurred in this region. Additional radiographs may once again be exposed in an attempt to overcome anatomical noise and visualize endodontic lesions more clearly (Huomonen & Ørstavik 2002).

Anatomical noise is dependent on several factors, including: overlying anatomy, the thickness of the cancellous bone and cortical plate and finally the relationship of the root apices to the cortical plate.

Brynolf (1967) compared the radiographic and histological appearance of 292 maxillary incisor teeth to assess whether there was a relationship between the radiographic and histological features of the periapical lesions. Overall, there was a high correlation between radiographic and histological findings, a conclusion that may have been related to the low anatomical noise in the area being assessed. The root apices of maxillary incisors lie very close to the adjacent cortical plate and therefore erosion of the cortical plate probably occurs very soon after periapical inflammation develops. In other areas of the jaws where there is more anatomical noise (e.g. the posterior mandible with its thicker cortical plate), the relationship between histological features and radiographic appearances may be less clear (Pitt Ford 1984).

Temporal perspective

Radiographic images represent a 'snapshot' in time of the area being assessed (Horner *et al.* 2002). To assess the outcome of endodontic treatment, radiographs exposed at different points in time should be compared (Friedman 2002). Pre-treatment, post-treatment and follow-up radiographs should be standardized with respect to their radiation geometry, density and contrast to allow reliable interpretation of any changes which may have occurred in the periapical tissues as a result of treatment (Gröndahl & Huomonen 2004). Poorly standardized radiographs may lead to under- or over-estimation of the degree of healing or failure (Fig. 9).

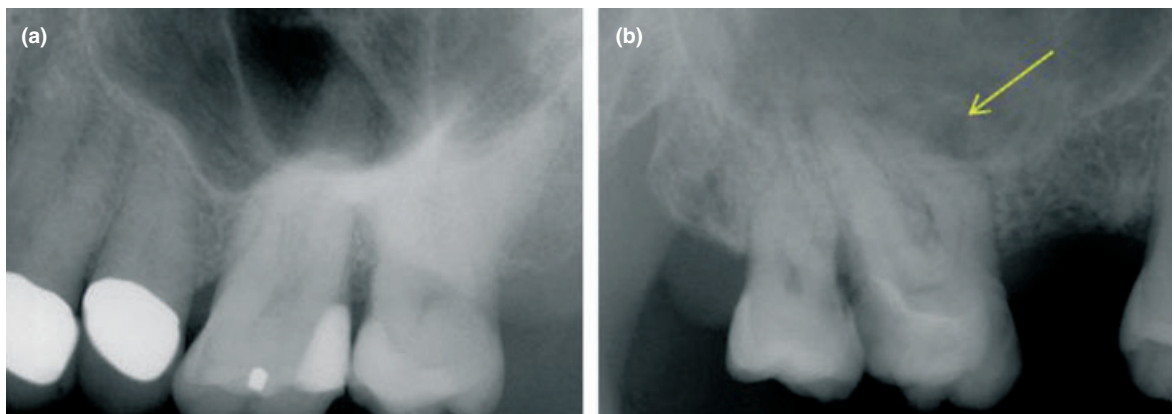


Figure 8 (a) The zygomatic arch is obscuring the apical anatomy of the maxillary molar teeth, (b) the radiolucent lesion (yellow arrow) on the mesial aspect of the mesio-buccal root may be difficult to accurately assess as it is superimposed over the radiolucent maxillary sinus.

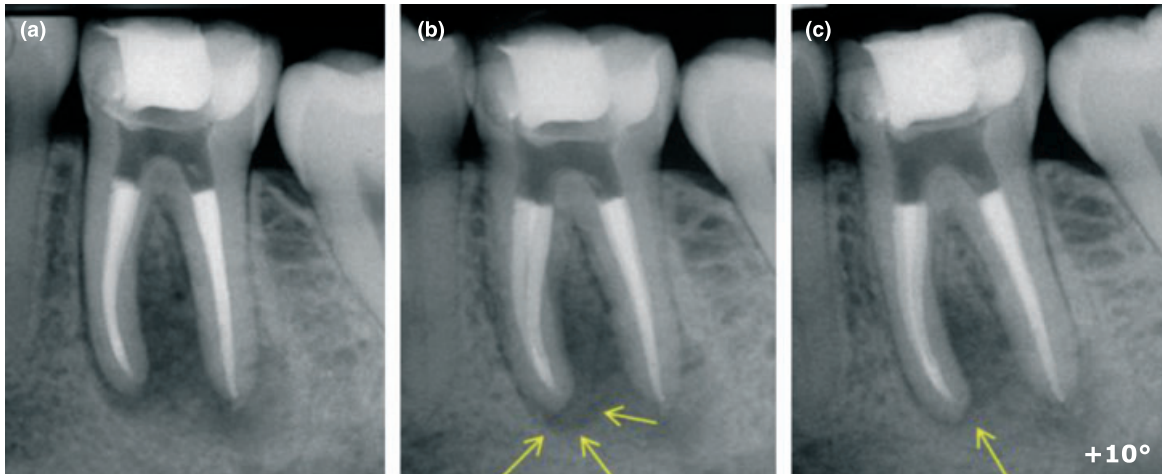


Figure 9 (a) This mandibular left molar tooth immediately after completion of root canal treatment, (b) the tooth is reviewed 6 months later, there appears to be no change in the size of the periapical radiolucencies, (c) if the angle of the X-ray tube head is changed by 10° there are definite signs of periapical healing.

Customized stents have been used to increase the reproducibility of radiation geometry when using paralleling technique. Elastomeric impression material is placed onto the bite block of the paralleling device, which is then positioned in the most favourable position and the patient asked to bite on it until it sets (Duckworth *et al.* 1983, Rudolph & White 1988). The same bite block may then be used for subsequent radiographs to ensure that the X-ray film, tooth and X-ray beam are consistently aligned. Even with these techniques, serial radiographs will still show small inconsistencies (Rudolph & White 1988). Stents may not be helpful in children and adolescent patients with developing dentitions and maxillo-facial skeletons.

Advanced radiographic techniques for endodontic diagnosis

Alternative imaging techniques have been suggested to overcome the limitations of intra-oral radiographs (Cotti & Campisi 2004, Nair & Nair 2007, Patel *et al.* 2007). In endodontics, some of these techniques may improve the diagnostic yield and assist clinical management.

Tuned aperture computed tomography (TACT)

Tuned aperture computed tomography works on the basis of tomosynthesis (Webber & Messura 1999). A series of 8–10 radiographic images are exposed at

different projection geometries using a programmable imaging unit, with specialized software to reconstruct a three-dimensional data set which may be viewed slice by slice (Fig. 10).

Claimed advantages of TACT over conventional radiographic techniques is that the images produced have less superimposition of anatomical noise over the area of interest (Webber *et al.* 1996, Tyndall *et al.* 1997). The overall radiation dose of TACT is no greater than 1–2 times that of a conventional periapical X-ray film as the total exposure dose is divided amongst the series of exposures taken with TACT (Nair *et al.* 1998, Nance *et al.* 2000). Additional advantages claimed for this technique include the absence of artefacts resulting from radiation interaction with metallic restorations (see later section on Computed tomography). The resolution is reported to be comparable with two-dimensional radiographs (Nair & Nair 2007).

Webber & Messura (1999) compared TACT with conventional radiographic techniques in assessing patients who required minor oral surgery. They concluded that TACT was 'more diagnostically informative and had more impact on potential treatment options than conventional radiographs'. Nance *et al.* (2000) compared TACT with conventional radiographic film to identify root canals in extracted mandibular and maxillary human molar teeth. With TACT, 36% of second mesio-buccal (MB2) canals were detected in maxillary molar teeth and 80% of third (mesio-lingual) canals were detected in mandibular molars. None of

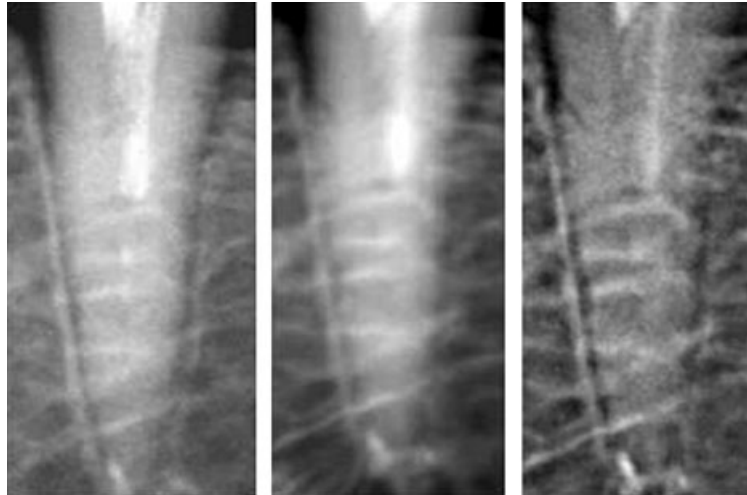

Figure 10 An oblique root fracture 2–3 mm below the marginal bone crest (left tooth surface) in a regular two-dimensional image (left) and in two versions of tuned aperture computed tomography images (middle and right images) [from Nair M. in Gröndahl & Huuonen (2004)].

these were detected on conventional X-ray films. The poor results with conventional radiography may have been partly because of the fact that parallax views were not taken. However, Barton *et al.* (2003) concluded that TACT did not significantly improve the detection rate of MB2 canals in maxillary first molar teeth when compared with two conventional radiographs taken using the parallax principle. The detection rate of MB2 canals using either technique was approximately 40%; the true incidence of MB2 canals was confirmed with the aid of a dental operating microscope to be much higher at 85%. It may be concluded that the complex nature of the adjacent anatomy around posterior maxillary molar teeth limits the use of TACT.

Recently, studies have concluded that TACT is suitable for detecting vertical root fractures (Nair *et al.* 2001, 2003). In one of these studies (Nair *et al.* 2001), oblique/vertical root fractures were induced in the mid-third of endodontically treated mandibular single-rooted extracted teeth. These teeth were then radiographed using TACT and conventional digital sensors. It was concluded that the diagnostic accuracy of TACT was superior to conventional two-dimensional radiography for the detection of vertical root fractures. However, these results should be viewed with caution as these artificially created fractures may have been confirmed from a basic clinical examination.

Tuned aperture computed tomography appears to be a promising radiographic technique for the future. However, at present it is still only a research tool

(Nair & Nair 2007), and has mostly been evaluated *ex-vivo*.

Magnetic resonance imaging (MRI)

An MRI scan is a specialized imaging technique which does not use ionizing radiation (Fig. 11). It involves the behaviour of hydrogen atoms (consisting of one proton and one electron) within a magnetic field which is used to create the MR image. The patient's hydrogen protons normally spin on their axis. The patient is placed within a strong magnetic field, which aligns the protons contained within hydrogen atoms along the long axis of the magnetic field and the patient's body. A pulsed beam of radio waves which has a similar frequency to the patient's spinning hydrogen atoms is then transmitted perpendicular to the magnetic field. This knocks the protons out of alignment, resulting in the hydrogen protons precessing like tiny gyroscopes, moving from a longitudinal to a transverse plane. The atoms behave like several mini bar-magnets, spinning synchronously with each other. This generates a faint radio-signal (resonance) which is detected by the receiver within the scanner. Similar radio-signals are detected as the hydrogen protons relax and return to their original (longitudinal) direction. The receiver information is processed by a computer, and an image is produced (White & Pharaoh 2004, Whaites 2007b).

The main dental applications of MRI to date have been the investigation of soft-tissue lesions in salivary

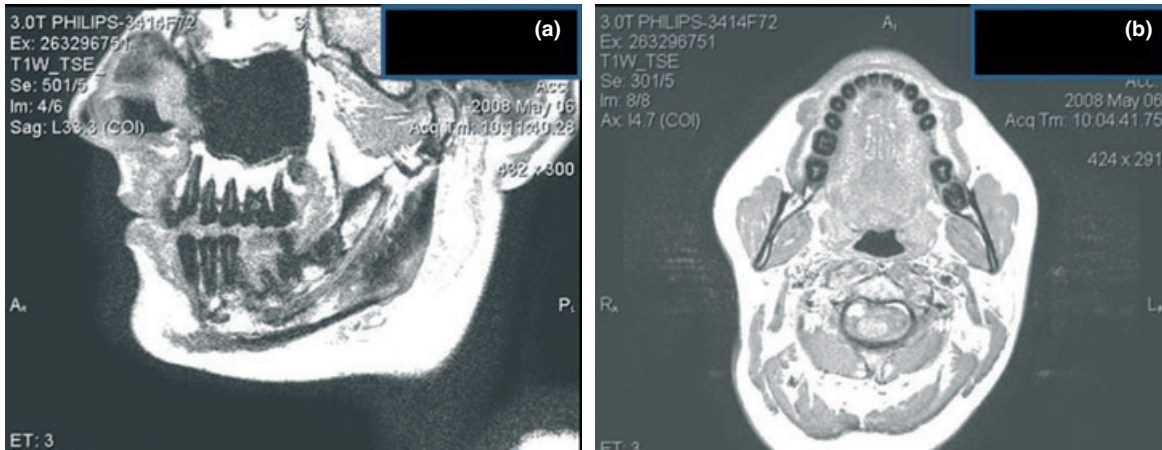


Figure 11 (a) A sagittal MRI scan of the head. Bone and teeth do not give a signal and therefore appear dark. The root canals can be clearly visualized, as can the maxillary root apices relationship to the maxillary sinus. (b) An axial MRI scan, the soft tissues can be clearly identified. Courtesy of Dr Crawford Gray, Aberdeen, UK.

glands, investigation of the temporomandibular joint and tumour staging (Goto *et al.* 2007, Whaites 2007b). MRI has also been used for treatment planning dental implant placement (Imamura *et al.* 2004, Monsour & Dhudia 2008). Recently, Tutton & Goddard (2002) performed MRI on a series of patients with dental disease. They were able to differentiate the roots of multi-rooted teeth; smaller branches of the neurovascular bundle could be clearly identified entering apical foramina. The authors also claimed that the nature of periapical lesions could be determined as well as the presence, absence and/or thickening of the cortical bone. Goto *et al.* (2007) compared measurements taken from three-dimensional reconstructed MRI and CT images of a dry mandible and hemi-mandible. They concluded that the accuracy of MRI was similar to CT. MRI scans are not affected by artefacts caused by metallic restorations (for example amalgam, metallic extracoronary restorations and implants) which can be a major problem with CT technology (Eggars *et al.* 2005). Cotti & Campisi (2004) suggested that MRI may be useful to assess the nature of endodontic lesions and for planning periapical surgery.

Magnetic resonance imaging has several drawbacks. These include: poor resolution compared with simple radiographs and long scanning times, in addition to great hardware costs and limited access only in dedicated radiology units. Different types of hard tissue (for example enamel and dentine) cannot be differentiated from one another or from metallic objects; they all appear radiolucent. It is for these reasons that MRI is

of limited use for the management of endodontic disease.

Ultrasound (US)

Ultrasound is based on the reflection (echoes) of US waves at the interface between tissues which have different acoustic properties (Gundappa *et al.* 2006). Ultrasonic waves are created by the piezoelectric effect within a transducer (probe). The US beam of energy is emitted and reflected back to the same probe (i.e. the probe acts as both the emitter and detector). The echoes are detected by a transducer which converts them into an electrical signal, from which a real-time black, white and shades of grey echo picture is produced on a computer screen (White & Pharaoh 2004). As the probe is moved over the area of interest, a new image is generated. Up to 50 images can be created per second, resulting in moving images on the screen (Cotti *et al.* 2002). The intensity or strength of the detected echoes is dependent on the difference between the acoustic properties of two adjacent tissues (Fig. 12). The greater the difference between tissues, the greater the difference in the reflected US energy and the higher the echo intensity. Tissue interfaces which generate a high echo intensity are described as hyperechoic (e.g. bone and teeth), whereas anechoic (e.g. cysts) describes areas of tissues which do not reflect US energy. Typically, the images seen consist of varying degrees of hyperechoic and anechoic areas as the areas of interest usually have a heterogeneous profile. The Doppler effect (the change of frequency of sound reflected from a moving source)

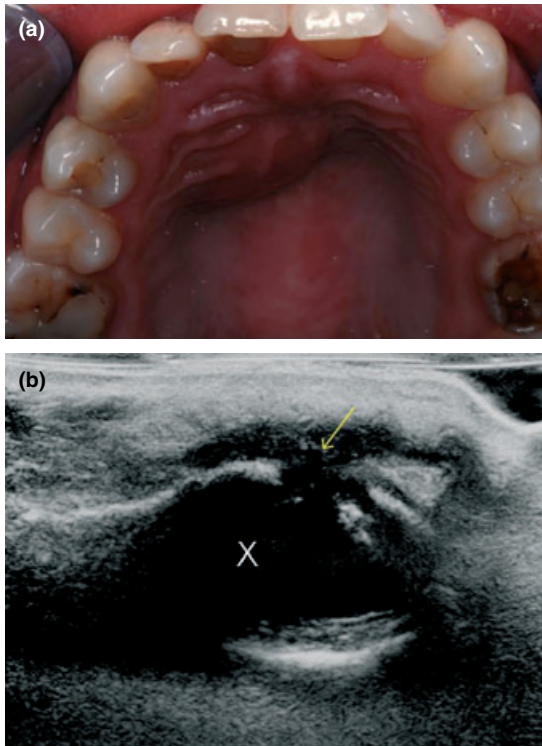


Figure 12 (a) Palatal view of a patient with a 20 mm diameter rubbery swelling. (b) Ultrasound image of the upper left maxillary incisor region, clearly showing a perforation of the labial cortical plate (yellow arrow) and a hypoechoic (dark) region (marked 'X') representing the palatal swelling.

can be used to detect the arterial and venous blood flow (Whaites 2007b).

Cotti *et al.* (2003) used US to assess if it was possible to differentially diagnose periapical lesions. Eleven periapical lesions of endodontic origin were examined with US imaging, a provisional diagnosis was determined according to the echo picture (hyperechoic and hypoechoic) and evidence of vascularity within the lesion was determined using the colour laser Doppler effect. The provisional diagnosis (seven cysts and four granulomas) determined by US was confirmed to be correct histologically in all 11 cases. Gundappa *et al.* (2006) repeated the Cotti *et al.* (2003) study and also concluded that US was a reliable diagnostic technique for determining the pathological nature (granuloma versus cysts) of periapical lesions. However, in neither study were the apical biopsies removed *in-toto* with the root apex [Cotti E. (2008), personal communication] therefore making it impossible to confirm whether a cystic appearing lesion was a true or pocket cyst. In

addition, the lesions were not serially sectioned making accurate histological diagnosis impossible (Nair *et al.* 1996). The ability of US to assess the true nature and type (for example true versus pocket cyst) of periapical lesions is doubtful.

Ultrasound is blocked by bone and is therefore useful only for assessing the extent of periapical lesions where there is little or no overlying cortical bone. Whilst US may be used with relative ease in the anterior region of the mouth, the positioning the probe is more difficult against the buccal mucosa of posterior teeth. In addition, the interpretation of US images is usually limited to radiologists who have had extensive training in the use and interpretation of US images.

Computed tomography (CT)

Computed tomography is an imaging technique which produces three-dimensional images of an object by taking a series of two-dimensional sectional X-ray images. Essentially, CT scanners consist of a gantry which contains the rotating X-ray tubehead and reciprocal detectors. In the centre of the gantry, there is a circular aperture, through which the patient is advanced. The tubehead and reciprocal detectors within the gantry either rotate synchronously around the patient, or the detectors take the form of a continuous ring around the patient and only the X-ray source moves within the gantry. The data from the detectors produce an attenuation profile of the particular slice of the body being examined. The patient is then moved slightly further into the gantry for the next slice data to be acquired. The process is repeated until the area of interest has been scanned fully (Fig. 13).

Early generations of the CT scanner acquired 'data' in the axial plane by scanning the patient 'slice by slice' using a narrow collimated fan shaped X-ray beam passing through the patient to a single array of reciprocal detectors. The detectors measured the intensity of X-rays emerging from the patient. Over the last three decades, there have been considerable advances in CT technology. Current CT scanners are called multi-slice CT (MSCT) scanners and have a linear array of multiple detectors, allowing 'multiple slices' to be taken simultaneously, as the X-ray source and detectors within the gantry rotate around the patient who is simultaneously advanced through the gantry. This results in faster scan times and therefore a reduced radiation exposure to the patient (Sukovic 2003, White & Pharaoh 2004). The slices of data are then 'stacked'

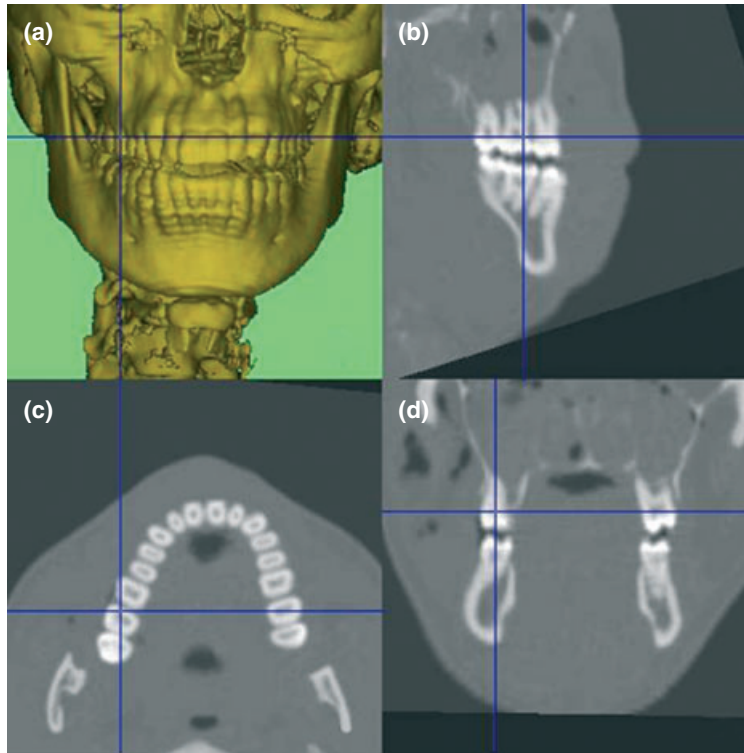


Figure 13 (a) Reconstructed three-dimensional CT image, (b–d) sagittal, axial and coronal reconstructed slices from a CT scan.

and reformatted to obtain three-dimensional images and multiplanar images which can be viewed in any plane the operator chooses (for example axial, coronal or sagittal) without having to expose the patient to further radiation. The interval between each slice may also be varied; closely approximated slices will give better spatial resolution, but will result in an increased radiation dose to the patient.

In addition to three-dimensional images, CT has several other advantages over conventional radiography. These include the elimination of anatomical noise and high contrast resolution, allowing differentiation of tissues with less than 1% physical density difference to be distinguished compared with a 10% difference in physical difference which is required with conventional radiography (White & Pharaoh 2004).

Computed tomography technology has been applied to the management of endodontic problems. Tachibana & Matsumoto (1990) published one of the first reports on the application of CT technology in endodontics. They were able to gain additional information on the root canal anatomy and its relationship to vital structures such as the maxillary sinus using reconstructed axial slices and three-dimensional reconstruc-

tion of the CT data. Velvart *et al.* (2001) compared the information derived from CT scans and periapical radiographs of 50 mandibular posterior teeth scheduled for periapical surgery to the clinical findings at the time of surgery. They found that CT detected the presence of an apical lesion and the location of the inferior alveolar nerve in all cases, compared with 78% and 39% respectively with periapical radiographs. Furthermore, additional essential information such as the bucco-lingual thickness of the cortical and cancellous bone, the position and inclination of the root within the mandible could only be assessed using CT. They concluded that CT 'should be considered before the surgical treatment of mandibular premolars and molars when on the dental radiograph the mandibular canal is not visible or in close proximity to the lesion/root'.

Recently, Huuonen *et al.* (2006) assessed the diagnostic value of CT and parallax periapical radiographs of maxillary molar teeth requiring endodontic retreatment. More periapical lesions were detected with CT compared with periapical radiographs. In addition, the distance between the palatal and buccal cortical plates and the root apices could only be determined with CT. Huuonen *et al.* (2006) concluded that the

information obtained from CT was essential for decision making in surgical retreatment, for example, whether to approach the palatal root palatally or buccally. However, one should bear in mind that a very high radiation dose is required to achieve a high enough resolution to assess root canal anatomy in adequate detail with CT.

Computed tomography may also be useful for the diagnosis of poorly localized odontogenic pain. In these circumstances, conventional radiographs of the periapical tissues may not reveal anything untoward. In these cases, CT may confirm the presence of a periapical lesion (Velvart *et al.* 2001). The assessment of the 'third dimension' with CT imaging also allows the number of roots and root canals to be determined, as well as where root canals join or divide. This knowledge is extremely useful when diagnosing and managing failing endodontic treatment. Huuononen *et al.* (2006) found that CT detected 30 of the 39 endodontically treated maxillary molars had two mesio-buccal canals; 27 of these were unfilled of which 22 had periapical lesions. This type of information may be relevant to endodontic retreatment decision making.

The uptake of CT in endodontics has been slow for several reasons, including the high effective dose (Ngan *et al.* 2003) and relatively low resolution of this imaging technique. Other disadvantages of CT are the high costs of the scans, scatter because of metallic objects, poor resolution compared with conventional radiographs and the fact that these machines are only found in dedicated radiography units (for example hospitals). Access may thus be problematic for dentists in practice. CT technology has now become superseded by cone beam computed tomography (CBCT) technology in the management of endodontic problems.

Cone beam computed tomography

Cone beam computed tomography or digital volume tomography is an extra-oral imaging system which was developed in the late 1990s to produce three-dimensional scans of the maxillo-facial skeleton at a considerably lower radiation dose than CT (Arai *et al.* 1999, Mozzo *et al.* 1999). CBCT differs from CT imaging in that the entire three-dimensional volume of data is acquired in the course of a single sweep of the scanner, using a simple, direct relationship between sensor and source which rotate synchronously around the patient's head. Depending on the CBCT scanner used, the X-ray source and the detector rotate between 180° and 360° around the patient's head. Unlike CT

scanners, most CBCT scanners either scan the patient sitting or standing up. The X-ray beam is cone-shaped (hence the name of the technique), and captures a cylindrical or spherical volume of data, described as the field of view (Fig. 14). Voxel size typically ranges between 0.08 and 0.4 mm³.

Its major advantage over CT scanners is the substantial reduction in radiation exposure. This is because of rapid scan times, pulsed X-ray beams and sophisticated image receptor sensors. The pulsed X-ray beam results in up to 570 projection or basis exposures being taken as the X-ray source and detector rotate around the patient. CBCT scanners are simple to use and take up about the same space as panoramic radiographic machines, which make CBCT scanners well suited for dental practice (Scarfe *et al.* 2006). The radiation dose may be further reduced by decreasing the size of the field of view, increasing the voxel size and/or reducing the number of projection images taken as the X-ray source rotates around the patient.

Tomographic slices, as thin as one voxel thick, may be displayed in a number of different ways. Typically, images are displayed in the three orthogonal planes axial, sagittal and coronal simultaneously. Selecting and moving the cursor on one image simultaneously alters the selected reconstructed slices in all three planes, thus allowing the area of interest to be dynamically traversed in 'real time'. Coronal and axial views of the tooth are readily produced, allowing the clinician to gain a truly three-dimensional view of the entire tooth and its surrounding anatomy. Surface rendering is also possible to produce three-dimensional images.

The image quality of CBCT scans is superior to helical CT for assessing the dental hard tissues (Hashimoto *et al.* 2003, 2006, 2007). A recent study compared the image quality of an experimental CBCT scanner to a MSCT scanner and concluded that the CBCT had a higher resolution for detecting small high-contrast (i.e. hard tissue) structures such as 'nerve canals' carrying neurovascular bundles (Bartling *et al.* 2007). A similar conclusion was reached by Hirsch *et al.* (2003) when his group compared limited CBCT with MSCT. However, the lower exposure settings of CBCT results in poor soft-tissue contrast compared with conventional CT.

Cone beam computed tomography is a major breakthrough in dental imaging. For the first time, the clinician is able to use a patient-friendly imaging system to easily view areas of interest in any plane rather than being restricted to the limited views available up to now with conventional radiography. CBCT technology is increasingly being used successfully

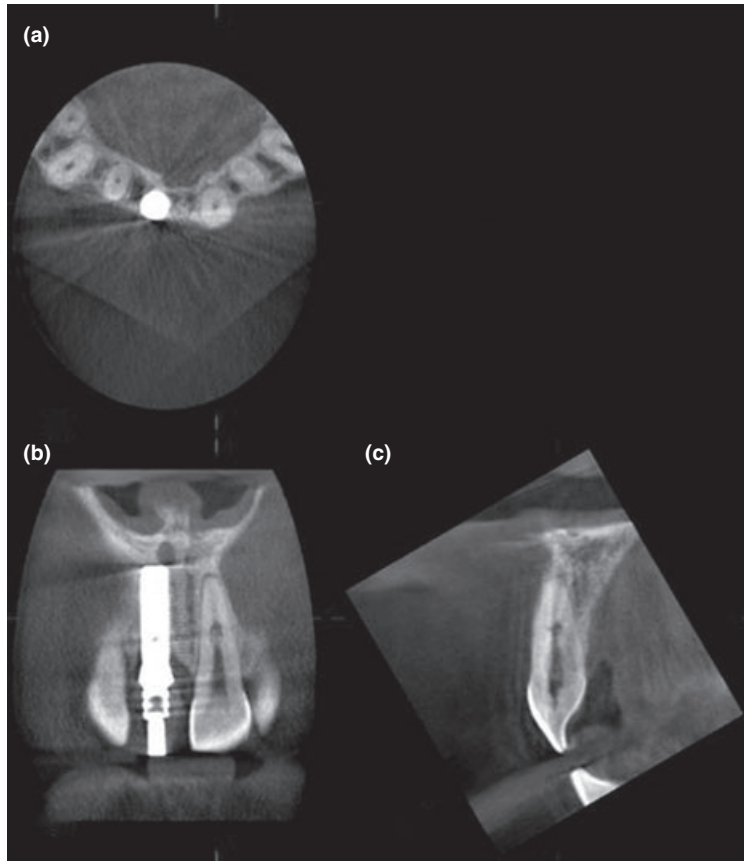


Figure 14 A limited volume CBCT scan using the three-dimensional Accuitomo scanner has been taken of maxillary central incisor region revealing internal resorption of the maxillary left central incisor. The three orthogonal [axial (top left), coronal (bottom left) and sagittal (bottom right)] views can be viewed simultaneously. A considerable amount of data especially from the nonclinical views is obtained from CBCT scans. Compare this with the periapical radiographs in Fig. 4.

for the management of endodontic problems (Cohenca *et al.* 2007, Patel & Dawood 2007, Patel *et al.* 2007).

Part 2 of this review will discuss the technology and endodontic applications of CBCT in detail.

Conclusions

- Even with the best intentions and refined technique, images acquired using conventional intra-oral radiographs reveal information in two-dimensions only (height and width). Valuable and relevant information in the third dimension (depth) is limited.
- Because of the inherent problems of positioning image receptors in the ideal position in relation to the anatomical area of interest, it may not be possible to obtain an accurate, undistorted view of the area of interest.

- The detection and assessment of the true nature of endodontic lesions and other relevant features may be impaired by adjacent anatomical noise. The effect of this anatomical noise is unique for each patient and is dependent on the degree of bone demineralization, size of the endodontic lesion and the physical nature of the anatomical noise (i.e. its thickness, shape and density of the overlying anatomy).
- Serial radiographs taken with the paralleling technique are not always consistently reproducible. This may result in under or over-estimation of actual healing or failure of endodontic treatment.

In certain situations (for example resorptive lesions, periapical surgery assessment) three-dimensional visualization of the endodontic problem is desirable. In these circumstances, three-dimensional imaging provided by CBCT is extremely useful.

Acknowledgements

The authors would like to thank Cavendish Imaging, London, UK.

References

- Arai Y, Tammisalo E, Iwai K, Hashimoto K, Shinoda K (1999) Development of a compact computed tomographic apparatus for dental use. *Dentomaxillofacial Radiology* **28**, 245–8.
- Bartling SH, Majdani O, Gupta R et al. (2007) Large scan field, high spatial resolution flat-panel detector based volumetric CT of the whole human skull base and for maxillofacial imaging. *Dentomaxillofacial Radiology* **36**, 317–27.
- Barton DJ, Clark SJ, Eleazer PD, Scheetz JP, Farman AG (2003) Tuned-aperture computed tomography versus parallax analog and digital radiographic images in detecting second mesiobuccal canals in maxillary first molars. *Oral Surgery, Oral Medicine, Oral Pathology, Oral Radiology and Endodontics* **96**, 223–8.
- Bender IB, Seltzer S (1961) Roentgenographic and direct observation of experimental lesions in bone: I. *Journal of the American Dental Association* **62**, 152–60.
- Brynolf I (1967) A histological and roentgenological study of the periapical region of human upper incisors. *Odontologisk Revy* **18** (Suppl. 11), 1–176.
- Brynolf I (1970) Roentgenologic periapical diagnosis IV. When is one roentgenogram not sufficient? *Swedish Dental Journal* **63**, 415–23.
- Cohenca N, Simon JH, Roges R, Morag Y, Malfaz JM (2007) Clinical indications for digital imaging in dento-alveolar trauma. Part 1: traumatic injuries. *Dental Traumatology* **23**, 95–104.
- Cotti E, Campisi G (2004) Advanced radiographic techniques for the detection of lesions in bone. *Endodontic Topics* **7**, 52–72.
- Cotti E, Vargiu P, Dettori C, Mallarini G (1999) Computerized tomography in the management and follow-up of extensive periapical lesion. *Endodontics and Dental Traumatology* **15**, 186–9.
- Cotti E, Campisi G, Garau V, Puddu G (2002) A new technique for the real study of periapical lesions: ultrasound real time imaging. *International Endodontic Journal* **35**, 148–52.
- Cotti E, Campisi G, Ambu R, Dettori C (2003) Ultrasound real-time imaging in the differential diagnosis of periapical lesions. *International Endodontic Journal* **36**, 556–63.
- Duckworth JE, Judy PF, Goodson JM, Socransky SS (1983) A method for the geometric and densitometric standardization of intraoral radiographs. *Journal of Periodontology* **54**, 435–40.
- Eggars G, Ricker M, Kress J, Fiebach J, Dickhaus H, Hassfeld S (2005) Artefacts in magnetic resonance imaging caused by dental material. *Magnetic Resonance Materials in Physics, Biology and Medicine* **18**, 103–11.
- Flores MT, Andreasen JO, Bakland LK et al. (2007a) Guidelines for the management of traumatic dental injuries. I. Fractures and luxations of permanent teeth. *Dental Traumatology* **2**, 66–71.
- Flores MT, Andreasen JO, Bakland LK et al. (2007b) Guidelines for the management of traumatic dental injuries. II. Avulsions of permanent teeth. *Dental Traumatology* **2**, 72–5.
- Forsberg J (1987a) Radiographic reproduction of endodontic 'working length' comparing the paralleling and the bisecting-angle techniques. *Oral Surgery, Oral Medicine, Oral Pathology, Oral Radiology and Endodontics* **64**, 353–60.
- Forsberg J (1987b) A comparison of the paralleling and bisecting-angle radiographic techniques in endodontics. *International Endodontic Journal* **20**, 177–82.
- Forsberg J (1987c) Estimation of the root filling length with paralleling and bisecting-angle radiographic techniques performed by undergraduate students. *International Endodontic Journal* **20**, 282–6.
- Forsberg J, Halse A (1994) Radiographic simulation of a periapical lesion comparing the paralleling and the bisecting-angle techniques. *International Endodontic Journal* **27**, 133–8.
- Friedman S (2002) Prognosis of initial endodontic therapy. *Endodontic Topics* **2**, 59–98.
- Glickman GW, Pettiette MT (2006) Chapter 5. Preparation for treatment. In: Cohen S, Hargreaves KM, eds. *Pathways of the Pulp*, 9th edn. St. Louis, MI: Mosby Elsevier, pp. 97–135.
- Goldman M, Pearson AH, Darzenta M (1972) Endodontic success – who's reading the radiograph? *Oral Surgery, Oral Medicine, Oral Pathology* **33**, 432–7.
- Goto TK, Nishida S, Nakamura Y et al. (2007) The accuracy of three-dimensional magnetic resonance 3D vibe images of the mandible: an in vitro comparison of magnetic resonance imaging and computed tomography. *Oral Surgery, Oral Medicine, Oral Pathology, Oral Radiology and Endodontology* **103**, 550–9.
- Gröndahl H-G, Huuonen S (2004) Radiographic manifestations of periapical inflammatory lesions. *Endodontic Topics* **8**, 55–67.
- Gundappa M, Ng SY, Whaites EJ (2006) Comparison of ultrasound, digital and conventional radiography in differentiating periapical lesions. *Dentomaxillofacial Radiology* **35**, 326–33.
- Hashimoto K, Yoshinori Y, Iwai K et al. (2003) A comparison of a new limited cone beam computed tomography machine for dental use with a multidetector row helical CT machine. *Oral Surgery, Oral Medicine, Oral Pathology, Oral Radiology and Endodontology* **95**, 371–7.
- Hashimoto K, Kawashima S, Araki M, Sawada K, Akiyama Y (2006) Comparison of image performance between cone-beam computed tomography for dental use and four-row multidetector helical CT. *Journal of Oral Science* **48**, 27–34.
- Hashimoto K, Kawashima S, Kameoka S et al. (2007) Comparison of image validity between cone beam computed

- tomography for dental use and multidetector row helical computed tomography. *Dentomaxillofacial Radiology* **36**, 465–71.
- Hirsch E, Graf H-L, Hemprich A (2003) Comparative investigation of image quality of three different X-ray procedures. *Dentomaxillofacial Radiology* **32**, 201–11.
- Horner K, Rout PGJ, Rushton VE (2002) *Interpreting Dental Radiographs*, 1st edn. London, UK: Quintessence.
- Huomonen S, Ørstavik D (2002) Radiological aspects of apical periodontitis. *Endodontic Topics* **1**, 3–25.
- Huomonen S, Kvist T, Grondahl K, Molander A (2006) Diagnostic value of computed tomography in re-treatment of root fillings in maxillary teeth. *International Endodontic Journal* **39**, 827–33.
- Imamura H, Sato H, Matsuura T, Ishikawa M, Zezé R (2004) A comparative study of computed tomography and magnetic resonance imaging for the detection of mandibular canals and cross-sectional areas in diagnosis prior to dental implant treatment. *Clinical Implant Dentistry and Related Research* **6**, 75–81.
- Kullendorff B, Nilsson M (1996) Diagnostic accuracy of direct digital dental radiography for the detection of periapical bone lesions – II. Effects on diagnostic accuracy after application of image processing. *Oral Surgery, Oral Medicine, Oral Pathology, Oral Radiology and Endodontics* **82**, 585–9.
- Kullendorff B, Nilsson M, Rohlin M (1996) Diagnostic accuracy of direct digital dental radiography for the detection of periapical bone lesions – overall comparison between conventional and direct digital radiography. *Oral Surgery, Oral Medicine, Oral Pathology, Oral Radiology and Endodontics* **82**, 344–50.
- Kundel HL, Revesz G (1976) Lesion conspicuity, structured noise, and film reader error. *American Journal of Roentgenology* **126**, 1233–8.
- Lee S-J, Messer HH (1986) Radiographic appearance of artificially prepared periapical lesions confined to cancellous bone. *International Endodontic Journal* **19**, 64–72.
- Lofthag-Hansen S, Huomonen S, Gröndahl K, Gröndahl H-G (2007) Limited cone-beam CT and intraoral radiography for the diagnosis of periapical pathology. *Oral Surgery, Oral Medicine, Oral Pathology, Oral Radiology and Endodontology* **103**, 114–9.
- Low MTL, Dula KD, Bürgin W, von Arx T (2008) Comparison of periapical radiography and limited cone-beam tomography in posterior maxillary teeth referred for apical surgery. *Journal of Endodontics* **34**, 557–62.
- Manogue M, Patel S, Walker R (2005) Chapter A3. Diagnosis and treatment planning. In: *The Principles of Endodontics*, 1st edn. Oxford: Oxford University Press.
- Marmary Y, Koter T, Heling I (1999) The effect of periapical rarefying osteitis on cortical and cancellous bone. A study comparing conventional radiographs with computed tomography. *Dentomaxillofacial Radiology* **28**, 267–71.
- Monsour PA, Dudhia R (2008) Implant radiography and radiology. *Australian Dental Journal* **53**(1 Suppl), S11–25.
- Matherne RP, Angelopoulos C, Kulilid JC, Tira D (2008) Use of cone-beam computed tomography to identify root canal systems *in vitro*. *Journal of Endodontics* **34**, 87–9.
- Morgan RH (1965) Visual perception in fluoroscopy and radiology. *Radiology* **86**, 403–16.
- Mozzo P, Procacci C, Tacconi A, Martini PT, Andreis IA (1999) A new volumetric CT machine for dental imaging based on the cone-beam technique: preliminary results. *European Radiology* **8**, 1558–64.
- Nair MK, Nair UP (2007) Digital and advanced imaging in endodontics: a review. *Journal of Endodontics* **33**, 1–6.
- Nair PNR, Pajarola G, Schroeder HE (1996) Types and incidence of human periapical lesions obtained with extracted teeth. *Oral Surgery, Oral Medicine, Oral Pathology, Oral Radiology and Endodontics* **81**, 93–102.
- Nair MK, Tyndall DA, Ludlow JB, May K, Ye F (1998) The effects of restorative material and location on the detection of simulated recurrent caries. A comparison of dental film, direct digital radiography and tuner aperture computed tomography. *Dentomaxillofacial Radiology* **27**, 80–4.
- Nair MK, Nair UP, Gröndahl H-G, Webber RL, Wallace JA (2001) Detection of artificially induced vertical radicular fractures using tuned aperture computed tomography. *European Journal of Oral Science* **109**, 375–9.
- Nair MK, Gröndahl H-G, Webber RL, Nair UP, Wallace JA (2003) Effect of iterative restoration on the detection of artificially induced vertical radicular fractures by tuned aperture computed tomography. *Oral Surgery, Oral Medicine, Oral Pathology, Oral Radiology and Endodontology* **96**, 118–25.
- Nance R, Tyndall D, Levin LG, Trope M (2000) Identification of root canals in molars by tuned-aperture computed tomography. *International Endodontic Journal* **33**, 392–6.
- Ngan DCS, Kharbanda OP, Geenty JP, Darendeliler MA (2003) Comparison of radiation levels from computed tomography and conventional dental radiographs. *Australian Dental Journal* **19**, 67–75.
- Patel S, Dawood A (2007) The use of cone beam computed tomography in the management of external cervical resorption lesions. *International Endodontic Journal* **40**, 730–7.
- Patel S, Pitt Ford T (2007) Is the resorption external or internal? *Dental Update* **34**, 218–29.
- Patel S, Dawood A, Whaites E, Pitt Ford T (2007) The potential applications of cone beam computed tomography in the management of endodontic problems. *International Endodontic Journal* **40**, 818–30.
- Paurazas SB, Geist JR, Pink FE, Hoen MM, Steiman HR (2000) Comparison of diagnostic accuracy of digital imaging by using CCD and CMOS_APS sensors with E-speed film in the detection of periapical lesions. *Oral Surgery, Oral Medicine, Oral Pathology, Oral Radiology and Endodontology* **89**, 356–62.
- Pitt Ford TR (1984) Radiographic detection of periapical lesions in dogs. *Oral Surgery, Oral Medicine, Oral Pathology* **57**, 662–7.

- Revesz G, Kundel HL, Graber MA (1974) The influence of structured noise on the detection of radiologic abnormalities. *Investigative Radiology* **6**, 479–86.
- Rudolph DJ, White SC (1988) Film-holding instruments for intraoral subtraction radiography. *Oral Surgery, Oral Medicine, Oral Pathology* **65**, 767–72.
- Scarfe WC, Czerniejewski VJ, Farman AG, Avant SL, Molteni R (1999) In vivo accuracy and reliability of color-coded image enhancements for the assessment of periradicular lesion dimensions. *Oral Surgery, Oral Medicine, Oral Pathology, Oral Radiology and Endodontology* **88**, 603–11.
- Scarfe WC, Farman AG, Sukovic P (2006) Clinical applications of cone-beam computed tomography in dental practice. *Journal of the Canadian Dental Association* **72**, 75–80.
- Schwartz SF, Foster JK (1971) Roentgenographic interpretation of experimentally produced bony lesions. Part 1. *Oral Surgery, Oral Medicine, Oral Pathology* **32**, 606–12.
- Shoha RR, Dowson J, Richards AG (1974) Radiographic interpretation of experimentally produced bony lesions. *Oral Surgery, Oral Medicine, Oral Pathology, Oral Radiology and Endodontics* **38**, 294–303.
- Sukovic P (2003) Cone beam computed tomography in craniofacial imaging. *Orthodontic Craniofacial Research* **6**(Suppl. 1), 31–6.
- Tachibana H, Matsumoto K (1990) Applicability of X-ray computerized tomography in endodontics. *Endodontics and Dental Traumatology* **6**, 16–20.
- Tutton LM, Goddard PR (2002) MRI of the teeth. Pictorial review. *British Journal of Radiology* **75**, 552–62.
- Tyndall DA, Clifton TL, Webber RL, Ludlow JB, Horton RA (1997) TACT imaging of primary caries. *Oral Surgery, Oral Medicine, Oral Pathology, Oral Radiology and Endodontology* **84**, 214–25.
- Vande Voorde HE, Bjorndahl AM (1969) Estimated endodontic “working length” with paralleling radiographs. *Oral Surgery, Oral Medicine, Oral Pathology, Oral Radiology* **27**, 106–10.
- Velvart P, Hecker H, Tillinger G (2001) Detection of the apical lesion and the mandibular canal in conventional radiography and computed tomography. *Oral Surgery, Oral Medicine, Oral Pathology and Endodontology* **92**, 682–8.
- Walker RT, Brown JE (2005) Chapter 4. Radiography. In: Stock C, Walker R, Gulabivala K, eds. *Endodontics*, 3rd edn. Philadelphia, PA, USA: Mosby, pp. 77–92.
- Webber RL, Messura JK (1999) An in vivo comparison of digital information obtained from tuned-aperture computed tomography and conventional dental radiographic imaging modalities. *Oral Surgery, Oral Medicine, Oral Pathology, Oral Radiology and Endodontology* **88**, 239–47.
- Webber RL, Horton RA, Underhill TE, Ludlow JB, Tyndall DA (1996) Comparison of film, direct digital, and tuned-aperture computed tomography images to identify the location of crestal defects around endosseous titanium implants. *Oral Surgery, Oral Medicine, Oral Pathology, Oral Radiology and Endodontics* **81**, 480–90.
- Wenzel A (2006) A review of dentists’ use of digital radiography and caries diagnosis with digital systems. *Dentomaxillofacial Surgery* **35**, 307–14.
- Whaites E (2007a) Chapter 10. Periapical radiography. In: *Essentials of Dental Radiology and Radiography*, 4th edn. Philadelphia, PA, USA: Churchill Livingstone Elsevier.
- Whaites E (2007b) Chapter 19. Alternative and specialized imaging modalities. In: *Essentials of Dental Radiology and Radiography*, 4th edn. Philadelphia, PA, USA: Churchill Livingstone Elsevier.
- White S, Pharaoh M (2004) Chapter 13. Advanced Imaging Modalities. *Oral Radiology: Principles and Interpretation*, 5th edn. St Louis, MO: Mosby.